Dermatopathology

Diagnosis by First Impression

www.ebook3000.com

To Ulla, Anna, Jessica, and Sara who let me pursue
my career while they took care of everything else. (RJB)

To Peter, Dylan, and Owen. (CJK)

www.ebook3000.com

Dermatopathology

Diagnosis by First Impression

Third Edition

Christine J. Ko
Professor of Dermatology and Pathology
Yale University School of Medicine
New Haven, CT, USA

Ronald J. Barr
Dermatopathologist
Laguna Pathology Medical Group
Laguna Beach, CA
and
Professor Emeritus, Dermatology and Pathology
University of California
Irvine, CA, USA

WILEY Blackwell

www.ebook3000.com

This edition first published 2017 © 2017 by John Wiley & Sons, Ltd
First edition 2008 © 2008 Christine J. Ko and Ronald J. Barr
Second edition 2011 © 2011 John Wiley & Sons, Ltd

Registered office: John Wiley & Sons, Ltd, The Atrium, Southern Gate, Chichester, West Sussex, PO19 8SQ, UK
Editorial offices: 9600 Garsington Road, Oxford, OX4 2DQ, UK
The Atrium, Southern Gate, Chichester, West Sussex, PO19 8SQ, UK
1606 Golden Aspen Drive, Suites 103 and 104, Ames, Iowa 50010, USA

For details of our global editorial offices, for customer services and for information about how to apply for permission to reuse the copyright material in this book please see our website at www.wiley.com/wiley-blackwell

The right of the author to be identified as the author of this work has been asserted in accordance with the UK Copyright, Designs and Patents Act 1988.

All rights reserved. No part of this publication may be reproduced, stored in a retrieval system, or transmitted, in any form or by any means, electronic, mechanical, photocopying, recording or otherwise, except as permitted by the UK Copyright, Designs and Patents Act 1988, without the prior permission of the publisher.

Designations used by companies to distinguish their products are often claimed as trademarks. All brand names and product names used in this book are trade names, service marks, trademarks or registered trademarks of their respective owners. The publisher is not associated with any product or vendor mentioned in this book. It is sold on the understanding that the publisher is not engaged in rendering professional services. If professional advice or other expert assistance is required, the services of a competent professional should be sought.

The contents of this work are intended to further general scientific research, understanding, and discussion only and are not intended and should not be relied upon as recommending or promoting a specific method, diagnosis, or treatment by health science practitioners for any particular patient. The publisher and the author make no representations or warranties with respect to the accuracy or completeness of the contents of this work and specifically disclaim all warranties, including without limitation any implied warranties of fitness for a particular purpose. In view of ongoing research, equipment modifications, changes in governmental regulations, and the constant flow of information relating to the use of medicines, equipment, and devices, the reader is urged to review and evaluate the information provided in the package insert or instructions for each medicine, equipment, or device for, among other things, any changes in the instructions or indication of usage and for added warnings and precautions. Readers should consult with a specialist where appropriate. The fact that an organization or Website is referred to in this work as a citation and/or a potential source of further information does not mean that the author or the publisher endorses the information the organization or Website may provide or recommendations it may make. Further, readers should be aware that Internet Websites listed in this work may have changed or disappeared between when this work was written and when it is read. No warranty may be created or extended by any promotional statements for this work. Neither the publisher nor the author shall be liable for any damages arising herefrom.

Library of Congress Cataloging-in-Publication Data

Names: Ko, Christine J., author. | Barr, Ronald J. (Dermatopathologist), author.
Title: Dermatopathology : diagnosis by first impression / Christine J. Ko, Ronald J. Barr.
Description: Third edition. | Oxford, UK ; Ames, Iowa : John Wiley & Sons, Inc., 2017. | Includes indexes.
Identifiers: LCCN 2016016543 (print) | LCCN 2016017183 (ebook) | ISBN 9781119149453 (pbk.) |
ISBN 9781119149460 (pdf) | ISBN 9781119149477 (epub)
Subjects: | MESH: Skin Diseases—diagnosis | Skin Diseases—pathology | Skin—pathology | Microscopy | Atlases
Classification: LCC RL96 (print) | LCC RL96 (ebook) | NLM WR 17 | DDC 616.5/075—dc23
LC record available at https://lccn.loc.gov/2016016543

ISBN 9781119149453

A catalogue record for this book is available from the British Library.

Wiley also publishes its books in a variety of electronic formats. Some content that appears in print may not be available in electronic books.

Set in 9/12pt Frutiger LT Std by Aptara Inc., New Delhi, India

1 2017

www.ebook3000.com

Contents

Preface, vi
Acknowledgments, vii
About the Companion Website, viii

Introduction, 1

Chapter 1 Shape on Low Power, 23
Epidermis
- Regular acanthosis, 25
- Lobular proliferation, 29
- Reticulated proliferation, 35
- Central pore, 42
- Epidermal perforation, 46

Dermis
- Circular islands, 49
- Cords/tubules and comma shapes, 53
- Space with a lining, 59
- Papillations, 70
- Polypoid (dome-shaped), 77
- Square/rectangular, 82
- Palisading reactions, 88
- Pseudoepitheliomatous hyperplasia above abscesses, 93
- Pink ball, (see Chapter 6)

Chapter 2 Gestalt: Rash/inflammatory, 97
Epidermal changes
- Parakeratosis, 99
- Spongiosis, 102
- Papulosquamous (psoriasiform), 106
- Interface (vacuolar), 112
- Interface (lichenoid), 117

Inflammation: Specific patterns and Cell Type
- Epidermal eosinophils, 123
- Perivascular, 127
- Band-like dermal/papillary dermal infiltrate, 131
- Diffuse/nodular, 137
- Subcutaneous, 144

Chapter 3 Cell Type, 153
Melanocytic, 155
Spindle cells, 164
Endothelial, 178
Giant, 192
Clear, 202

Chapter 4 "Top-Down", 219
Hyperkeratosis/parakeratosis, 221
Upper epidermal change, 228
Acantholysis, 238
Subepidermal space/cleft, 248
Granular "material" in cells, 255
"Busy" dermis, 260
Dermal material, 263
Fat necrosis, 276

Chapter 5 Color – Blue, 279
Blue tumor, 281
Mucin and glands or ducts, 291
Mucin, 295

Chapter 6 Color – Pink, 303
Pink ball of spindle cells, 305
Pink material, 308
Pink dermis, 315
Epidermal necrosis, 317

Index (Pattern), 323
Index (Histological Category), 329
Index (Alphabetical), 333

www.ebook3000.com

Preface

The purpose of this book is to focus on a selection of commonly tested entities, showing low to high power views. Major differences among diagnoses that are sometimes confused are emphasized on Key Differences pages to help train the eye to rapidly notice distinctive features. As a picture is worth a thousand words, text is kept to a minimum. This book should be used as a companion to dermatopathology textbooks and as a pictorial reference/study tool, given that this approach is utilized by the experienced dermatopathologist when constructing examination questions. Often the major distractors are based on gestalt rather than etiology or conventional classifications. It is often the lookalikes that are the most deceptive even though they have no obvious relationship to the correct diagnosis. This book will also be helpful to the dermatopathology novice as it introduces a simple and effective way to approach a slide, and to that end, common diagnoses have been specifically included (i.e. actinic keratosis, basal cell carcinoma).

www.ebook3000.com

Acknowledgments

Dr. James H. Graham, MD, master of dermatopathology and dermatology, who taught me most of what I know.

Ronald J. Barr

Dr. Ronald Barr, Dr. Scott Binder, my dermatopathology colleagues at Yale (Dr. Jennifer McNiff, Dr. Earl Glusac, Dr. Rossitza Lazova, Dr. Shawn Cowper, Dr. Antonio Subtil, Dr. Anjela Galan, Dr. Marcus Bosenberg, and Dr. Peggy Myung), Dr. Jean Bolognia – their insights over the years have been invaluable. We also acknowledge the residents at Yale, those in Thailand, and Hadas Skupsky, who rotated with Dr. Barr; all of whom gave constructive feedback on how to improve the atlas for this edition. Thanks are also due to the team at Wiley Blackwell for all their efforts to improve the atlas.

Christine J. Ko

www.ebook3000.com

About the Companion Website

This book is accompanied by a companion website:

www.wiley.com/go/ko/dermatopathology3e

The website includes:

- Interactive multiple choice questions
- PowerPoints of all figures from the book for downloading

www.ebook3000.com

Introduction

Recognizing a disease process on a histopathologic slide becomes instantaneous, with increasing familiarity. Breaking this process down into the "how" is difficult, especially given that the steps may not be the same for each individual. Nonetheless, on a basic level, it is important to separate a solitary growth ("tumor" or "lesion") from a rash ("inflammatory" process; Figures 1–3), focus on the most obvious pathologic finding, and run through a differential diagnosis. With experience, that "obvious" pathologic finding (i.e. where to start) becomes second nature. The diseases in this atlas are grouped, arbitrarily, by such findings (see the Index by Pattern). Notably, basic algorithms are ultimately overly simplistic, and there is overlap of the two major divisions in Figure 1 (tumor versus rash). For example, clear cell acanthoma can architecturally mimic psoriasis, mycosis fungoides can appear to be a dermatitis, and epithelioid sarcoma can be confused with a palisading granulomatous process.

Key concepts in cognitive psychology come into play during visual recognition, and having some understanding of how the brain processes visual information can be helpful in training the eye to see (Table 1). In figure-ground separation, the brain focuses on a perceived figure and tends to ignore the background. Thus, an important initial step in diagnosing disease when viewing microscopic slides is to train the brain to accurately identify the most important features ("figure"). In order to make sense of visual stimuli, the brain also automatically groups information. With all else being equal, similar objects will be grouped together, closer objects will be grouped together, and objects perceived as having a similar color/texture or common enclosure ("common region") will be grouped together. Clues such as body site (Figure 4) and absence of obvious pathology (Figure 5 and Table 2) can also be useful.

Table 1 Visual recognition in dermatopathology as related to cognitive psychology.

Dermatopathology		Cognitive psychology concept
Overview (2×/4× ocular)	• "Tumor" versus "Rash" – Architecture – Body site – Cell type	• Gestalt – Figure-ground separation – Grouping
Higher magnification (10×/20×/40× ocular)	• Confirm cell type/morphology • Finer details of architecture	• Grouping using finer details – Similarity – Proximity – Common region

Dermatopathology: Diagnosis by First Impression, Third Edition. By Christine J. Ko and Ronald J. Barr.
© 2017 John Wiley & Sons, Ltd. Published 2017 by John Wiley & Sons, Ltd.
Companion website: www.wiley.com/go/ko/dermatopathology3e

www.ebook3000.com

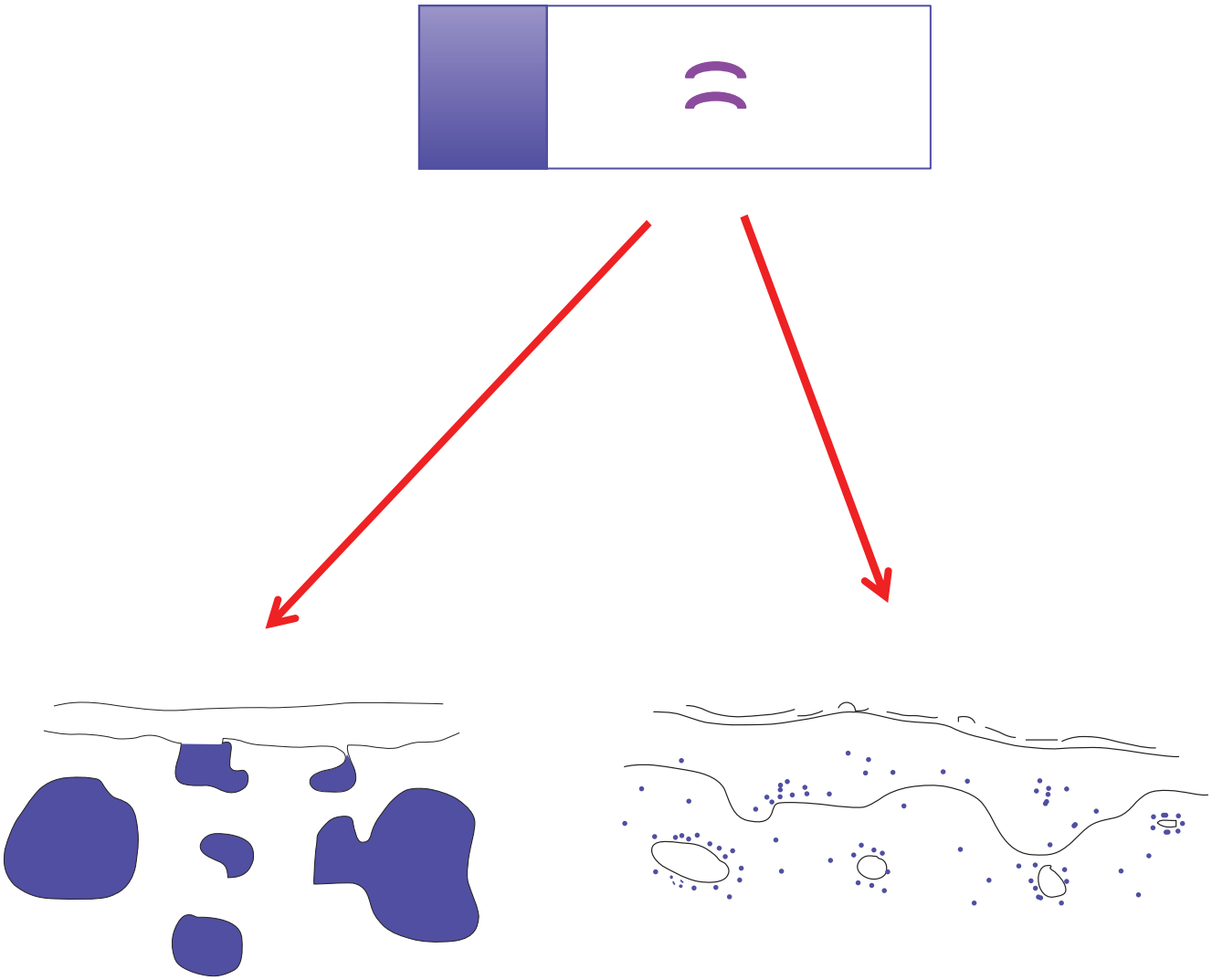

Tumor/Growth
- Location (Figure 2A)
- Architecture (Figure 2B; see Chapter 1)
- Cell type (Figure 2C and D; see Chapter 3)
- Other clues, including color (see Chapters 4–6)

Rash/inflammatory (see Chapter 2)
- Epidermal changes (Figure 3A)
- Distribution of inflammation (Figure 3B)
- Cell type (Figure 3C)
- Other clues (see Chapters 3–6)

Figure 1 Gestalt impression of a slide
- A major initial breakpoint in evaluating a specimen on a slide is the determination of the type of process: tumor/growth versus rash/inflammatory

Note In some cases, it is not readily apparent if the process is a tumor or an inflammatory process (examples include mycosis fungoides, a form of cutaneous T-cell lymphoma, as well as deep fungal infections, which can induce florid epidermal hyperplasia mimicking a squamous cell carcinoma).

www.ebook3000.com

Epidermal

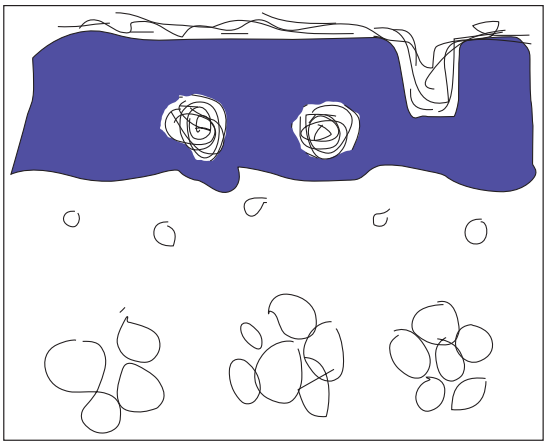

Dermal

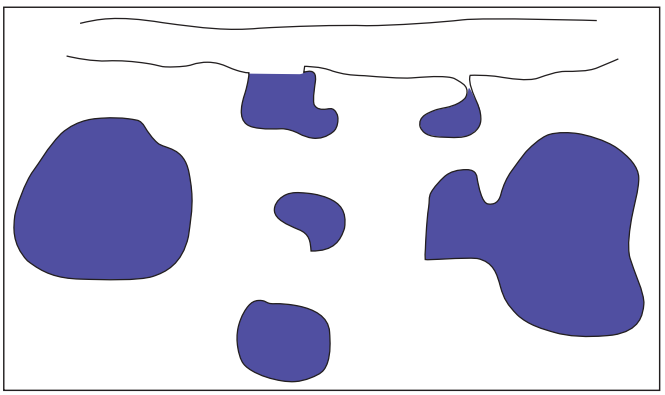

Subcutaneous

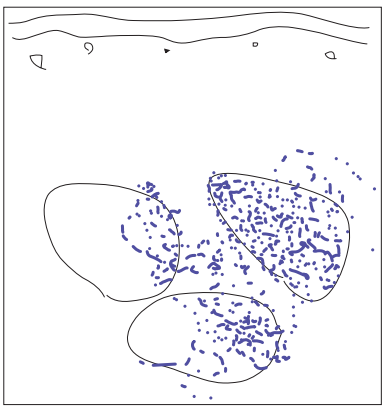

Figure 2(A) Location of the tumor

- Important characteristics to consider for a tumor/growth include location (A), architecture (B), cell type (C), and benignancy versus malignancy (D). The eye can be trained to focus in on the blue areas (figure-ground separation; grouping)

Regular acanthosis

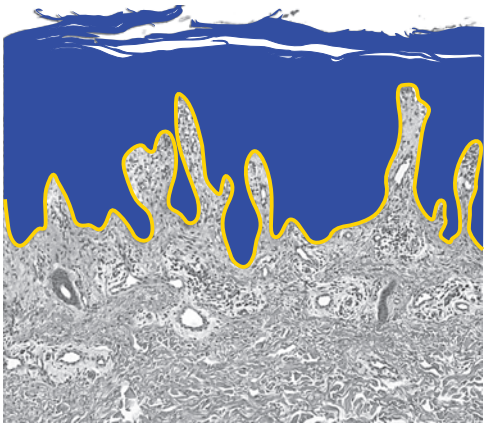

Lobular proliferation

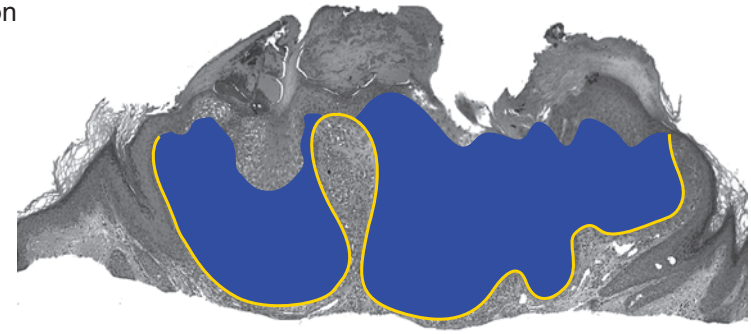

Central pore

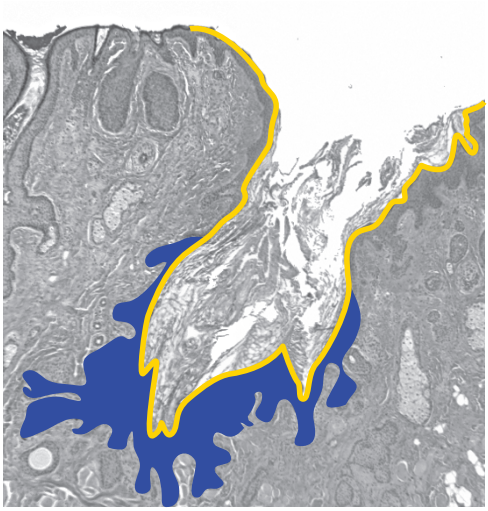

Figure 2(B) Architecture of an epidermal tumor/process

Circular islands

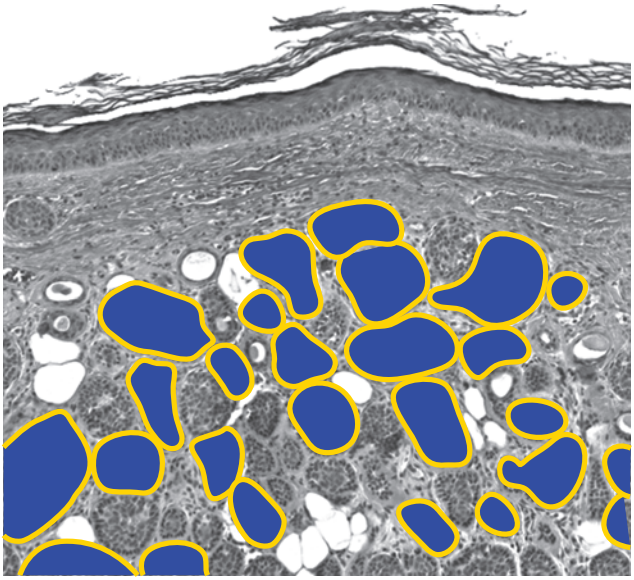

Cords/tubules and comma shapes

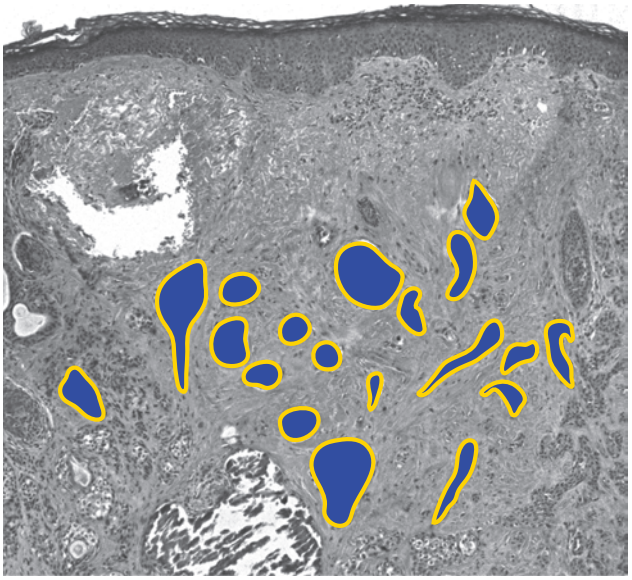

Space with a lining

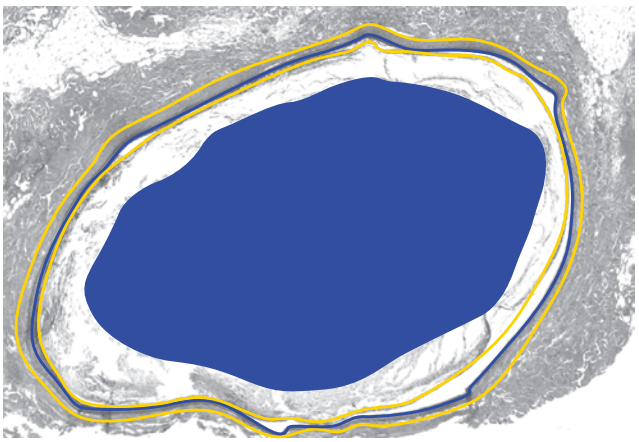

Papillations

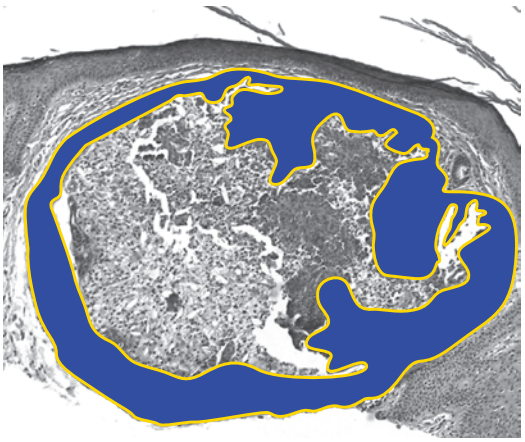

Figure 2(B), *continued*

- Dermal tumors can have various architectural patterns

Note Benign tumors are often symmetric with a pushing border, and malignant tumors may be asymmetric and infiltrative.

Polypoid (dome-shaped)

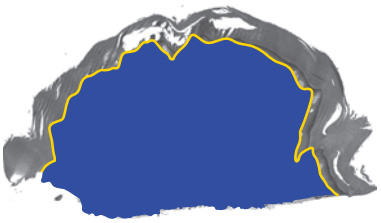

Square/rectangular



Palisading reactions

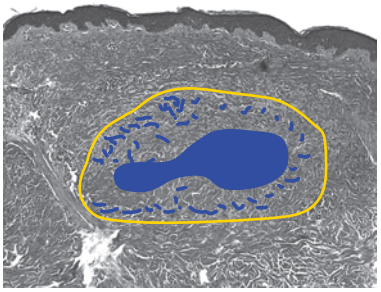

Pseudoepitheliomatous hyperplasia above abscesses

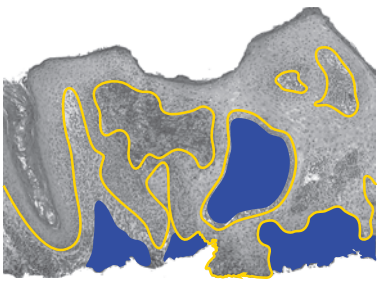

Figure 2(B), ***continued***

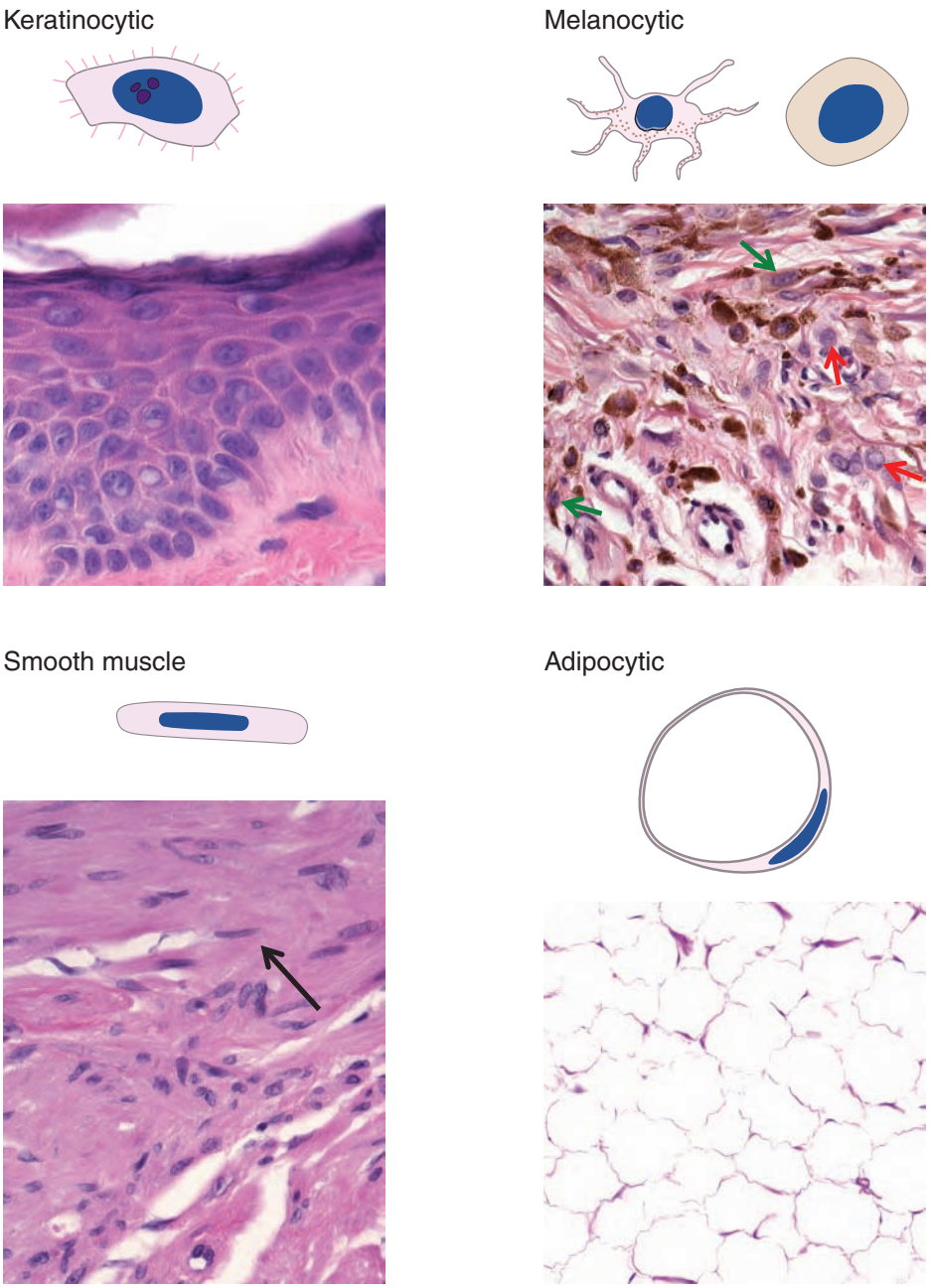

Figure 2(C) Different tumors are predominantly composed of a particular cell type

- Keratinocytic: rectangular/polygonal shape, intercellular bridges, round nucleus and small nucleolus
- Melanocytic: may be nested/clustered; nevomelanocyte (red arrow): oval nuclei, small nucleolus, pseudonuclear inclusions or melanin pigment may be evident; dendritic melanocyte (green arrow): thin cytoplasmic processes extending away from cell center
- Smooth muscle: spindle cell with abundant cytoplasm, perinuclear clear space, cigar-shaped nucleus
- Adipocytic: thin membrane with compressed nucleus

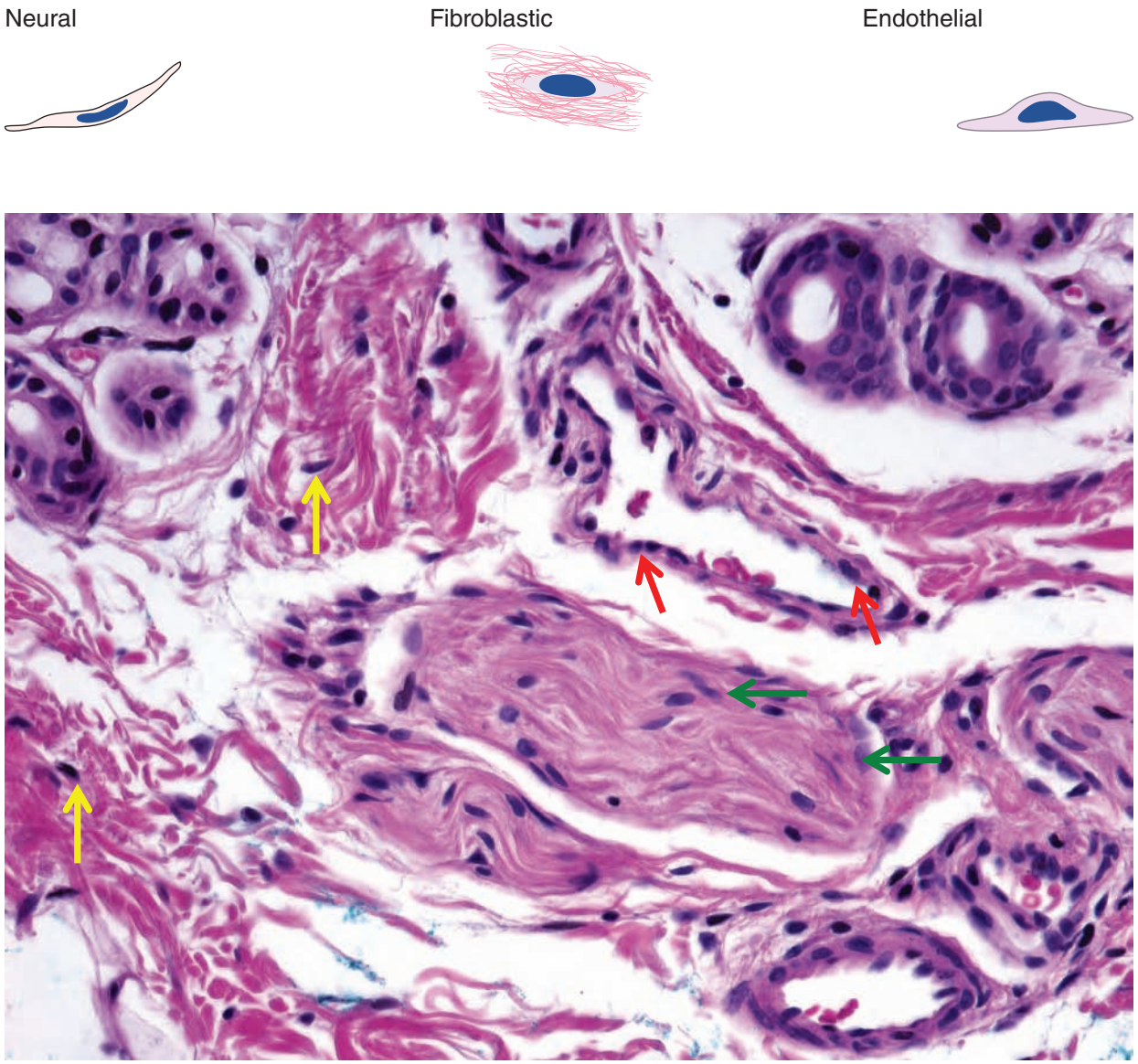

Figure 2(C), *continued*

- Neural: spindle cell with tapered nucleus, pink cytoplasm (green arrows)
- Fibroblast: spindle cell with oval nucleus (yellow arrows)
- Endothelial: blue nuclei surrounding vascular spaces (red arrows)

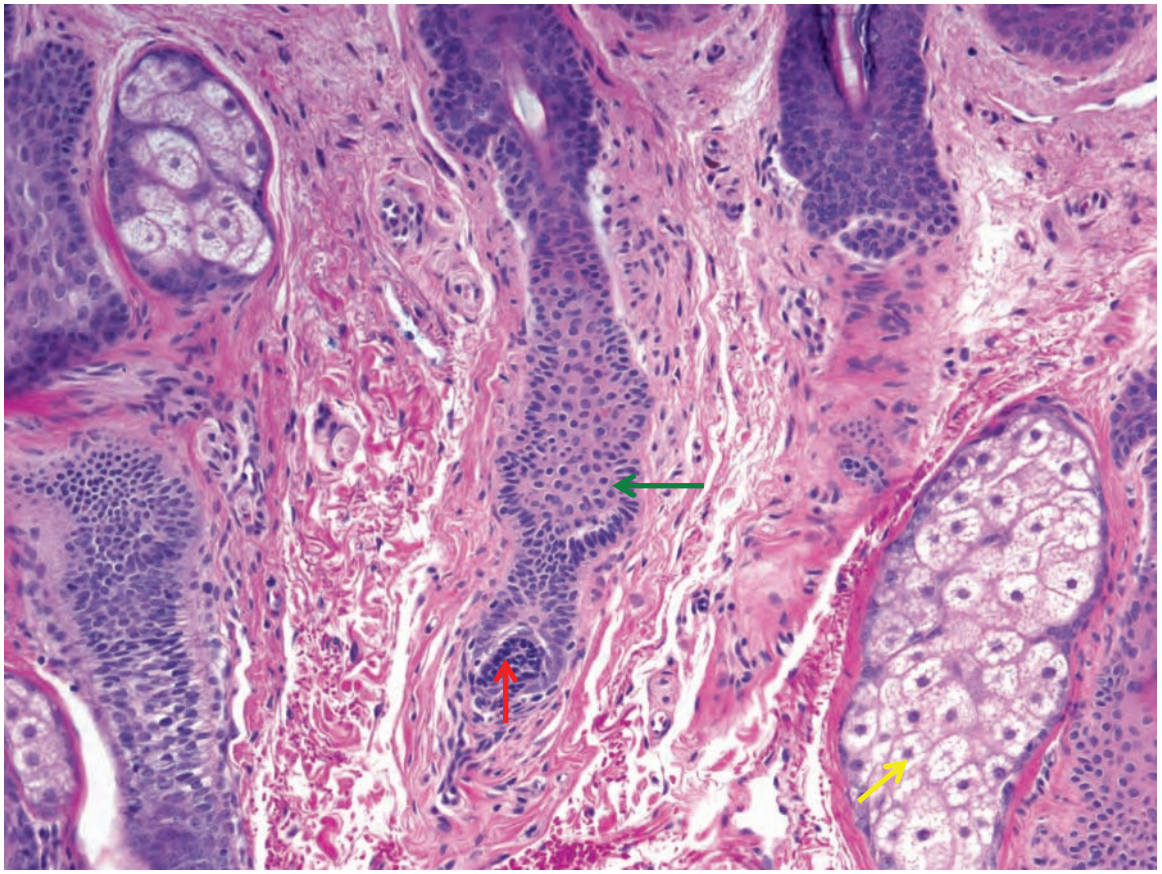

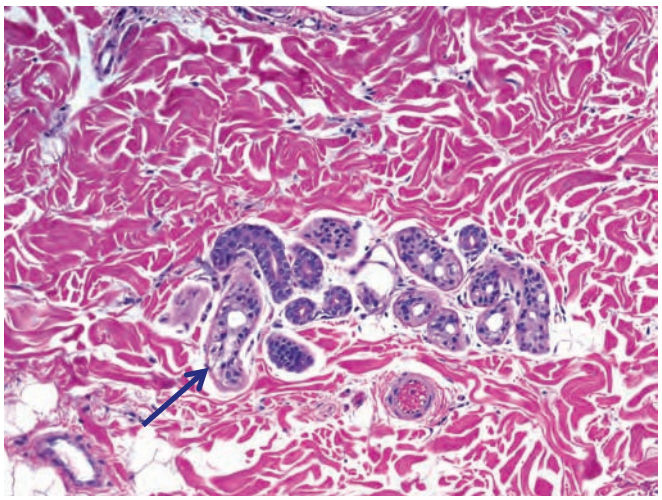

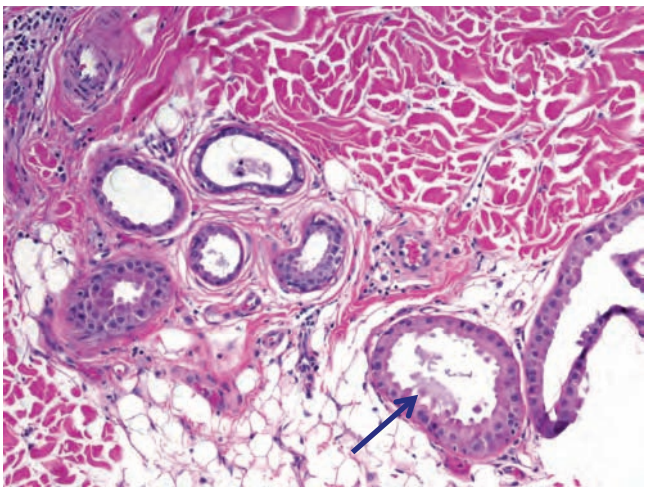

Figure 2(C), *continued*

- Hair follicle: matrical cells are round to oval and dark blue (red arrow); outer root sheath cells are pale pink (green arrow)
- Sebocytes: bubbly cytoplasm (yellow arrow) and central nucleus that may be star-shaped (scalloped)
- Eccrine gland and duct: the gland has clear cells (blue arrow); the duct has an eosinophilic pink cuticle
- Apocrine gland and duct: the gland often shows decapitation secretion (black arrow)

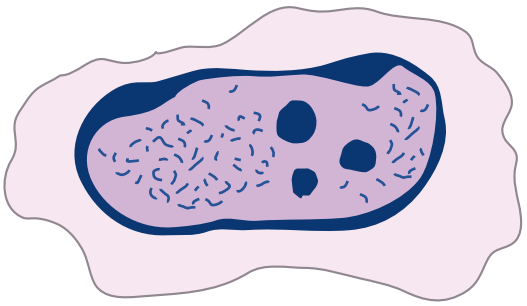

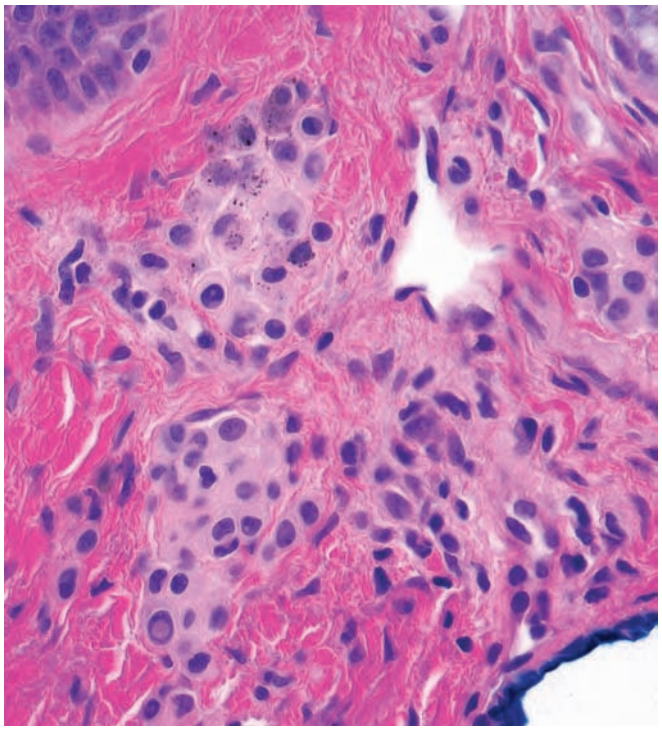

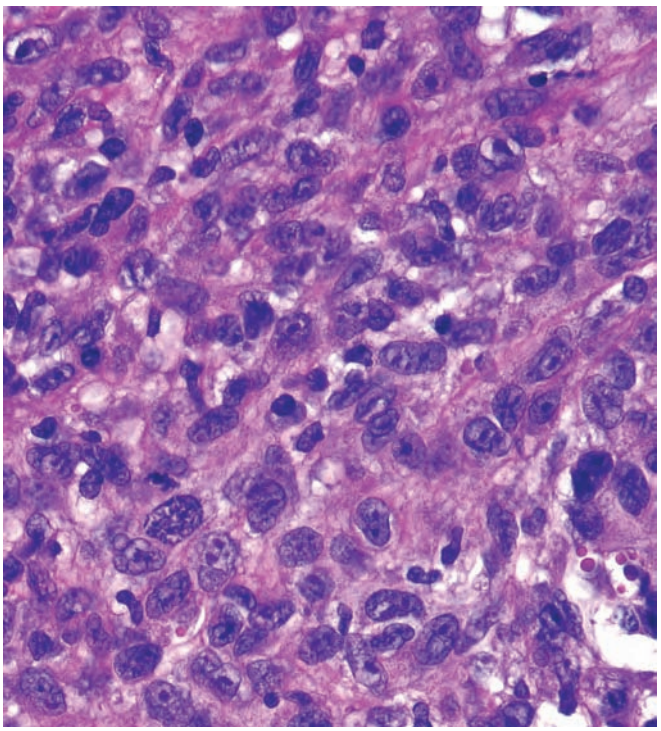

Figure 2(D) Cytologic features are important in pointing toward a benign versus malignant tumor

- Malignant cells have high nuclear: cytoplasmic ratio, irregular chromatin pattern, irregular nuclear contours, irregular nucleolar shape and size
- Primarily nuclear details suggest cytological malignancy
- Cytoplasmic features point to differentiation: keratinocytes – eosinophilic, hyalinized cytoplasm, melanocytes – fine brown pigment

Benign nevomelanocytes (left)	versus	**Melanoma cells (right)**
Small nucleus, abundant cytoplasm		Large nucleus, relatively little cytoplasm
Smooth nuclear border		Irregular nuclear border
Chromatin pattern nondescript		Irregular, chunky nuclear contents (chromatin)
Inconspicuous nucleolus		1 or more large, purple nucleoli

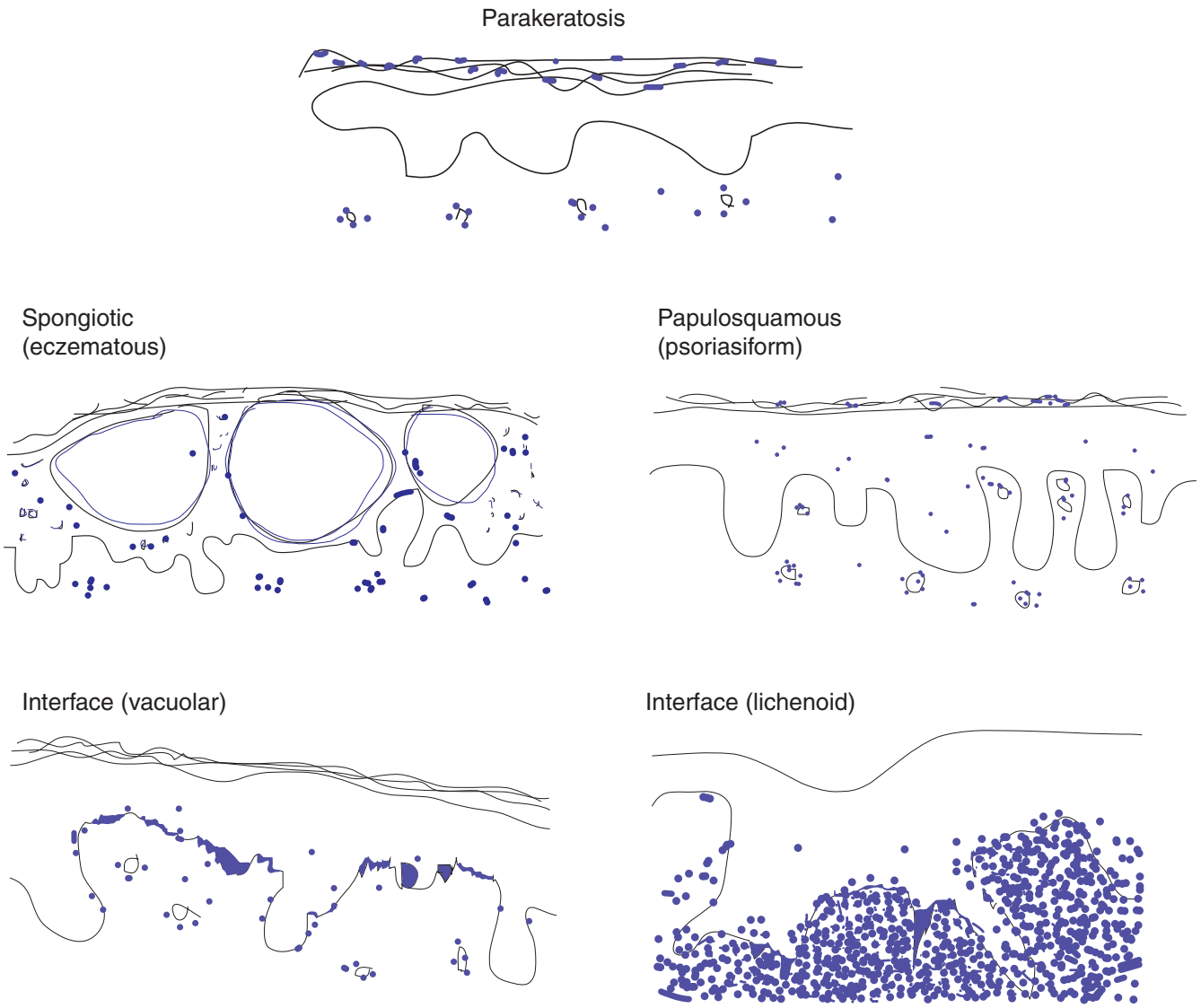

"Rash": key concepts

- The eye can be trained to focus in on the blue areas (figure-ground separation; grouping)
- Key features include epidermal changes (A), distribution of inflammation (B), and inflammatory cell type (C)
- Parakeratosis is often present in spongiotic and papulosquamous disorders; dry parakeratosis without serum but with neutrophils is suggestive of psoriasis
- Simplistically, a dermatitis can be categorized as spongiotic, papulosquamous, or interface

Figure 3(A) Key epidermal changes

- Parakeratosis: retained nuclei in the stratum corneum
- Spongiosis: increased intercellular spaces and sometimes vesicles
- Papulosquamous: thickened epidermis
- Interface (vacuolar): spaces in basal cells, which may be polygonal (squamotized), lymphocytes at junction
- Interface (lichenoid): dense band of lymphocytes between epidermis and dermis with necrotic keratinocytes

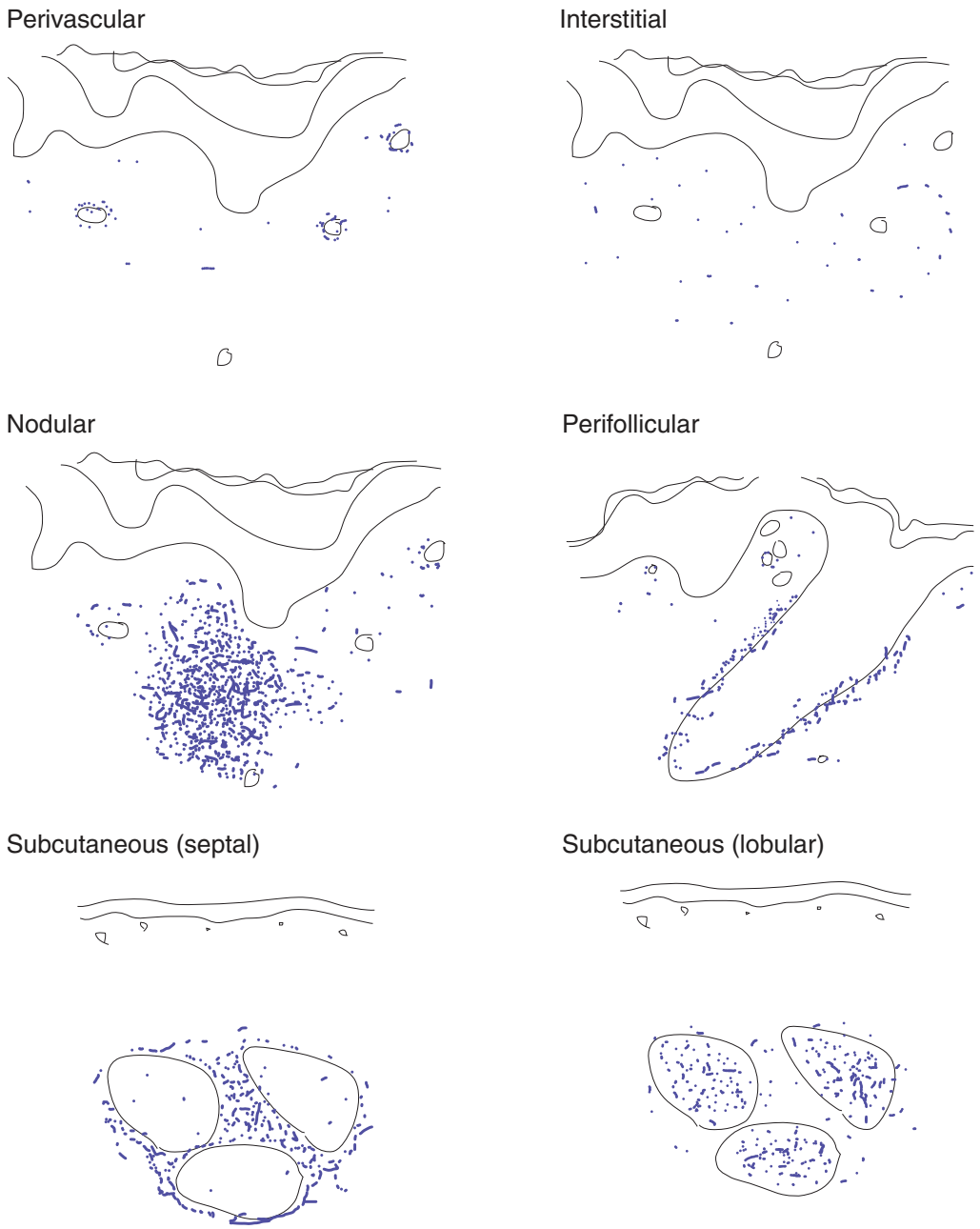

Figure 3(B) Distribution of inflammation – major patterns.
See Figure 3(A) for lichenoid

www.ebook3000.com

Lymphocytes



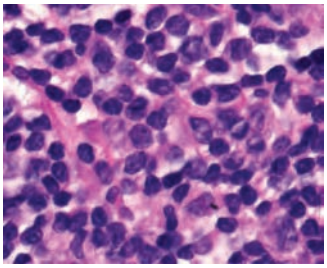

Neutrophils

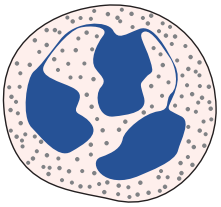

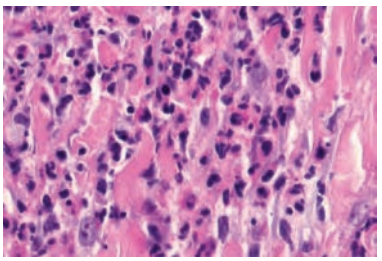

Eosinophils

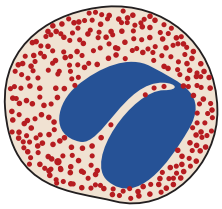

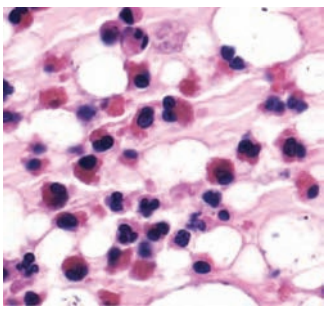

Histiocytes

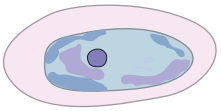

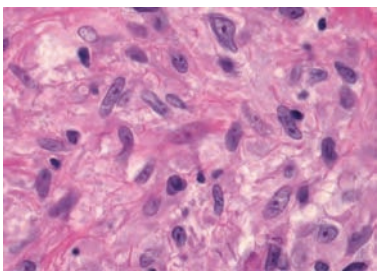

Giant cells

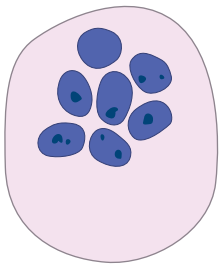

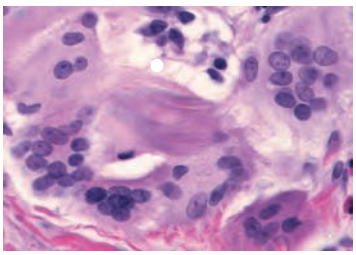

Plasma cells

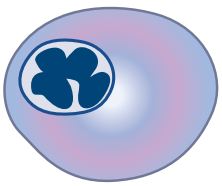

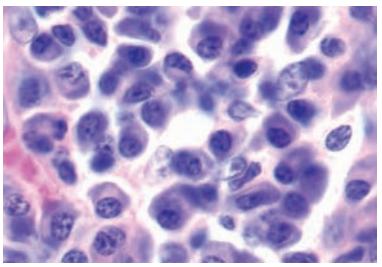

Figure 3(C) The morphology of key inflammatory cells

- Lymphocyte: round blue nucleus, little cytoplasm
- Neutrophil: multilobed nucleus
- Eosinophil: bilobed nucleus with bright pink-red cytoplasmic granules
- Histiocyte: oval nucleus
- Giant cell: multiple nuclei in one cell
- Plasma cell: clock-faced nucleus on one side of cell, perinuclear clear space

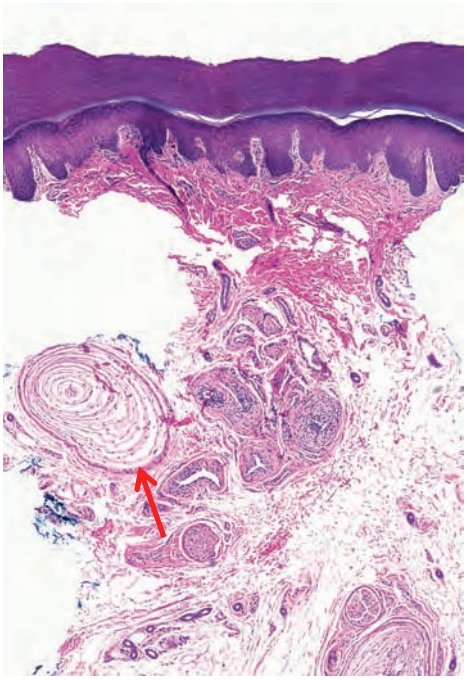

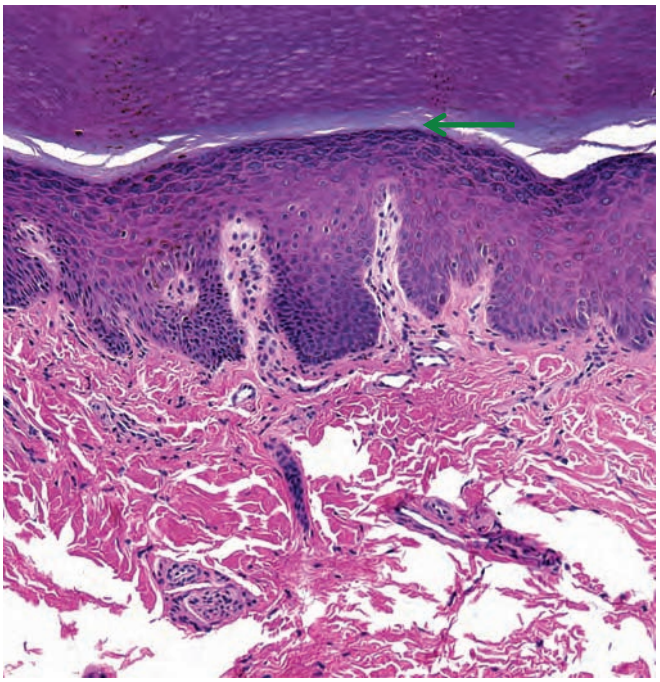

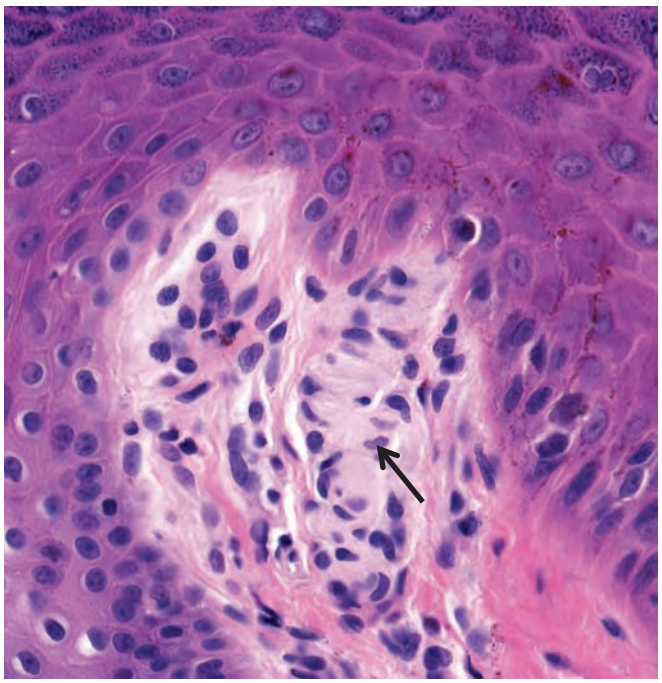

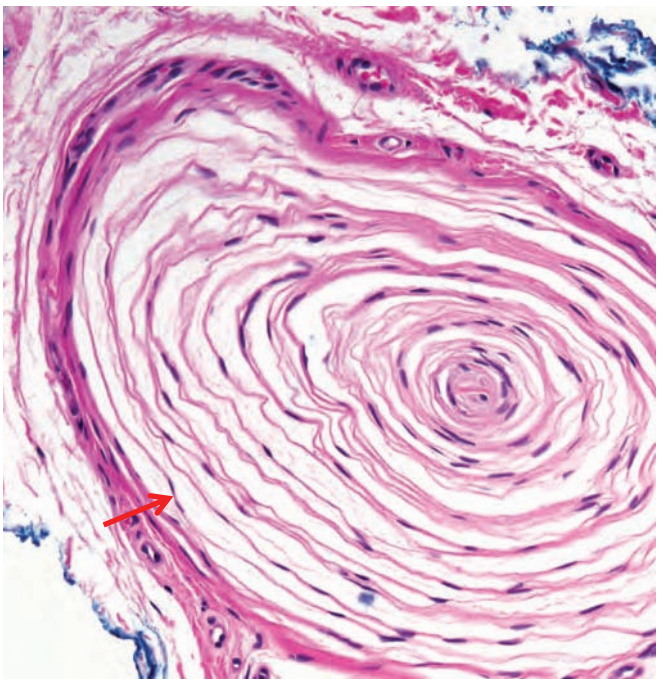

Characteristic body sites

- The location on the body (body site) can often be determined by training the eye/brain to perceive certain features
- **Figure 4:** Acral (A), mucosal (B), eyelid (C), axilla (D)

Figure 4(A) Acral skin
Note Meissner's corpuscles (black arrow), Pacinian corpuscles (red arrow), and thick stratum corneum with a stratum lucidum (green arrow).

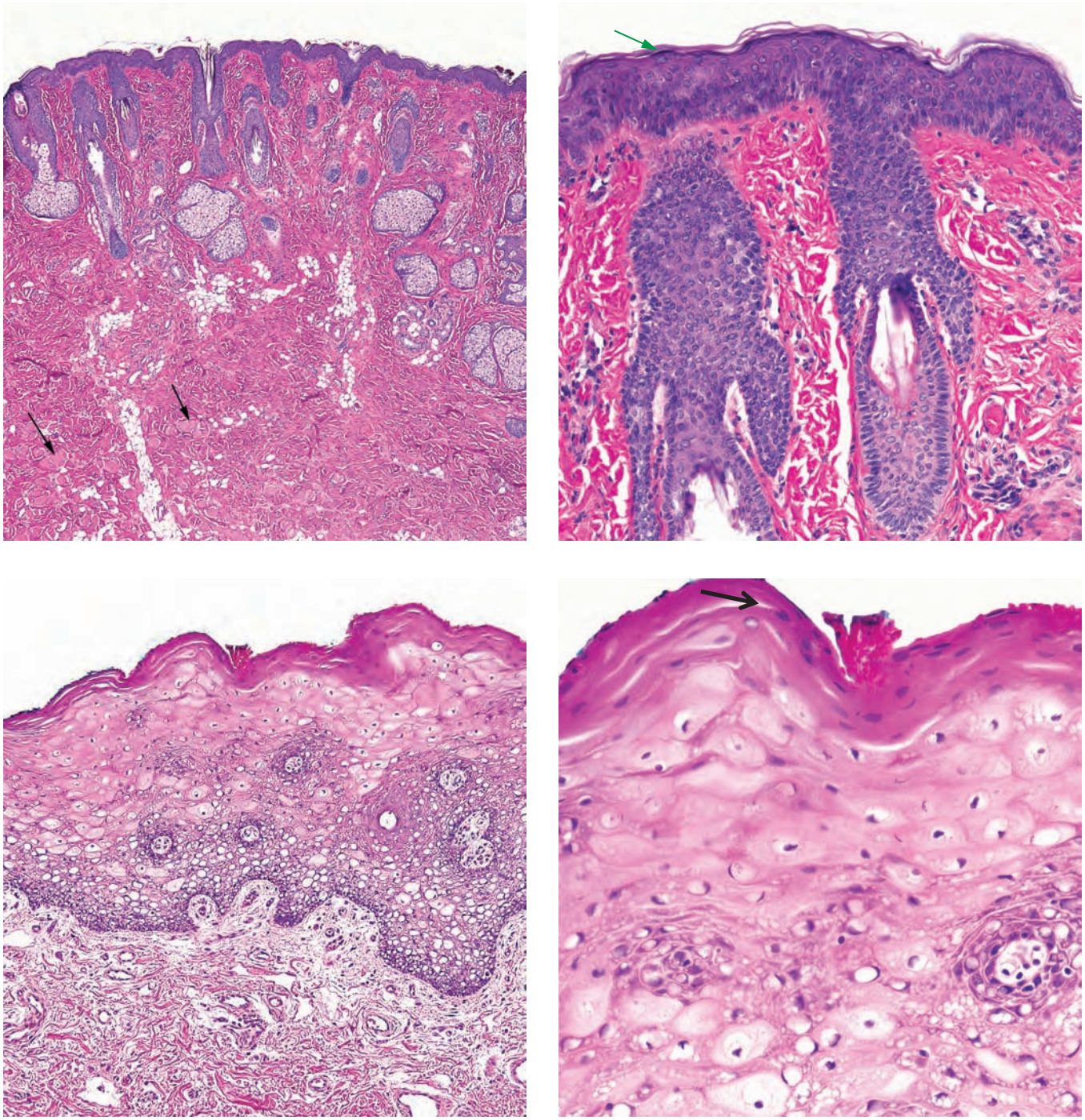

Figure 4(B) Cutaneous lip (top row) has keratin and a granular layer (green arrow) as well as adnexal structures

- Skeletal muscle is often present (black arrows)
- Normal mucosal lip (bottom row) lacks keratin and a granular layer; the keratinocytes have clear cytoplasm
- The mucosa shown is abnormal as there is subtle parakeratosis (black arrow bottom right image)

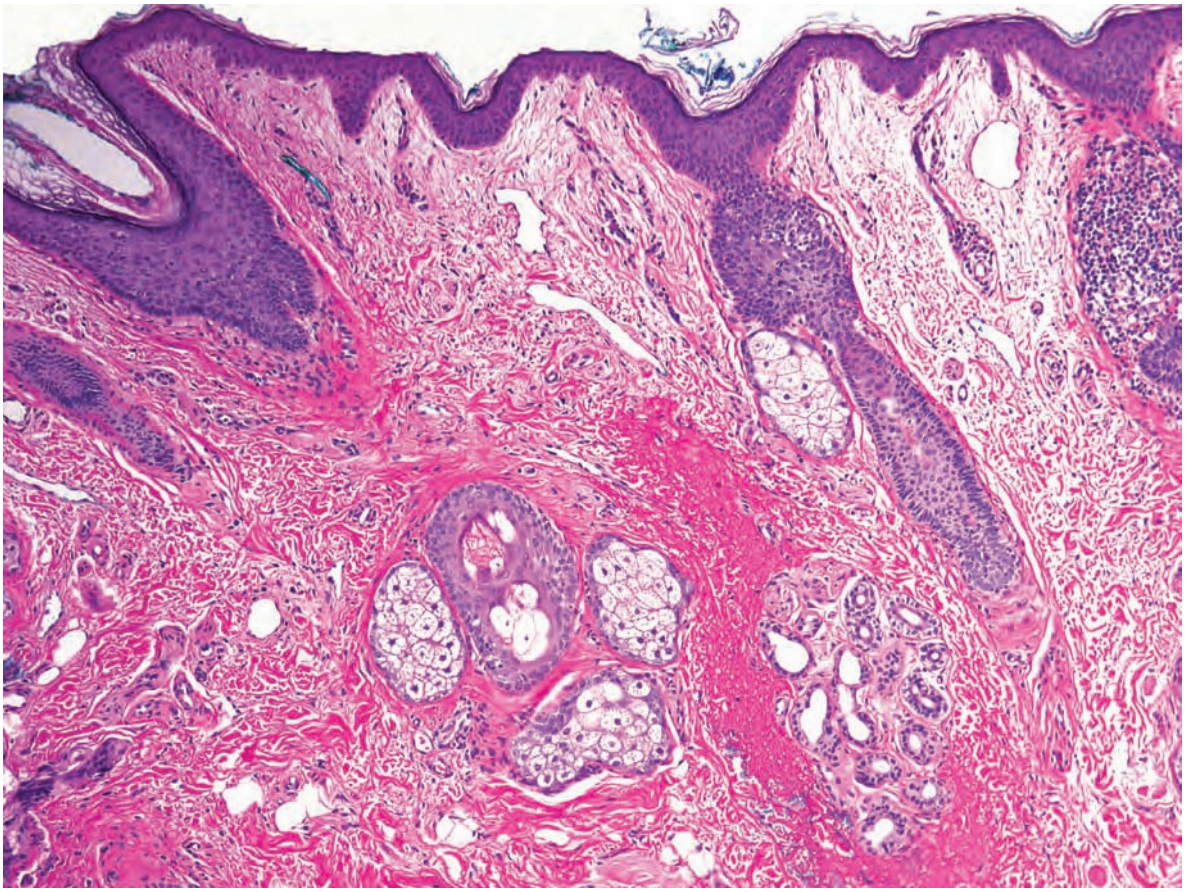

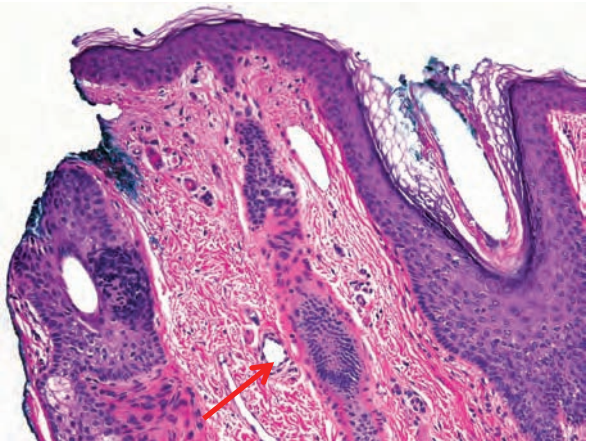

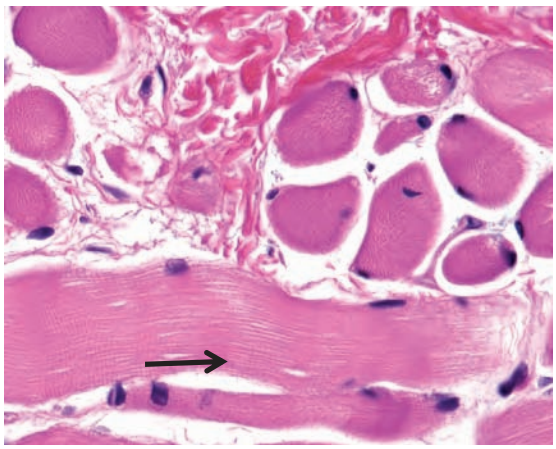

Figure 4(C) Eyelid skin has a thin epidermis with dermal vellus hairs (red arrow) and skeletal muscle (black arrow)

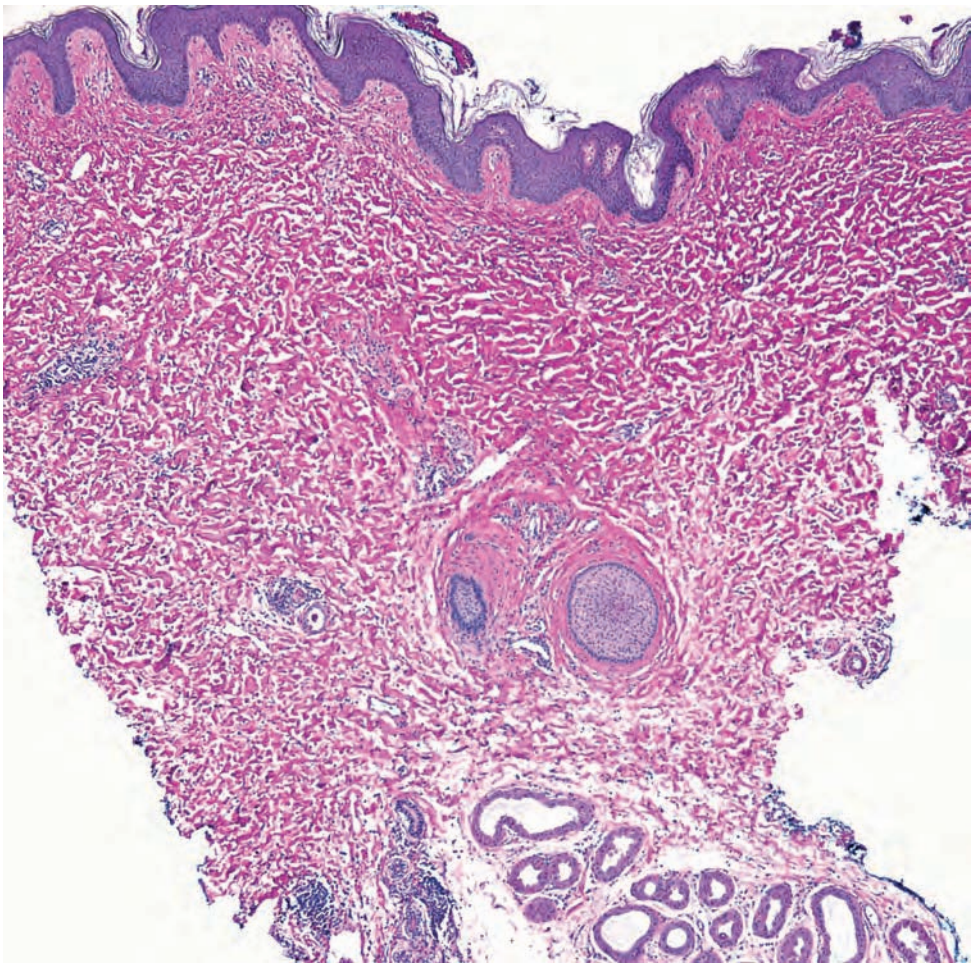

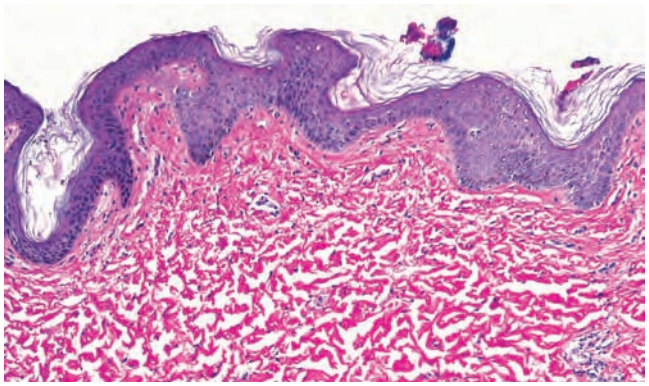

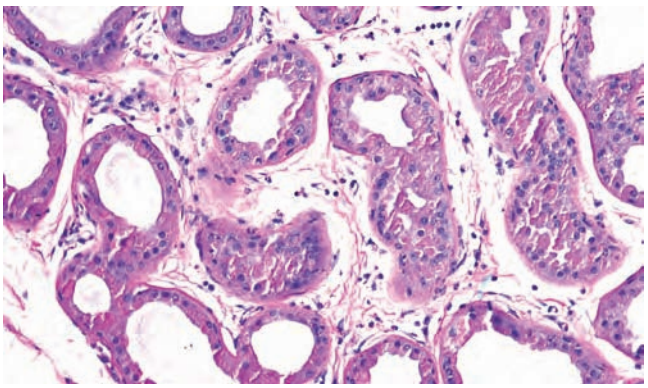

Figure 4(D) Axilla

- The epidermis is undulating, often with basilar melanin pigment. There are apocrine glands in the deep dermis

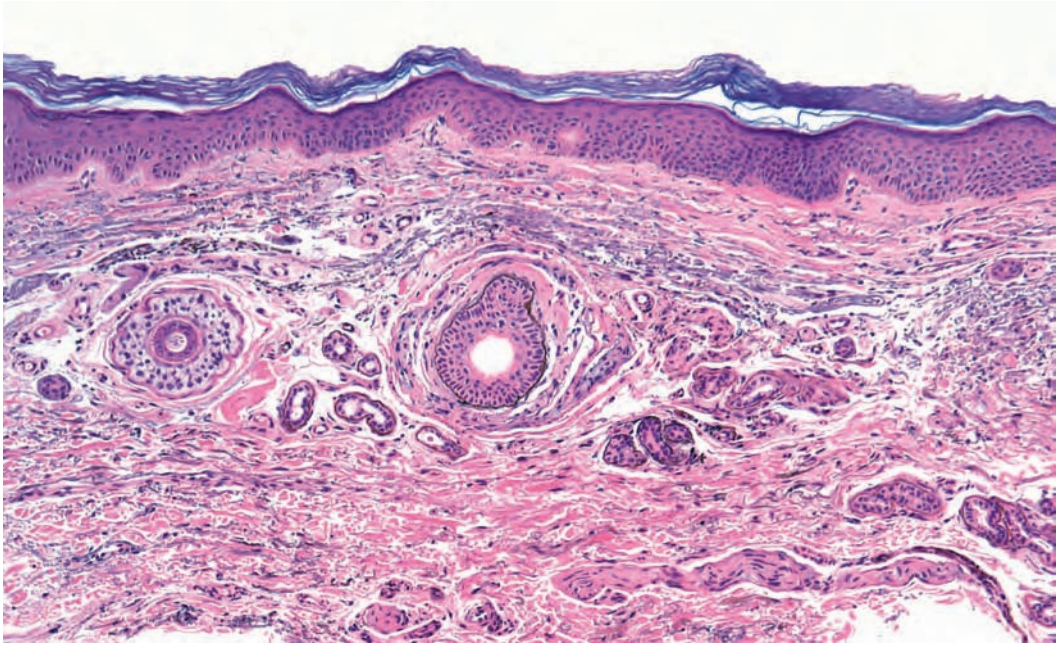

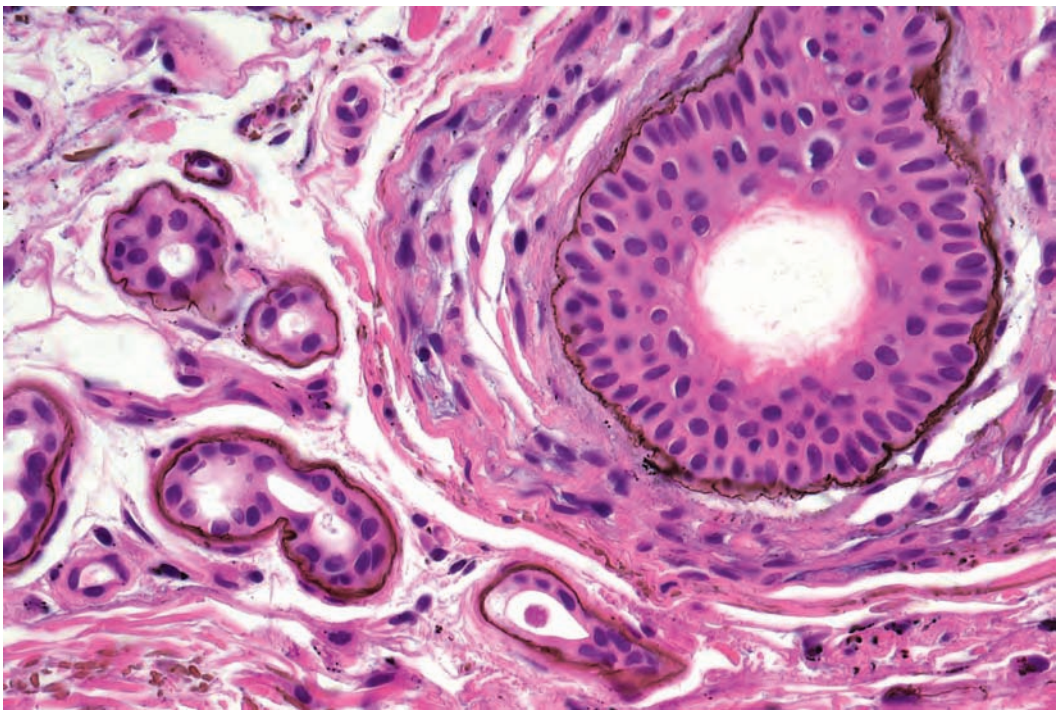

Table 2 (see page 22) shows a differential of "normal" appearing skin. Some entities, like vitiligo, require special stains (i.e. a melanocytic marker).

Figure 5(A) Argyria

- There are fine black granules in the basement membrane of hair follicles and eccrine glands
- Black granules are also deposited on elastotic fibers, so-called "pseudo-ochronosis"

Source: Case courtesy of James E. Fitzpatrick, MD.

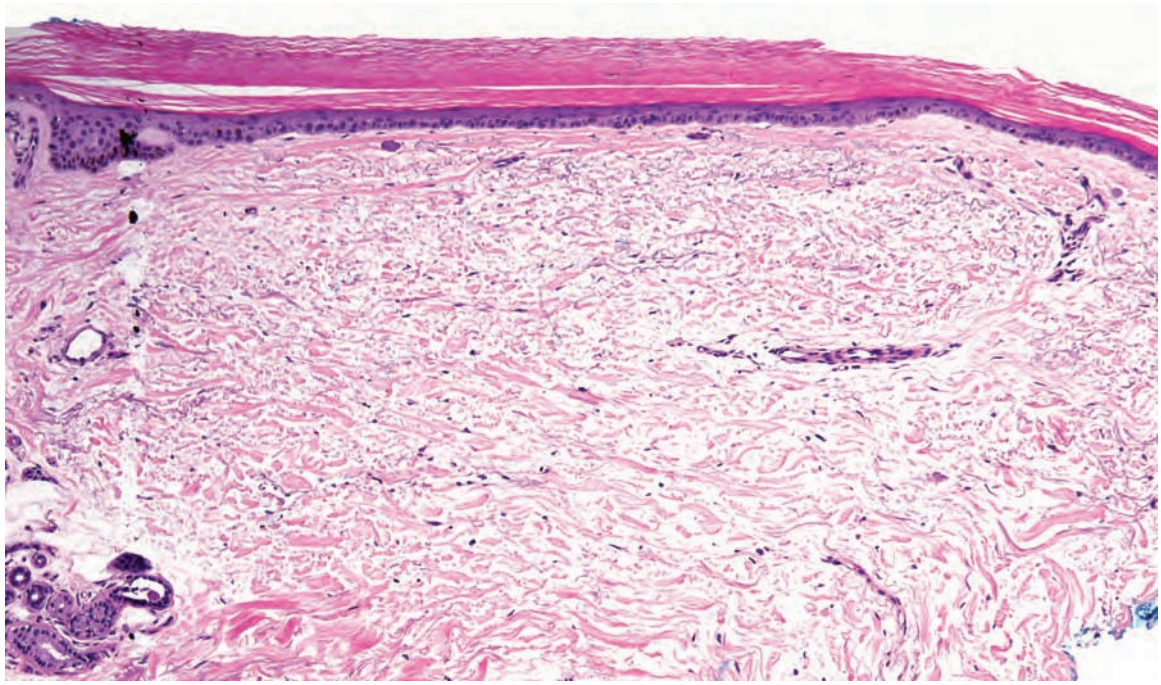

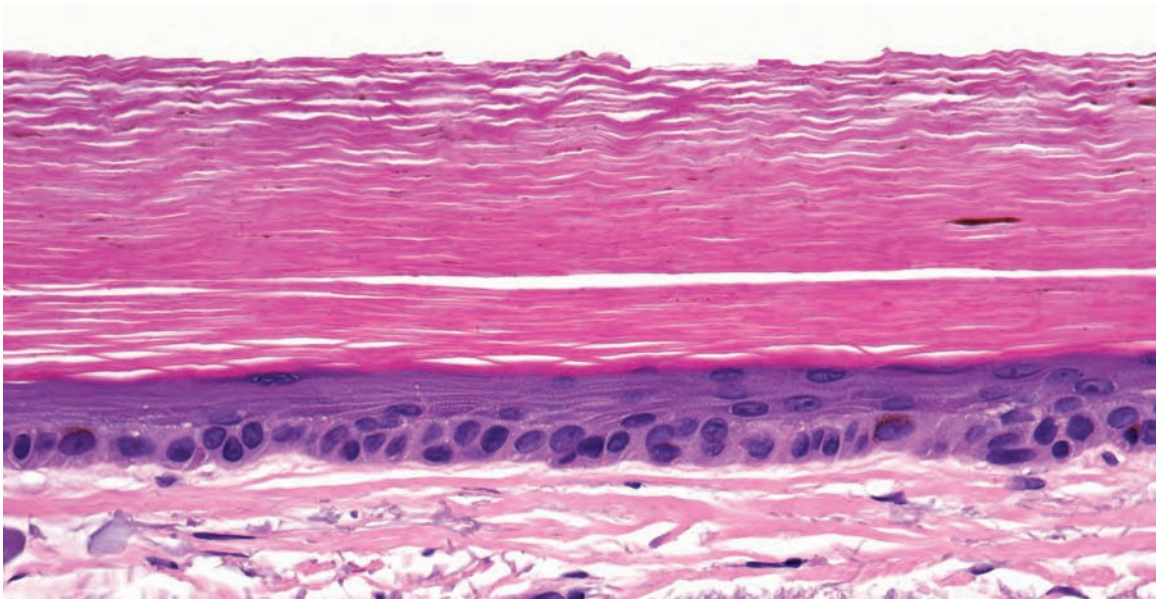

Figure 5(B) Ichthyosis vulgaris

- This example from an older patient has solar elastosis in the dermis
- There is hyperekeratosis above an attenuated granular layer

Source: Case courtesy of Jeff D. Harvell, MD.

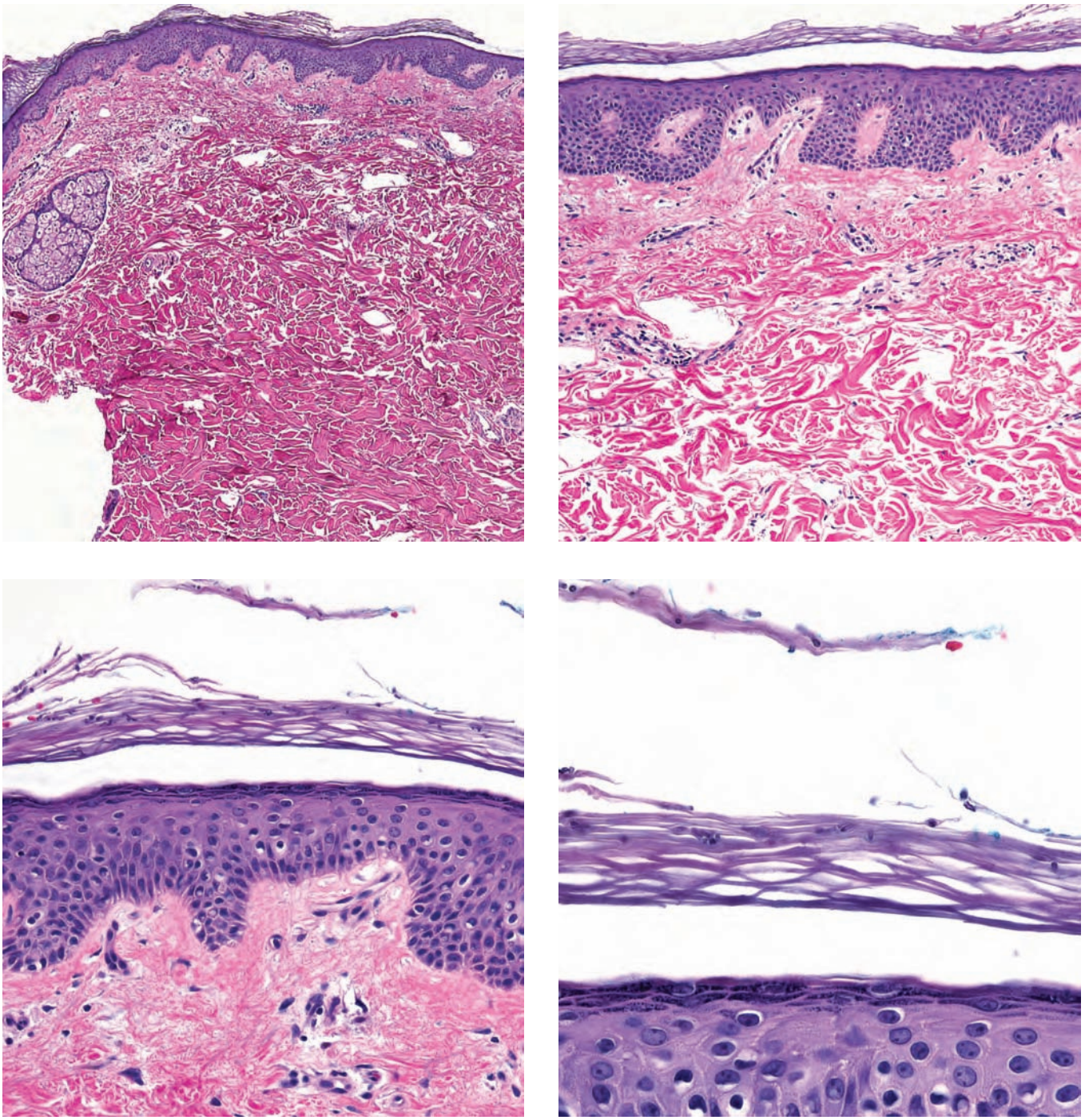

Figure 5(C) Tinea versicolor
- Yeast and hyphal forms in the stratum corneum

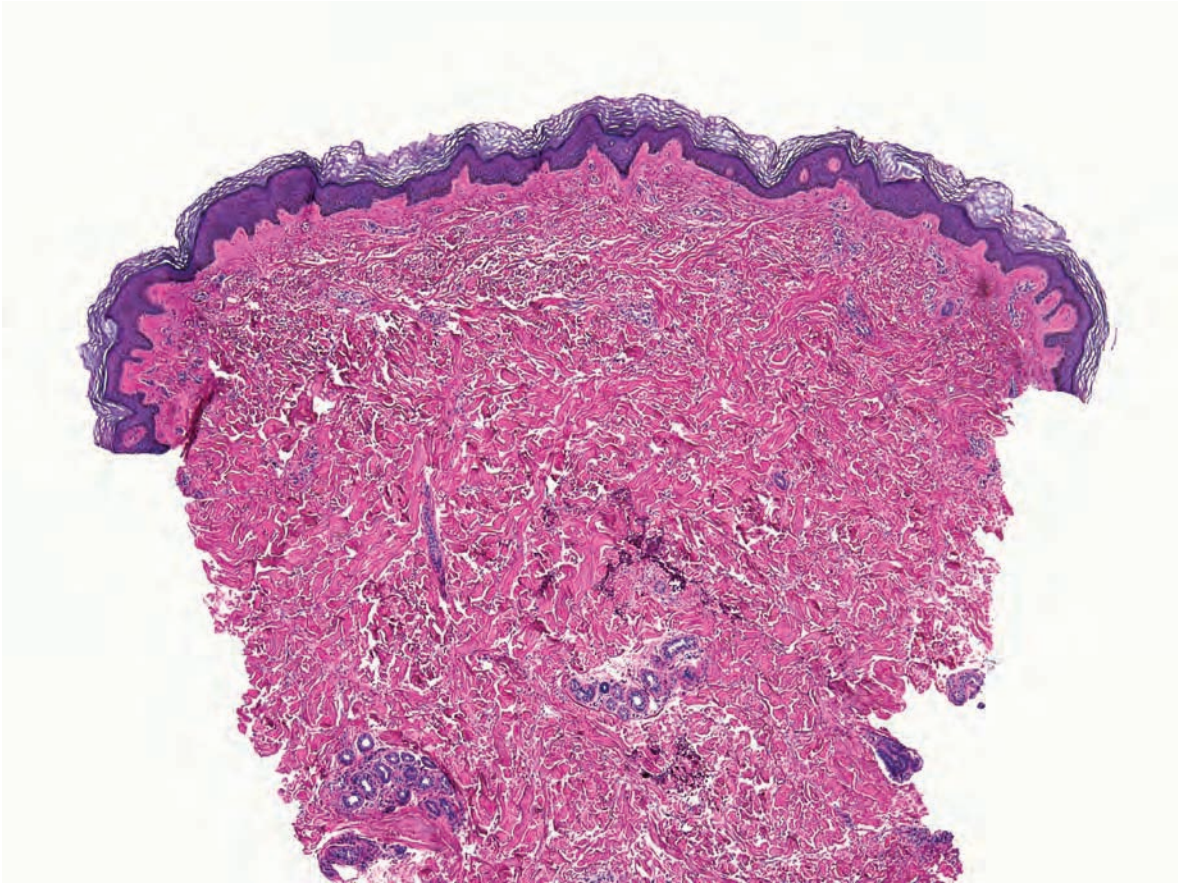

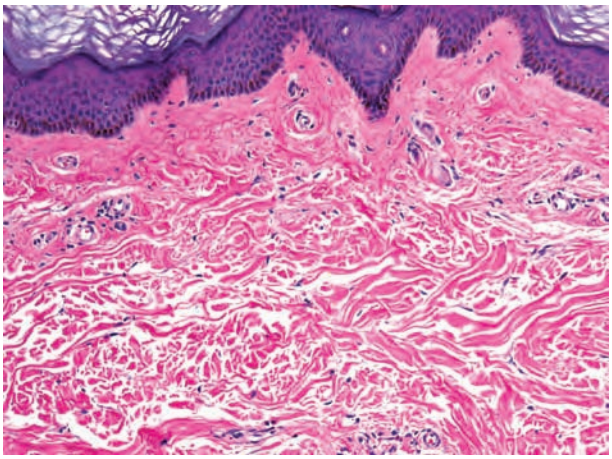

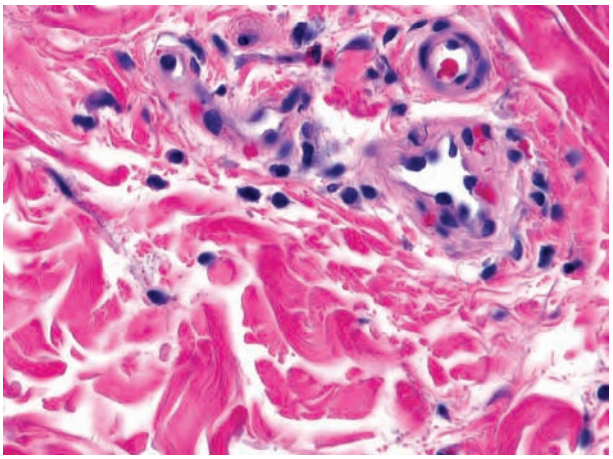

Figure 5(D) Urticaria

- Urticaria can appear "normal" at low power, particularly when inflammation is sparse
- There are perivascular and interstitial lymphocytes and eosinophils

Table 2 Some entities to consider for a gestalt impression of "normal" skin

"Normal" skin	Look for
Argyria	Flecks of black material around eccrine glands; elastic fibers may be discolored (Figure 5A)
Ichthyosis vulgaris	Hyperkeratosis above hypogranulosis or absent granular layer (Figure 5B)
Macular amyloidosis	Amorphous, smooth pink globules in the papillary dermis Pigment incontinence
Scleredema	"Square"/rectangular biopsy shape Increased space +/– mucin between collagen bundles
Tinea versicolor	Spores and pseudohyphae in the stratum corneum (Figure 5C)
Urticaria	Mixed inflammation (interstitial and perivascular) (Figure 5D)

1 Shape on Low Power

- Epidermis
  - Regular acanthosis, 25
  - Lobular proliferation, 29
  - Reticulated proliferation, 35
  - Central pore, 42
  - Epidermal perforation, 46
- Dermis
  - Circular islands, 49
  - Cords/tubules and comma shapes, 53
  - Space with a lining, 59
  - Papillations, 70
  - Polypoid (dome-shaped), 77
  - Square/rectangular, 82
  - Palisading reactions, 88
  - Pseudoepitheliomatous hyperplasia above abscesses, 93
  - Pink ball (see Chapter 6)

Dermatopathology: Diagnosis by First Impression, Third Edition. By Christine J. Ko and Ronald J. Barr.

© 2017 John Wiley & Sons, Ltd. Published 2017 by John Wiley & Sons, Ltd.

Companion website: www.wiley.com/go/ko/dermatopathology3e

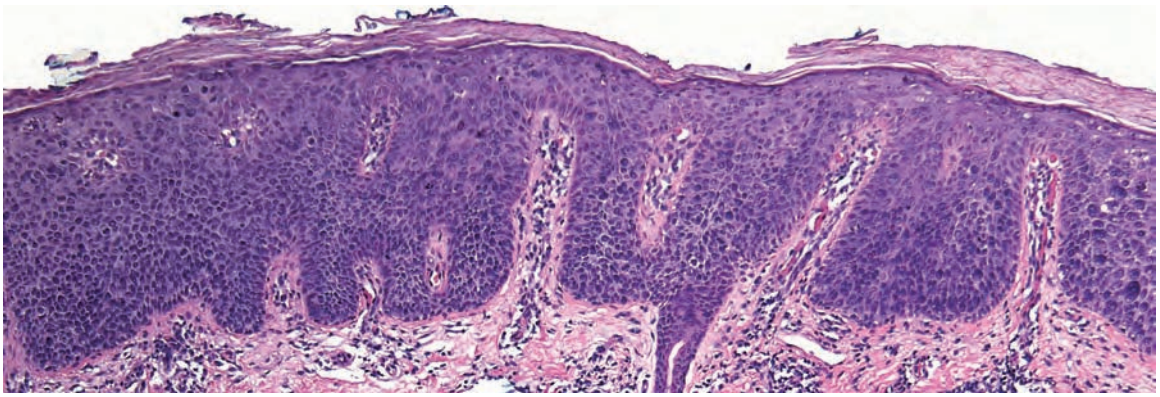

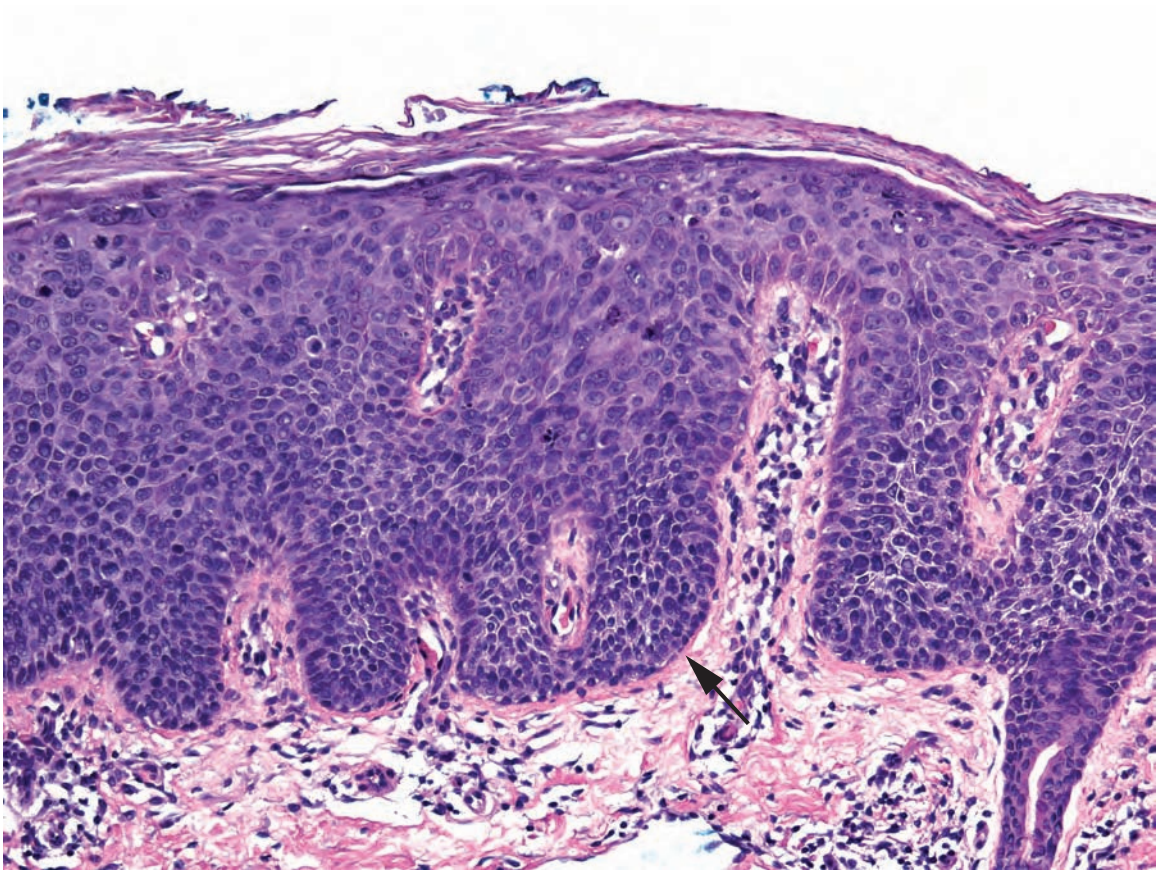

- Epidermal acanthosis
- Parakeratosis
- Full-thickness disorder of keratinocytes with atypical cells and mitoses
- Basal layer may focally appear normal ("eyeliner" sign) (arrow)

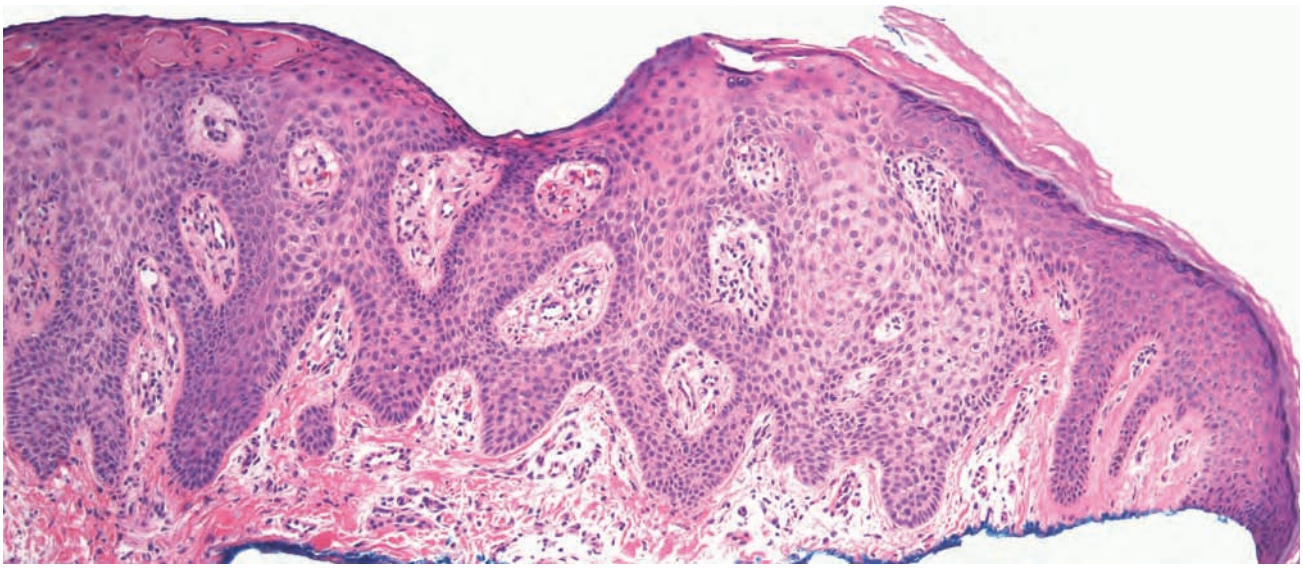

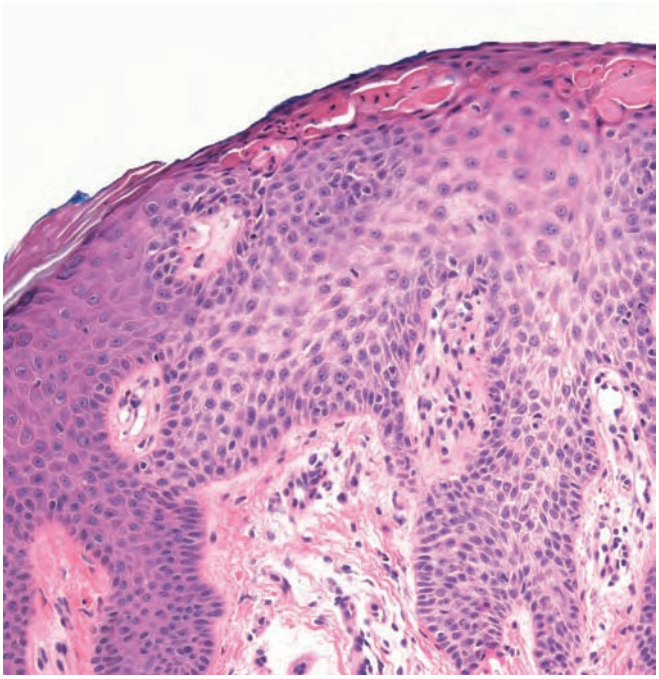

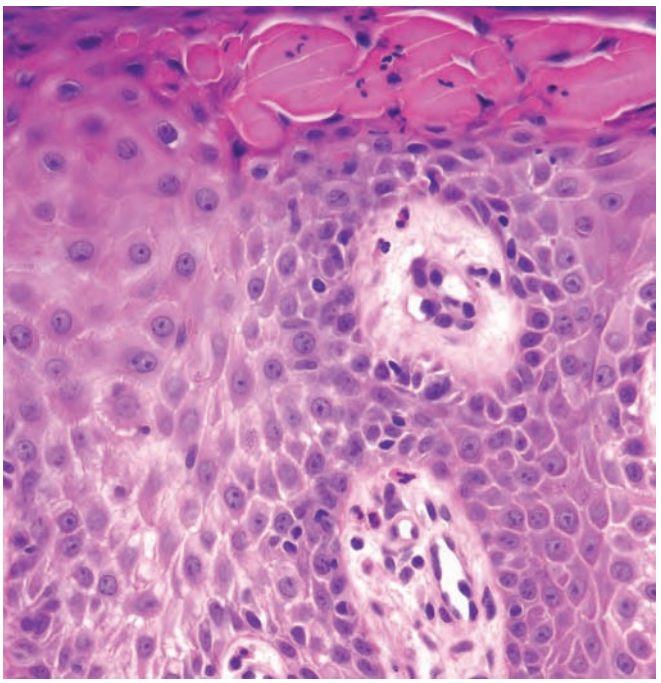

- Epidermal acanthosis
- Clear cells well-demarcated from the normal epidermis and adnexal keratinocytes
- Parakeratosis above clear cells

Clear cell acanthoma

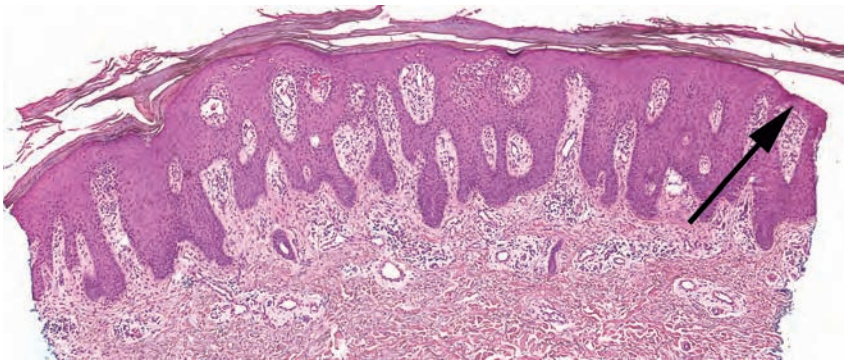

- Epidermal acanthosis
- Parakeratosis
- Neutrophils in stratum corneum (asterisk)
- Hypogranulosis
- Thinned suprapapillary plates (long arrow)
- Dilated vessels in papillary dermis (short arrows)

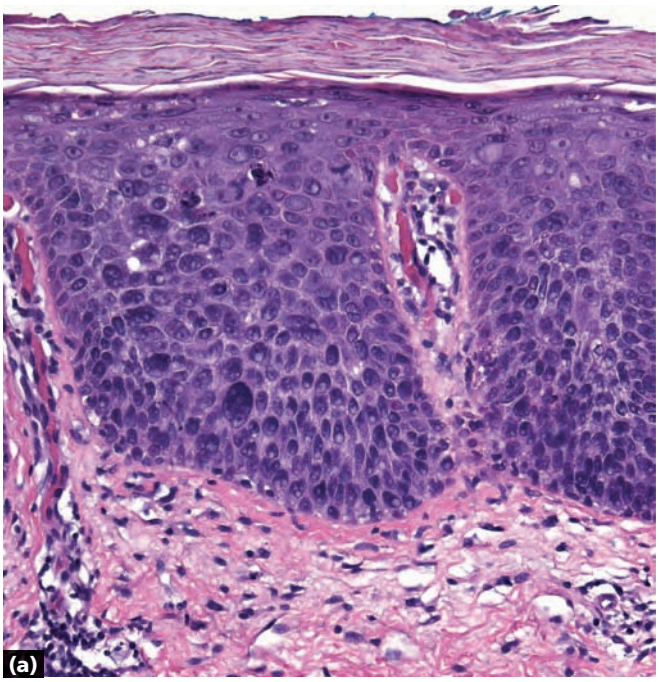

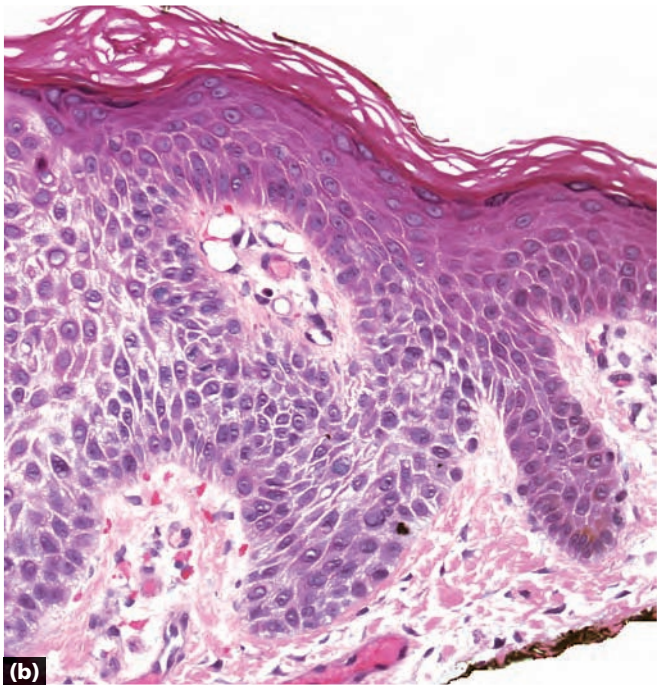

a Bowen disease: disordered keratinocytes and atypical mitoses
b Clear cell acanthoma: pale/clear keratinocytes well-demarcated from normal epidermis
c Psoriasis: confluent parakeratosis above thickened epidermis, neutrophils in stratum corneum, normal keratinocytes, thin suprapapillary plates, dilated vessels

Key differences

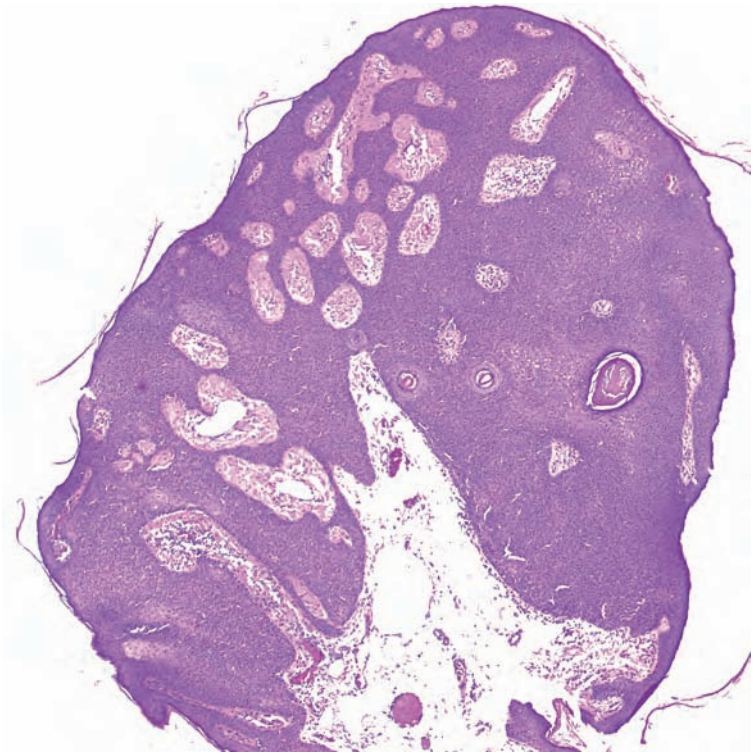

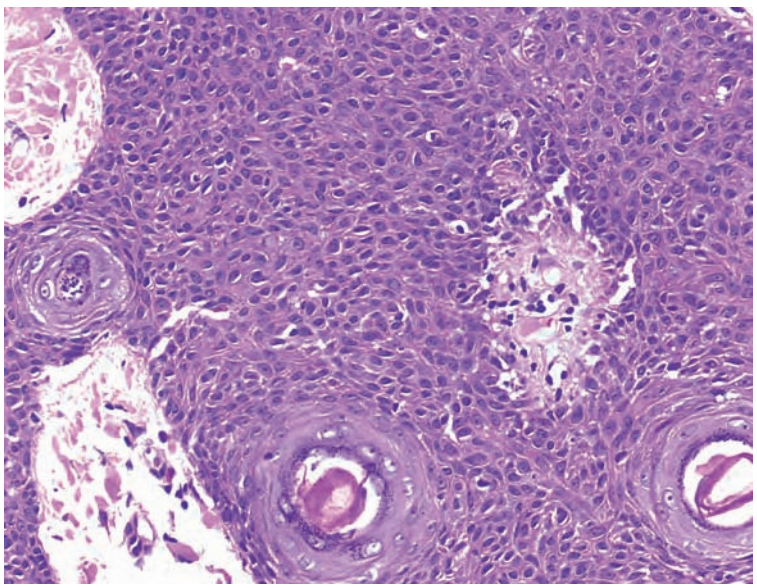

- Lobular proliferation
- Normal-appearing keratinocytes with some arranged in squamous eddies

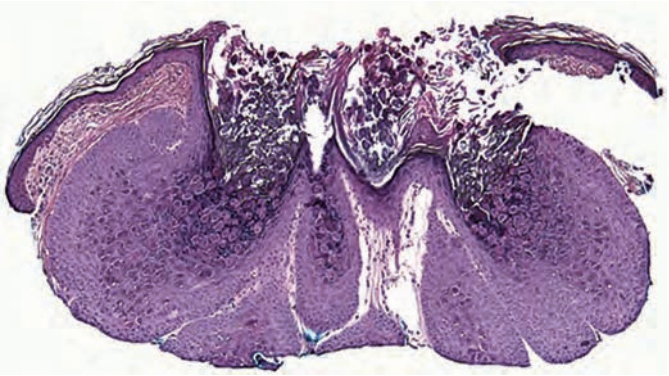

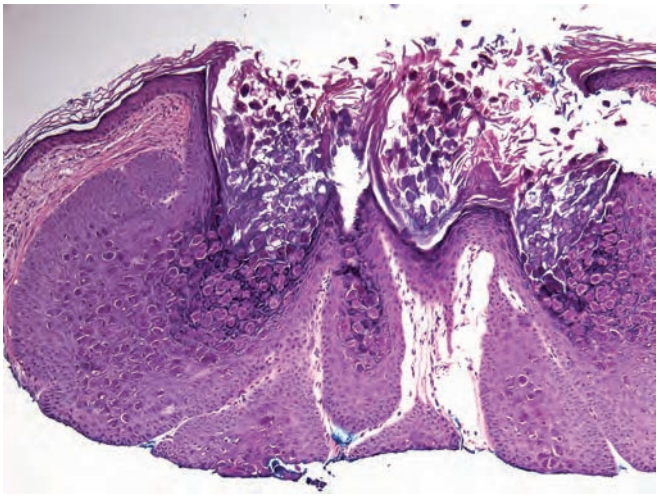

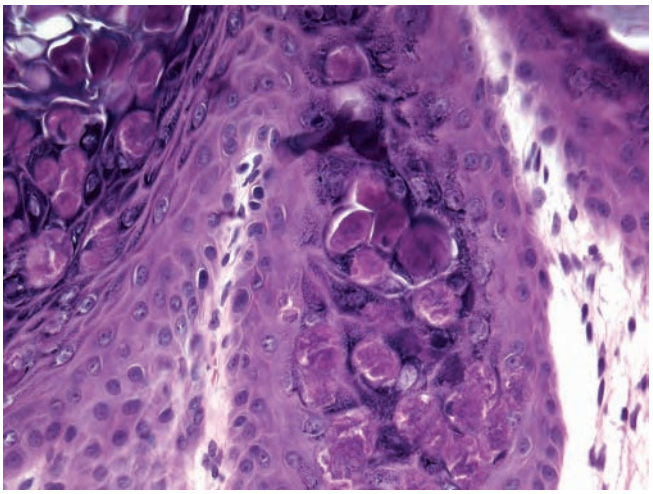

- Lobular proliferation
- Blue-gray hue to some of the keratinocytes
- Large, pink cytoplasmic inclusions (Henderson-Paterson bodies)

Molluscum contagiosum

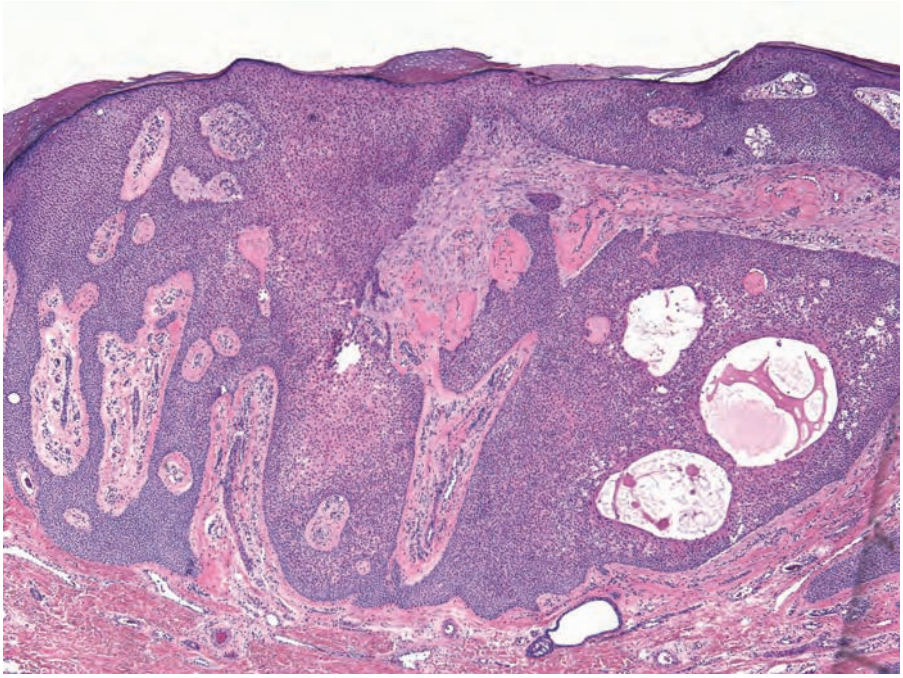

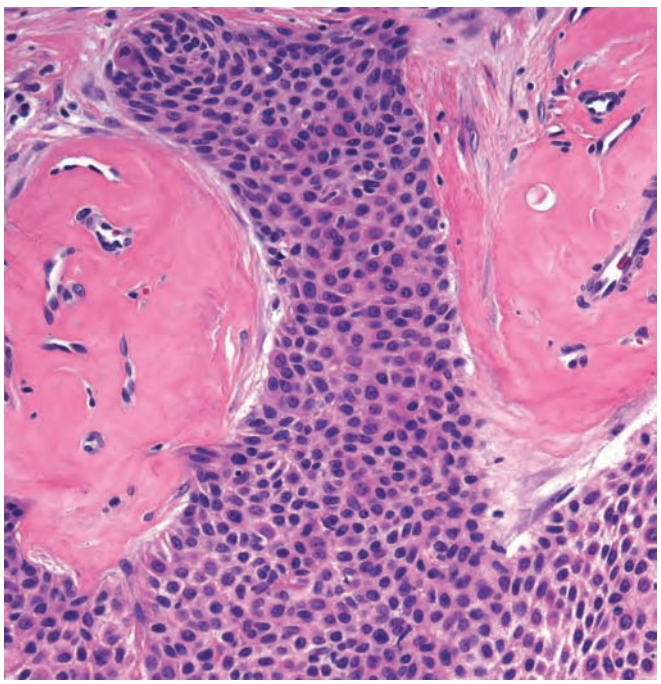

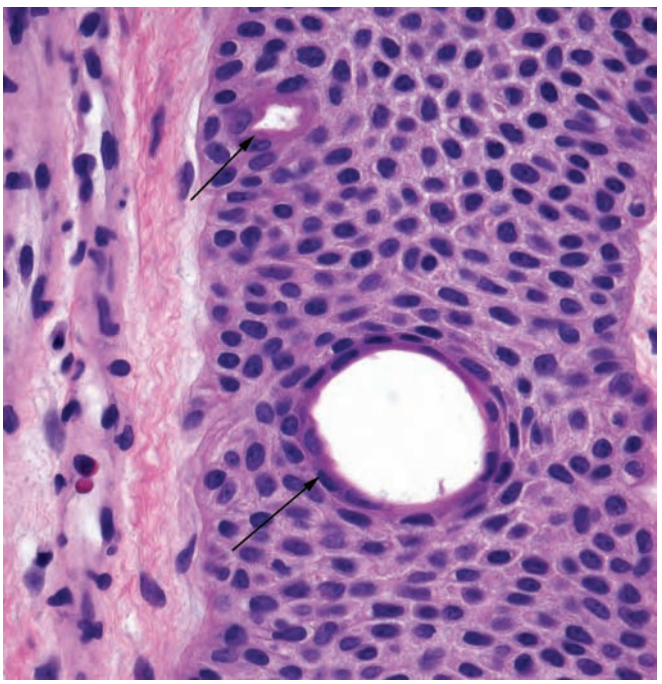

- Lobular proliferation (can be reticulated)
- Uniform blue cells with interspersed ducts (arrows)
- Fibrotic or hyalinized stroma with dilated vessels

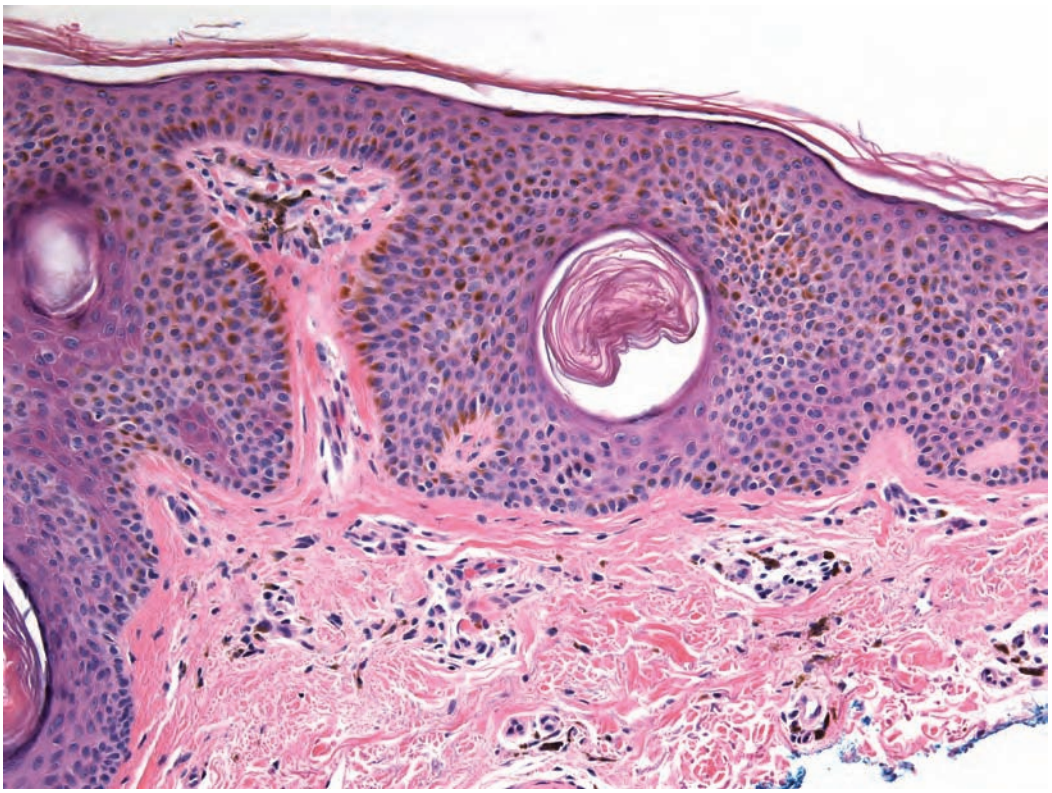

- Lobular proliferation
- Acanthosis of epidermis
- Pseudohorn cysts
- No ducts

Seborrheic keratosis, acanthotic

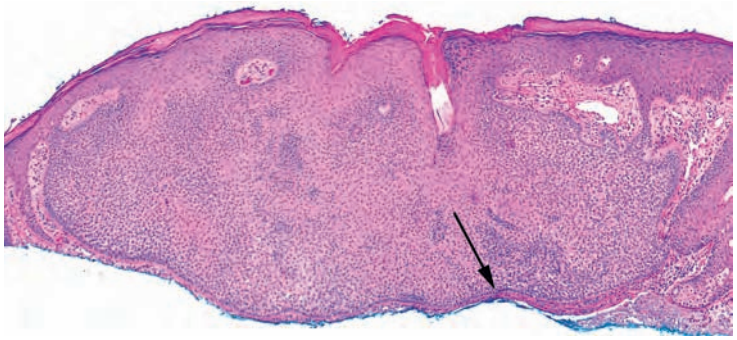

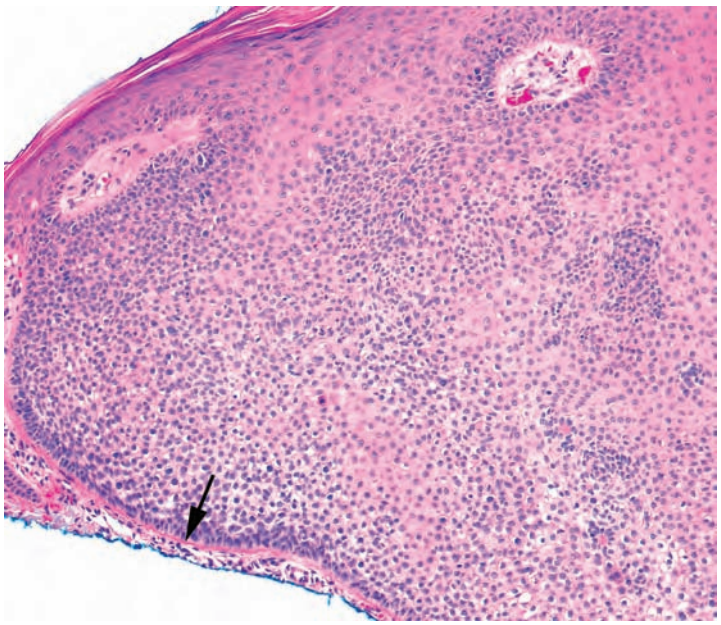

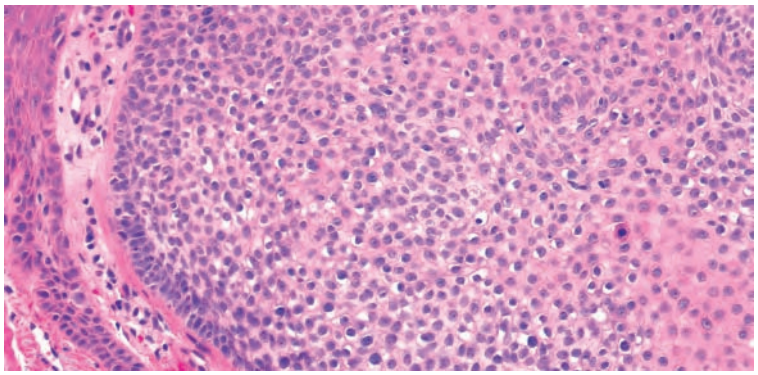

- Lobular proliferation
- Proliferation composed of pale/clear cells
- Peripheral palisading (long arrow) with thickened basement membrane (short arrow)

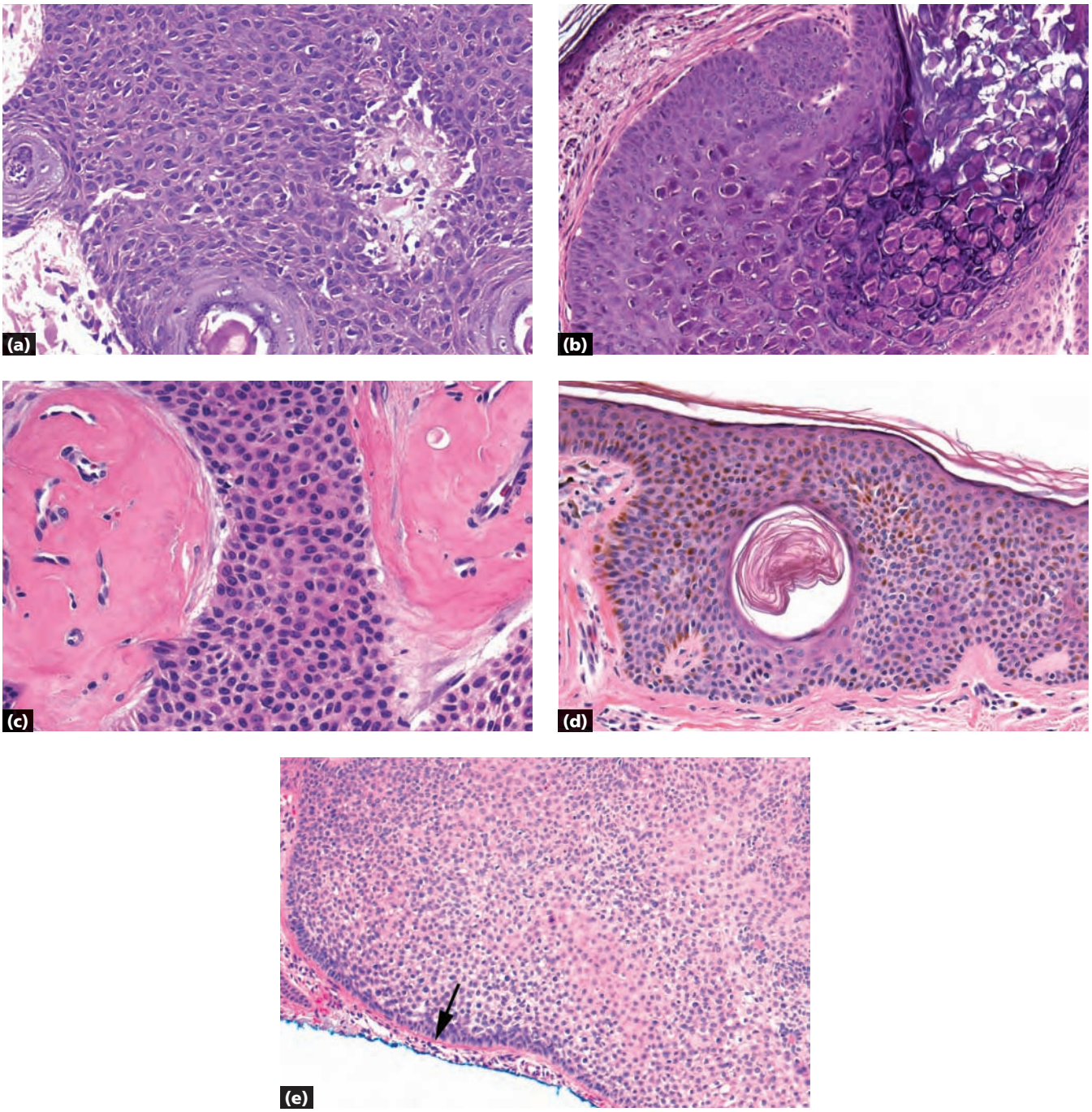

a Inverted follicular keratosis: squamous eddies of normal keratinocytes
b Molluscum contagiosum: intracytoplasmic pink inclusions (Henderson-Paterson bodies)
c Poroma: uniform blue cells with interspersed ducts, hyalinized stroma
d Seborrheic keratosis: pseudohorn cysts
e Trichilemmoma: pale/clear keratinocytes with peripheral palisading and thickened basement membrane

Key differences

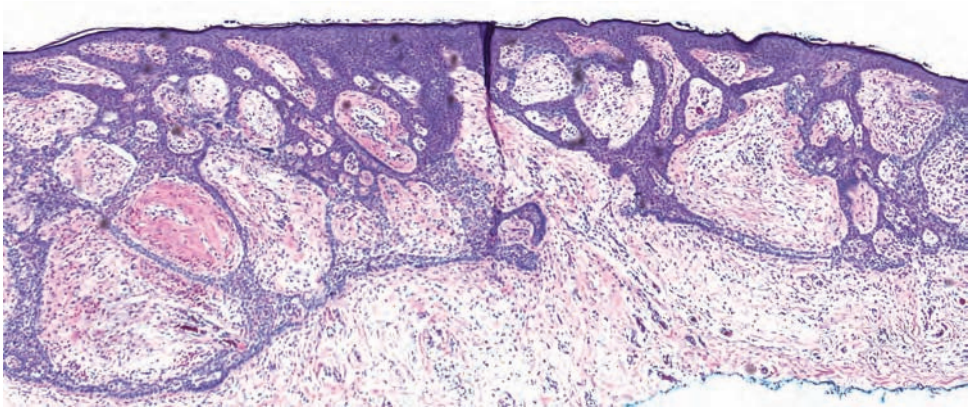

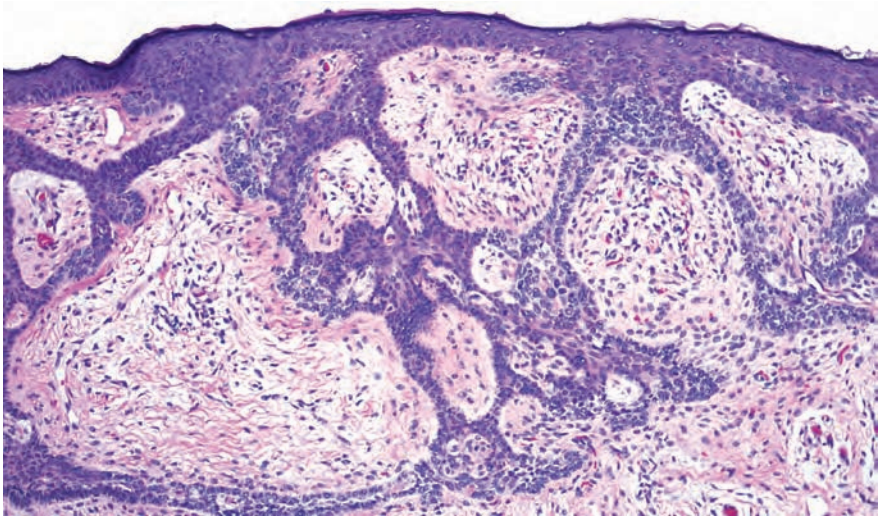

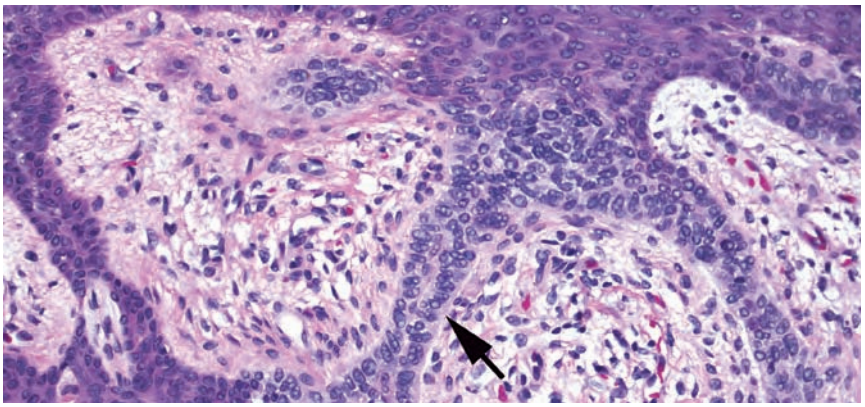

- Reticulated proliferation
- Strands of basaloid cells in a fibrovascular stroma
- Some hints of palisading of cells (arrow)

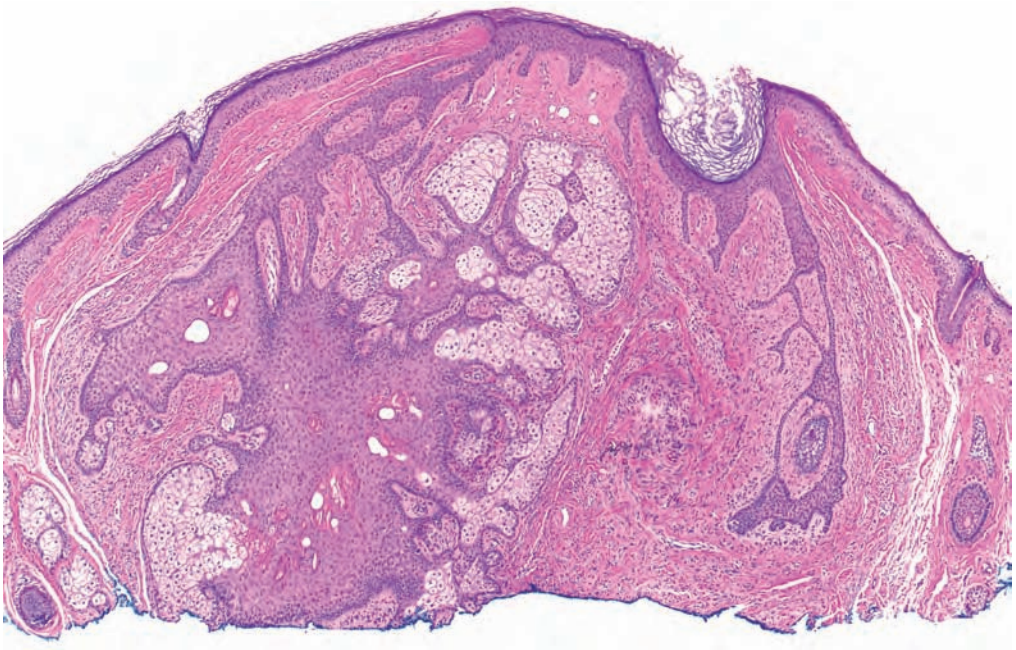

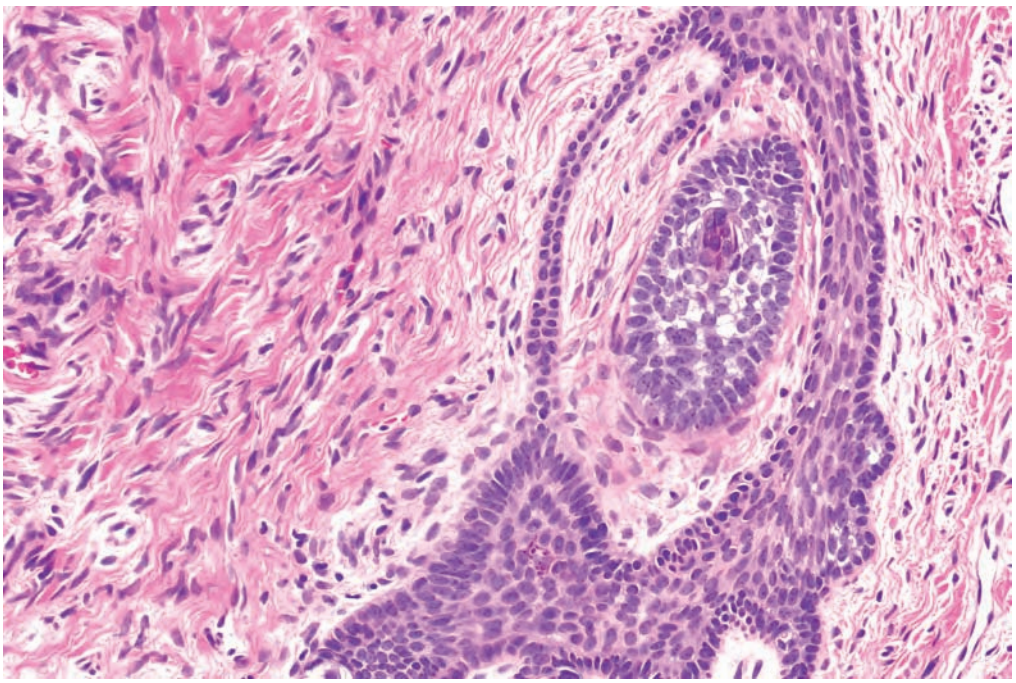

- Reticulated proliferation
- Fibrotic stroma adjacent to the hair follicle has reticulated strands of epithelium
- This entity has overlap with trichodiscoma (most consider these a spectrum of the same entity)

Fibrofolliculoma

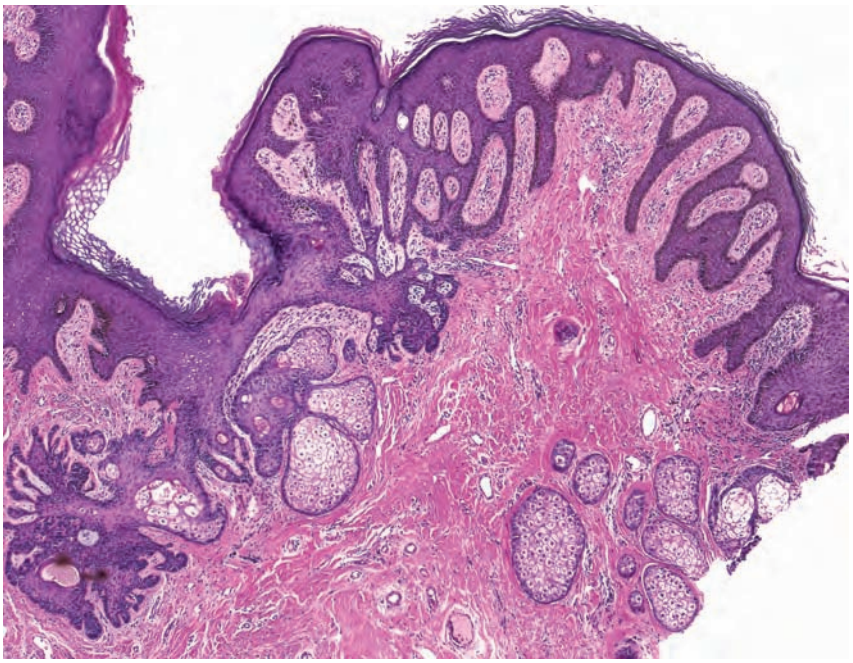

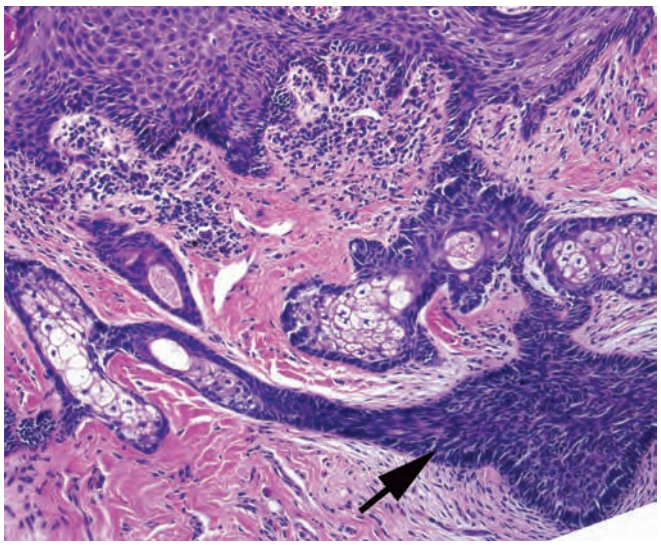

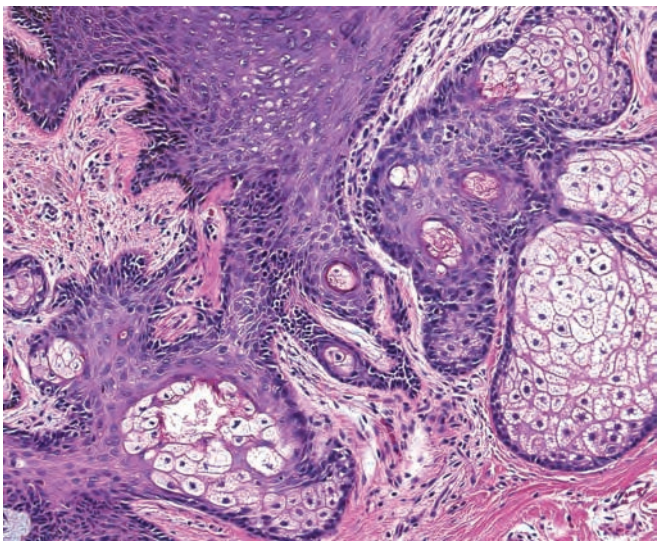

- Reticulated proliferation
- Sebaceous glands, basaloid proliferations (arrow) connect to the epidermis
- Apocrine glands may be seen deep
- Absent terminal hairs in mature stage

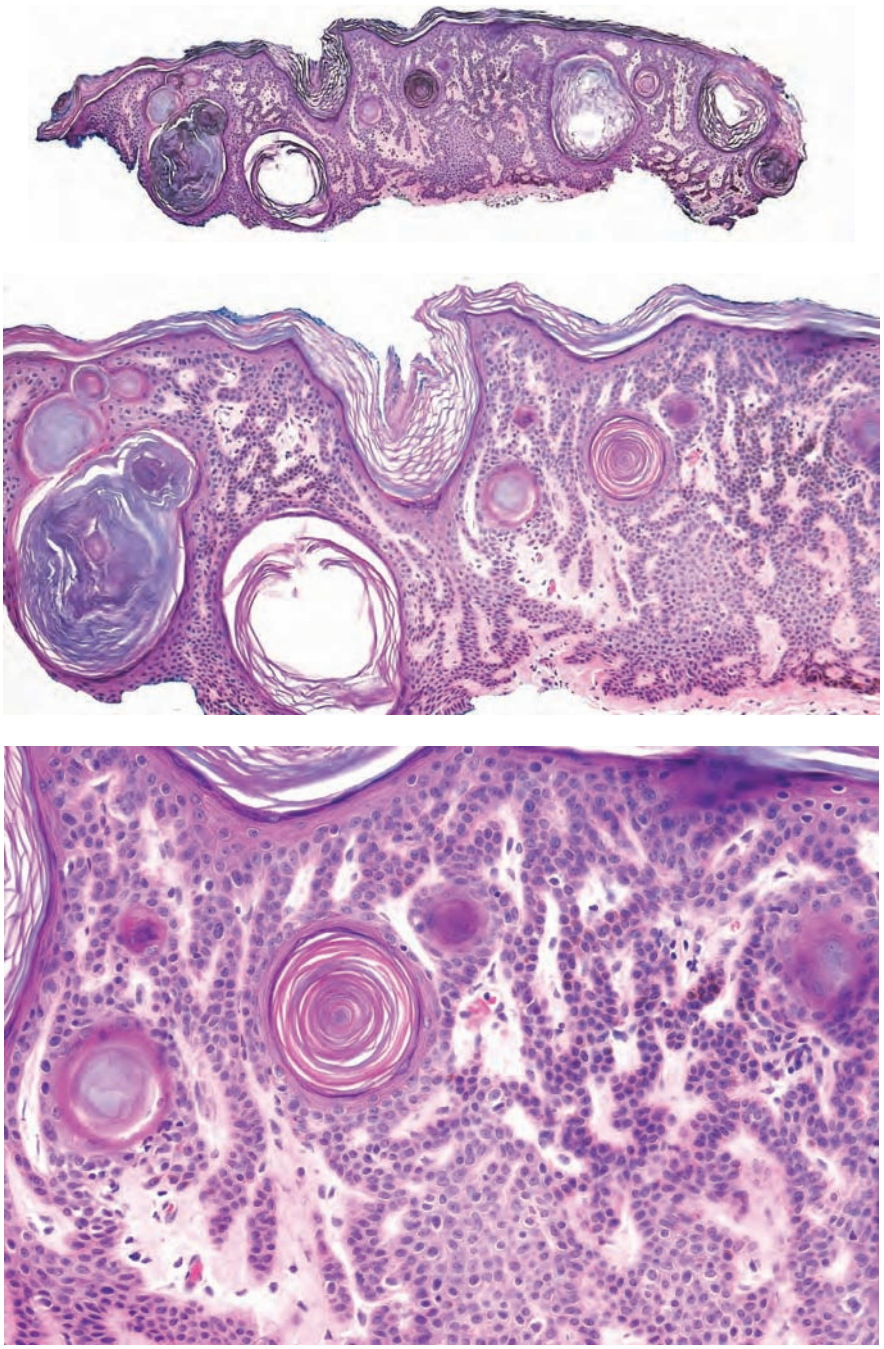

- Reticulated proliferation
- Strands of banal keratinocytes, often pigmented
- Interspersed pseudohorn cysts

Seborrheic keratosis, reticulated

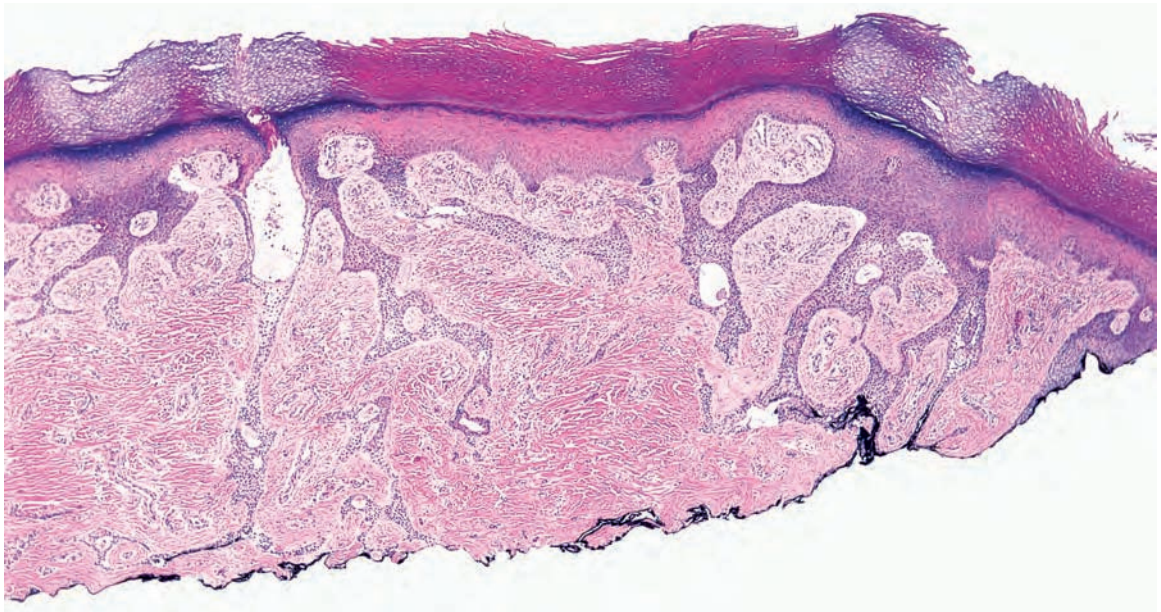

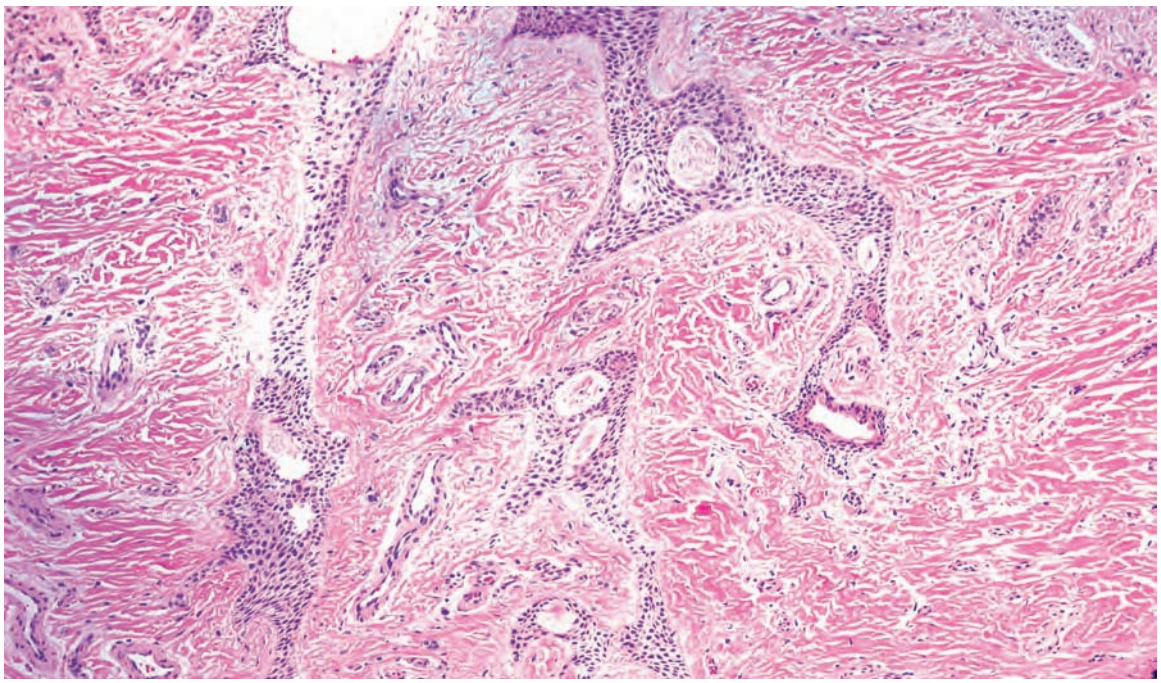

- Reticulated proliferation
- Strands of banal, round cells
- Interspersed ducts

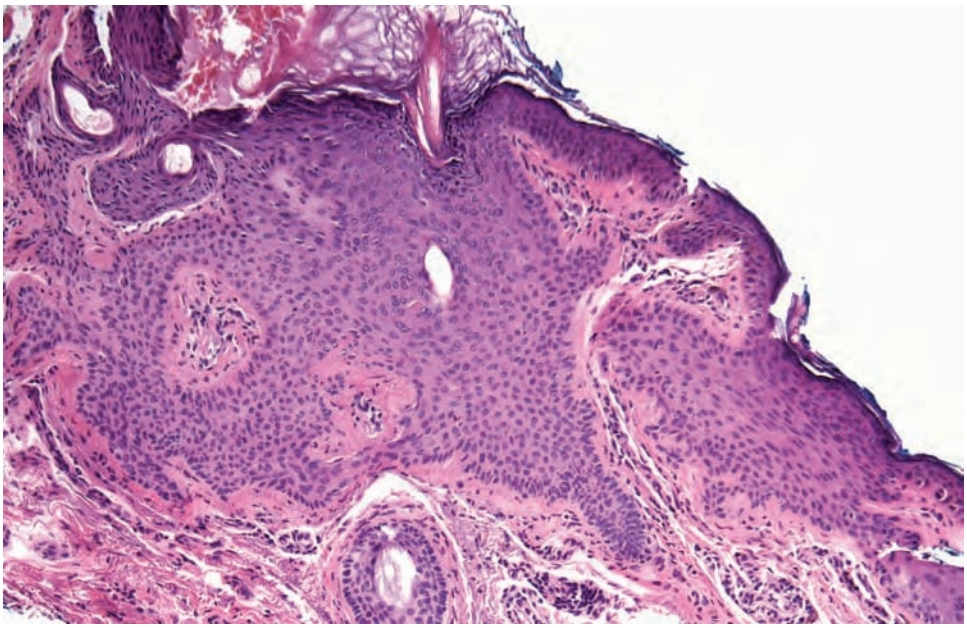

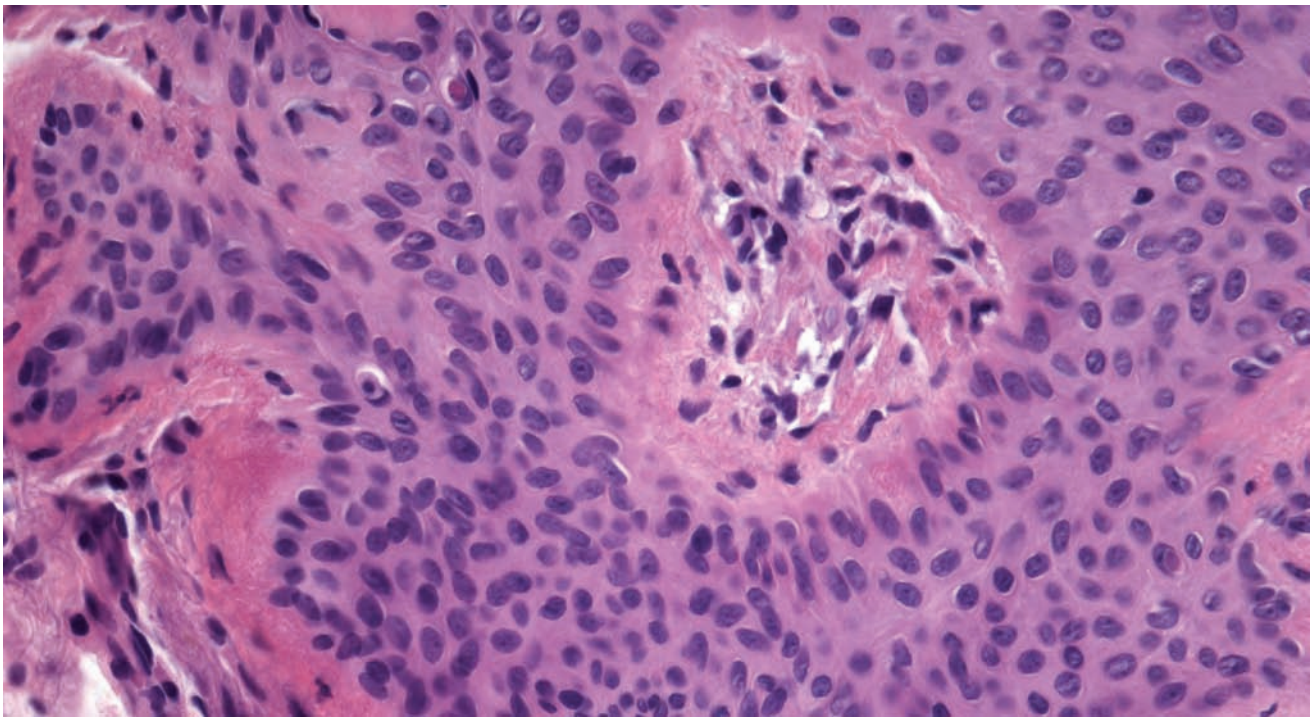

- Reticulated proliferation
- Pale cells in columns with "windows" of dermis in between
- Peripheral palisading

Tumor of the follicular infundibulum

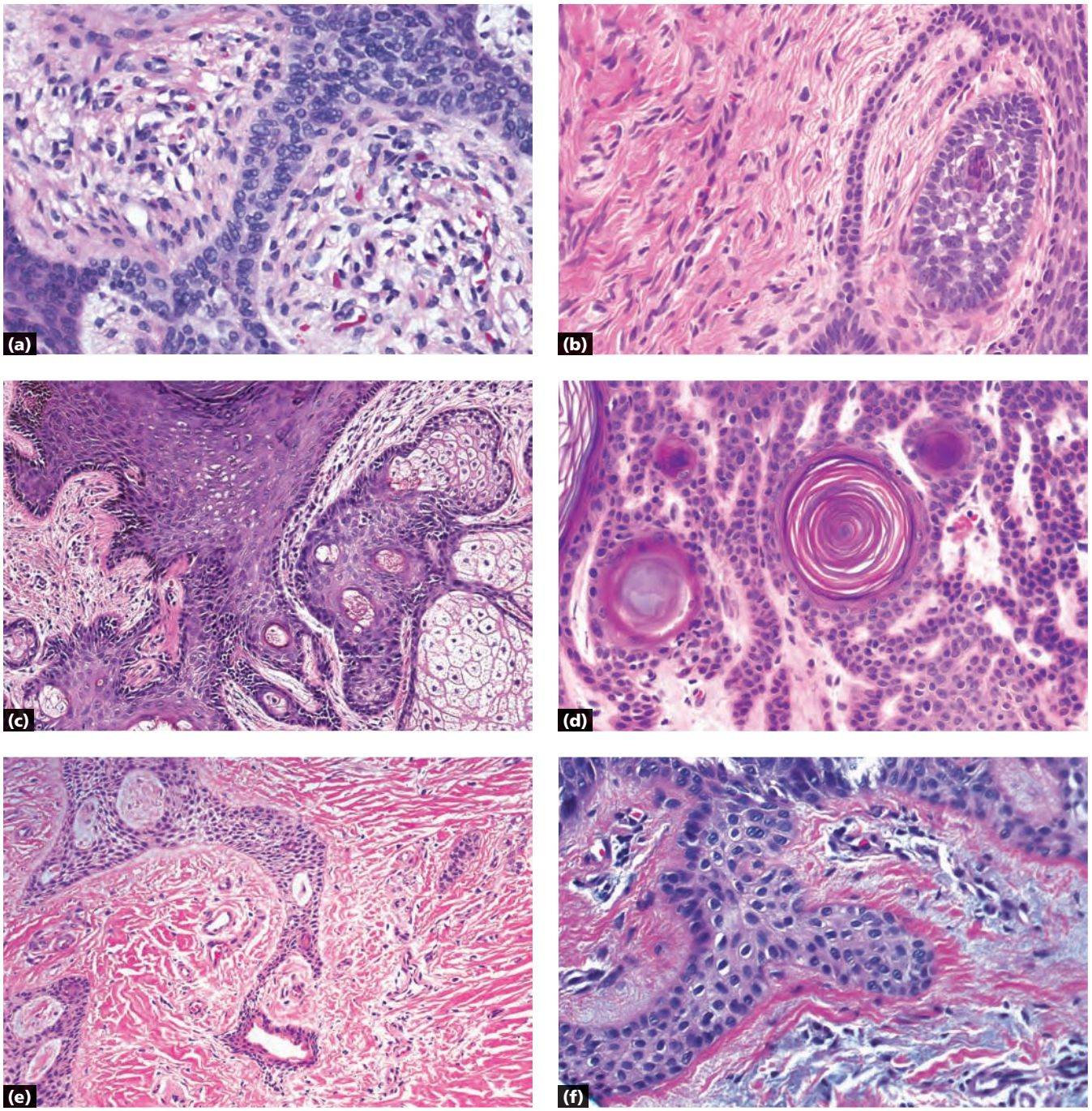

a Fibroepithelioma of Pinkus: strands of basaloid epithelium in fibrovascular stroma
b Fibrofolliculoma: hair follicle with adjacent fibrotic stroma and reticulated epithelium
c Nevus sebaceus: proliferation of epidermis connecting to sebaceous lobules and basaloid proliferations
d Seborrheic keratosis, reticulated: reticulated strands of banal keratinocytes, often pigmented; interspersed pseudohorn cysts
e Syringofibroadenoma: strands of uniform, round cells with interspersed ducts
f Tumor of the follicular infundibulum: pale cells in columns with "windows" of dermis in between

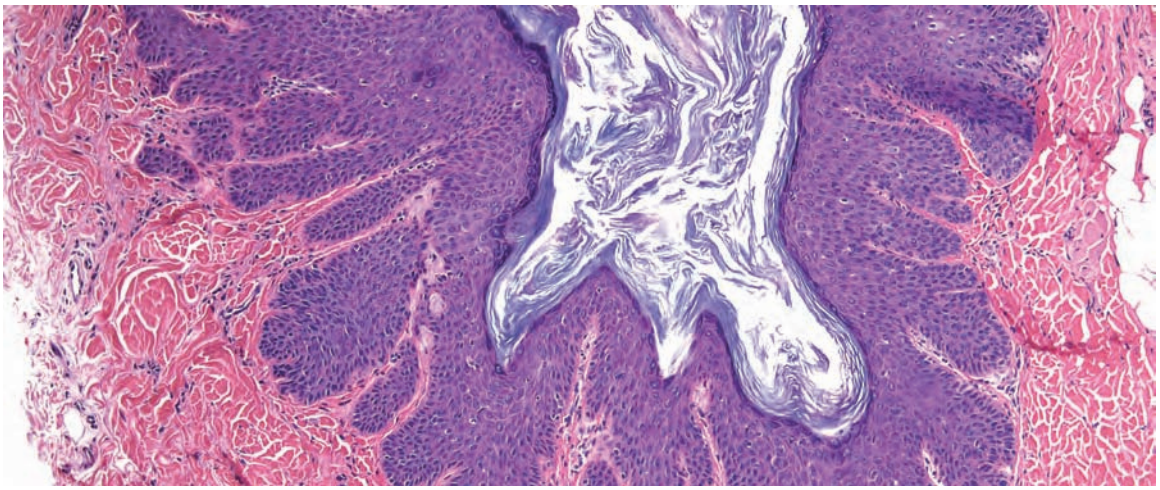

- Central pore
- Invaginated epidermis is acanthotic

Dilated pore of Winer

www.ebook3000.com

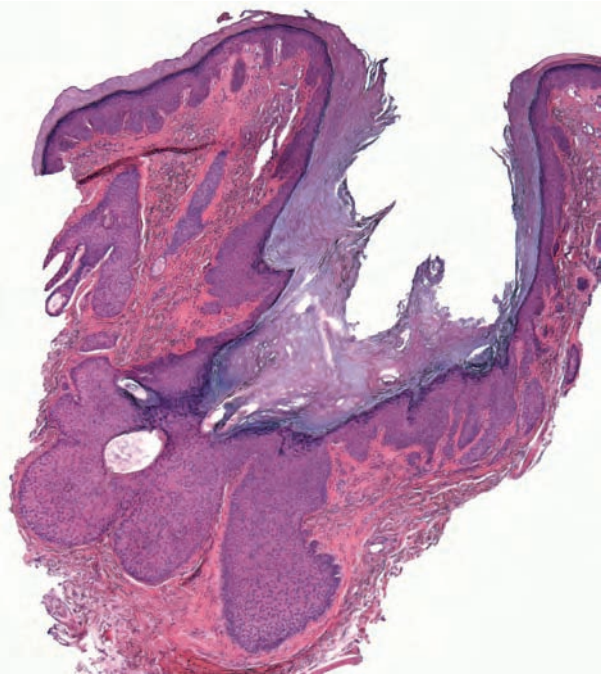

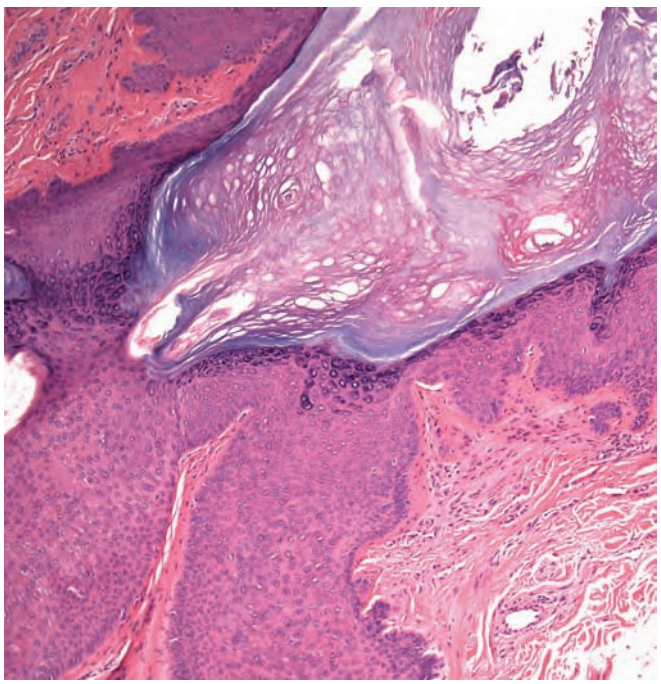

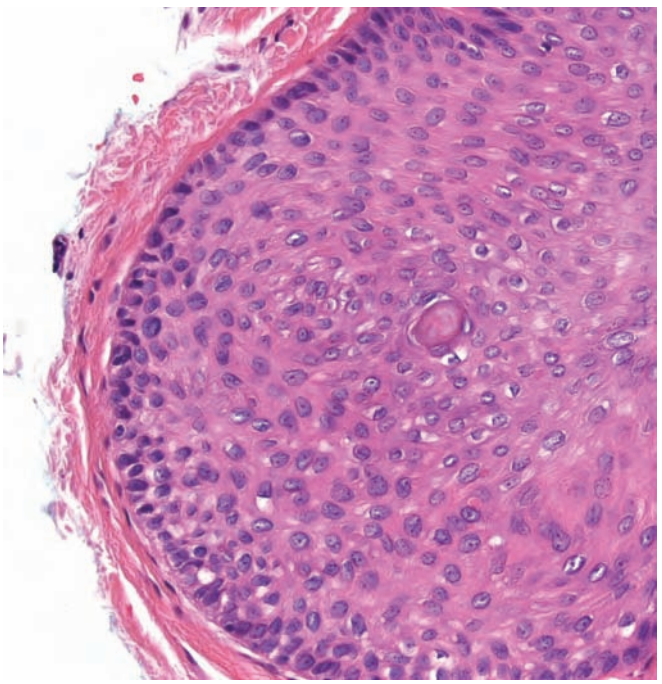

- Central pore
- Invaginated epidermis is acanthotic and has areas resembling outer root sheath with peripheral palisading around slightly pale cells

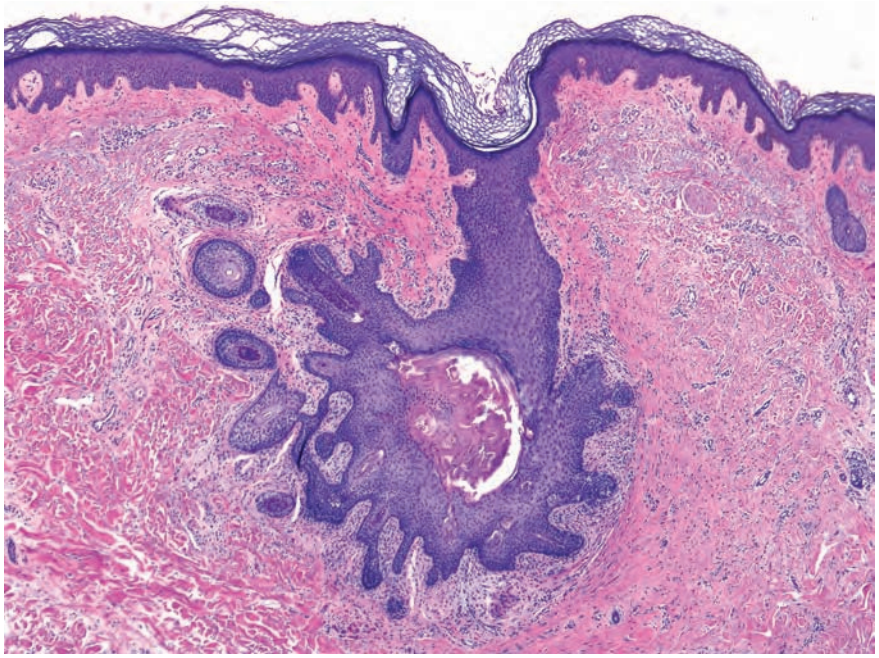

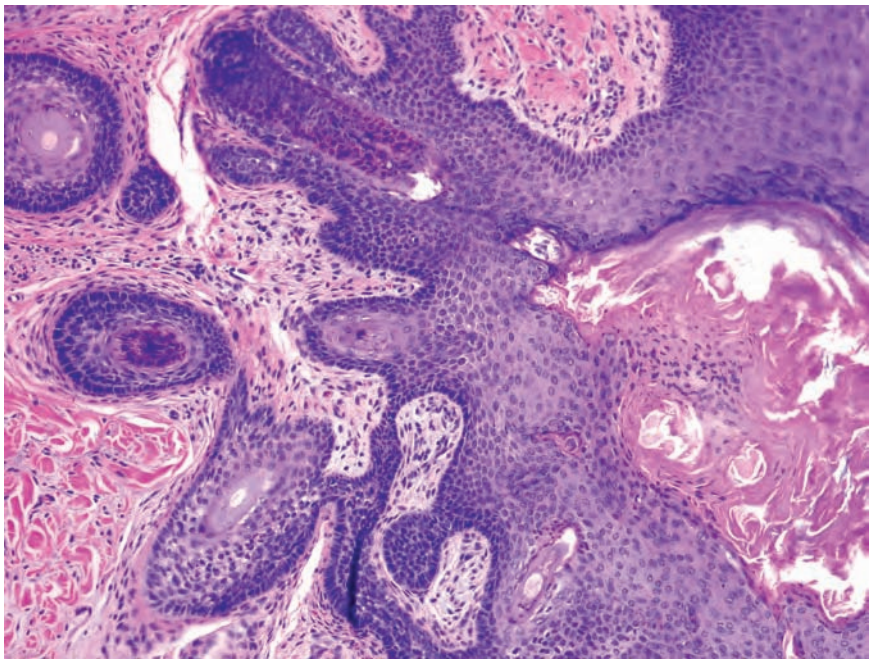

- Central pore
- Invaginated epidermis connects to a primary hair follicle
- Multiple secondary hair follicles radiating away from the central follicle

Trichofolliculoma

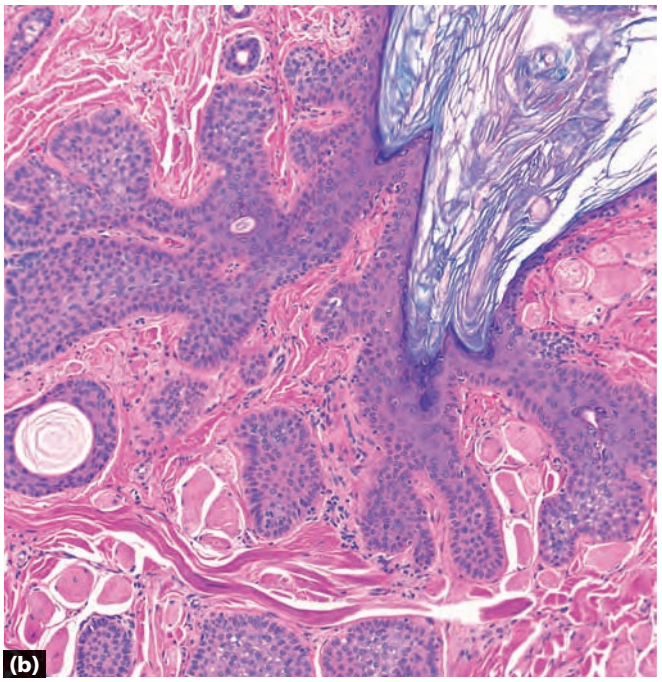

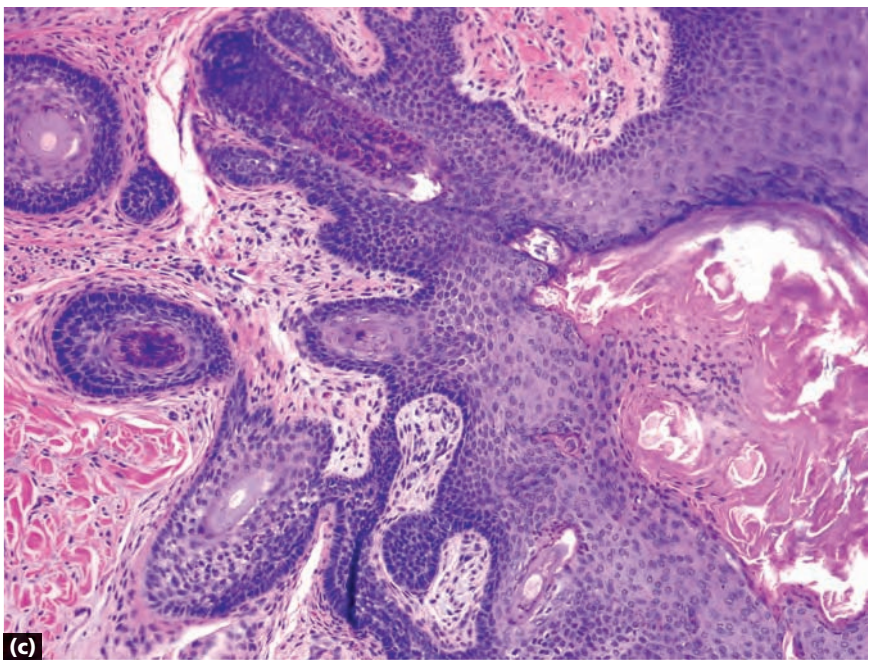

a Dilated pore of Winer: acanthotic epidermis
b Pilar sheath acanthoma: epidermal acanthosis and areas resembling outer root sheath
c Trichofolliculoma: primary follicle and surrounding secondary follicles

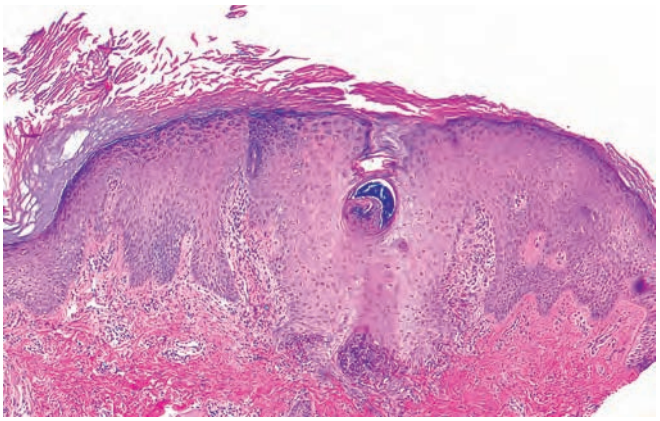

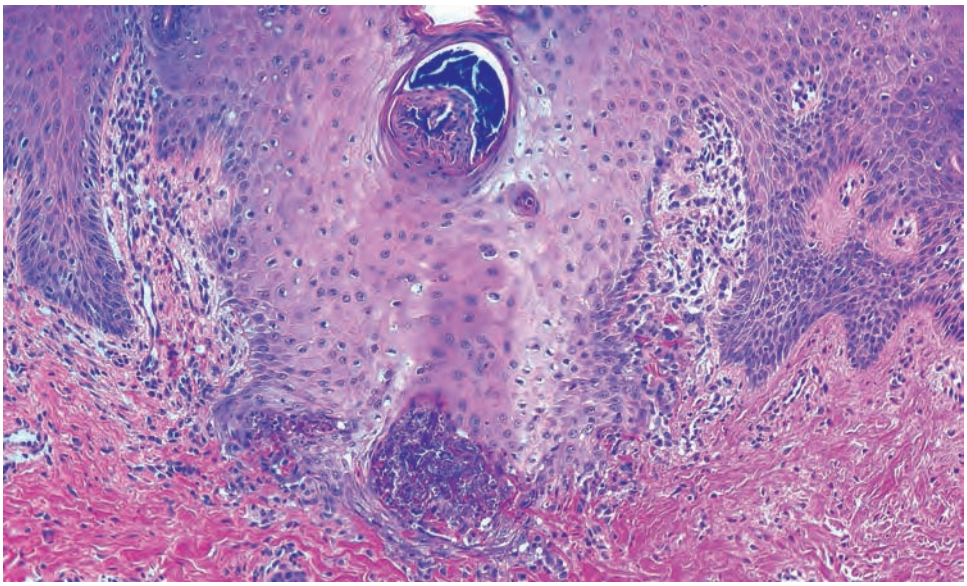

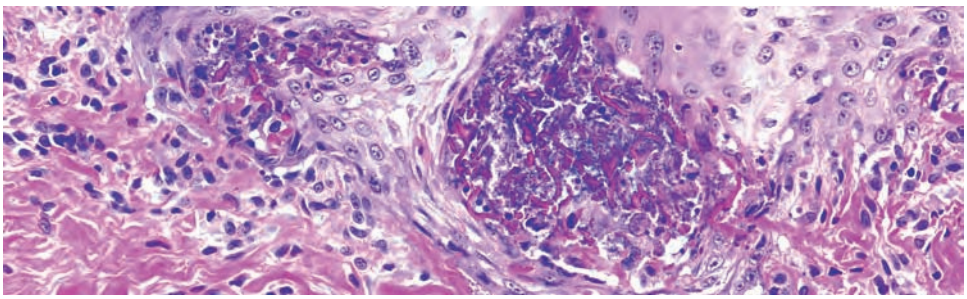

- Epidermal perforation
- Elongated claw (epidermal rete) gripping thin, glassy, eosinophilic elastic fibers and debris
- Altered elastic fibers are thinner than the collagen fibers in the dermis

Elastosis perforans serpiginosa

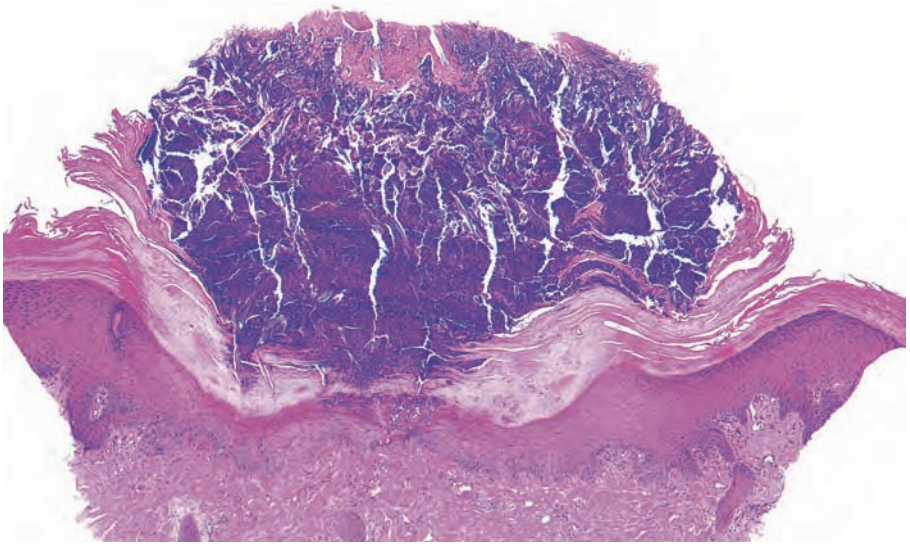

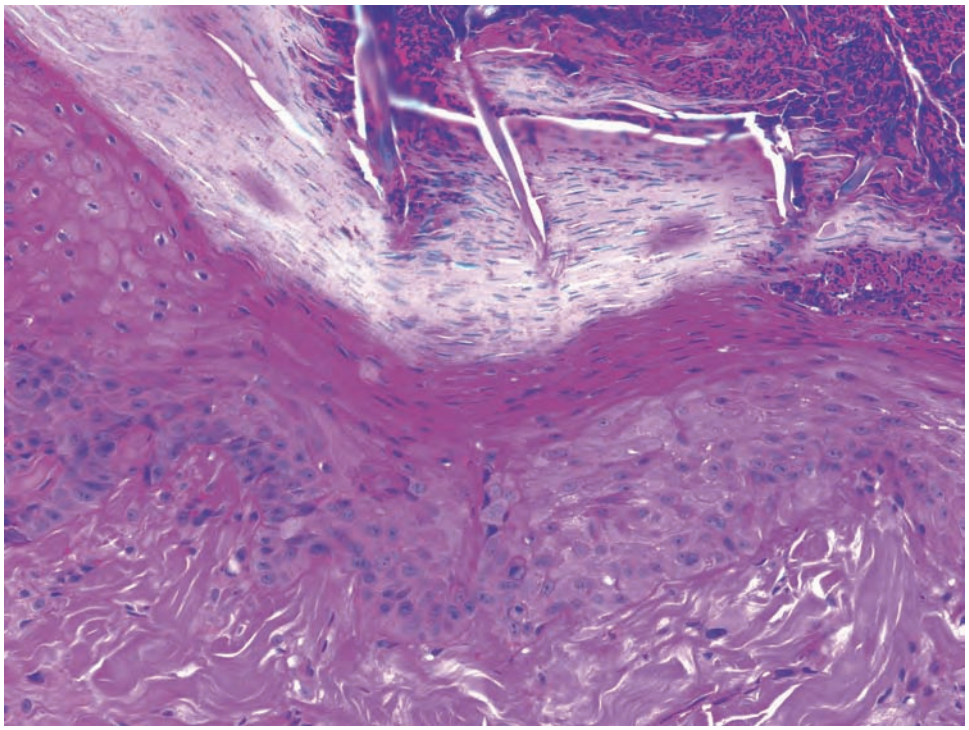

- Epidermal perforation
- Shallow cup-shaped architecture
- Pink collagen fibers extend vertically through epidermis

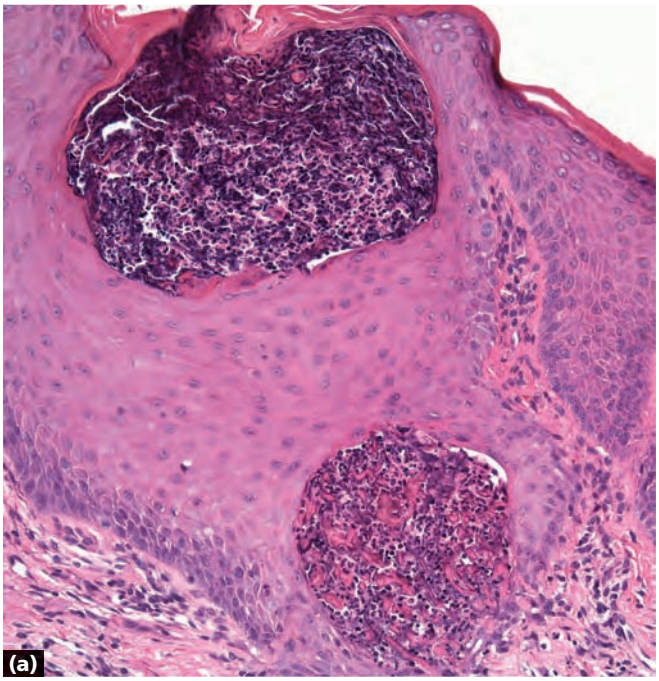

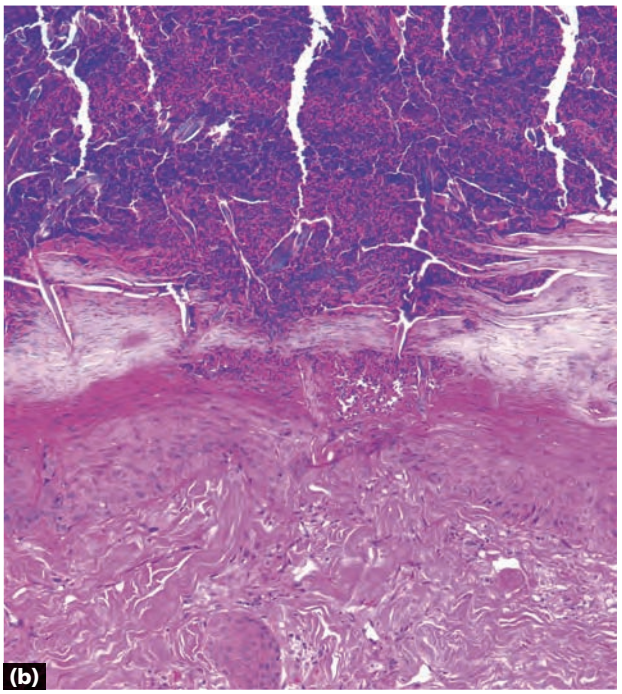

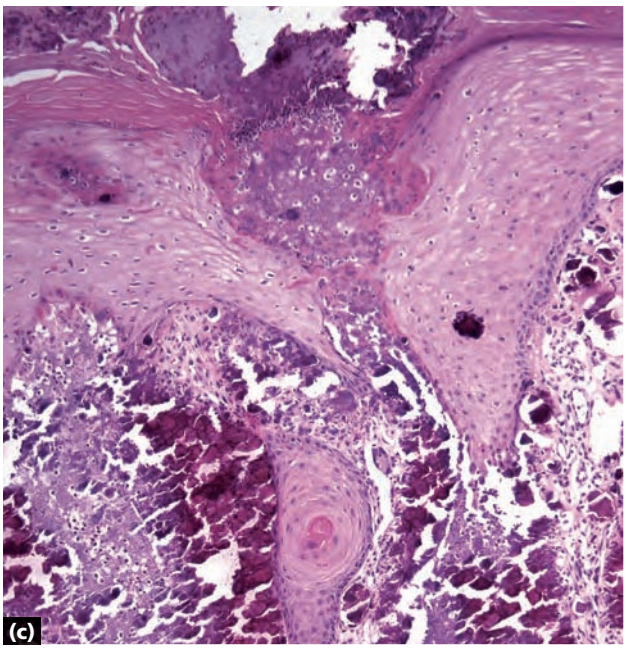

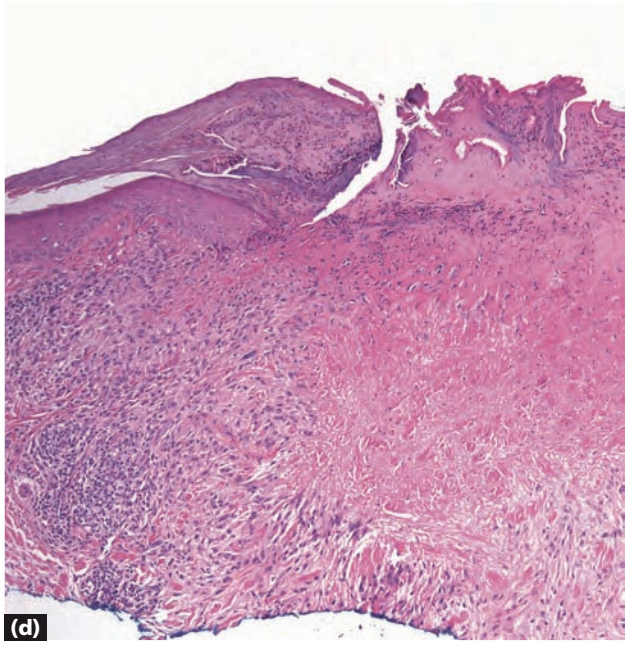

a Elastosis perforans serpiginosis: elongated rete forming a claw (tortuous channel); case courtesy of Whitney High, MD, JD
b Reactive perforating collagenosis: shallow, broad cup-shaped architecture
c Calcinosis cutis, perforating: chunky, bluish material (see page 264) at the base of an ulcer
d Granuloma annulare, perforating: palisading histiocytes around collagen with mucin (see page 89)

Note Other entities may also perforate the epidermis, for example, chondrodermatitis nodularis helicis, pseudoxanthoma elasticum.

Key differences

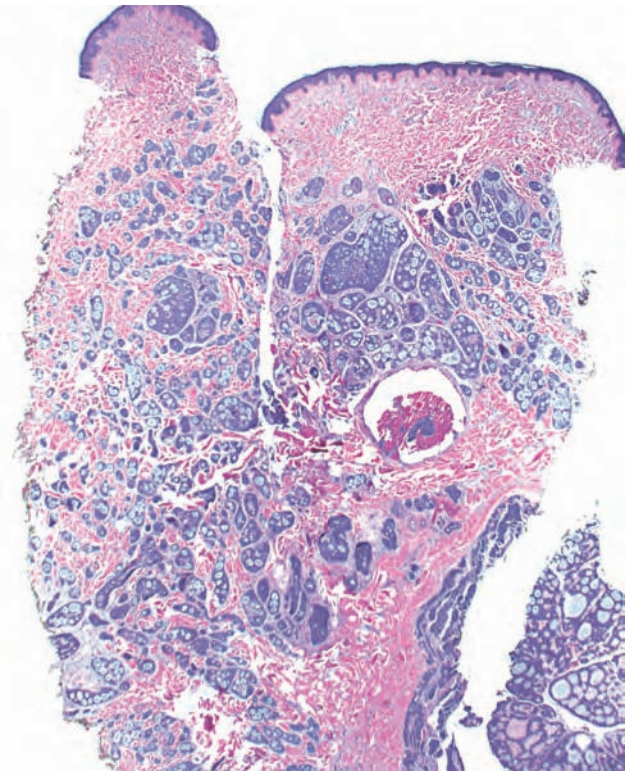

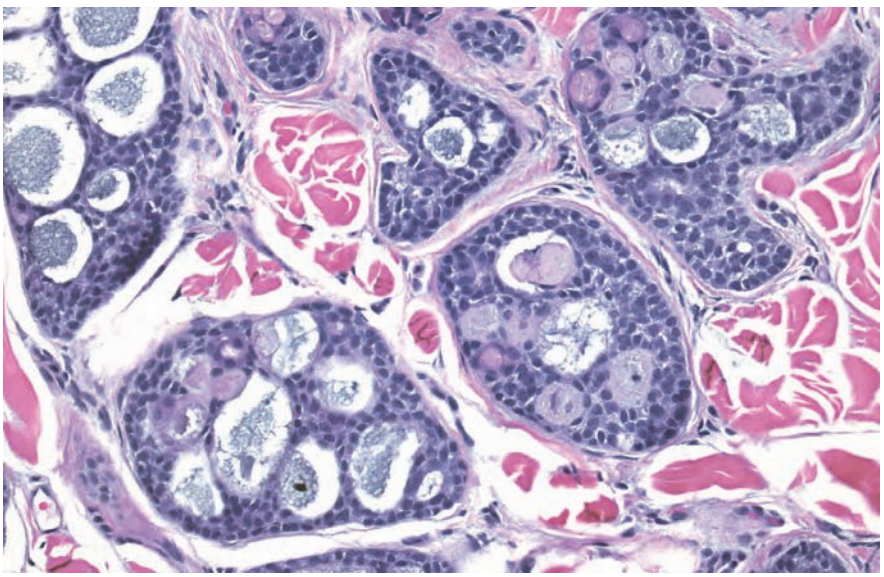

- Circular dermal islands
- Islands contain basaloid cells with a cribriform pattern of duct-like spaces filled with amorphous material

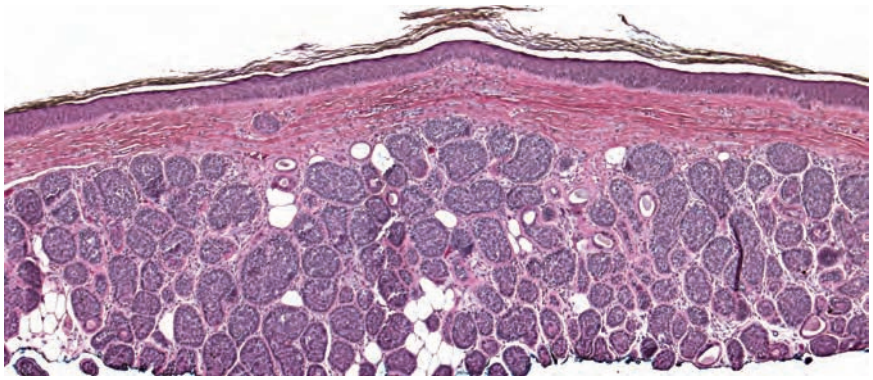

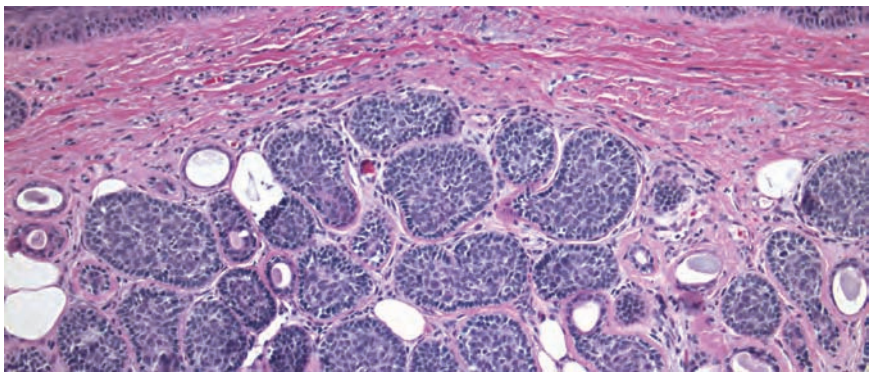

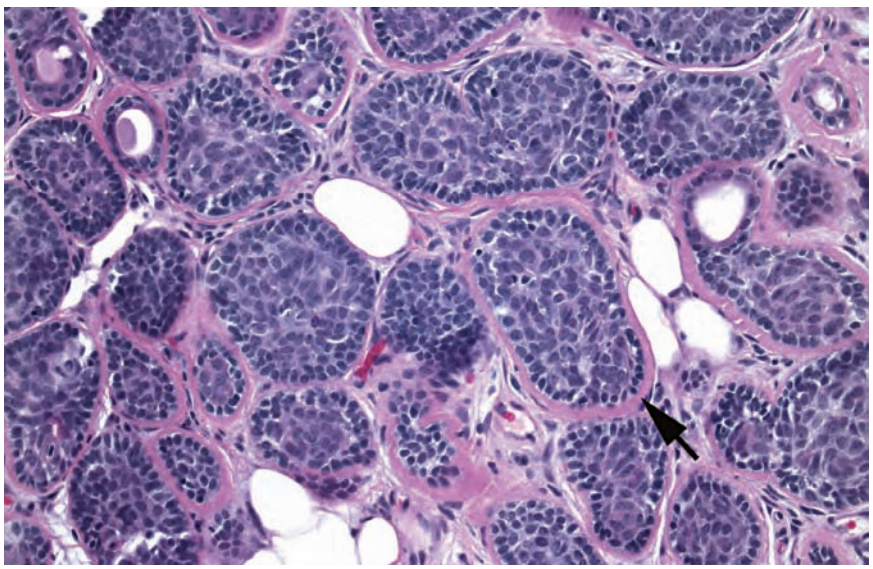

- Circular dermal islands
- Islands contain basaloid cells surrounded by a thick pink basement membrane (arrow)
- Islands arranged like a "jigsaw puzzle"

Cylindroma

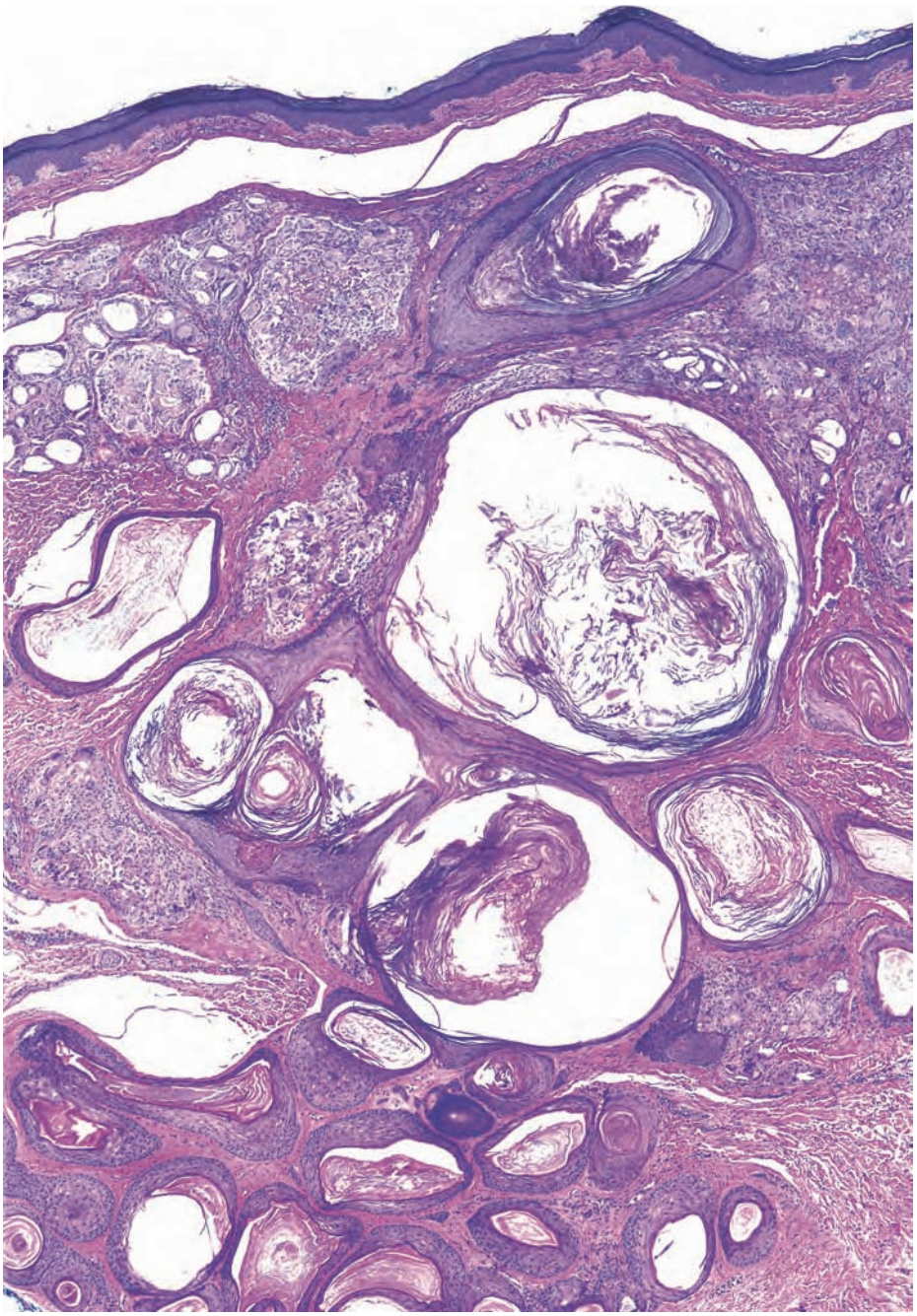

- Circular dermal islands
- Islands of epithelium with central flaky keratin (horn cysts)
- Interspersed basaloid cords

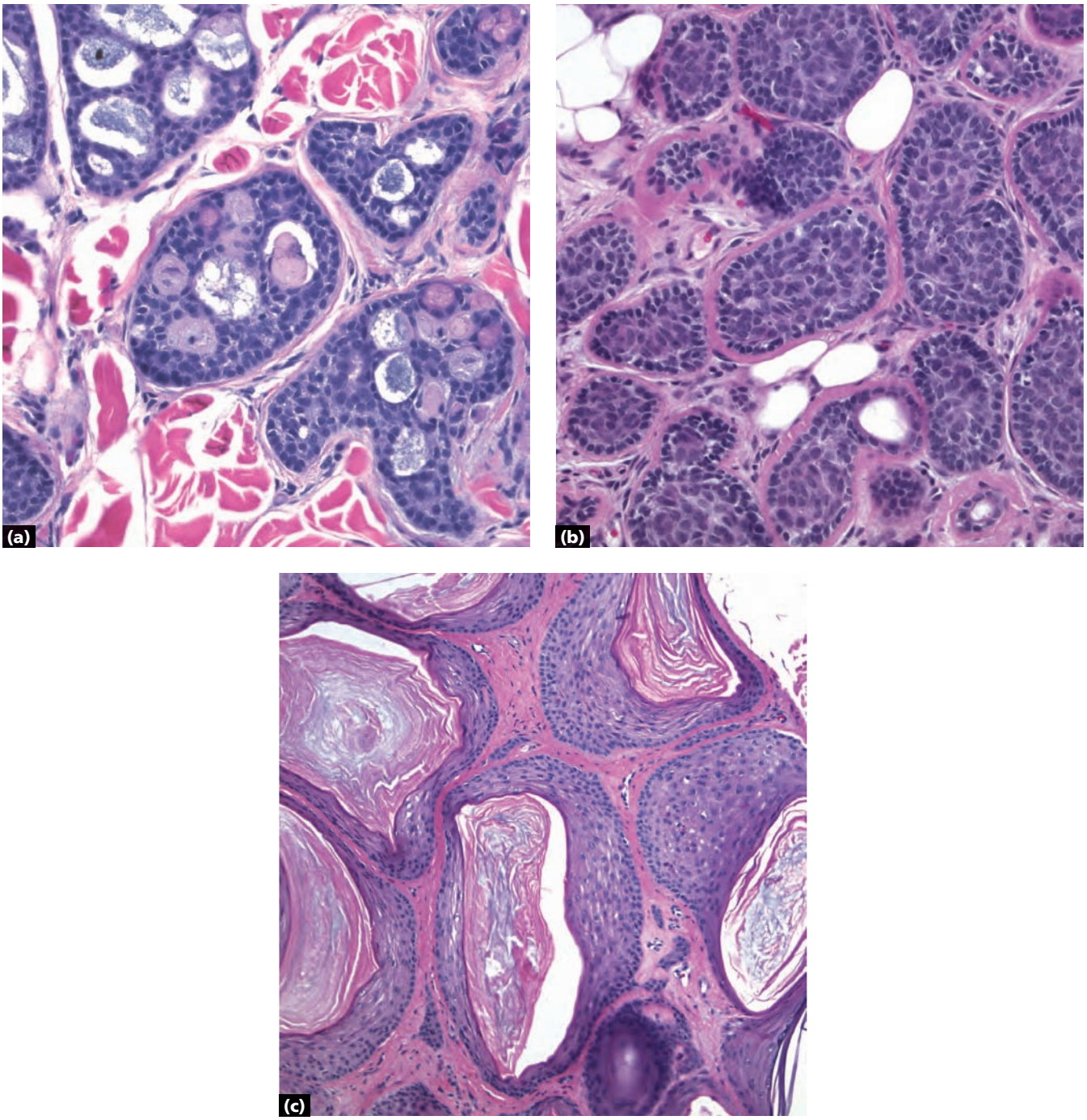

a Adenoid cystic carcinoma: cribriform pattern of duct-like structures
b Cylindroma: puzzle-like arrangement, thick/pink basement membrane
c Trichoadenoma: numerous horn cysts

Key differences

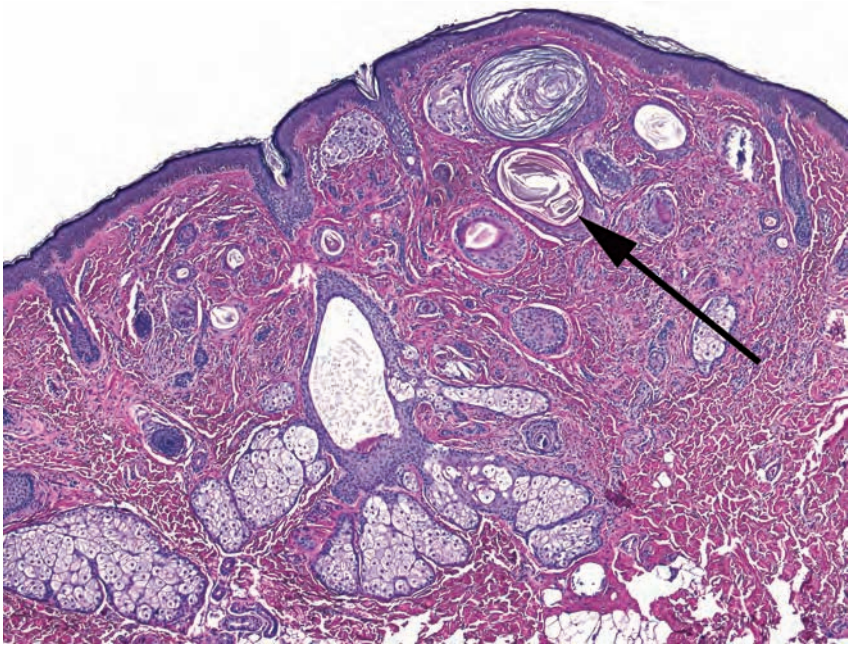

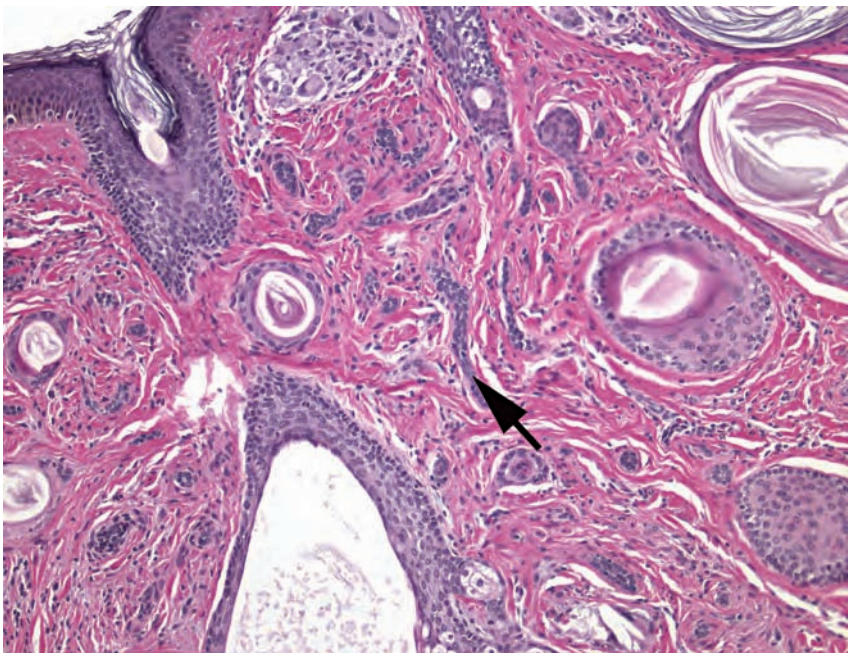

- Cords/tubules and comma shapes in dermis
- Numerous horn cysts (long arrow) in fibrotic stroma
- Tubules of two-layered epithelium (short arrow)
- Calcification often present
- Confined to dermis

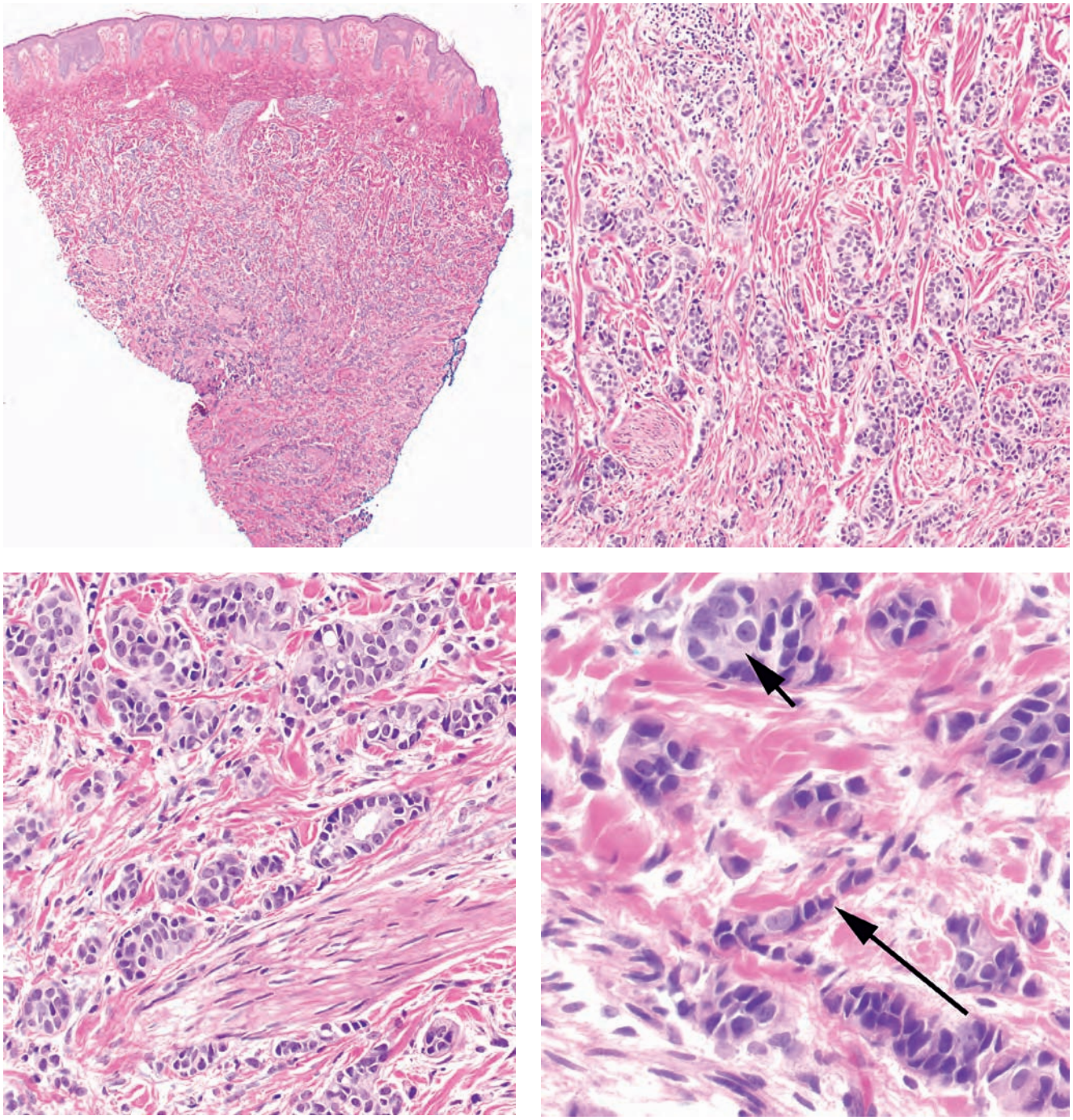

- Cords/tubules and comma shapes in dermis and below
- Tubules of single-layered ("Indian filing" – long arrow) and multi-layered epithelium
- Some cells forming gland-like structures (short arrow)
- Other metastatic carcinomas may look like this – need clinical history; immunohistochemistry may be helpful

Metastatic breast carcinoma

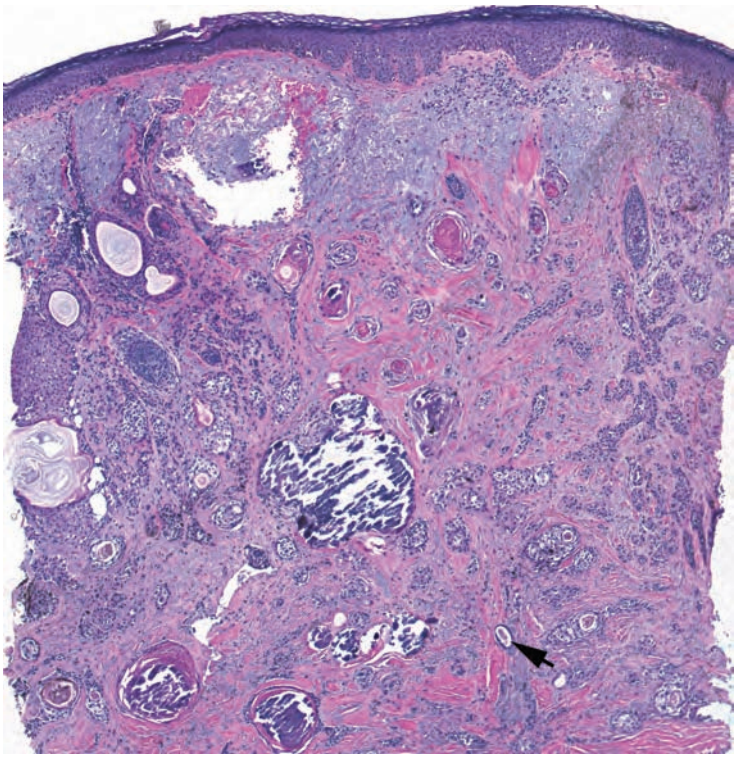

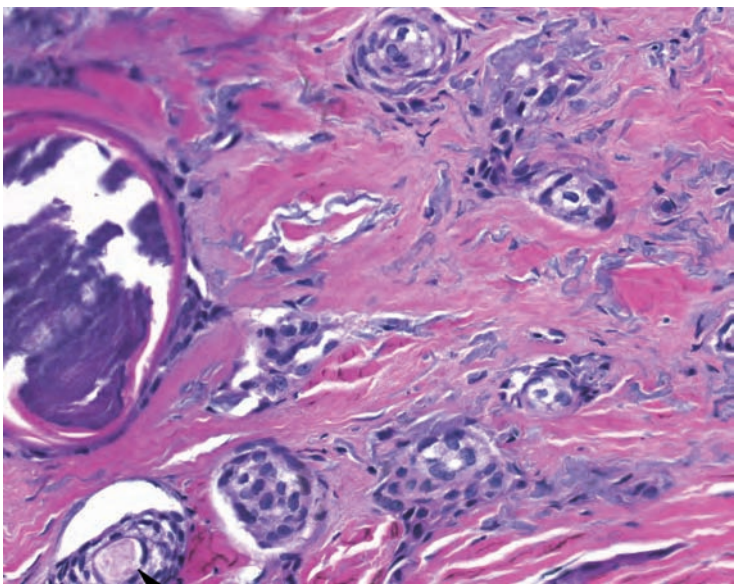

- Cords/tubules and comma shapes in dermis
- Comma shapes with duct-like spaces
- Deeply infiltrative (fills dermis)
- Perineural involvement

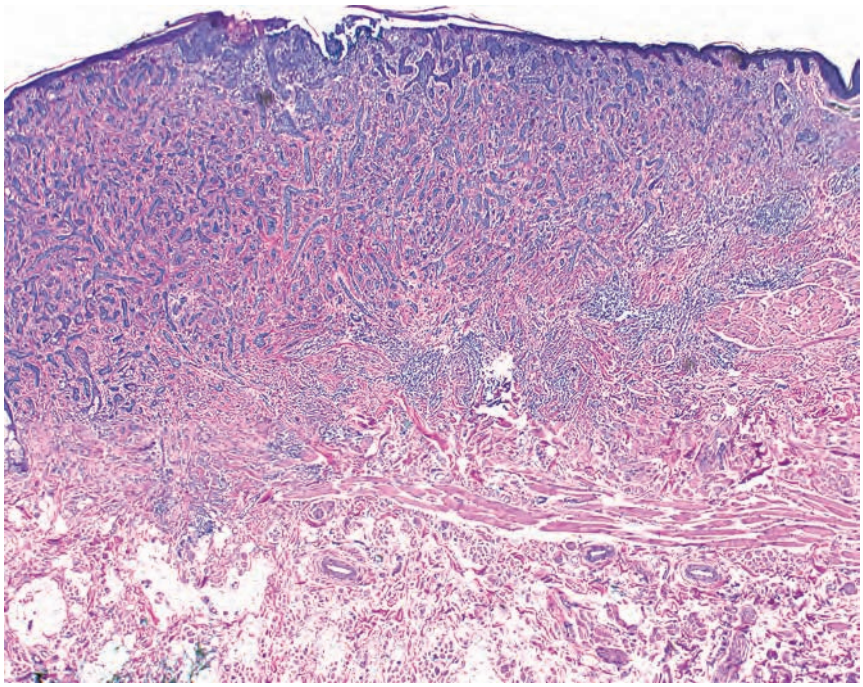

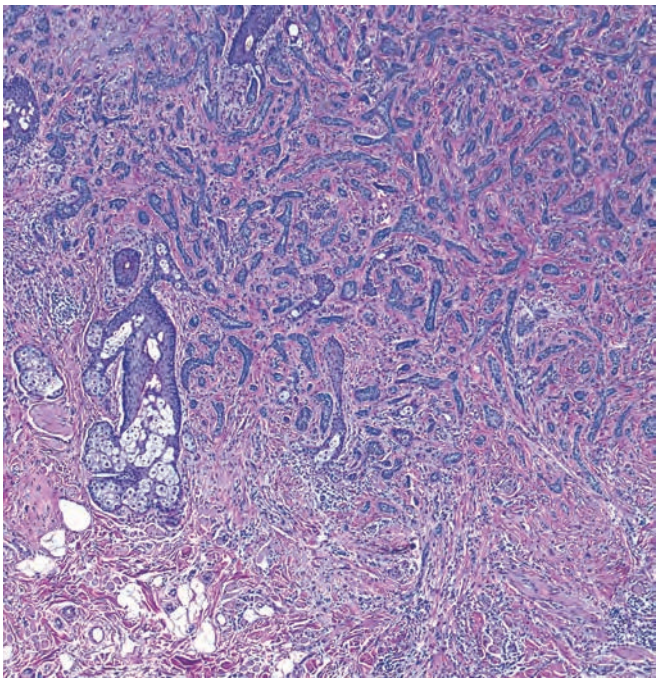

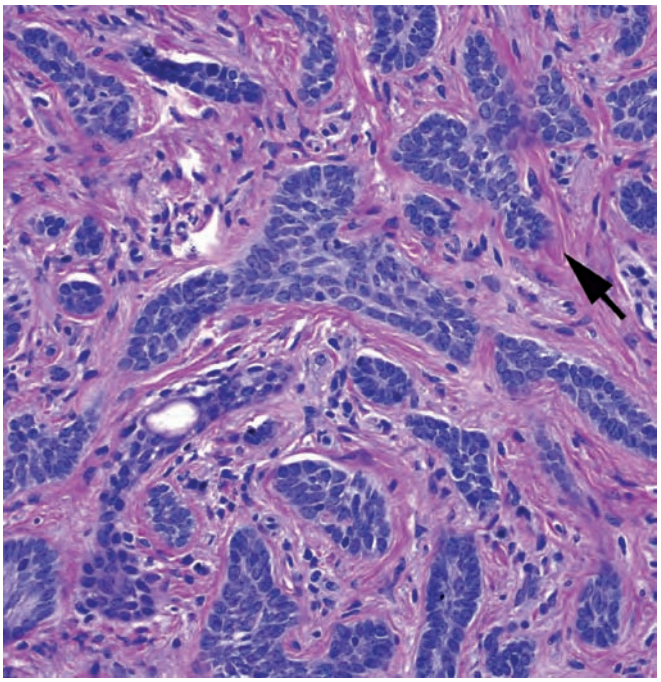

- Cords/tubules and comma shapes in dermis
- Tubules of epithelium composed of basaloid cells with hints of peripheral palisading
- New collagen forming around islands (arrow)
- Deeply infiltrative

Morpheaform basal cell carcinoma

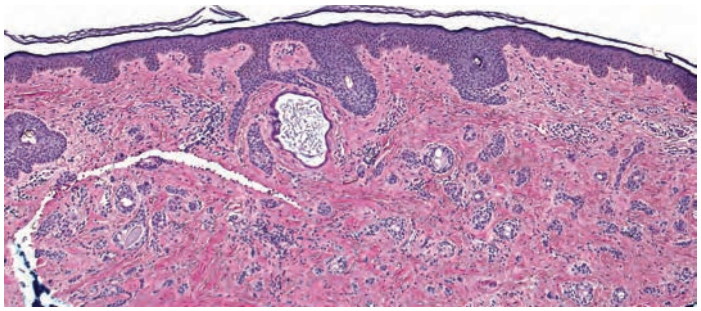

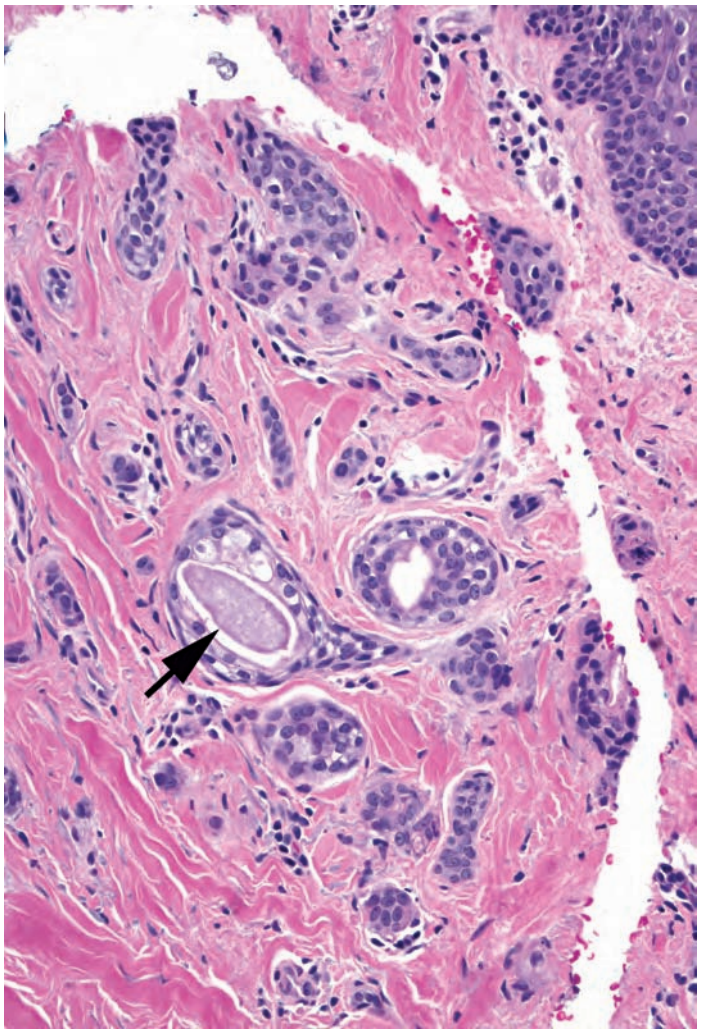

- Cords/tubules and comma shapes in dermis
- Restricted to upper dermis
- "Tadpoles" of epithelium with duct-like structures in heads (arrow)
- Darker cells at periphery, clear cells in center
- Eosinophilic cuticle lining lumina
- No horn cysts

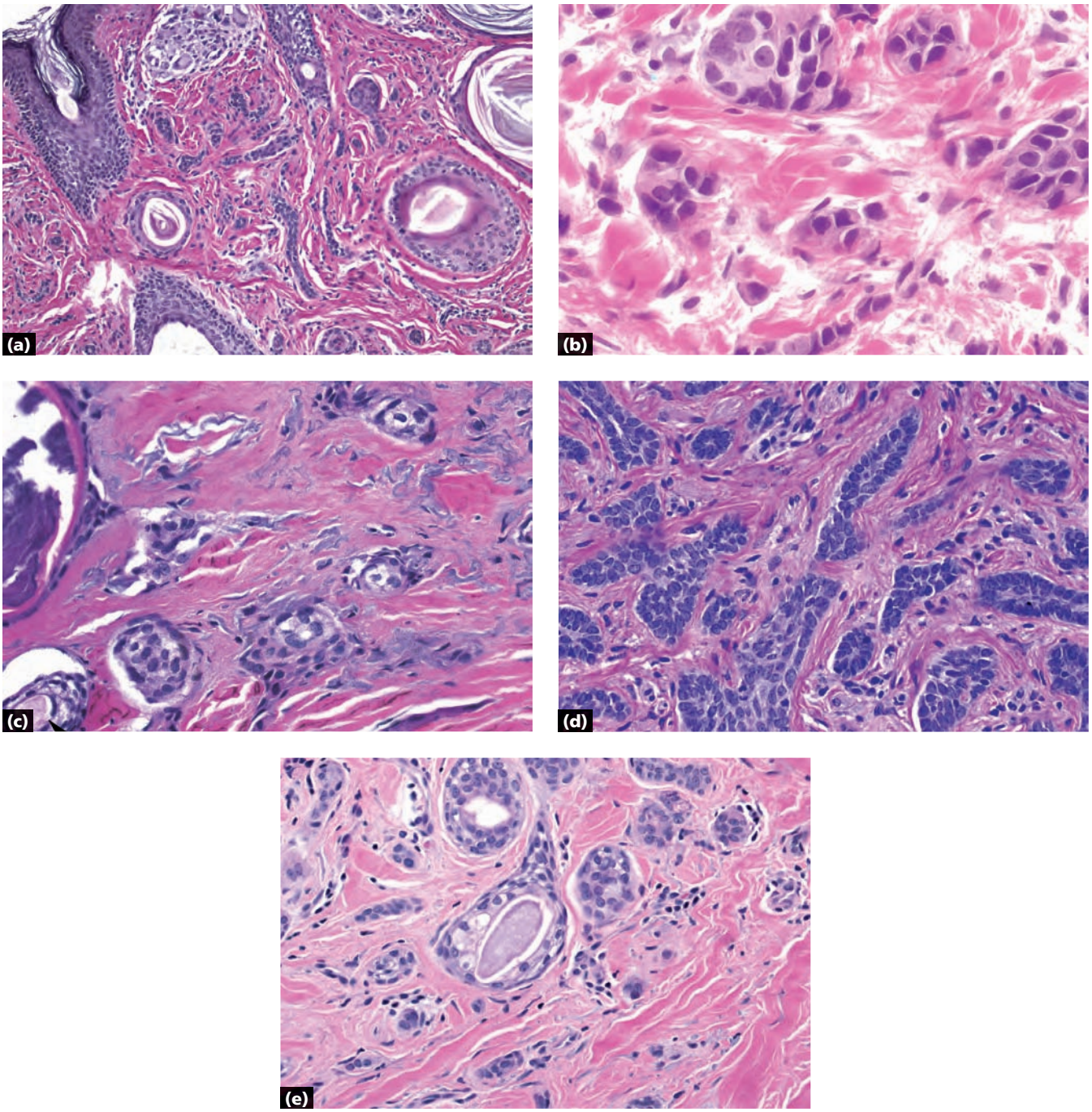

a Desmoplastic trichoepithelioma: horn cysts, no clear cells, circular areas of epithelium surround keratin
b Metastatic breast carcinoma: single filing of atypical cells, deeply infiltrative
c Microcystic adnexal carcinoma: like syringoma with tadpole-like structures but deeply infiltrative, perineural involvement
d Morpheaform basal cell carcinoma: infiltrative cords of basaloid cells with hints of peripheral palisading; may have some duct-like structures (but less than **c**)
e Syringoma: superficial tadpoles with clear cells

Key differences

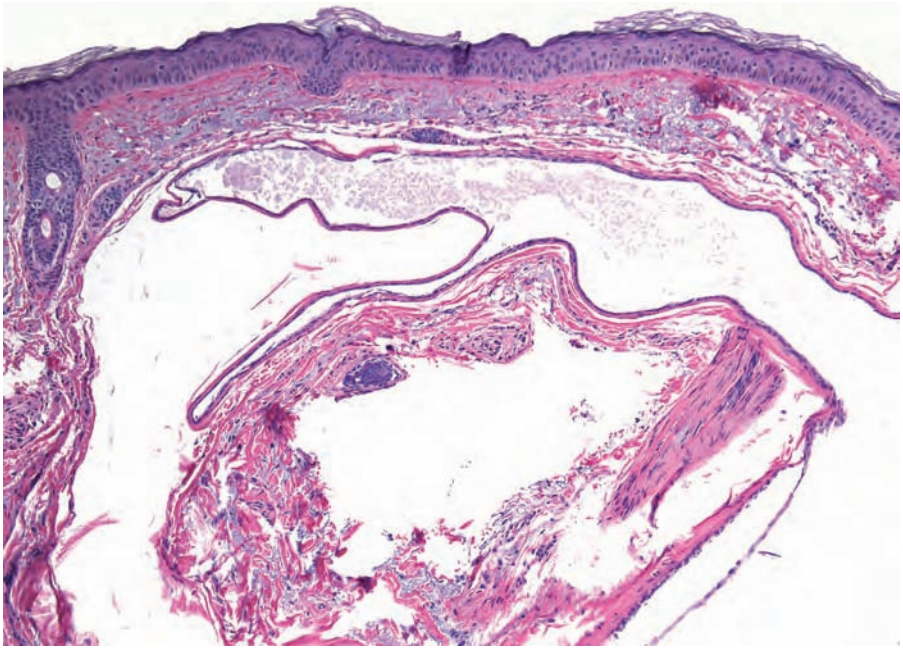

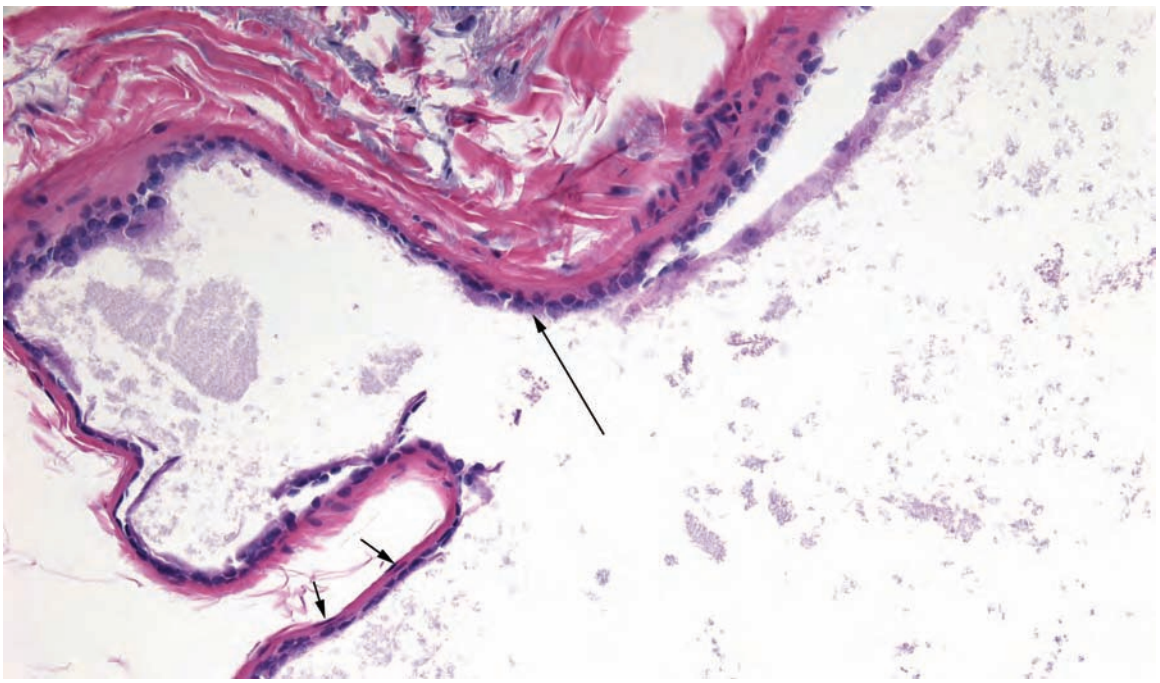

- Space with a lining
- Lining composed of an inner layer of cells with decapitation secretion (long arrow) and a compressed layer of myoepithelial cells (short arrow)

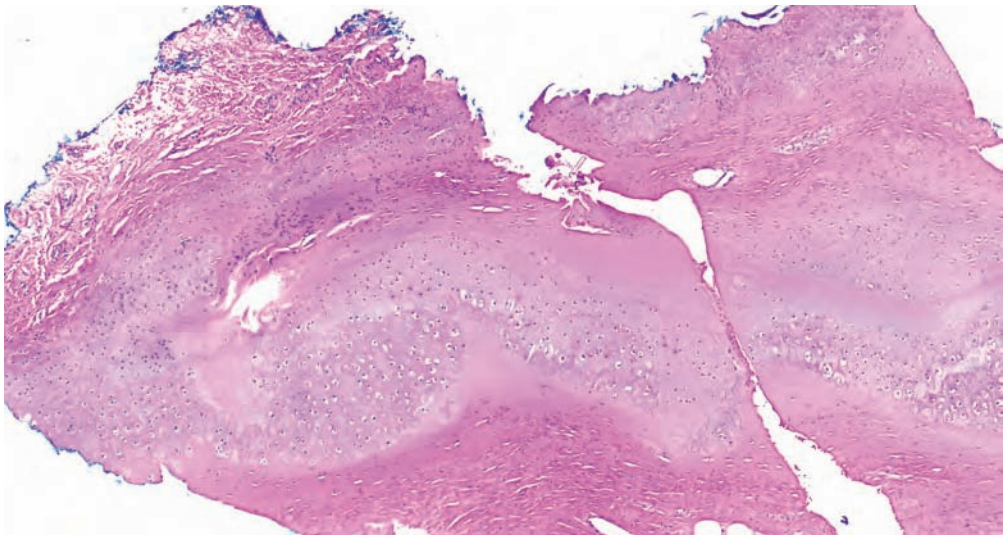

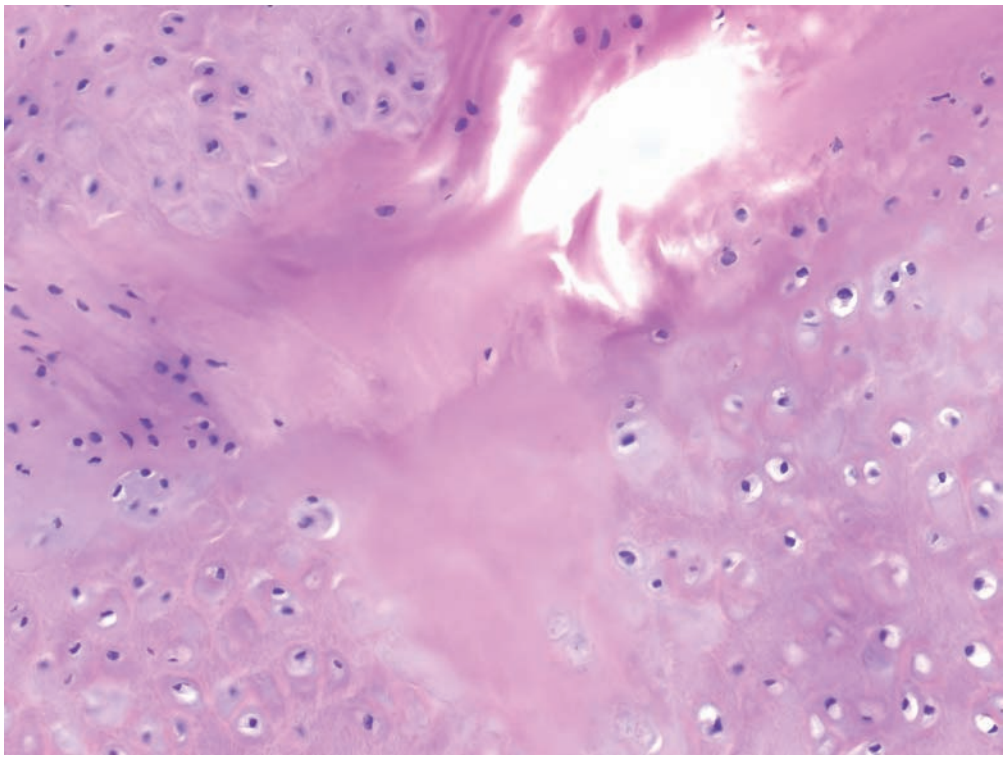

- Space with a lining
- "Lining" is not a true epithelial layer but is cartilage
- Centrally, there is degeneration of cartilage

Auricular pseudocyst

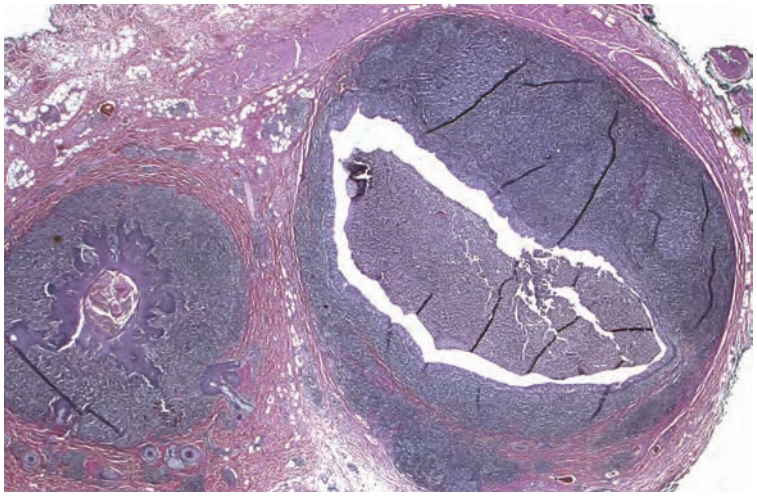

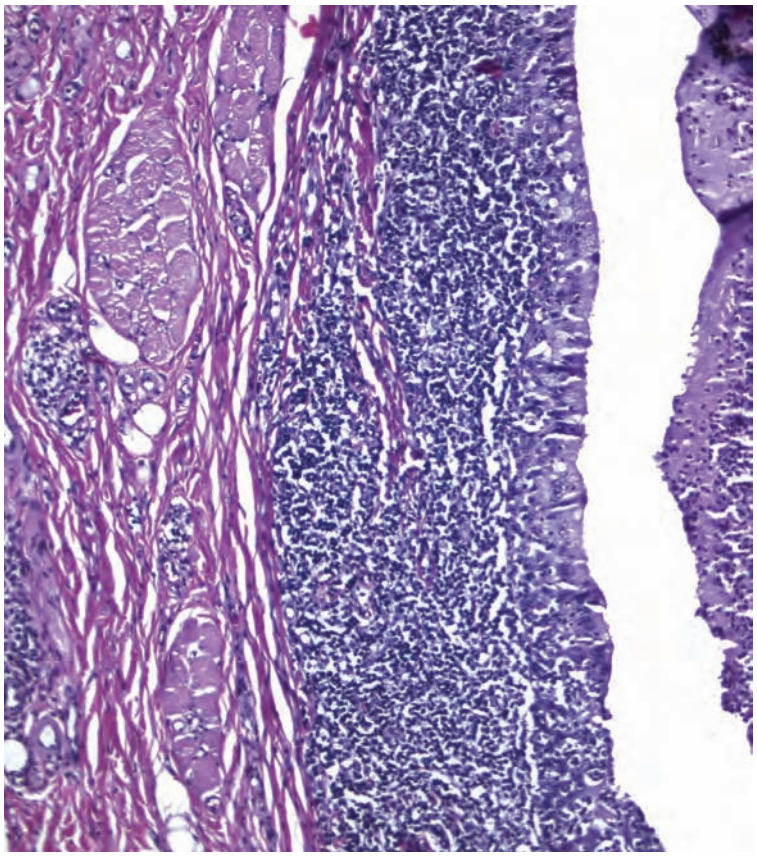

- Space with a lining
- Lining composed of squamous or sometimes cuboidal/ columnar epithelium often with squamous metaplasia
- Prominent lymphoid follicles in wall

Branchial cleft cyst

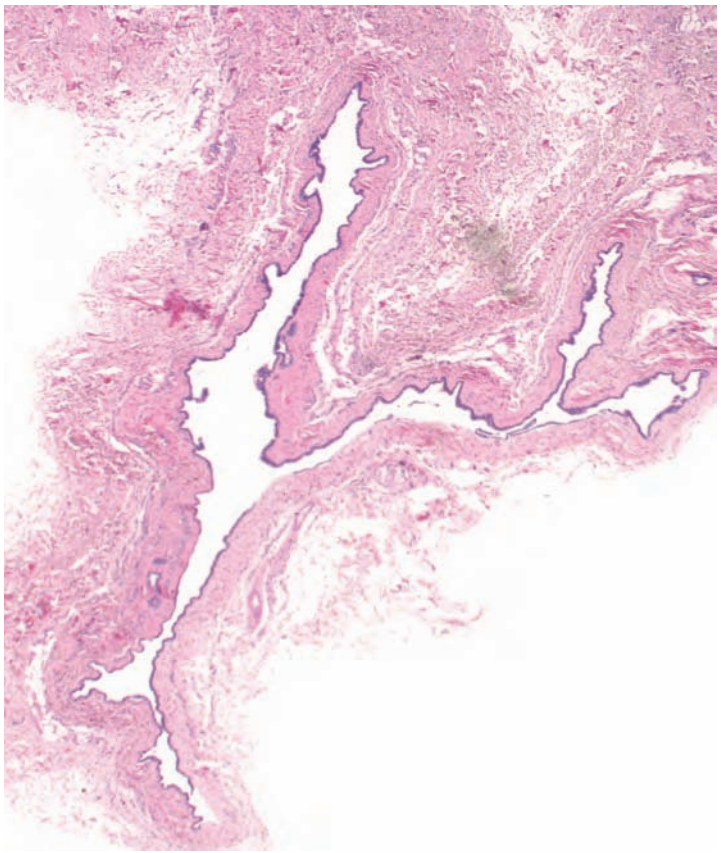

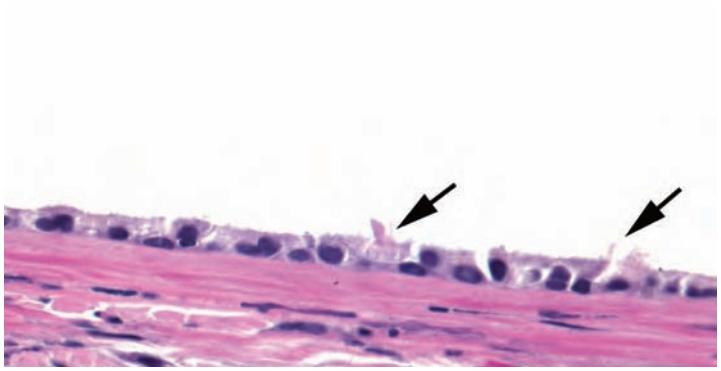

- Space with a lining
- Lining composed of cuboidal/columnar epithelium with cilia (arrows)

Cutaneous ciliated cyst

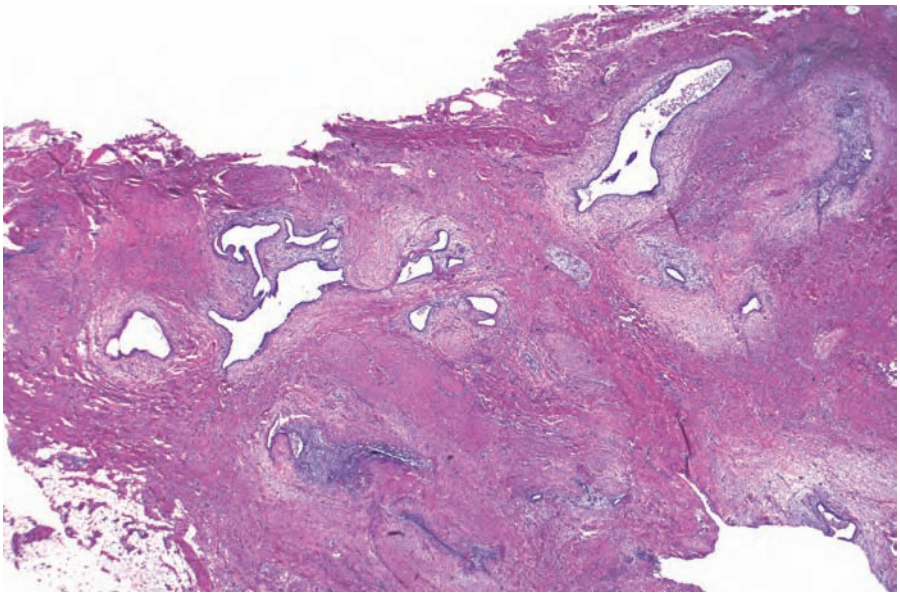

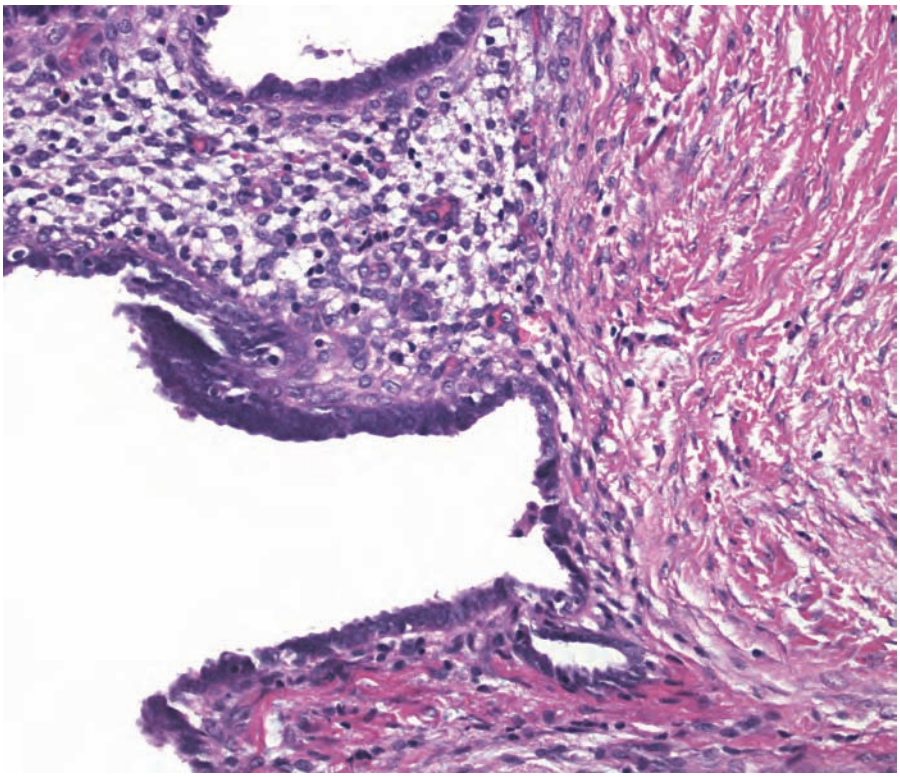

- Space with a lining
- Spaces embedded in a fibrovascular stroma (endometrial stroma)
- Lining composed of crowded blue cells
- Hemosiderin deposits common in stroma

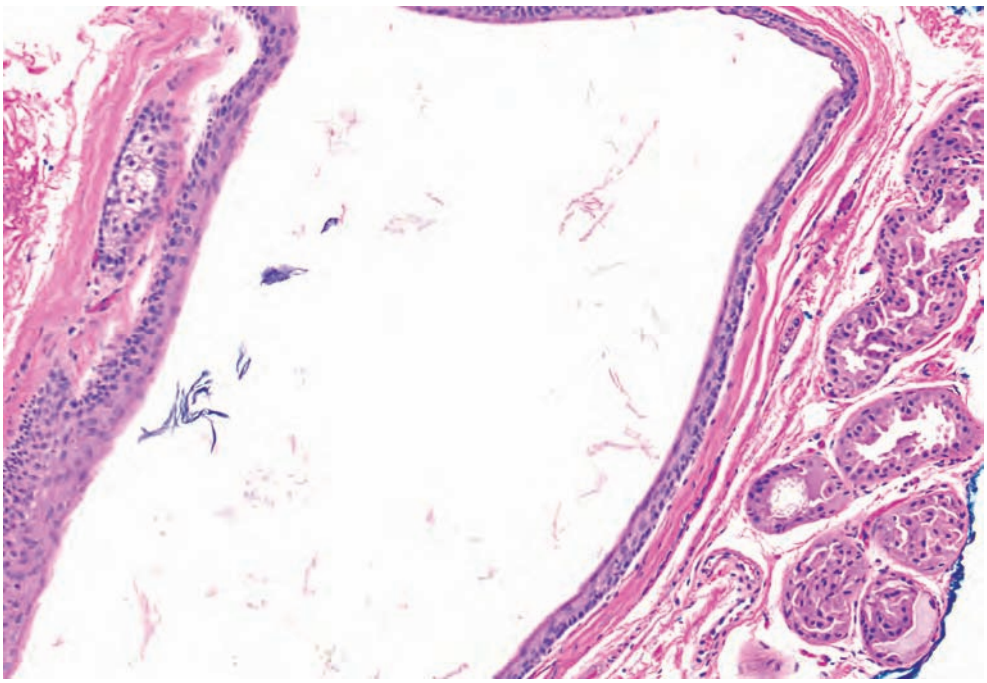

- Space with a lining
- Lining composed of squamous epithelium
- Walls contain adnexal structures

Dermoid cyst

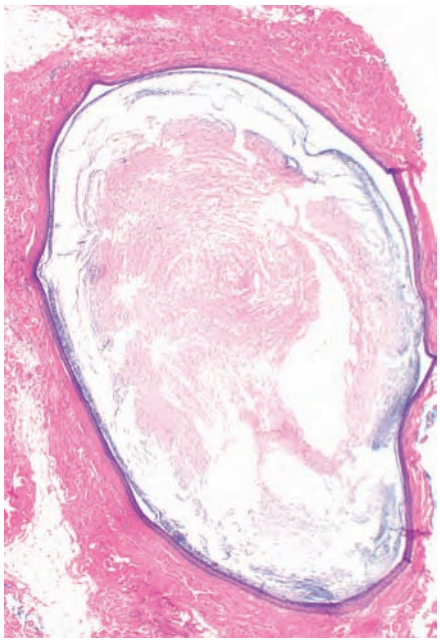

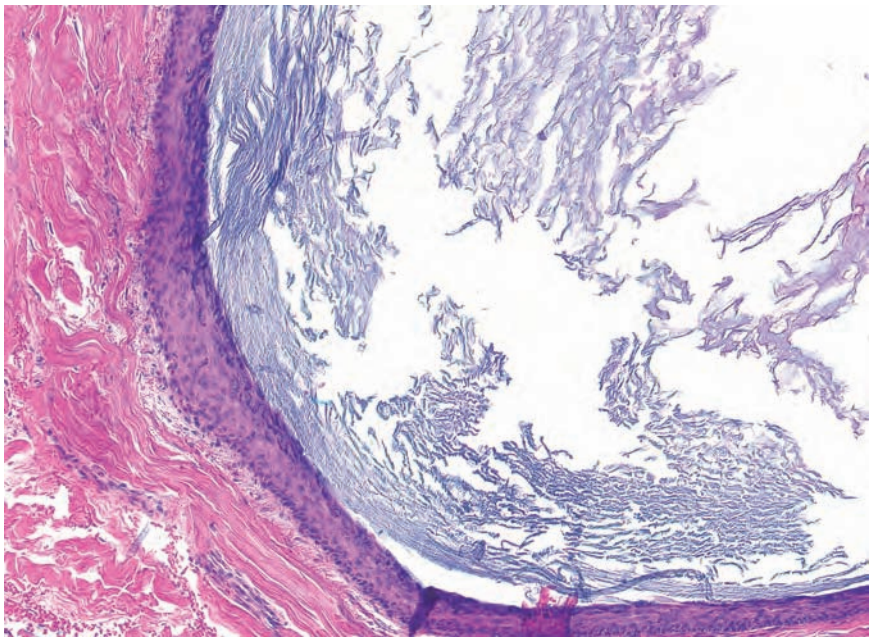

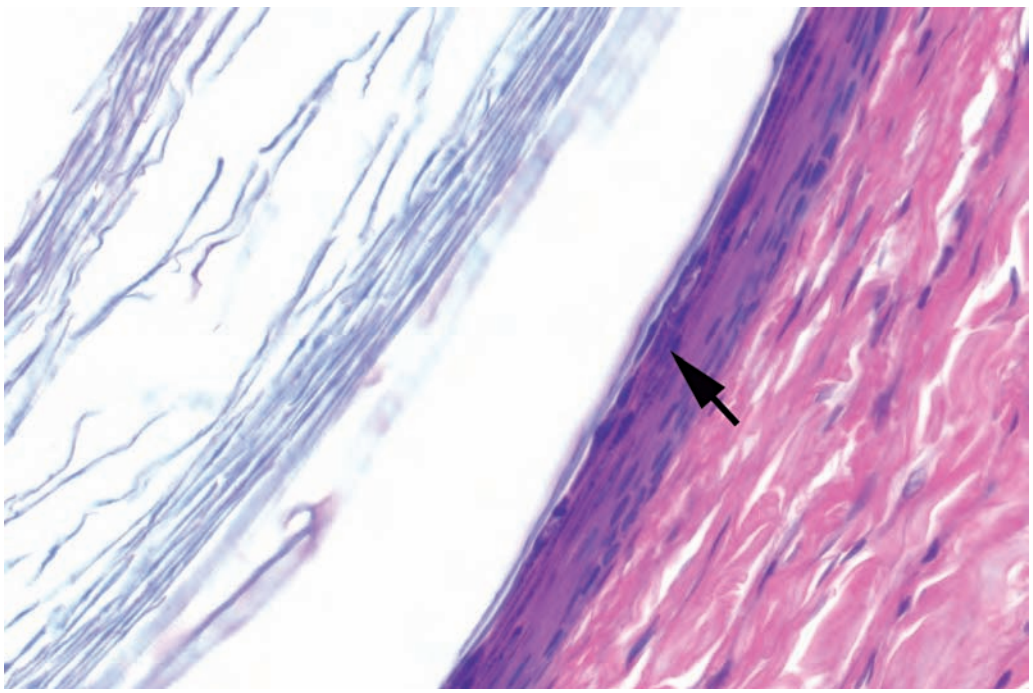

- Space with a lining
- Lining composed of squamous epithelium with a granular layer (arrow)
- Cyst contents composed of flakes of keratin

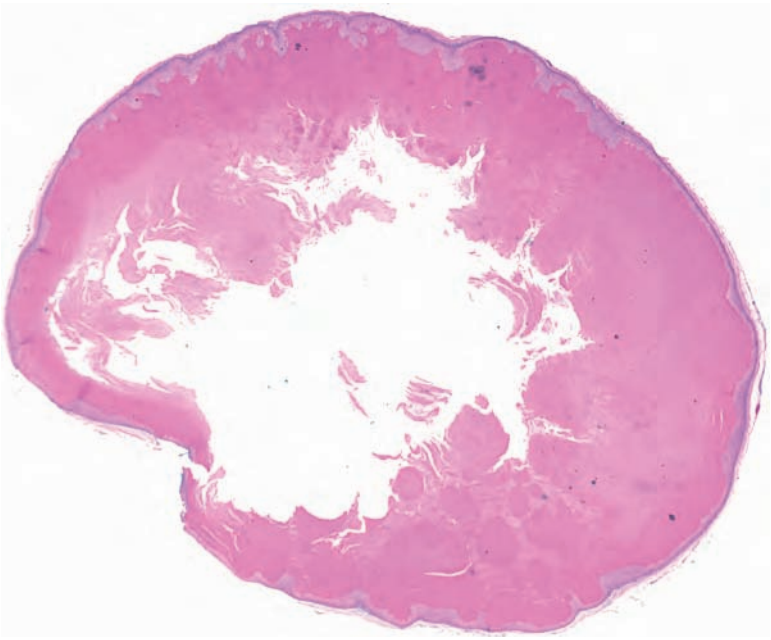

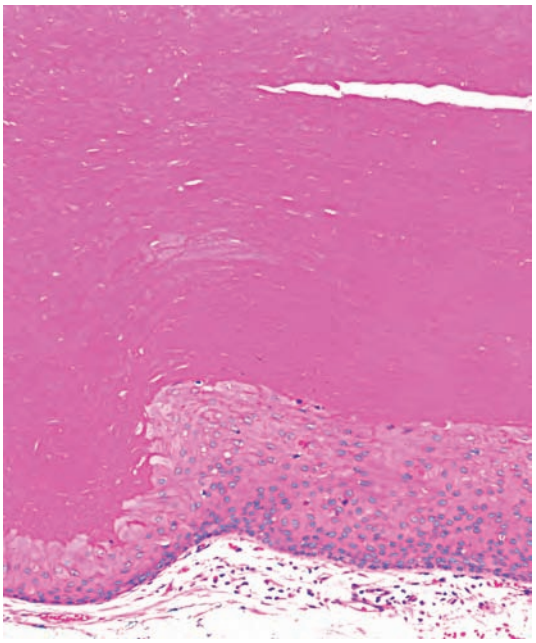

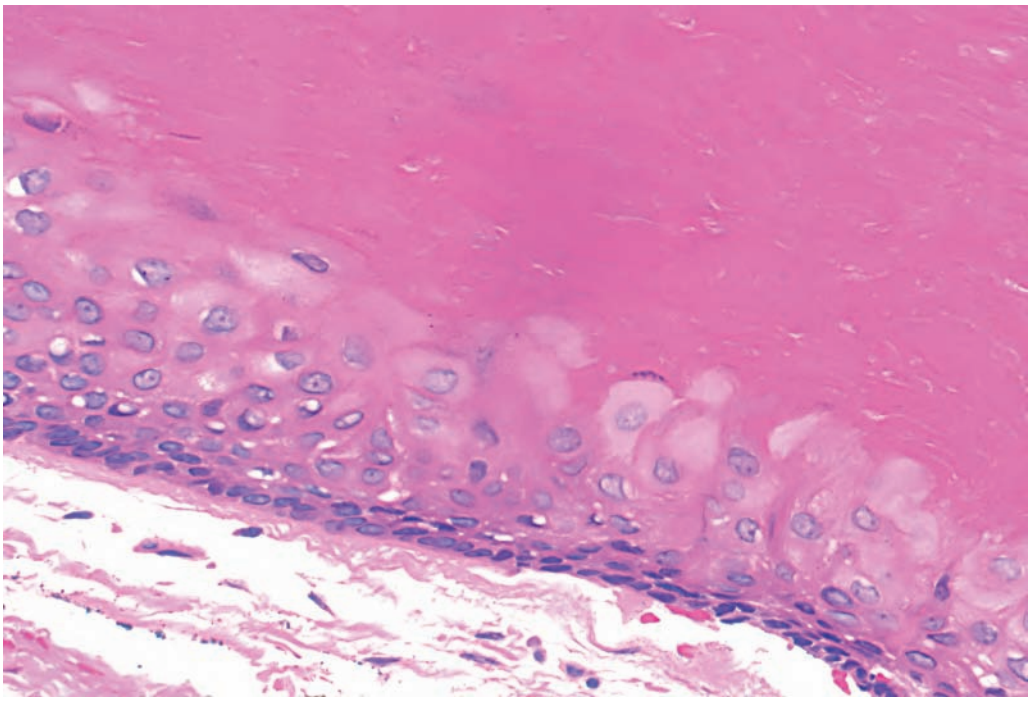

- Space with a lining
- Lining composed of squamous epithelium without a granular layer
- Cyst contents composed of dense pink keratin

Pilar cyst

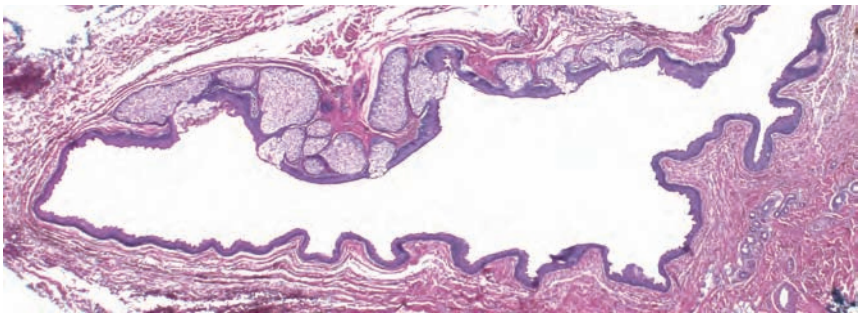

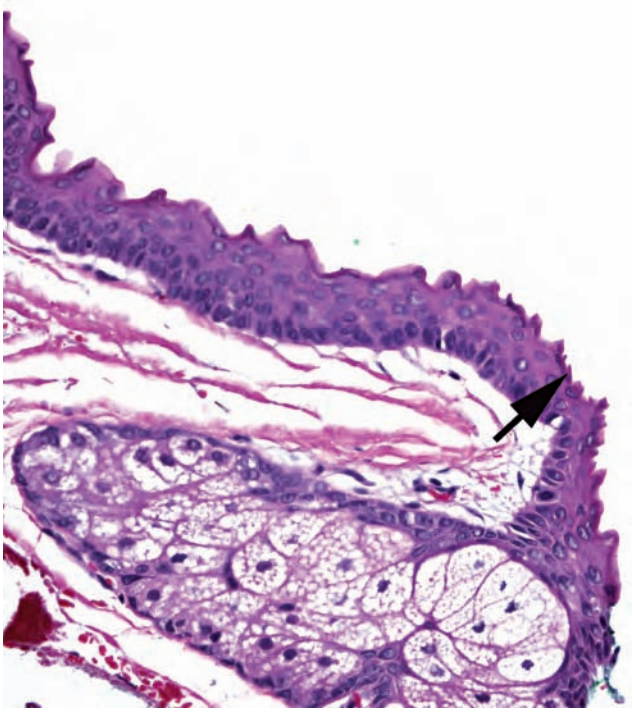

- Space with a lining
- Lining composed of layered epithelium with a bright pink crenulated keratin (arrow)
- Sebaceous glands in wall

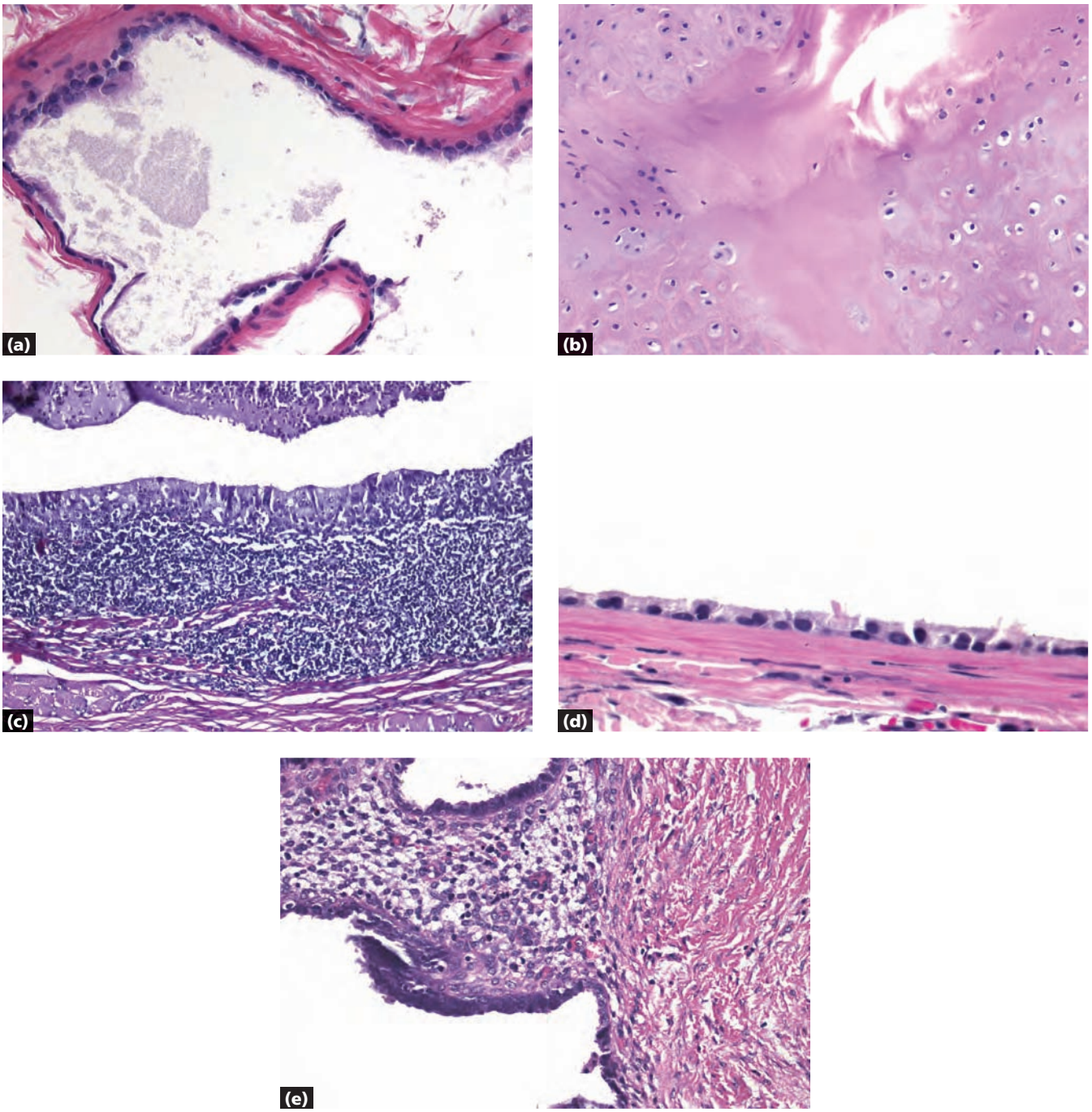

a Apocrine hidrocystoma: decapitation secretion
b Auricular pseudocyst: degeneration surrounded by cartilage
c Branchial cleft cyst: prominent lymphoid follicles in wall
d Cutaneous ciliated cyst: columnar epithelium with cilia; no structures in wall
e Cutaneous endometriosis: fibrovascular stroma with glands

Key differences

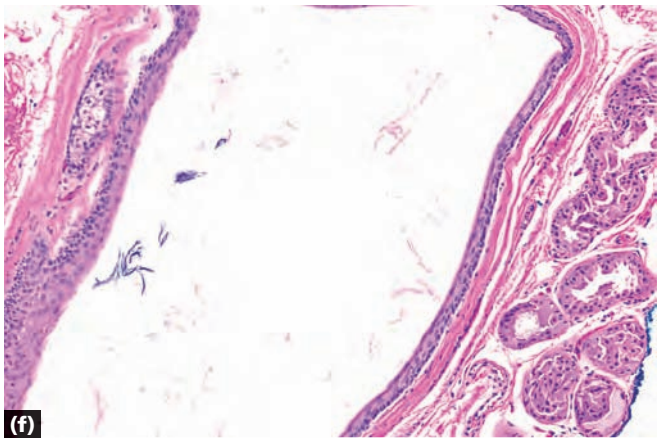

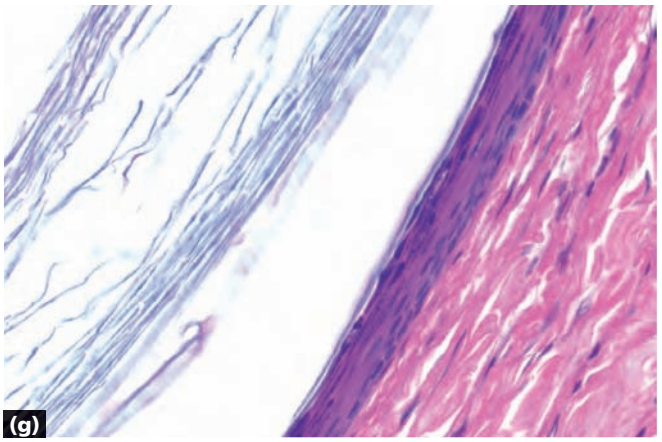

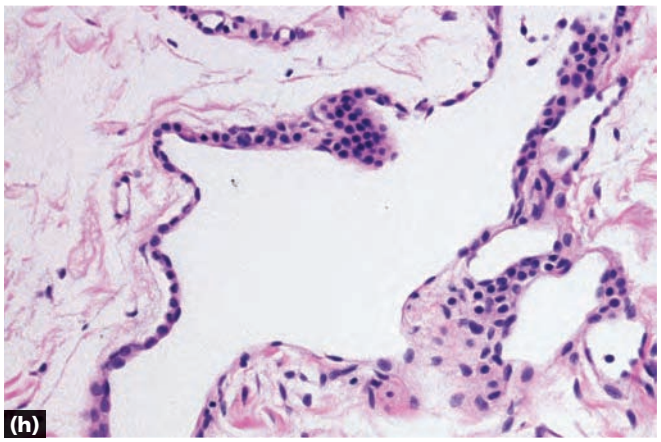

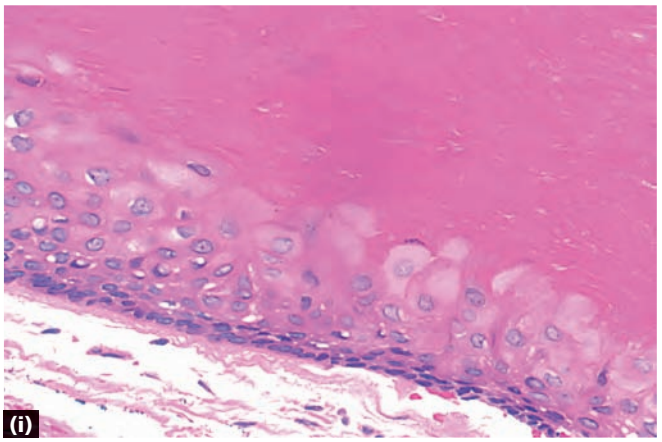

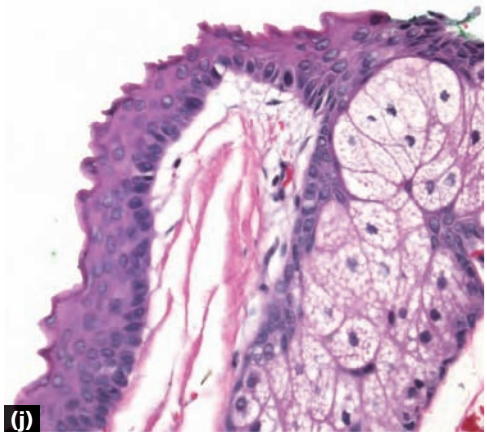

f Dermoid cyst: sebaceous glands and other adnexal structures in wall

g Epidermal inclusion cyst: epithelium with granular layer, flakes of keratin in center

h Glomuvenous malformation (glomangioma): monomorphous, cuboidal blue cells (see also glomus tumor on page 282)

i Pilar cyst: epithelium without granular layer, dense keratin in center

j Steatocystoma: crenulated keratin lining the cyst; sebaceous glands in wall

Note Bronchogenic cysts are uncommon, and are diagnosed by clinical history and the presence of columnar epithelium +/– cilia, +/– cartilage in wall; venous lakes are common and are composed of flattened endothelial cells with erythrocytes in the space.

Key differences, *continued*

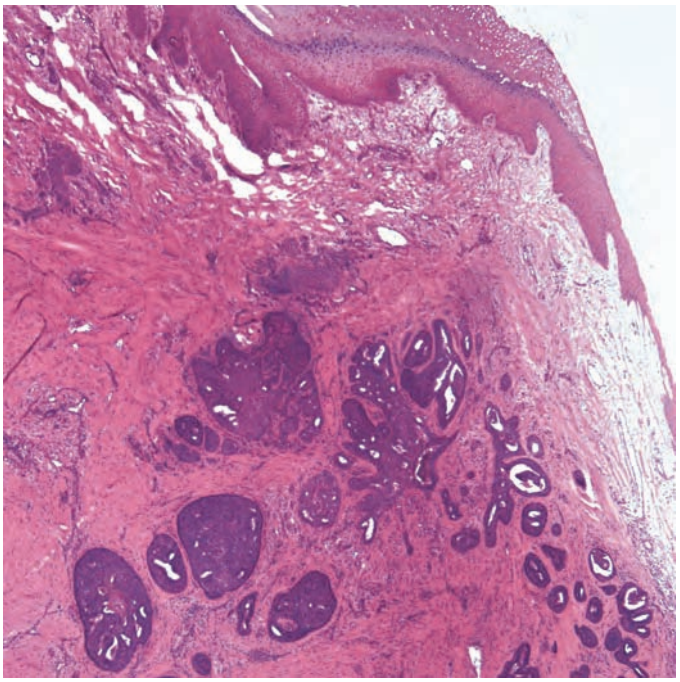

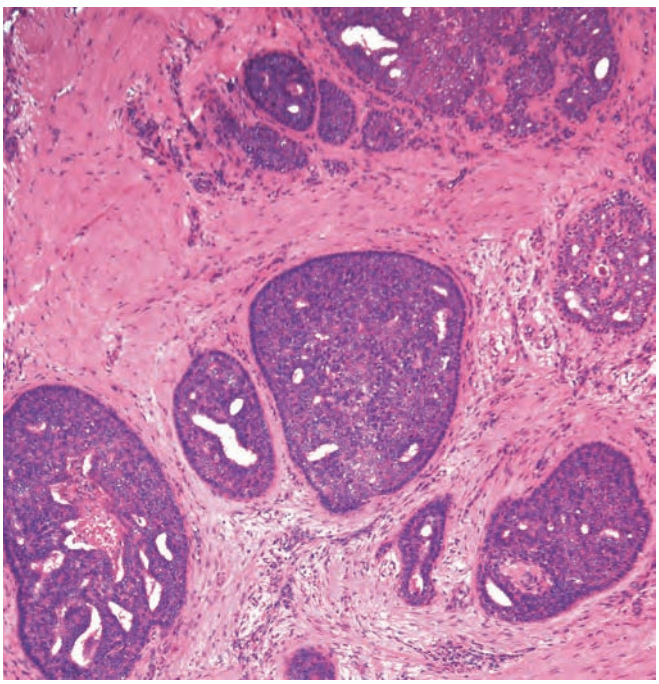

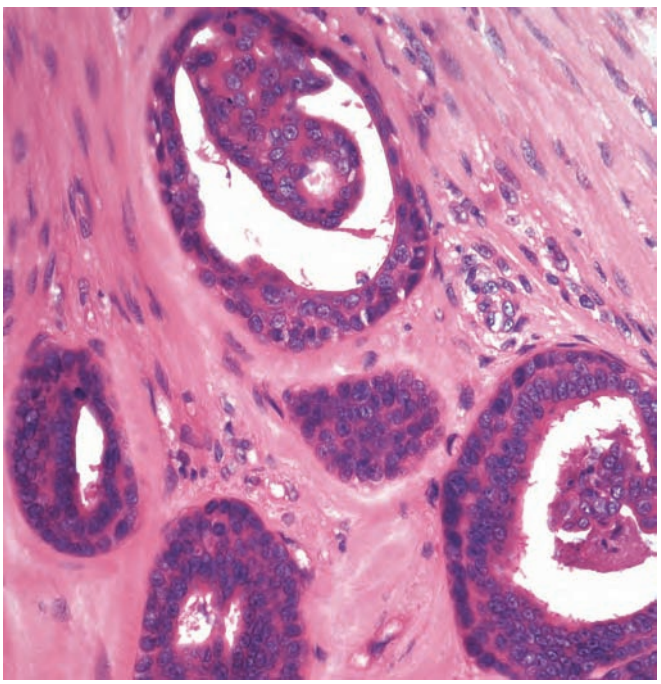

- Papillated dermal tumor
- Disordered layers of epithelium in large papillations with some tubules
- Variable cytological atypia and mitotic figures
- Acral location

Aggressive digital papillary adenocarcinoma

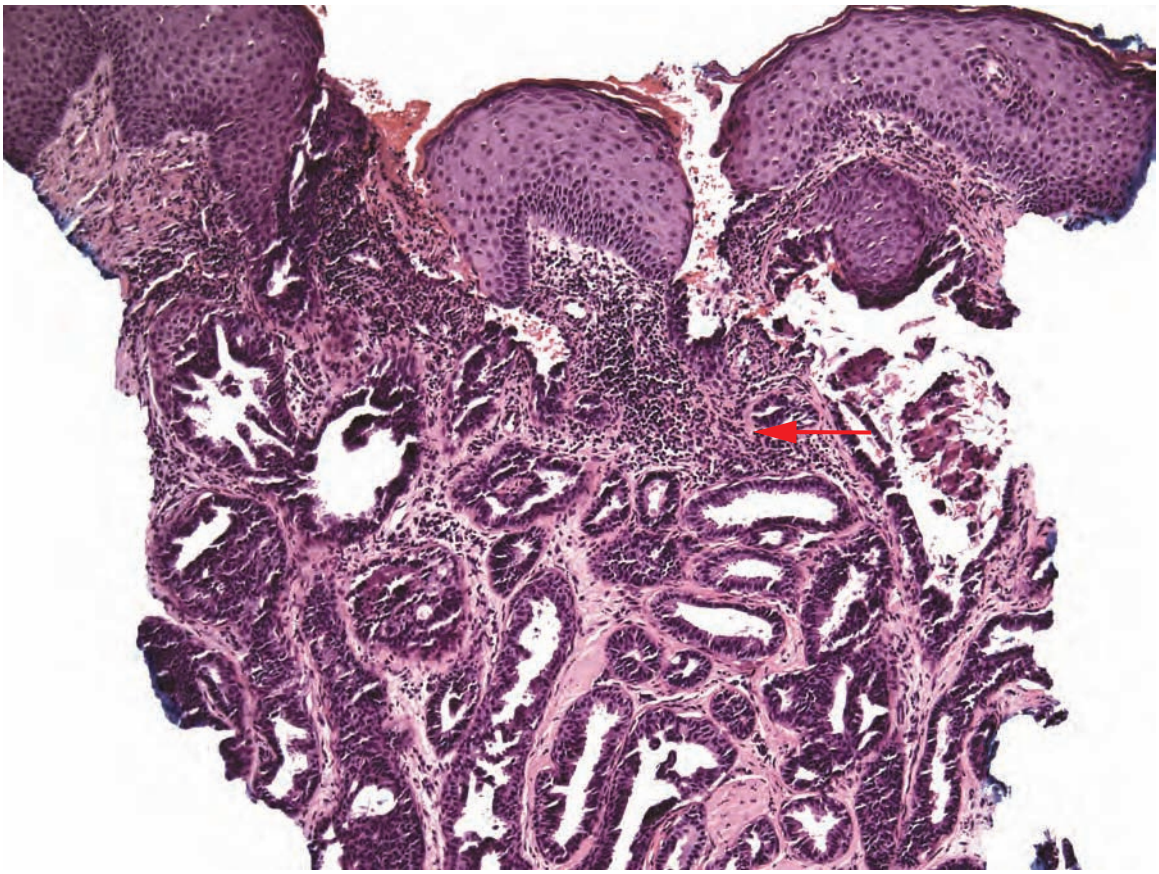

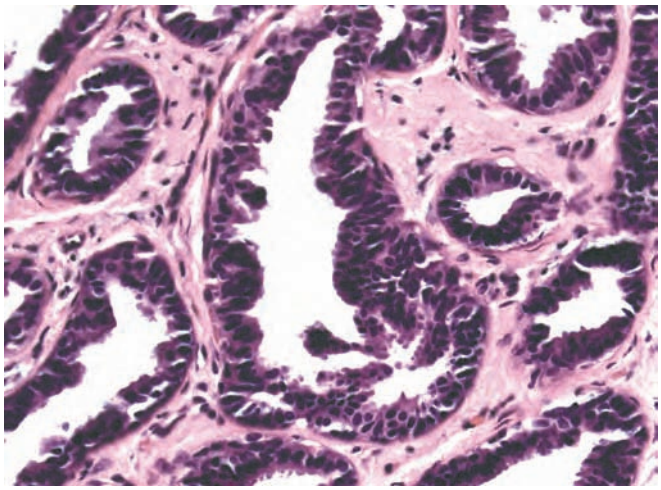

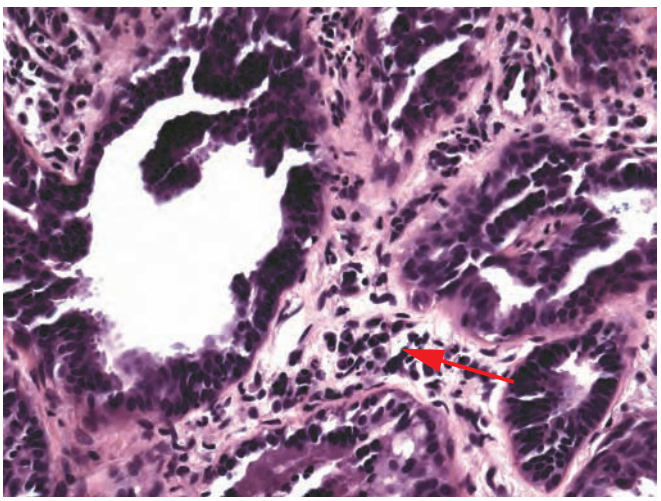

- Papillated dermal tumor
- Nipple can sometimes be identified by fascicles of smooth muscle in dermis
- Circular islands, some cystic, and tubules
- Compressed myoepithelial cells at periphery of islands/tubules
- Decapitation secretion often evident
- Resembles syringocystadenoma papilliferum (stromal plasma cells [arrows]) or tubular apocrine adenoma

Erosive adenomatosis of the nipple (nipple adenoma)

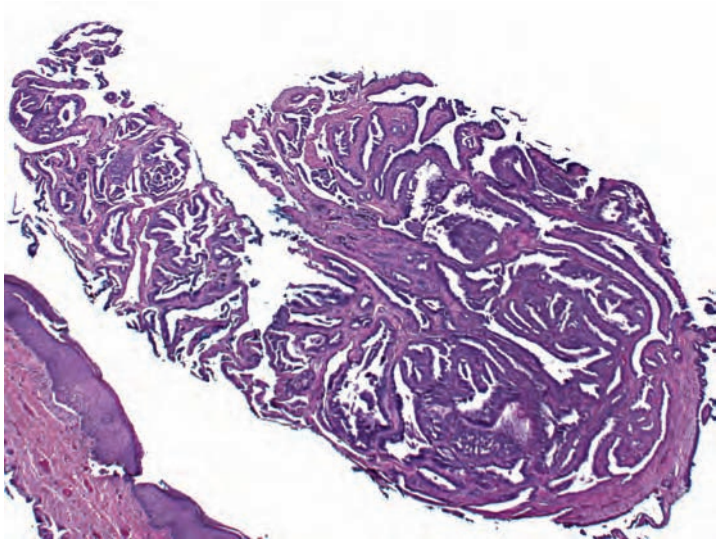

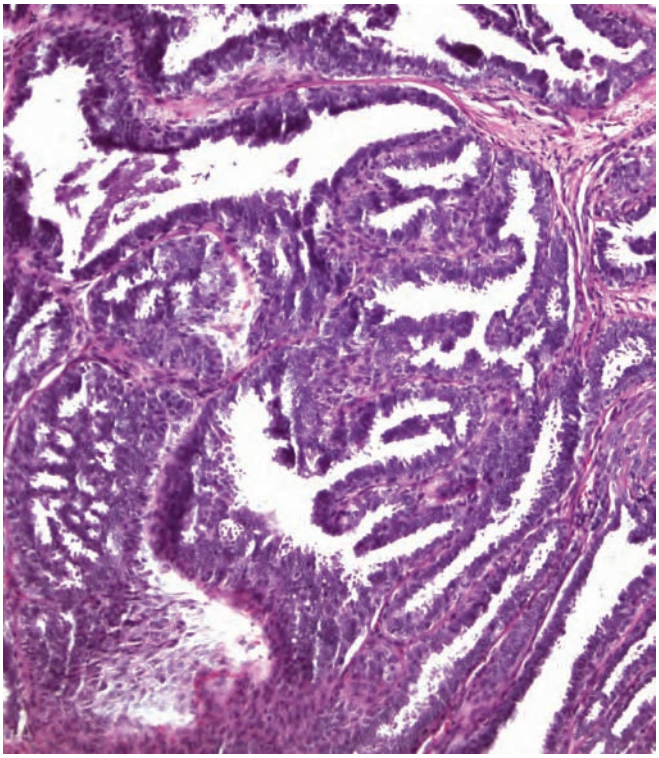

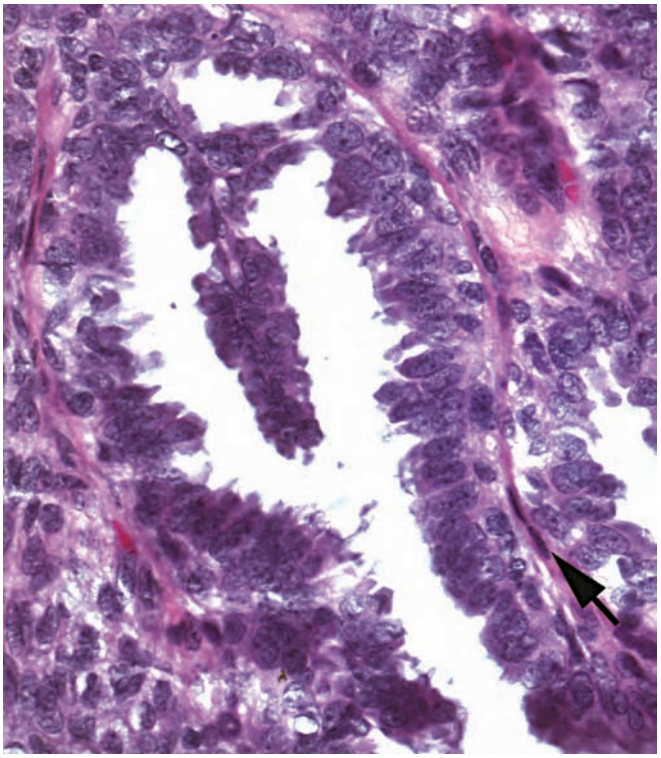

- Papillated dermal tumor
- Finger-like projections have cores of collagen/fibroblasts (arrow)
- No connection to epidermis

Hidradenoma papilliferum

www.ebook3000.com

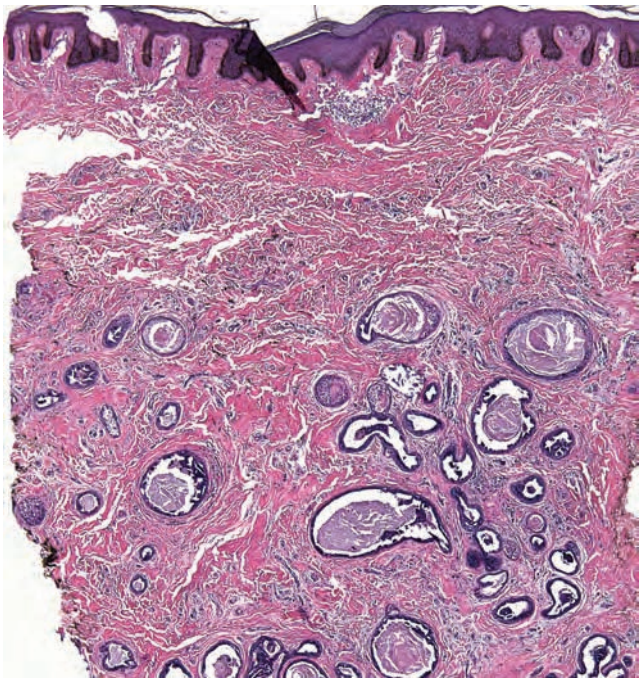

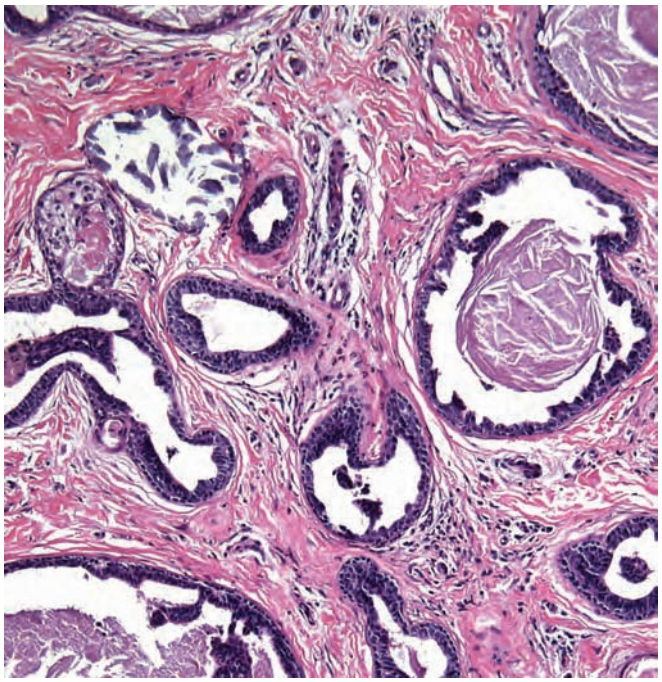

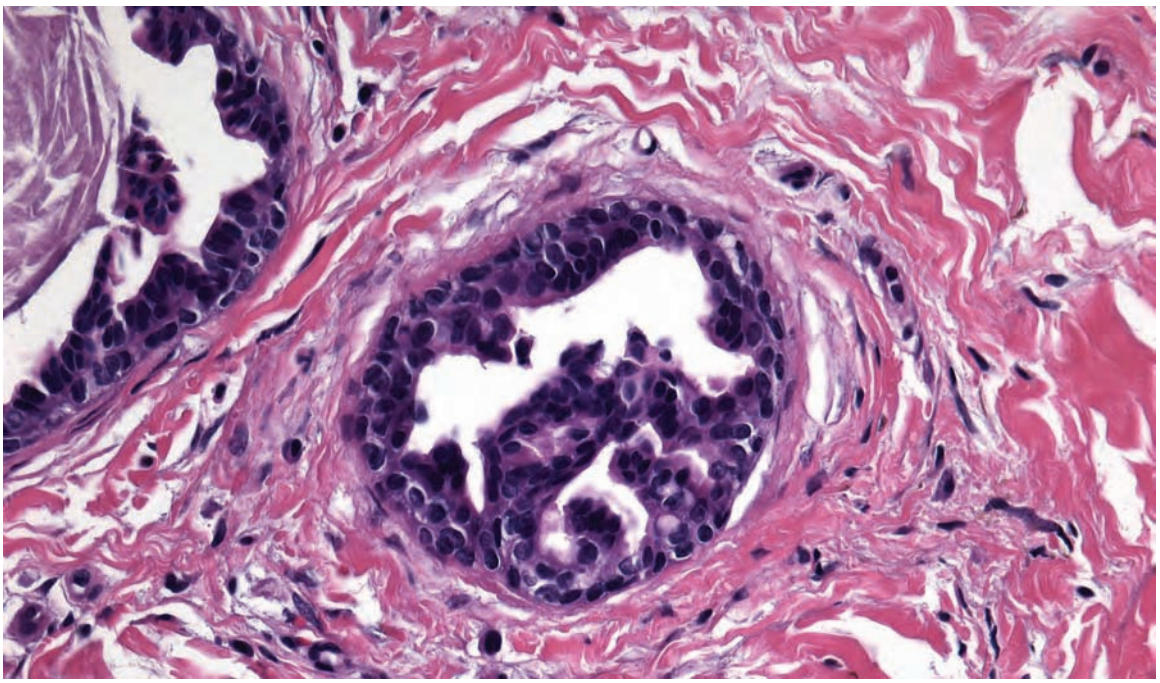

- Islands of epithelium with papillated projections
- With or without epidermal connection
- Duct-like spaces lined by eosinophilic cuticle
- Overlaps with tubular apocrine adenoma

Papillary eccrine adenoma

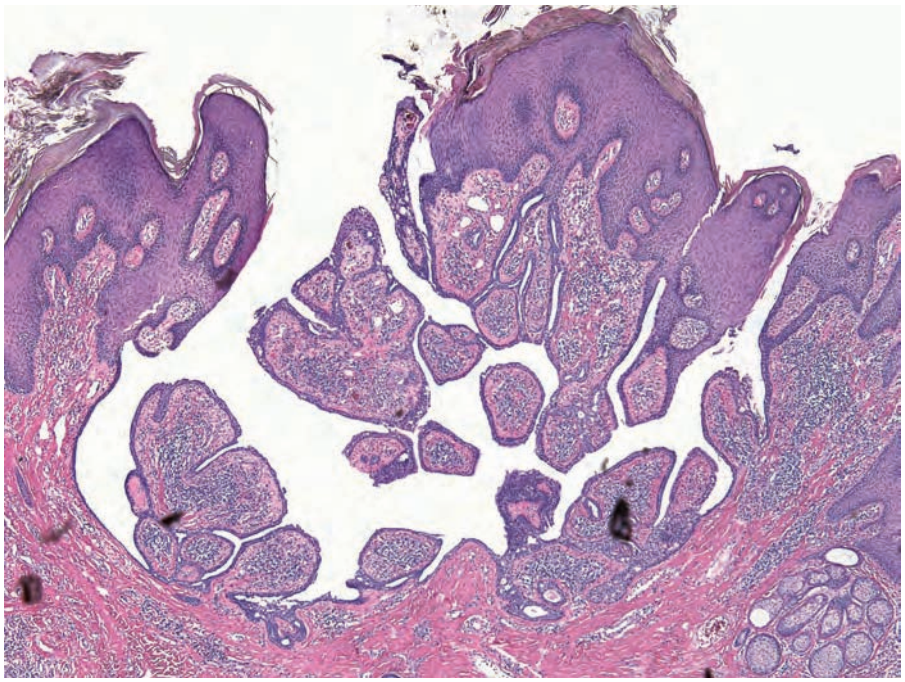

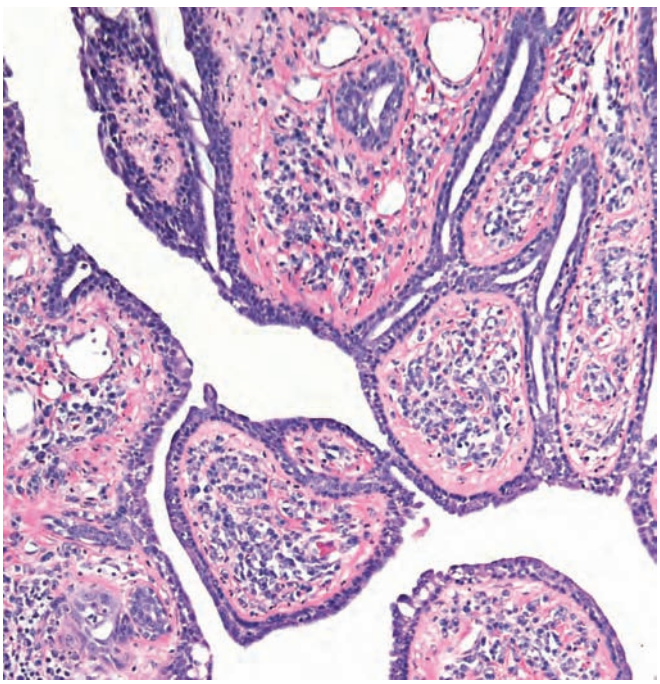

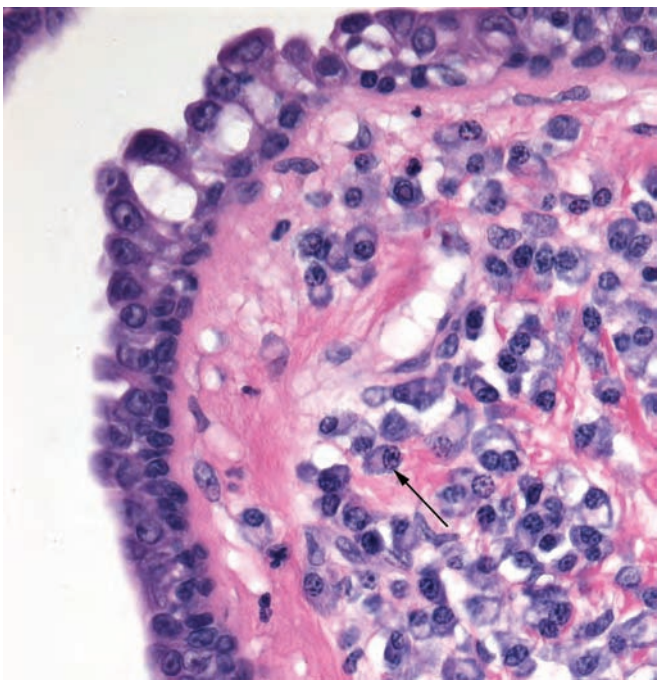

- Papillated dermal tumor
- Papillations contain numerous plasma cells (arrow)
- Tumor often connected to epidermis

Syringocystadenoma papilliferum

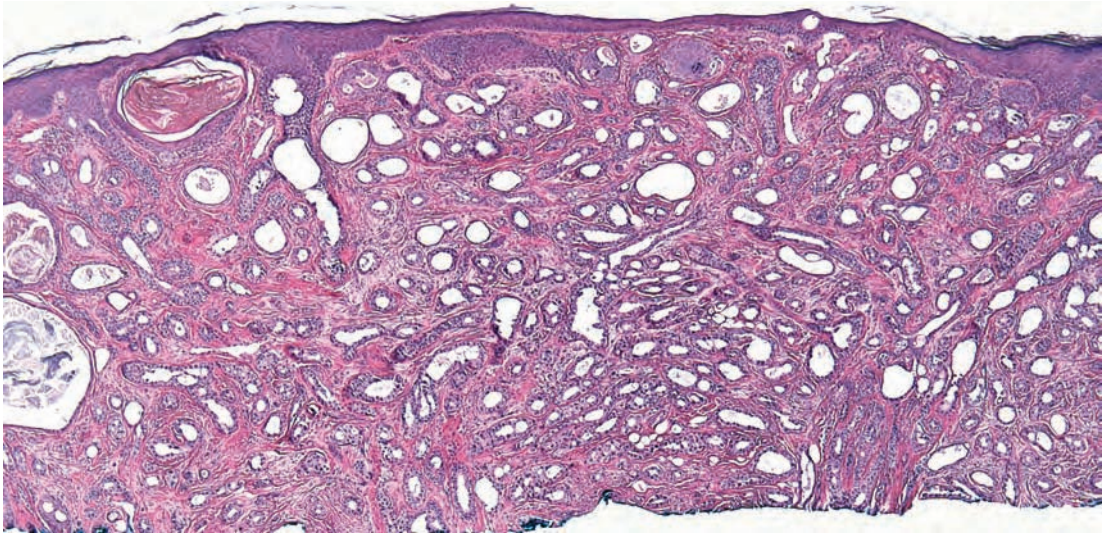

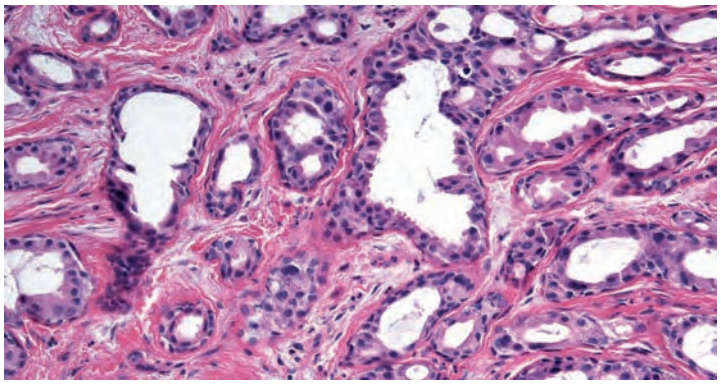

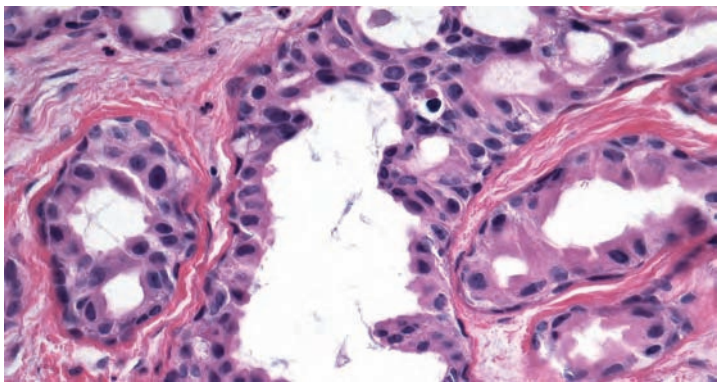

- Papillated dermal tumor
- Evidence of decapitation secretion
- Overlaps with papillary eccrine adenoma

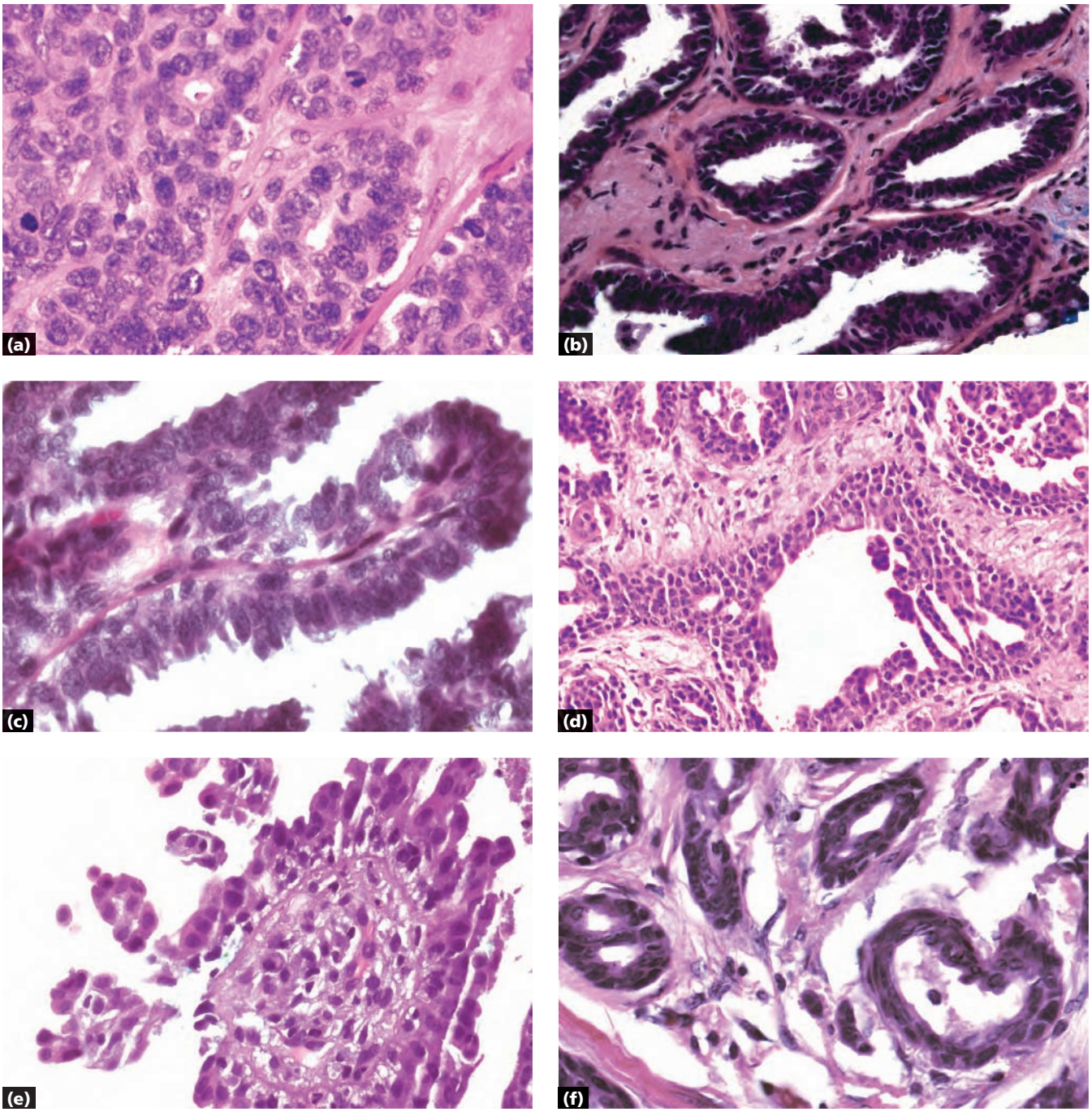

a Aggressive digital papillary adenocarcinoma: large tumor, atypical cells and mitoses piled up
b Florid papillomatosis (erosive adenomatosis) of the nipple (nipple adenoma): resembles syringocystadenoma papilliferum but fewer plasma cells; nipple may be identified by smooth muscle bundles in dermis
c Hidradenoma papilliferum: thin papillations with fibrovascular cores
d Papillary eccrine adenoma: islands of epithelium with papillated areas
e Syringocystadenoma papilliferum: fat papillations with plasma cells in cores
f Tubular apocrine adenoma: decapitation secretion and papillations within islands

Key differences

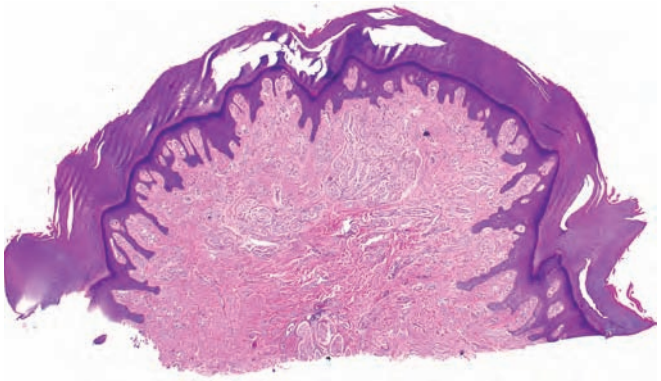

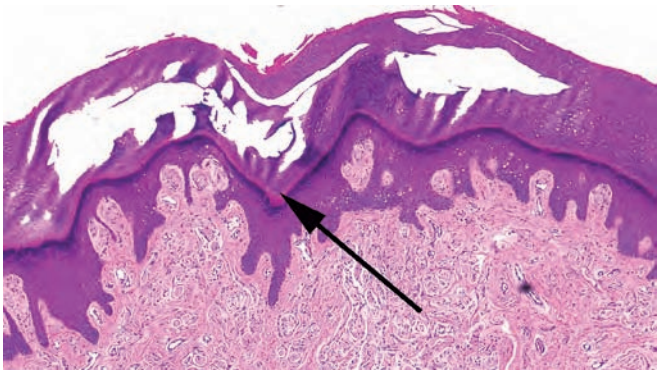

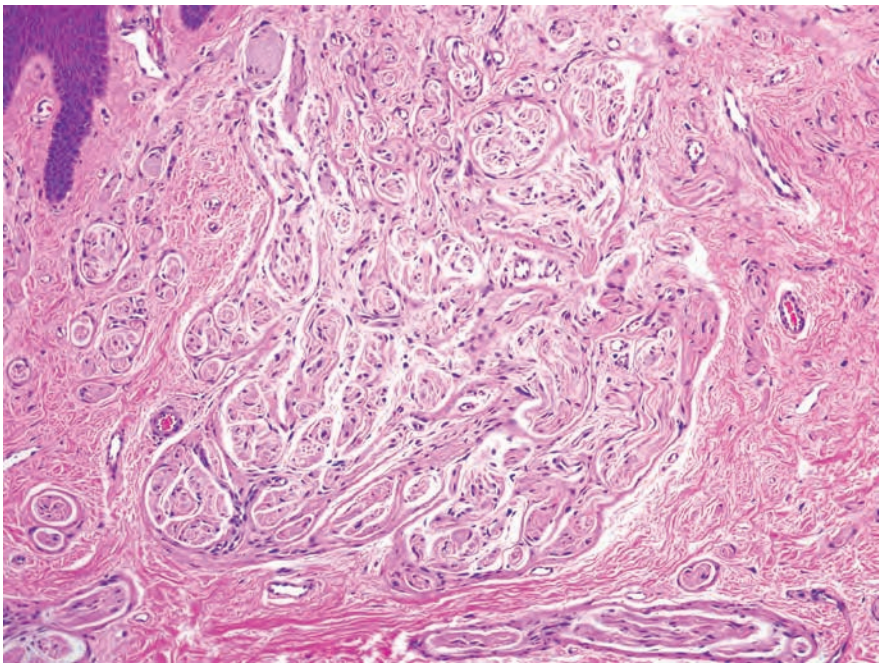

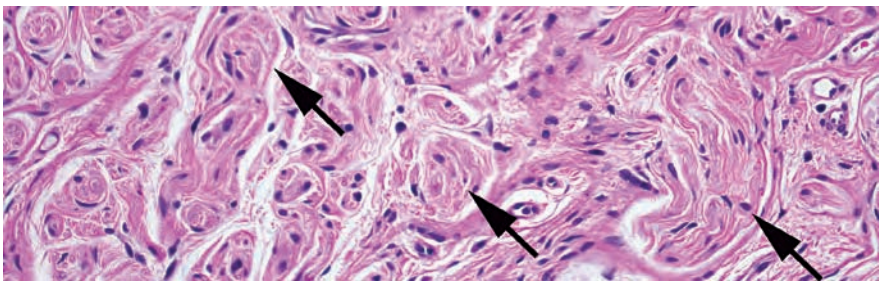

- Polypoid shape
- Acral skin (thick stratum corneum with stratum lucidum [long arrow])
- Dermal nerve bundles (short arrows)

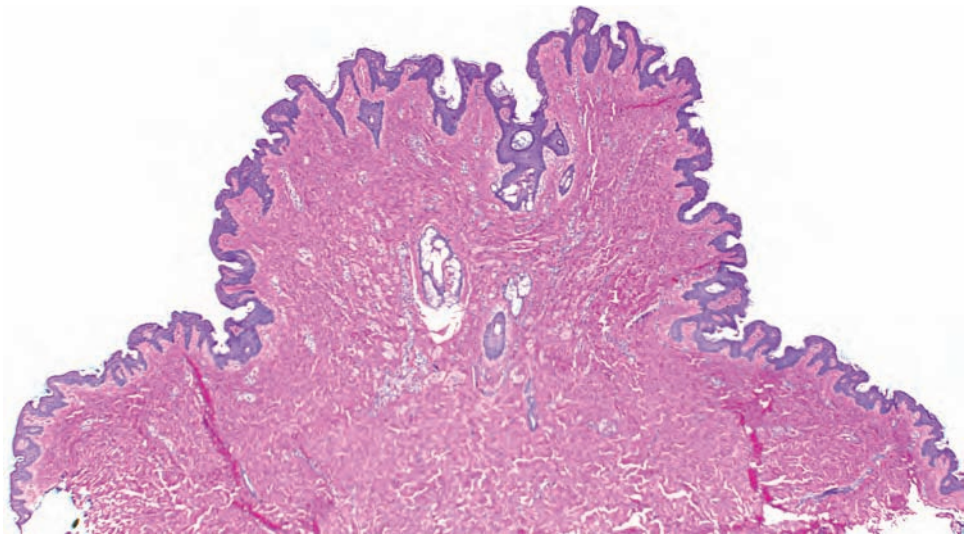

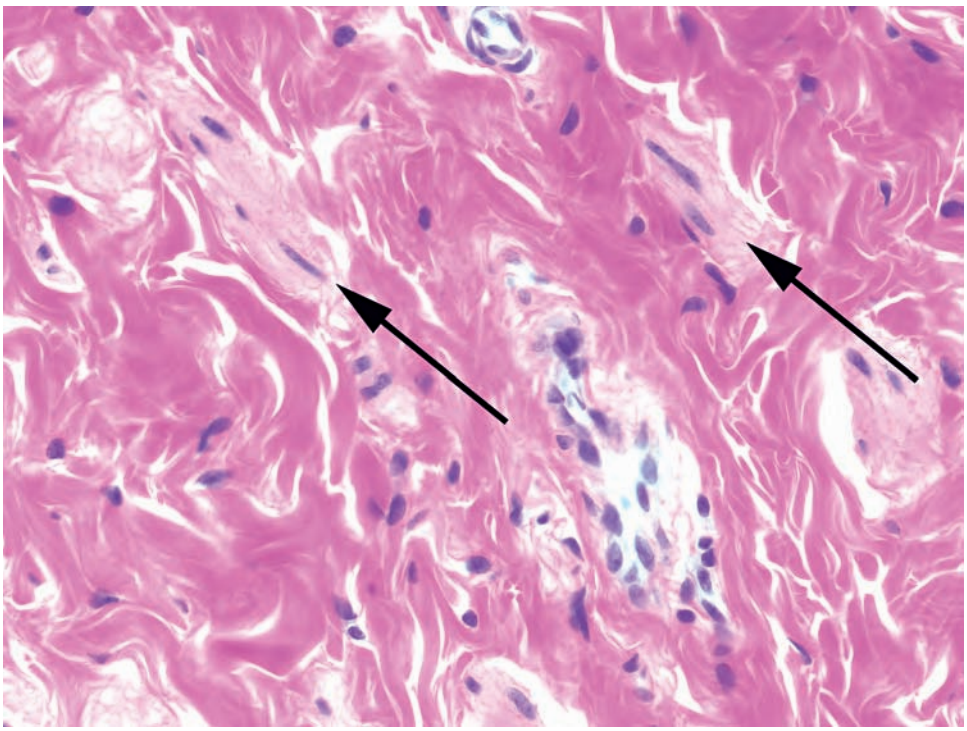

- Polypoid shape
- May see a slight invagination of surface epidermis with underlying sebaceous glands
- Surface epidermis often slightly acanthotic and hyperpigmented
- May see mammary ducts or apocrine glands deep
- Dermis with numerous smooth muscle bundles (arrows)

Accessory nipple

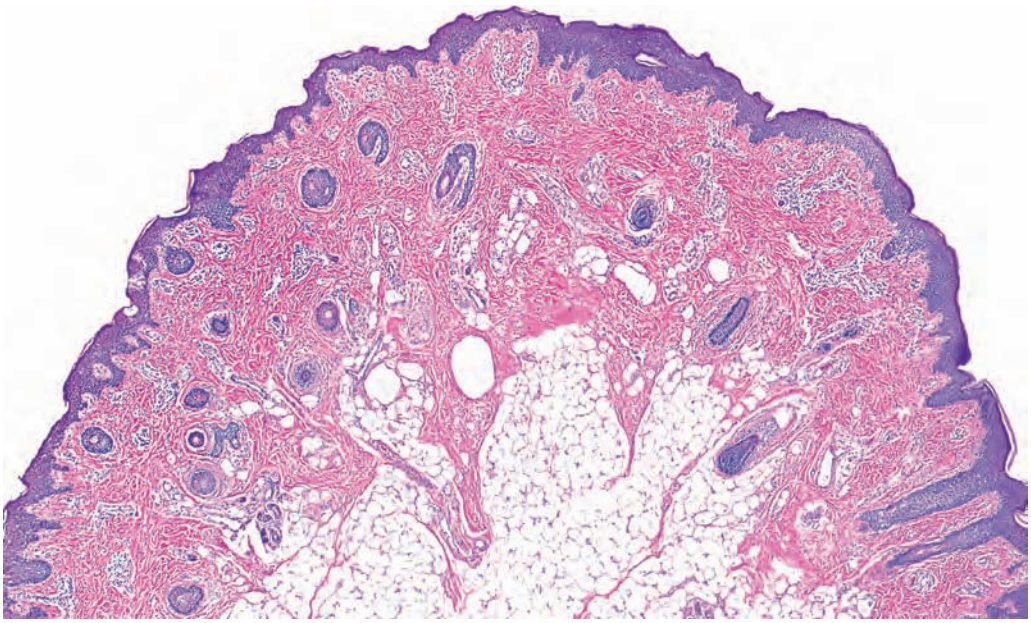

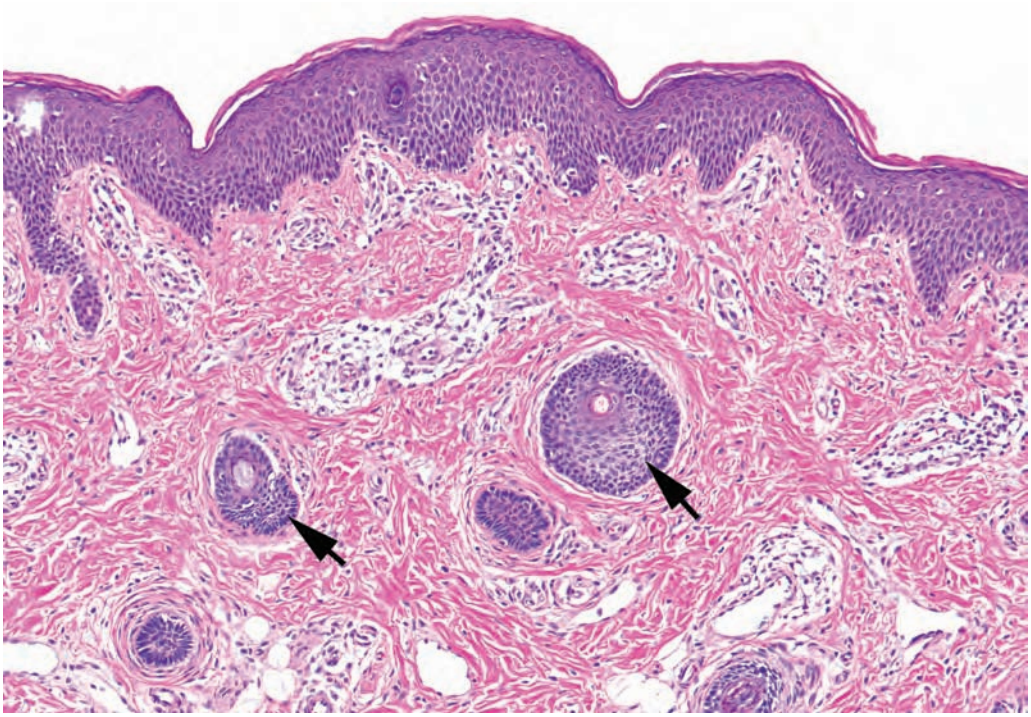

- Polypoid shape
- Thin epidermis
- Vellus hairs (arrows)
- Cartilage not always present
- Differential diagnosis of numerous vellus hairs
  – Eyelid/earlobe/sometimes facial skin
  – Vellus hair nevus

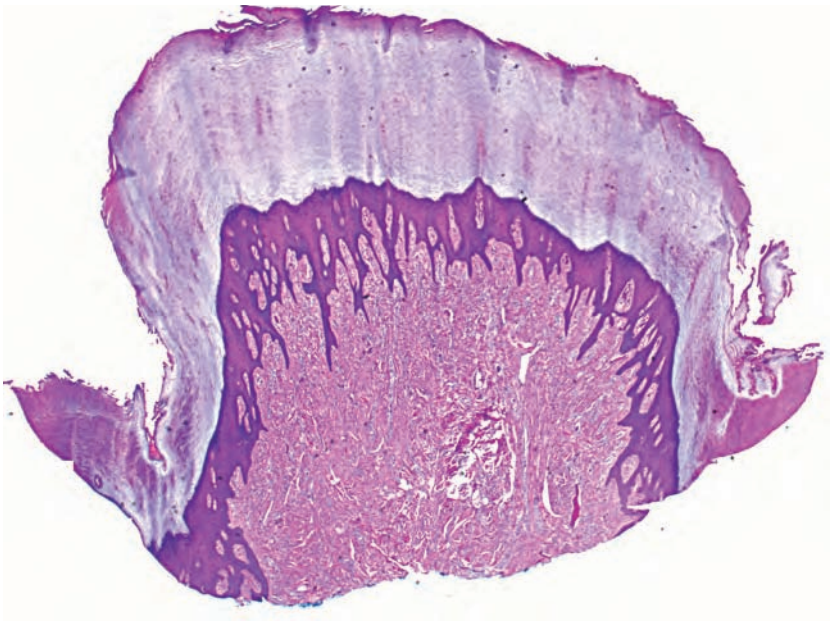

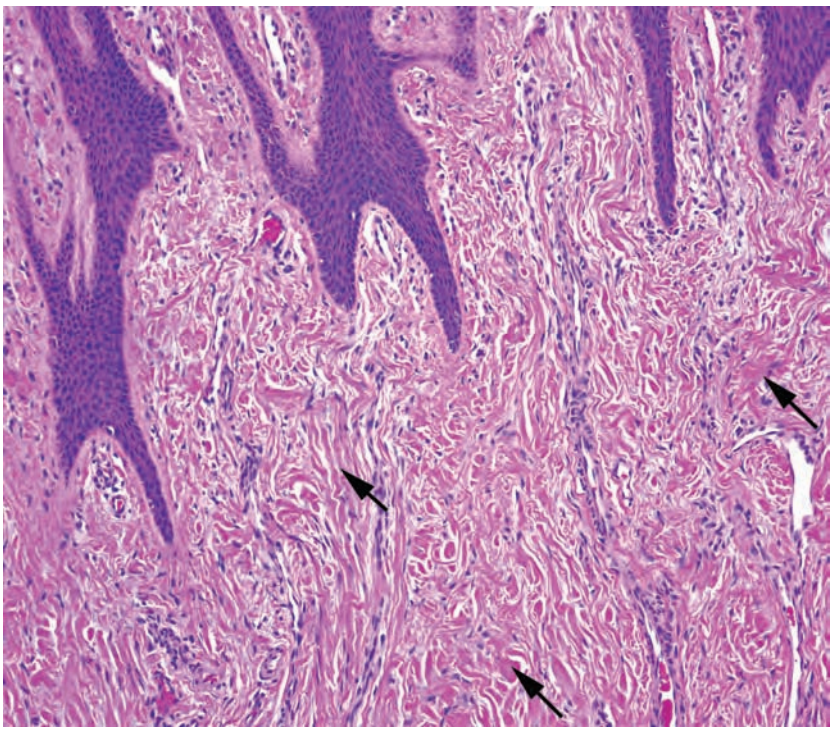

- Polypoid shape
- Acral skin
- Fibrovascular stroma (thick collagen [arrows])

Digital fibrokeratoma

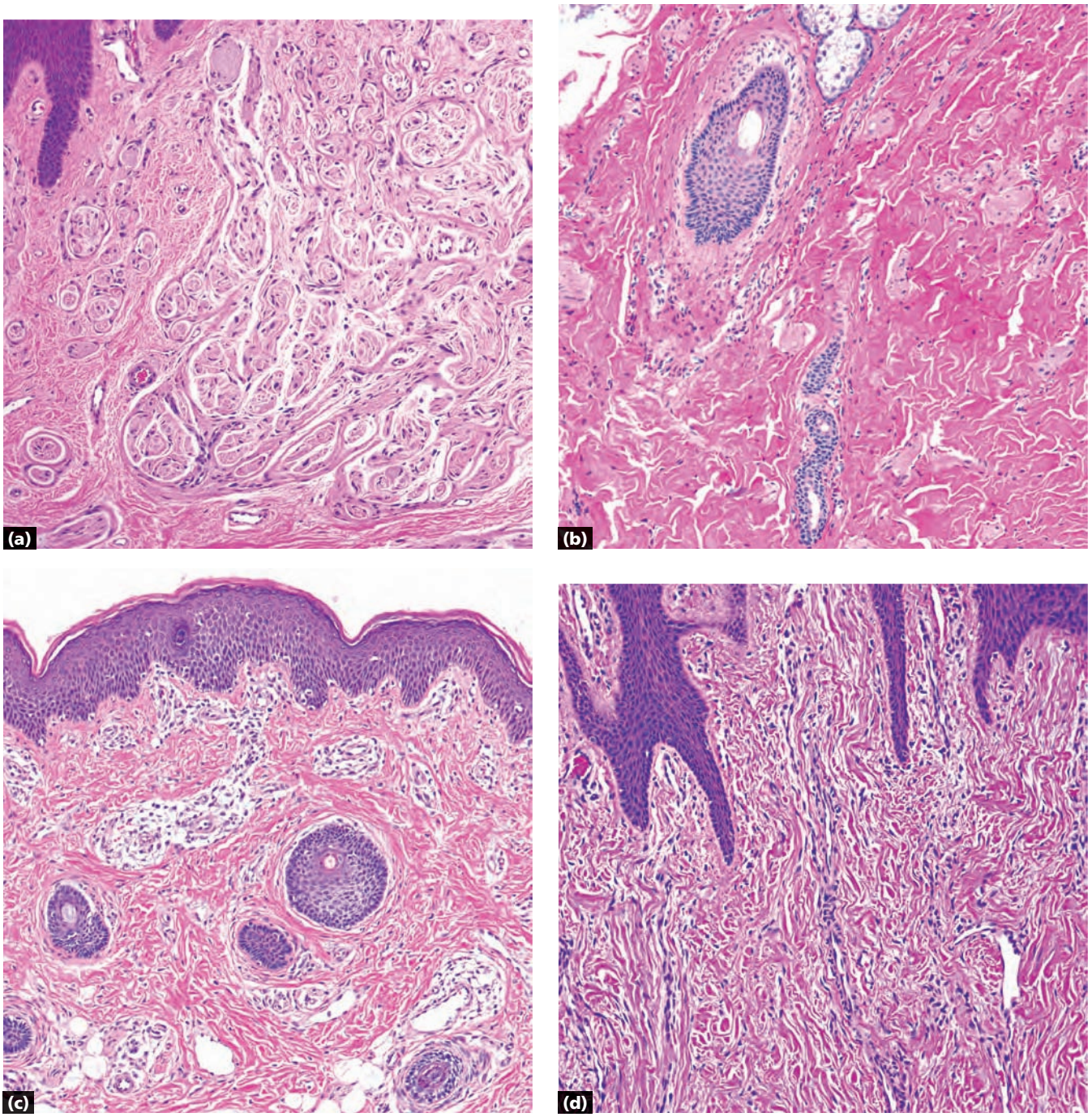

a Accessory digit: nerve bundles in the dermis
b Accessory nipple: sebaceous glands, mammary ducts or apocrine glands, smooth muscle bundles in the dermis
c Accessory tragus: vellus hairs in the dermis
d Digital fibrokeratoma: collagen in the dermis
Note Other entities may also be polypoid; for example, intradermal nevus, neurofibroma, fibrous papule, etc.

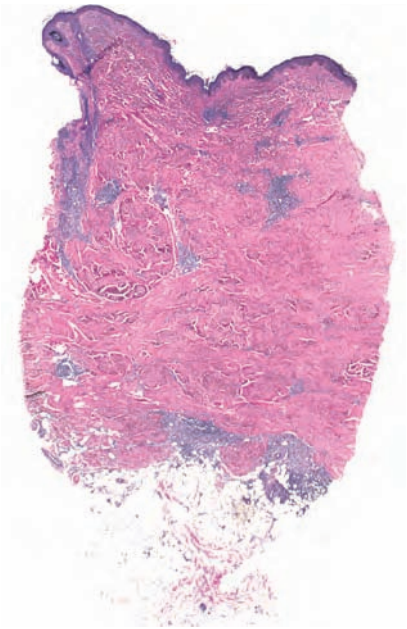

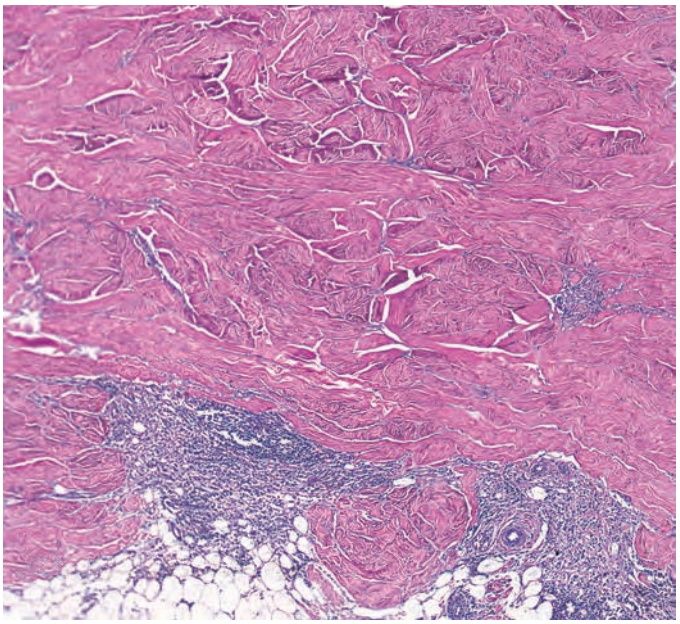

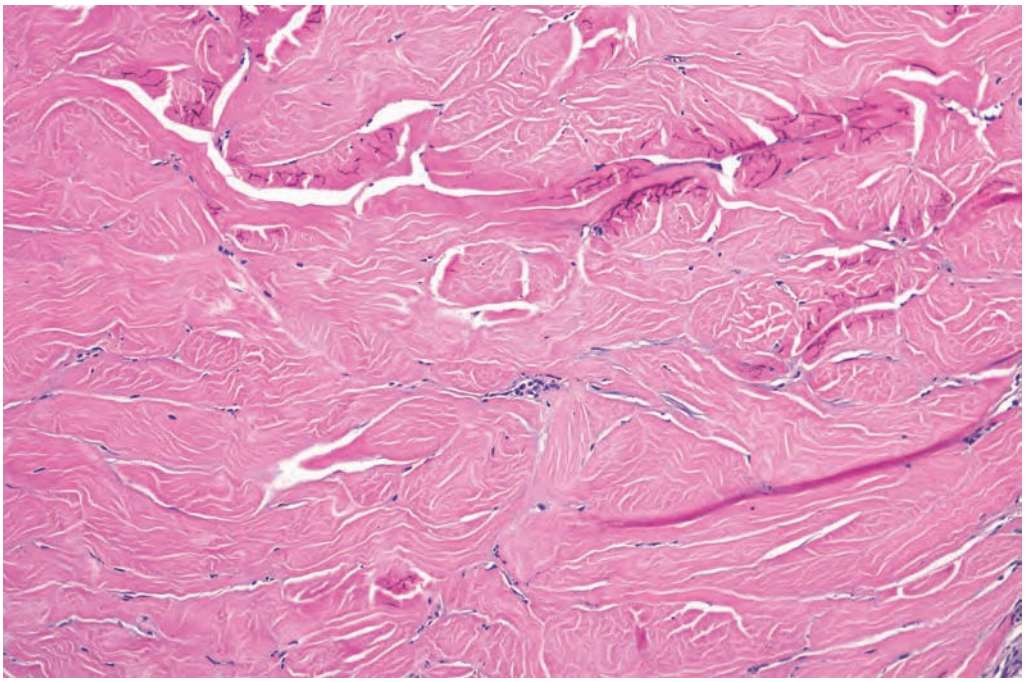

- Square/rectangular shape
- Thick, pink smudgy collagen in dermis
- Plasma cells around vessels
- Atrophic or absent adnexal structures

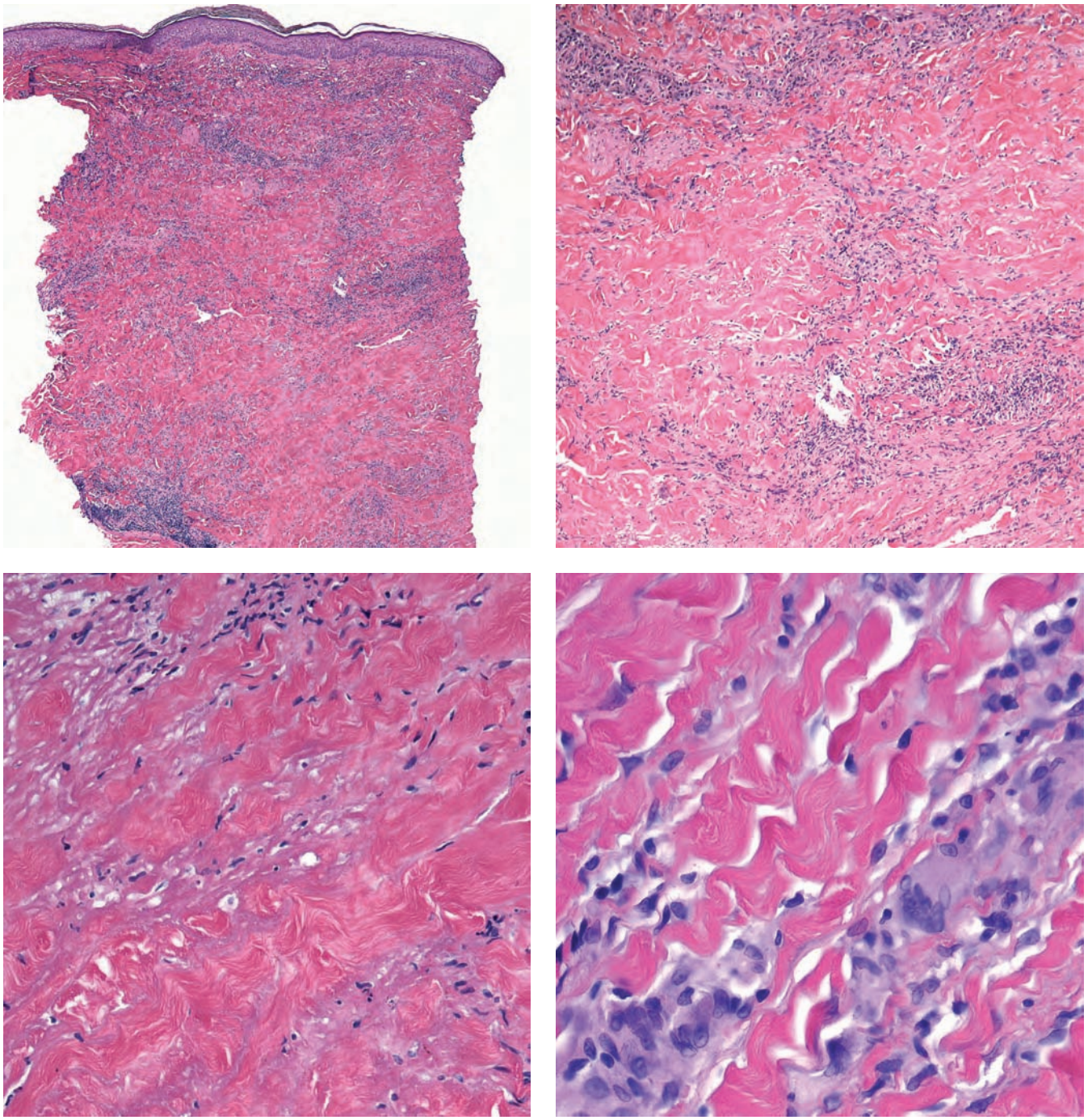

- Square/rectangular shape
- Altered, reddened collagen (necrobiosis) layered with inflammation
- Giant cells and plasma cells are prominent

Necrobiosis lipoidica

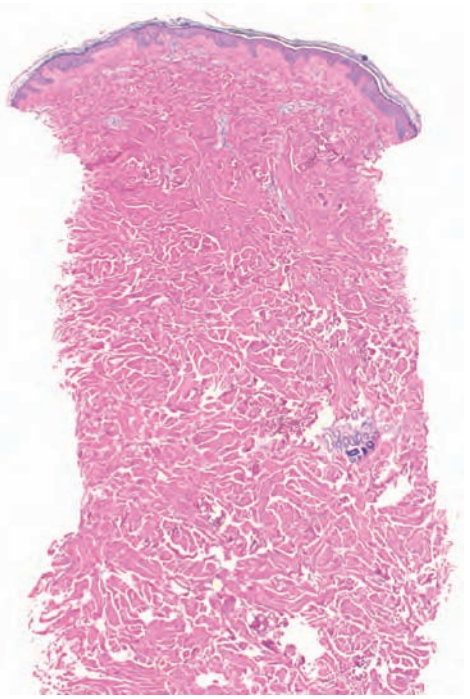

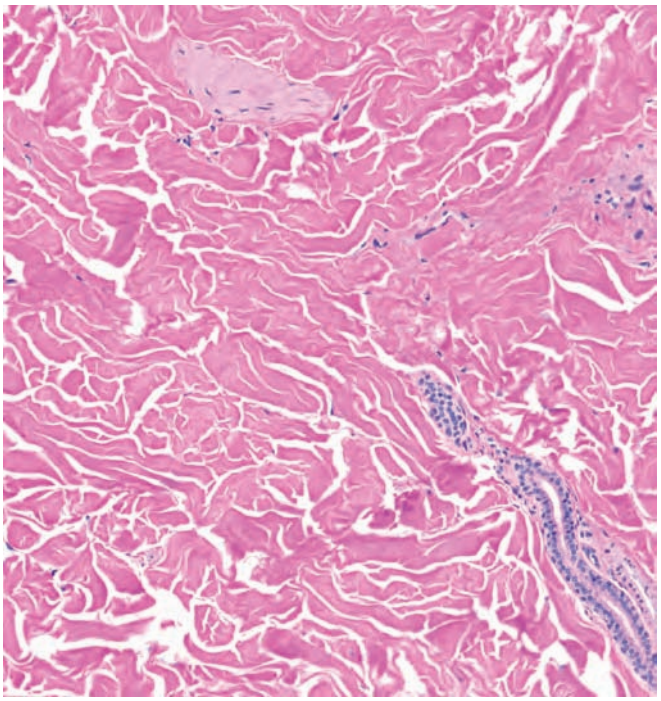

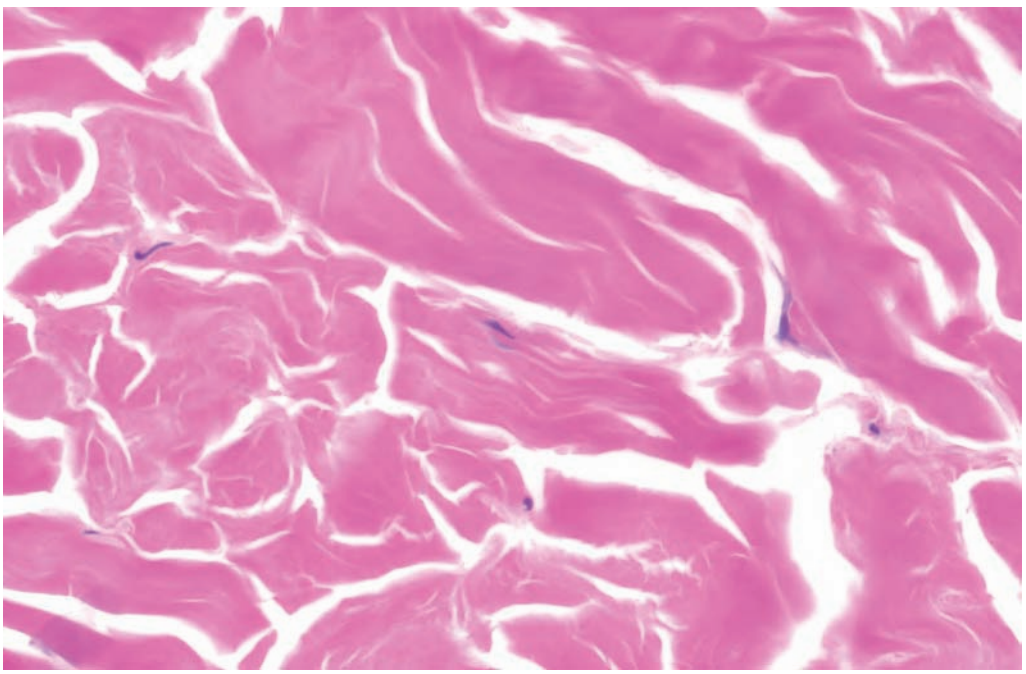

- Square/rectangular shape
- Normal-appearing collagen bundles in dermis
- No increased mucin

Normal back skin

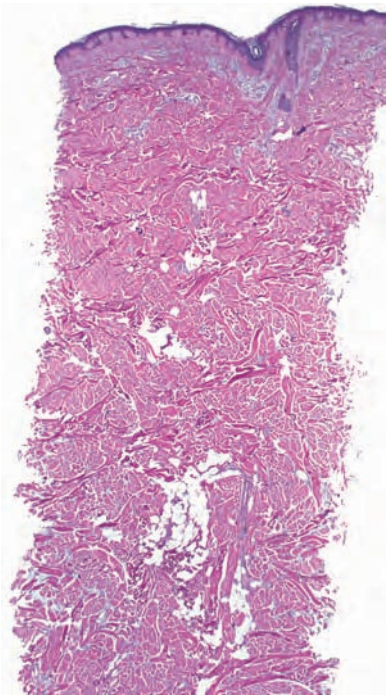

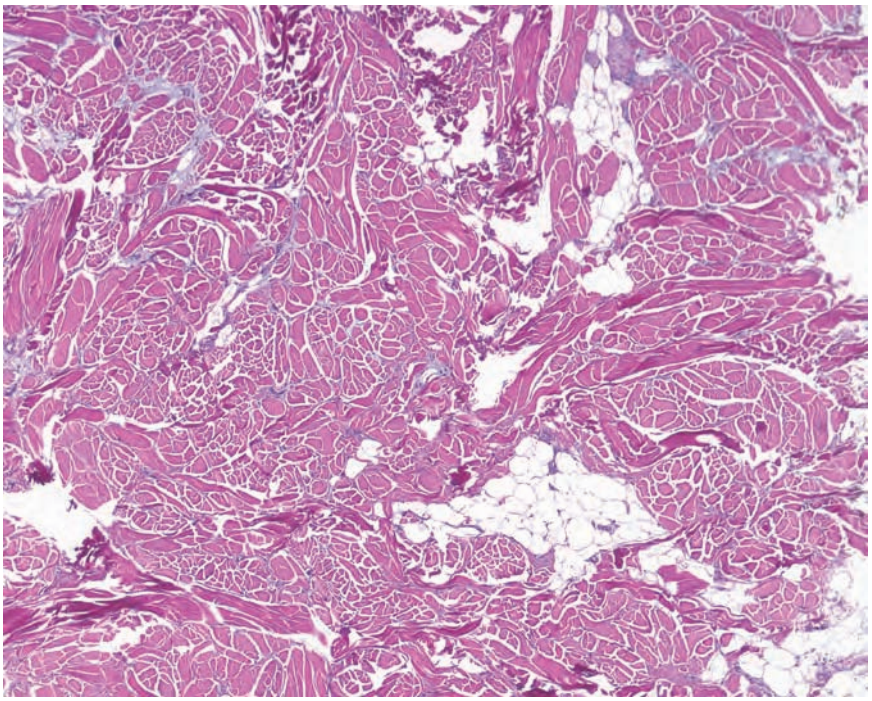

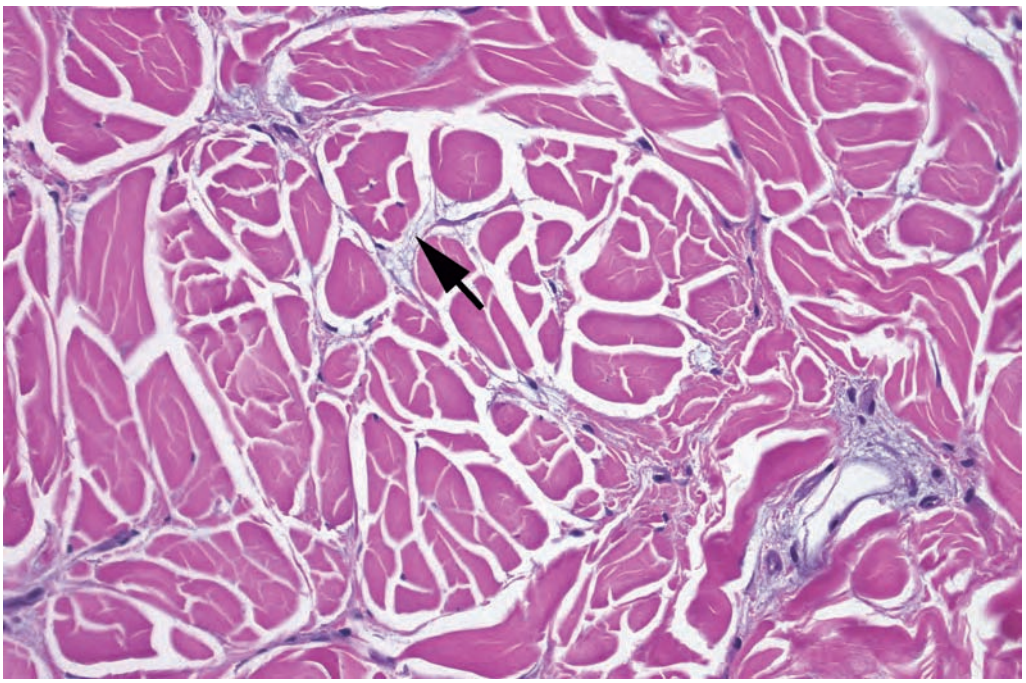

- Square/rectangular shape
- Slight widening of space between collagen due to mucin (arrow)
- No increase in fibroblasts

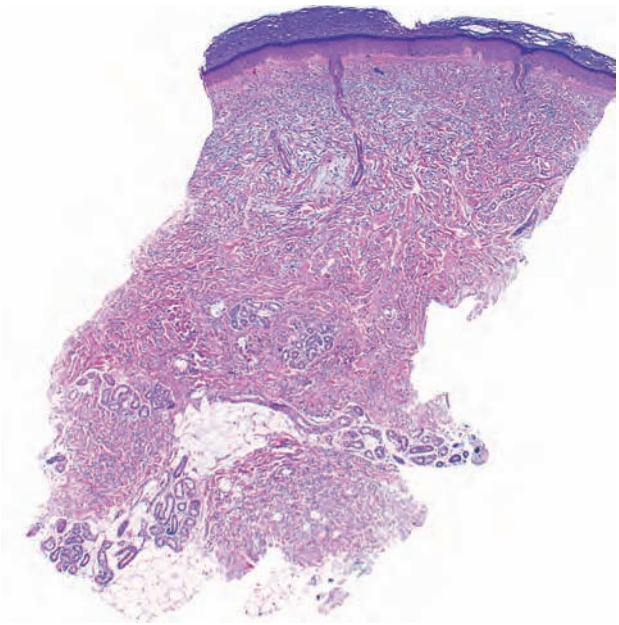

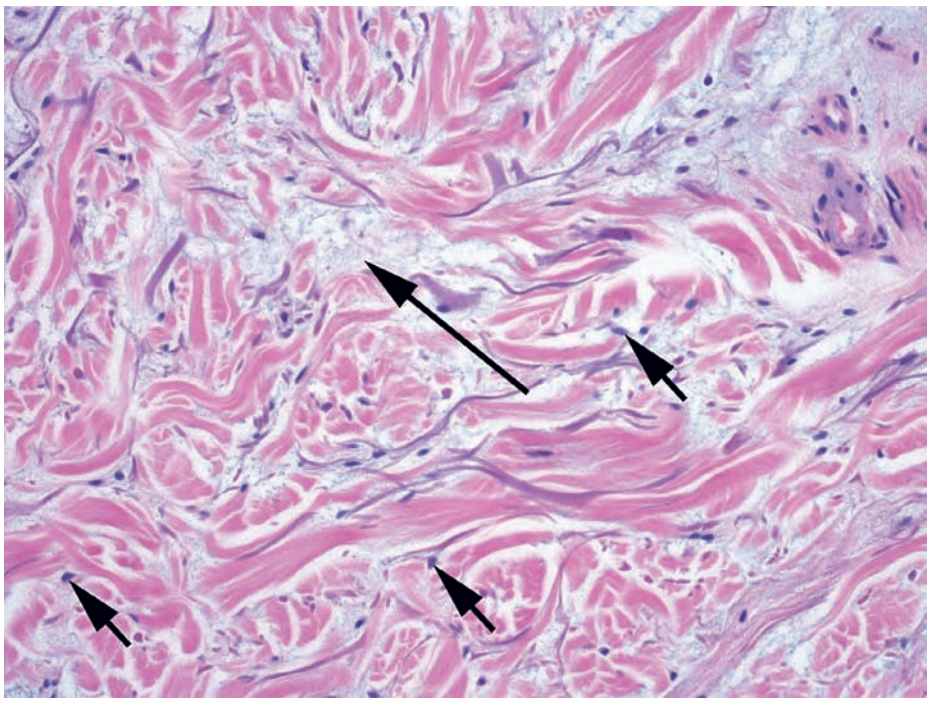

- Square/rectangular shape
- Slight widening of space between collagen due to mucin (long arrow)
- Increased fibroblasts (short arrows)

Note Lichen myxedematosus is histologically similar but clinically different.

Note Nephrogenic systemic fibrosis may show similar findings but may have deeper involvement.

Scleromyxedema

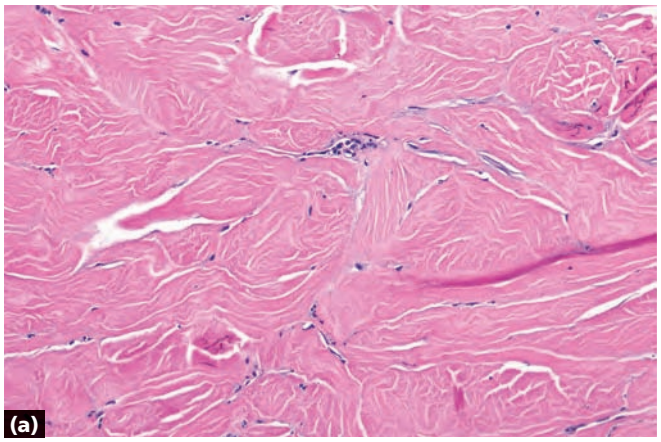

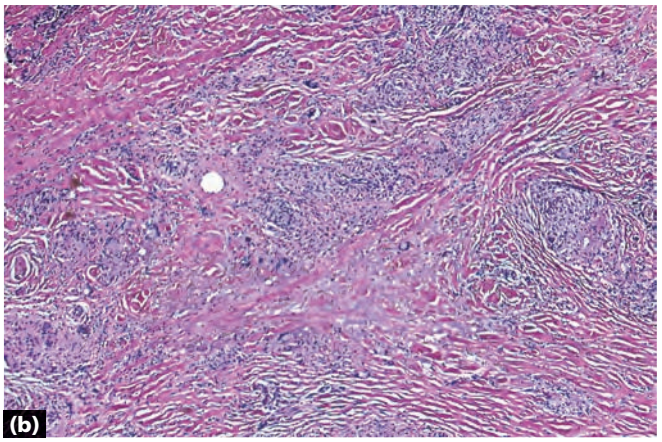

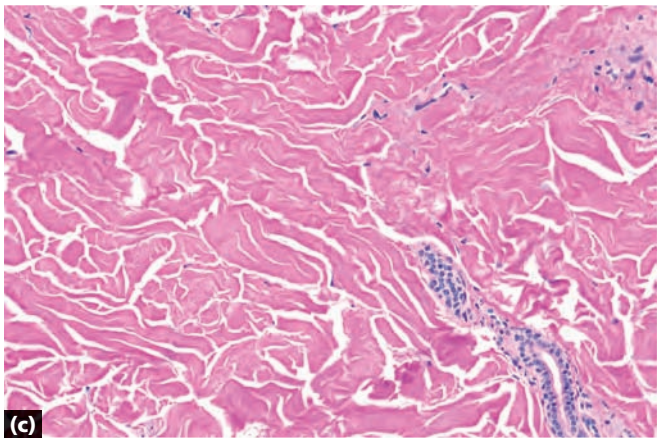

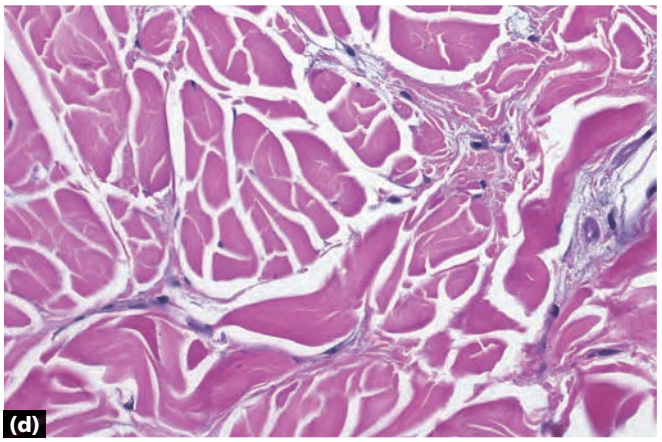

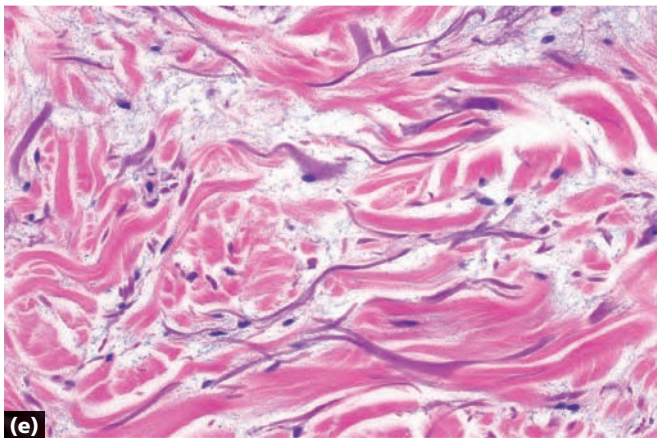

a Morphea: thickened bundles of collagen with loss of fenestrations between collagen bundles
b Necrobiosis lipoidica: reddened collagen sandwiched between layers of inflammatory cells (giant cells, plasma cells)
c Normal back: normal-sized collagen bundles, no increased mucin
d Scleredema: mucin between collagen
e Scleromyxedema: mucin and increased fibroblasts

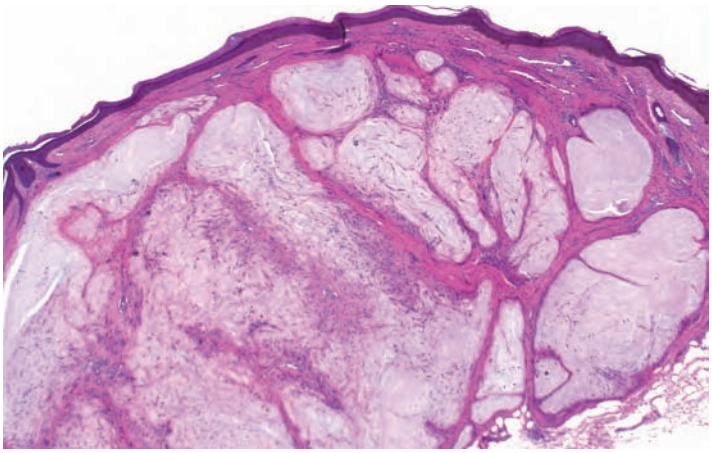

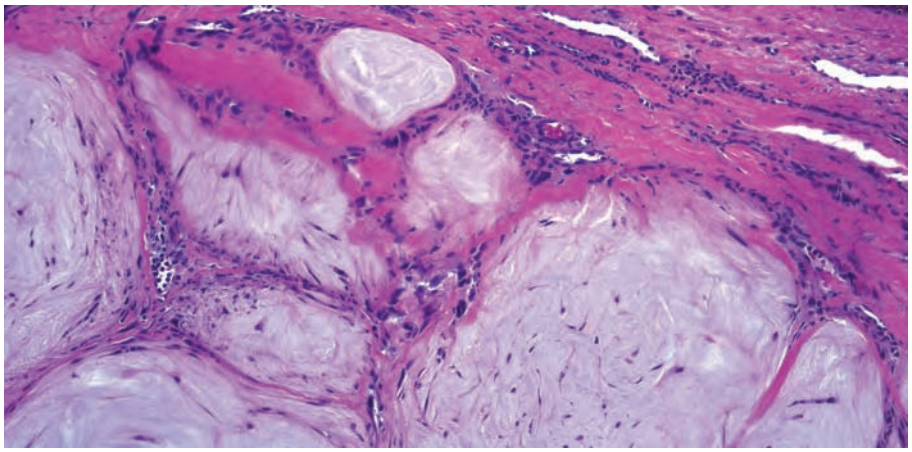

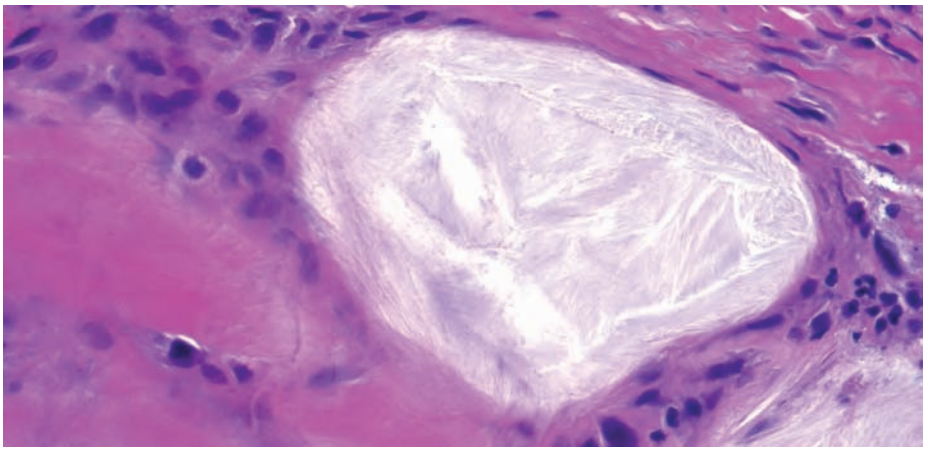

- Palisading of histiocytes around amorphous white-gray substance with a feathery edge

Gout

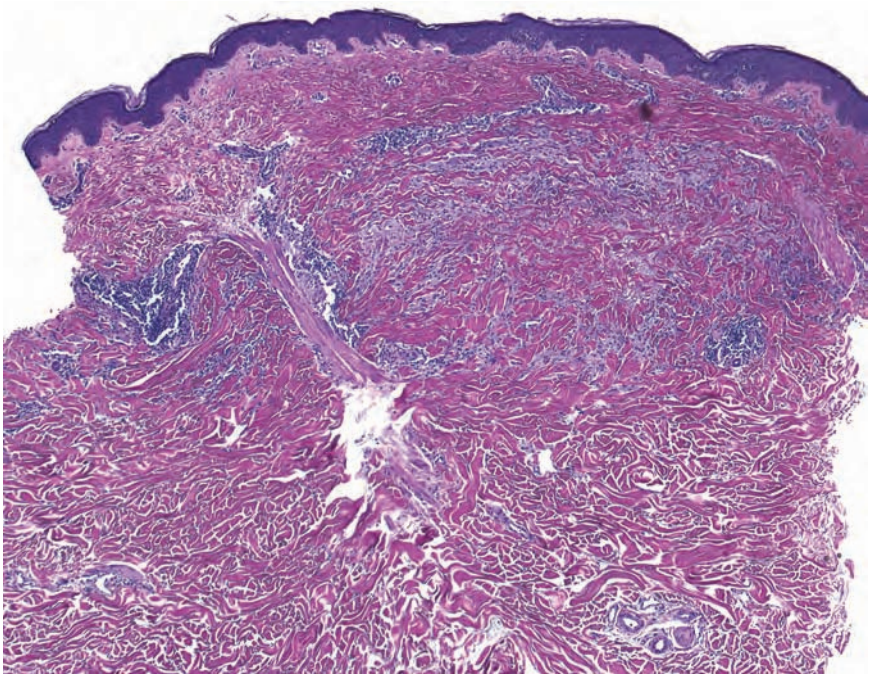

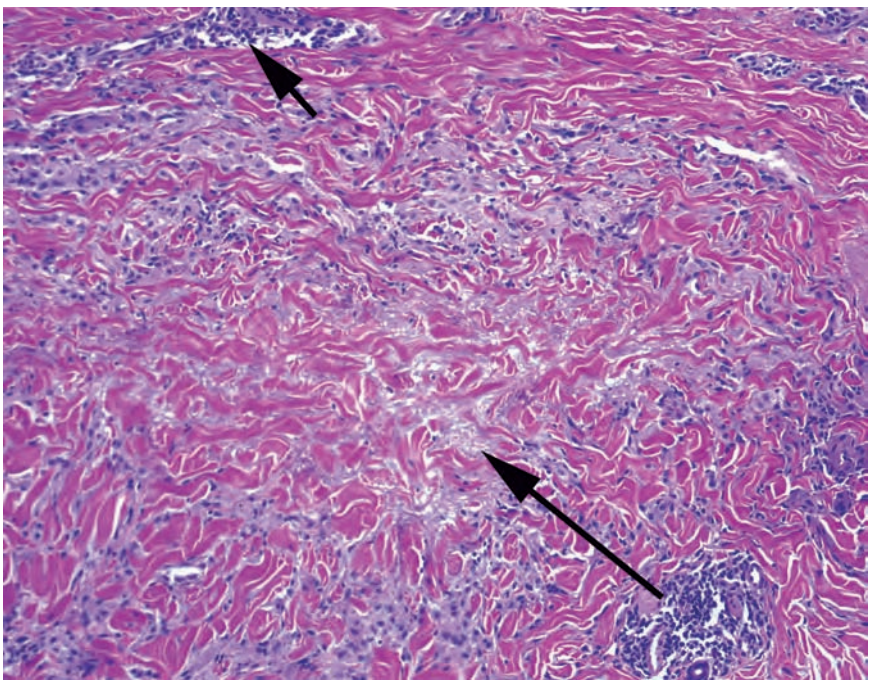

- Palisading of histiocytes around altered collagen, basophilic mucin (long arrow)
- Lymphocytes around vessels (short arrow)

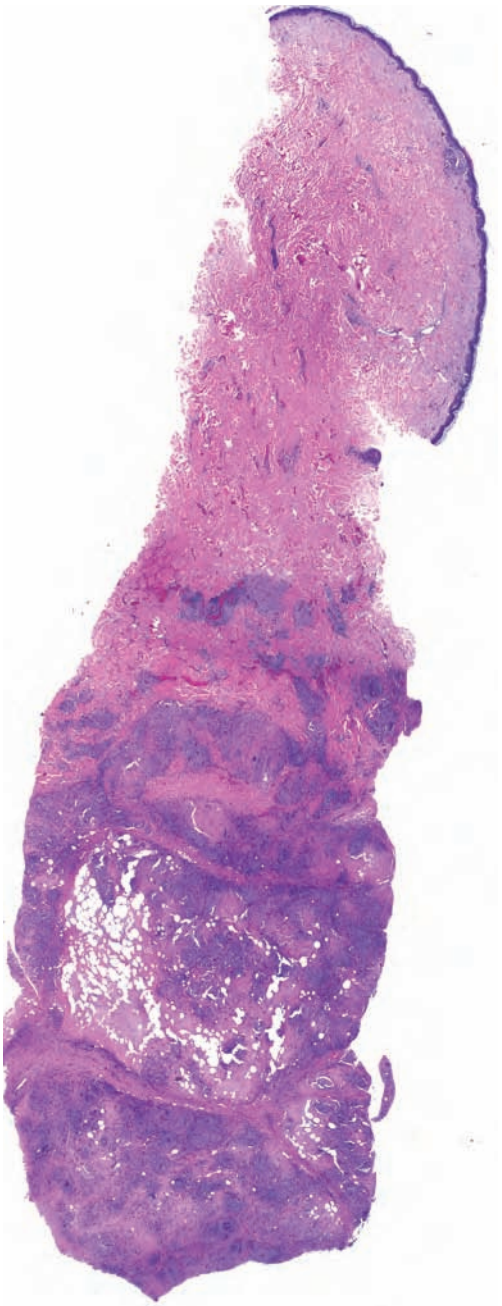

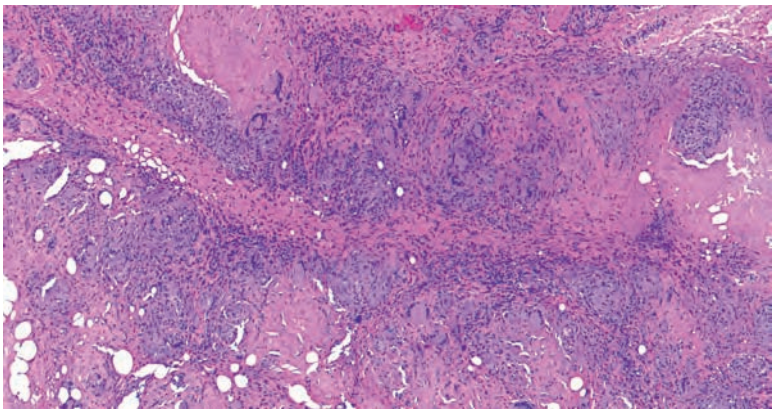

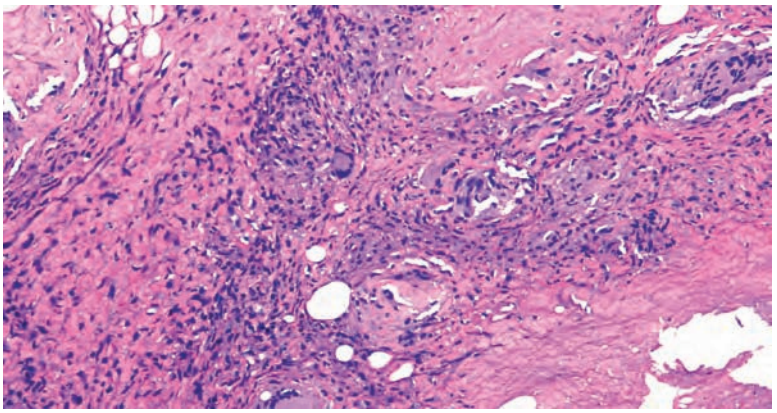

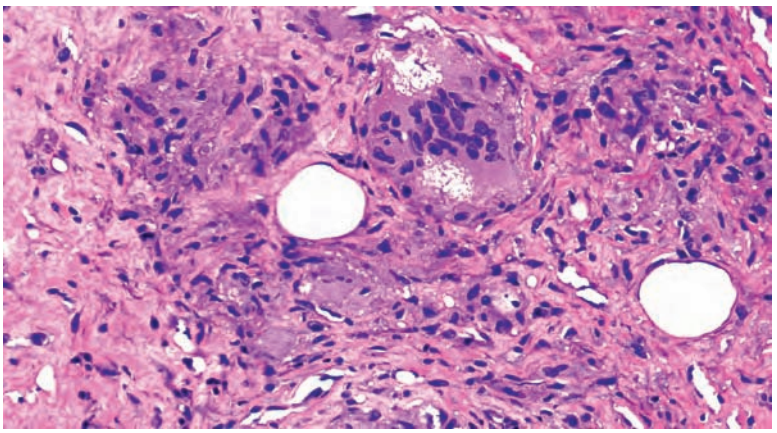

- Palisading of histiocytes and bizarre, multinucleated giant cells around foci of necrosis
- Scattered Touton giant cells
- Cholesterol clefts, plasma cells, and/or lymphoid follicles may be present

Necrobiotic xanthogranuloma

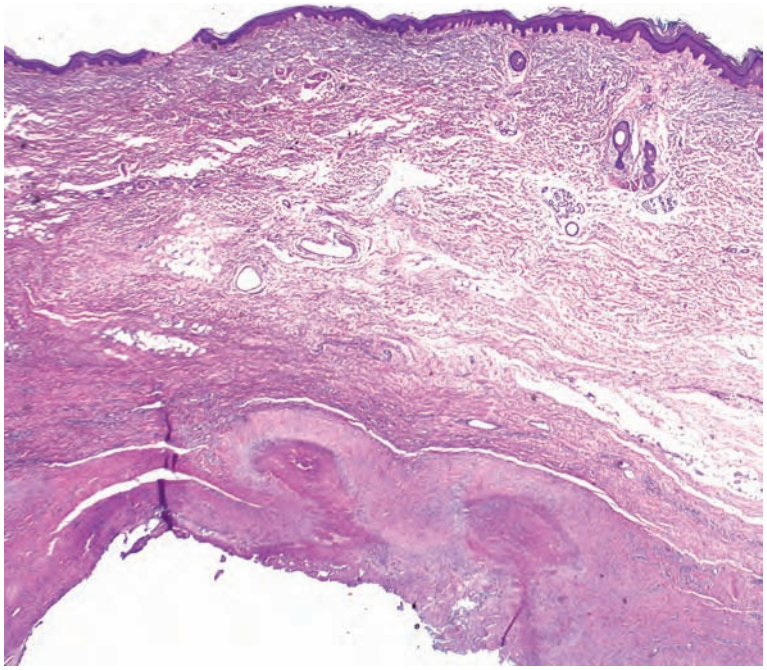

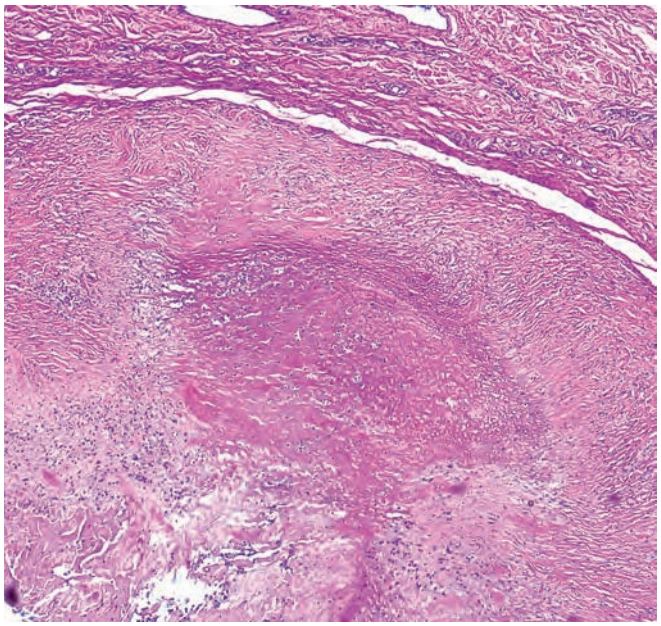

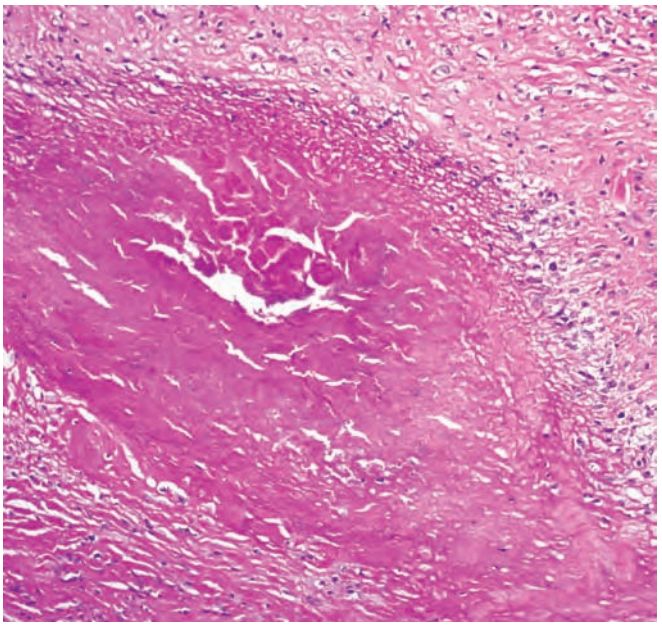

- Palisading of histiocytes around central pink fibrin
- The reaction is often deep

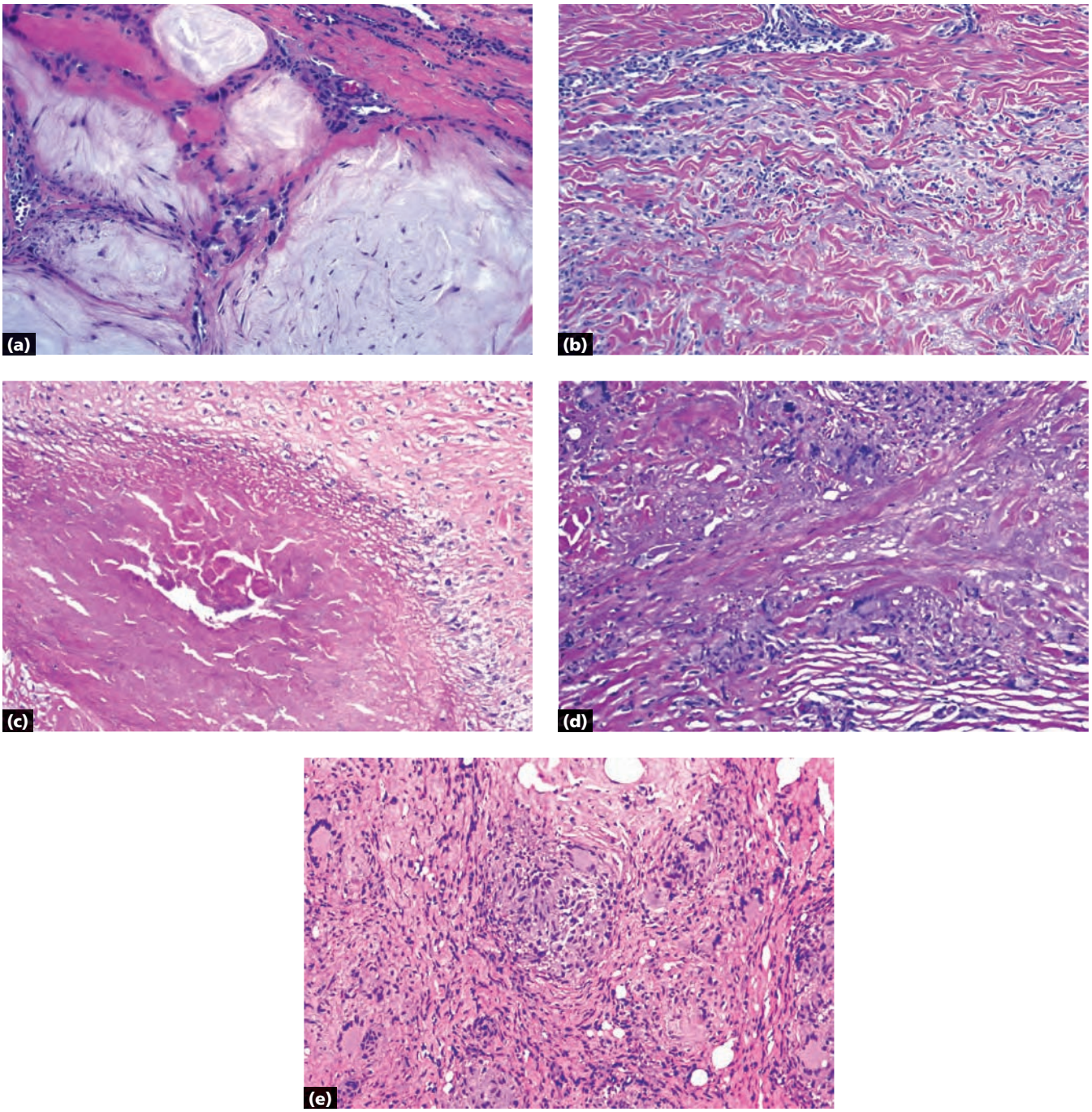

a Gout: central white-gray feathery material
b Granuloma annulare: central altered collagen interspersed with blue mucin
c Rheumatoid nodule: central pink fibrin
d Necrobiosis lipoidica: altered "red" collagen surrounded by giant cells, plasma cells (see page 83)
e Necrobiotic xanthogranuloma: bizarre, multinucleated giant cells; Touton giant cells

Key differences

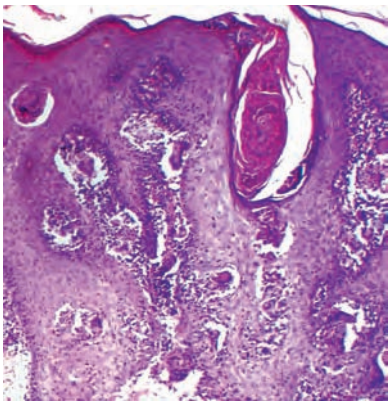

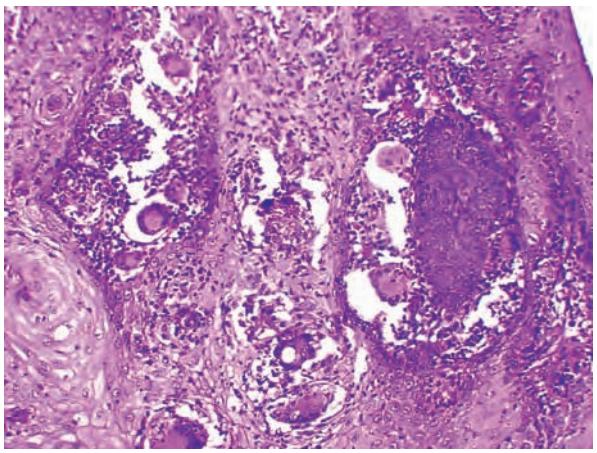

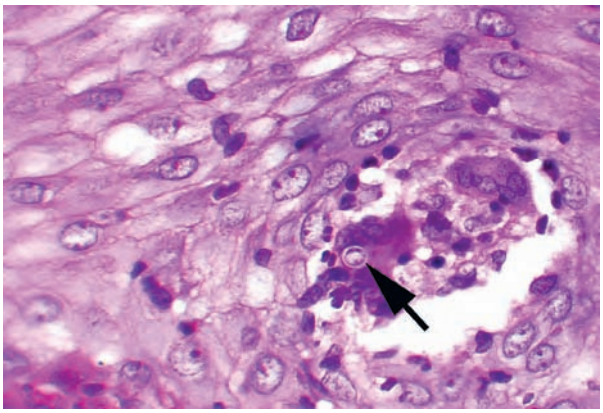

- Pseudoepitheliomatous hyperplasia above abscesses
- Yeast forms (arrow) that classically show broad-based budding

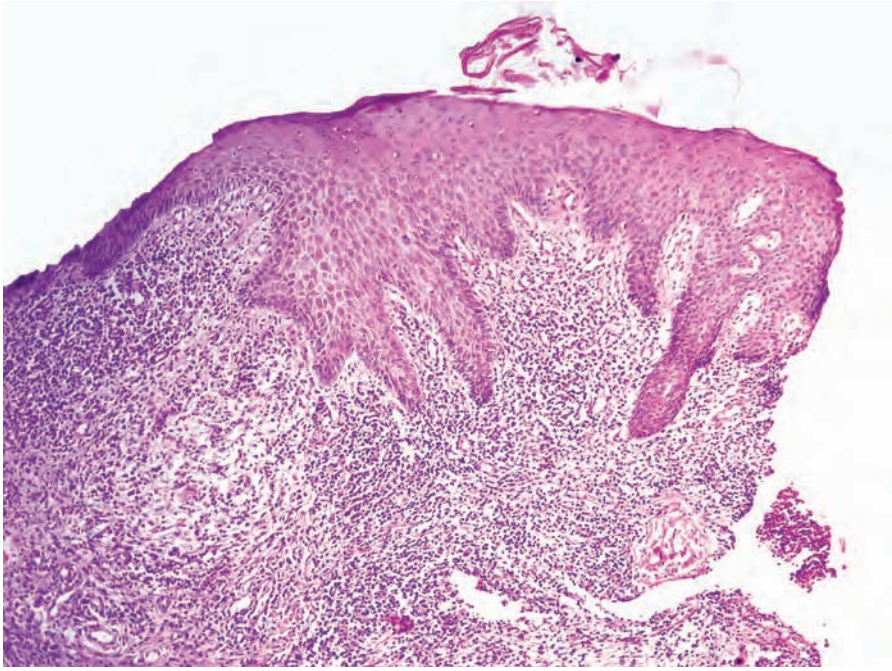

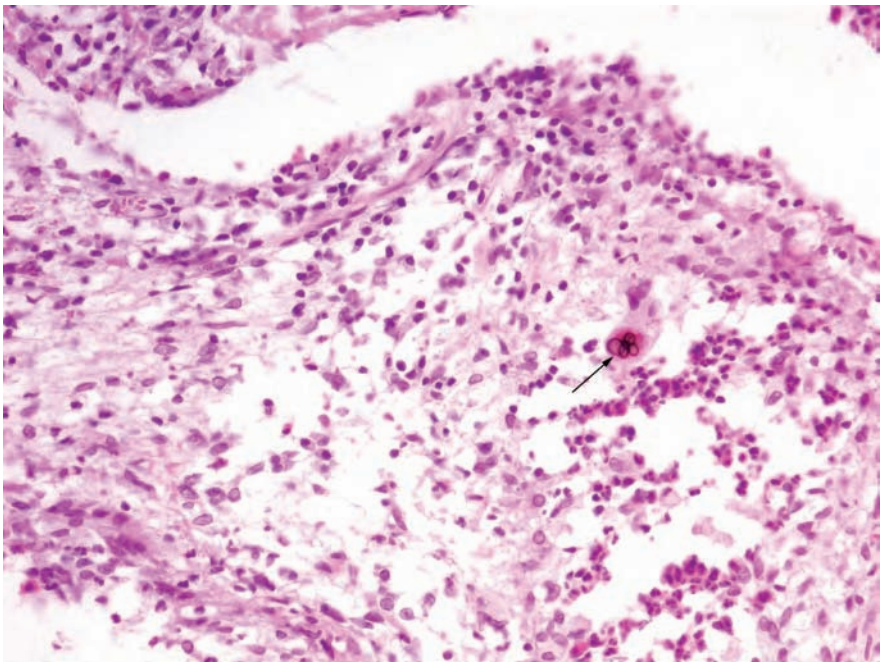

- Pseudoepitheliomatous hyperplasia above abscesses
- Brown-colored septate rounded "hot cross buns" (Medlar bodies, sclerotic bodies, copper pennies) (arrow)

Chromomycosis

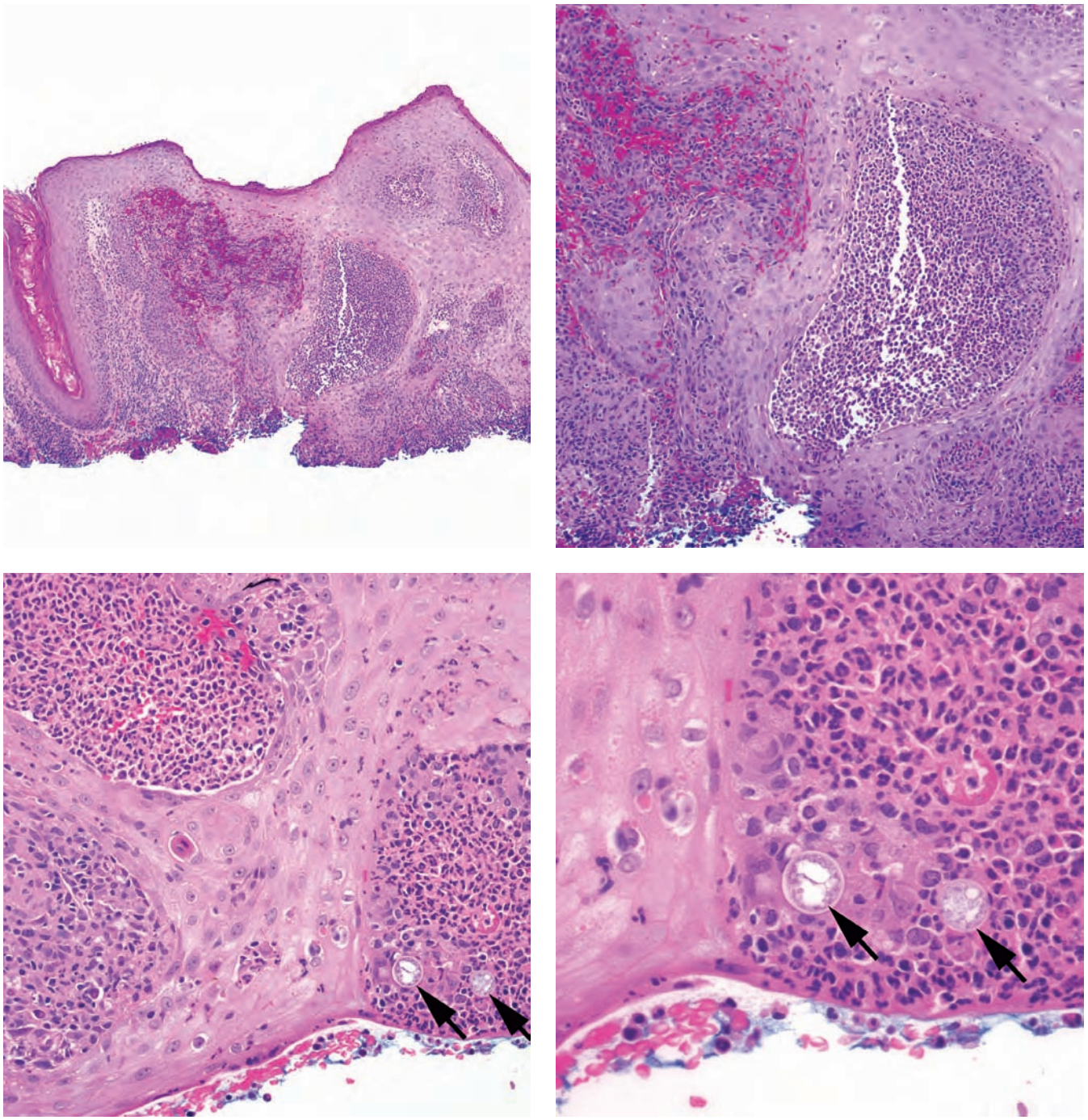

- Pseudoepitheliomatous hyperplasia above abscesses
- Large (~80-200 micron) spherules containing endospores (arrows)

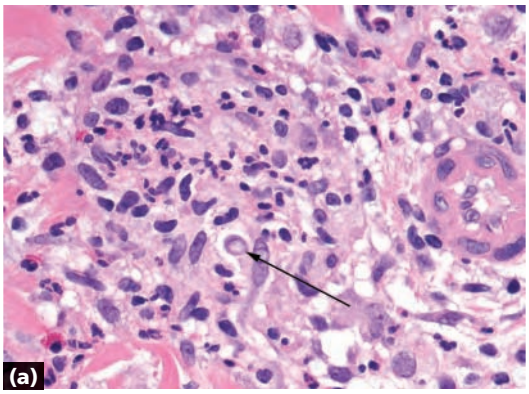

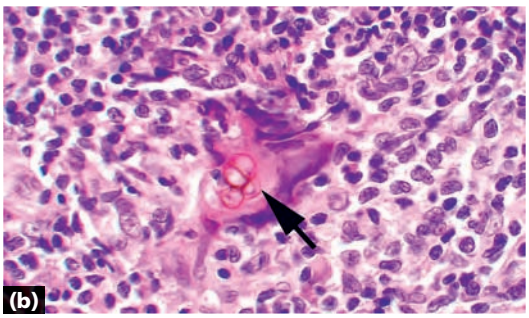

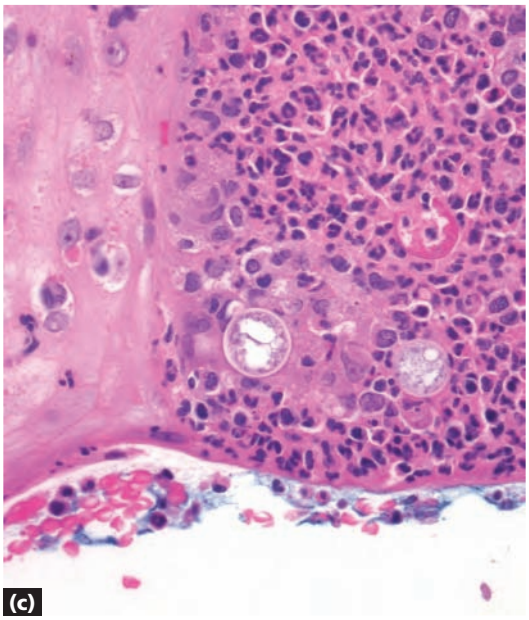

a Blastomycosis: ~8–30 micron yeast form (arrow)
b Chromomycosis: ~5–12 micron Medlar bodies
c Coccidioidomycosis: ~80-200 micron spherules with endospores

Note Paracoccidioidomycosis (~6–60 micron Mariner's wheel; an uncommon infection in the United States), sporotrichosis (organisms usually not evident in biopsies), and tuberculosis verrucosa cutis may also show this pattern.

Key differences

2 Gestalt: Rash/inflammatory

- Epidermal changes
  - Parakeratosis, 99
  - Spongiosis, 102
  - Papulosquamous (psoriasiform), 106
  - Interface (vacuolar), 112
  - Interface (lichenoid), 117
- Inflammation: Specific patterns and cell type
  - Epidermal eosinophils, 123
  - Perivascular, 127
  - Band-like dermal/papillary dermal infiltrate, 131
  - Diffuse/nodular, 137
  - Subcutaneous, 144

Dermatopathology: Diagnosis by First Impression, Third Edition. By Christine J. Ko and Ronald J. Barr.

© 2017 John Wiley & Sons, Ltd. Published 2017 by John Wiley & Sons, Ltd.

Companion website: www.wiley.com/go/ko/dermatopathology3e

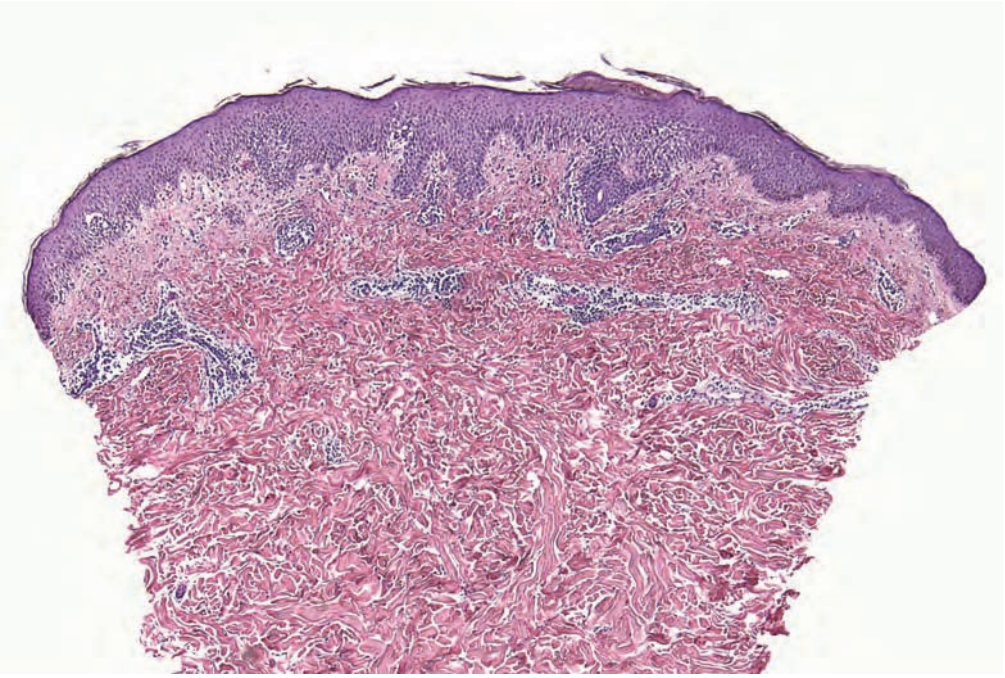

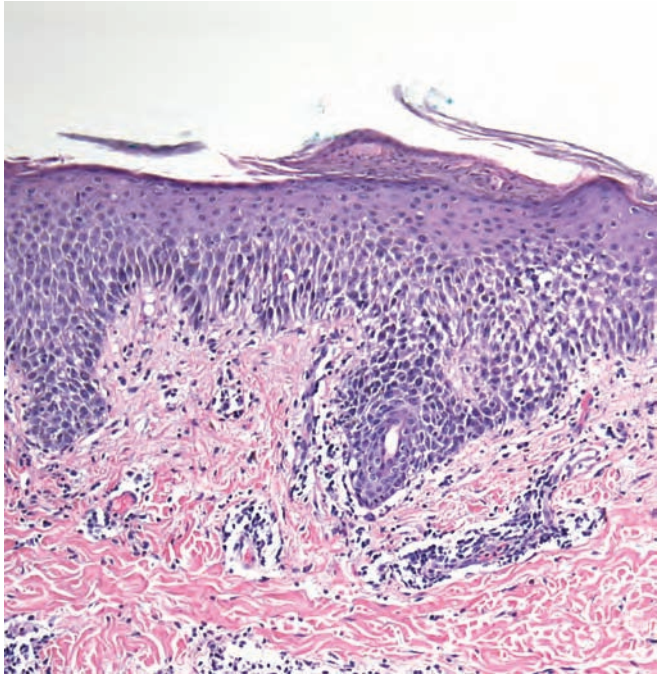

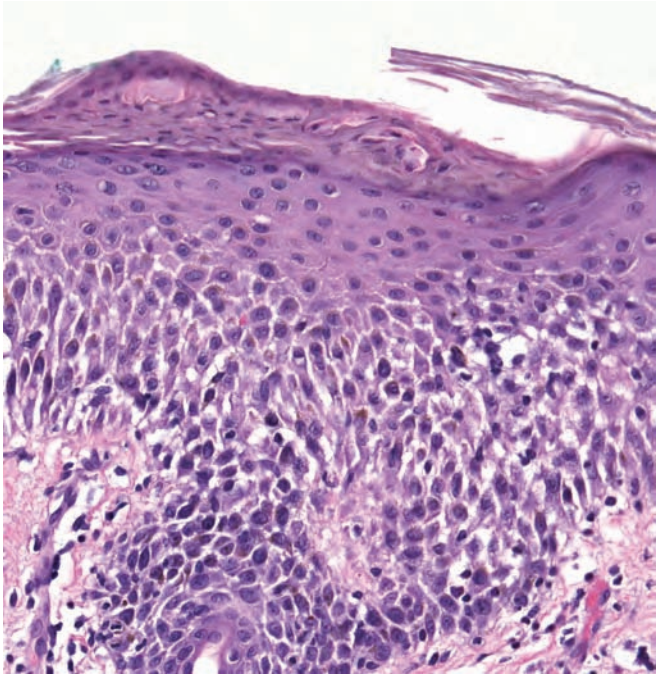

- "Wet" parakeratosis (parakeratosis with serum)
- Increased space between keratinocytes
- Vesicles may be present
- Exocytosis of lymphocytes
- Perivascular inflammation

Spongiotic dermatitis

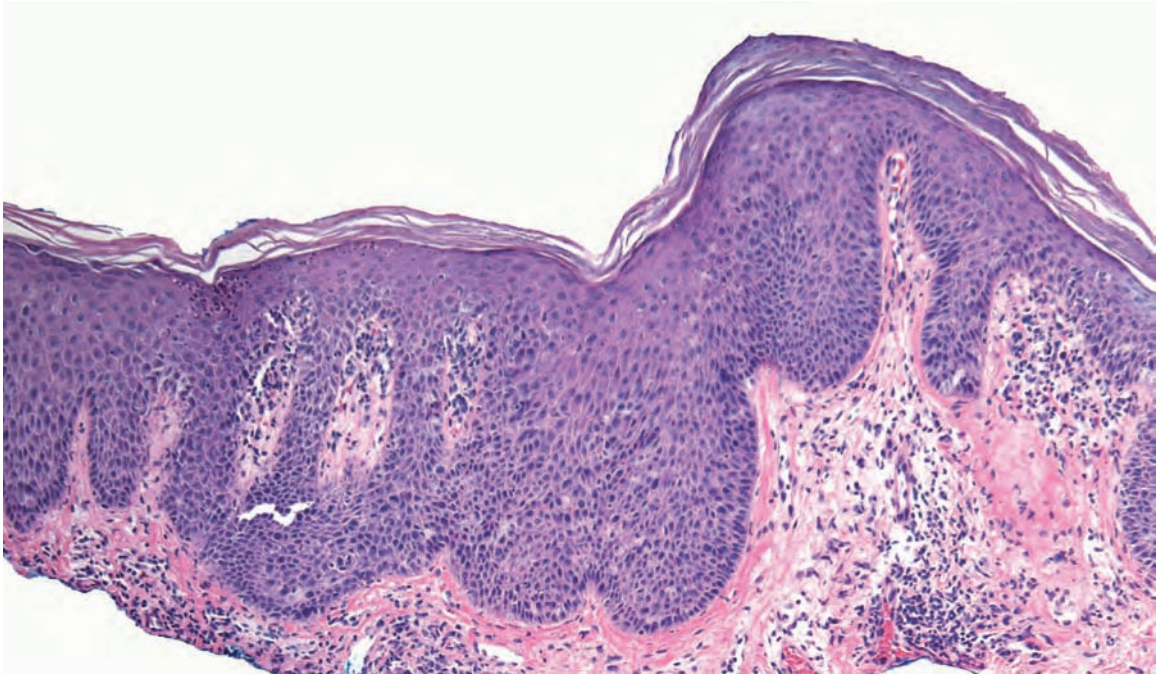

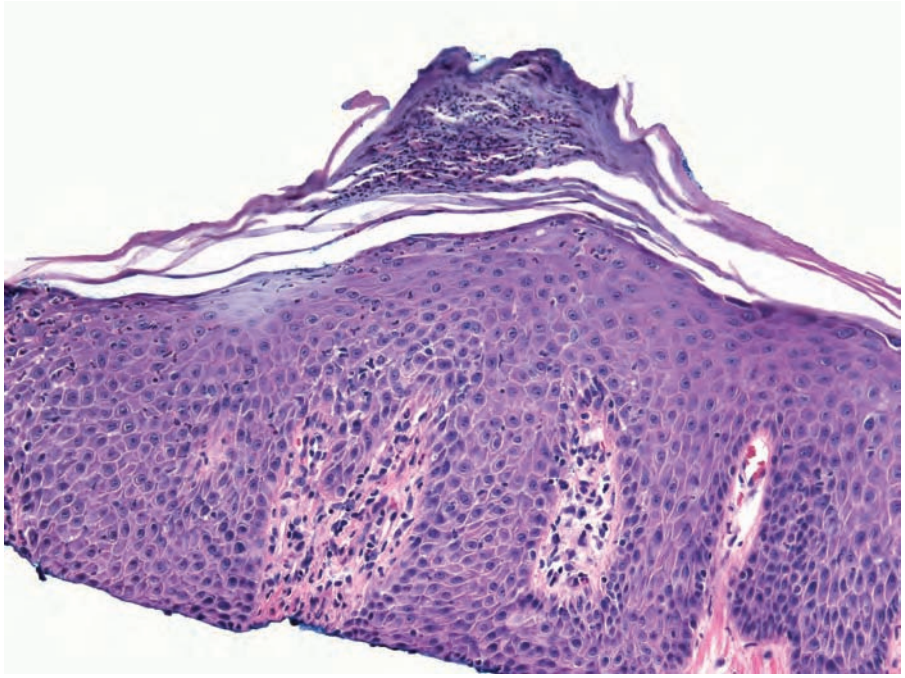

- Dry parakeratosis with neutrophils
- Regular acanthosis
- Hypogranulosis
- Neutrophils may be present in the stratum spinosum
- Prominent vessels in papillary dermis
- Perivascular inflammation

Psoriasis

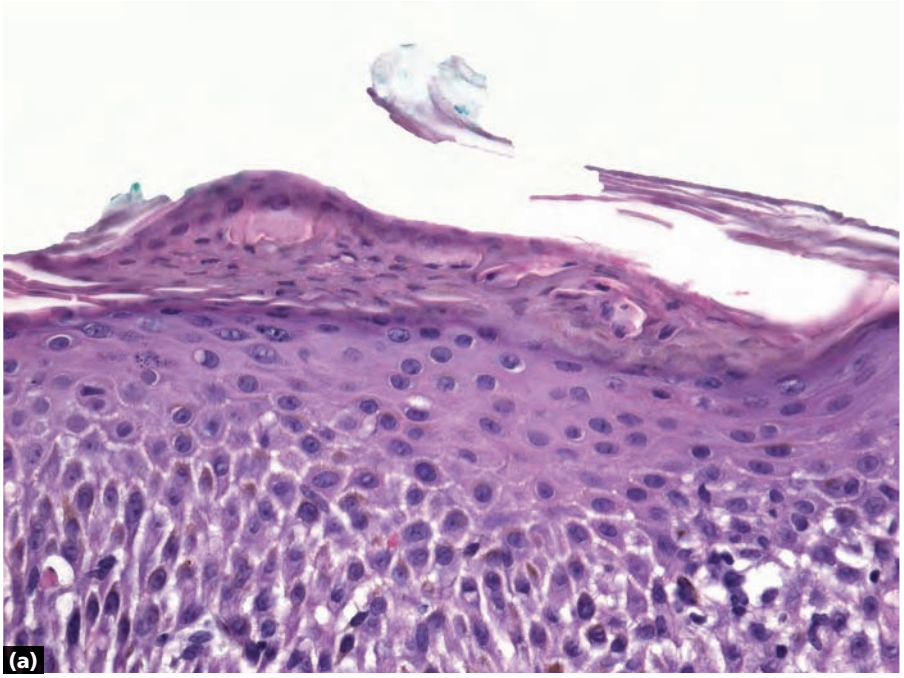

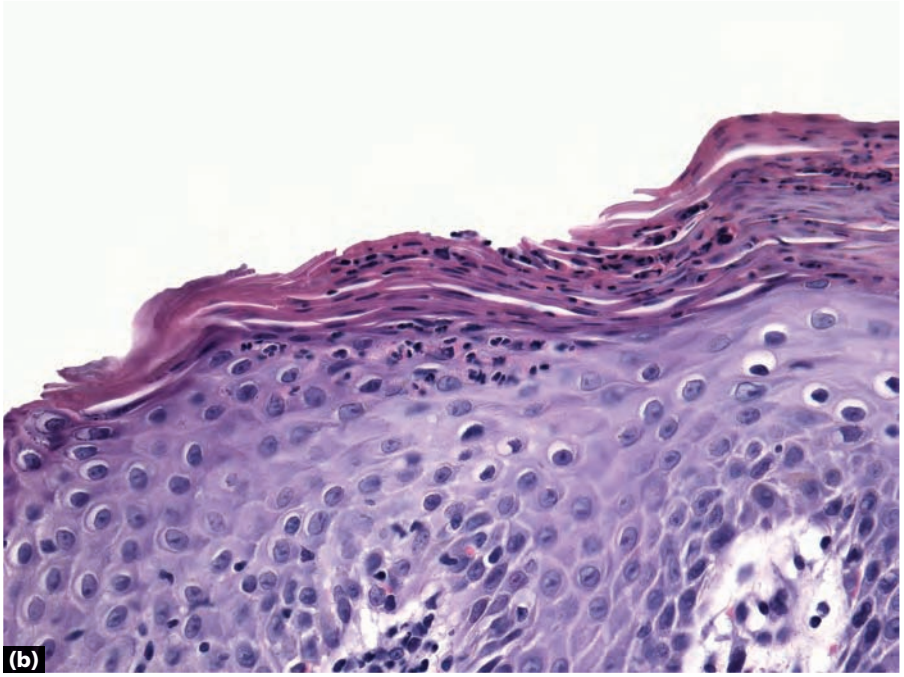

a Spongiotic dermatitis: wet parakeratosis, increased space between keratinocytes, preserved granular layer
b Psoriasis: dry parakeratosis with neutrophils, regular acanthosis, hypogranulosis, prominent papillary dermal blood vessels

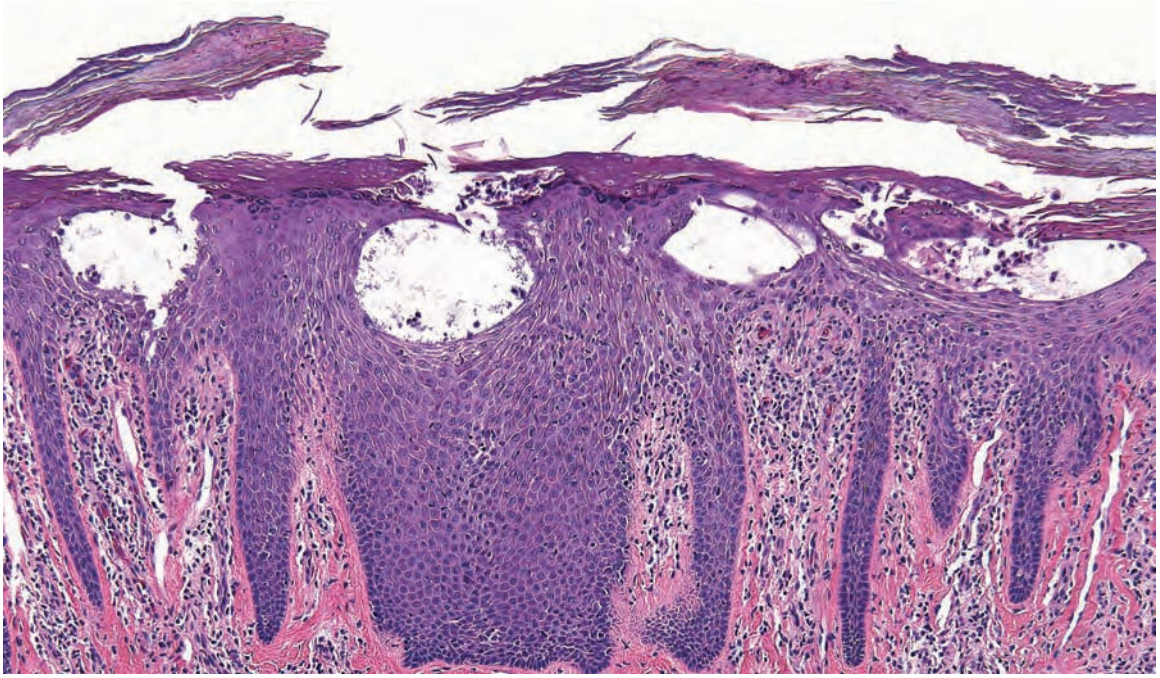

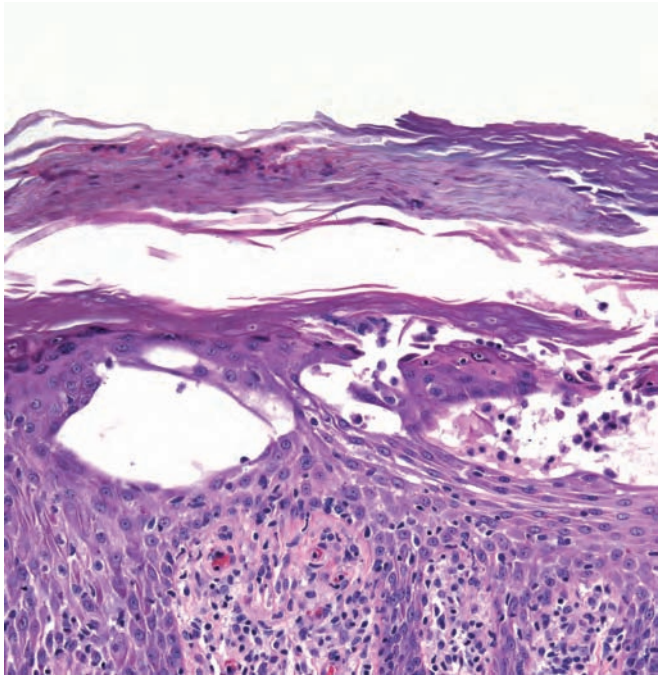

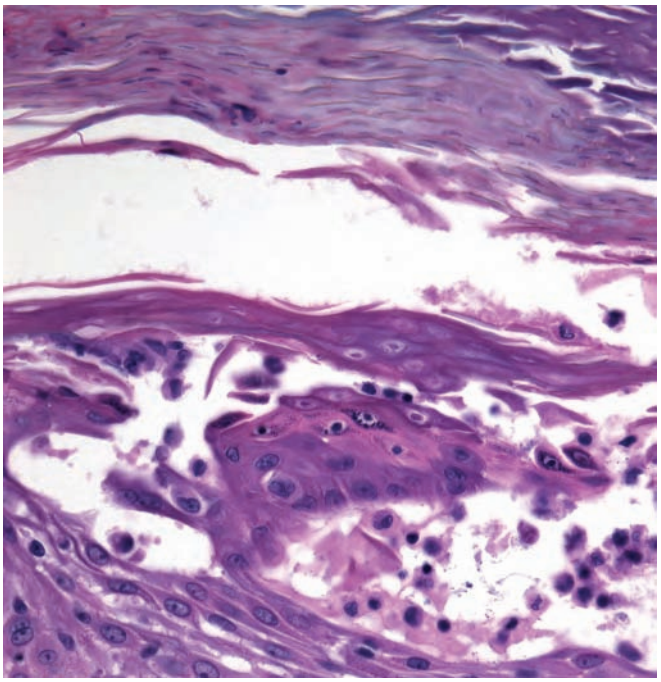

- Spongiosis
- Vesicles within epidermis may be prominent

Allergic contact dermatitis

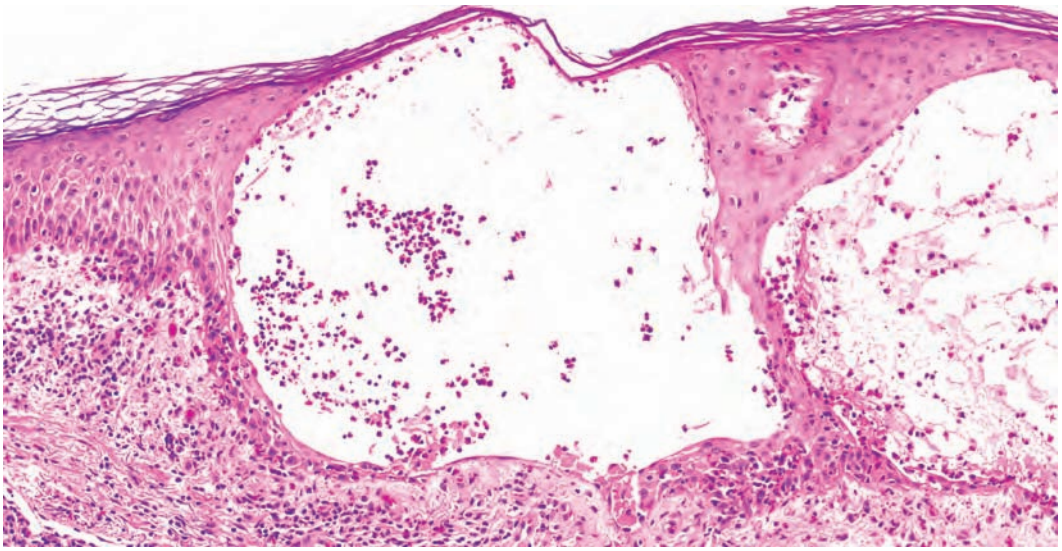

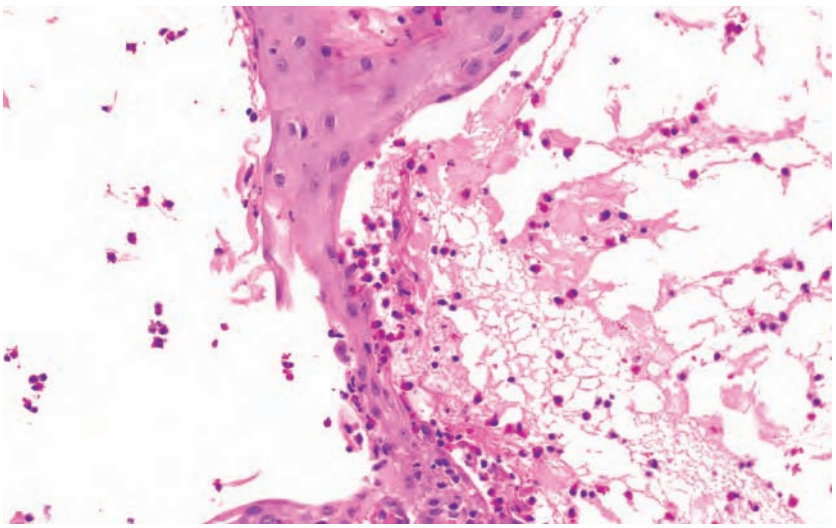

- Eosinophilic spongiosis
- Wedge-shaped pattern of inflammation on low power view
- Vesicles within epidermis may be prominent

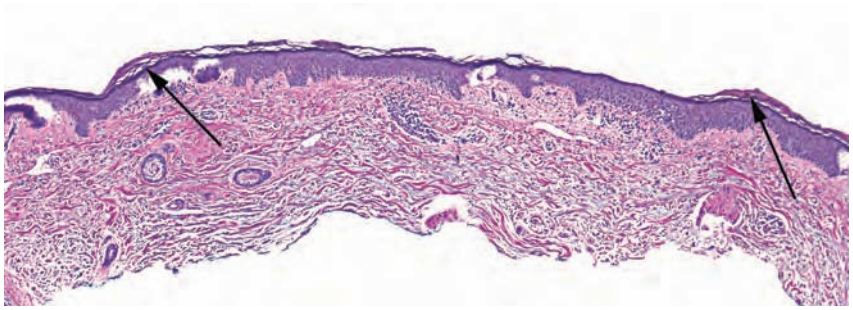

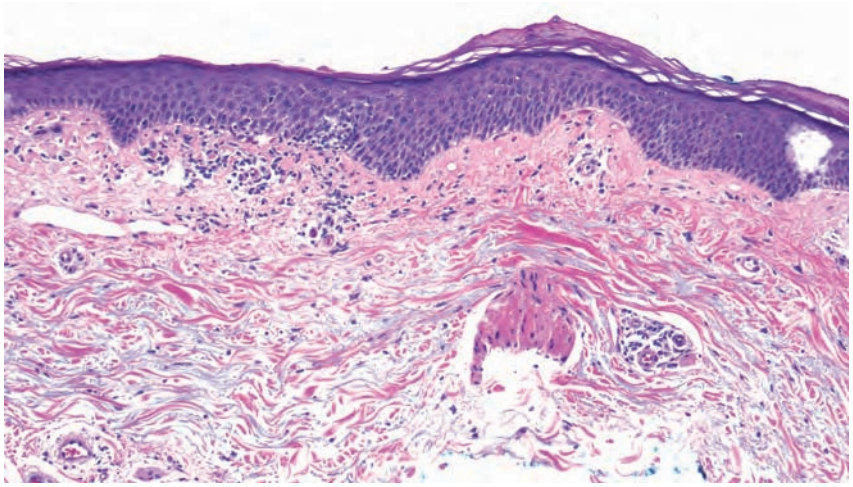

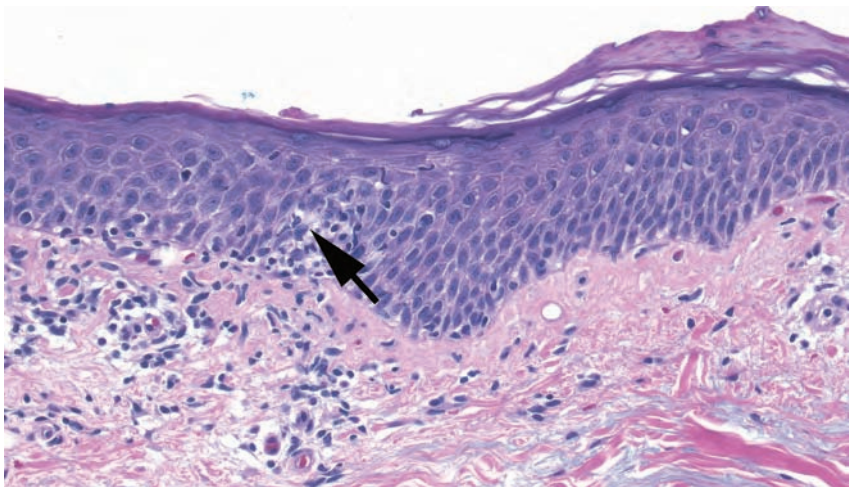

- Mild epidermal spongiosis (short arrow)
- Mounds of parakeratosis (long arrows)
- Superficial perivascular infiltrate of lymphocytes
- Extravasated erythrocytes

Note Guttate psoriasis is in the differential; guttate psoriasis is favored if there are neutrophils in the mounds of parakeratosis.

Pityriasis rosea

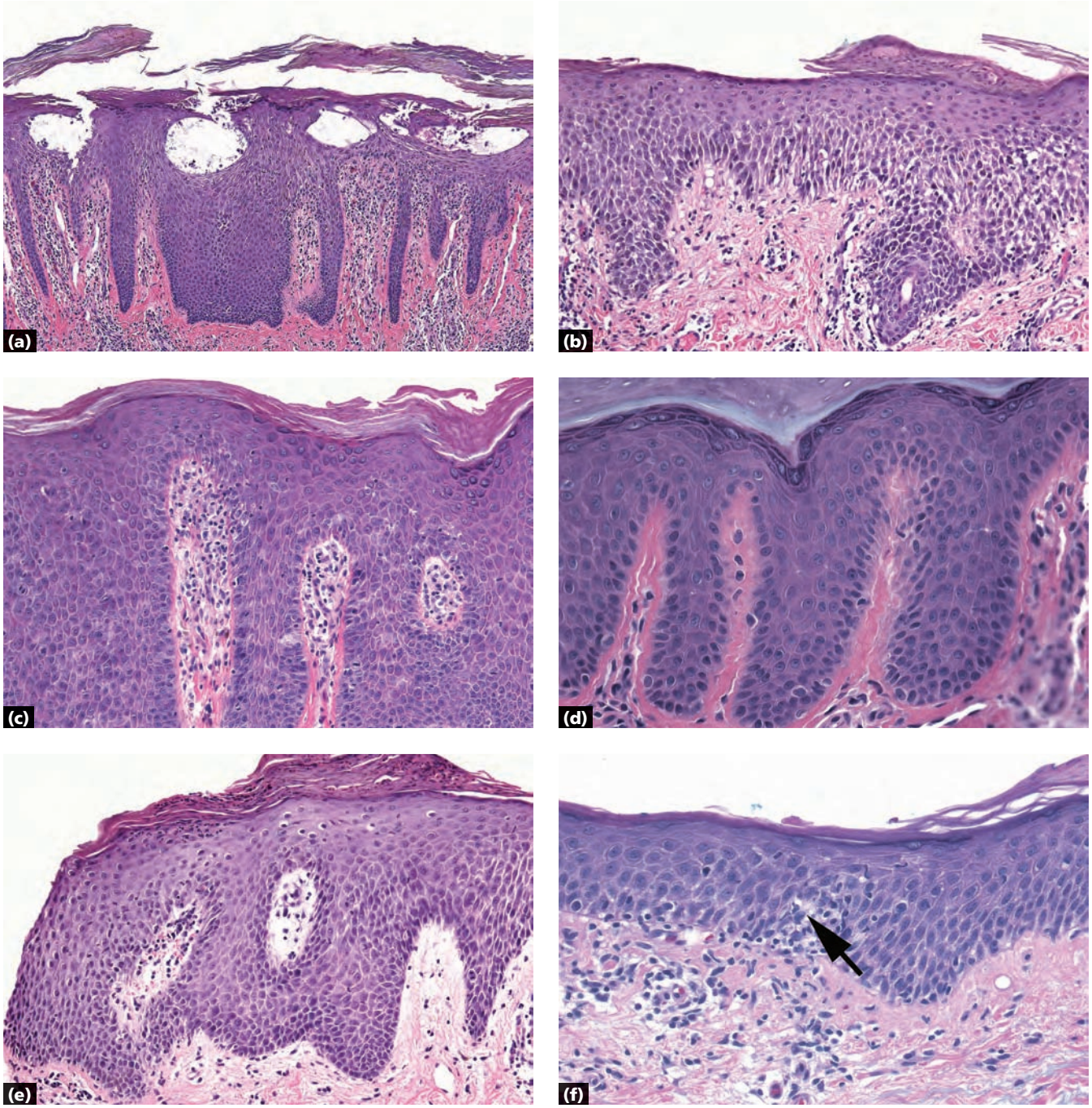

a Acute spongiosis with vesicles (allergic contact dermatitis): parakeratosis, intraepidermal vesicles, intercellular edema
b Acute to subacute spongiosis: parakeratosis with serum ("wet" parakeratosis), intercellular edema
c Chronic spongiosis: parakeratosis, granular layer preserved, acanthosis, subtle intercellular edema (see page 106)
d Lichen simplex chronicus: often a stratum lucidum, minimal intercellular edema, vertical streaking of collagen in papillary dermis (see page 107)
e Psoriasis: dry parakeratosis (parakeratosis generally lacking serum) often with neutrophils, hypogranulosis, neutrophils in stratum spinosum, regular acanthosis, prominent vessels in papillary dermis (see page 100, 109)
f Pityriasis rosea: interrupted foci of parakeratosis, collections of erythrocytes/lymphocytes in the epidermis and papillary dermis

Key differences

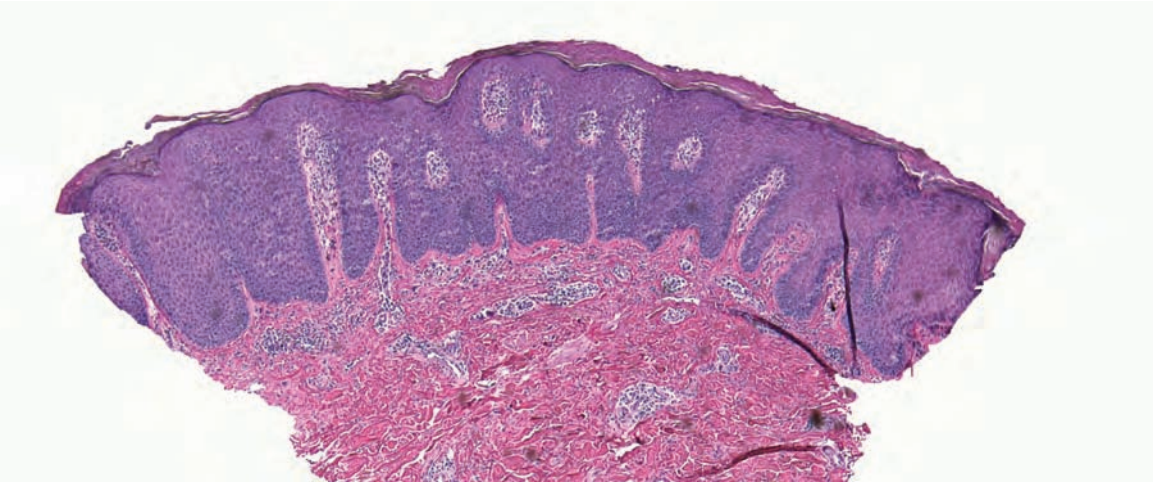

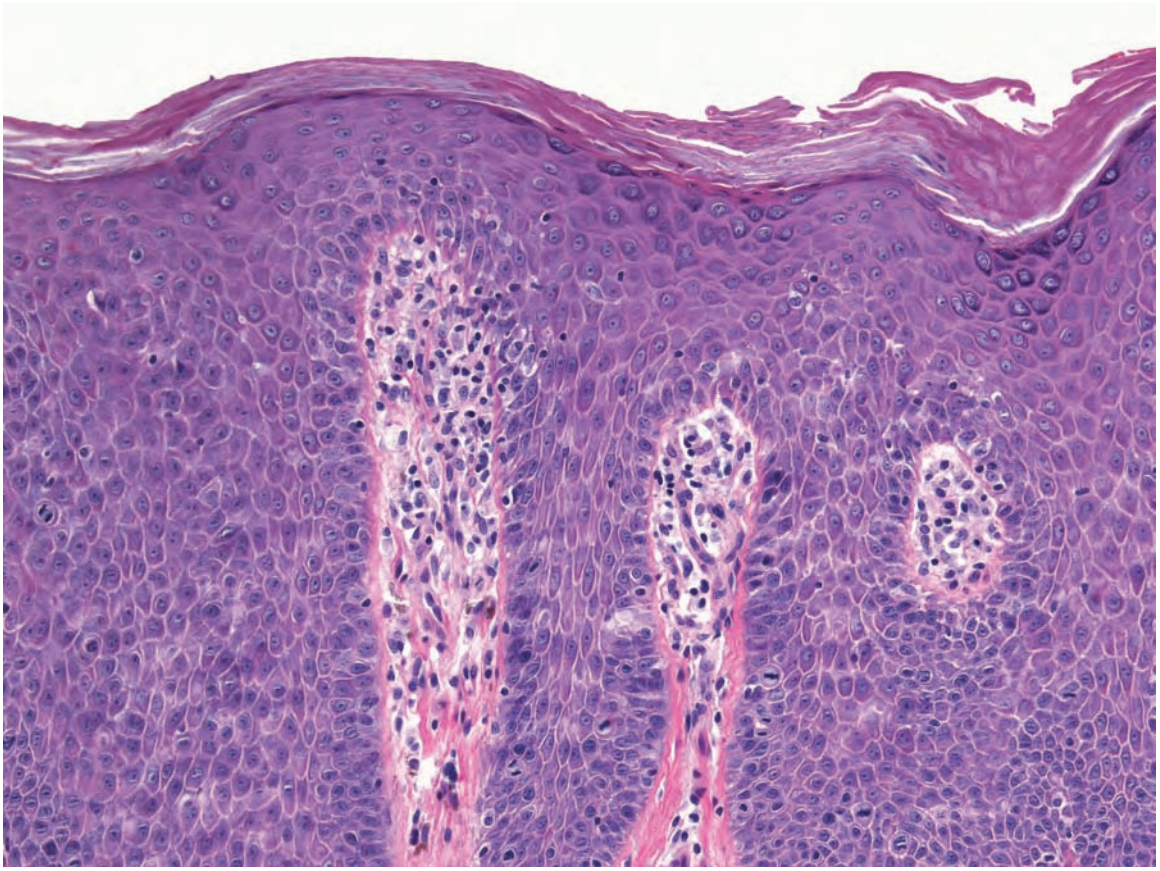

- Papulosquamous (psoriasiform)
- Foci of parakeratosis
- Subtle foci of interkeratinocytic edema
- Irregular acanthosis with preserved granular layer
- Perivascular inflammation

Note There is some overlap of chronic spongiotic dermatitis with lichen simplex chronicus, with the latter classically lacking parakeratosis and spongiosis and having dermal fibrosis.

Chronic spongiotic dermatitis

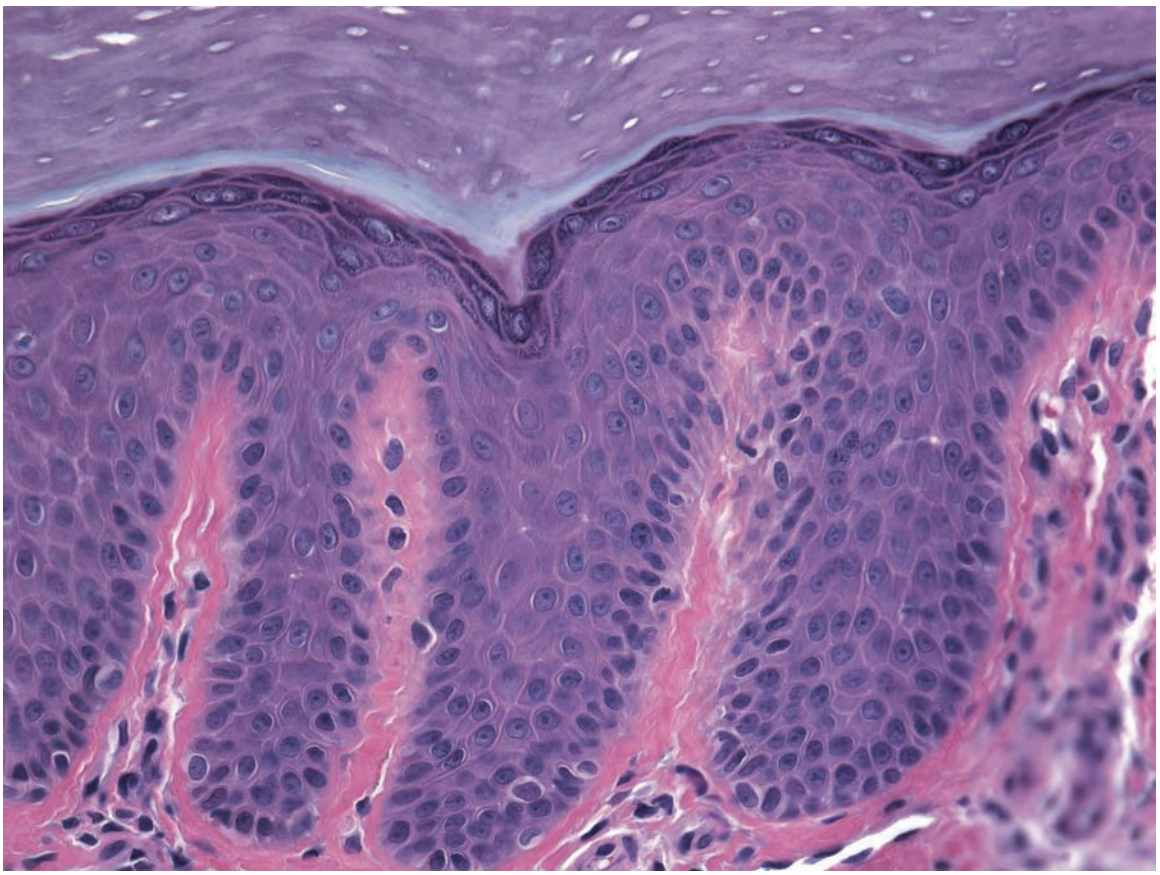

- Papulosquamous (psoriasiform)
- Hyperkeratosis with a stratum lucidum
- Irregular acanthosis with hypergranulosis
- Vertical streaking of collagen into the papillary dermis

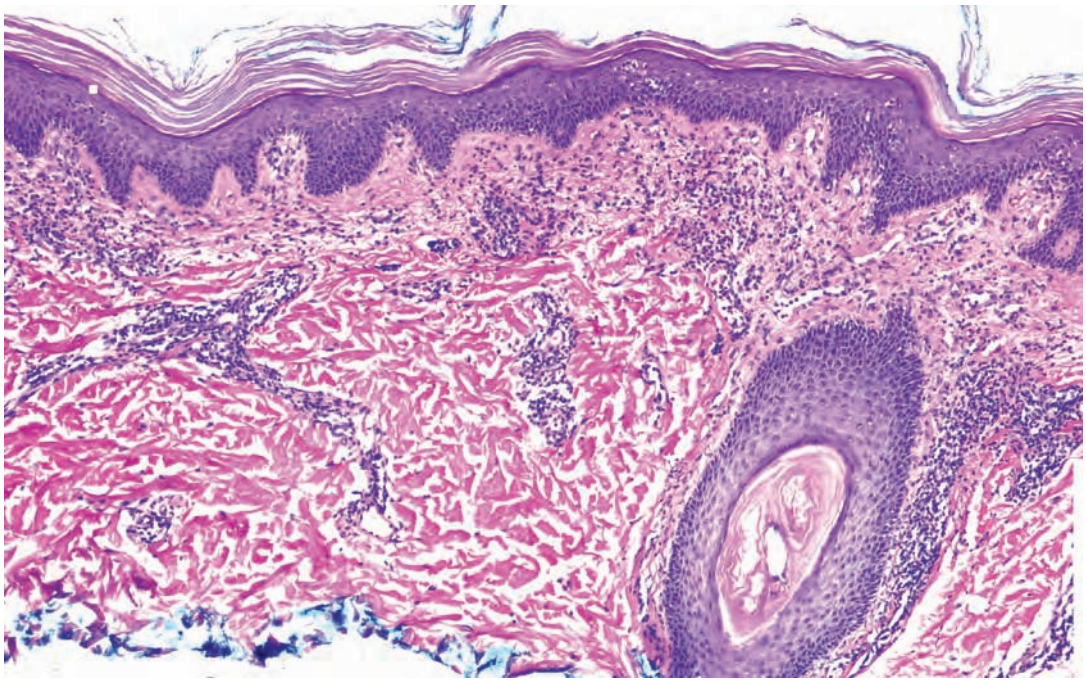

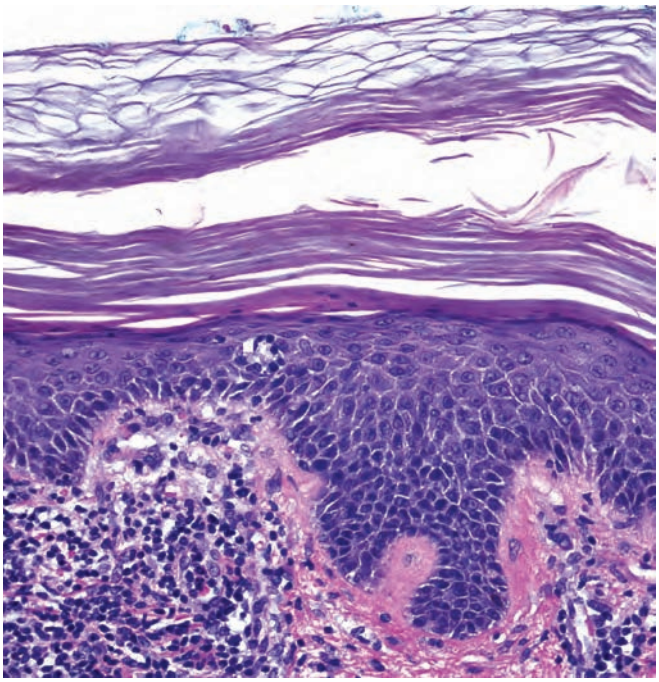

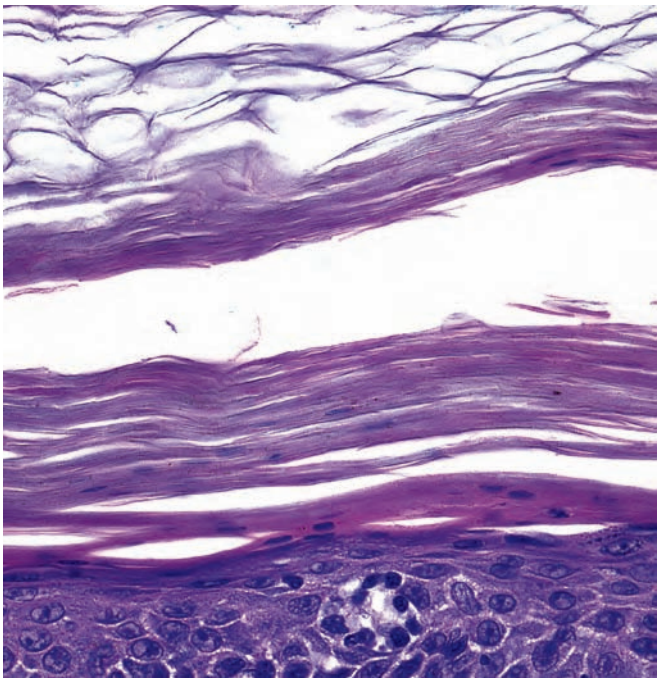

- Papulosquamous (psoriasiform)
- Hyperkeratosis alternates with dry parakeratosis in a checkerboard pattern
- Follicular plugging
- Irregular acanthosis of epidermis

Pityriasis rubra pilaris

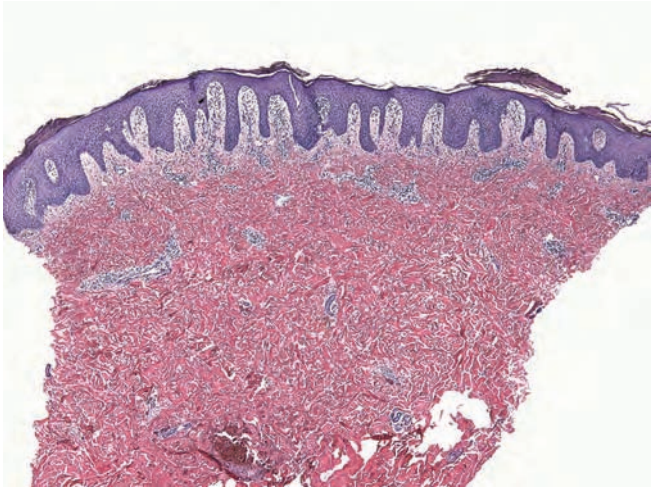

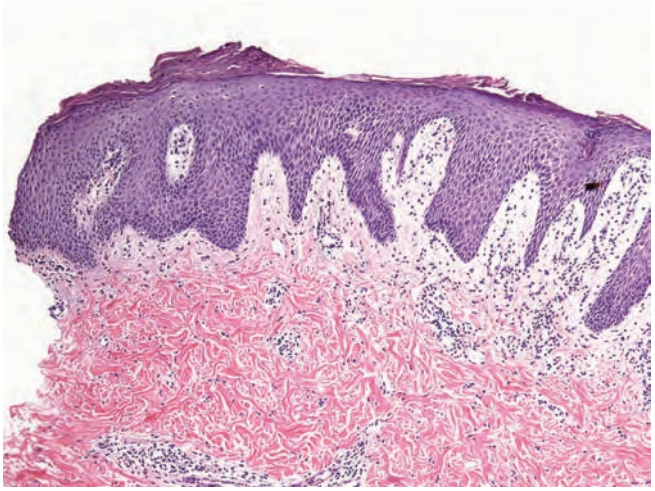

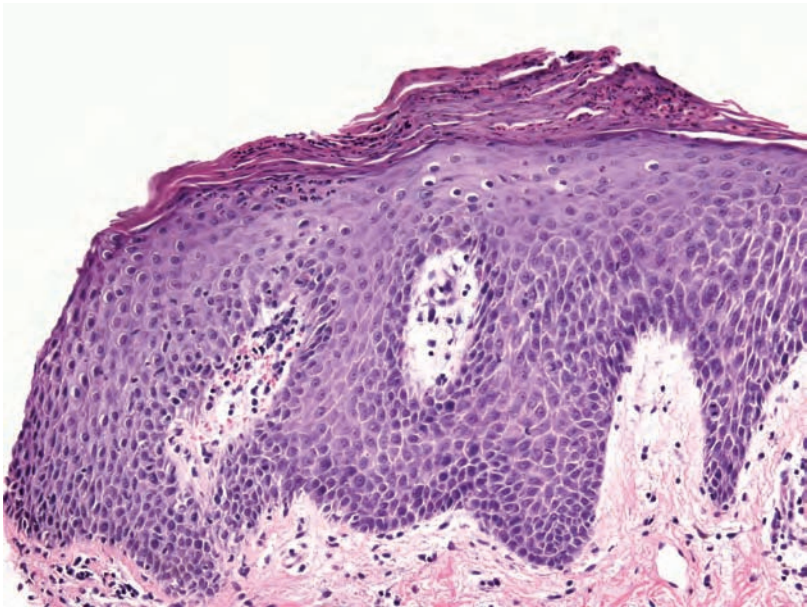

- Papulosquamous
- Dry parakeratosis with neutrophils
- Regular acanthosis with hypogranulosis
- Prominent papillary dermal blood vessels

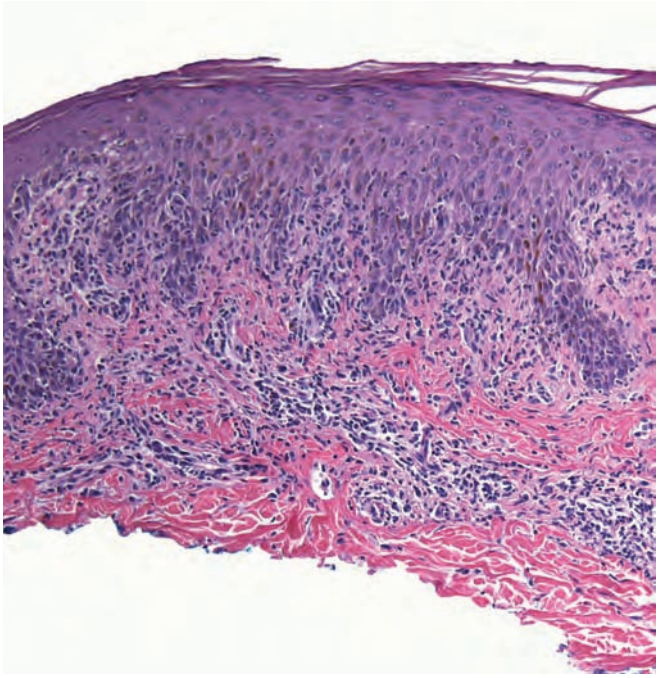

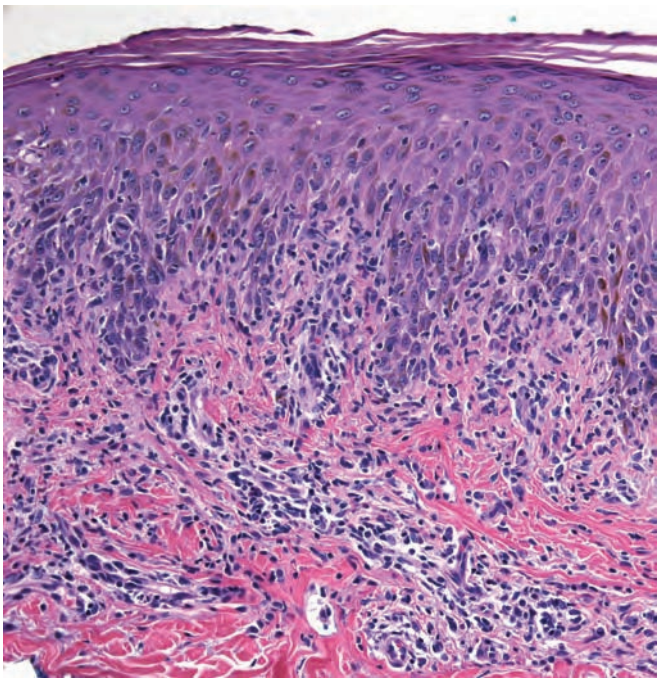

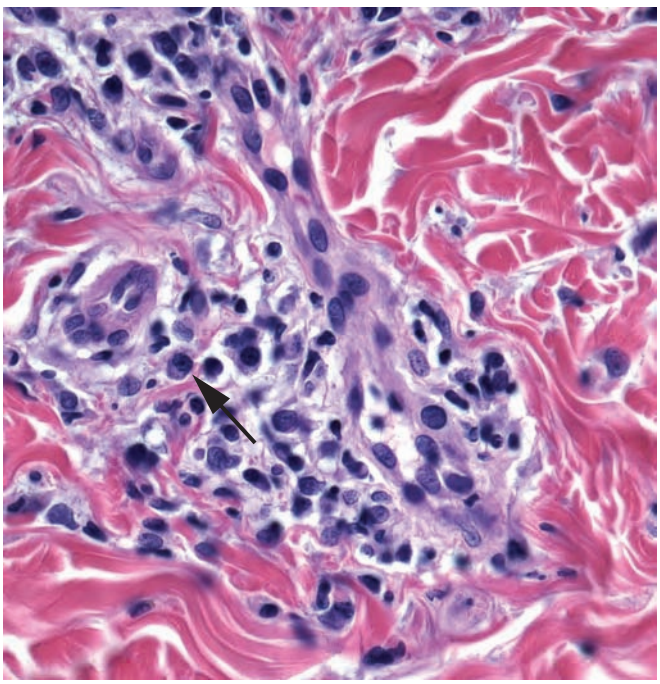

- Papulosquamous (psoriasiform)
- Looks like pityriasis lichenoides et varioliformis acuta with plasma cells (arrow)
- Parakeratosis, sometimes with neutrophils
- Acanthosis with slender rete
- Lichenoid and deep perivascular lymphoplasmacytic inflammation
- Swollen endothelial cells

Secondary syphilis

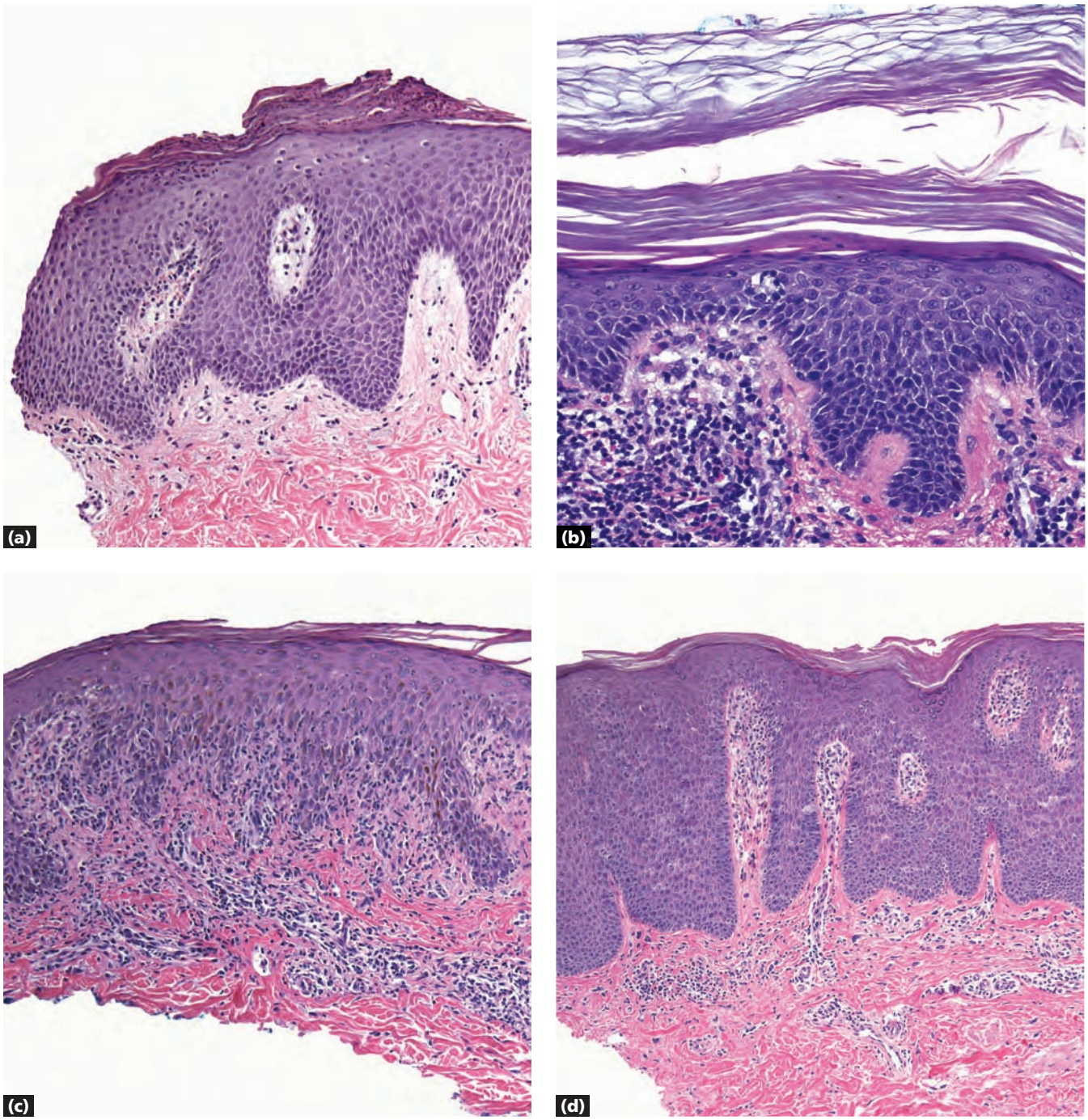

a Psoriasis: neutrophils in the epidermis, regular acanthosis, prominent papillary dermal blood vessels
b Pityriasis rubra pilaris: checkerboard pattern of hyperkeratosis and parakeratosis, follicular plugging
c Secondary syphilis: acanthosis with slender rete, lichenoid inflammation, swollen endothelial cells, plasma cells may be evident
d Chronic spongiotic dermatitis: parakeratosis and foci of spongiosis, irregular acanthosis

Note Some experts reserve the term "psoriasiform" for processes that are difficult/impossible to distinguish from psoriasis.

Key differences

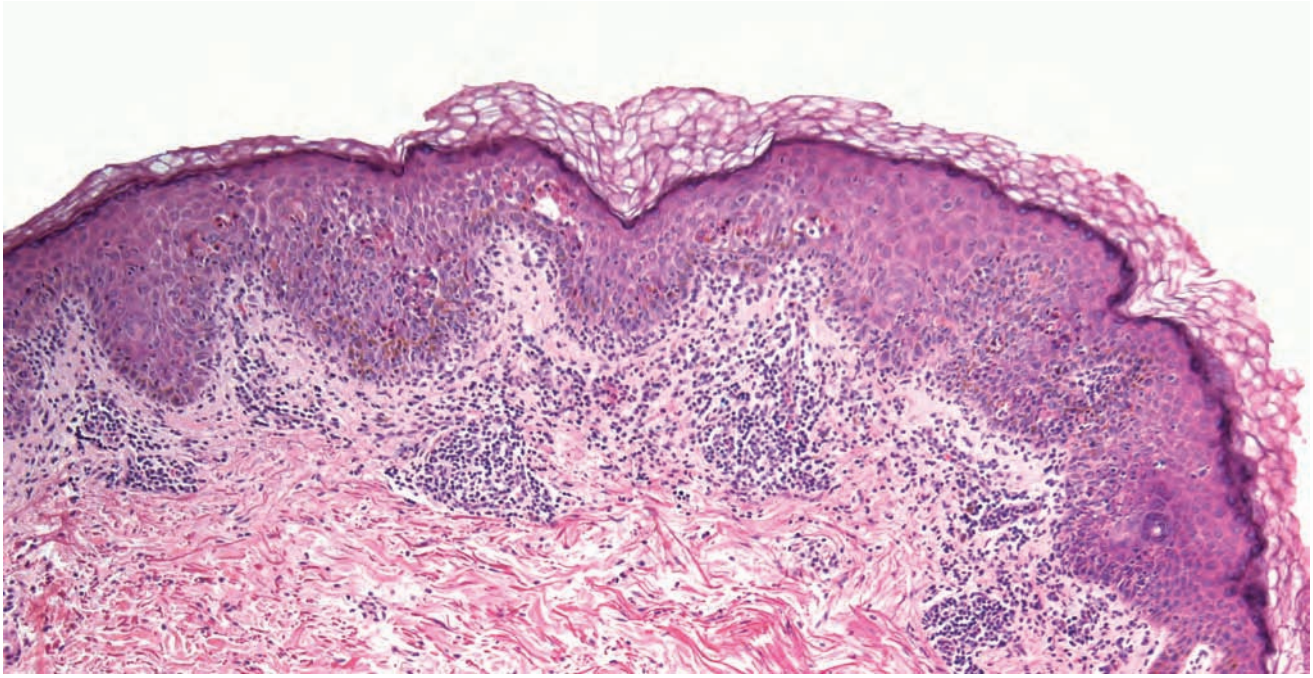

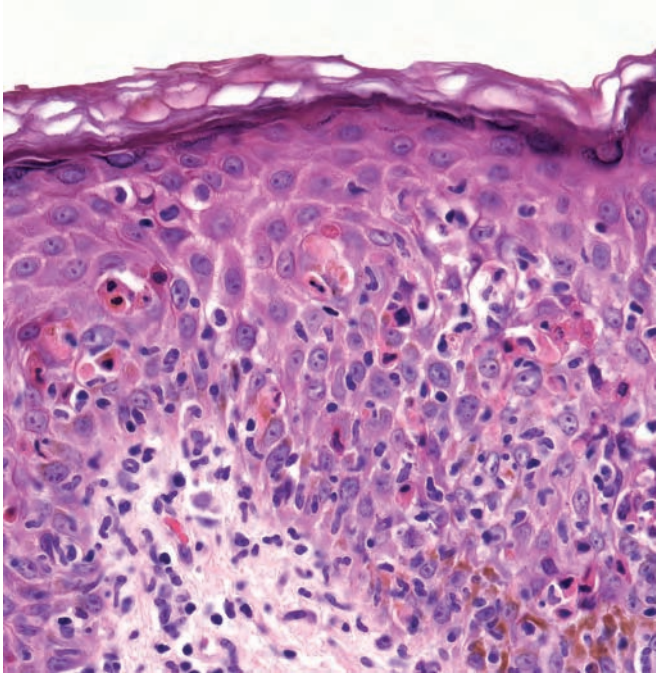

- Interface (vacuolar) change with necrotic keratinocytes in the lower epidermis
- Basket-woven stratum corneum
- Relatively sparse lymphocytic inflammation

Erythema multiforme

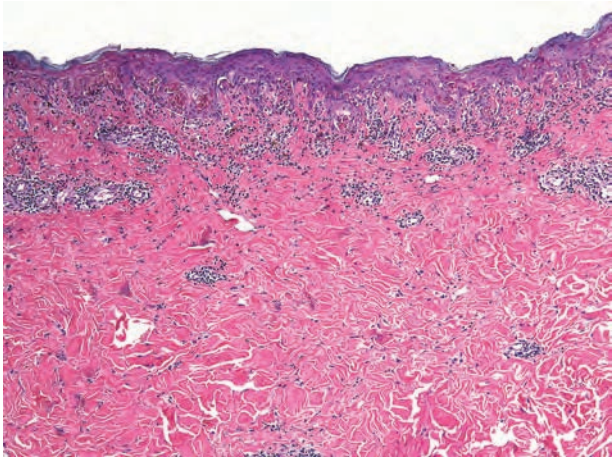

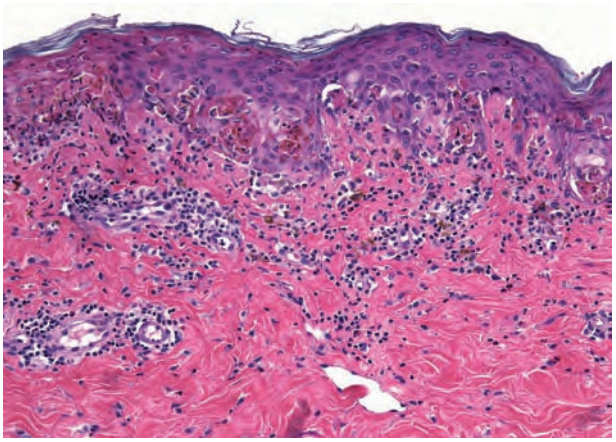

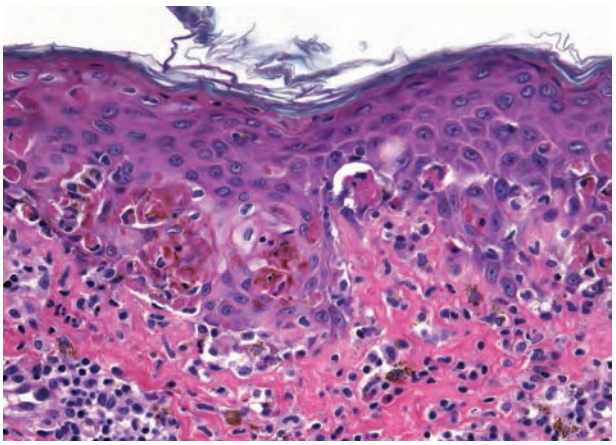

- Interface vacuolar change
- Basket-woven stratum corneum and dermal incontinence of pigment
- Numerous necrotic epidermal cells may be present, mimicking erythema multiforme
- Superficial and deep perivascular infiltrate
- Infiltrate is mixed with eosinophils and neutrophils

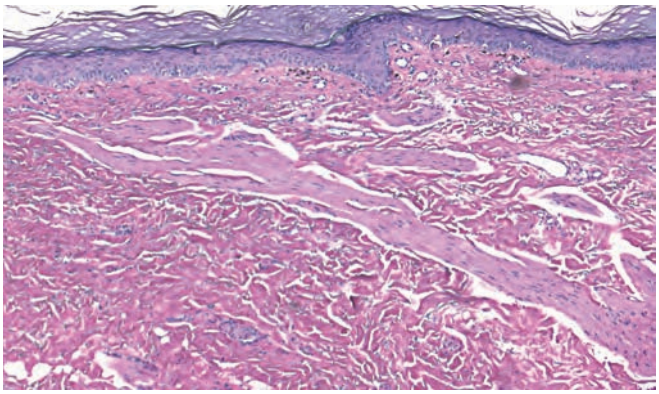

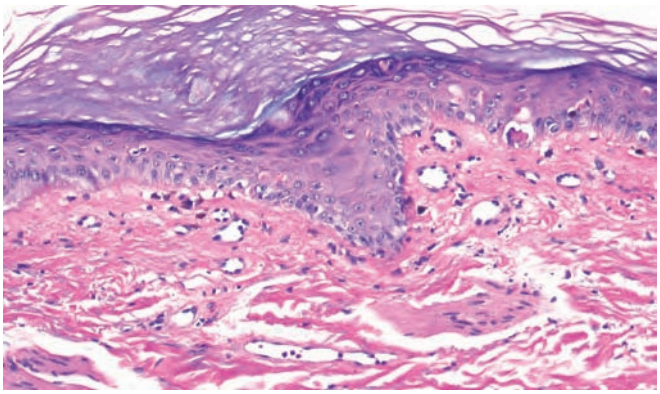

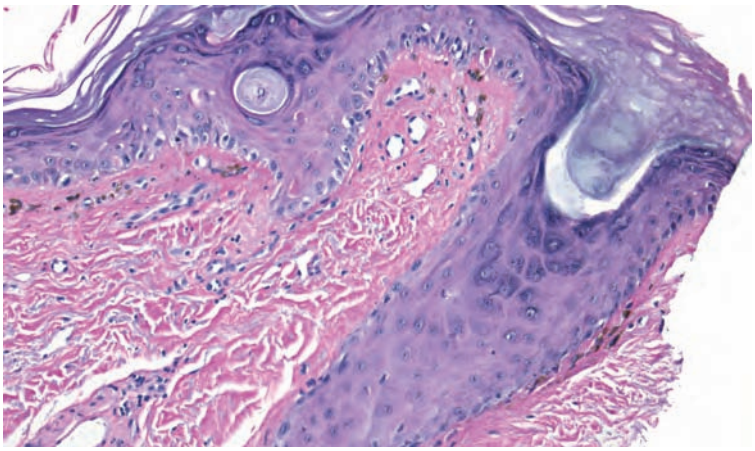

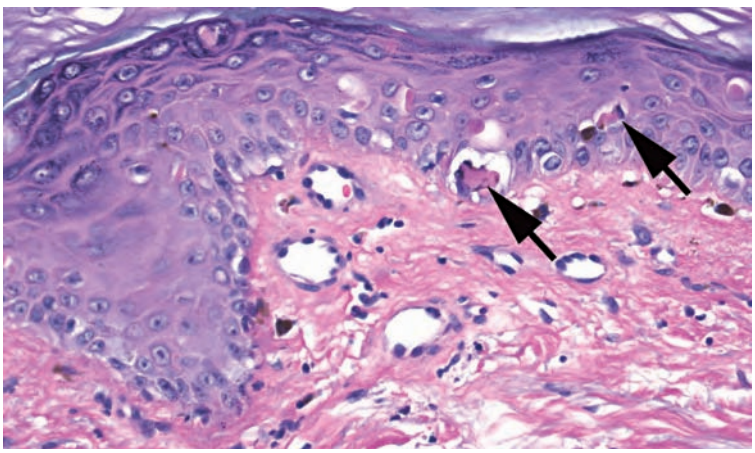

- Vacuolar change at dermoepidermal junction
- Necrotic keratinocytes (arrows) in epidermis and follicles with adjacent lymphocytes (satellite cell necrosis)

Graft-versus-host disease

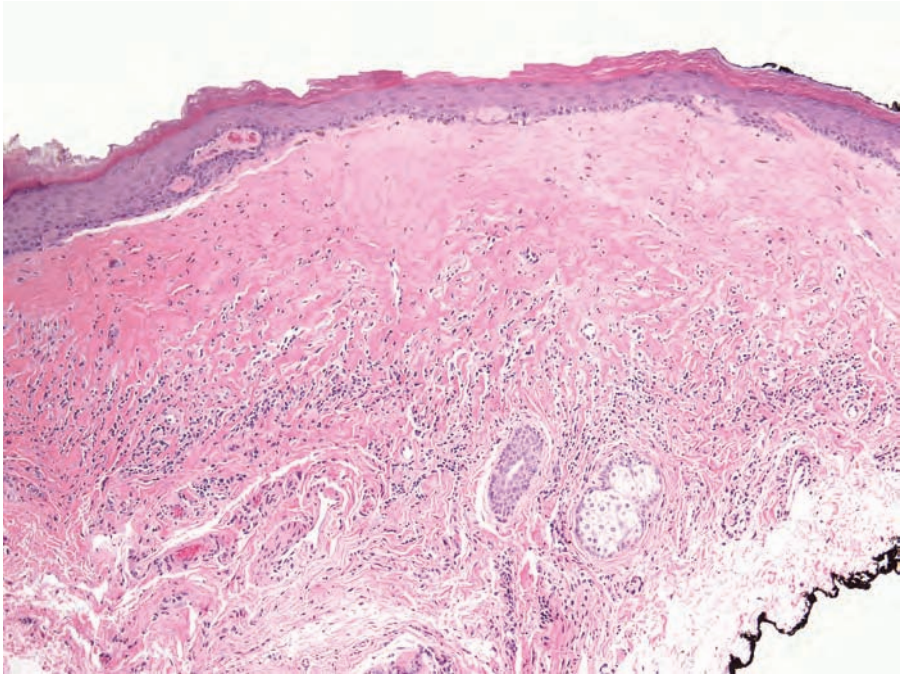

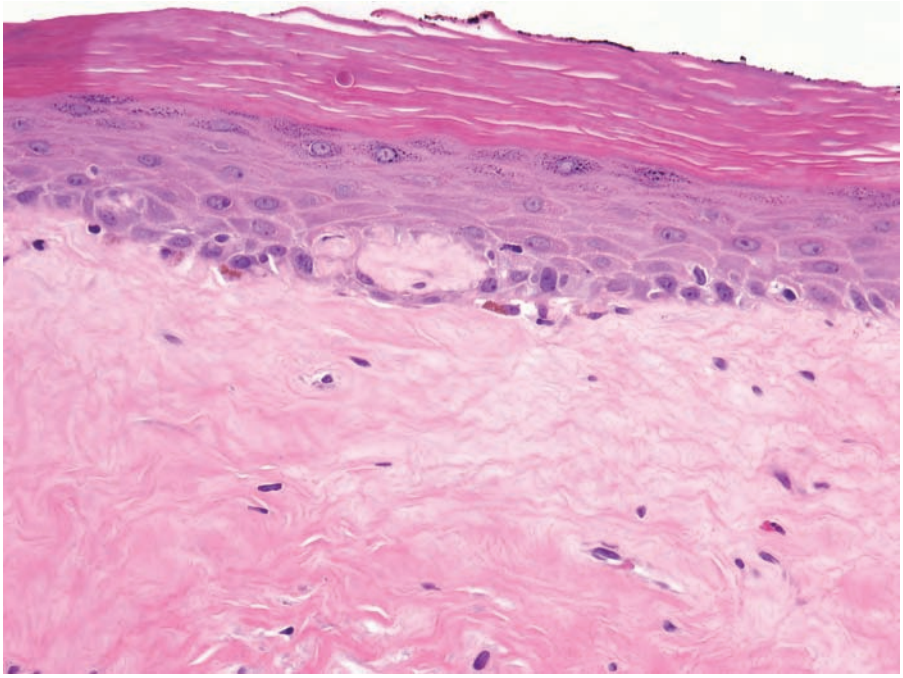

- Hyperkeratosis and lymphocytic infiltrate
- Vacuolar change at dermoepidermal junction
- Pink homogenization of papillary dermis
- Underlying band-like inflammatory infiltrate

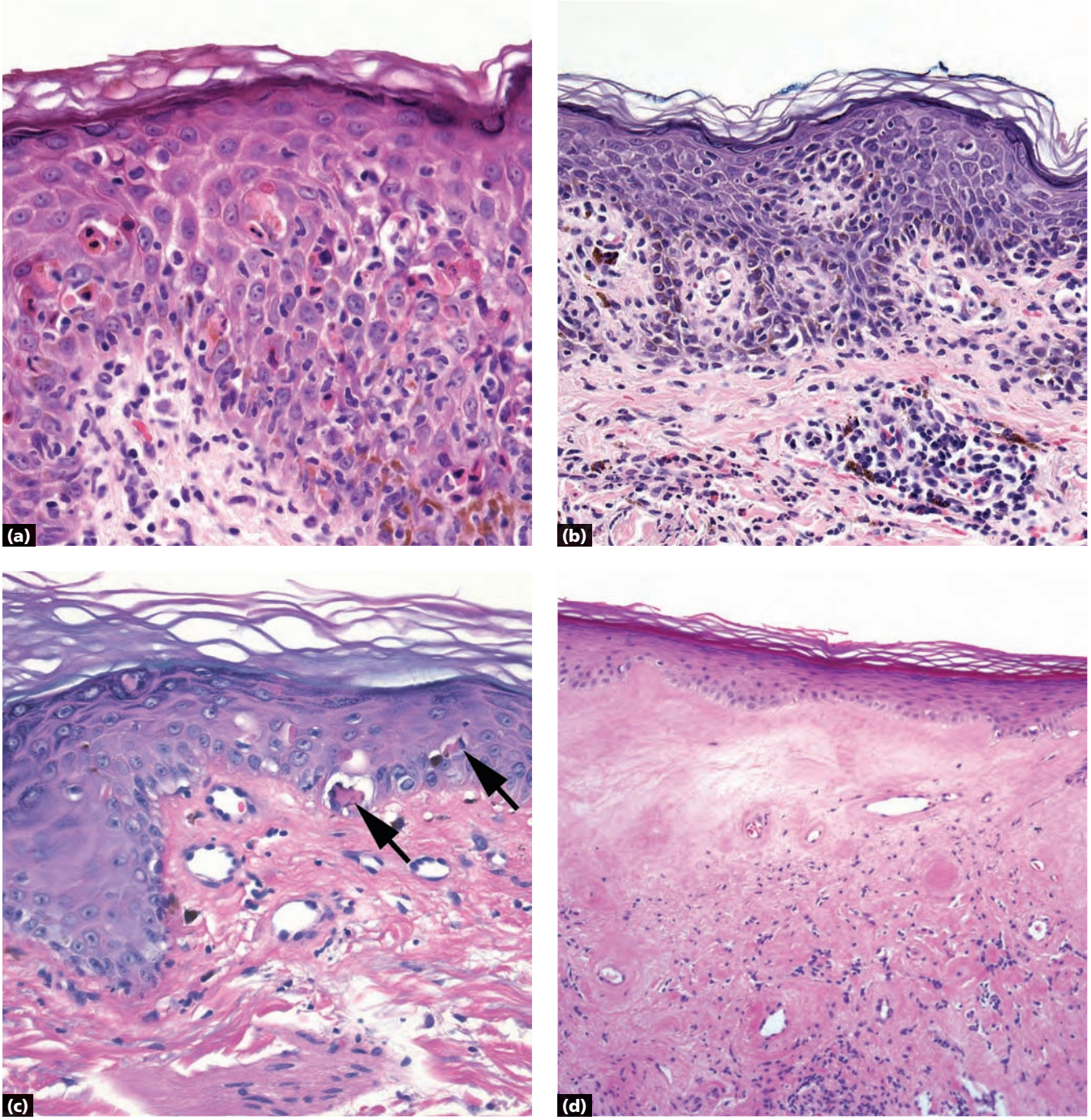

a Erythema multiforme: basket-woven stratum corneum, many necrotic keratinocytes in lower epidermis, superficial perivascular lymphocytes

b Fixed drug eruption: basket-woven stratum corneum, superficial and deep mixed inflammatory infiltrate, pigment incontinence

c Graft-versus-host disease: necrotic keratinocytes involving hair follicles, relatively sparse inflammation

d Lichen sclerosus: hyperkeratosis, hyalinization of superficial dermis, band of lymphocytes below hyalinized dermis

Key differences

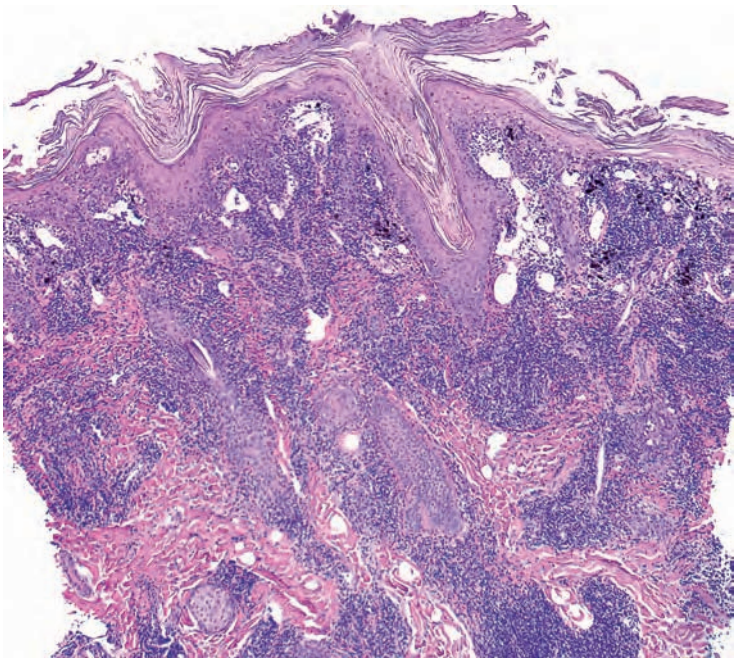

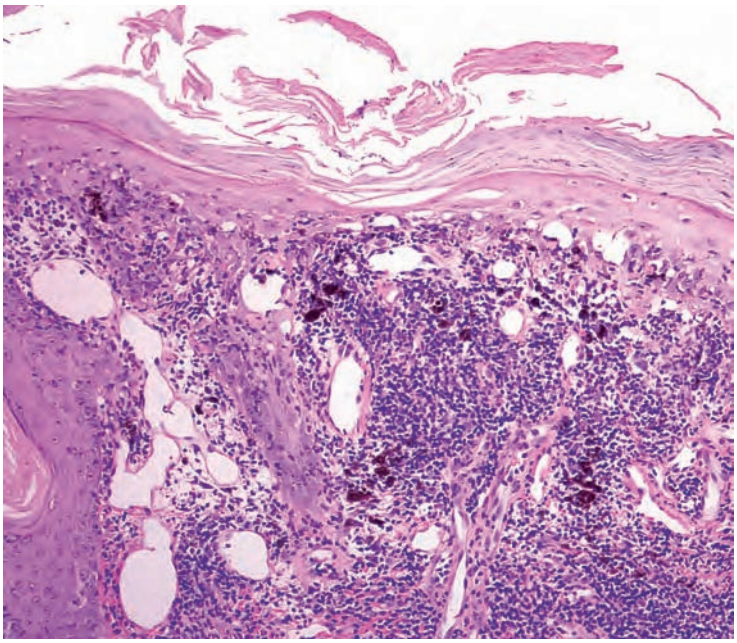

- Lichenoid infiltrate (note: sometimes discoid lupus shows interface vacuolar change)
- Follicular plugging
- Atrophic epidermis
- Thickened basement membrane
- Pigment incontinence
- Periadnexal and perivascular lymphocytic infiltrate

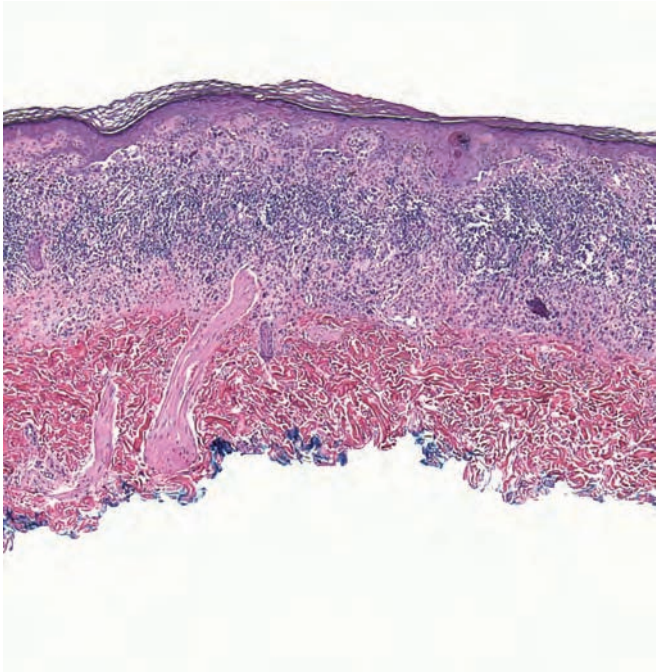

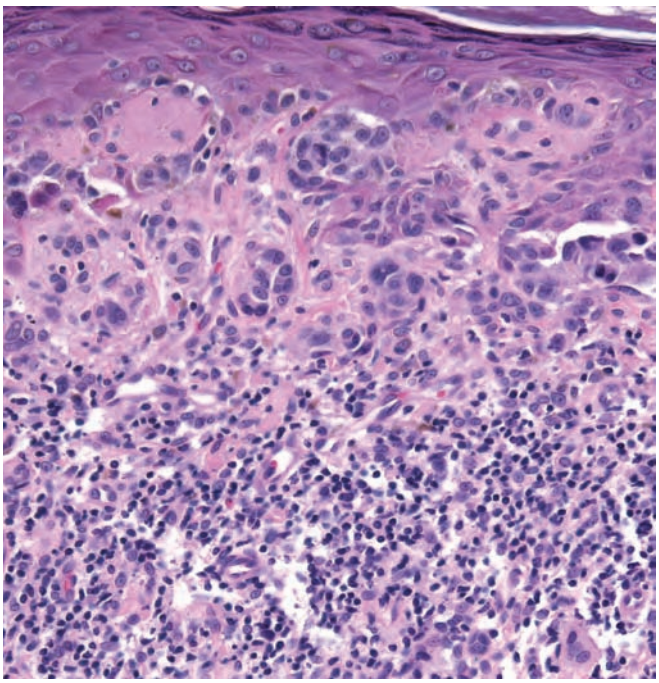

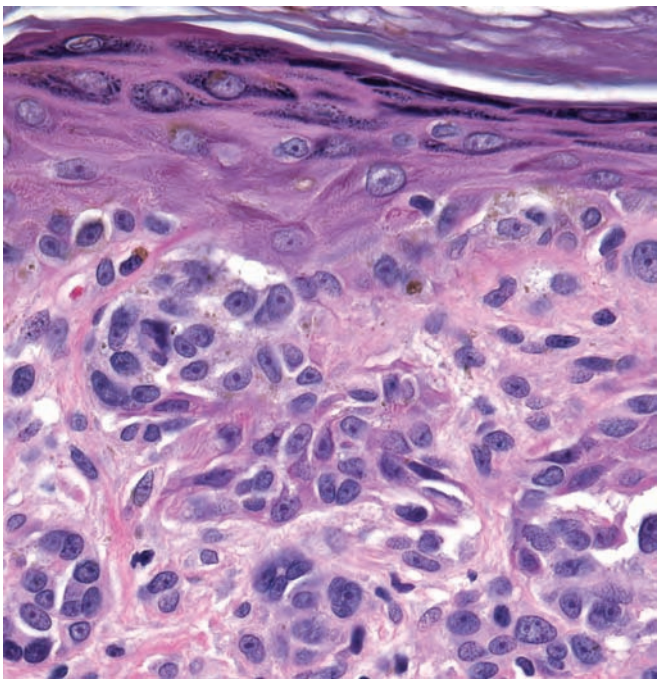

- Lichenoid infiltrate
- Nests of melanocytes at junction and/or in dermis (obscured by lymphocytes)

Halo nevus

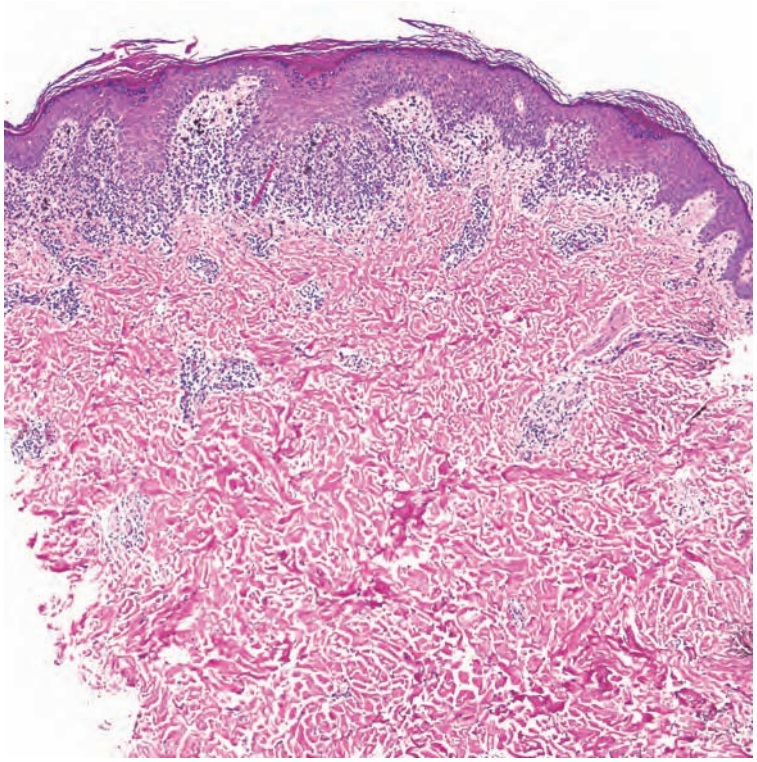

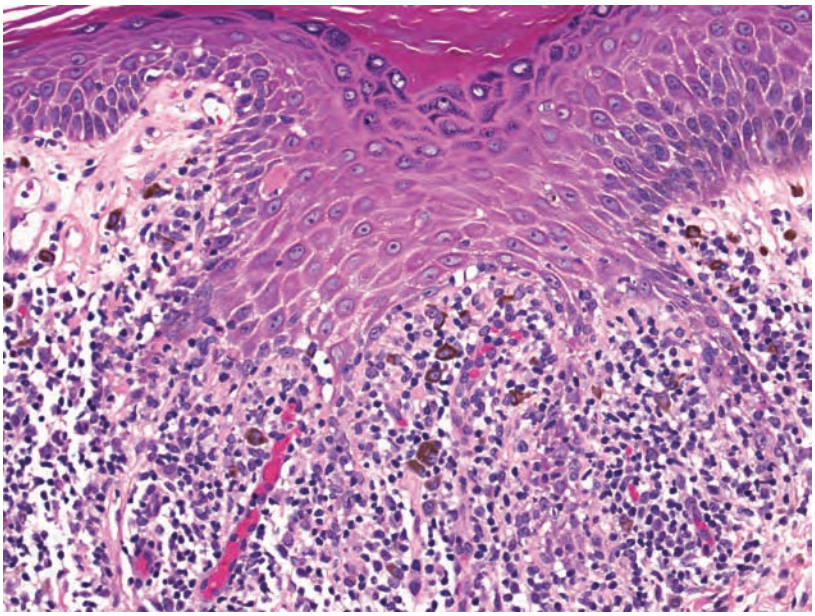

- Lichenoid infiltrate
- Hyperkeratosis, irregular acanthosis, hypergranulosis
- Saw-toothing of basal layer
- Colloid bodies, civatte bodies
- Pigment incontinence
- Usually no eosinophils
- If a mucosal surface, plasma cells may be present

Note Lichenoid drug reactions can look the same but usually show parakeratosis and eosinophils.
Note Benign lichenoid keratosis can look the same (need clinical history).

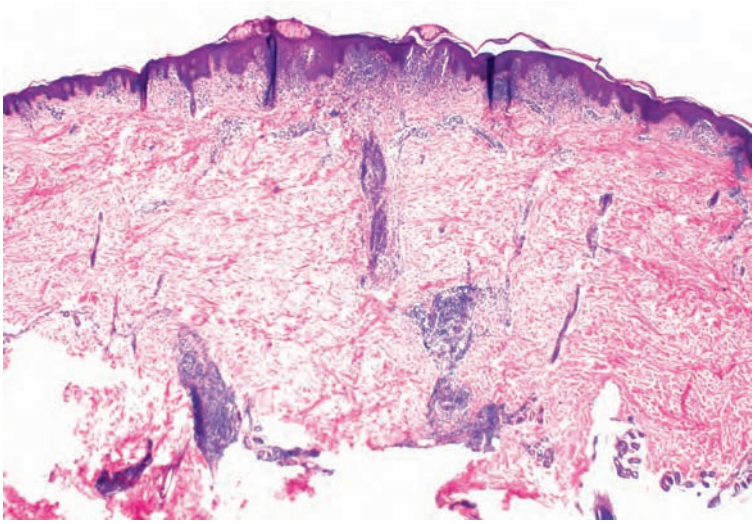

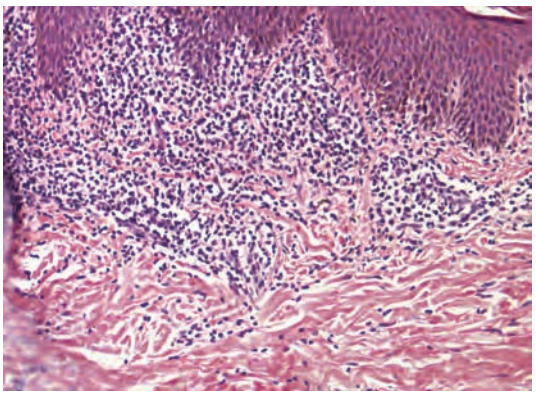

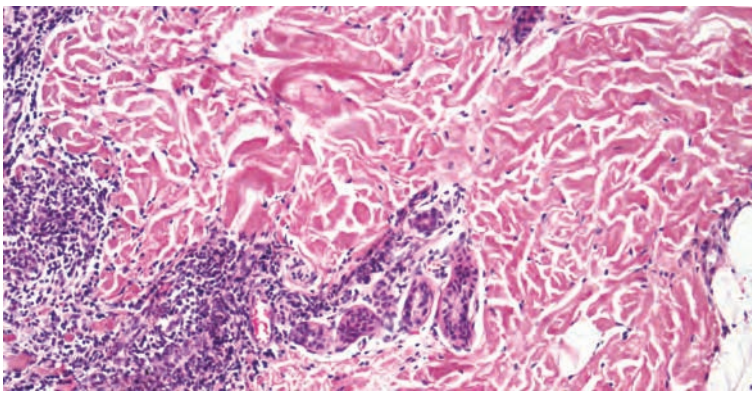

- Patchy lichenoid infiltrate and deep perivascular/periadnexal infiltrate
- Peri-eccrine lymphocytic infiltrate is a clue

Lichen striatus

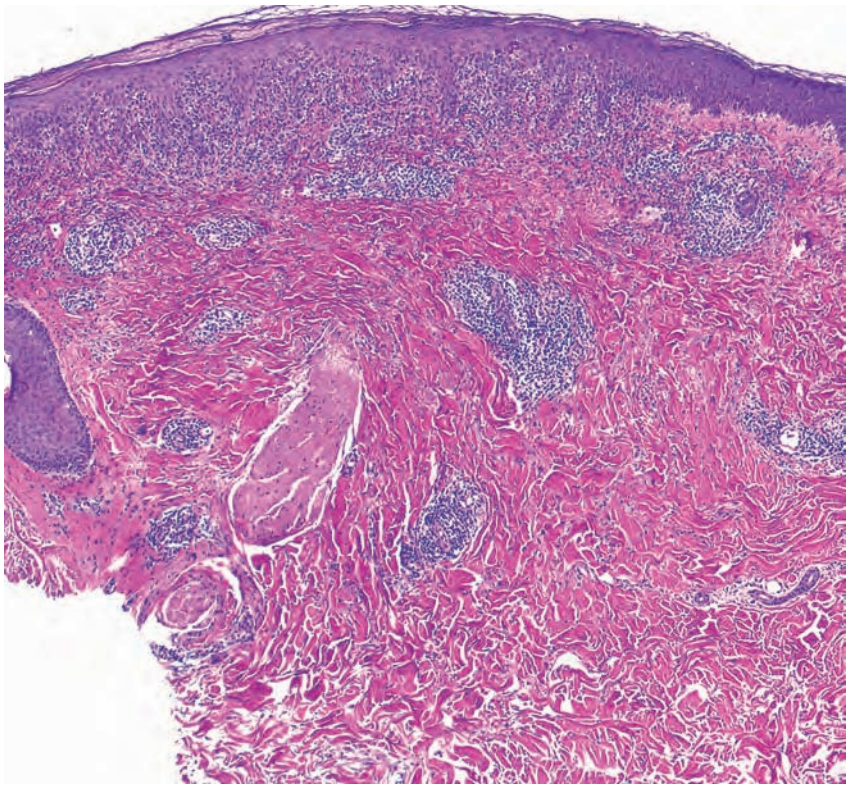

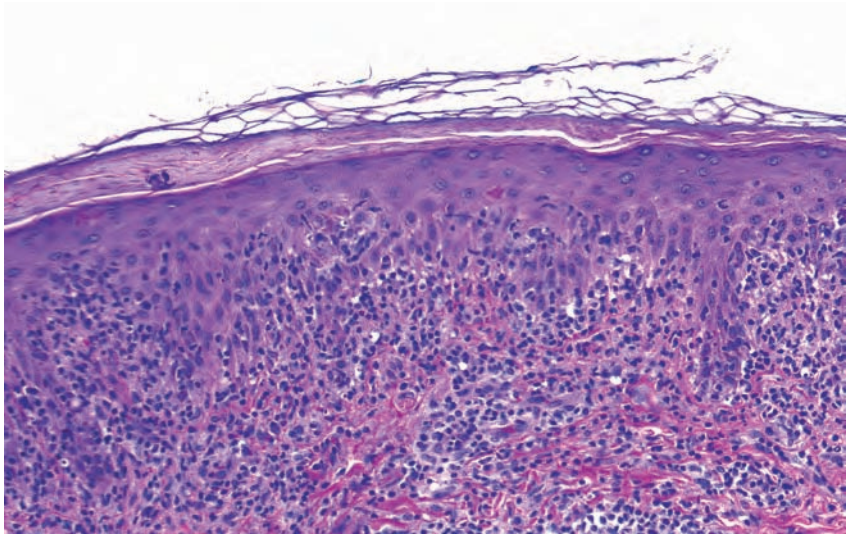

- Lichenoid and deep perivascular lymphocytic infiltrate (wedge-shaped on low power)
- If plasma cells present, consider secondary syphilis
- Parakeratosis
- Erythrocytes in the epidermis and extravasated in the dermis
- Necrosis of the epidermis

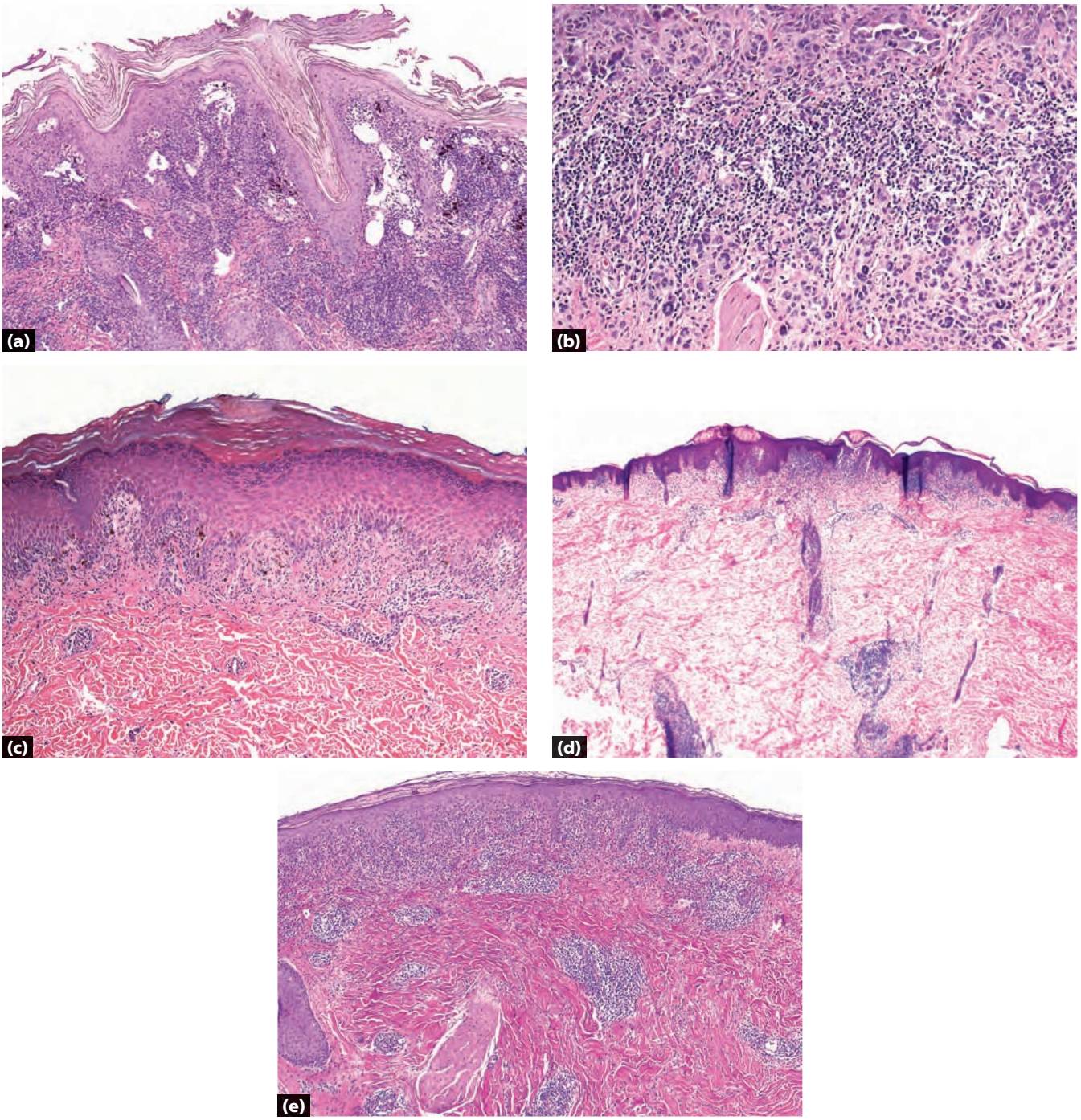

a Discoid lupus erythematosus: hyperkeratosis, epidermis may be atropic, thickened basement membrane, superficial and deep lymphocytic infiltrate

b Halo nevus: melanocytes present but obscured by lymphocytes

c Lichen planus: hyperkeratosis, hypergranulosis, acanthosis, irregular base of epidermis, heavy band of lymphocytes obscuring the epidermal base

d Lichen striatus: some spongiosis may be present, lymphocytes in the papillary dermis as well as in the deeper dermis around follicles and eccrine glands

e Pityriasis lichenoides et varioliformis acuta: parakeratosis, erythrocytes in epidermis and papillary dermis, lymphocytes peppering the base of the epidermis, superficial and deep lymphocytic infiltrate

Key differences

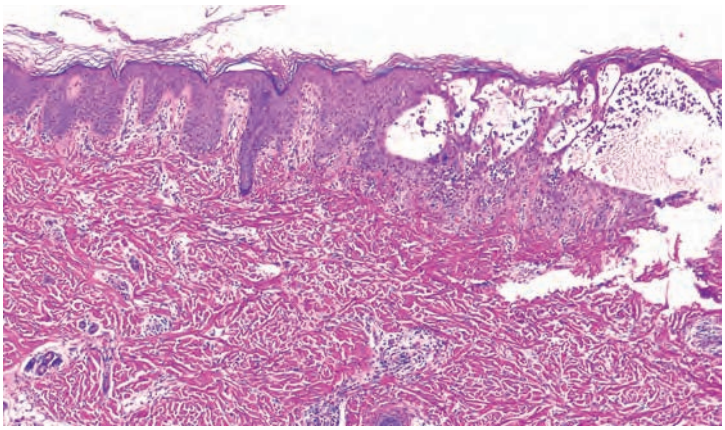

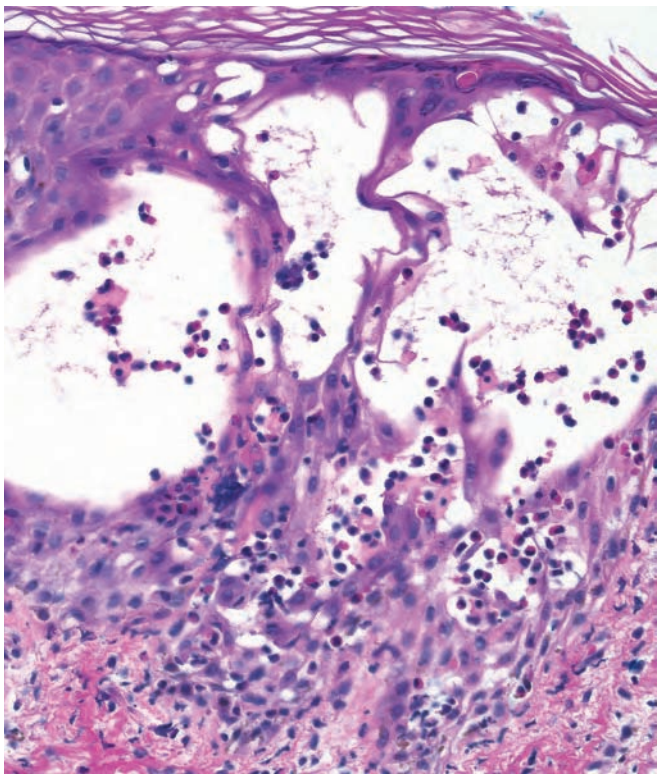

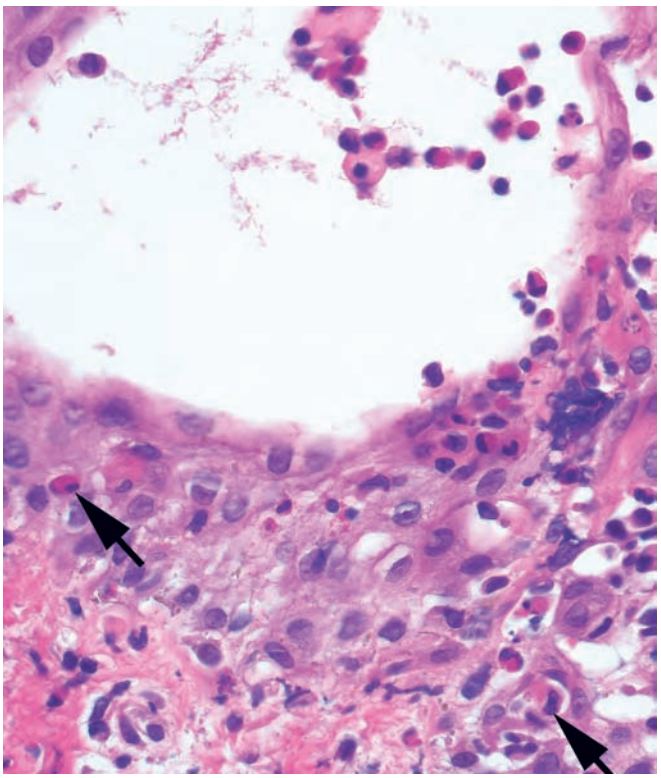

- Epidermal eosinophils
- Dyskeratotic keratinocytes in addition to eosinophils (arrows)

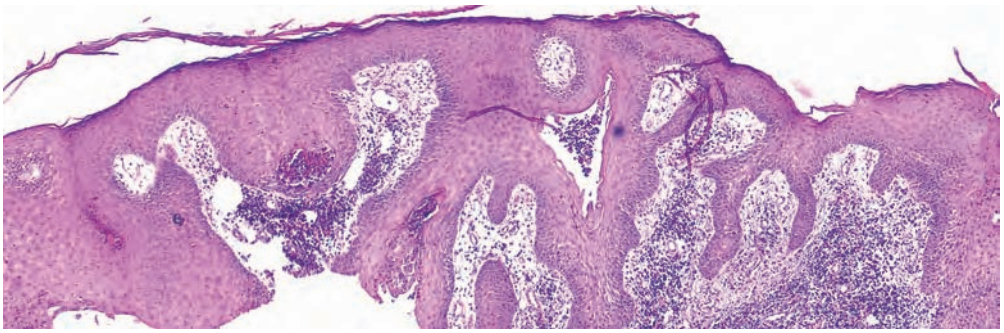

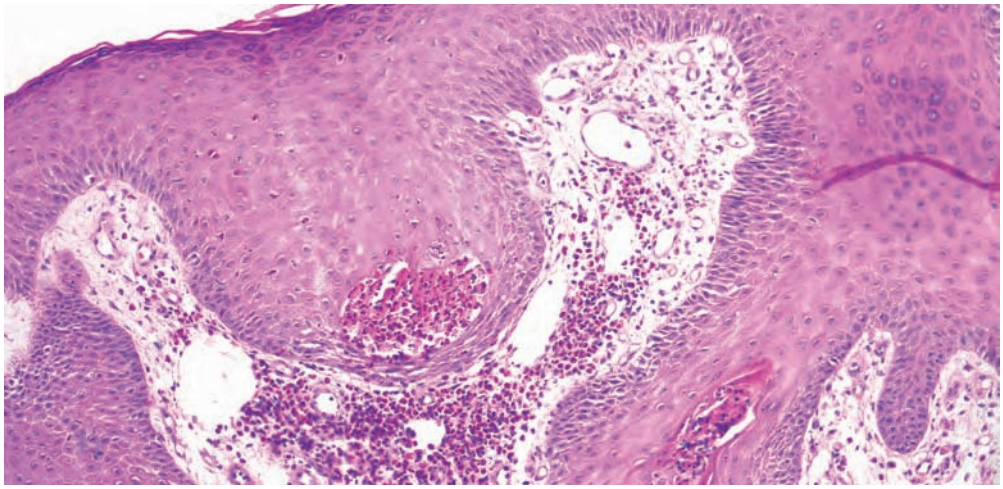

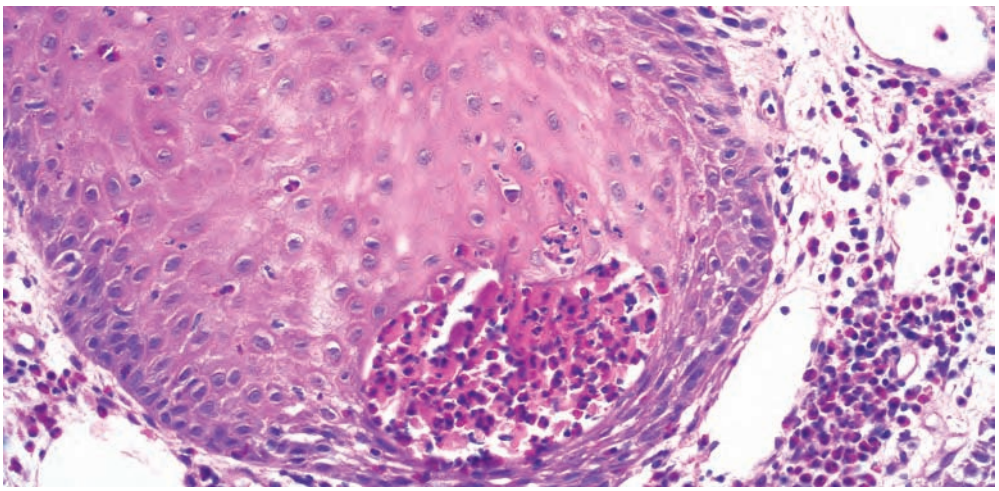

- Eosinophilic abscesses within epidermis
- Acantholysis may be absent to subtle
- Hyperplastic epidermis

Pemphigus vegetans

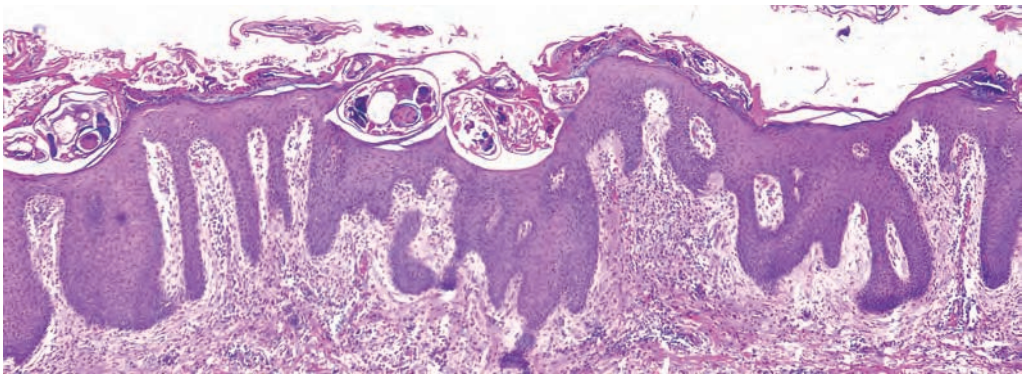

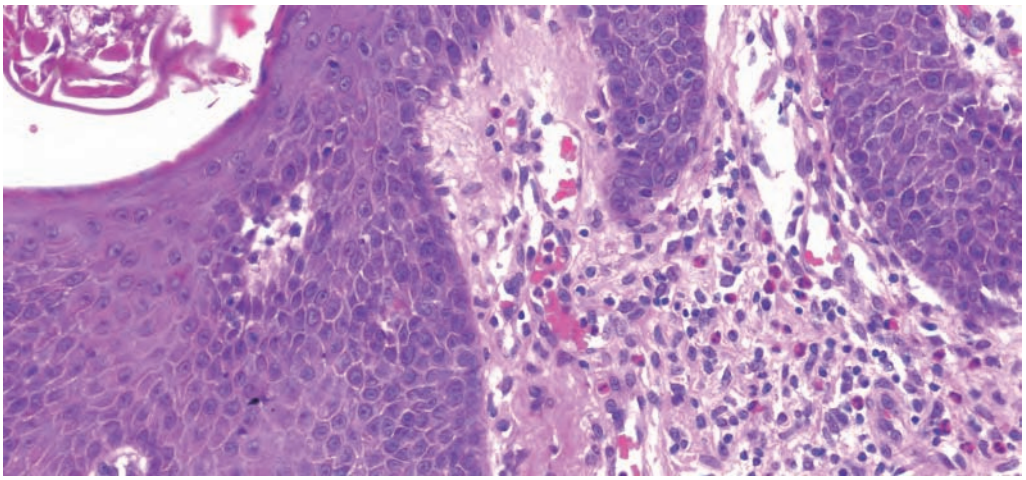

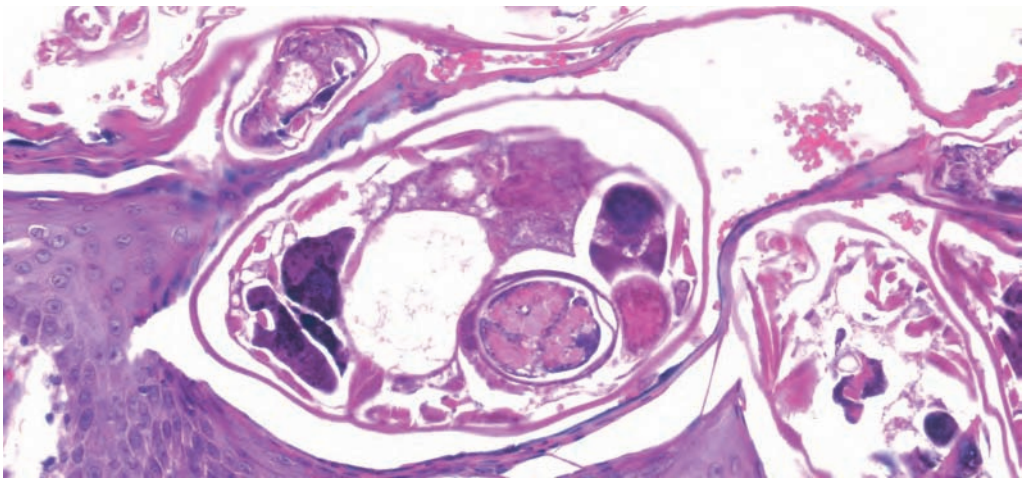

- Epidermal eosinophils
- Mites, scybala, eggs within stratum corneum

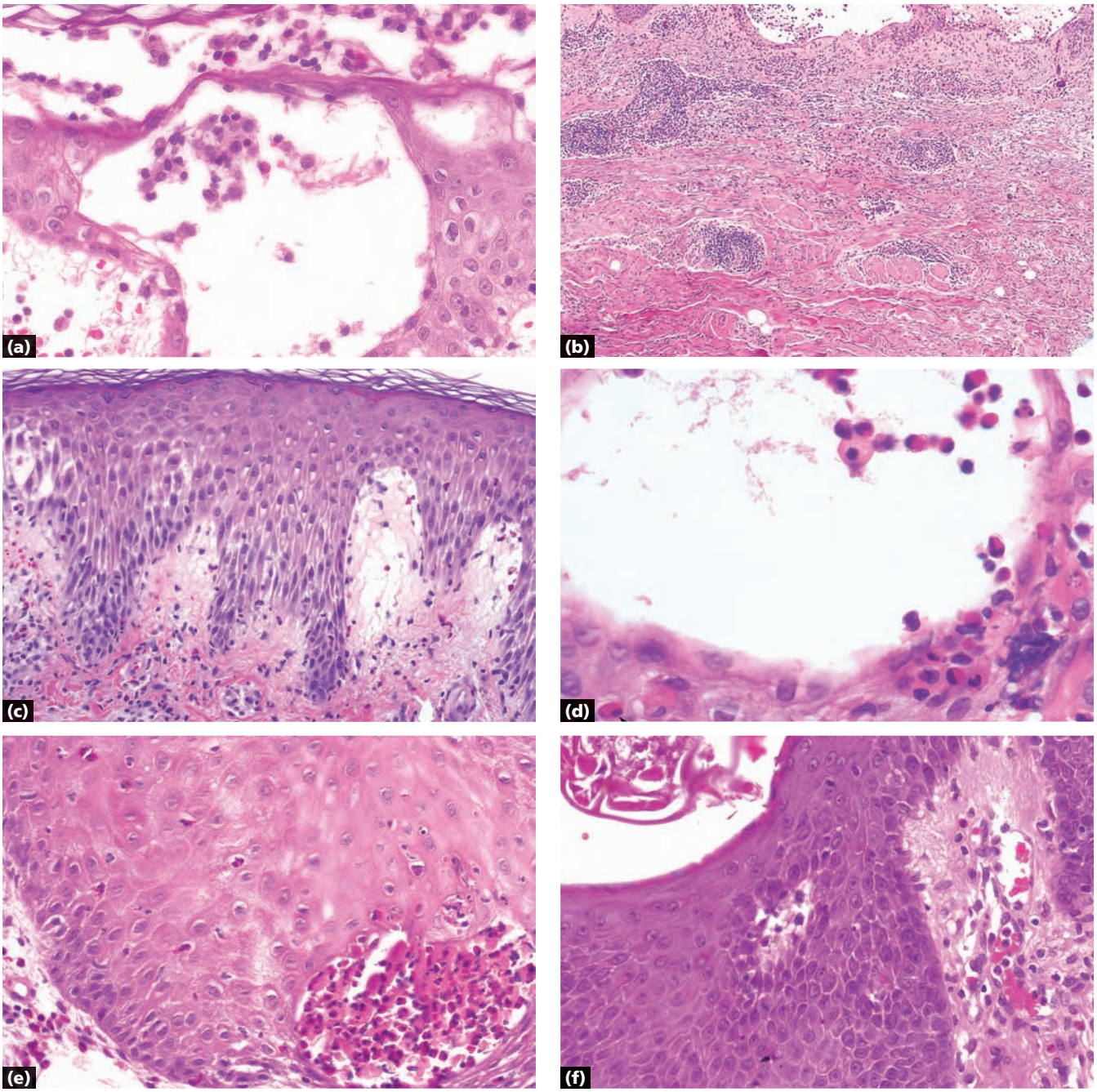

a Allergic contact dermatitis: orderly vesicles and eosinophils in epidermis (see page 102)
b Arthropod bite reaction: prominent vesicles and eosinophils in epidermis, may see an erosion, wedge-shaped infiltrate (see page 103)
c Bullous pemphigoid: subepidermal cleft and eosinophils at base (see page 249)
d Incontinentia pigmenti: eosinophilic spongiosis with dyskeratotic cells
e Pemphigus vegetans: eosinophilic abscesses within acanthotic epidermis
f Scabies: mites/scybala/eggs in stratum corneum

Key differences

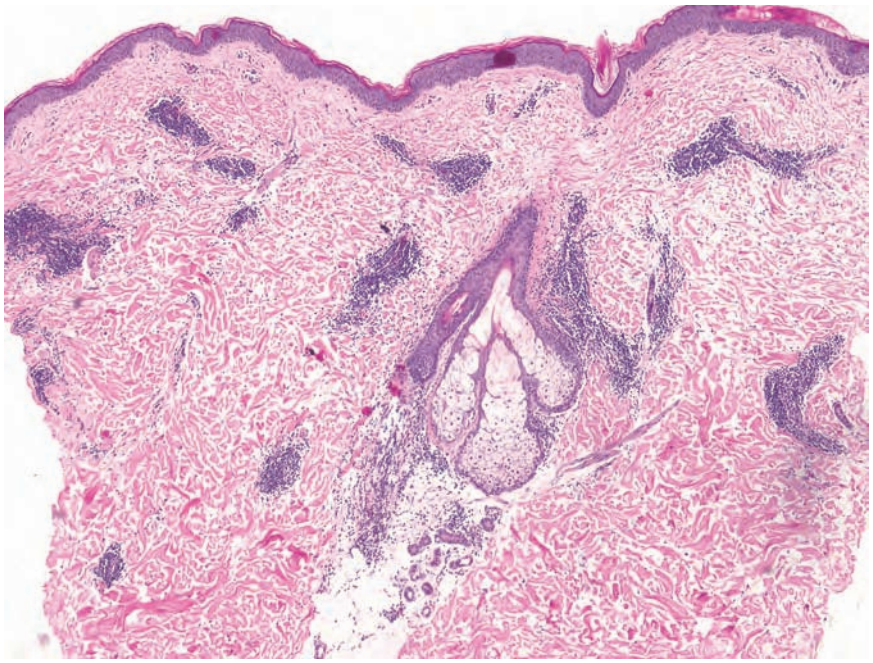

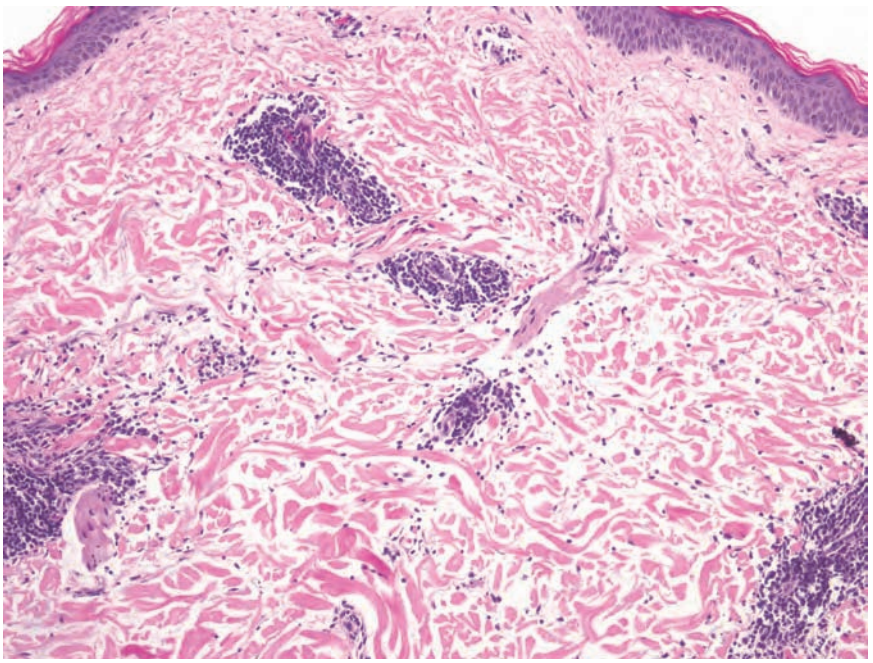

- Superficial and deep perivascular infiltrate of lymphocytes
- Lymphocytes tightly cuffed around vessels

Note Differential includes polymorphous light eruption (classically has dermal edema), Jessner's lymphocytic infiltrate, and connective tissue disorders.

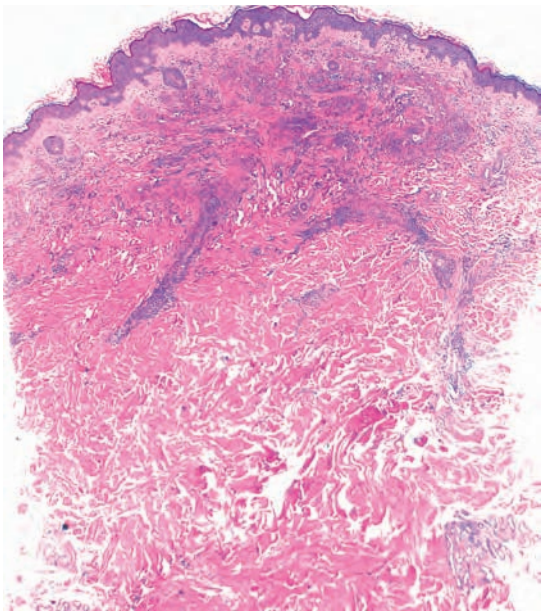

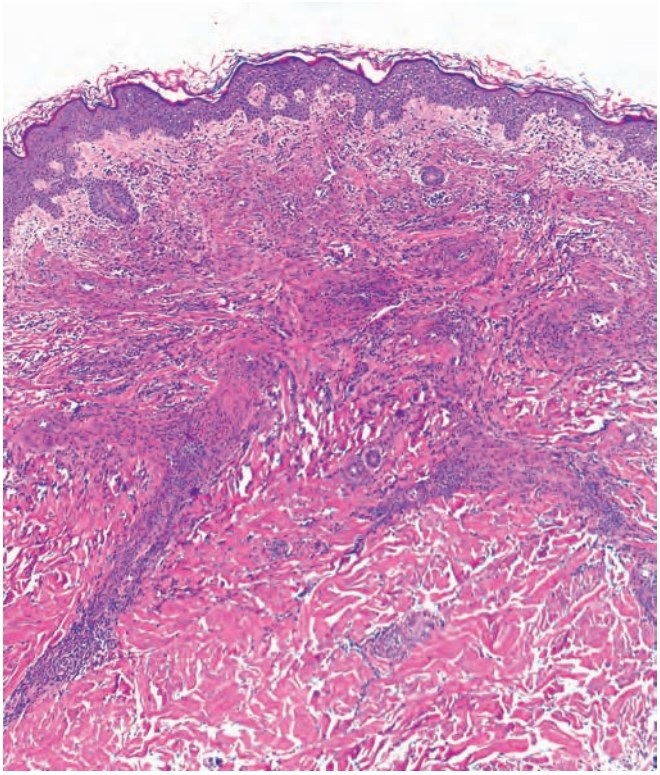

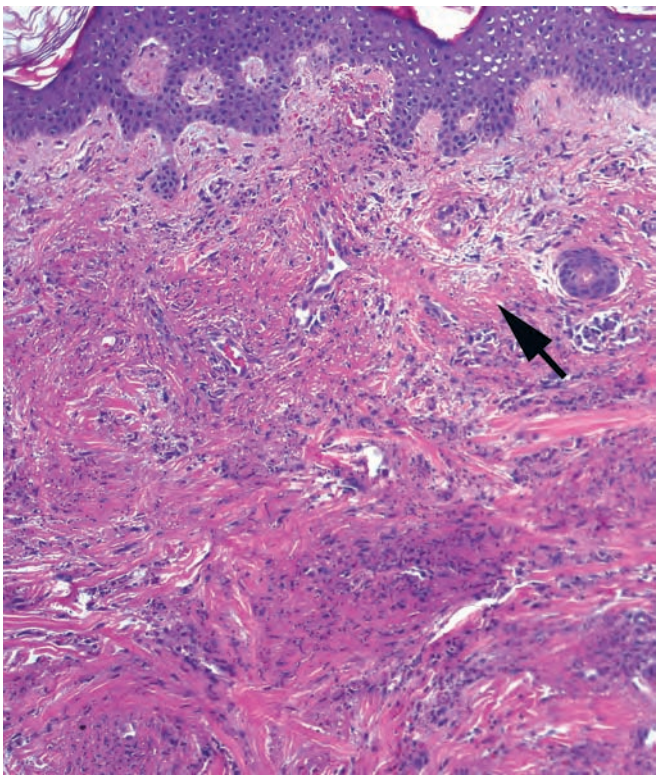

- Perivascular infiltrate of neutrophils and nuclear debris
- Alteration/necrosis of collagen (arrow)
- Extravasated erythrocytes
- Fibrin around vessels

Leukocytoclastic vasculitis

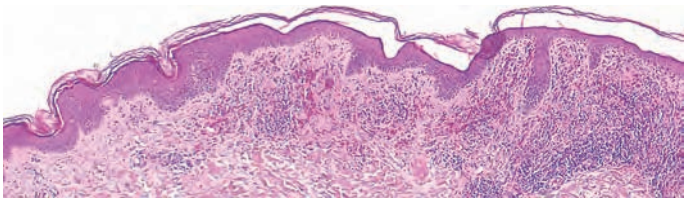

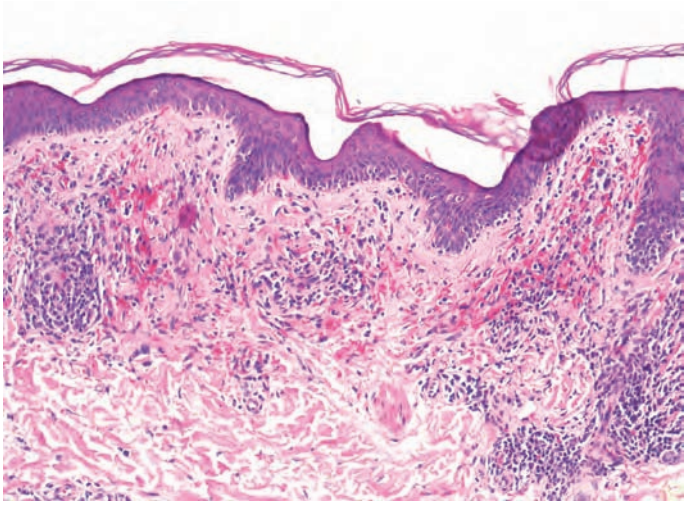

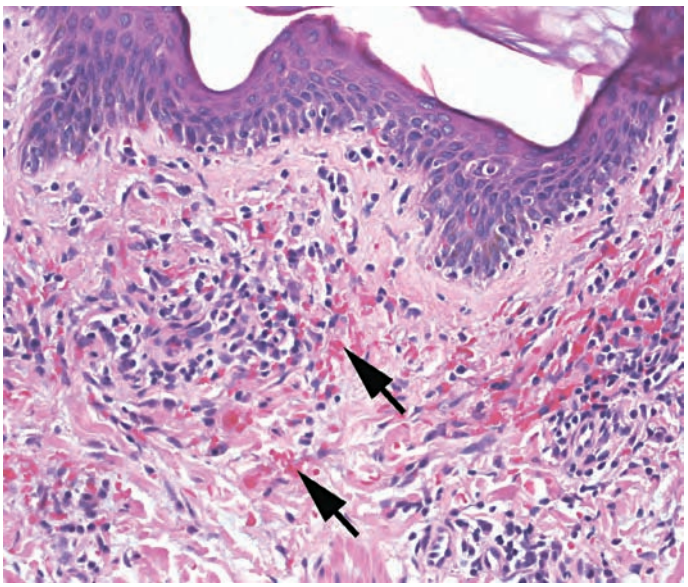

- Superficial perivascular infiltrate of lymphocytes (sometimes minimal)
- Extravasated erythrocytes (arrows)
- Hemosiderophages

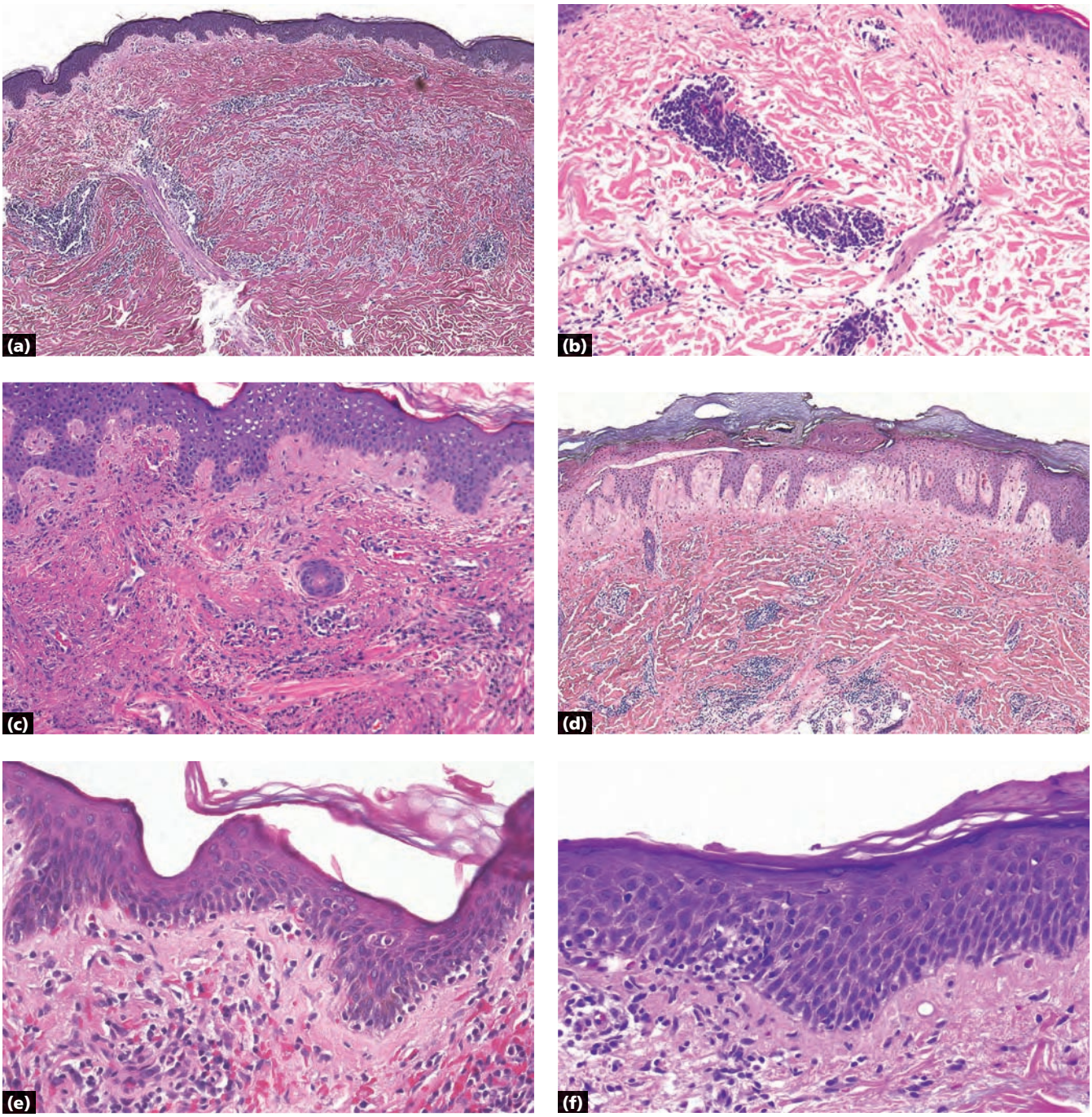

a Granuloma annulare: perivascular lymphocytes; interstitial/palisaded histiocytes around mucin (see page 89)
b Gyrate erythema: tightly cuffed superficial and deep perivascular infiltrate of lymphocytes, epidermis is normal
c Leukocytoclastic vasculitis: dermis looks "messy" on low power with perivascular neutrophils and nuclear debris, pink donuts of degenerated collagen, extravasated erythrocytes
d Perniosis: superficial and deep perivascular lymphocytes, perieccrine lymphocytes are a clue
e Pigmented purpuric dermatosis: perivascular (to lichenoid) infiltrate of lymphocytes, extravasated erythrocytes, hemosiderophages
f Pityriasis rosea: mounds of parakeratosis, mild epidermal spongiosis, superficial perivascular infiltrate of lymphocytes. extravasated erythrocytes (see page 104)

Key differences

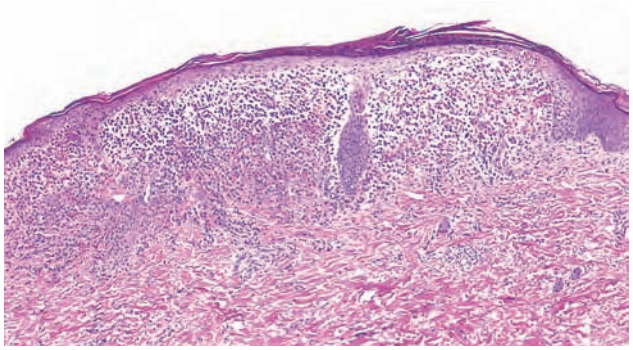

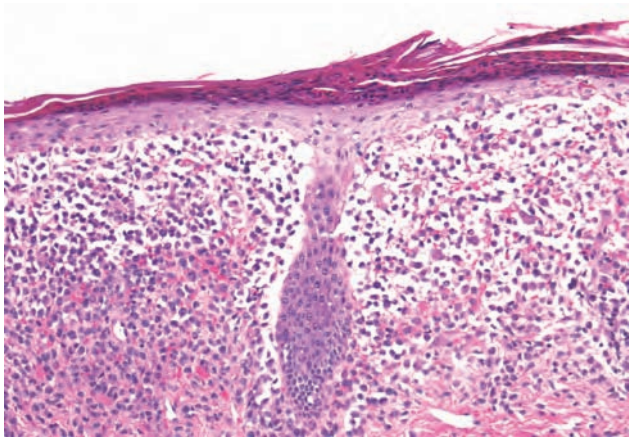

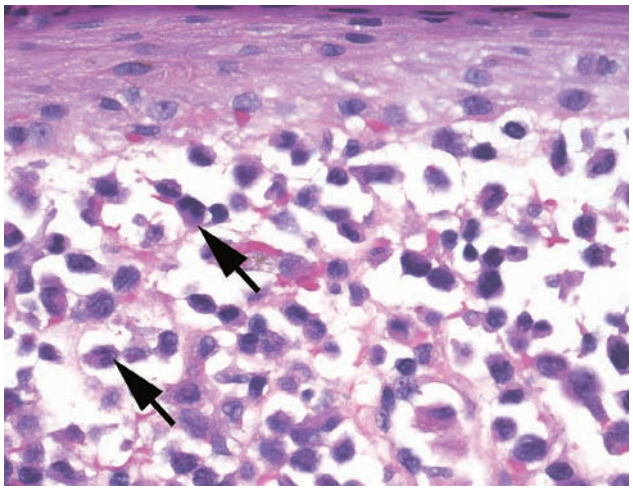

- Band-like upper dermal infiltrate
- Infiltrate abuts and involves epidermis
- Cells in infiltrate have kidney-shaped or coffee been (clefted) nuclei (arrows)
- Eosinophils may be present

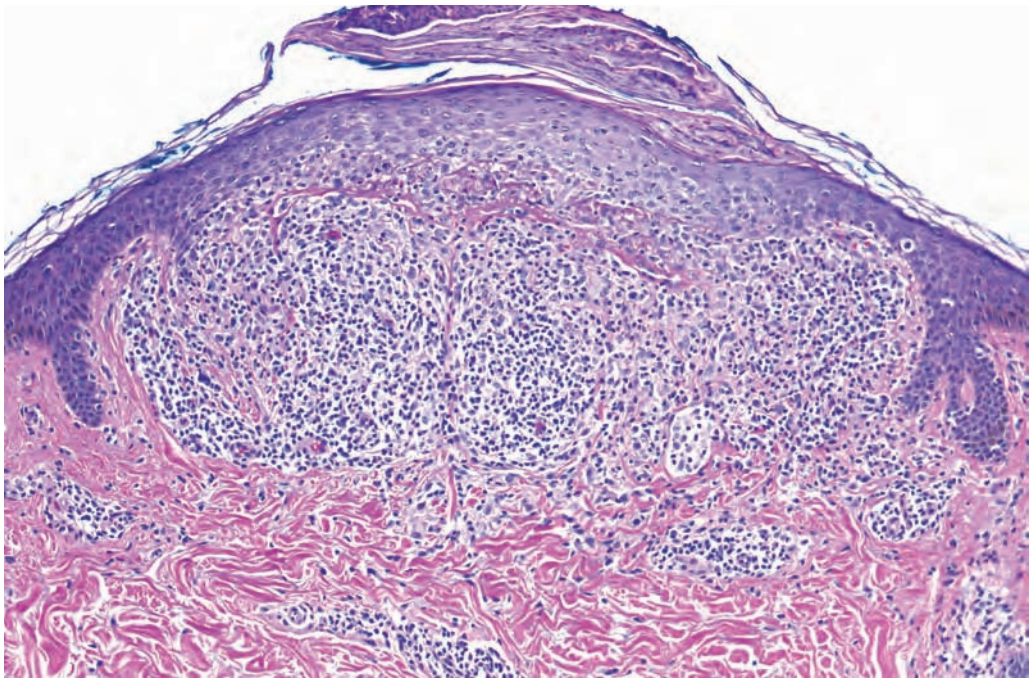

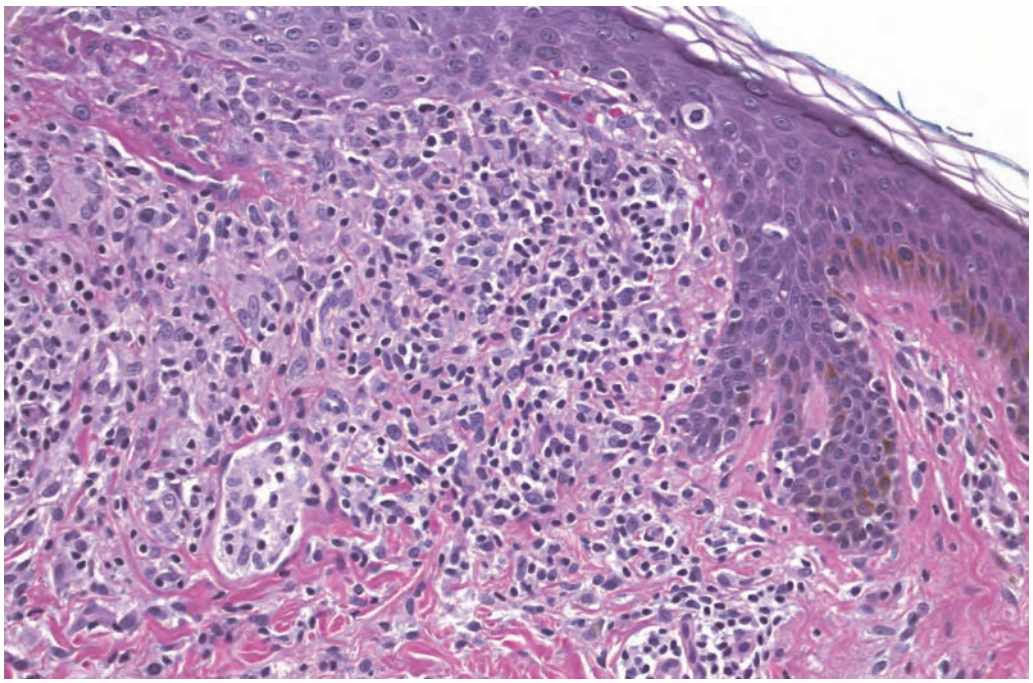

- Lichenoid infiltrate that is the "ball" being held by fingers of epidermis (the "claw")
- Infiltrate is composed of lymphocytes and histiocytes and occasional giant cells

Lichen nitidus

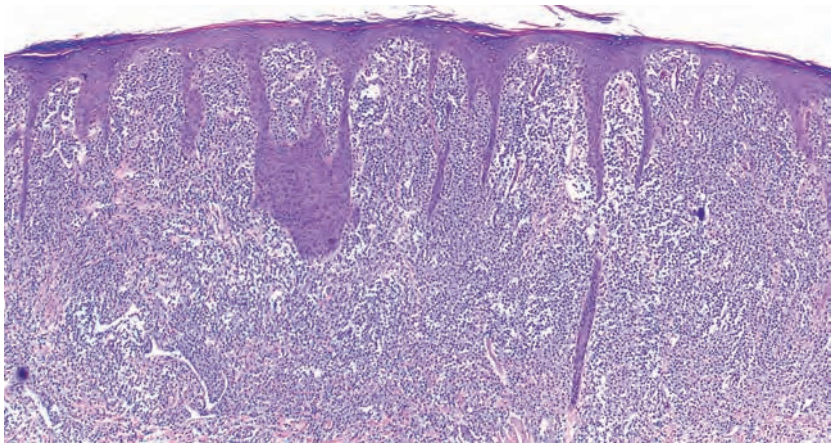

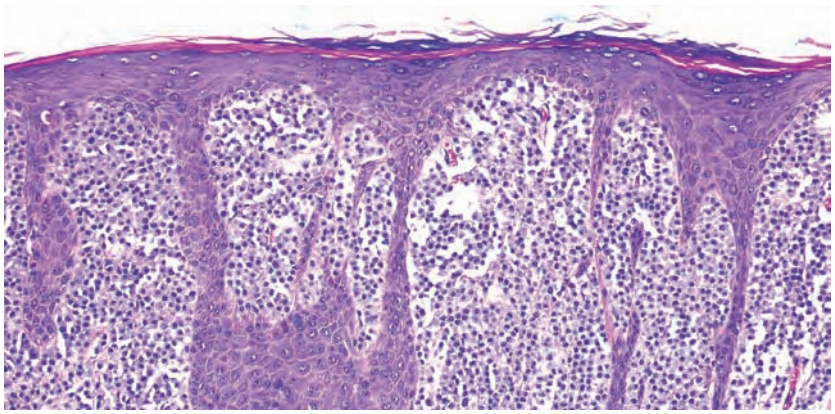

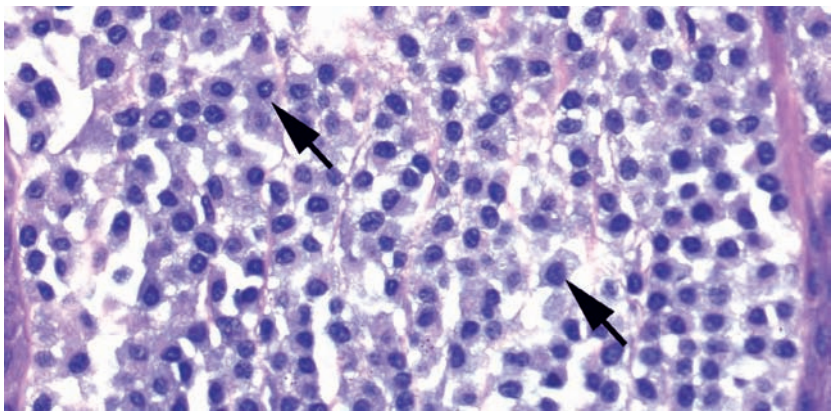

- Band-like upper dermal infiltrate (or sometimes perivascular or nodular)
- A small grenz zone is usually present
- Cells in infiltrate have round nuclei and granular gray-blue cytoplasm (arrows)
- Eosinophils may be present

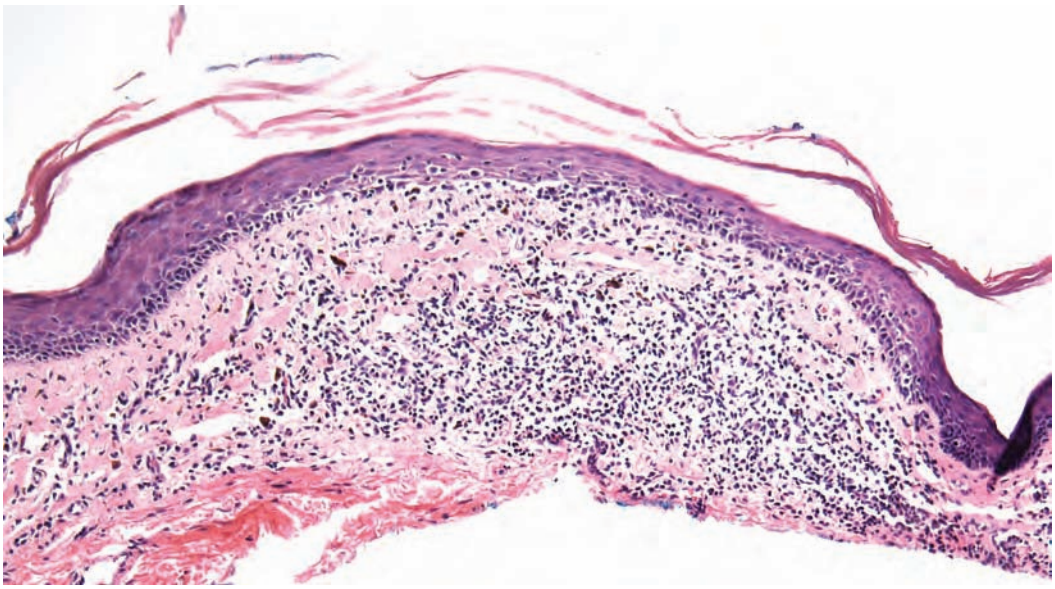

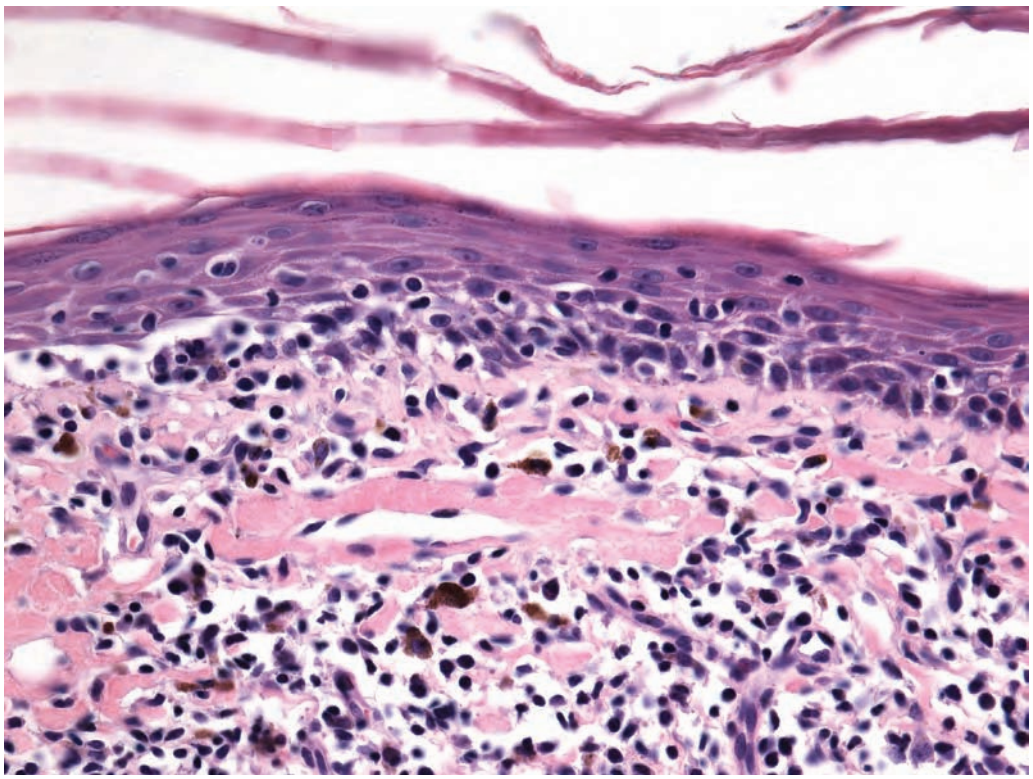

- Band-like upper dermal infiltrate
- Infiltrate abuts and involves epidermis
- May see Pautrier's microabscesses
- Hyperchromatic lymphocytes
- Hyalinized papillary dermis

Mycosis fungoides

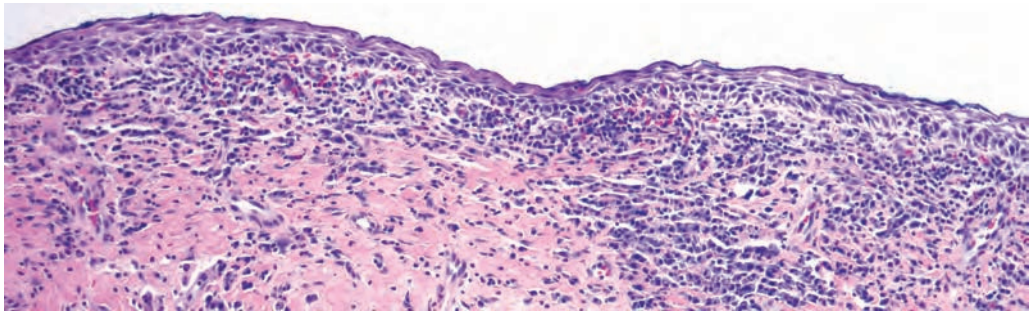

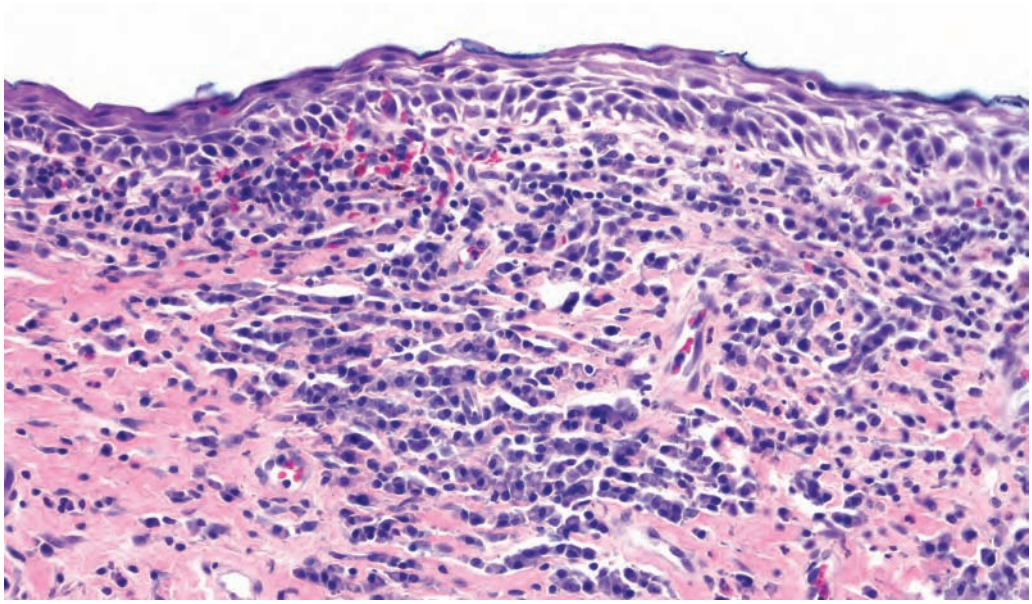

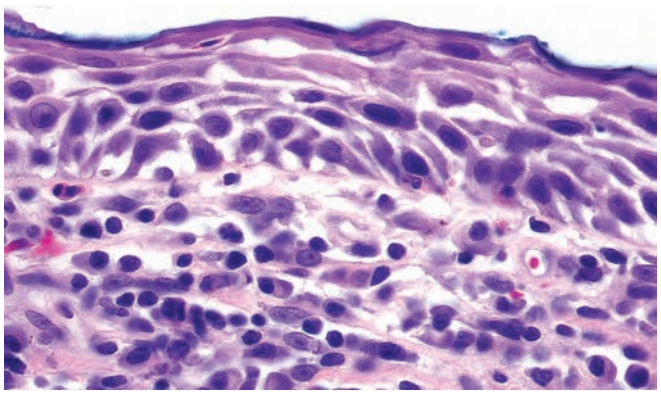

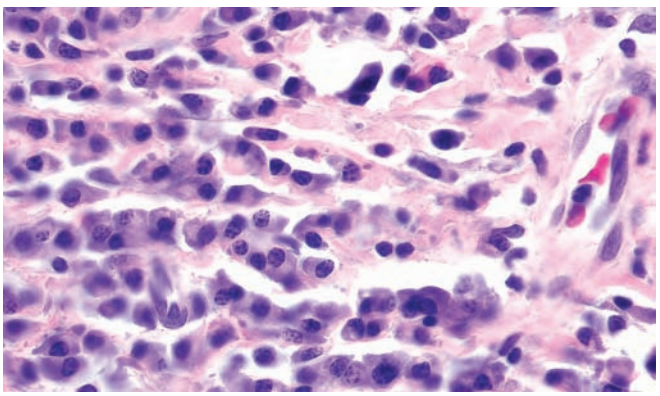

- Band-like upper dermal infiltrate
- Atrophic epidermis of diamond-shaped keratinocytes with intercellular edema
- Dermal infiltrate of plasma cells

Zoon balanitis (balantis circumscripta plasmacellularis)

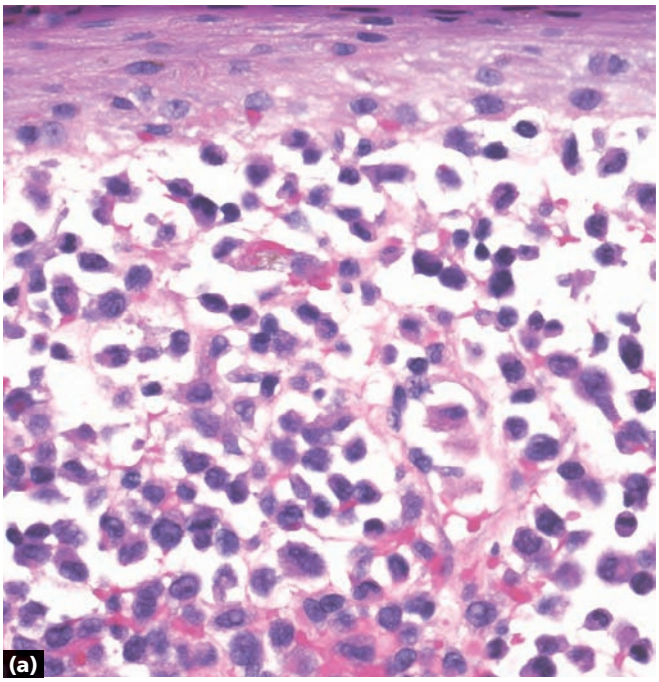

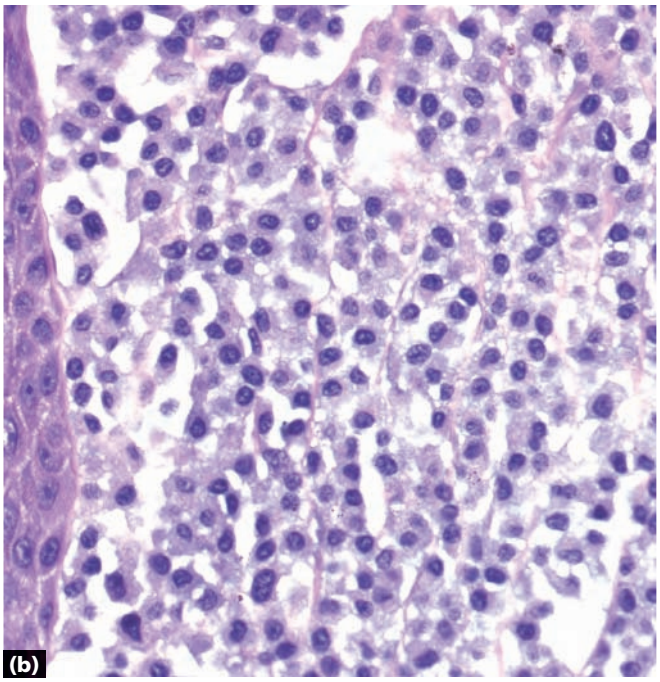

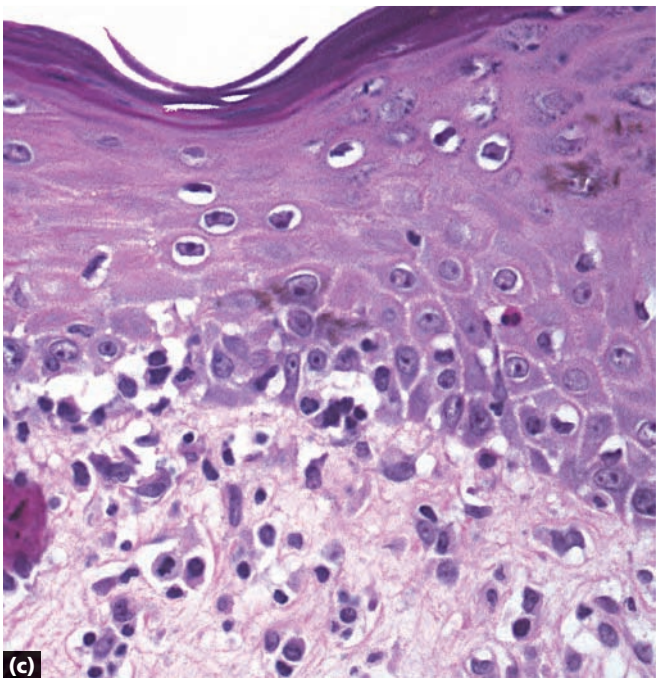

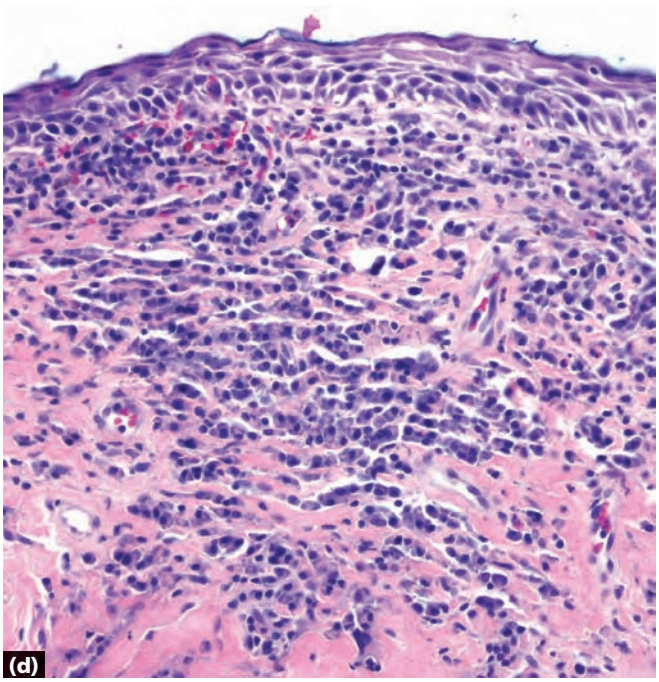

a Langerhans cell histiocytosis: kidney-shaped nuclei
b Mastocytosis: round nuclei and slightly granular cytoplasm
c Mycosis fungoides: cells in infiltrate have atypical nuclei, vacuolar change, fibrosis in dermis, lining up of lymphocytes at dermoepidermal junction
d Zoon balanitis: diamond-shaped keratinocytes with underlying plasma cells

Key differences

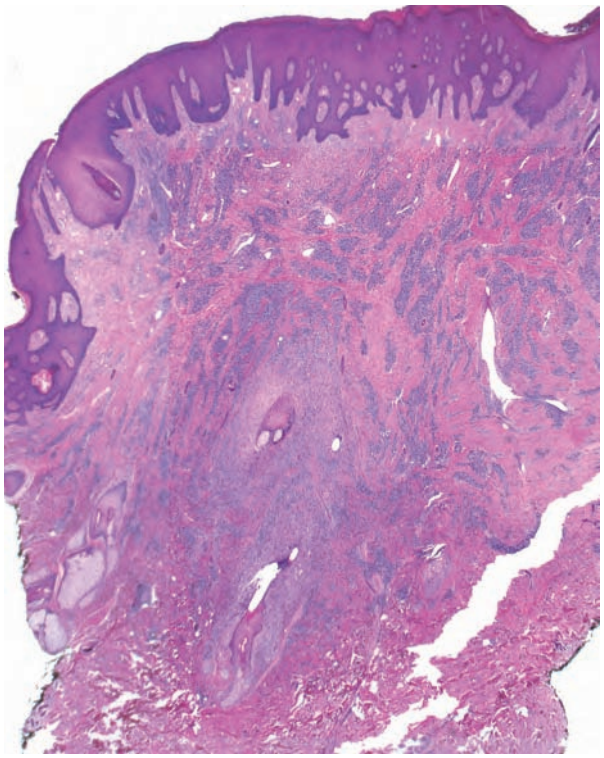

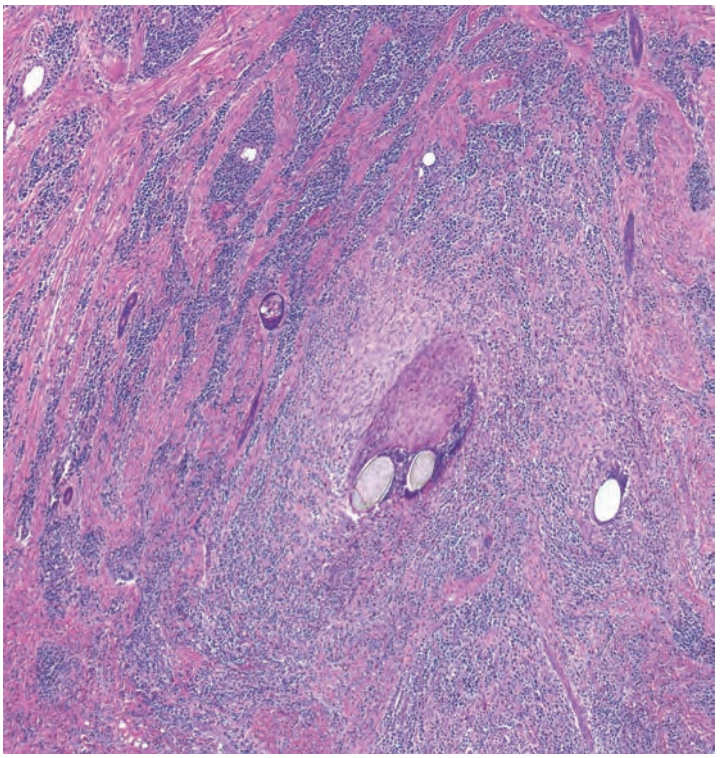

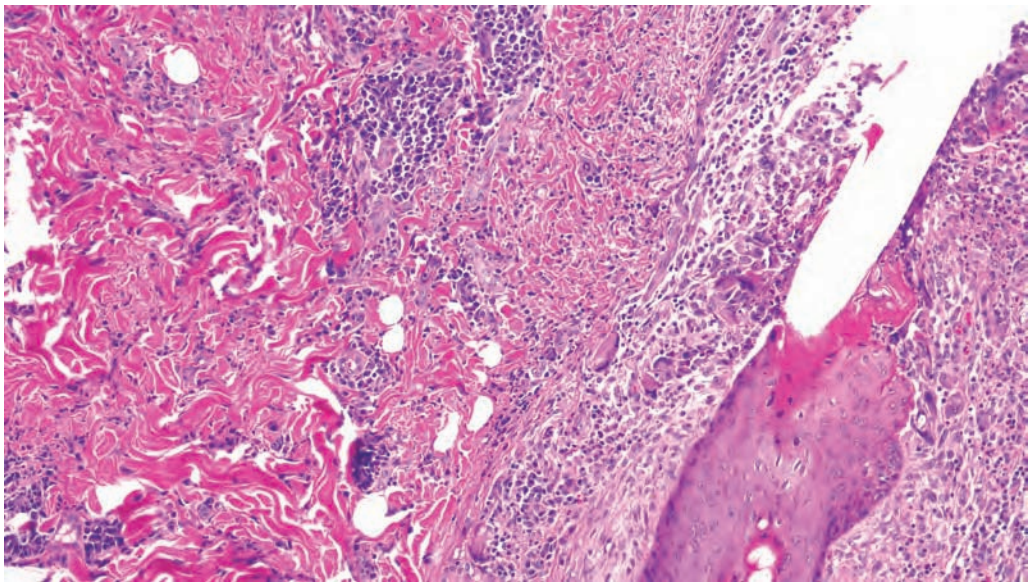

- Blue dense infiltrate
- Lymphoplasmacytic infiltrate surrounds and destroys hair follicles
- Free hair shafts may be seen in the dermis
- Scarring

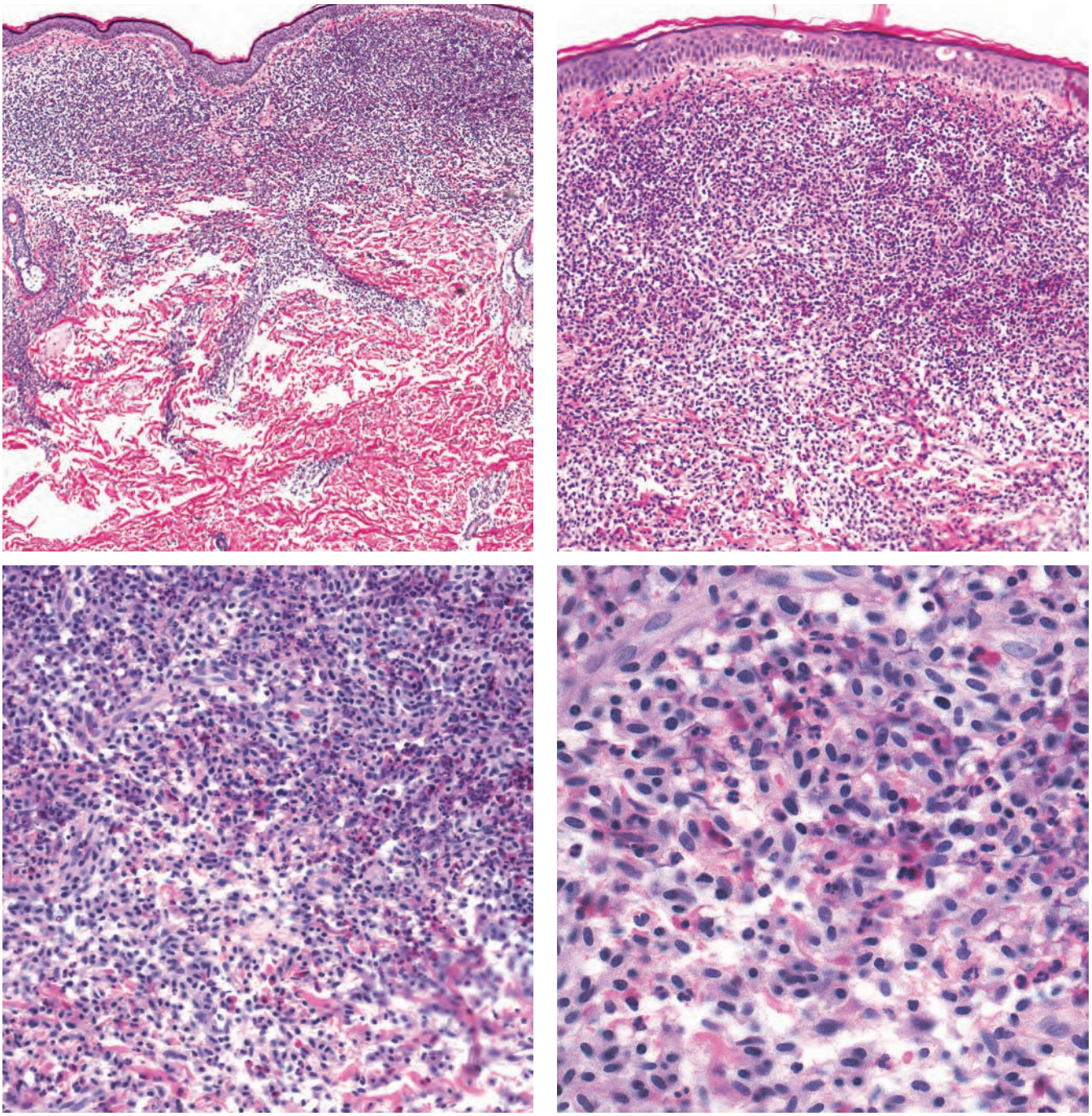

- Blue dense infiltrate
- Grenz zone
- Infiltrate composed of lymphocytes, histiocytes, eosinophils, neutrophils
- Variable presence of vasculitis

Granuloma faciale

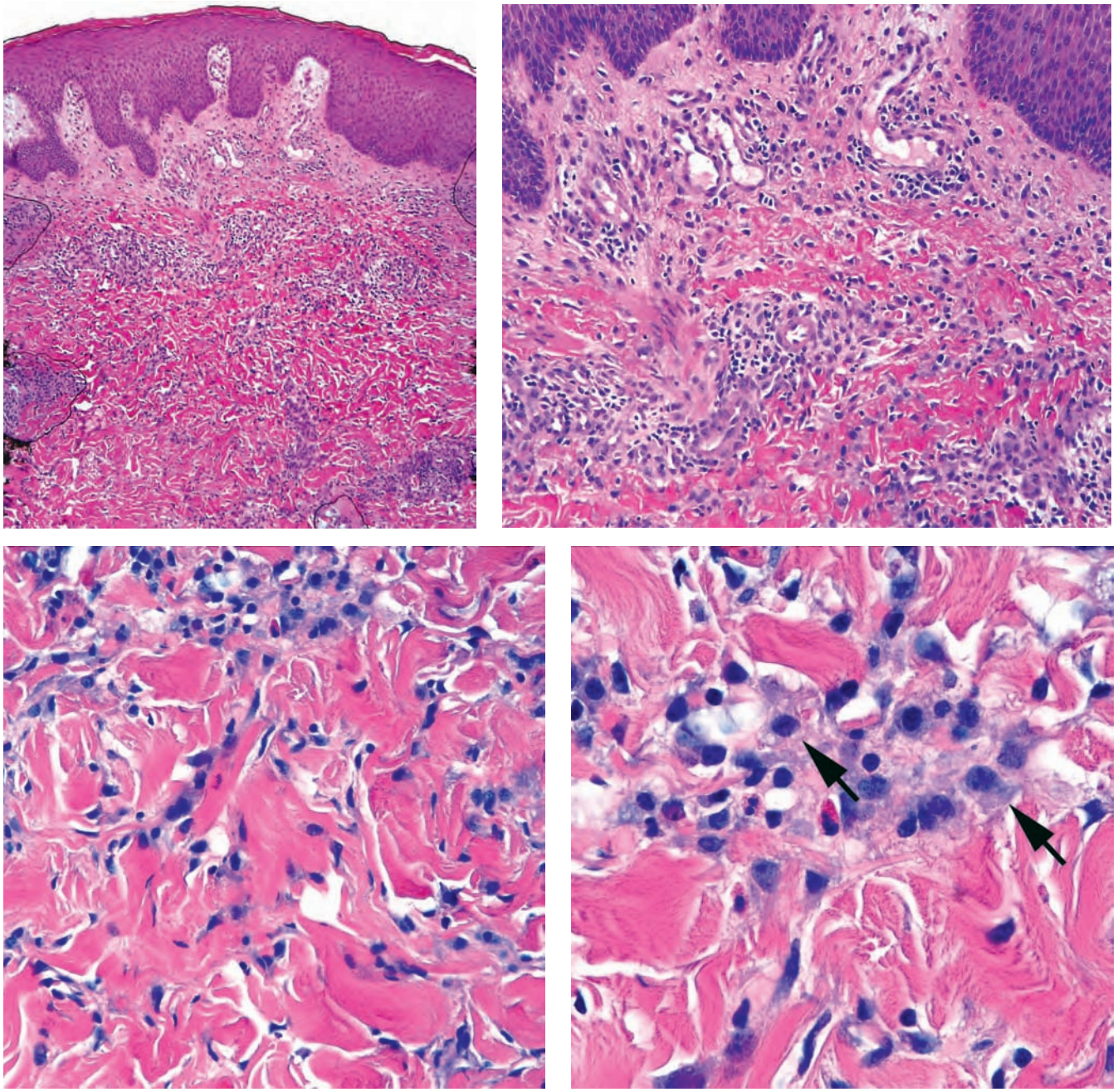

- Blue dense infiltrate
- Infiltrate is perivascular and infiltrating through collagen
- Cells are atypical with slightly granular cytoplasm (arrows)

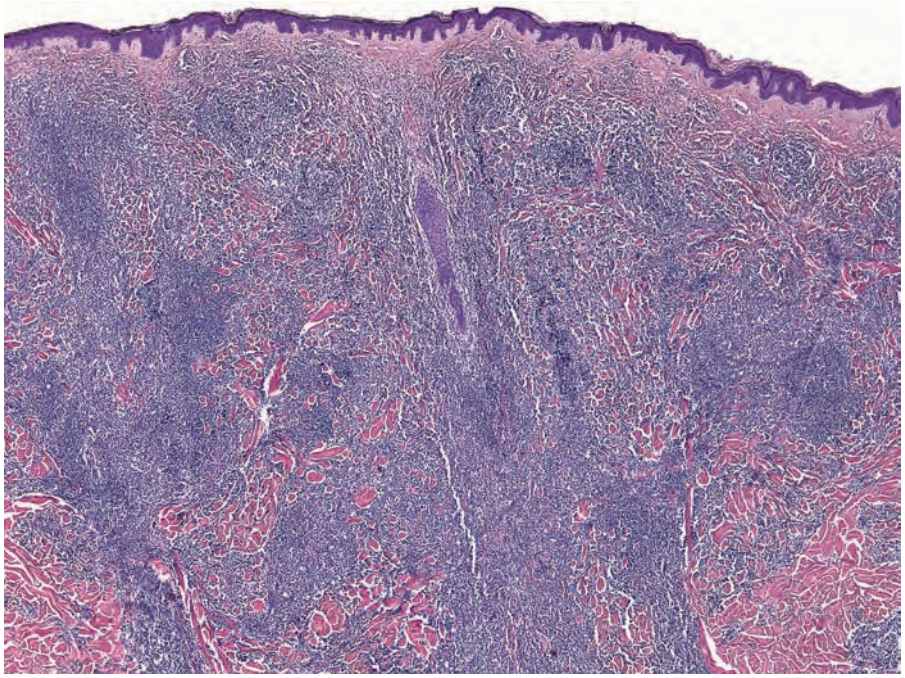

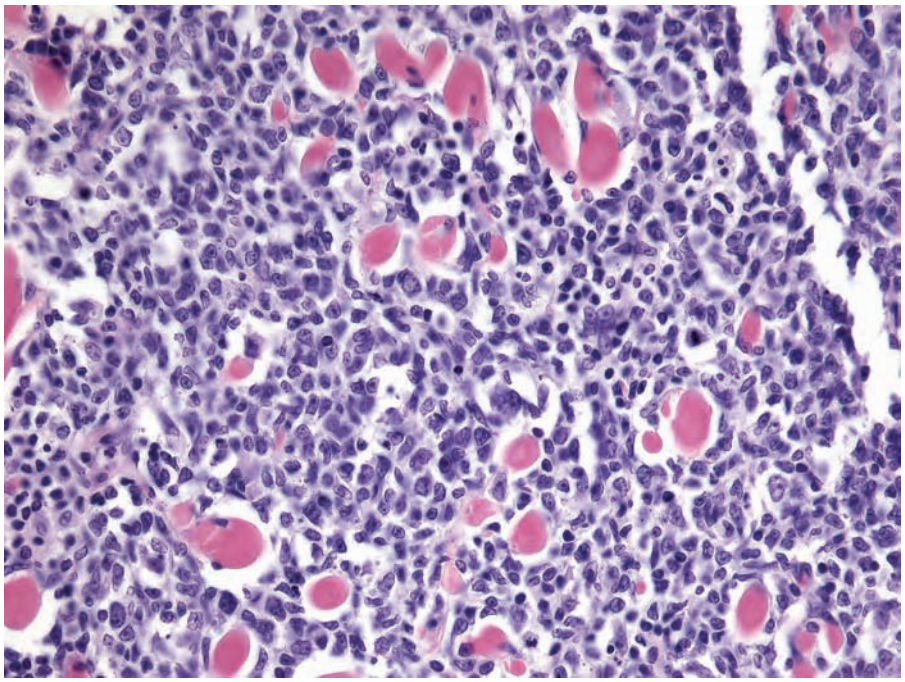

- Blue dense infiltrate
- Infiltrate composed of monomorphous lymphocytes, usually atypical
- Often a "bottom-heavy" infiltrate

Note Clinical history and special stains may be critical in making the diagnosis.

Lymphoma

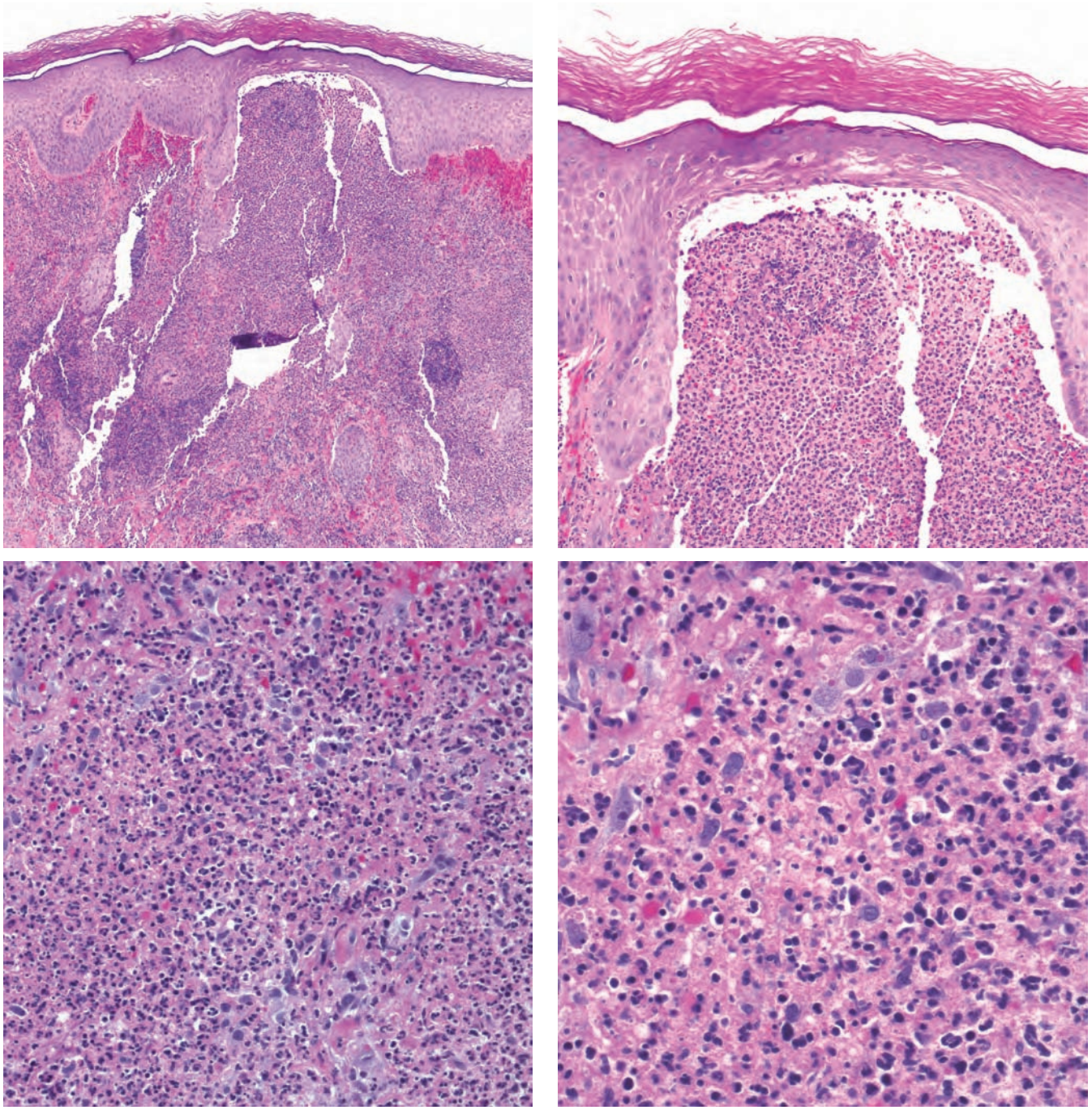

- Blue dense infiltrate
- Papillary dermal edema
- Infiltrate composed of neutrophils
- Generally vasculitis is not prominent

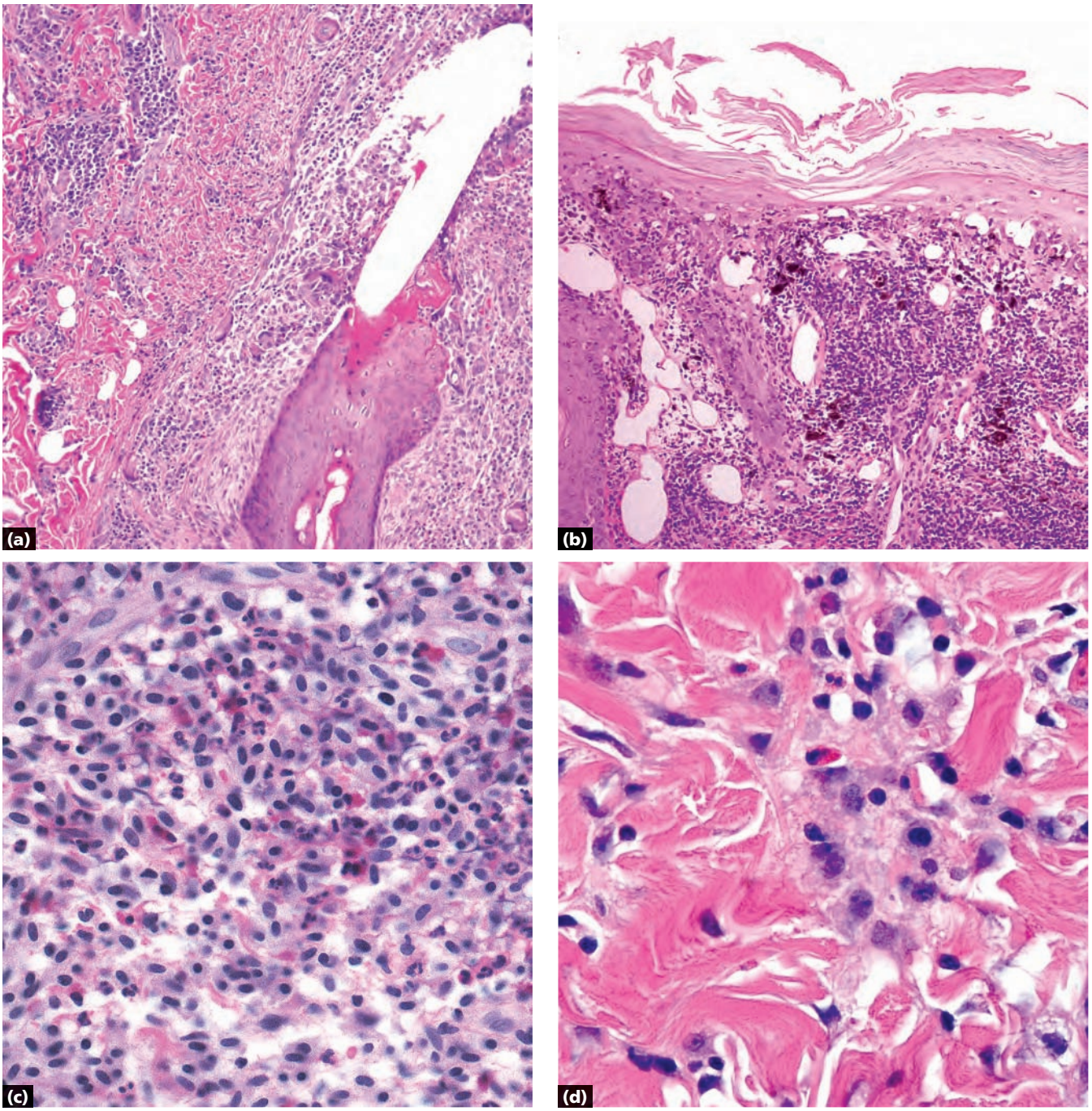

a Acne keloidalis: lymphoplasmacytic infiltrate around/destroying hair follicles with scarring

b Discoid lupus erythematosus: interface changes, superficial and deep perivascular and periadnexal lymphocytic infiltrate, pigment incontinence (see page 117)

c Granuloma faciale: mixed infiltrate with eosinophils under a grenz zone, vasculitis

d Leukemia (myelogenous): atypical cells with granular cytoplasm around vessels and infiltrating dermis

Key differences

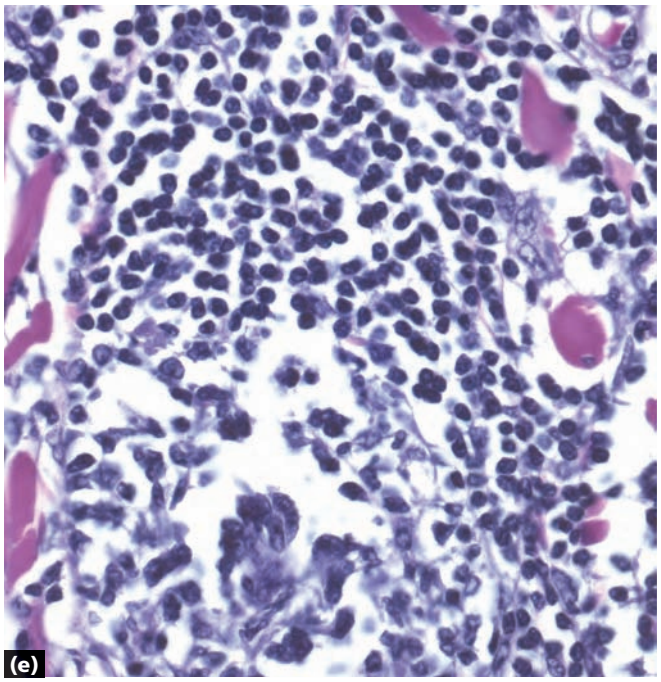

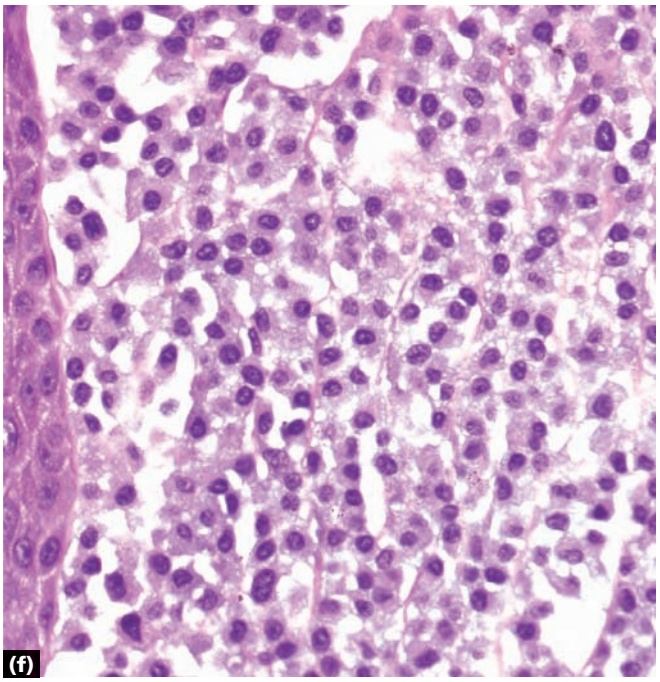

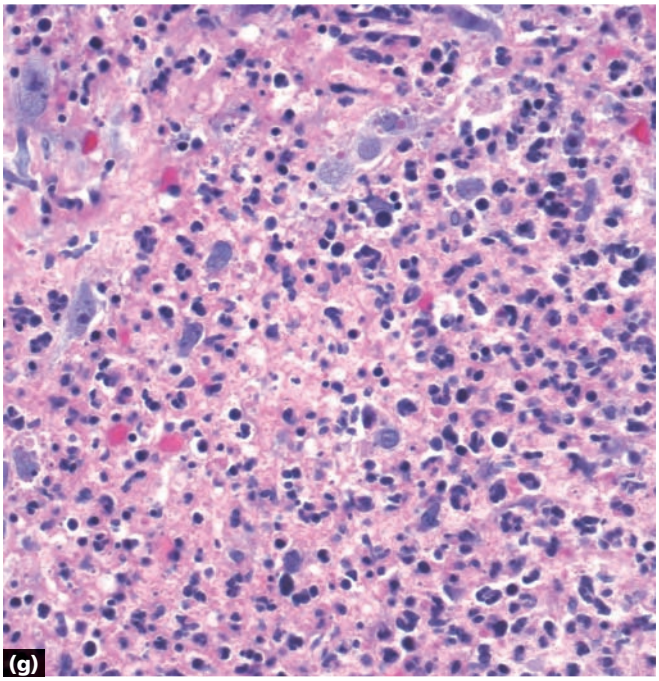

e Lymphoma: monomorphous lymphocytes filling dermis
f Mastocytoma: dense collection of mast cells with "fried egg" appearance (see page 133)
g Sweet syndrome: infiltrate of neutrophils

Note Infections may also have a dense infiltrate.

Key differences, *continued*

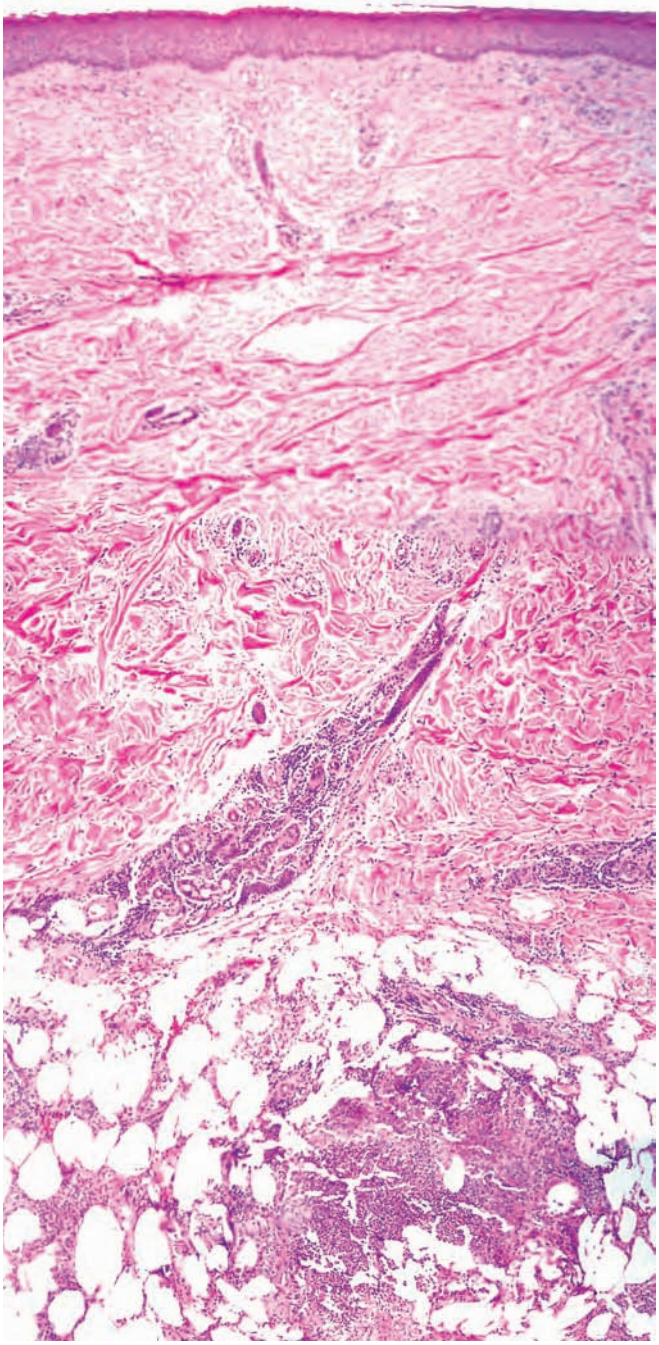

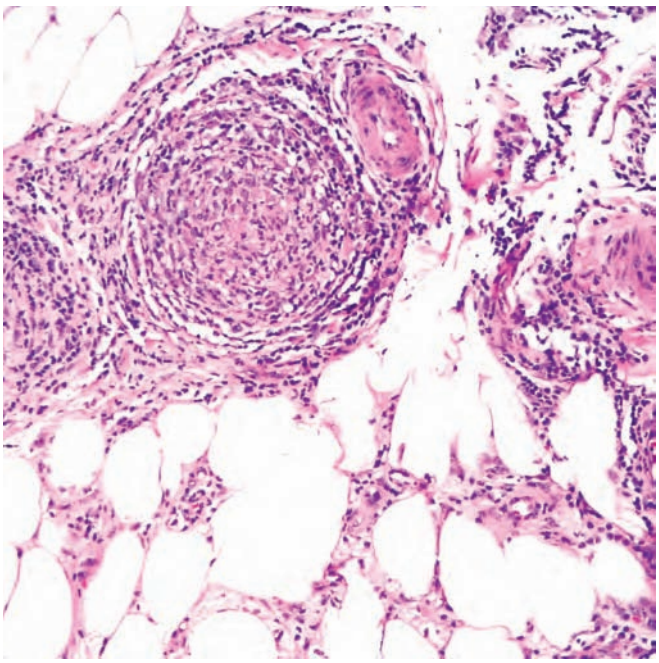

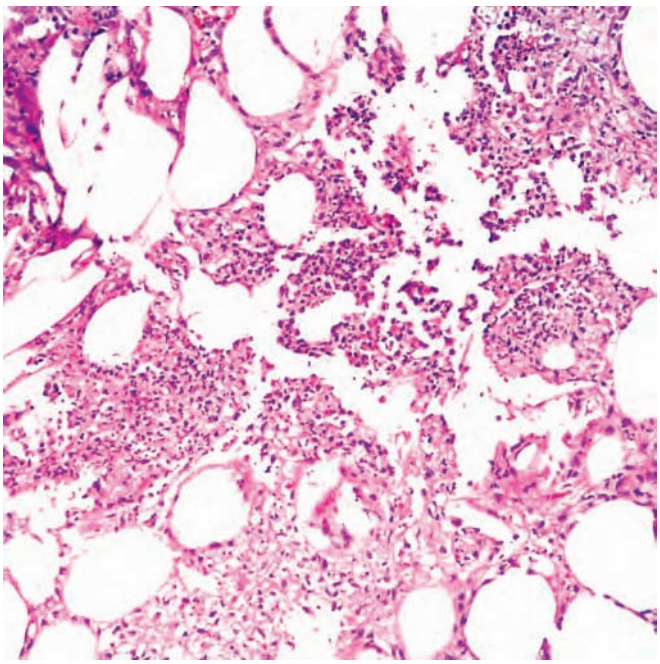

- Subcutaneous inflammation
- Lobular panniculitis with mixed inflammation (histiocytes, lymphocytes, neutrophils)
- Inflammation around vessels (vasculitis) in the septae
- "Panniculitis > vasculitis"; see polyarteritis nodosa on page 147

Erythema induratum

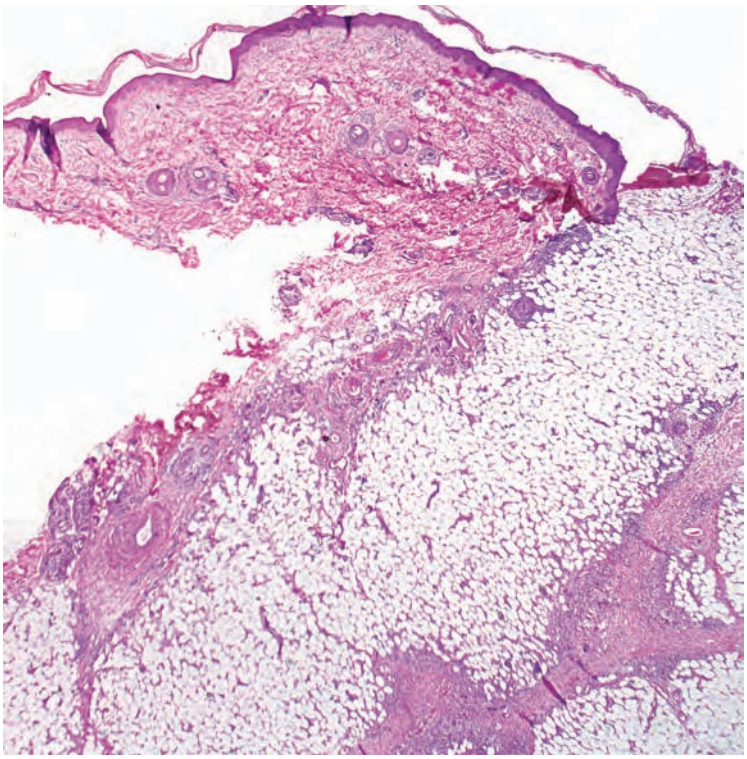

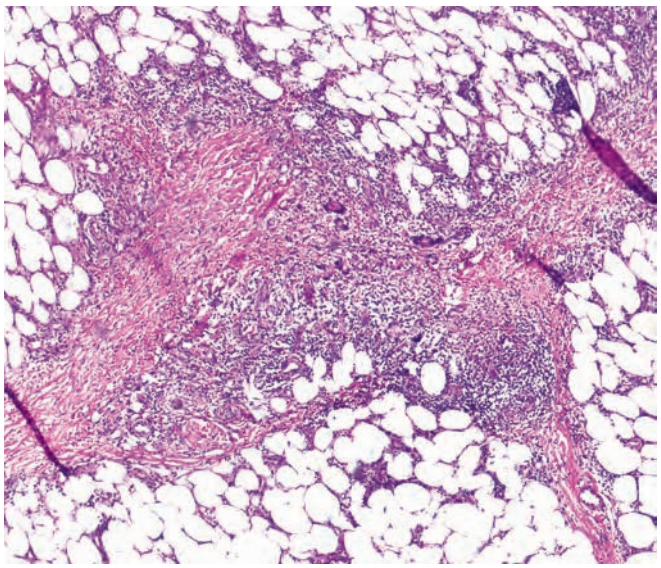

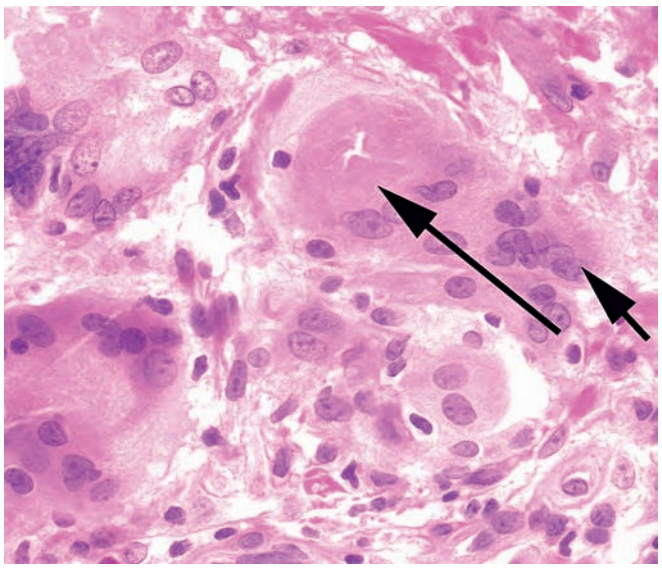

- Subcutaneous inflammation
- Septal panniculitis with thickened septae between lobules of adipocytes
- Septae contain giant cells (short arrow)
- Early lesions may have neutrophils, eosinophils
- Miescher's radial granuloma may be seen (long arrow)

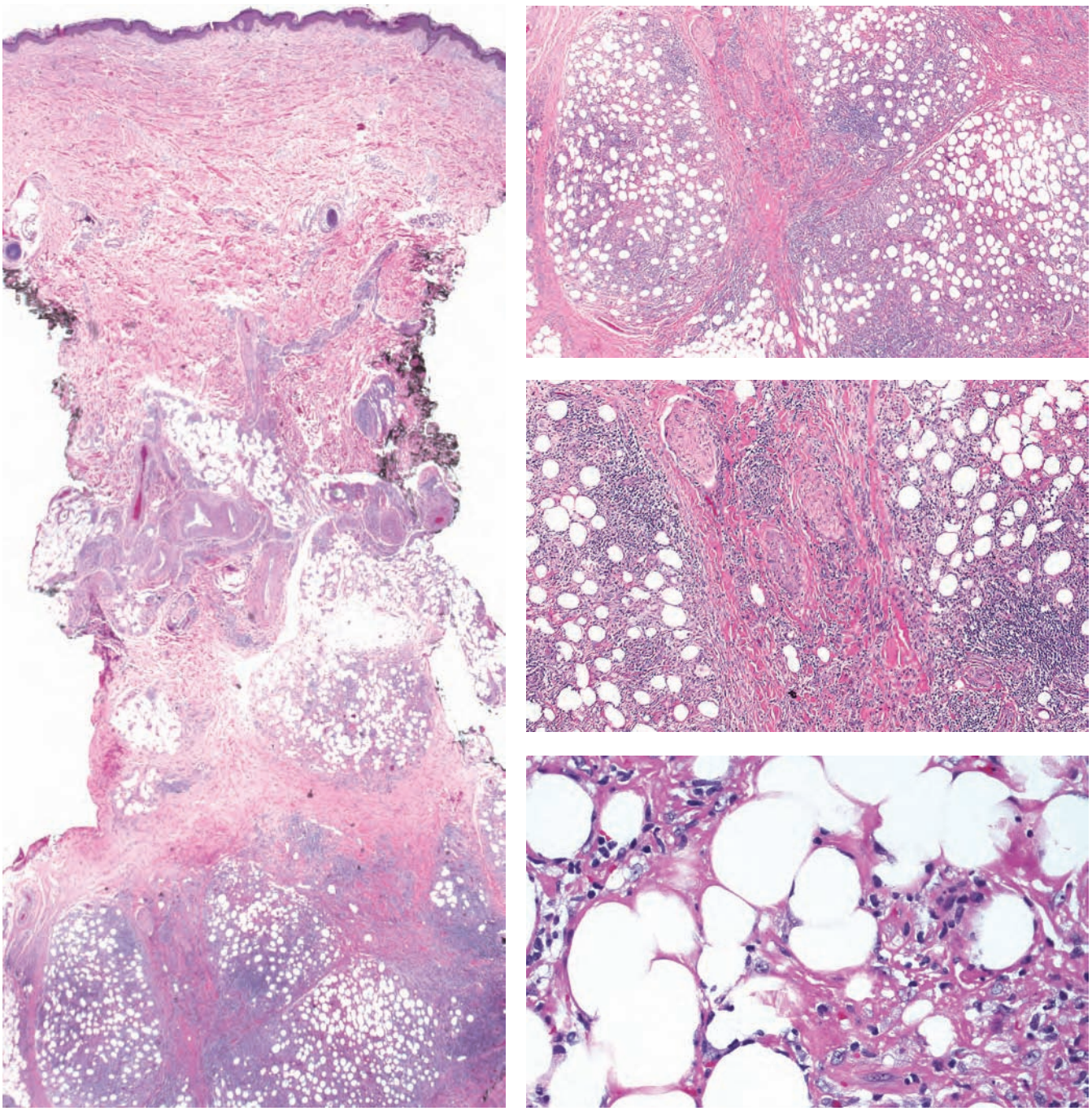

- Subcutaneous inflammation
- Lymphoplasmacytic infiltrate (lobular panniculitis)
- Lymphoid follicles may be present
- Fibrinoid (hyaline) necrosis of fat
- Later stages show hyalinization of fat (hyaline sclerosis)

Lupus profundus

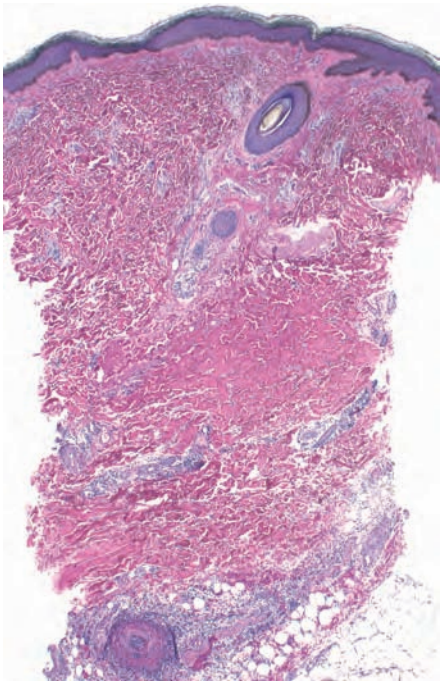

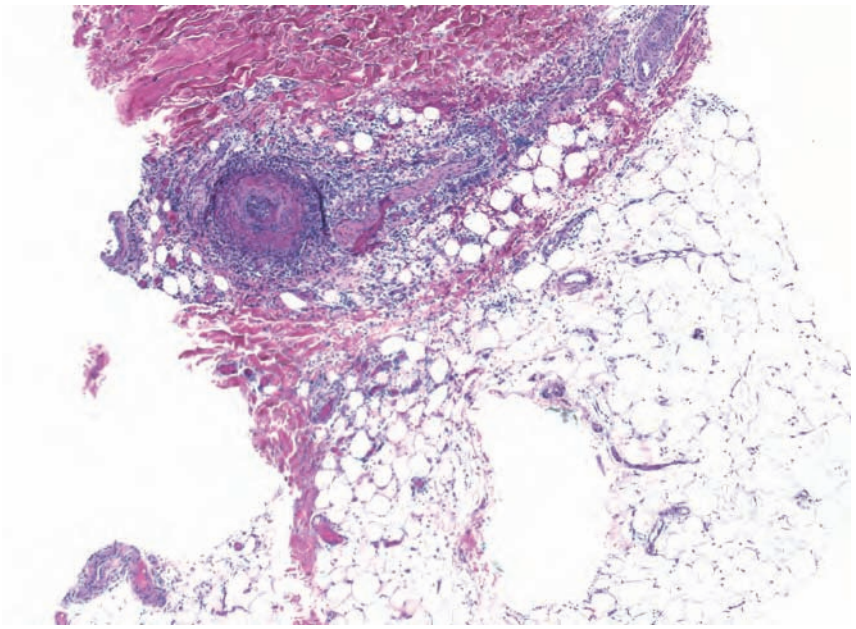

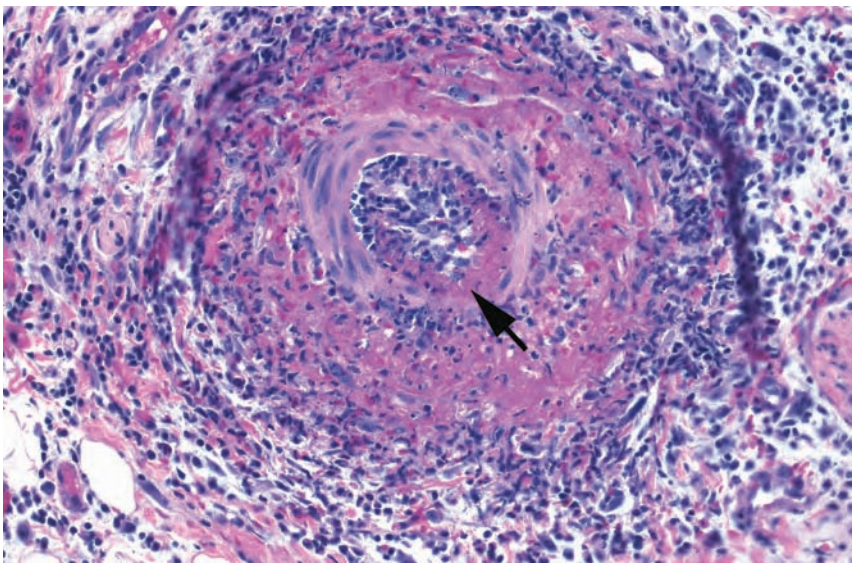

- Subcutaneous inflammation
- Septal panniculitis
- Often at dermal-subcutis junction, a large vessel is involved with inflammation (vasculitis) (arrow)
- "Vasculitis > panniculitis"; see erythema induratum on page 144

Polyarteritis nodosa

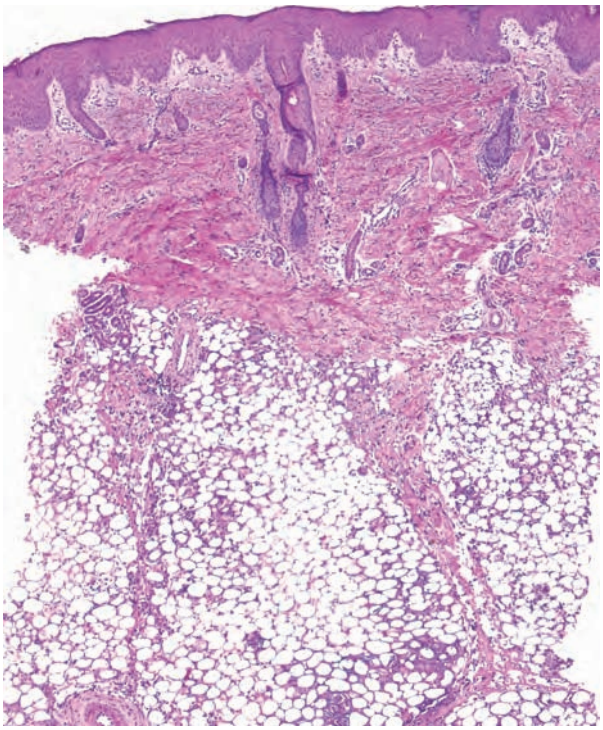

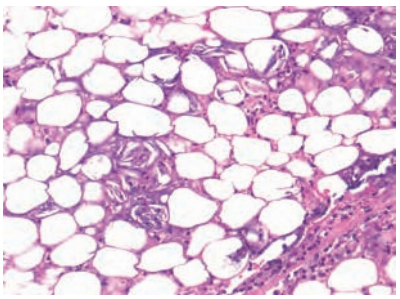

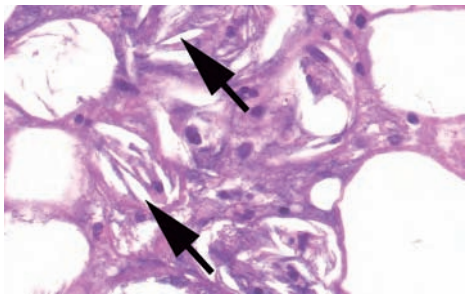

- Subcutaneous inflammation
- Lobular panniculitis
- Inflammation and radial crystalline shapes (arrows) within fat lobules

Note Post-steroid panniculitis can look the same.
Note Sclerema neonatorum also has crystalline shapes but lacks inflammation.

Subcutaneous fat necrosis of the newborn

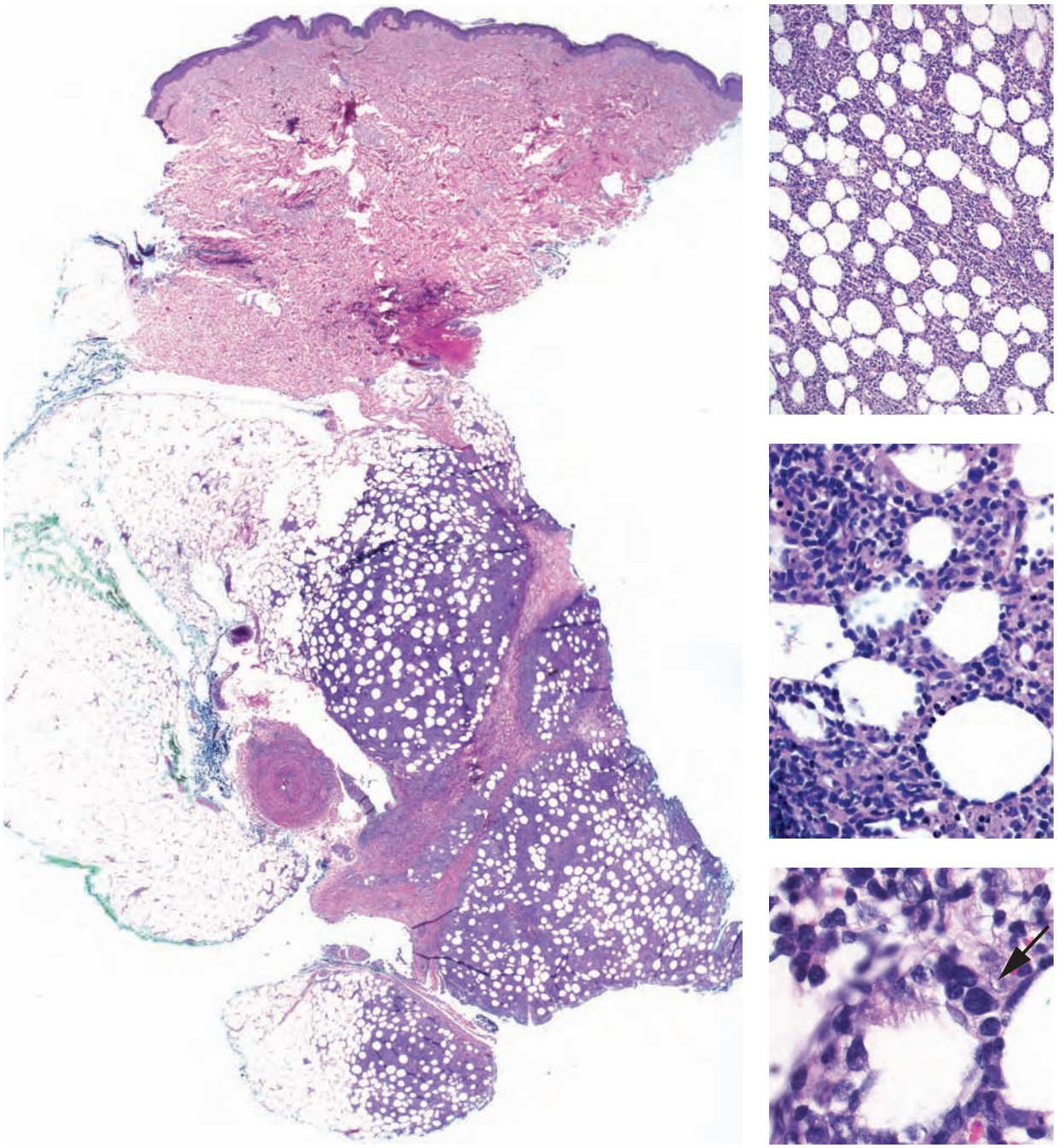

- Subcutaneous inflammation
- Lobular involvement of inflammation
- Atypical lymphocytes rim fat cells (arrow)

Source: Photos courtesy of Antonio Subtil, MD.

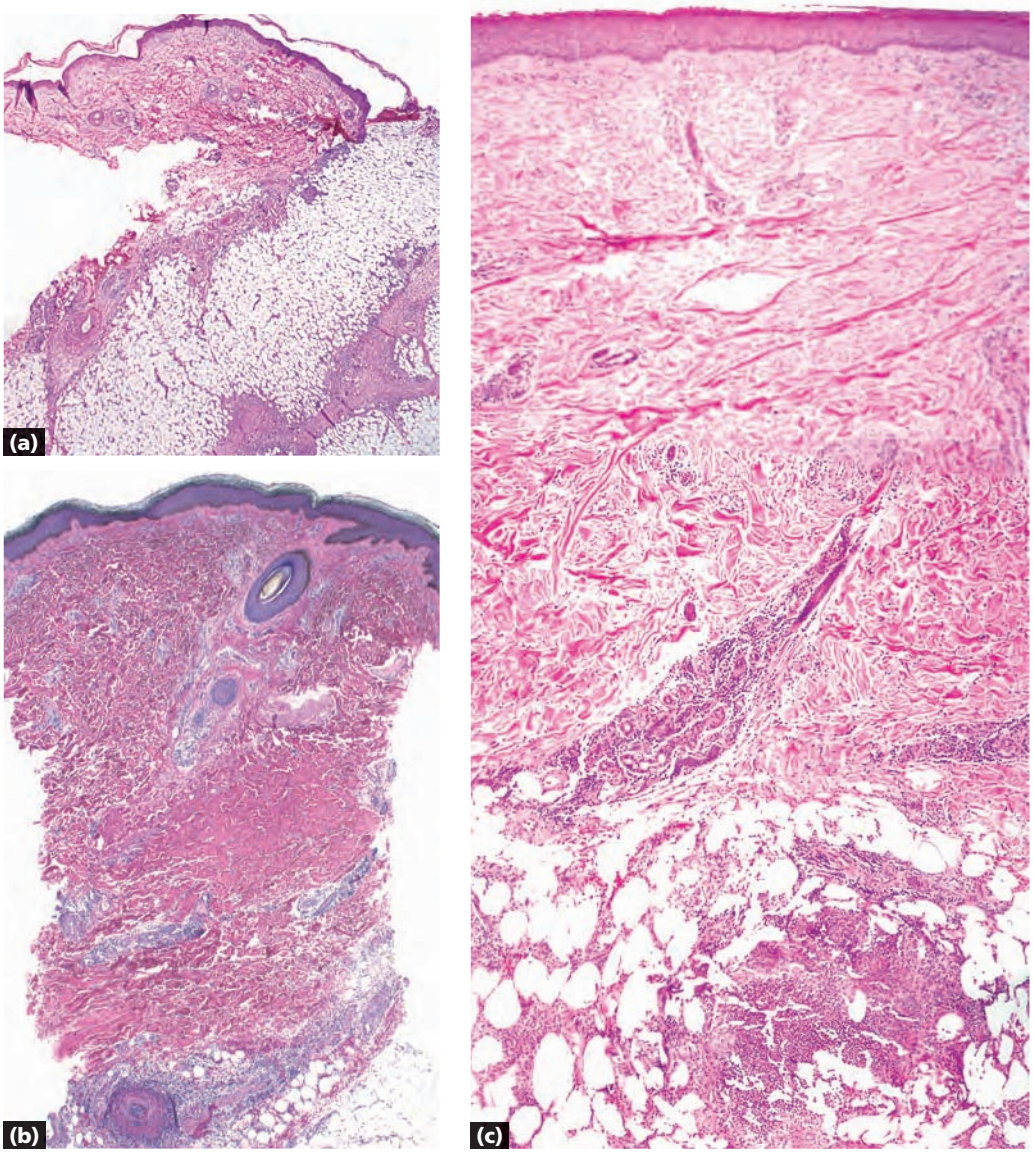

a Erythema nodosum: septal thickening with giant cells (sometimes neutrophils and eosinophils)
b Polyarteritis nodosa: vasculitis of a medium-sized vessel, often at dermal-subcutis junction, "vasculitis > panniculitis"
c Erythema induratum: vasculitis and lobular mixed inflammation, "panniculitis > vasculitis"

Key differences

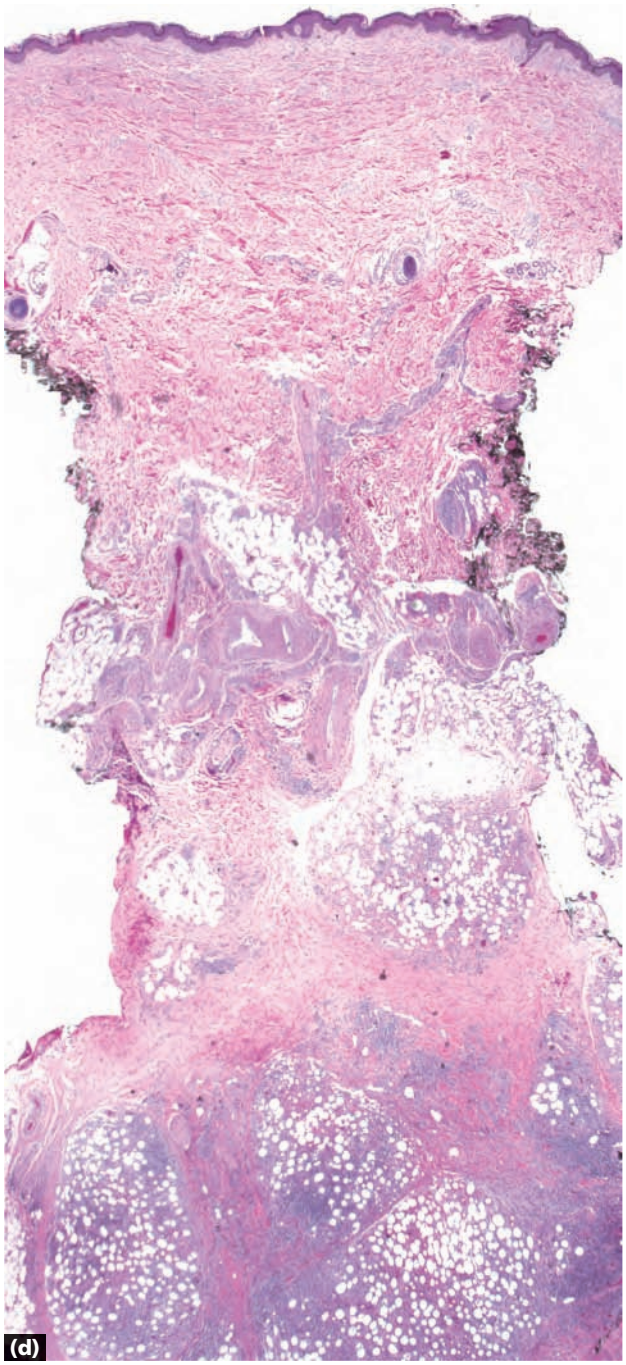

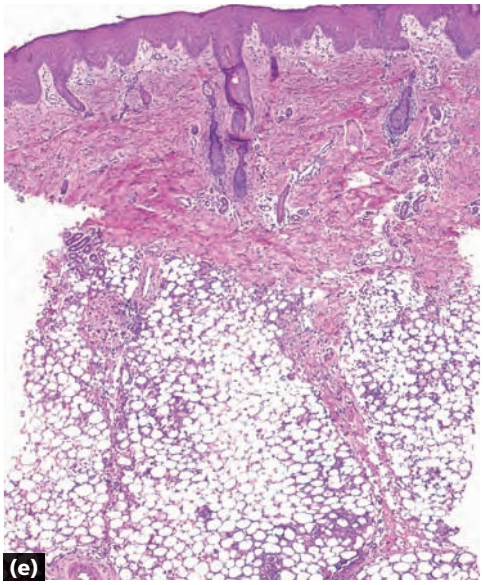

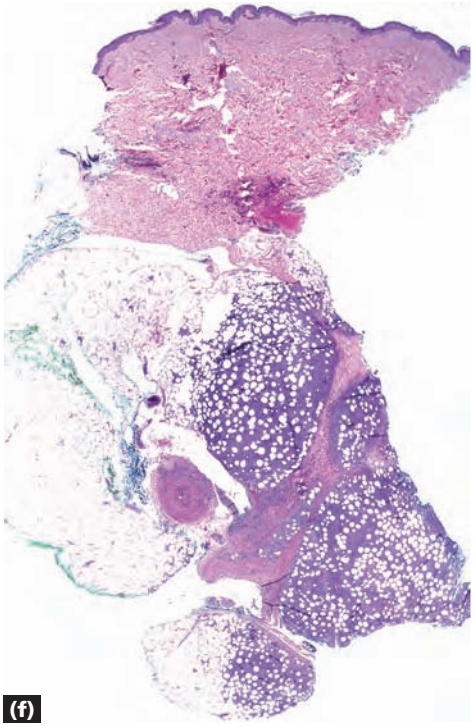

d Lupus profundus: hyaline fat necrosis, lymphoid follicles
e Subcutaneous fat necrosis of the newborn: histiocytes, some containing crystals, and lymphocytes within fat lobules
f Subcutaneous T-cell lymphoma: rimming of adipocytes with atypical lymphocytes

Key differences, *continued*

3 Cell Type

- Melanocytic, 155
- Spindle cells, 164
- Endothelial, 178
- Giant, 192
- Clear, 202

Dermatopathology: Diagnosis by First Impression, Third Edition. By Christine J. Ko and Ronald J. Barr.
© 2017 John Wiley & Sons, Ltd. Published 2017 by John Wiley & Sons, Ltd.
Companion website: www.wiley.com/go/ko/dermatopathology3e

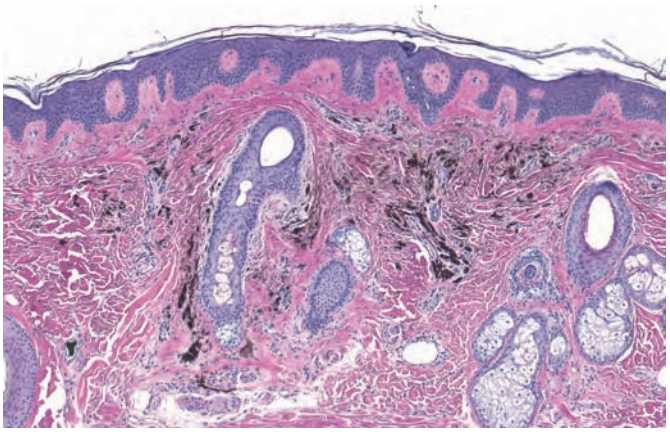

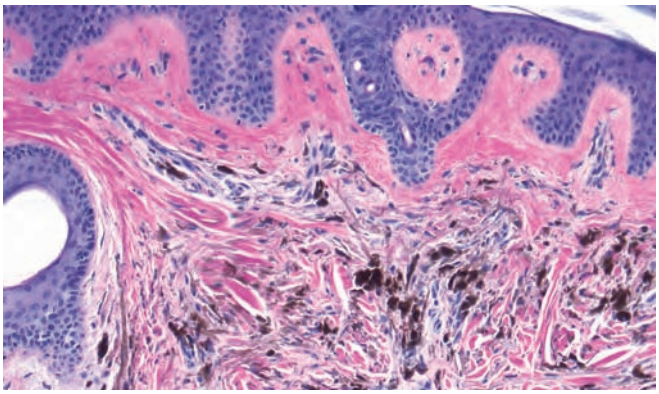

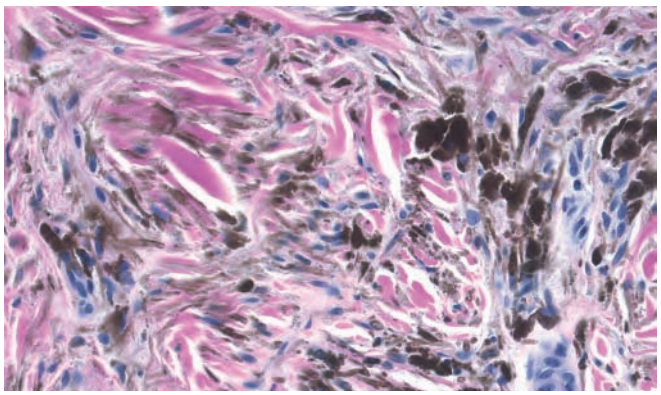

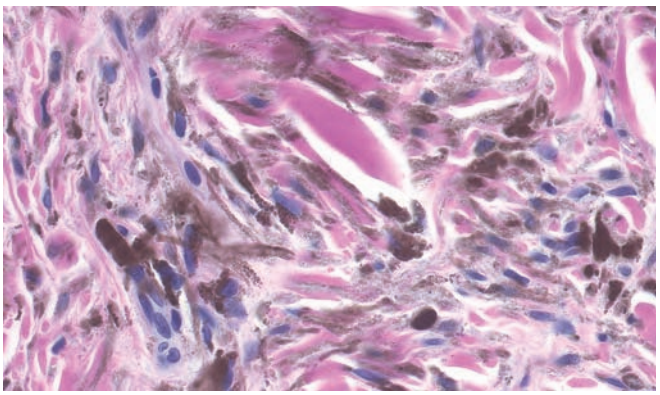

- Melanocytes
- Cells are small and spindled/dendritic with occasional cells containing melanin pigment
- Dermis often hyalinized
- Melanophages often present

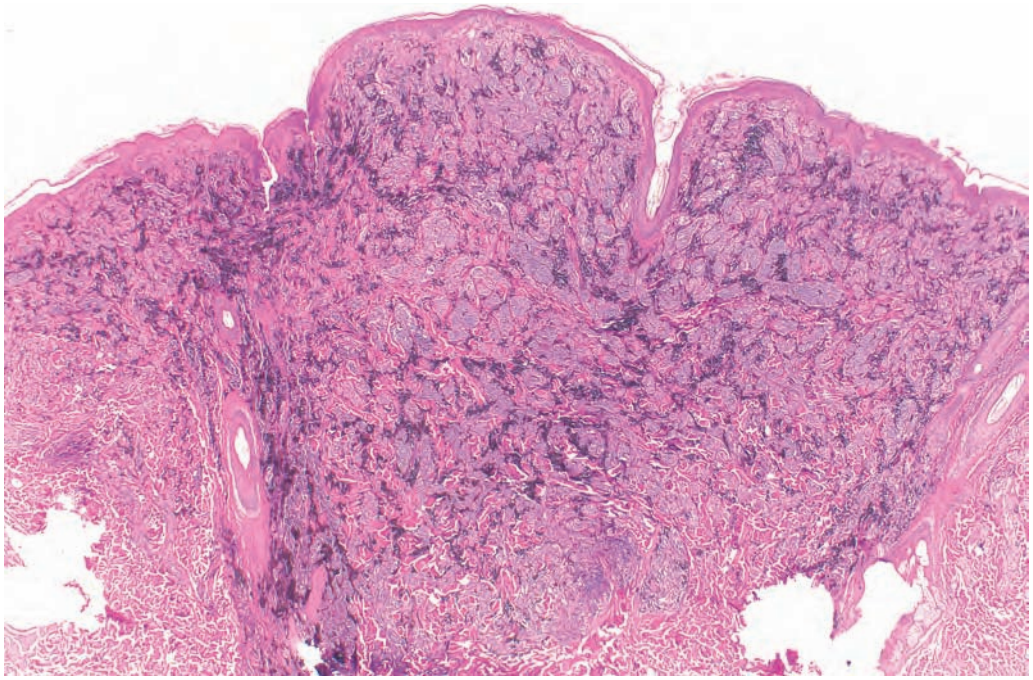

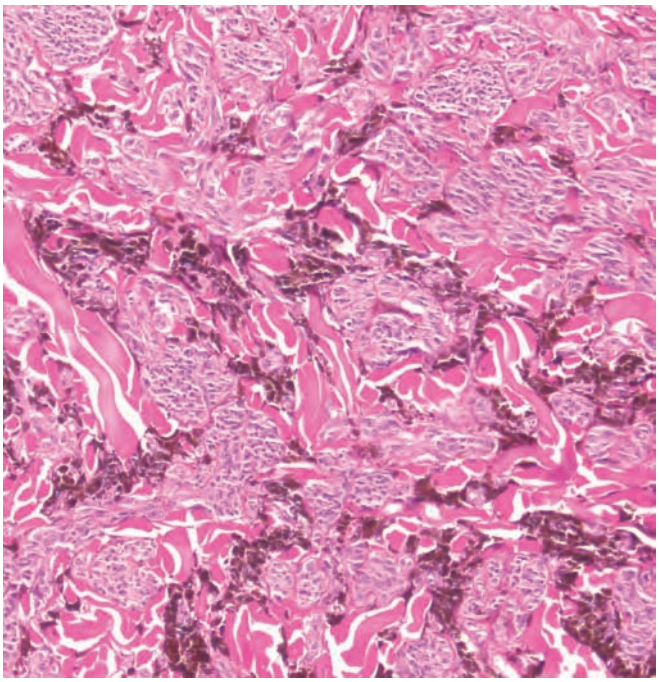

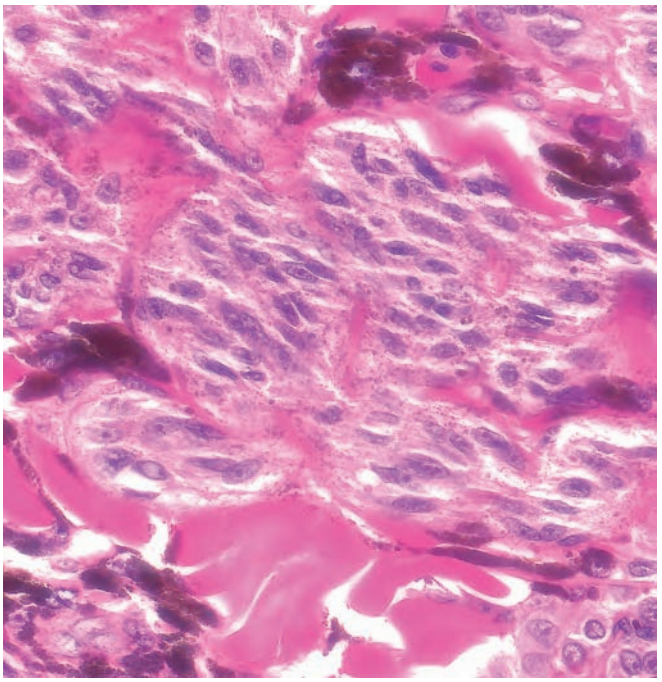

- Melanocytes
- Epithelioid melanocytes are admixed with or bordered by uniformly distributed melanophages
- Pattern on low power is wedge-shaped (often centered around a follicle)

Deep penetrating nevus

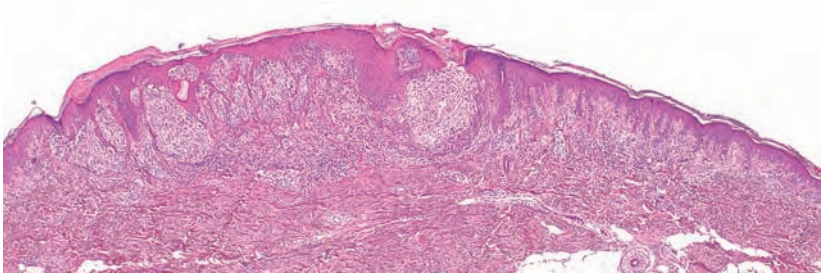

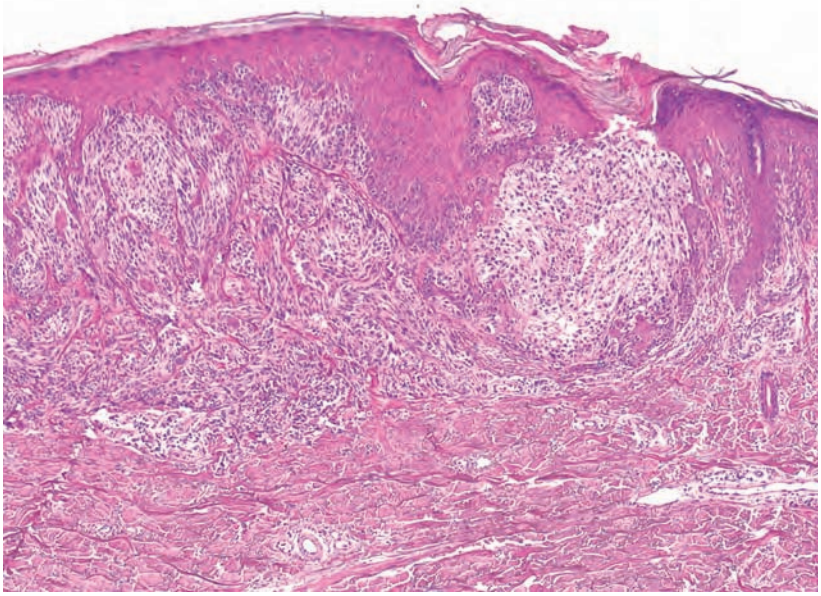

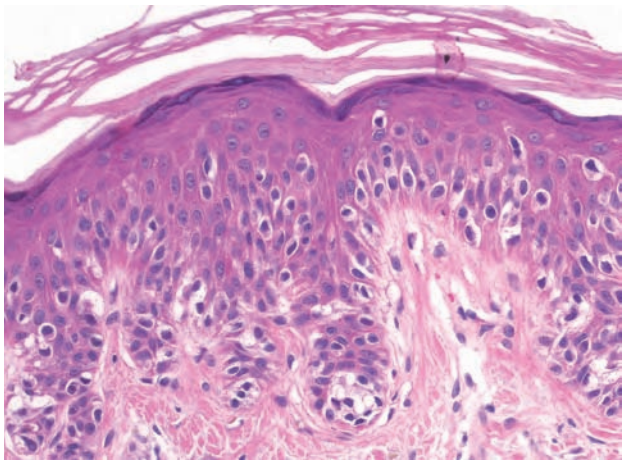

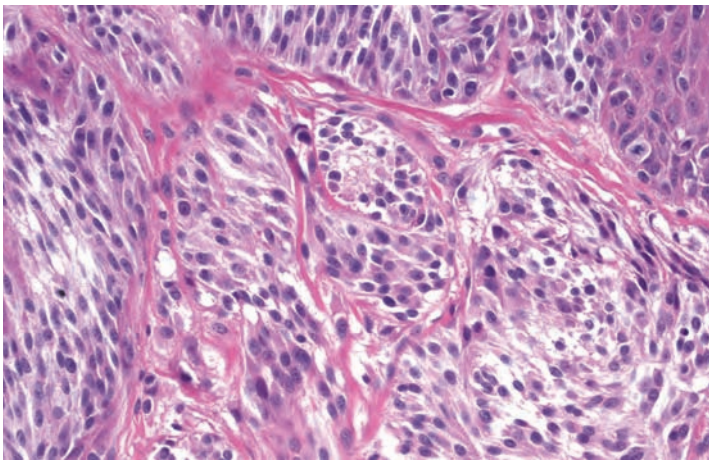

- Melanocytes
- Cells are confluent at the junction with irregularly sized nests, scattered high and low within the epidermis
- Atypical cells and mitoses in epidermal and dermal nests

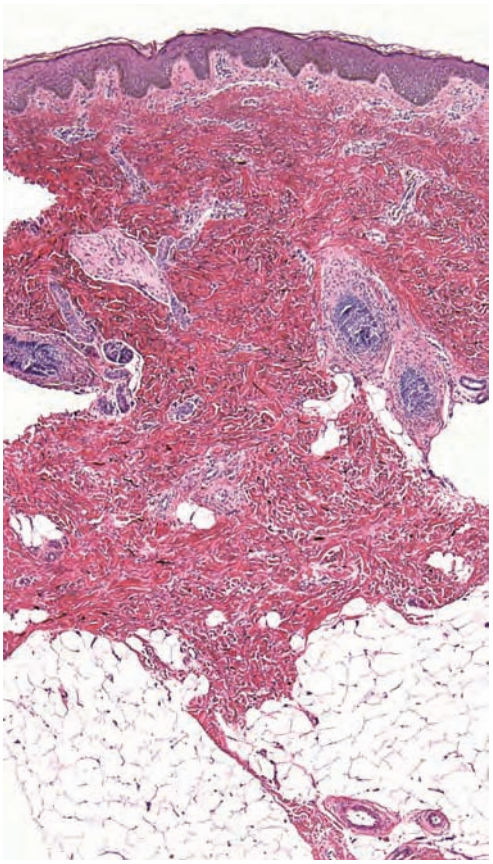

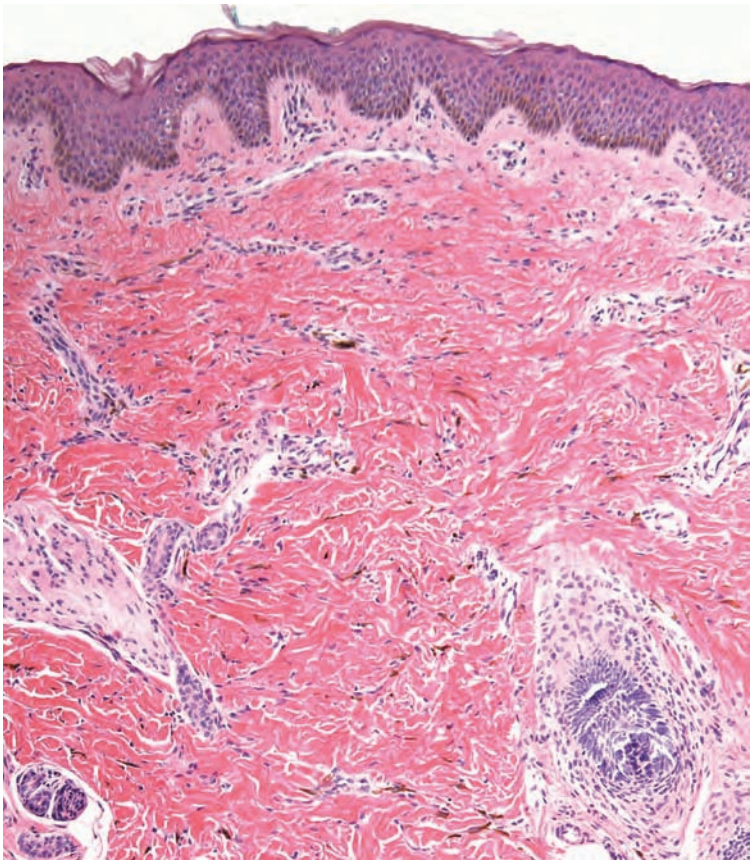

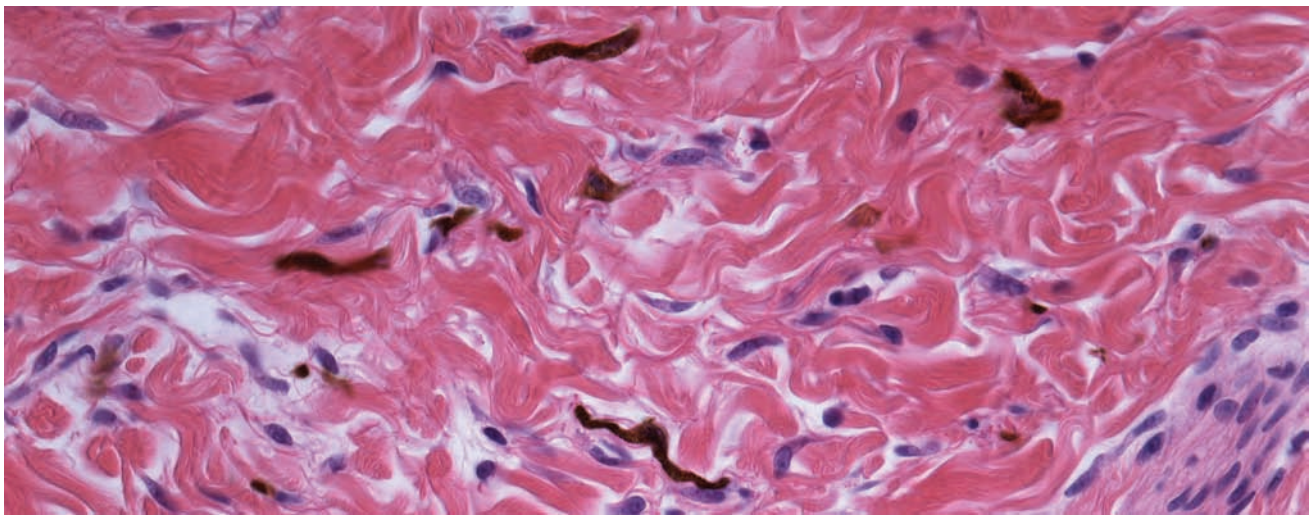

- Dendritic melanocytes distributed throughout the dermis

Mongolian spot

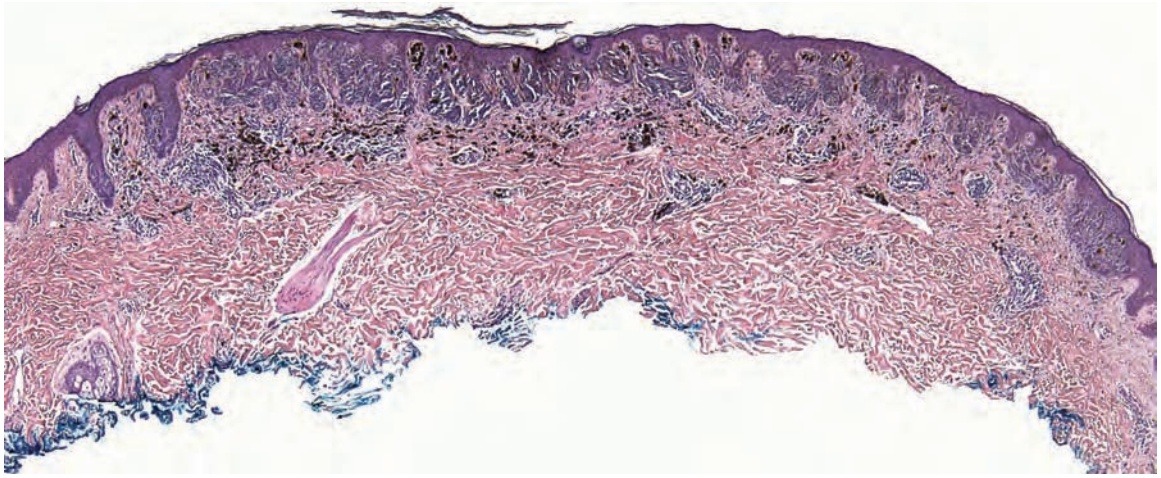

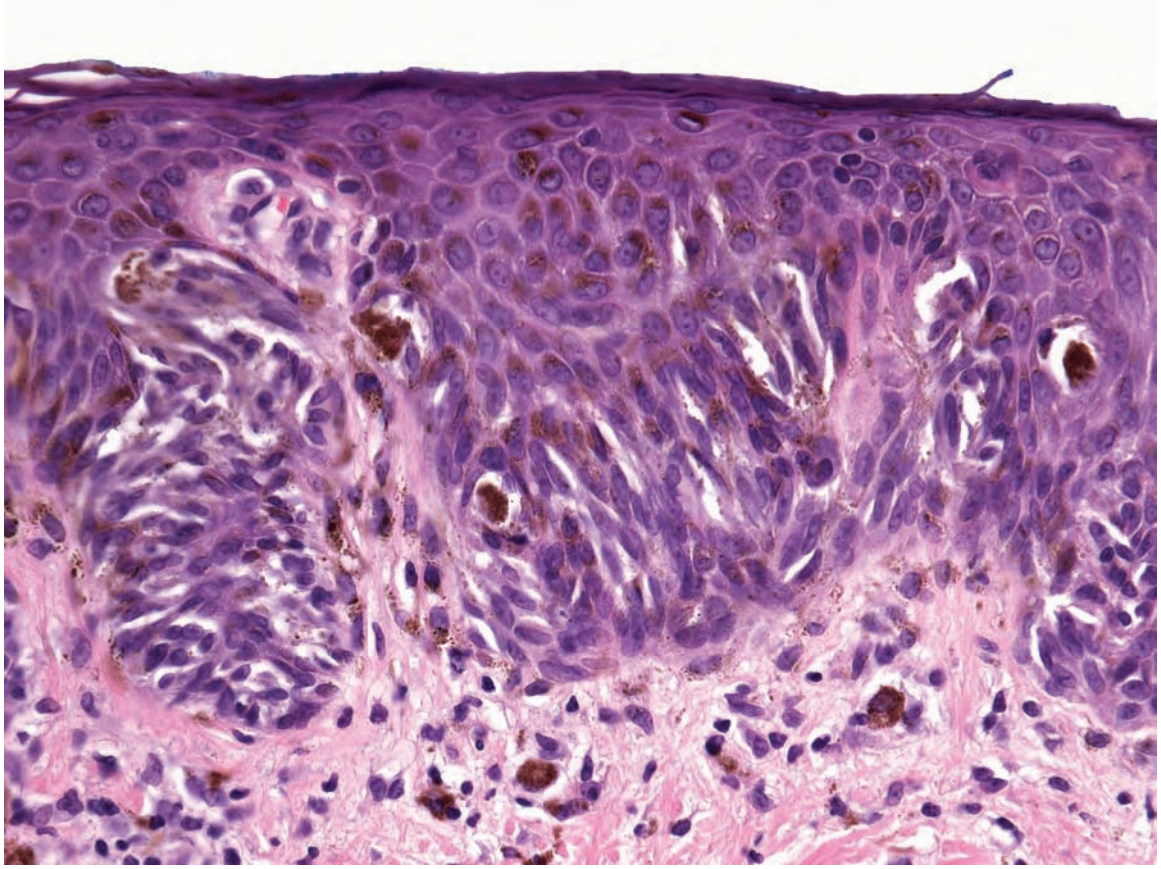

- Melanocytes
- Pigmented spindle cells are arranged in vertical fascicles in the base of the epidermis
- Pushing margin into superficial dermis

Pigmented spindle cell nevus of Reed

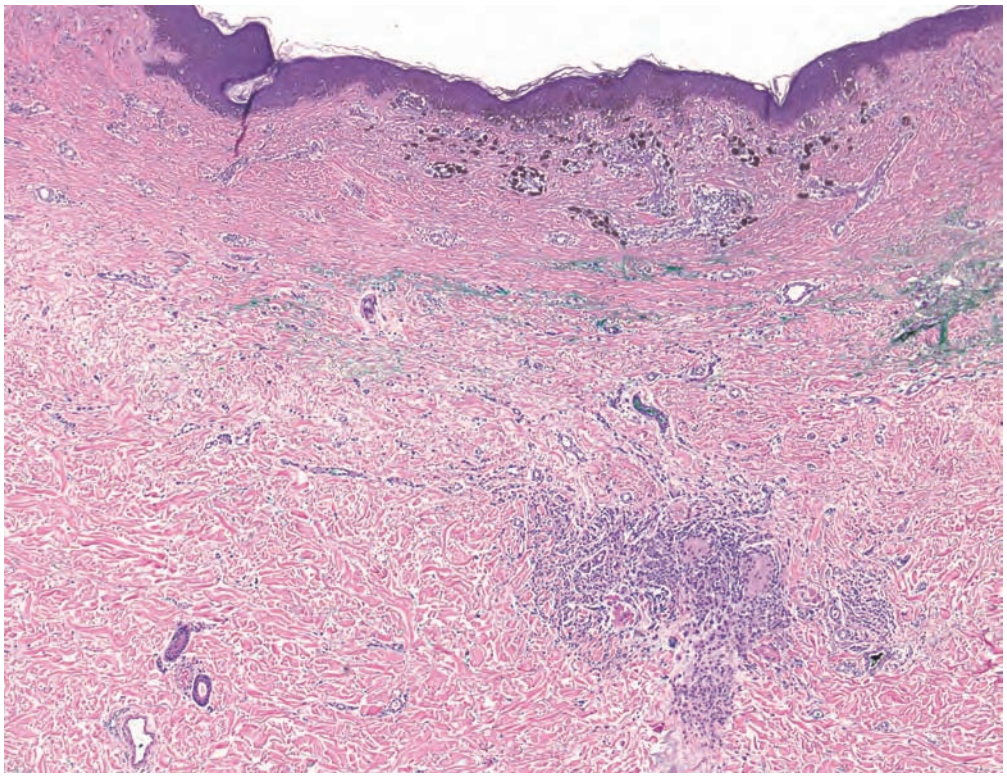

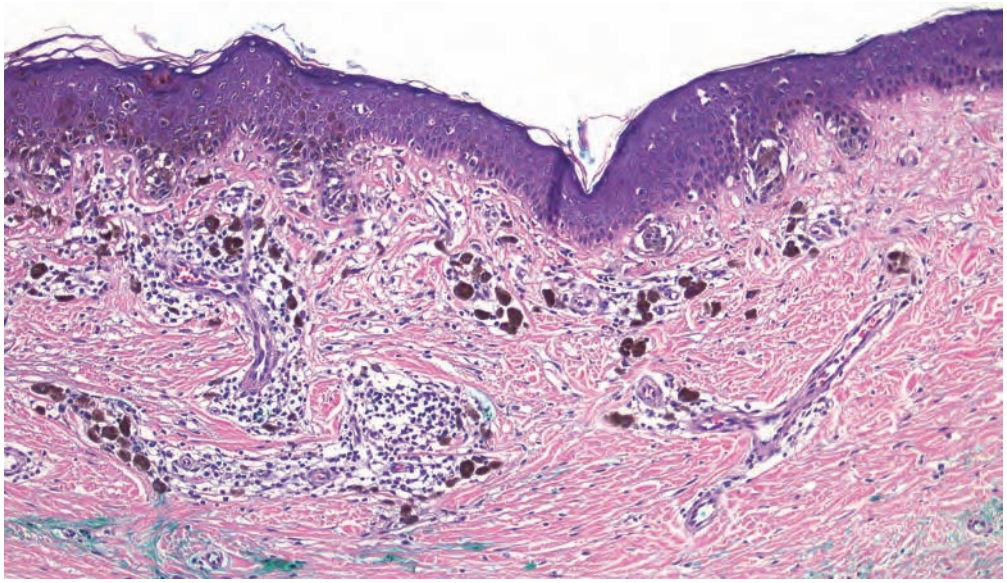

- Melanocytes
- Cells are in irregularly shaped nests, sometimes confluent, confined to area above a dermal scar
- Predominantly junctional involvement

Recurrent nevus

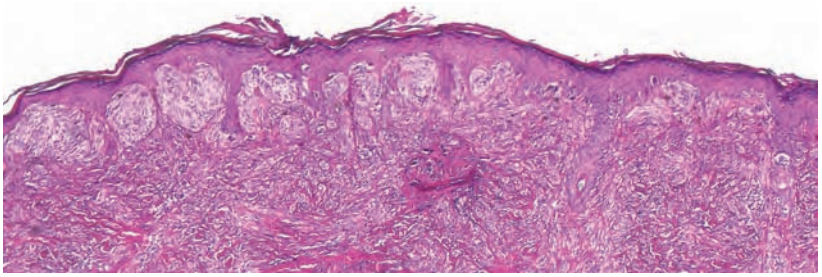

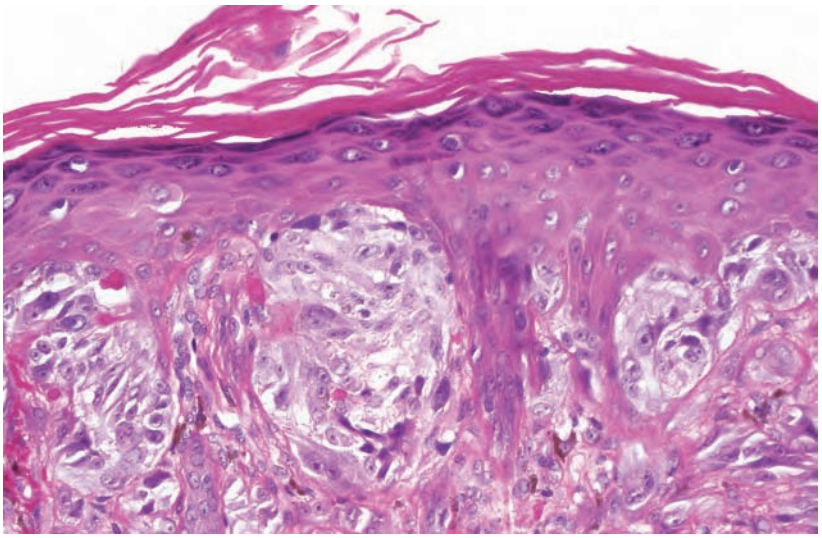

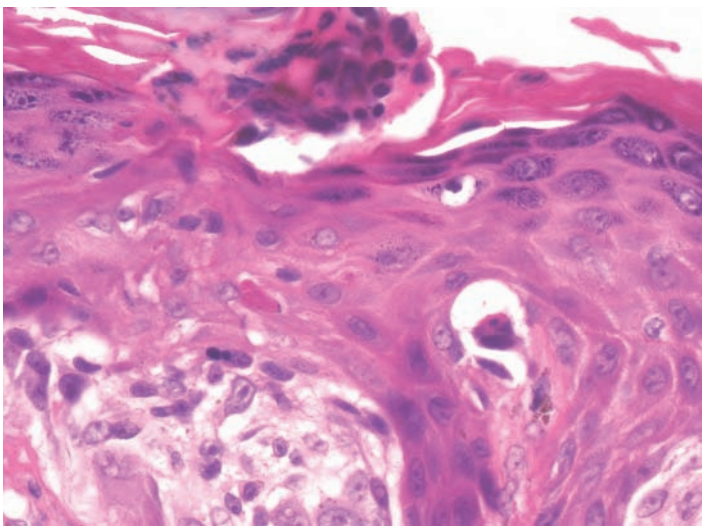

- Melanocytes, spindled and epithelioid
- Cells are in vertical fascicles within the epidermis ("school of fish")
- Well-circumscribed and symmetric
- Kamino bodies
- Clefting above nests
- Cells are atypical but all resemble each other

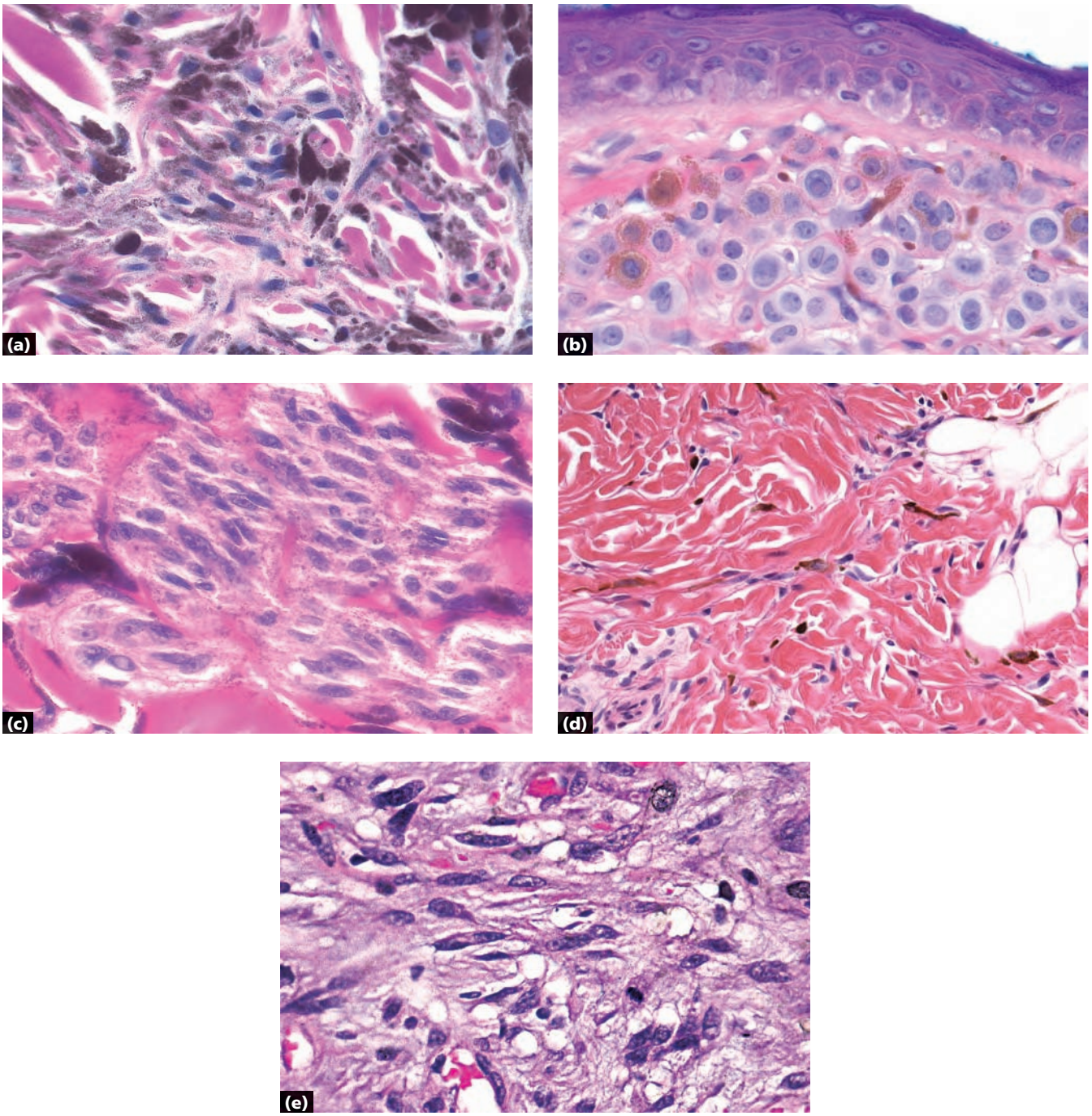

a Blue nevus: finely pigmented spindle/dendritic cells and melanophages within the dermis
b Intradermal nevus: circular melanocytes with fine brown pigment in nests (clusters)
c Deep penetrating nevus: epithelioid melanocytes in clusters with surrounding melanophages
d Mongolian spot: dendritic melanocytes infiltrating between collagen bundles
e Melanoma, desmoplastic: atypical spindle cells (see page 165)

Key differences

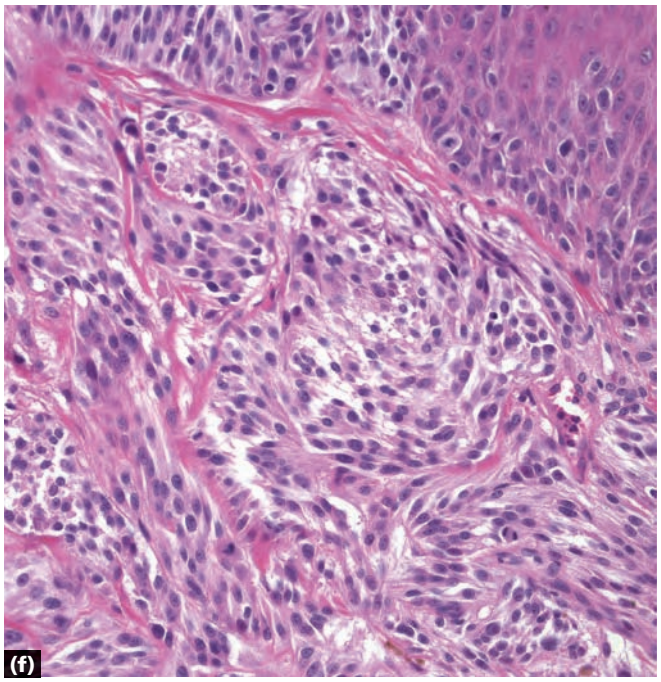

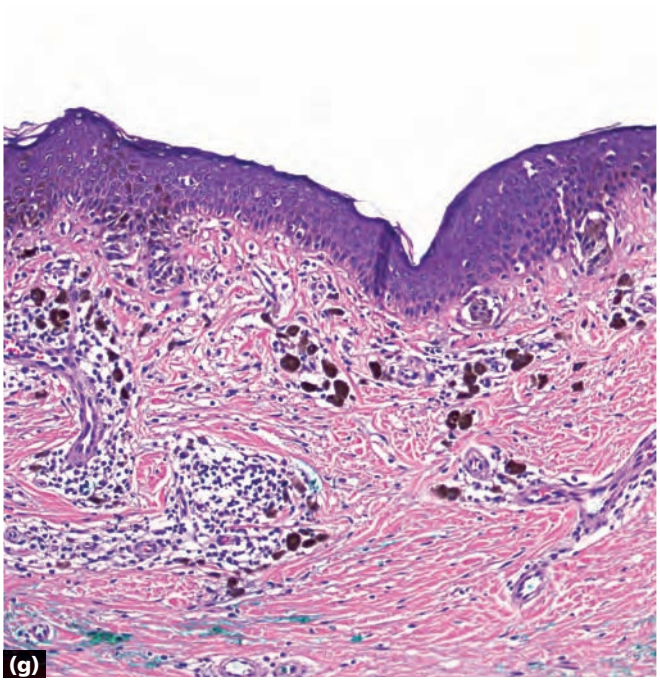

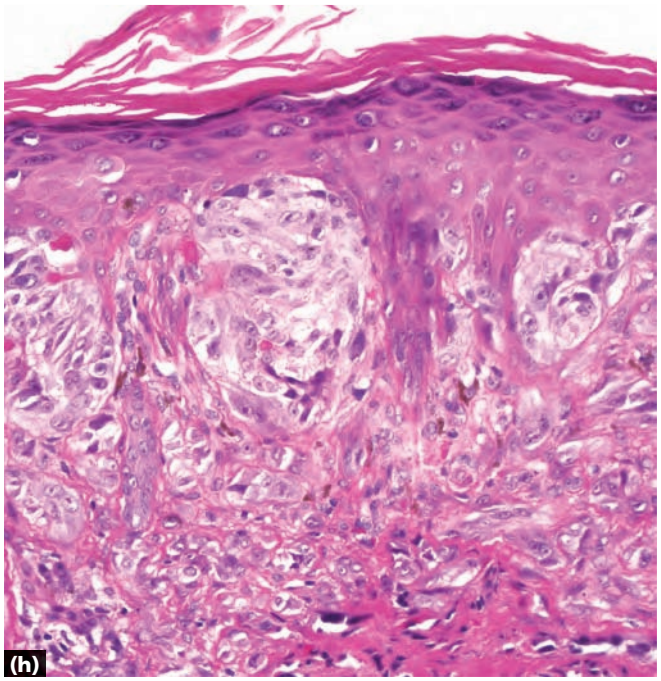

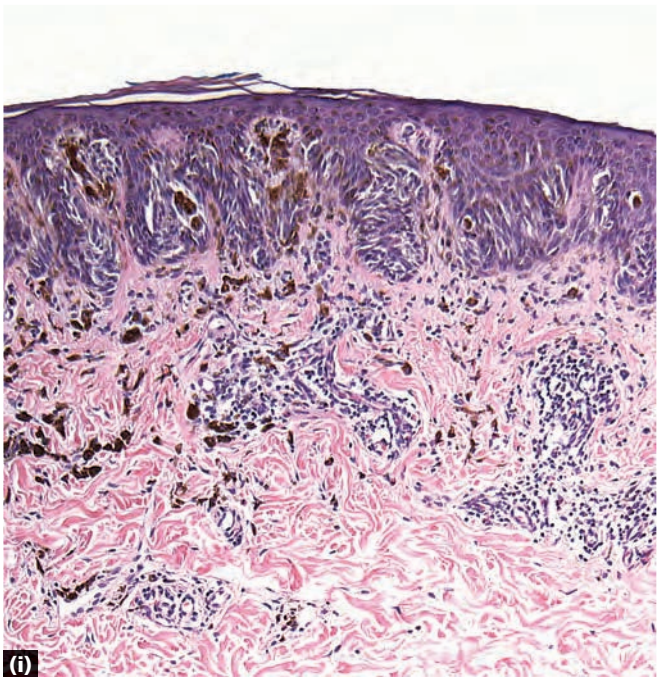

f Melanoma – Atypical cells in irregular pattern in epidermis and dermis, asymmetric, dermal mitoses

g Recurrent nevus – Irregular nests of pigmented cells above a scar

h Spitz nevus – Vertically arranged epithelioid and spindle cells, symmetric

i Pigmented spindle cell nevus of Reed – Vertically arranged pigmented spindle cells in base of epidermis with pushing margin into dermis

Key differences, *continued*

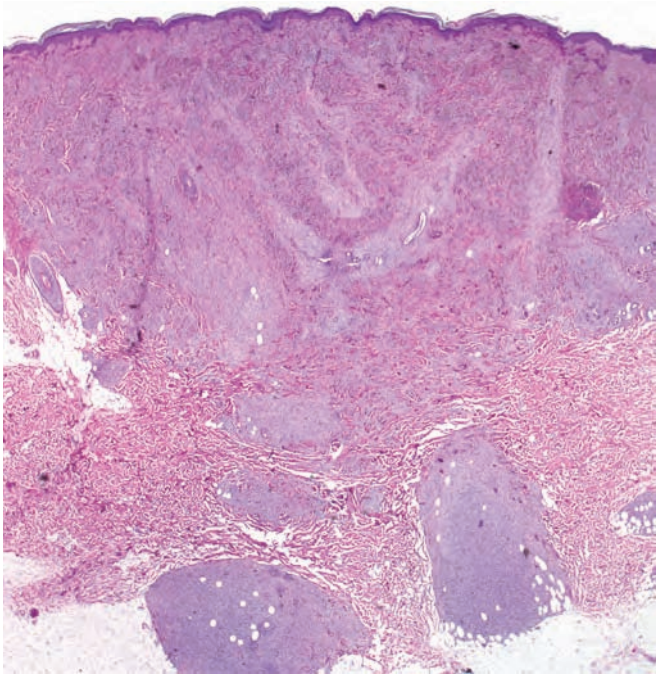

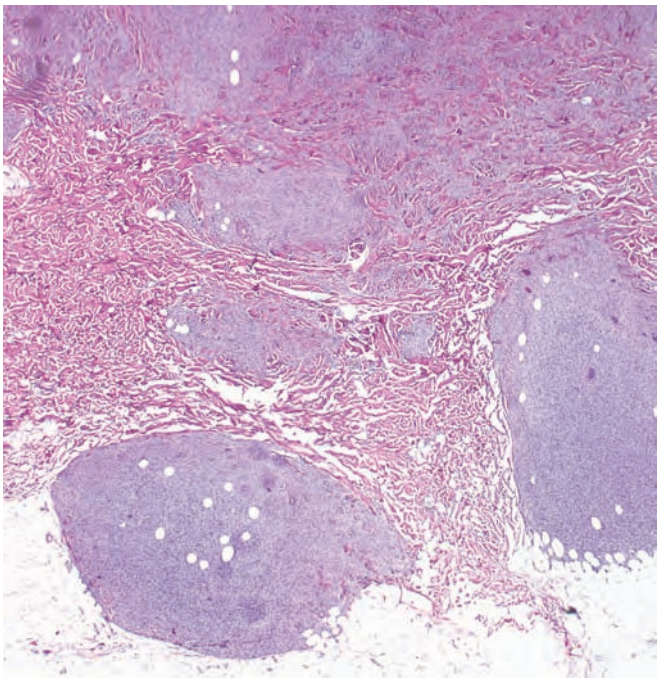

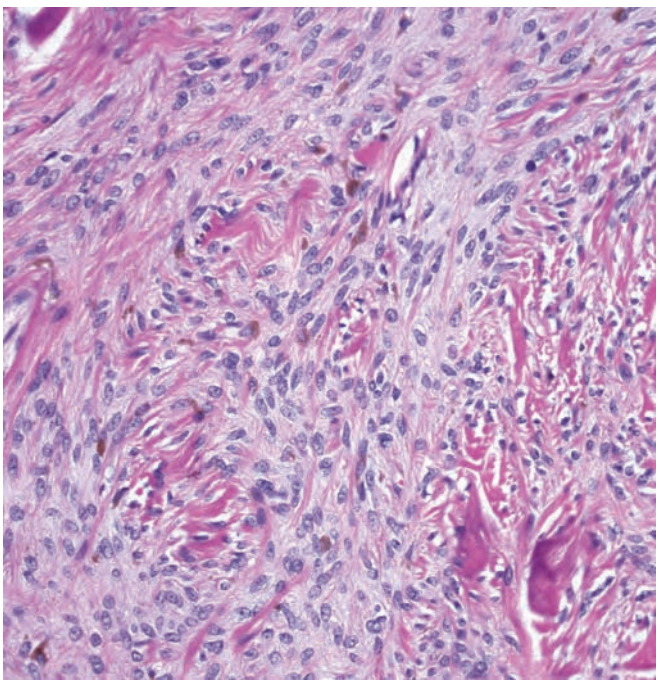

- Melanocytes that are spindled (and also appear rounded when fascicles are cut cross-wise) (so-called biphasic pattern)
- Often bulbous into the deep dermis
- Scattered melanin pigment within the cells

Blue nevus, cellular

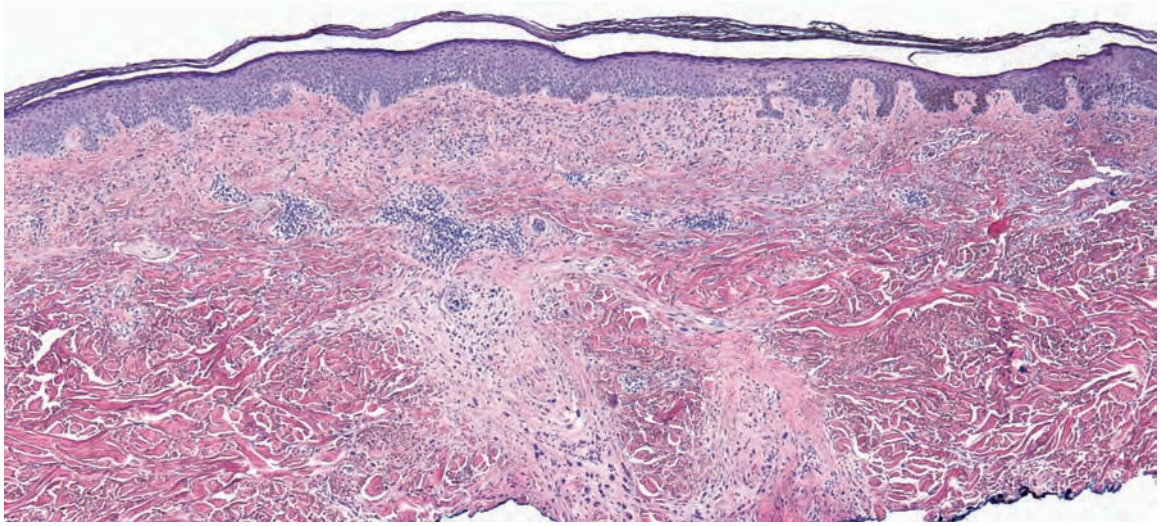

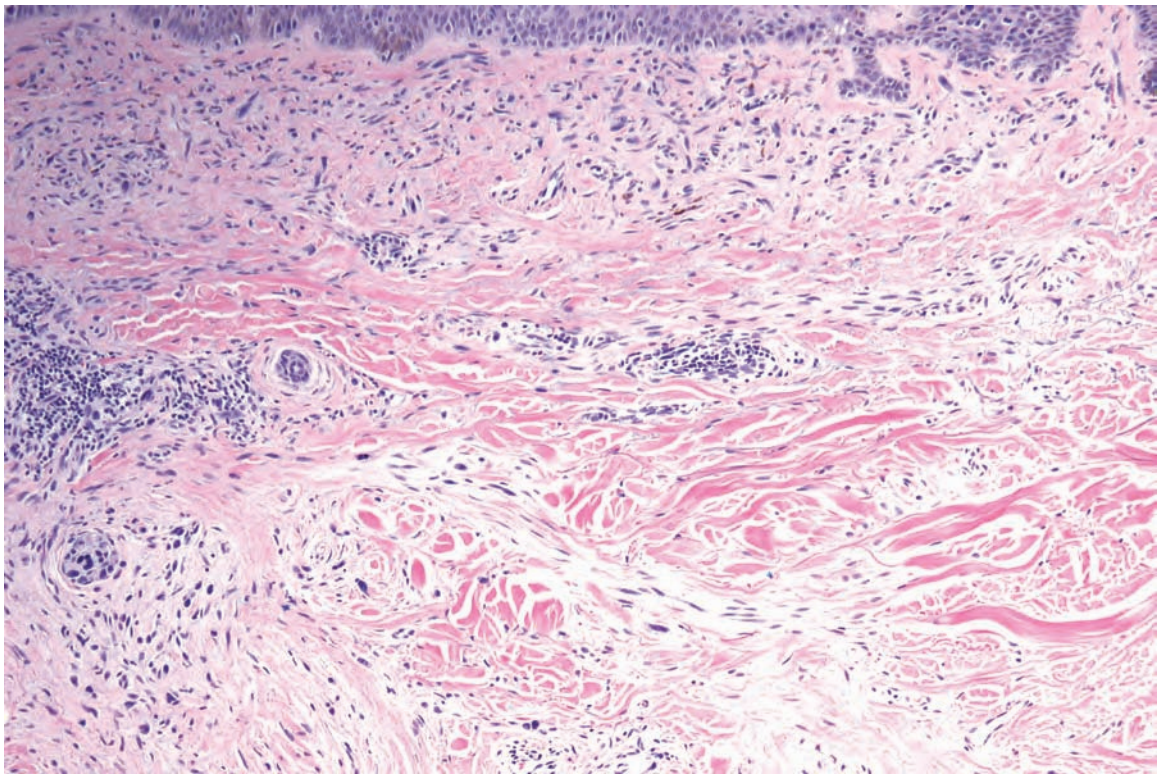

- Melanocytes
- Cells are spindled and arranged in bundles infiltrating through collagen
- Cells are atypical
- Often overlying in situ-melanoma changes in epidermis
- Perivascular lymphocytes are a clue

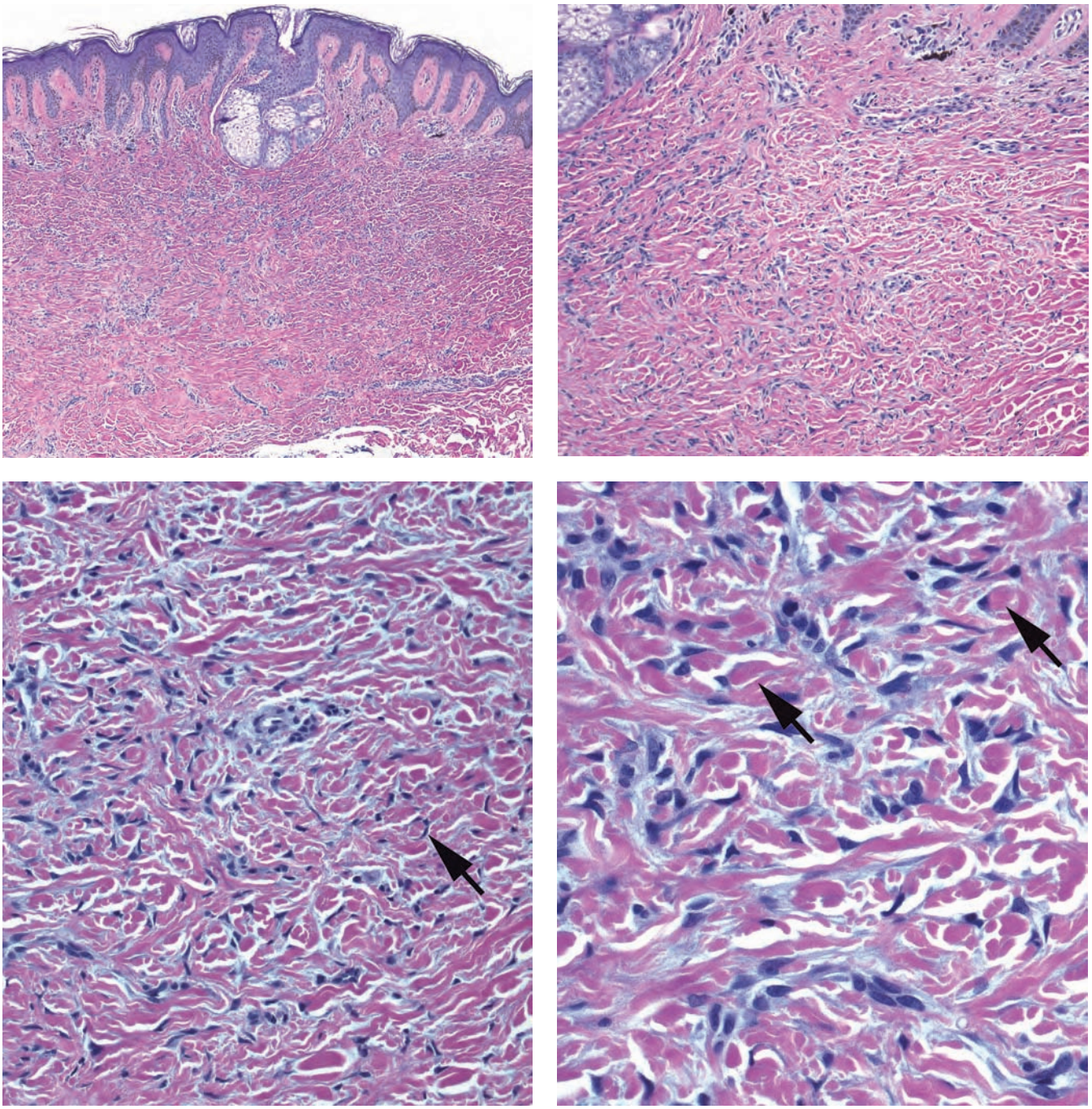

- Short spindle cells (fibrohistiocytes) in a "busy dermis"
- Epidermis often acanthotic and pigmented
- May have basaloid buds or sebaceous lobules at base of epidermis
- Cells entrap collagen at the periphery (arrows)
- Collagen bundles appear to be "coming at you" (90° to slide surface)

Dermatofibroma

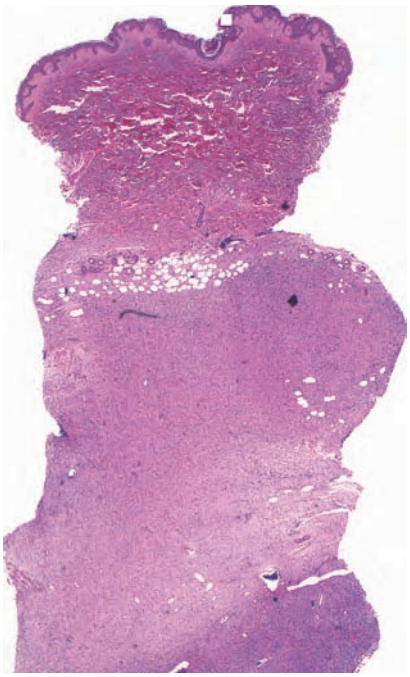

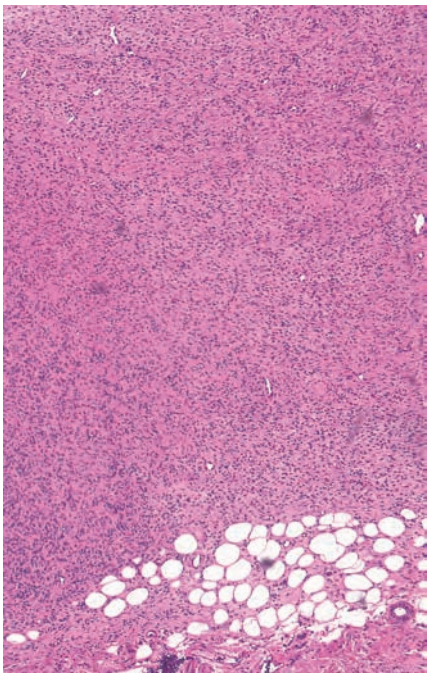

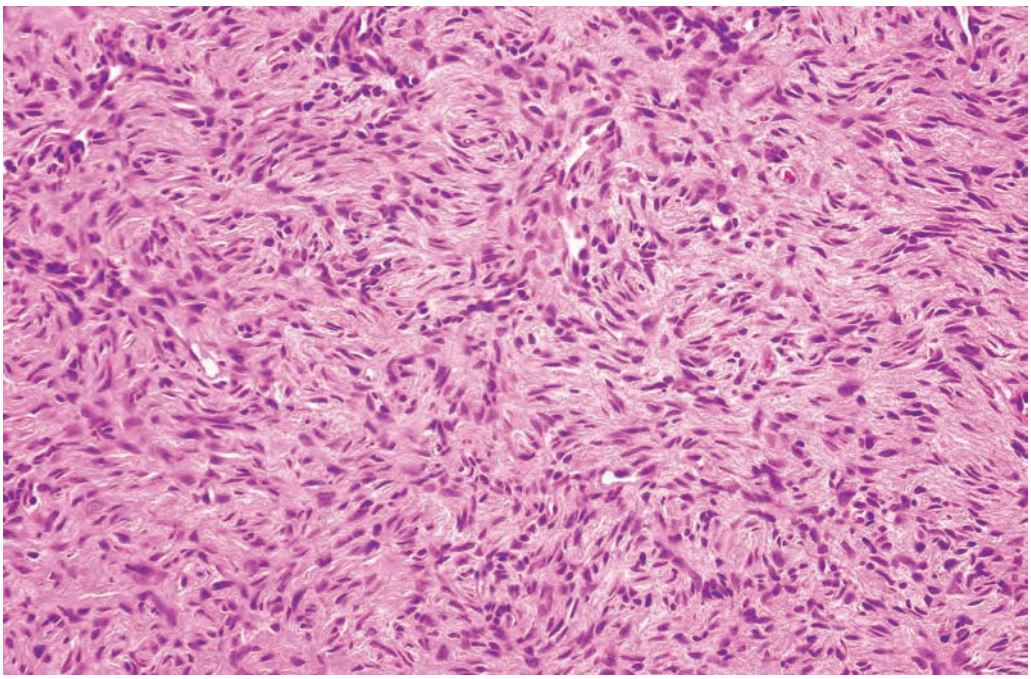

- Spindle cells (fibrocytes) filling dermis
- Cells are monomorphous and arranged in a storiform (cartwheel) pattern
- Infiltration into the fat in layered or honeycomb pattern

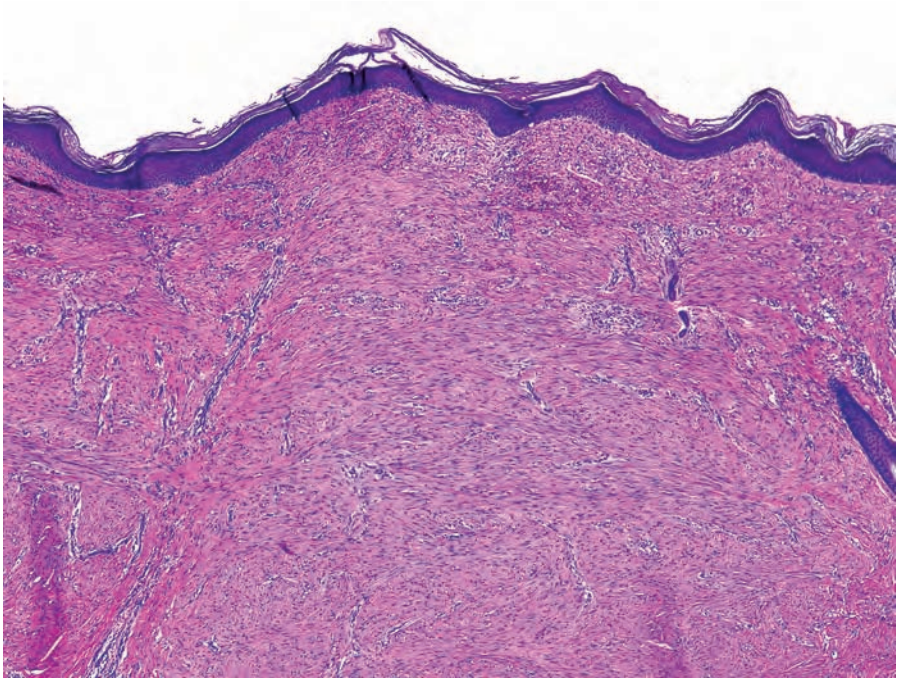

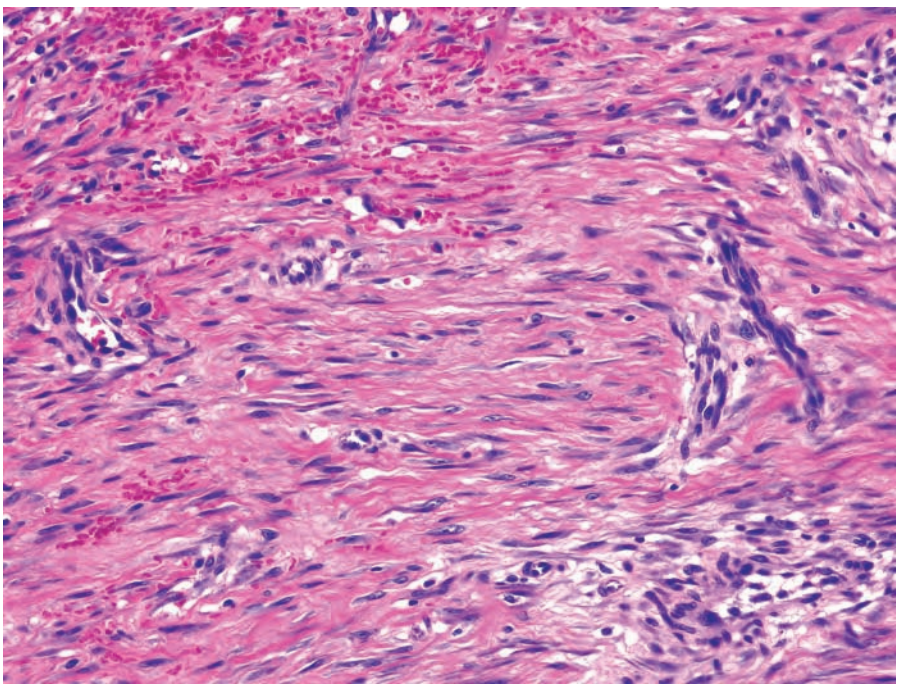

- Spindle cells (fibrocytes)
- Cells are arranged parallel to epidermis
- Vessels oriented perpendicular to epidermal surface

Scar

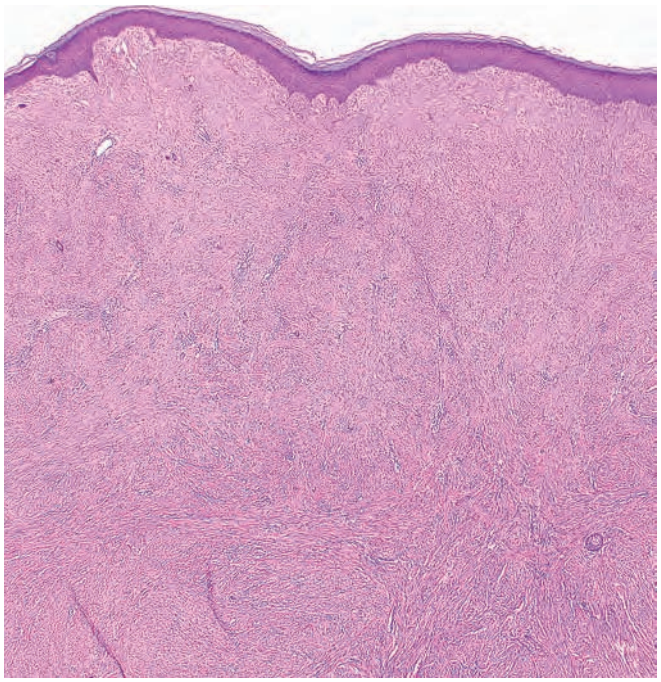

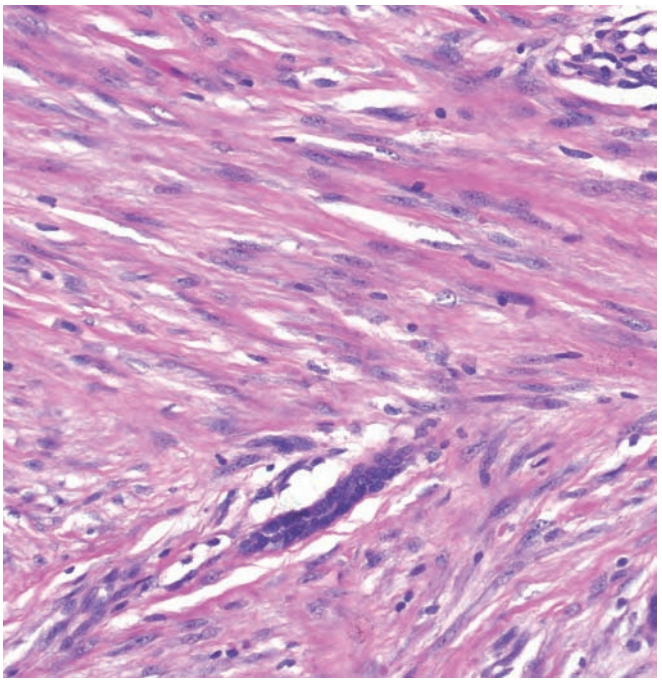

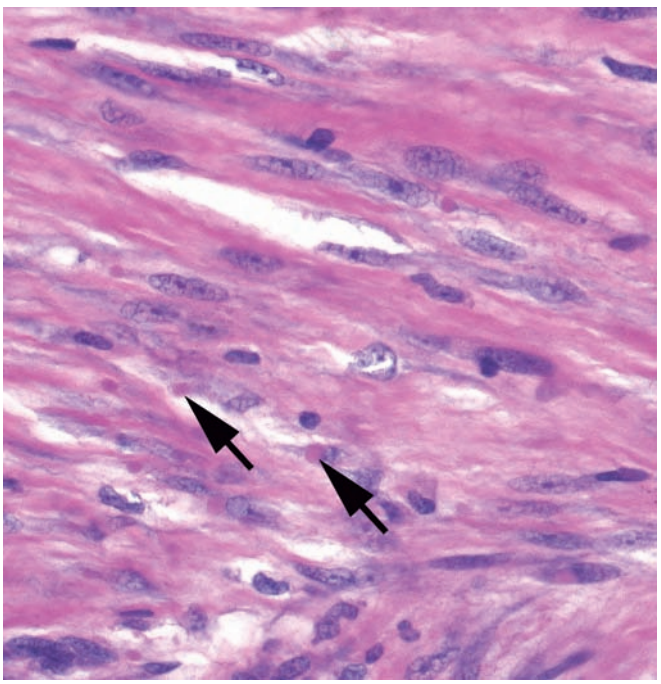

- Spindle cells (myofibroblasts)
- Cells have round pink cytoplasmic inclusions (arrows)
- Cells are arranged in long fascicles

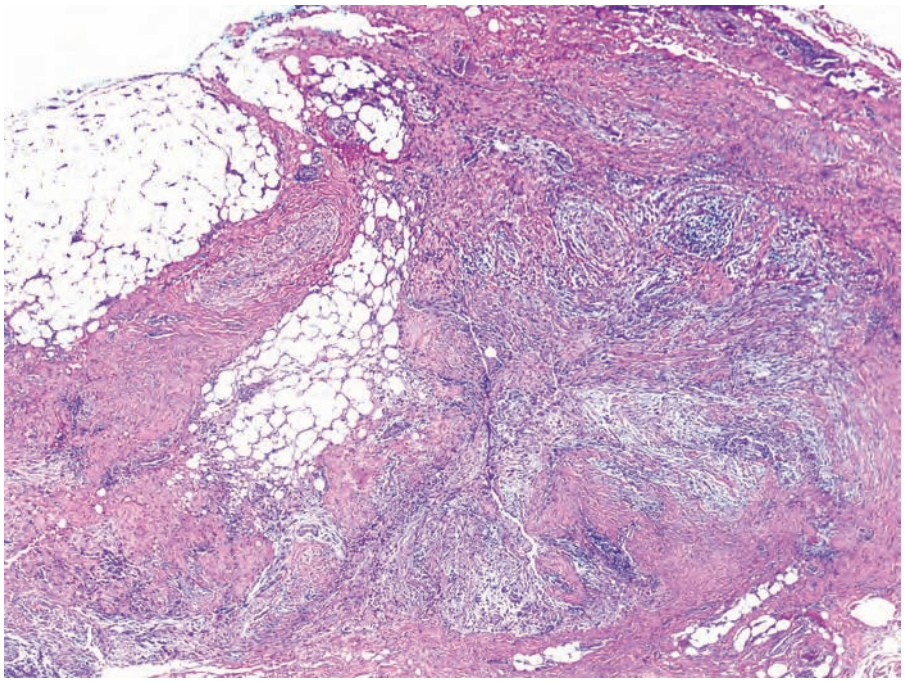

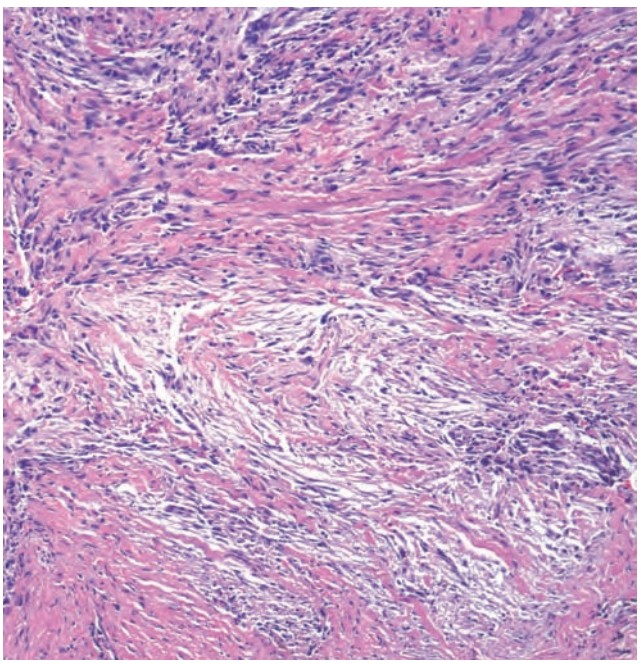

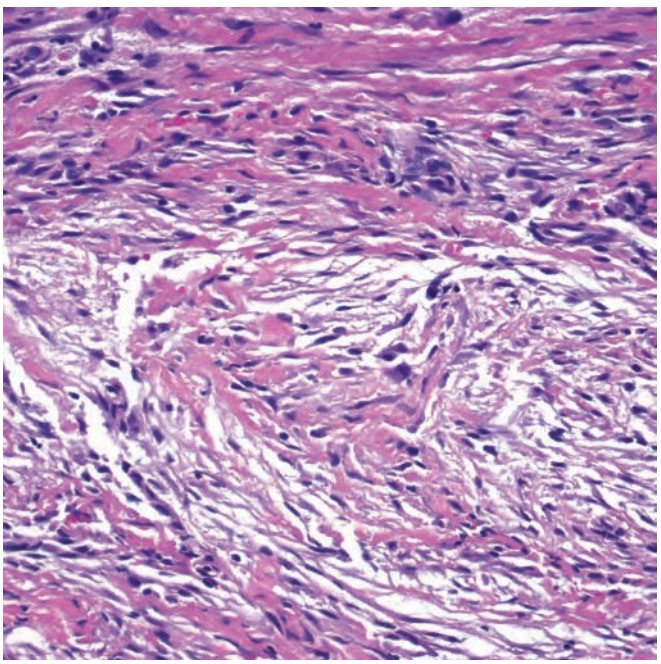

- Spindle cells (myofibroblasts)
- Myxoid areas of elongated cells with oval nuclei with tapered ends and elongated cytoplasm ("tissue-culture fibroblasts")
- Extravasated erythrocytes
- Mitoses may be seen
- Radial arrangement of blood vessels at periphery
- Deep tumor, often no epidermis present

Nodular fasciitis

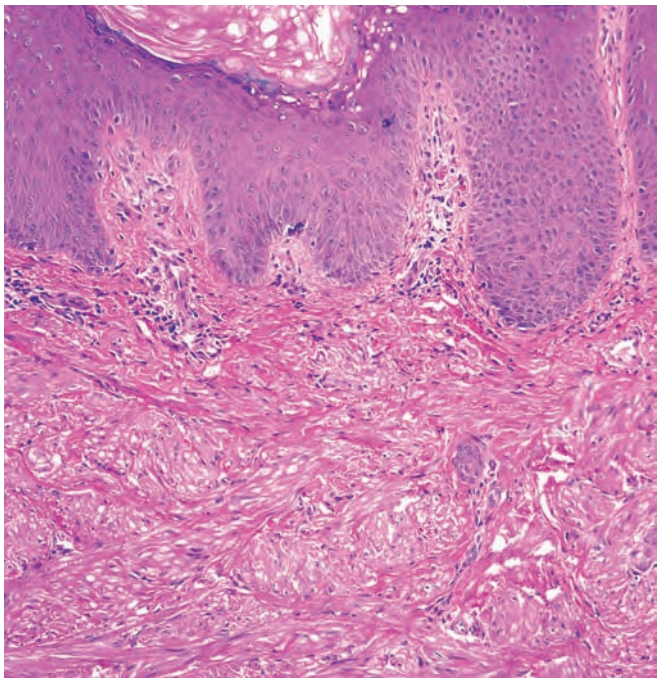

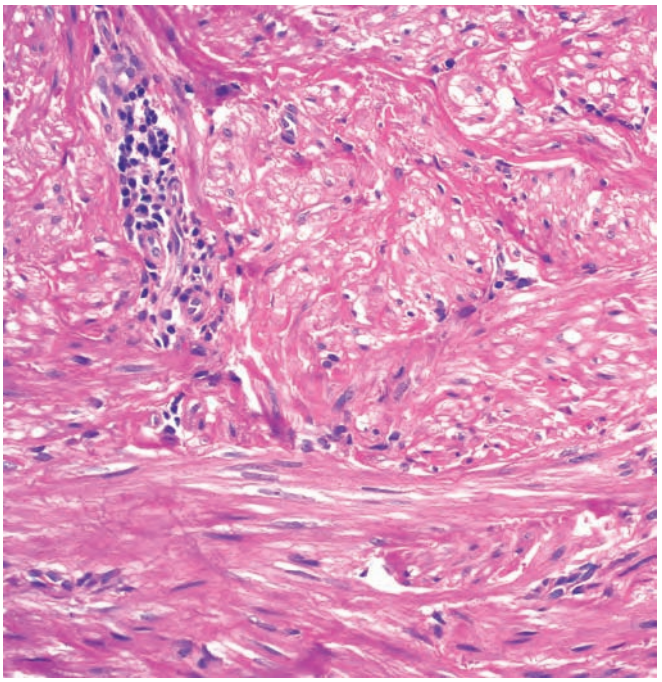

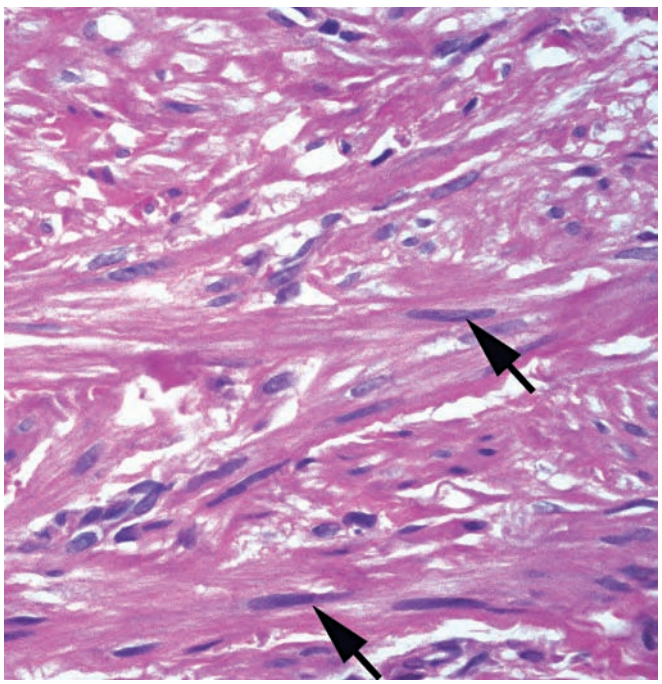

- Spindle cells (smooth muscle cells)
- Cells are arranged in fascicles which intersect at 90 degree angles
- Cigar-shaped nuclei (arrows)
- Cells cut in cross-section have perinuclear vacuoles around round nuclei

Note Normal nipple has small bundles of smooth muscle cells (same appearance as an accessory nipple, see page 78).

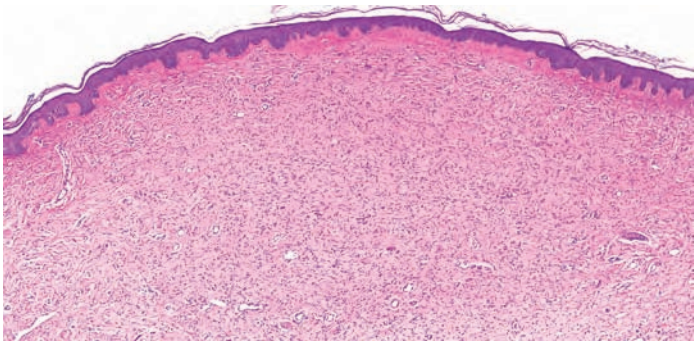

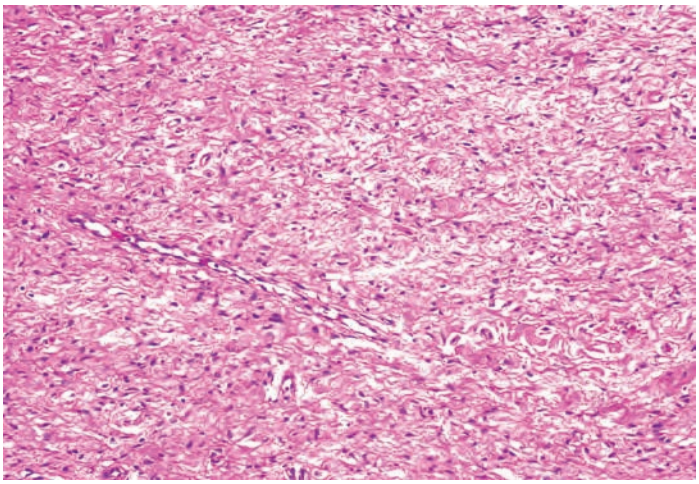

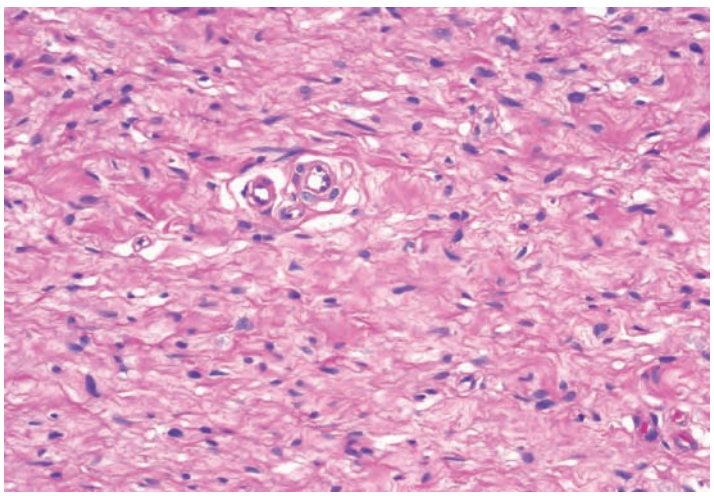

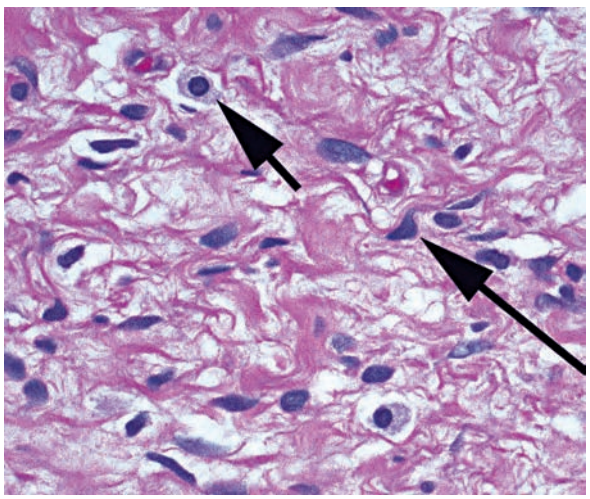

- Spindle cells (neural – pericytes)
- Cells have thin, wavy nuclei (long arrow)
- Light pink stroma
- Scattered mast cells (short arrow)
- Not encapsulated

Neurofibroma

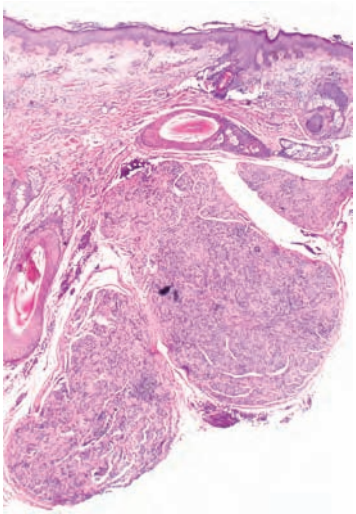

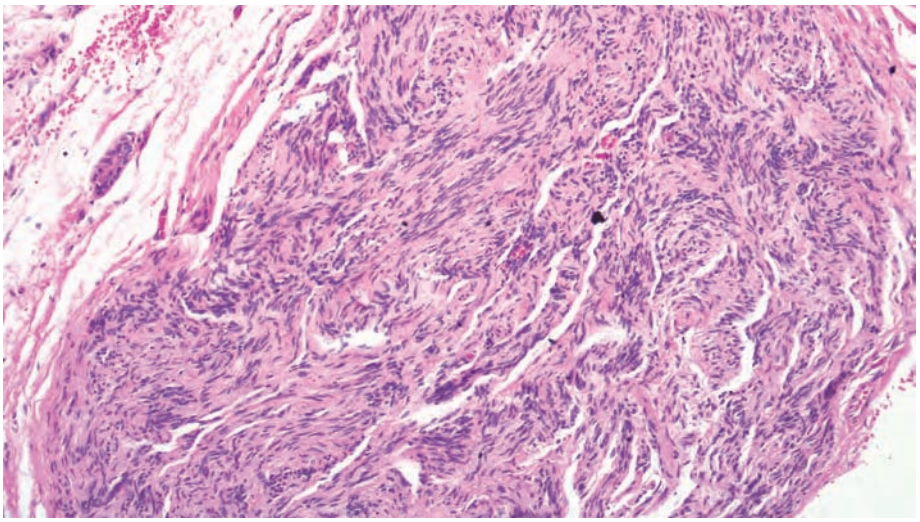

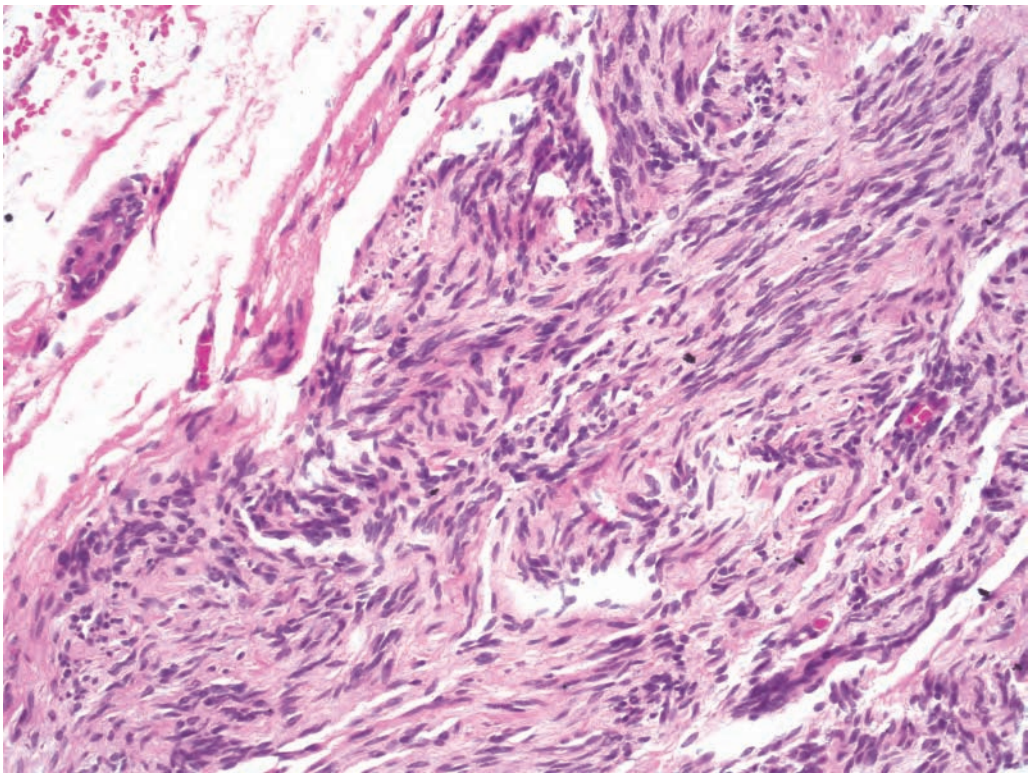

- Spindle cells (neural – Schwann cells)
- Cells are arranged in fascicles with characteristic clefting
- Often not truly encapsulated

Palisaded encapsulated neuroma

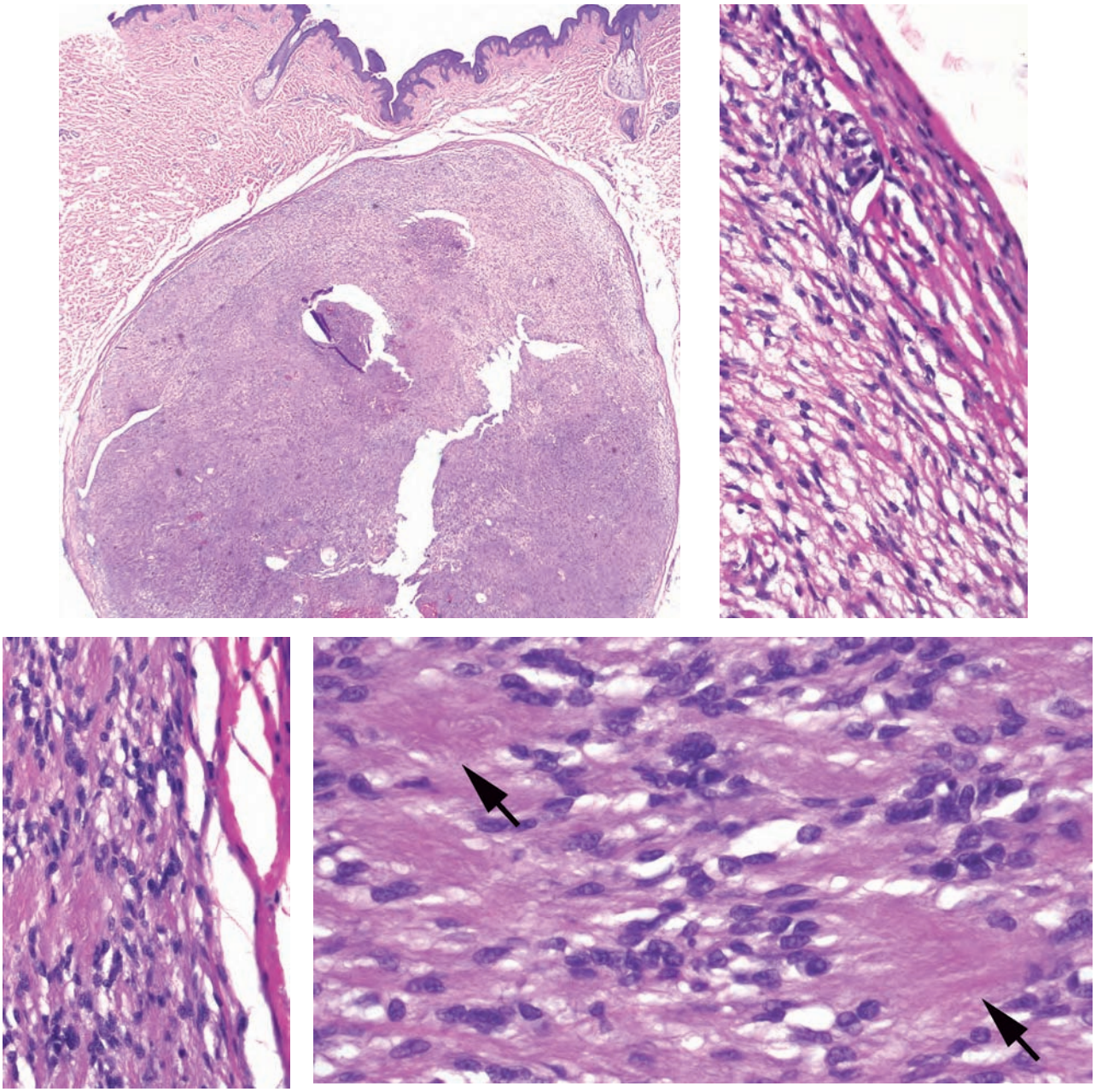

- Spindle cells (neural – Schwann cells)
- Antoni A areas – cellular
- Antoni B areas – myxoid
- Verocay bodies (arrows) – palisaded arrangement of nuclei around a central pink area of collagen
- Encapsulated
- Vascular spaces may be very dilated
- Often a deep tumor with no epidermis present

Schwannoma

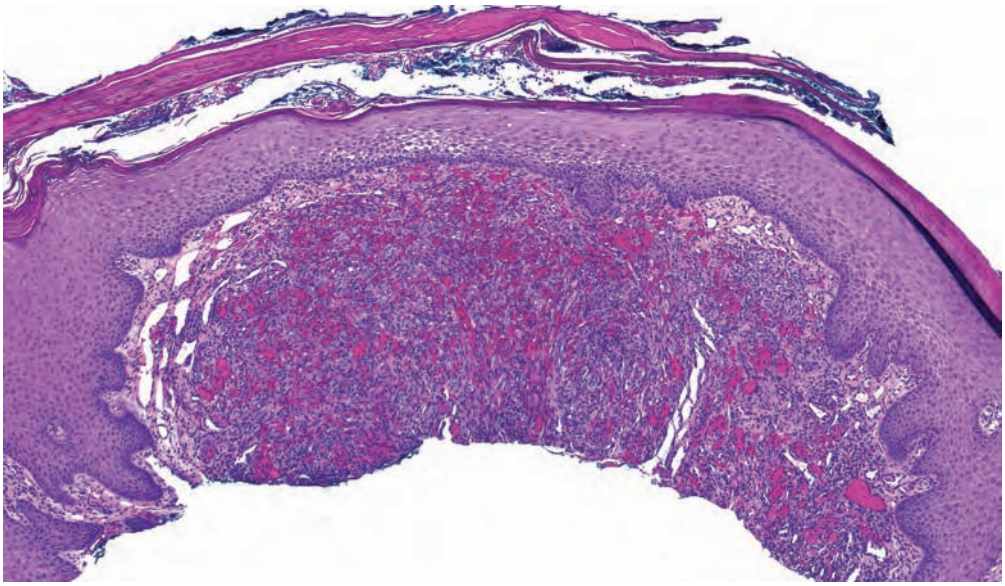

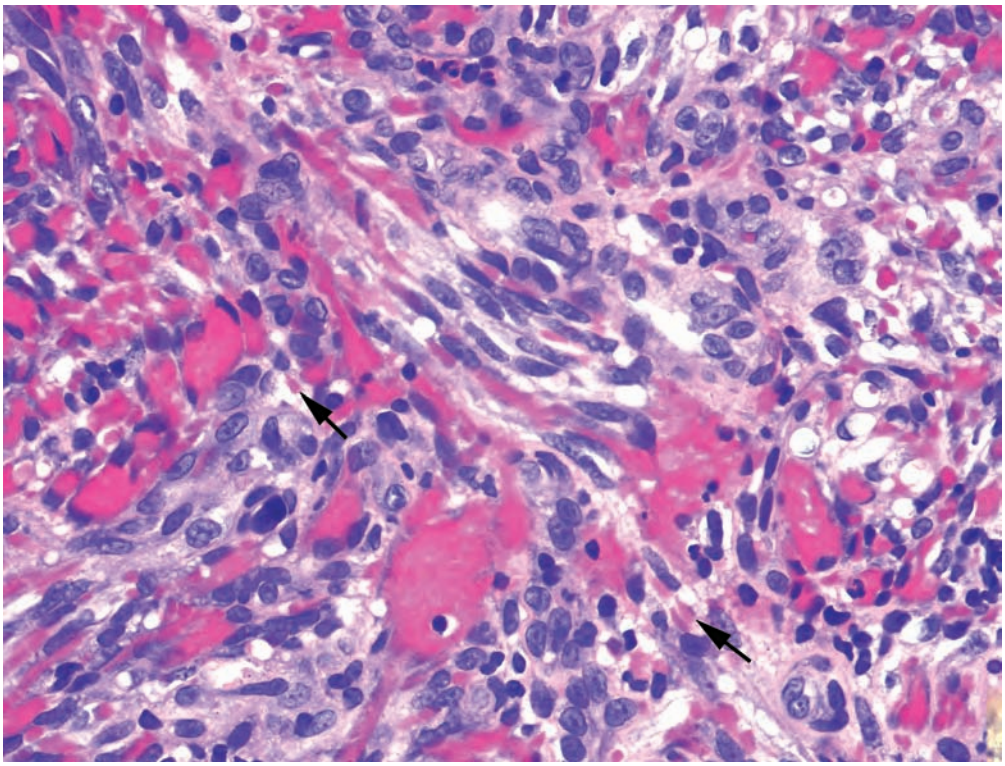

- Spindle cells, hyperchromatic (endothelial cells)
- Interspersed erythrocytes
- Intracytoplasmic pink globules (erythrophagolysosomes) (arrows)

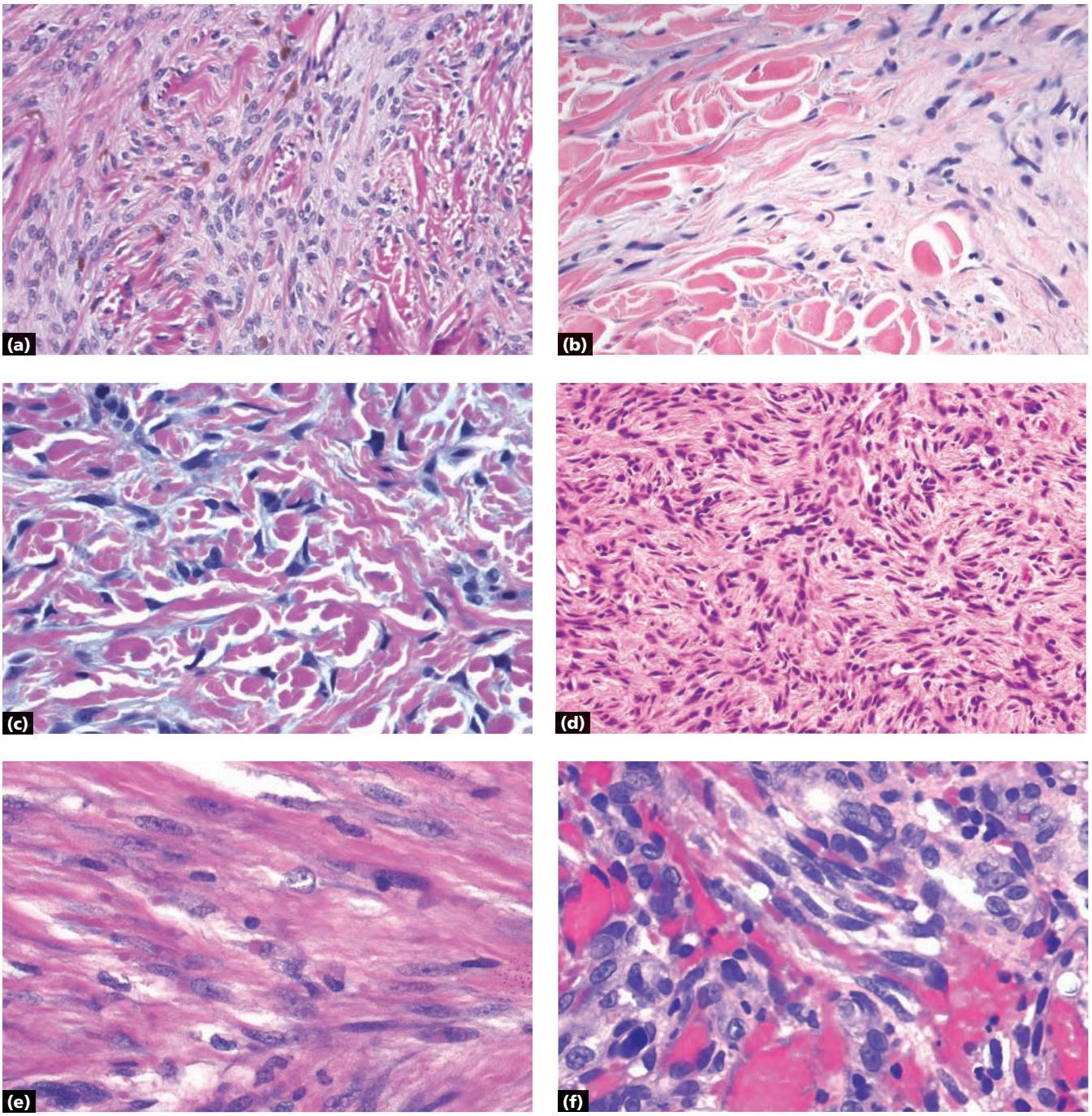

a Blue nevus, cellular: spindled melanocytes with fine melanin pigment in the cytoplasm; fascicular arrangement
b Desmoplastic melanoma: spindled atypical melanocytes in fascicles; often overlying melanoma in situ
c Dermatofibroma: fibrohistiocytic cells with collagen entrapment at periphery, epidermal acanthosis
d Dermatofibrosarcoma protuberans: monomorphous fibroblastic spindle cells in cartwheel arrangement; infiltration into fat
e Infantile digital fibromatosis: spindled myofibroblasts with bright pink cytoplasmic inclusions
f Kaposi sarcoma, nodular: atypical spindled endothelial cells with interspersed erythrocytes and intracytoplasmic erythrophagolysosomes

Key differences

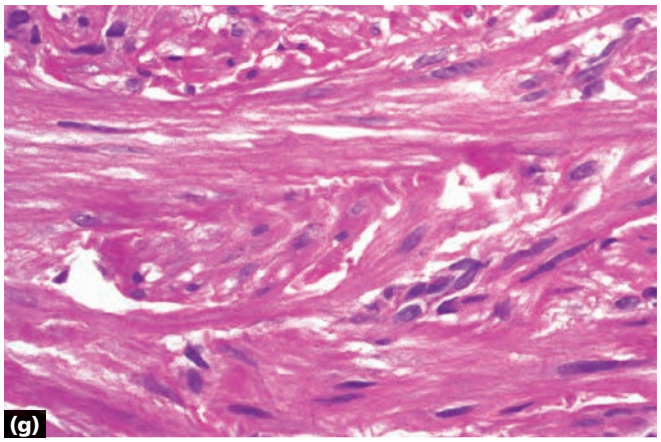

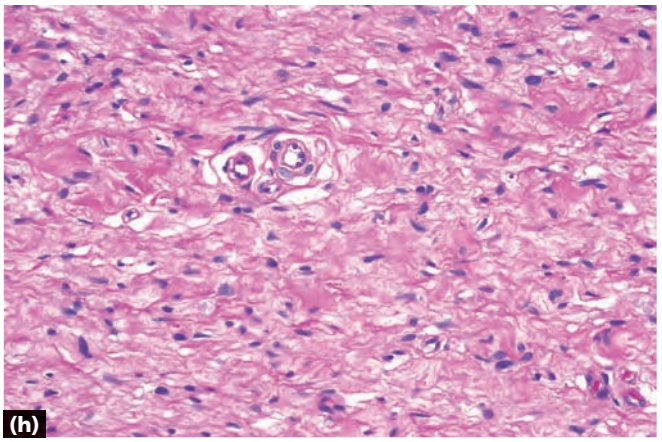

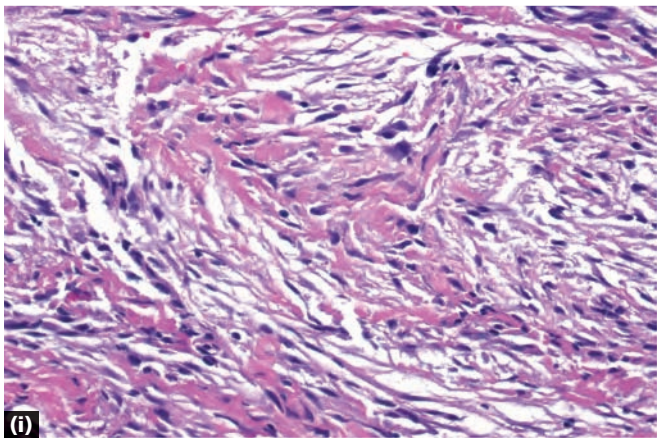

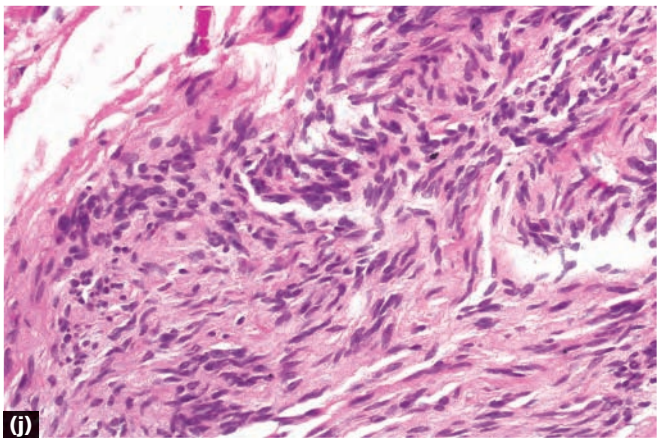

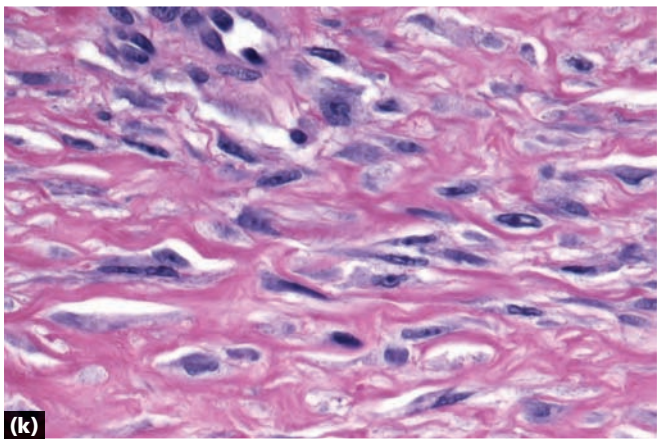

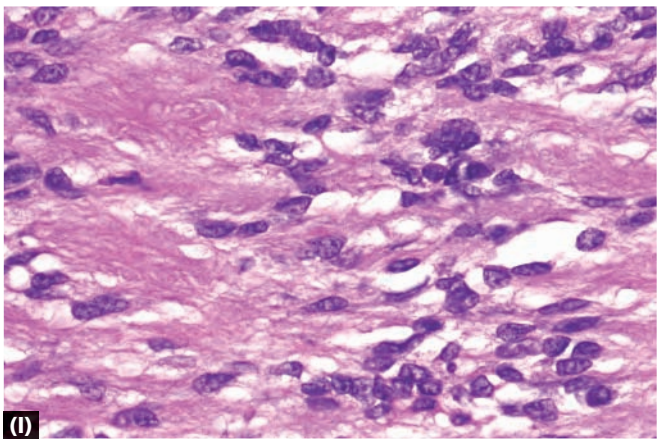

g Leiomyoma: smooth muscle cells (cigar-shaped nuclei with perinuclear clear space) in long fascicles
h Neurofibroma: pericytes with wavy nuclei, mast cells, bubble-gum pink stroma
i Nodular fasciitis: elongated myofibroblasts in loose stroma, extravasated erythrocytes, often deep in the fat
j Palisaded encapsulated neuroma: clefts between collections of spindle cells (Schwann cells) with nuclear palisading
k Scar: spindle cells (fibroblasts) arranged parallel to epidermal surface
l Schwannoma: Schwann cells with particular architectural features – Verocay bodies, myxoid areas, encapsulation

Key differences, *continued*

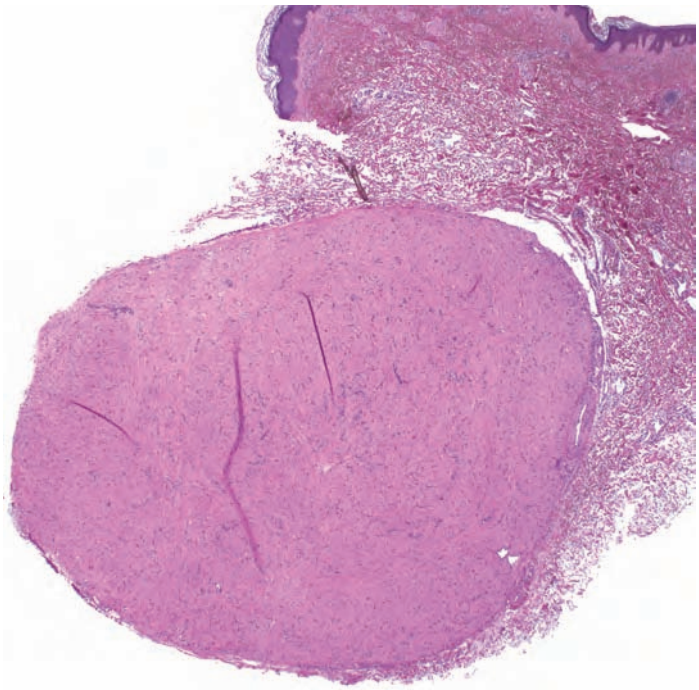

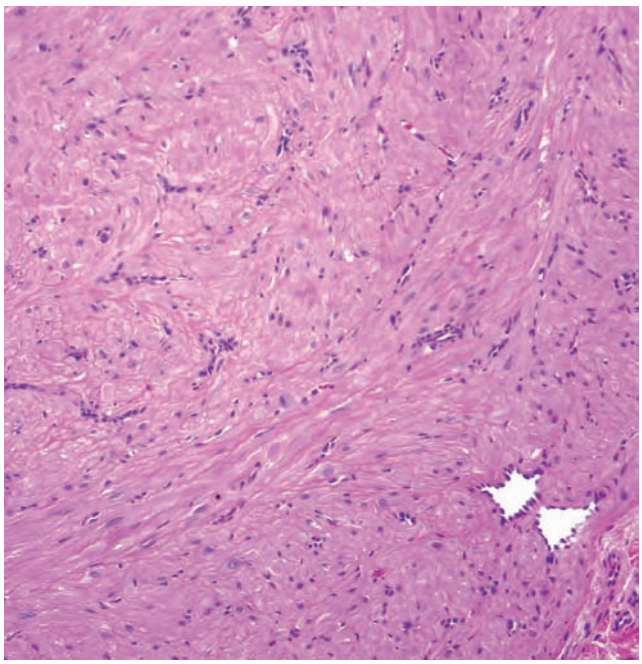

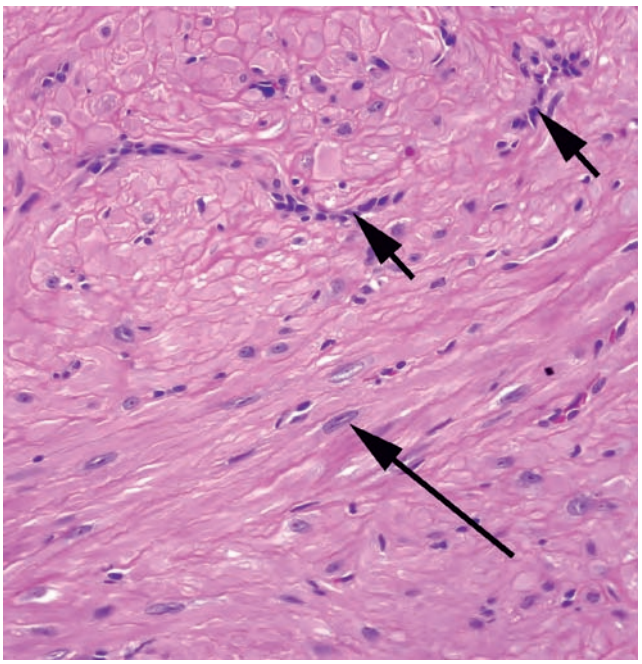

- Endothelial cells (suggestion of vessels)
- Circular pink ball in dermis
- Scar-like appearance
- Mass composed of smooth muscle cells (cigar-shaped nuclei – long arrow) with compressed vessels (short arrows) (sometimes dilated)

Angioleiomyoma

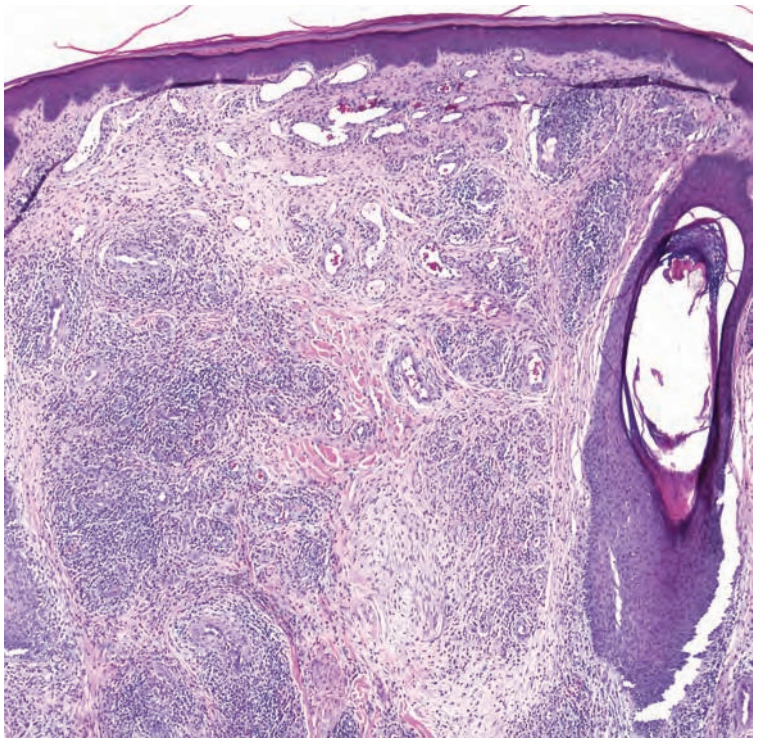

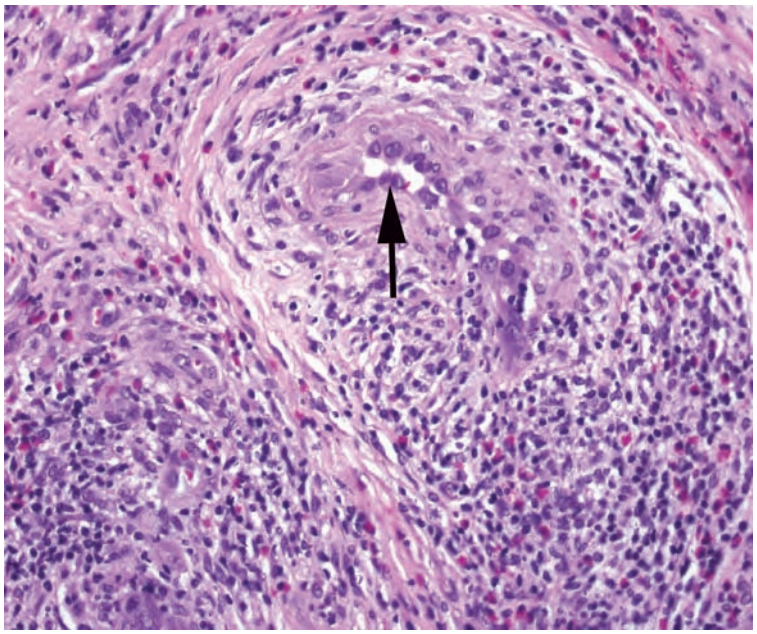

- Endothelial cells (and vessels)
- Numerous vessels with epithelioid ("hobnail") endothelial cells (arrow) surrounded by inflammation
- Clusters of epithelioid endothelial cells may mimic granulomas
- Eosinophils may be prominent

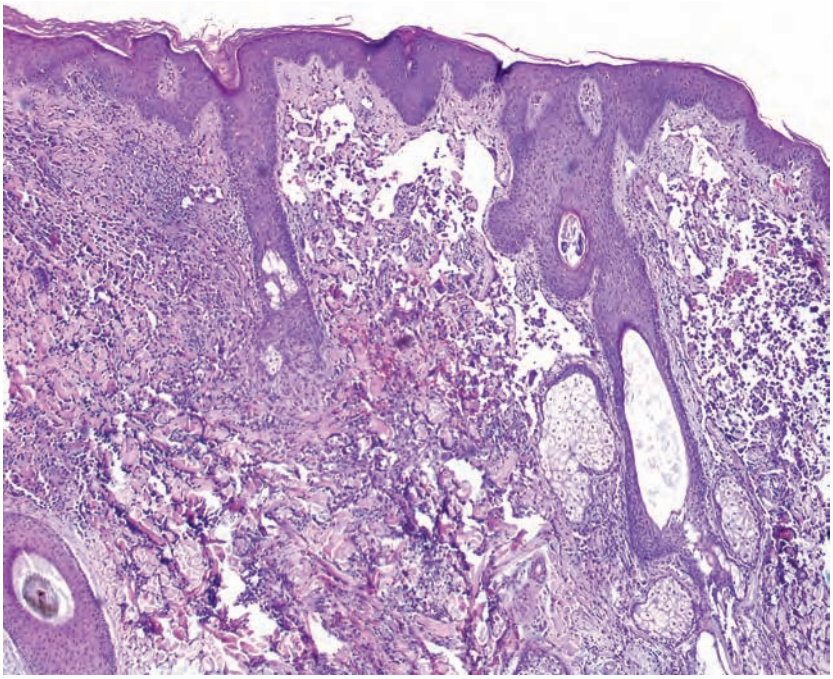

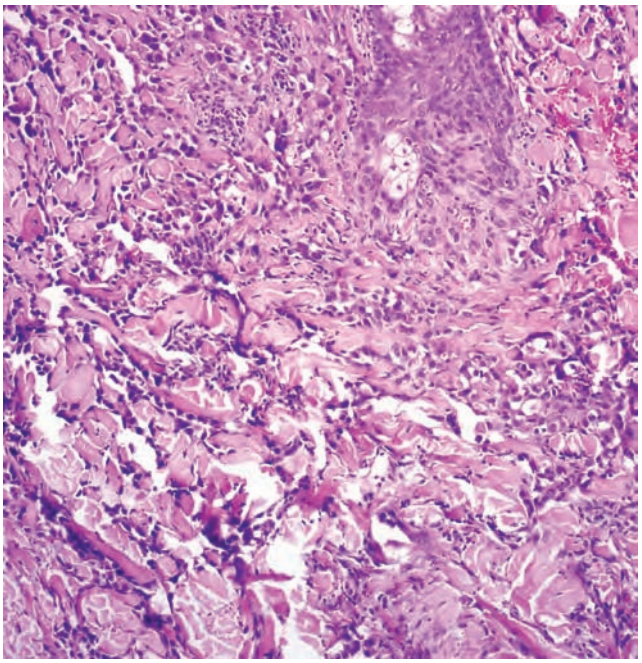

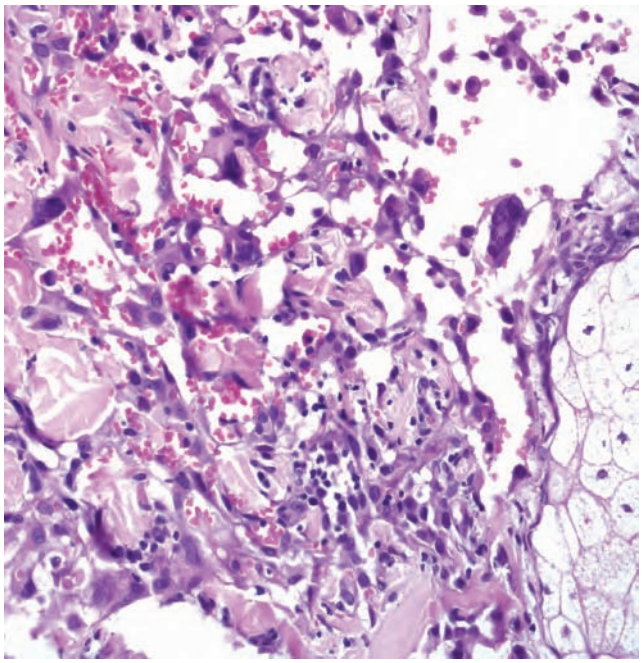

- Endothelial cells (suggestion of vessels)
- Dissection of collagen bundles by a maze-like arrangement of vessels lined by atypical cells
- Papillary endothelial fronds (papillated clusters of endothelial cells)
- Deeply infiltrative

Angiosarcoma

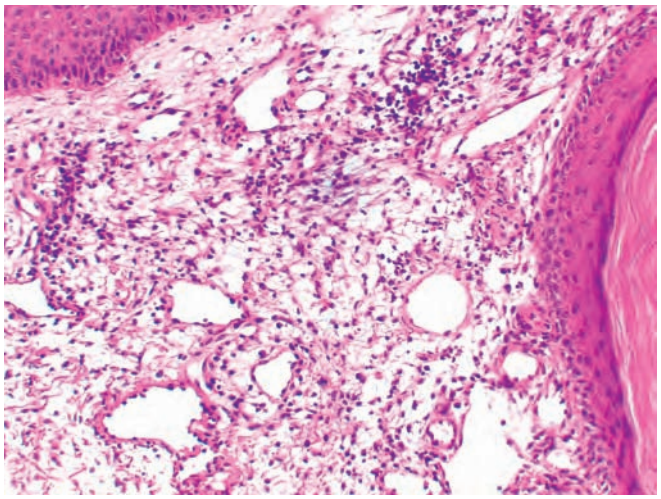

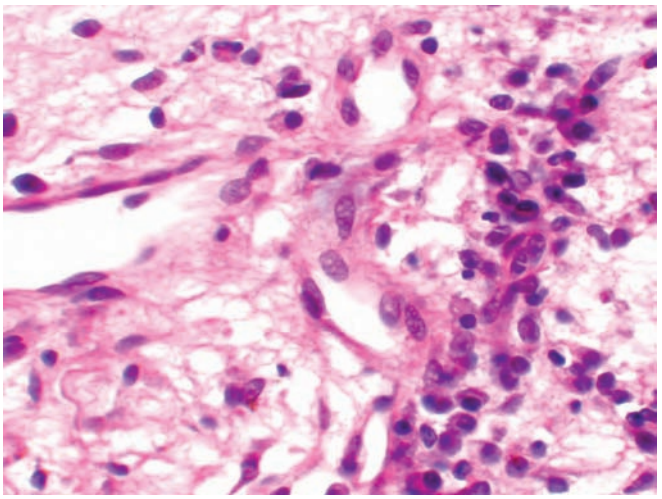

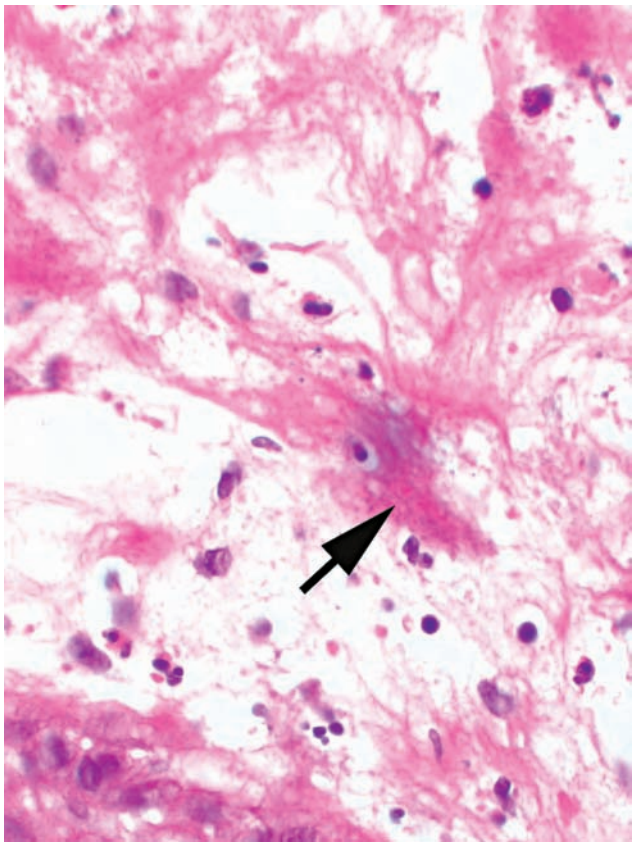

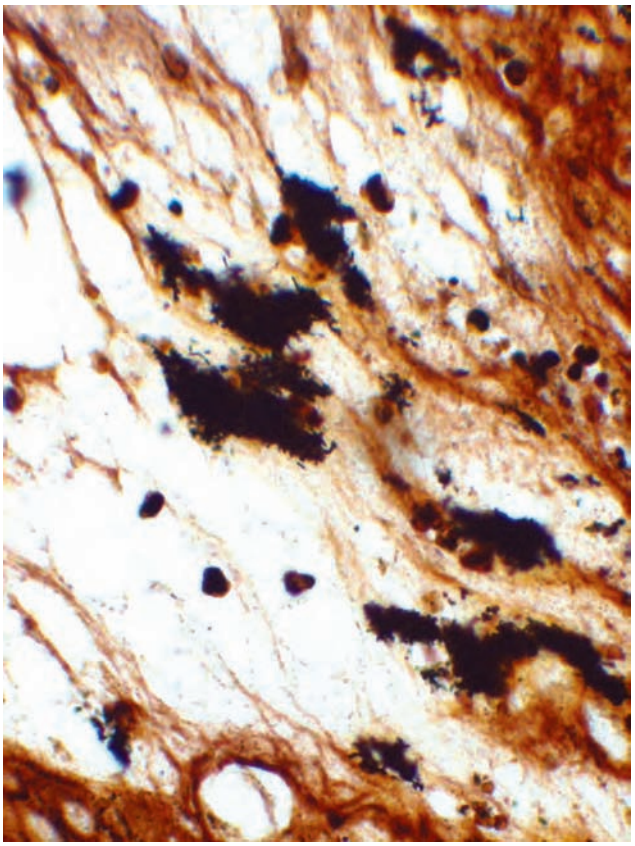

- Endothelial cells (and vessels)
- Superficial vessels surrounded by plasma cells and "clouds" of organisms (arrow) that stain with silver

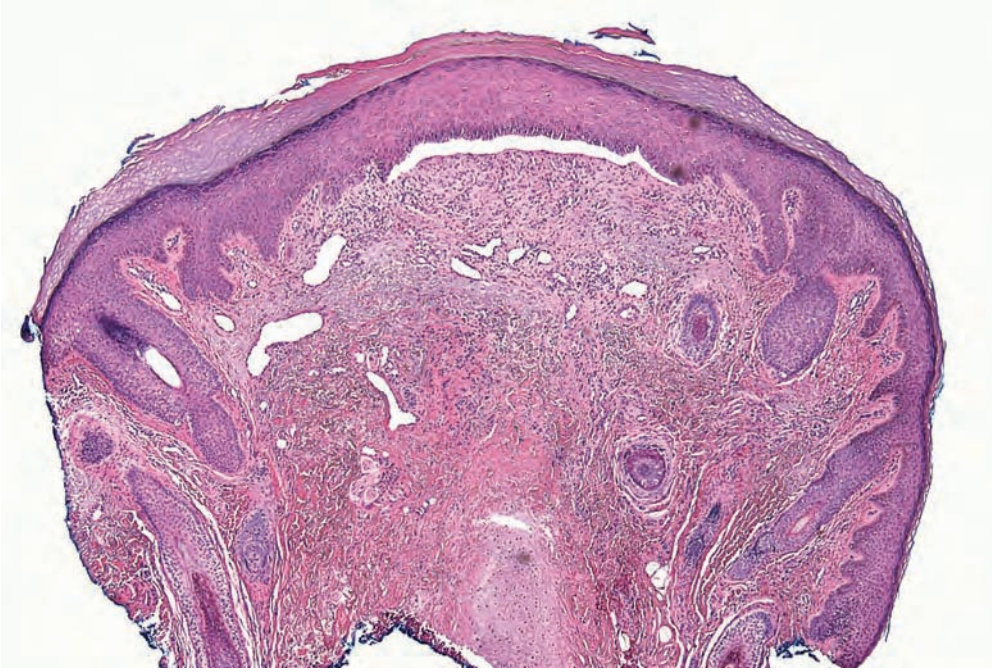

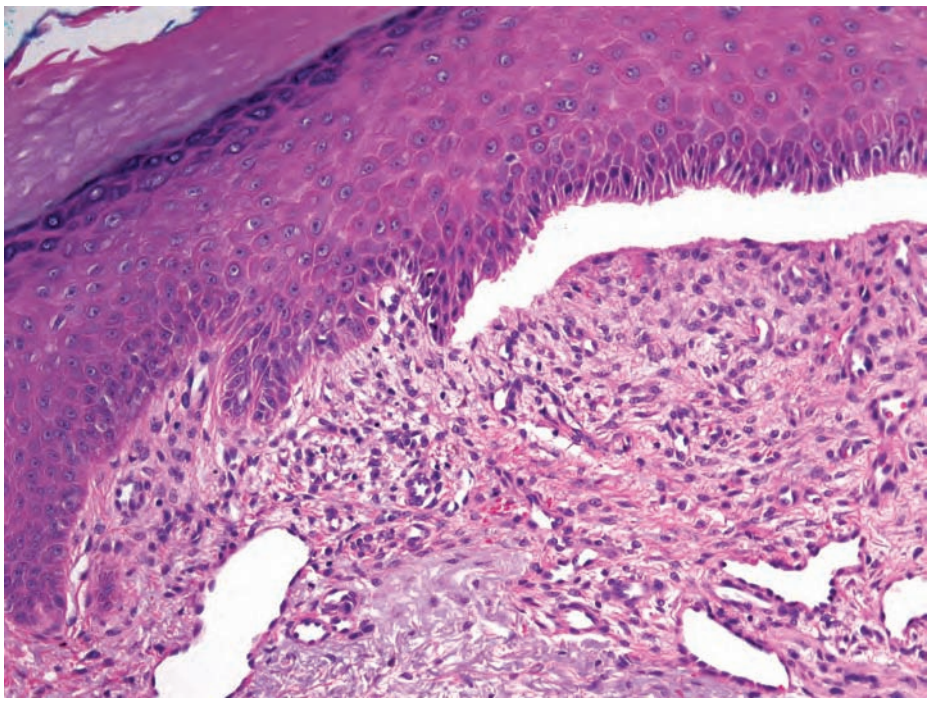

- Endothelial cells (and vessels)
- Hyperkeratosis
- Central erosion/ulceration of epidermis with underlying pink fibrin and flanking vessels
- Vascular ectasia with plump endothelial cells
- Cartilage may be present beneath fibrin

Chondrodermatitis nodularis helicis

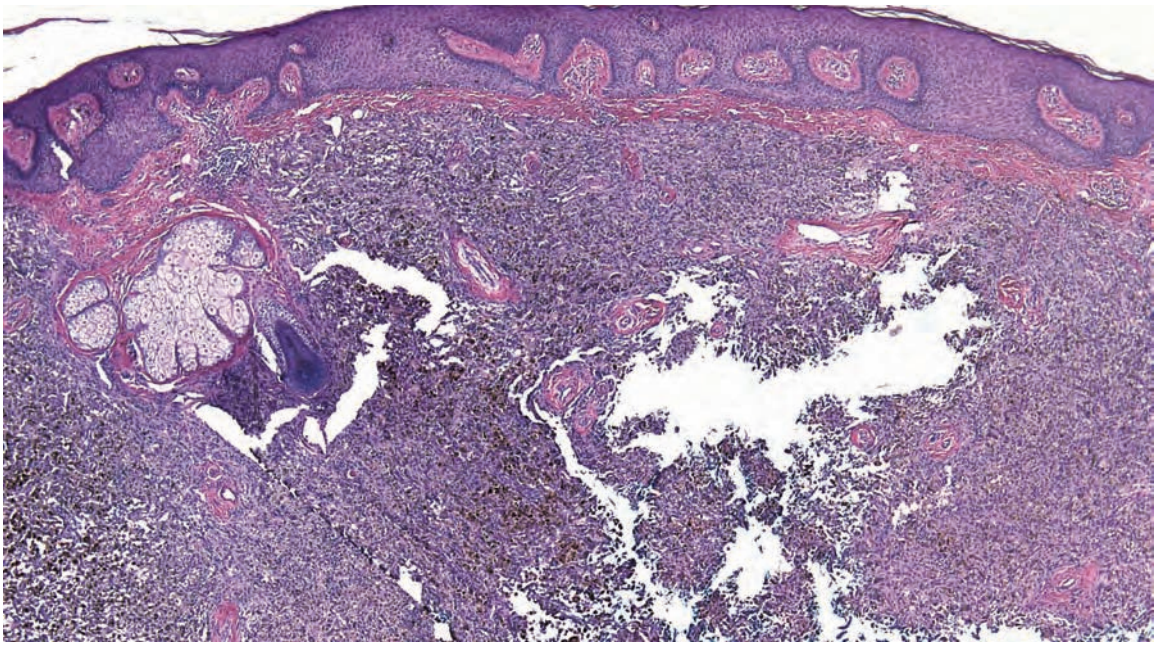

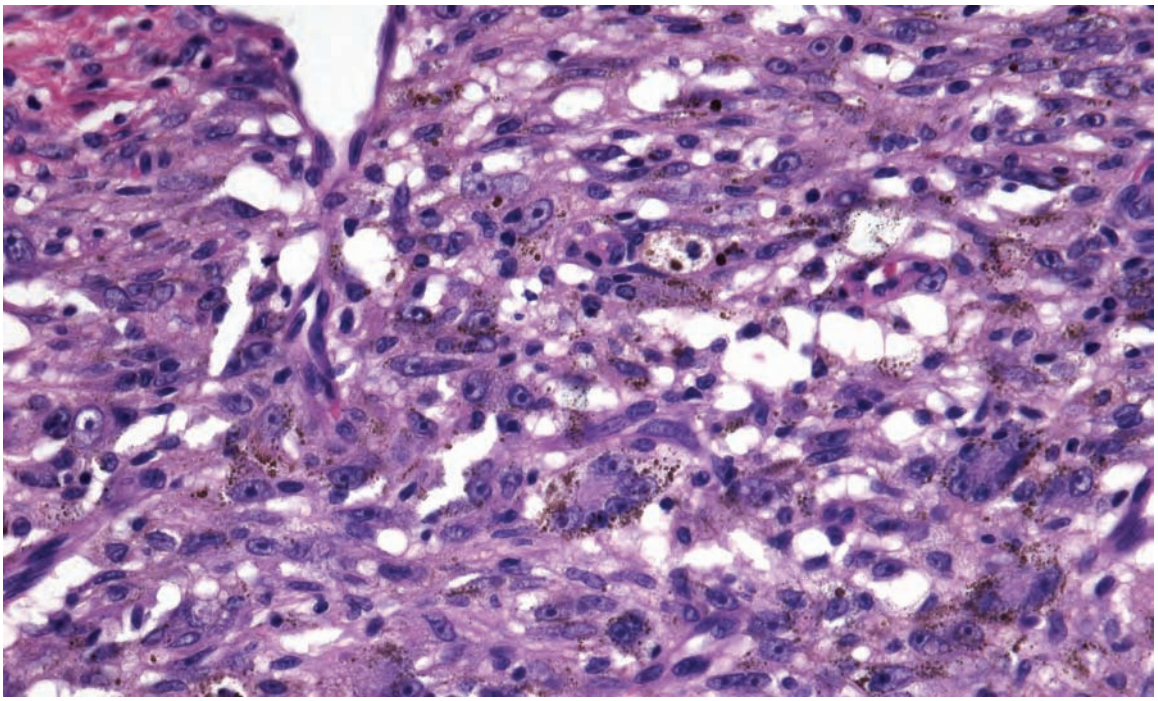

- Suggestion of vessels
- Epidermal acanthosis
- Touton giant cells with rim of hemosiderin pigment as well as spindle and epithelioid cells

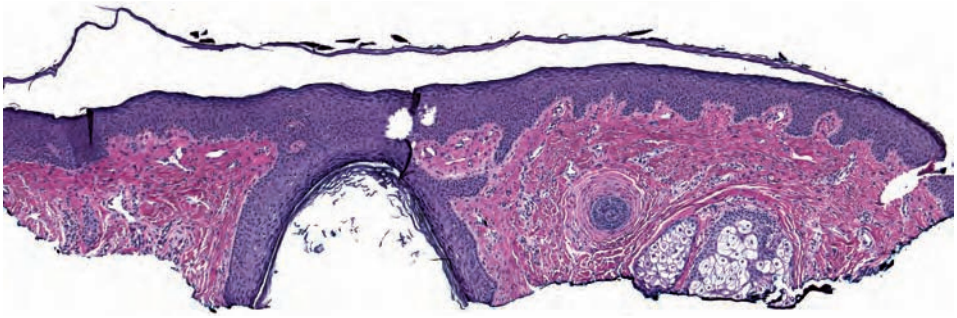

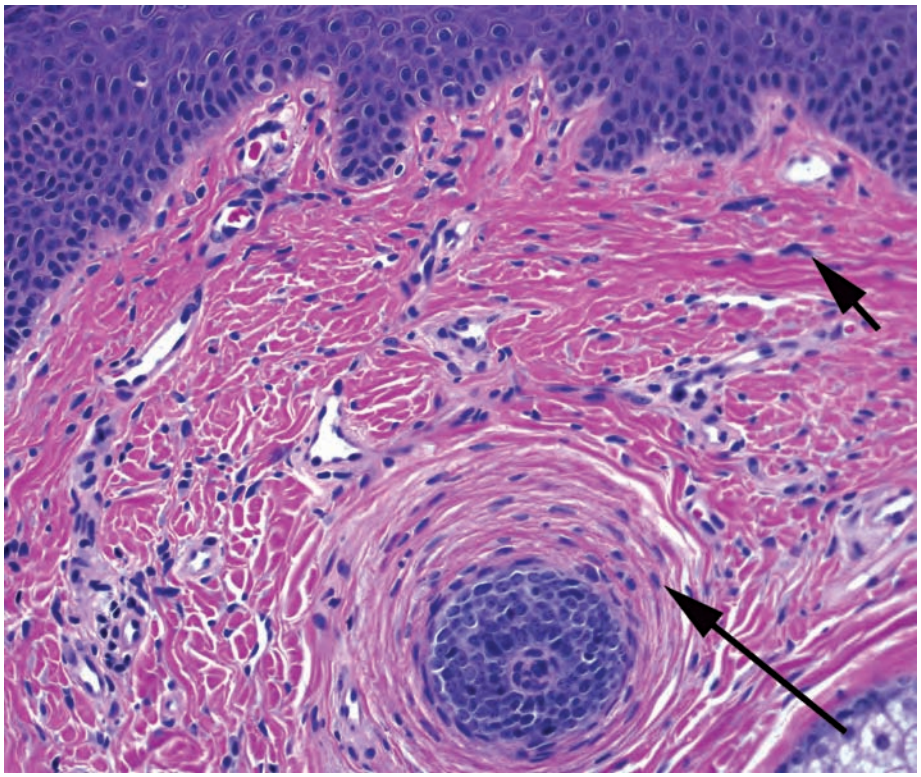

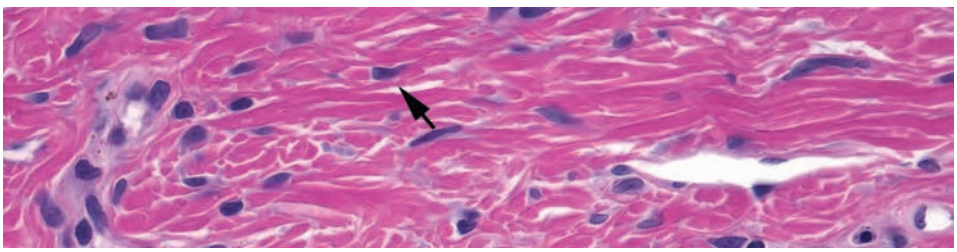

- Endothelial cells (and vessels)
- Fibrotic stroma
- Concentric fibrosis around vessels/adnexae (long arrow)
- Stellate fibroblasts (short arrow)

Fibrous papule

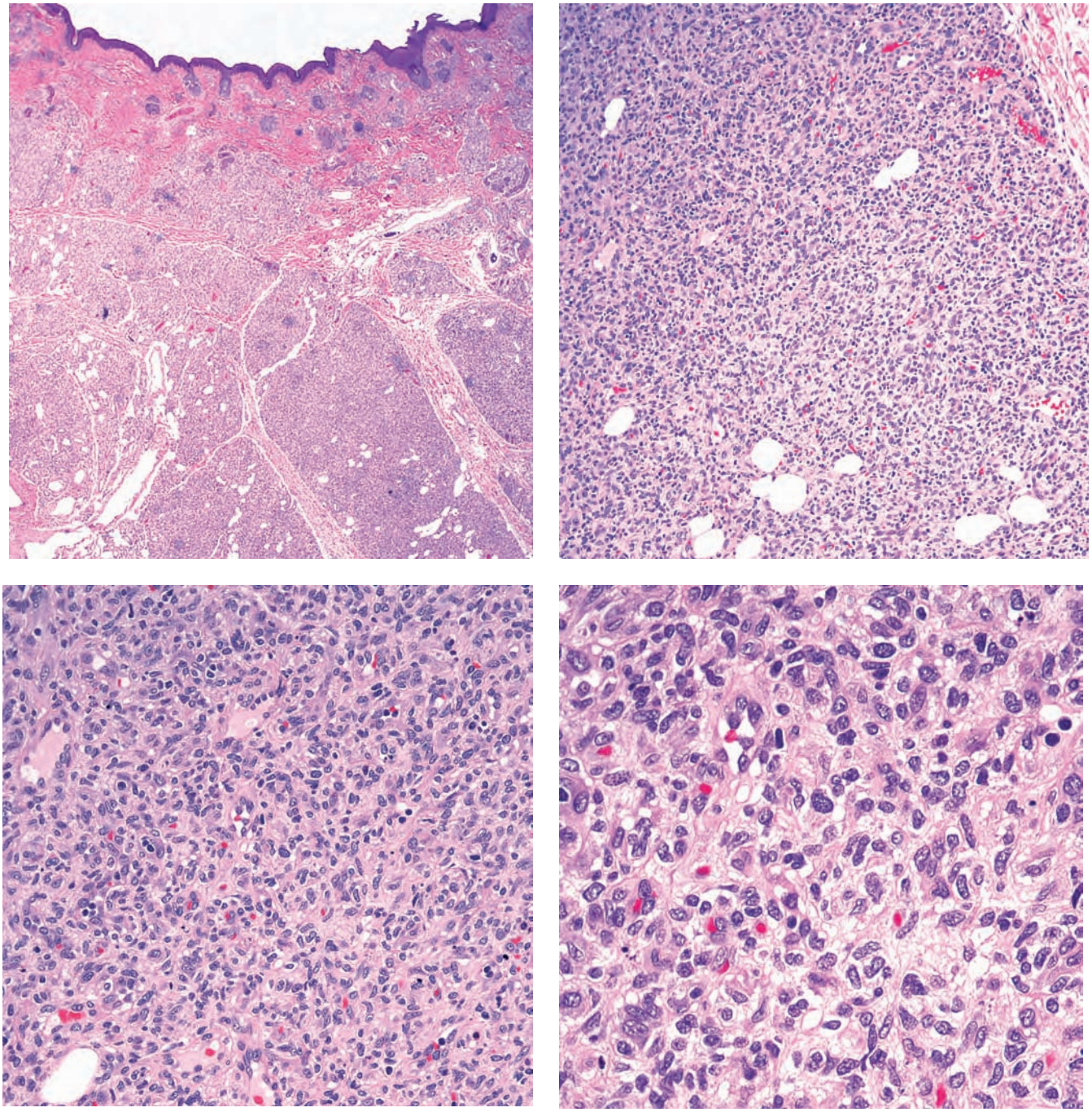

- Endothelial cells (suggestion of vessels)
- Lobules of small blue cells
- Scattered spaces containing erythrocytes within the lobules

Infantile hemangioma

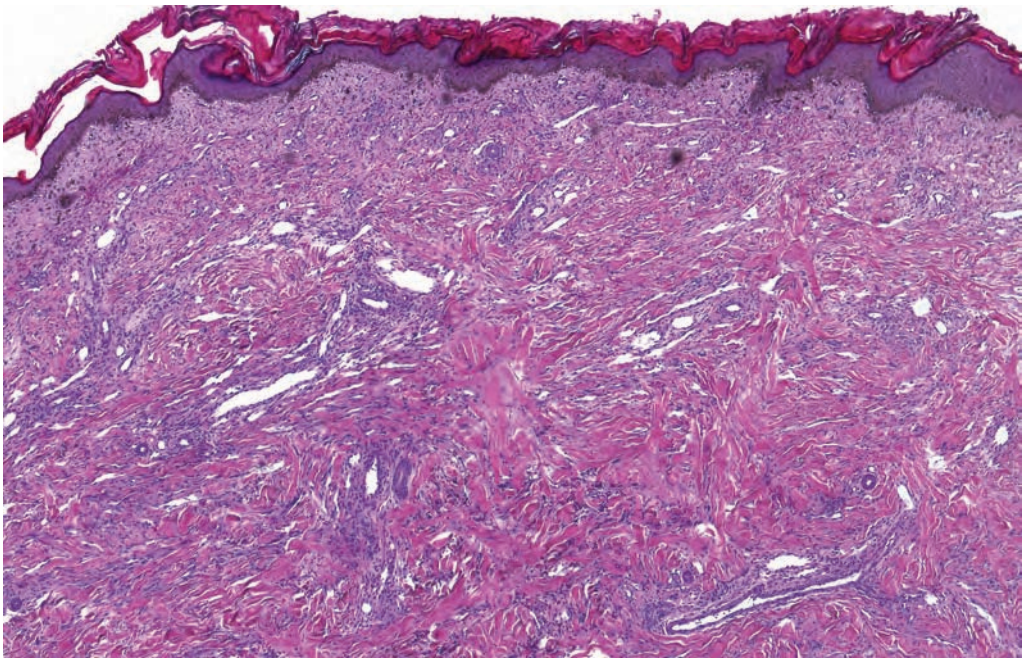

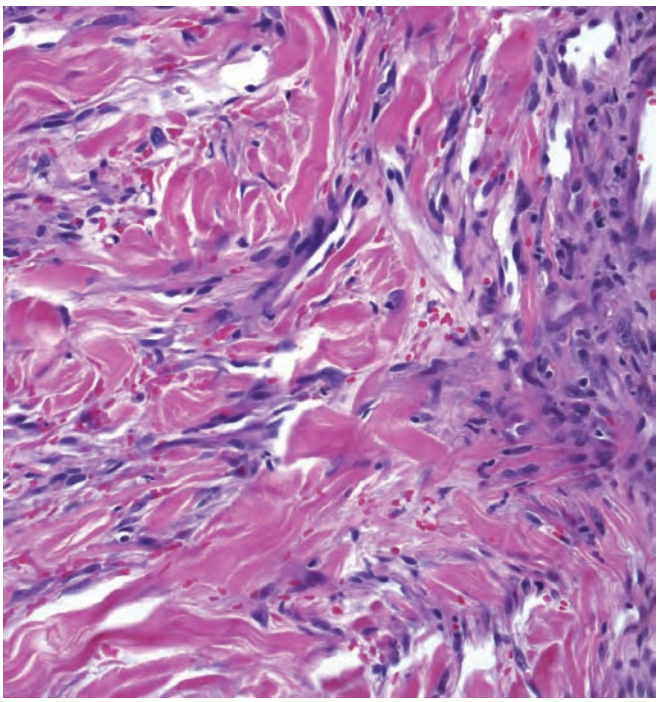

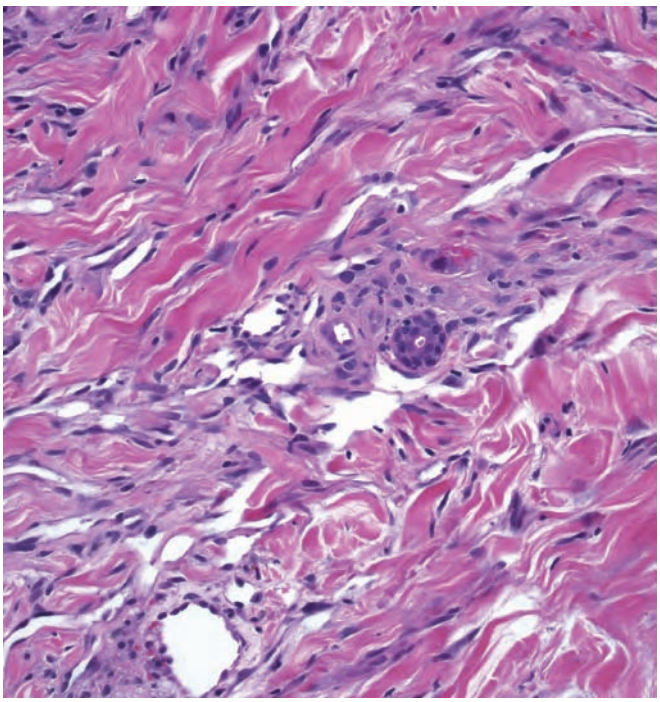

- Endothelial cells (suggestion of vessels)
- Vessels forming around other vessels (promontory sign)
- Vessels may be lined by inconspicuous endothelial cells

Kaposi sarcoma, patch/plaque

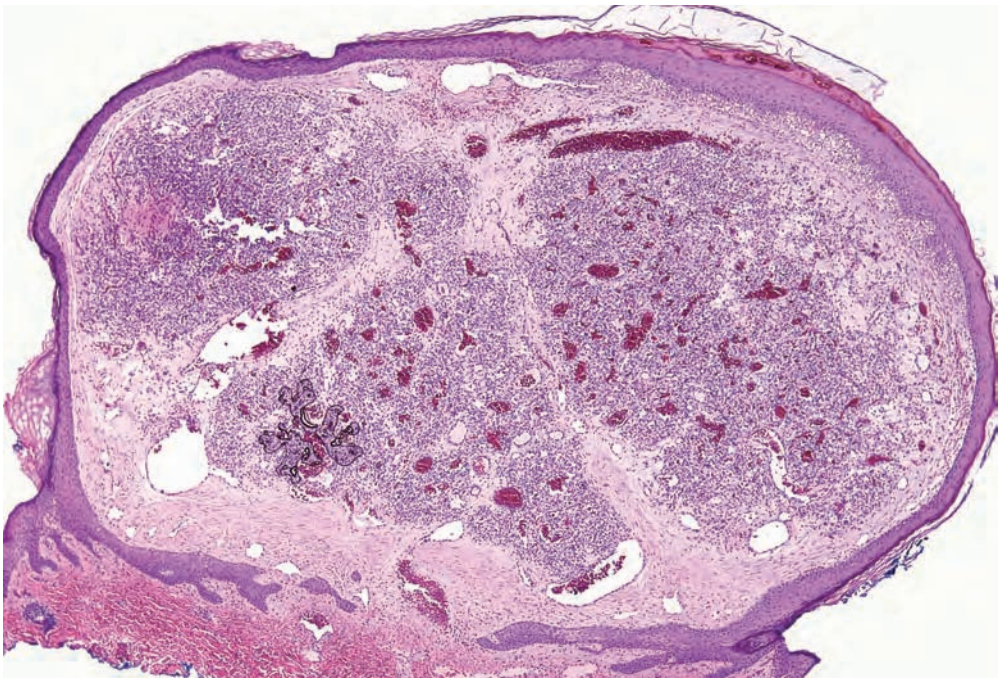

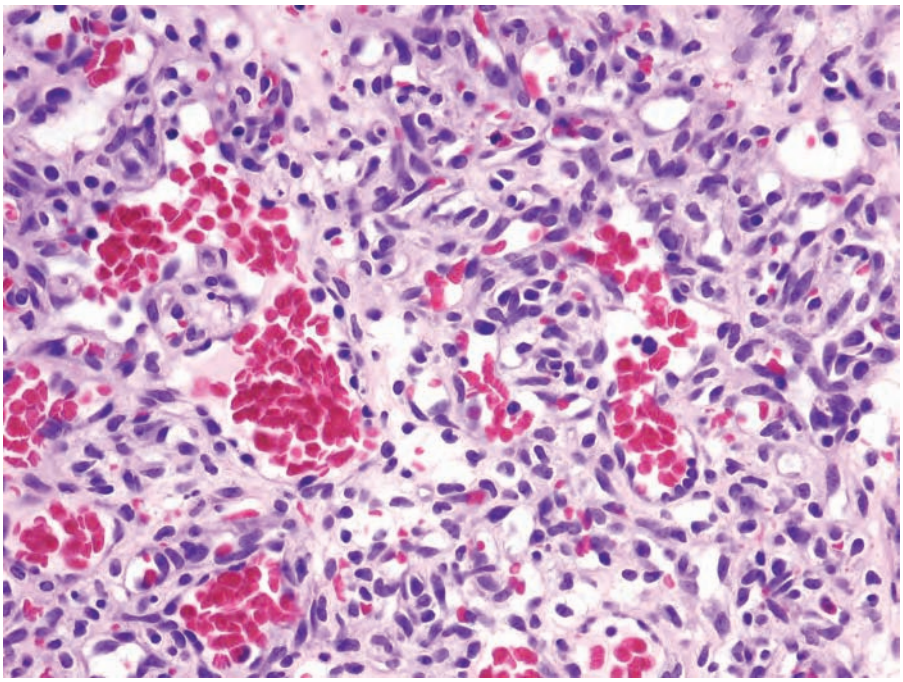

- Endothelial cells (and vessels)
- Lobules of dilated vessels embedded in loose stroma with inflammatory cells

Pyogenic granuloma

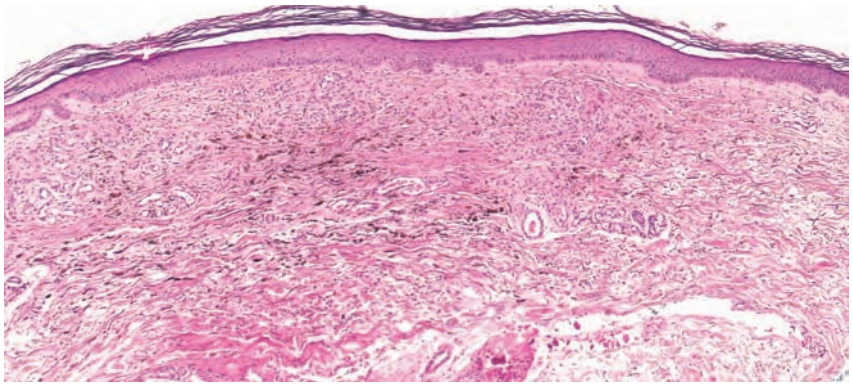

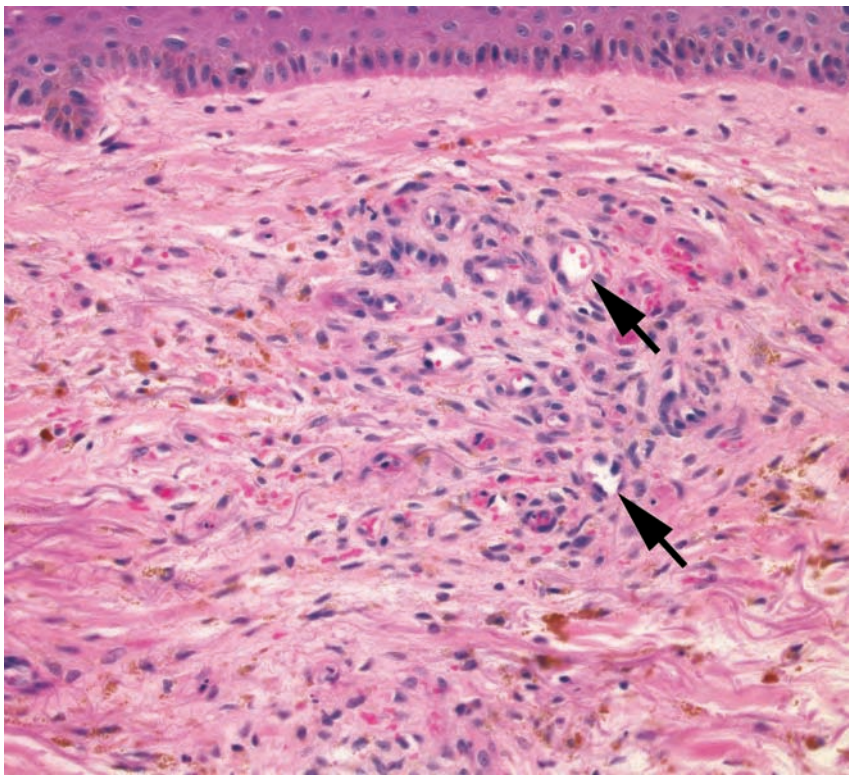

- Endothelial cells (and vessels)
- Hyperkeratosis
- Variable spongiosis
- Small caliber thick-walled capillaries in clusters in the upper dermis (arrows)
- Hemosiderin

Stasis dermatitis

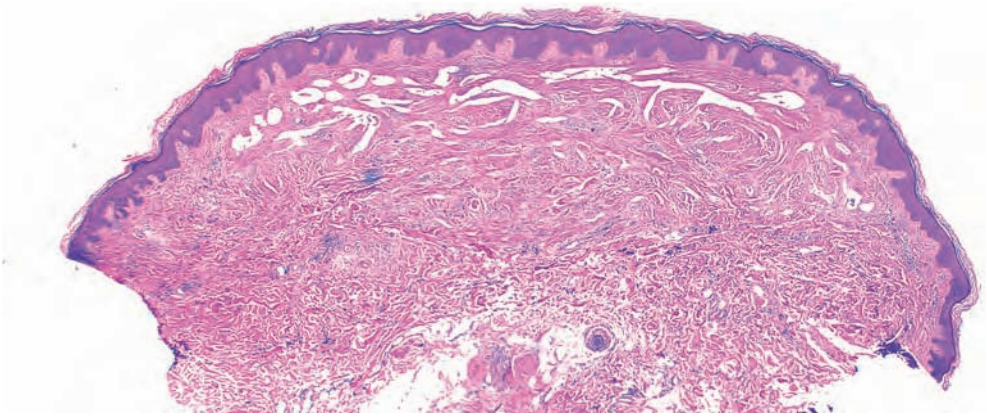

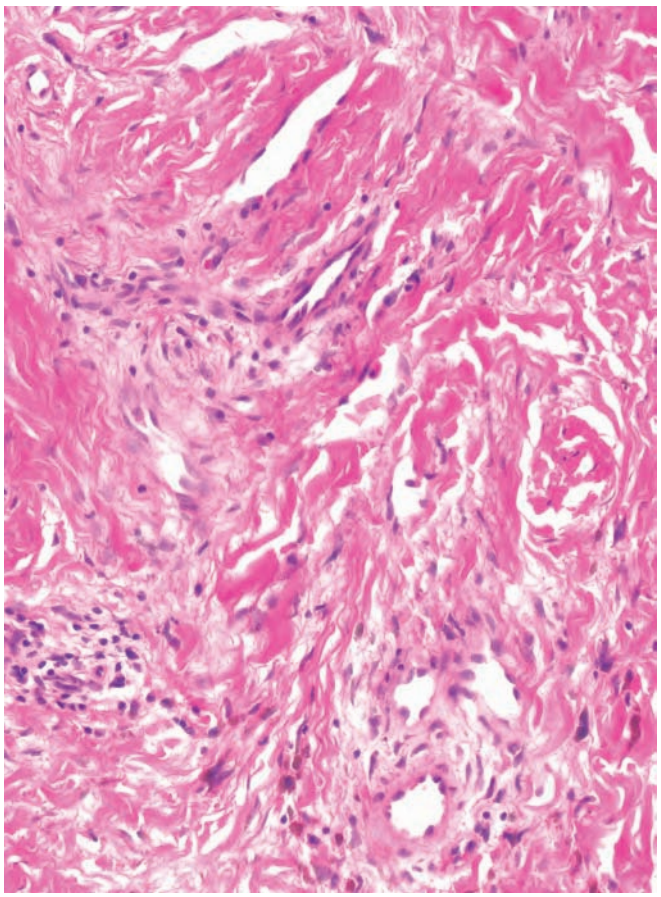

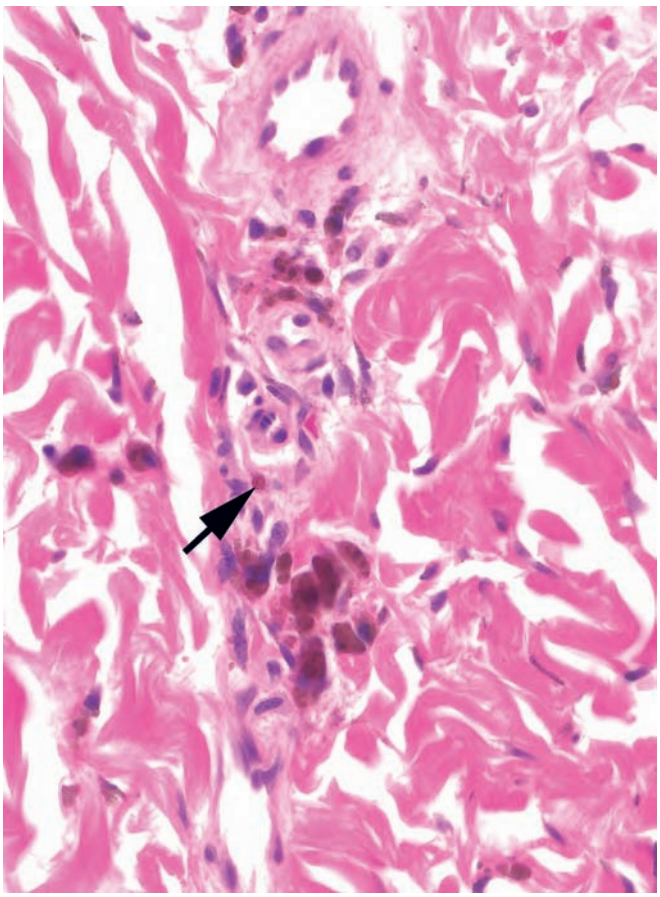

- Endothelial cells (and vessels)
- Somewhat wedge-shaped arrangement of vessels
- Biphasic with slightly dilated vessels centrally and compressed vessels at periphery
- Hemosiderin (arrow) around the peripheral vessels

Targetoid hemosiderotic (hobnail) hemangioma

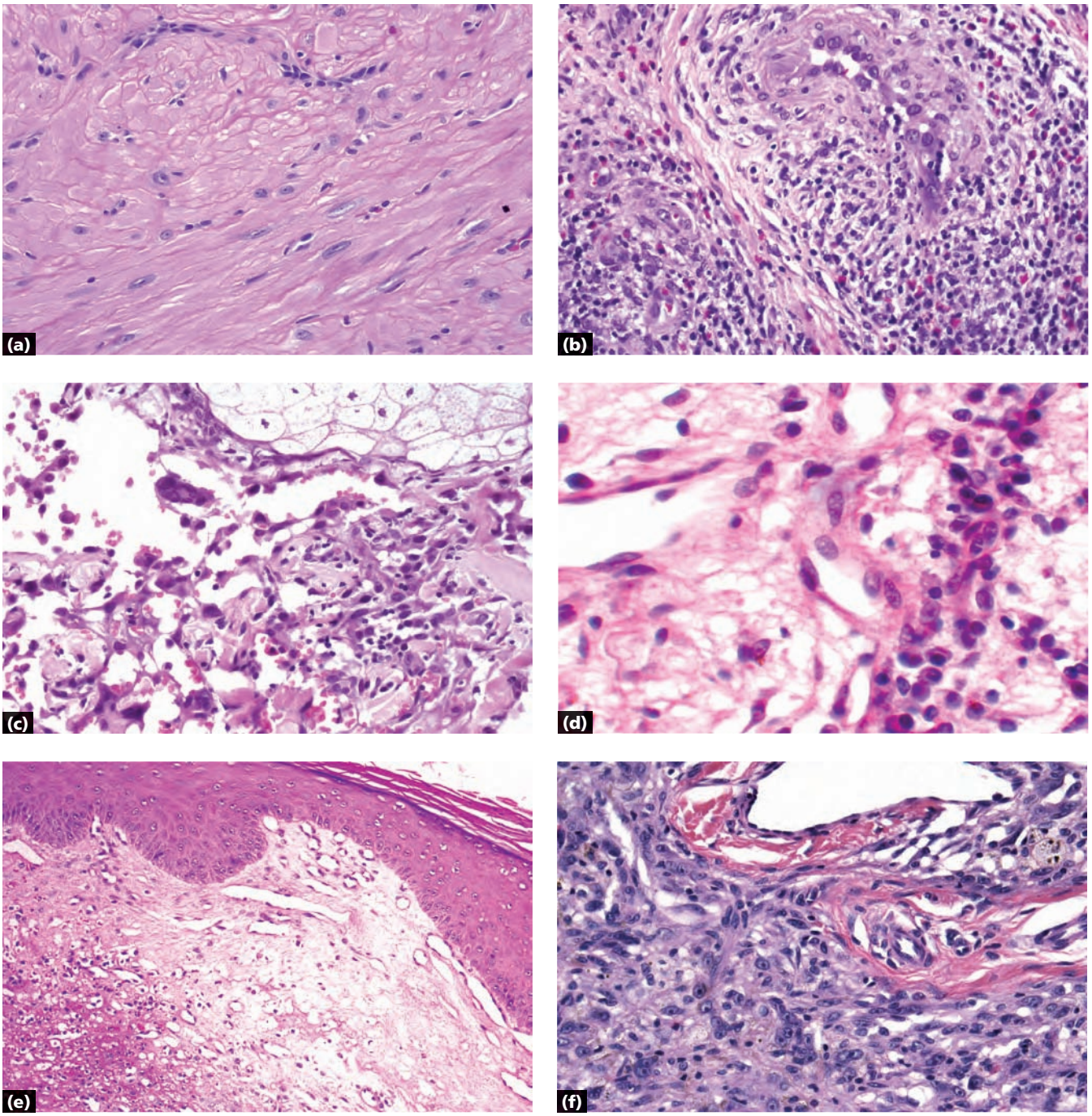

a Angioleiomyoma: well-circumscribed pink ball composed of cigar-shaped spindle cells and compressed to dilated vessels

b Angiolymphoid hyperplasia with eosinophilia: dilated vessels with prominent hobnail endothelial cells surrounded by inflammation, +/– numerous eosinophils

c Angiosarcoma: maze-like connection of vessels lined by atypical endothelial cells

d Bacillary angiomatosis: dilated vessels surrounded by inflammation that includes plasma cells and ill-defined "clouds"

e Chondrodermatitis nodularis helicis: dilated vessels on either side of fibrin; epidermis may be eroded/ulcerated or acanthotic/atrophic

f Dermatofibroma, hemosiderotic: histiocytes and giant cells with hemosiderin

Key differences

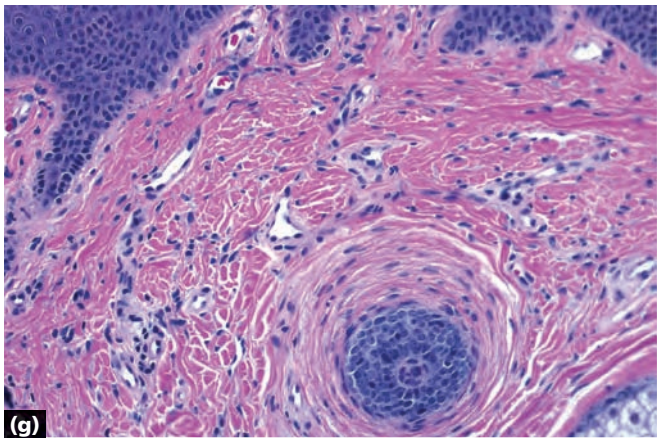

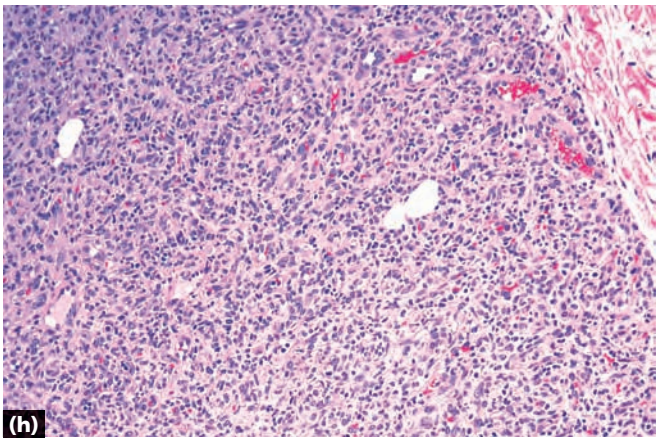

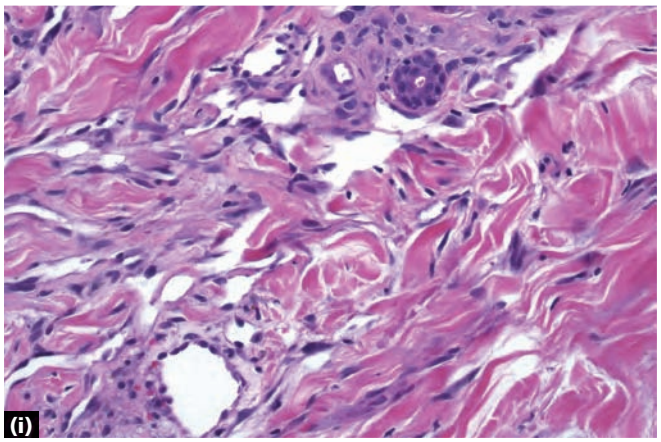

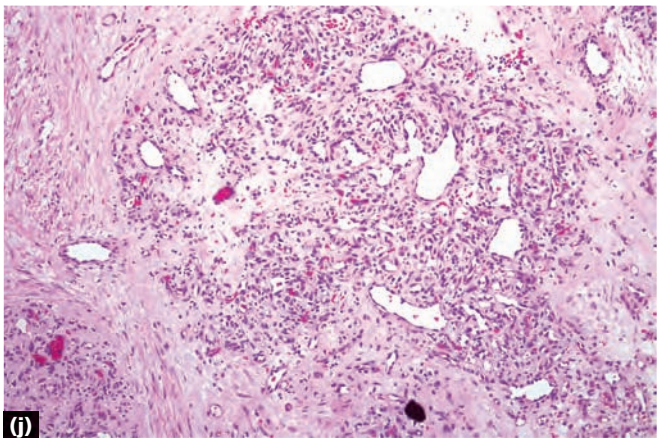

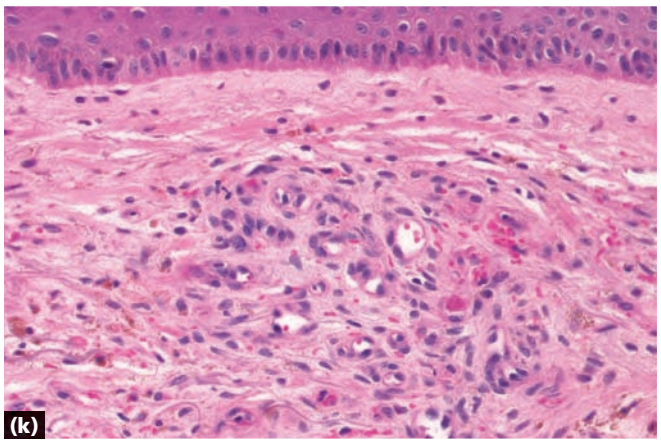

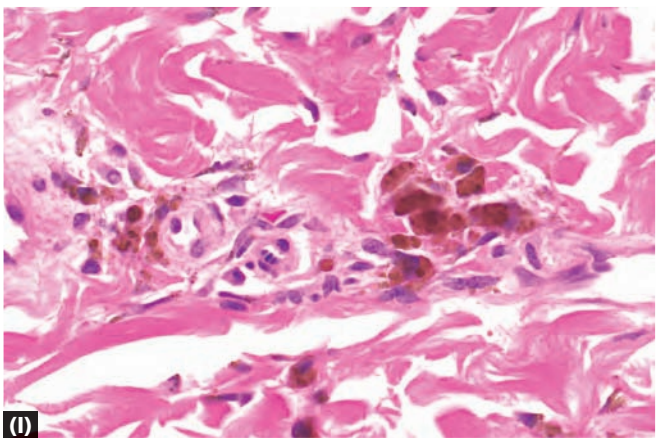

g Fibrous papule: fibrotic stroma with stellate fibroblasts and dilated vessels
h Infantile hemangioma: lobules of small blue cells with interspersed spaces containing erythrocytes
i Kaposi sarcoma, patch/plaque: slit-like or angulated spaces dissecting through collagen; vessels around vessels
j Pyogenic granuloma: clusters of dilated vessels surrounded by mixed inflammation
k Stasis dermatitis: small clusters of capillaries in upper dermis with hemosiderin
l Targetoid hemosiderotic hemangioma: wedge-shaped area of increased vessels with hemosiderin at periphery

Key differences, *continued*

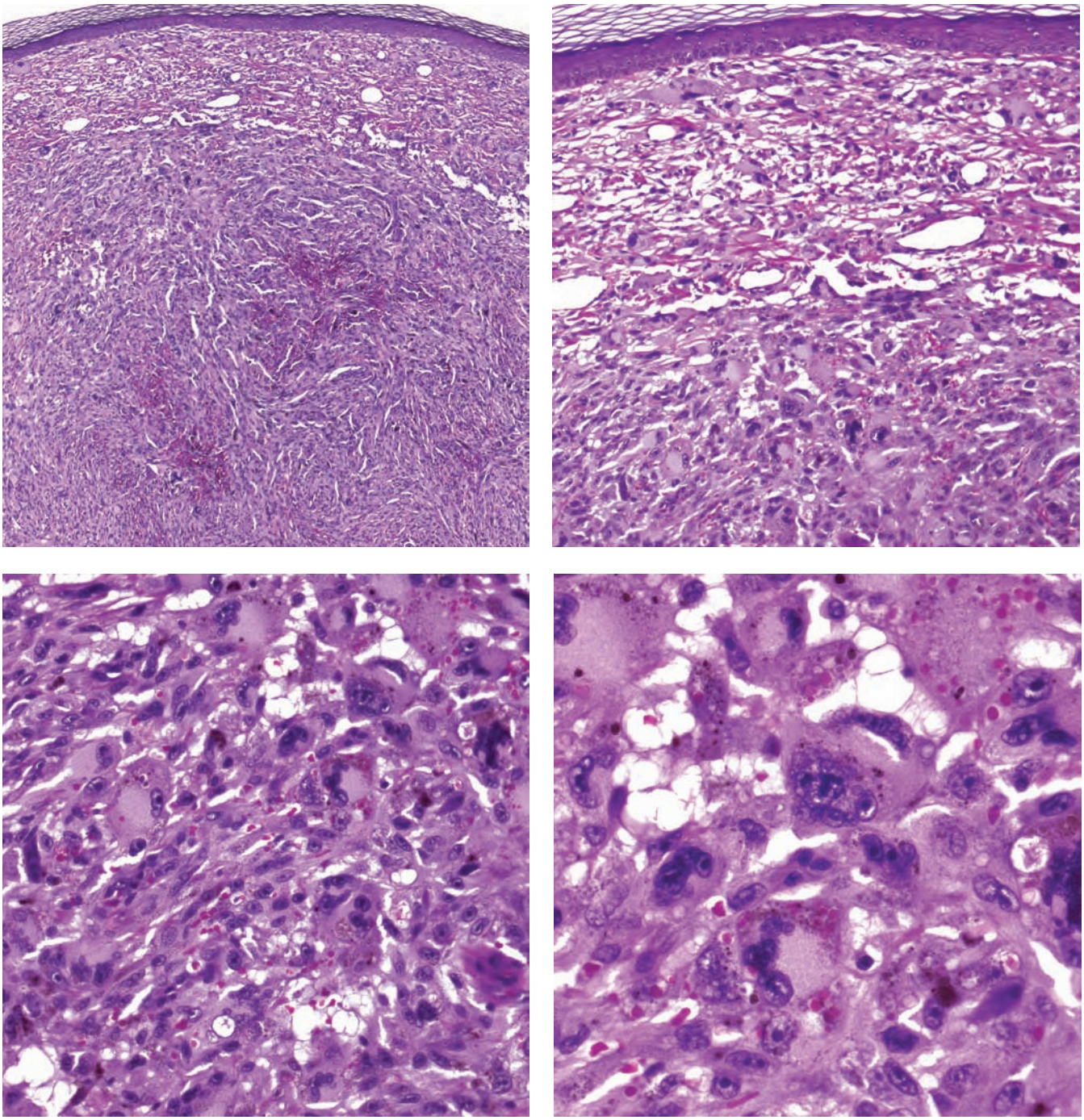

- Giant cells with bizarre nuclei
- Cells are atypical
- Mitoses
- Often a grenz zone above the atypical cells and solar elastosis flanking the atypical cells

Atypical fibroxanthoma

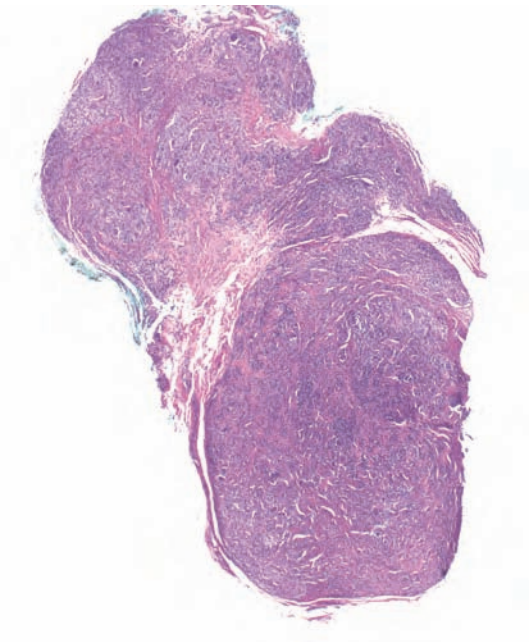

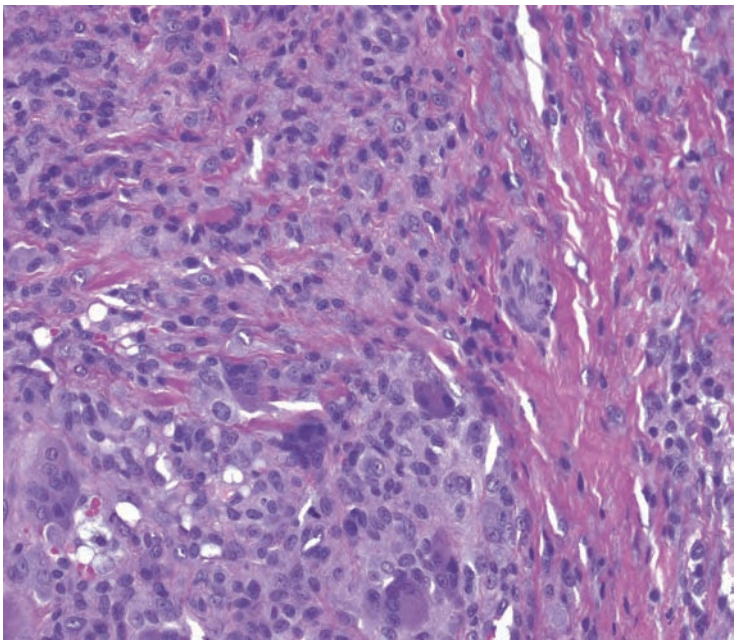

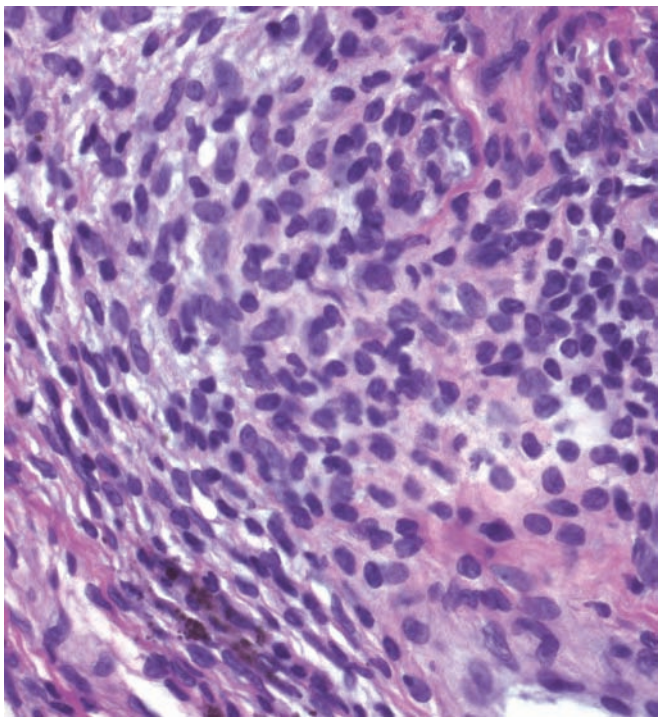

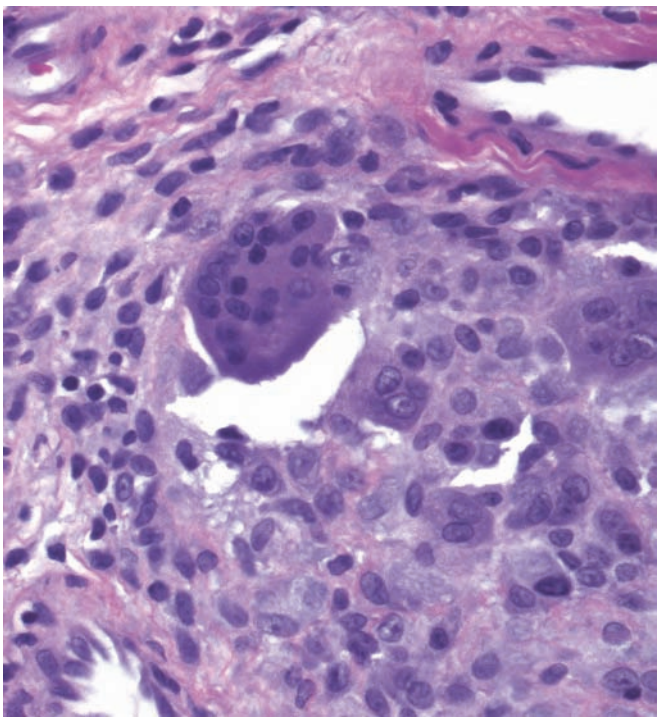

- Giant cells of osteoclastic type (nuclei arranged haphazardly on one side of the cell)
- Nuclei of giant cells resemble the nuclei of adjacent histiocytes
- Hemosiderophages
- Often a deep tumor (no epidermis present)

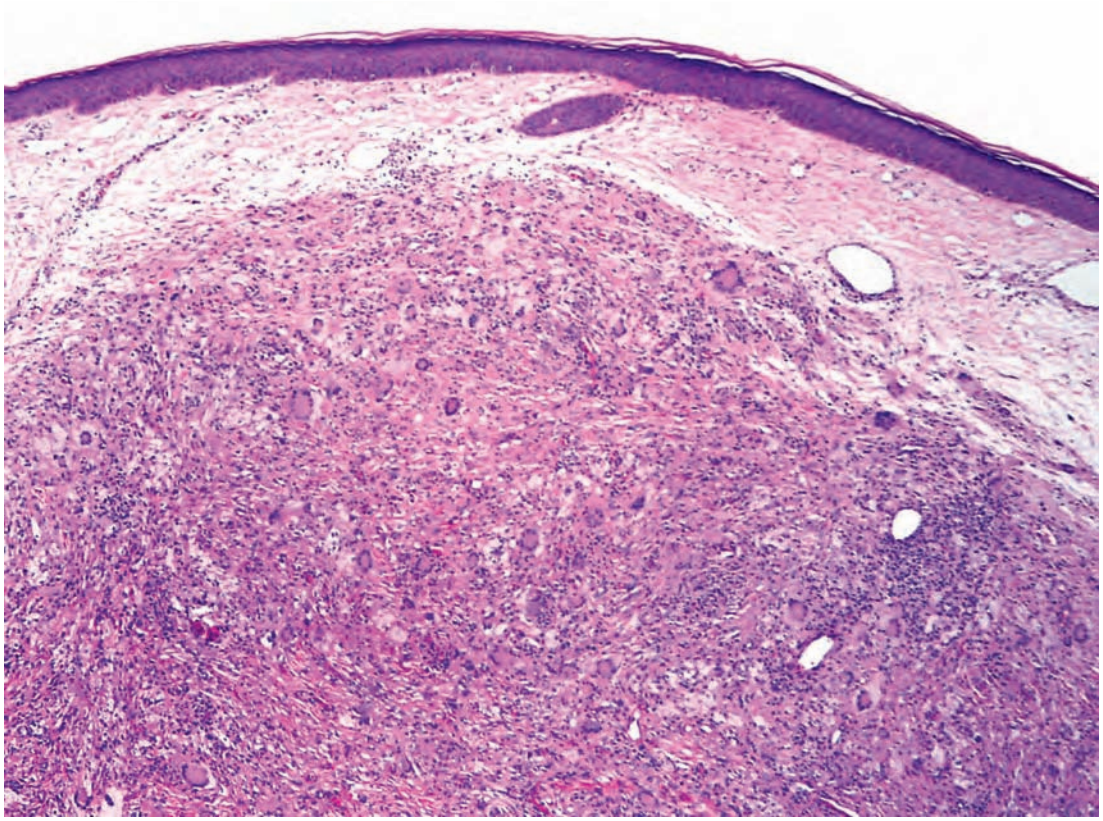

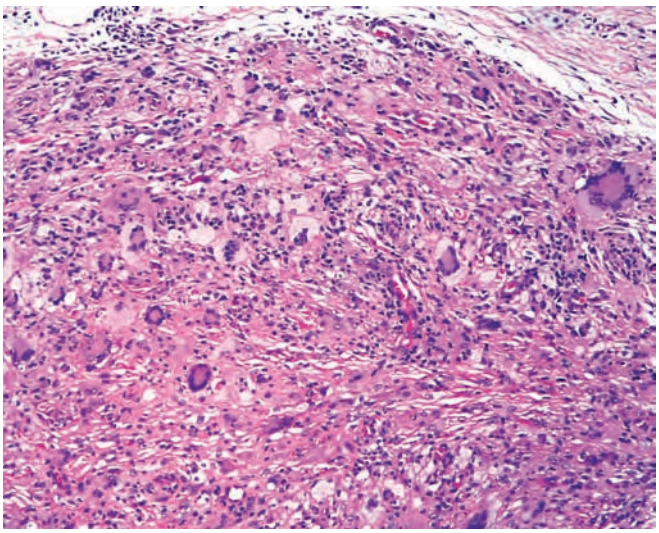

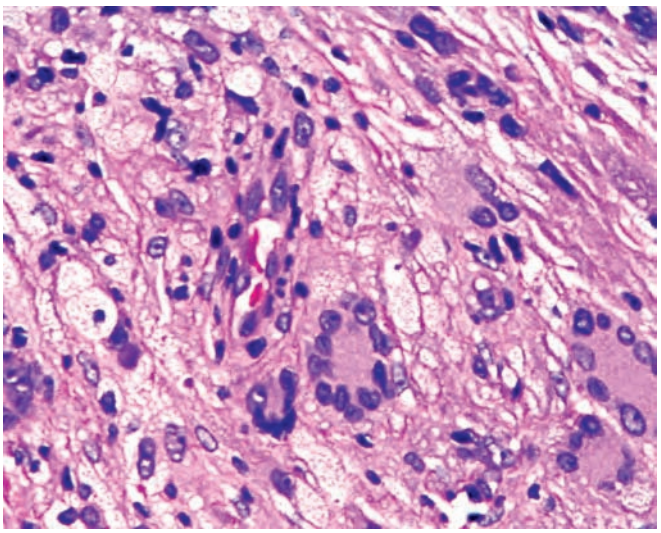

- Touton giant cells (wreath of nuclei with pink center and foamy cytoplasm outside the wreath) arranged at periphery of collection of histiocytes
- Eosinophils may be present
- Scattered foamy cells may be present

Juvenile xanthogranuloma

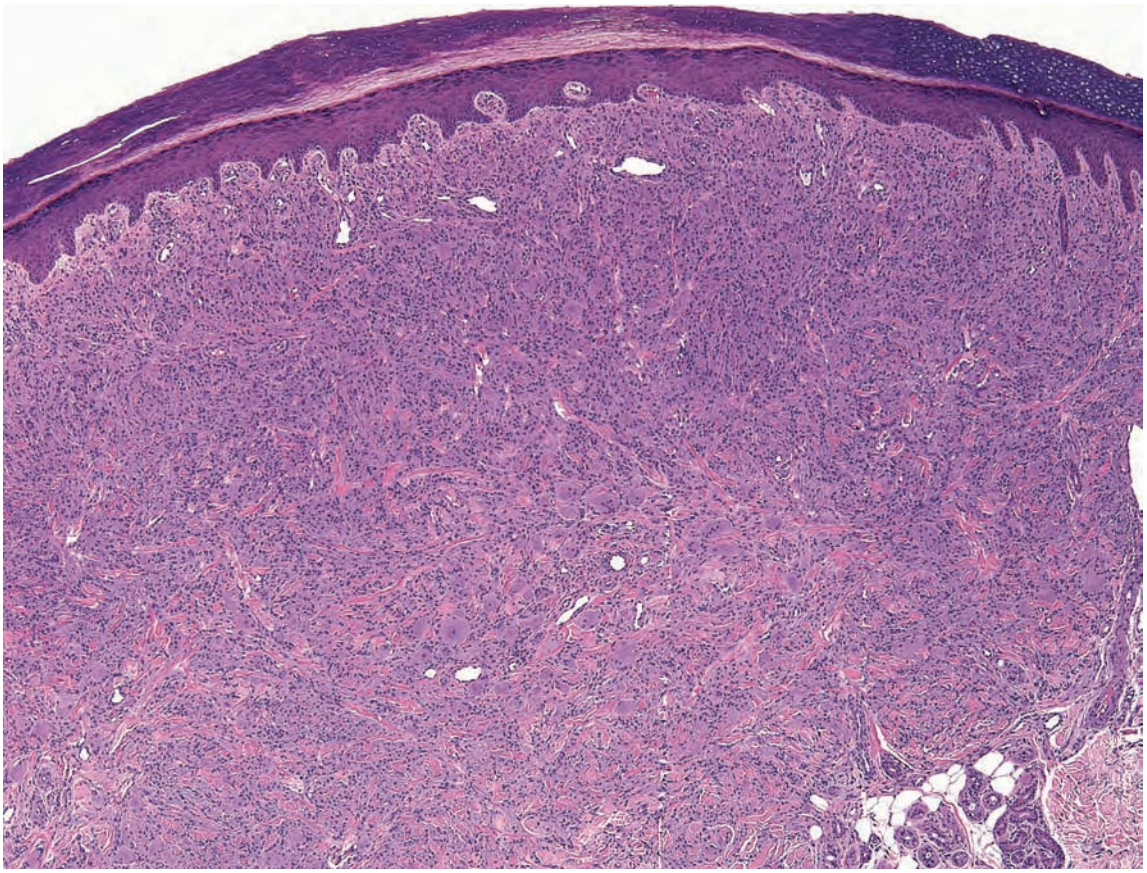

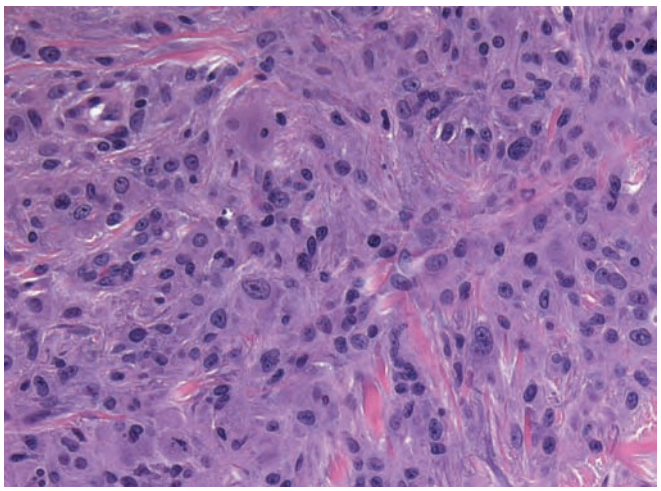

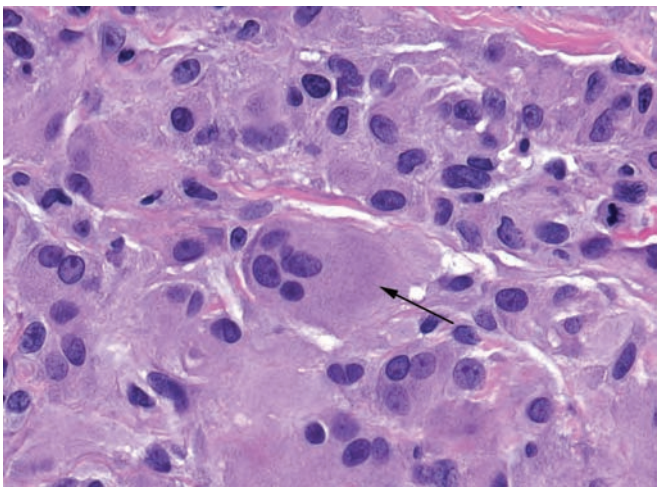

- Oncocytic giant cells (multinucleated cells with ground glass pink cytoplasm) (arrow)

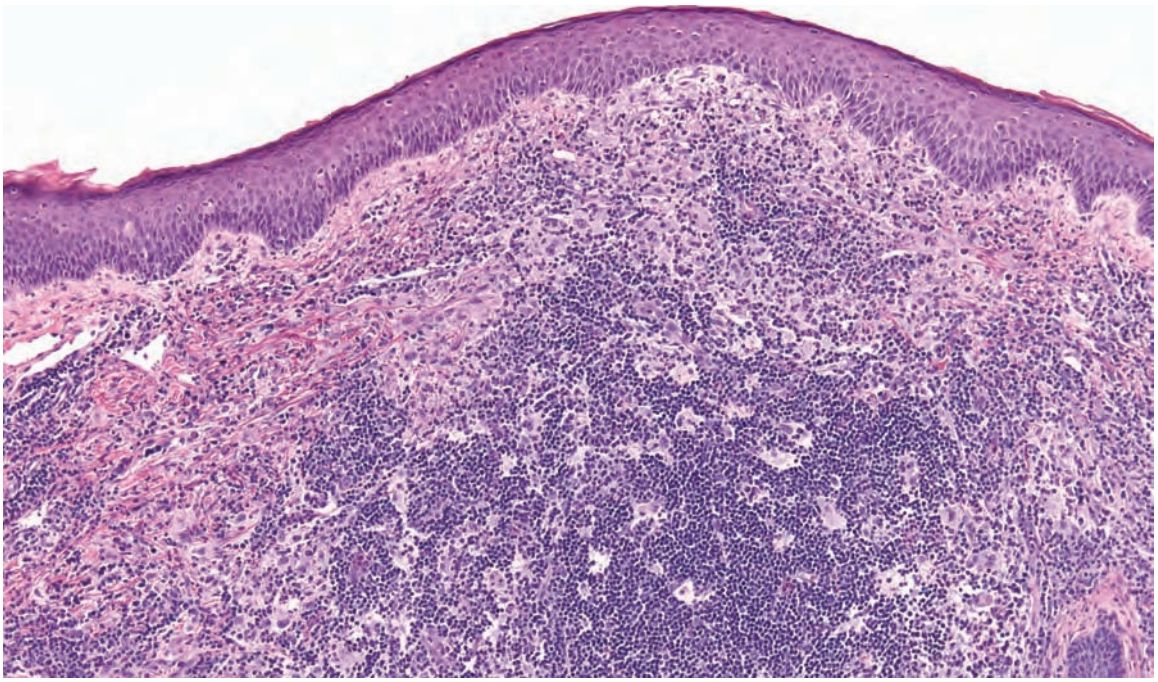

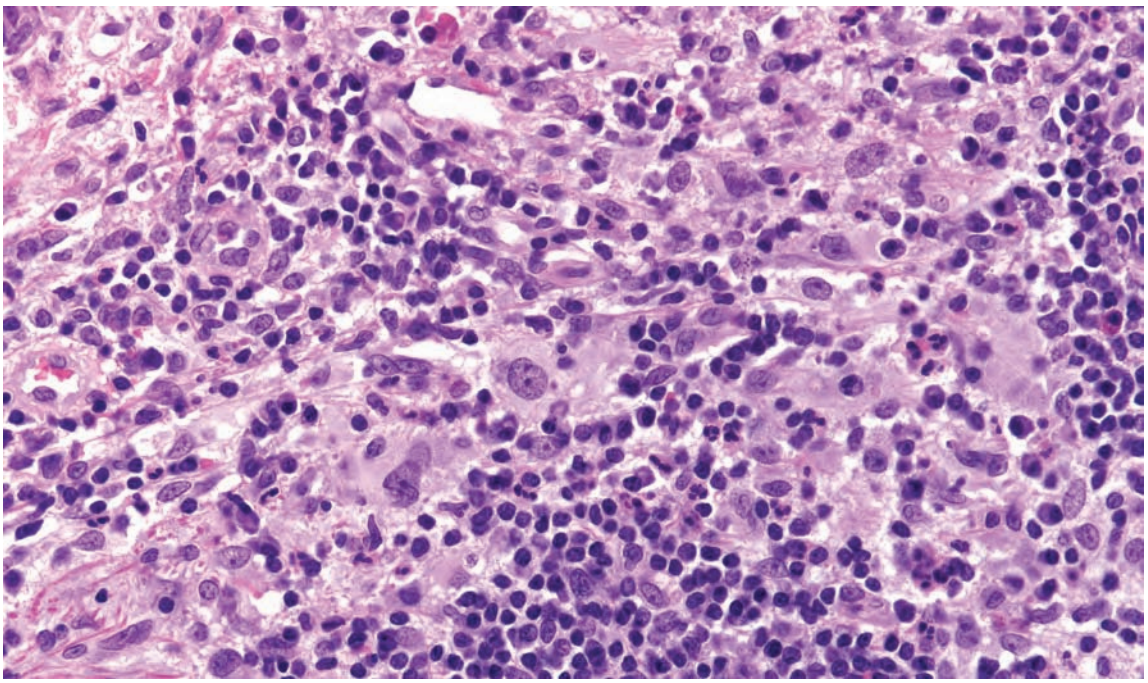

- Giant cells and interspersed collections of lymphocytes giving an alternating pink and blue color
- Giant cells show emperipolesis (intact inflammatory cells in the cytoplasm); the giant cells are S-100 positive

Rosai-Dorfman disease

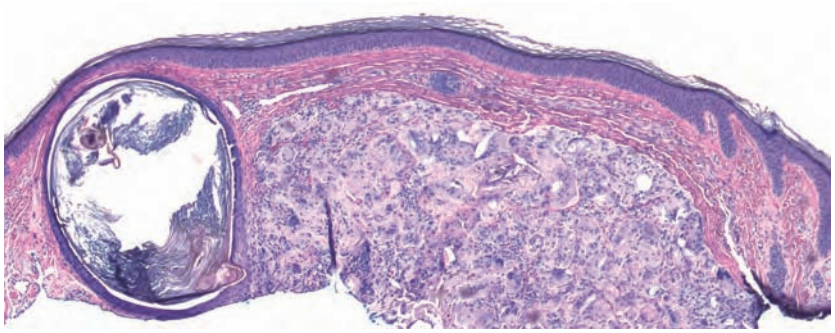

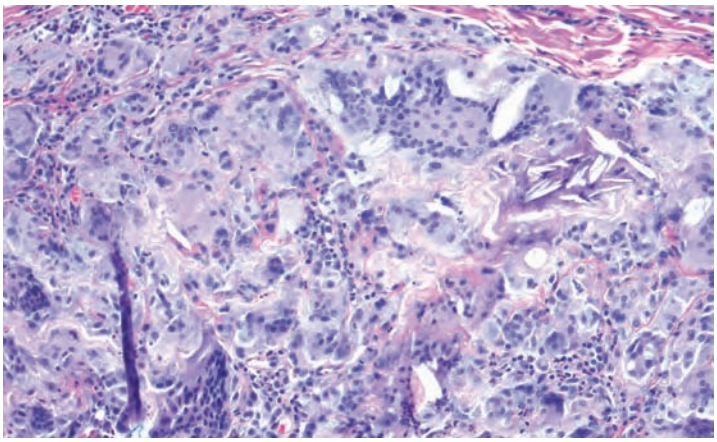

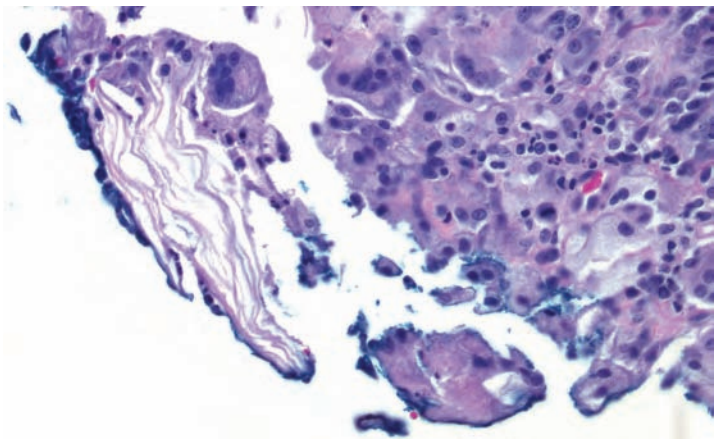

- Foreign-body giant cells (haphazardly arranged nuclei), neutrophils
- Keratin spicules can be seen near/engulfed by multinucleated cells

Ruptured cyst/keratin granuloma

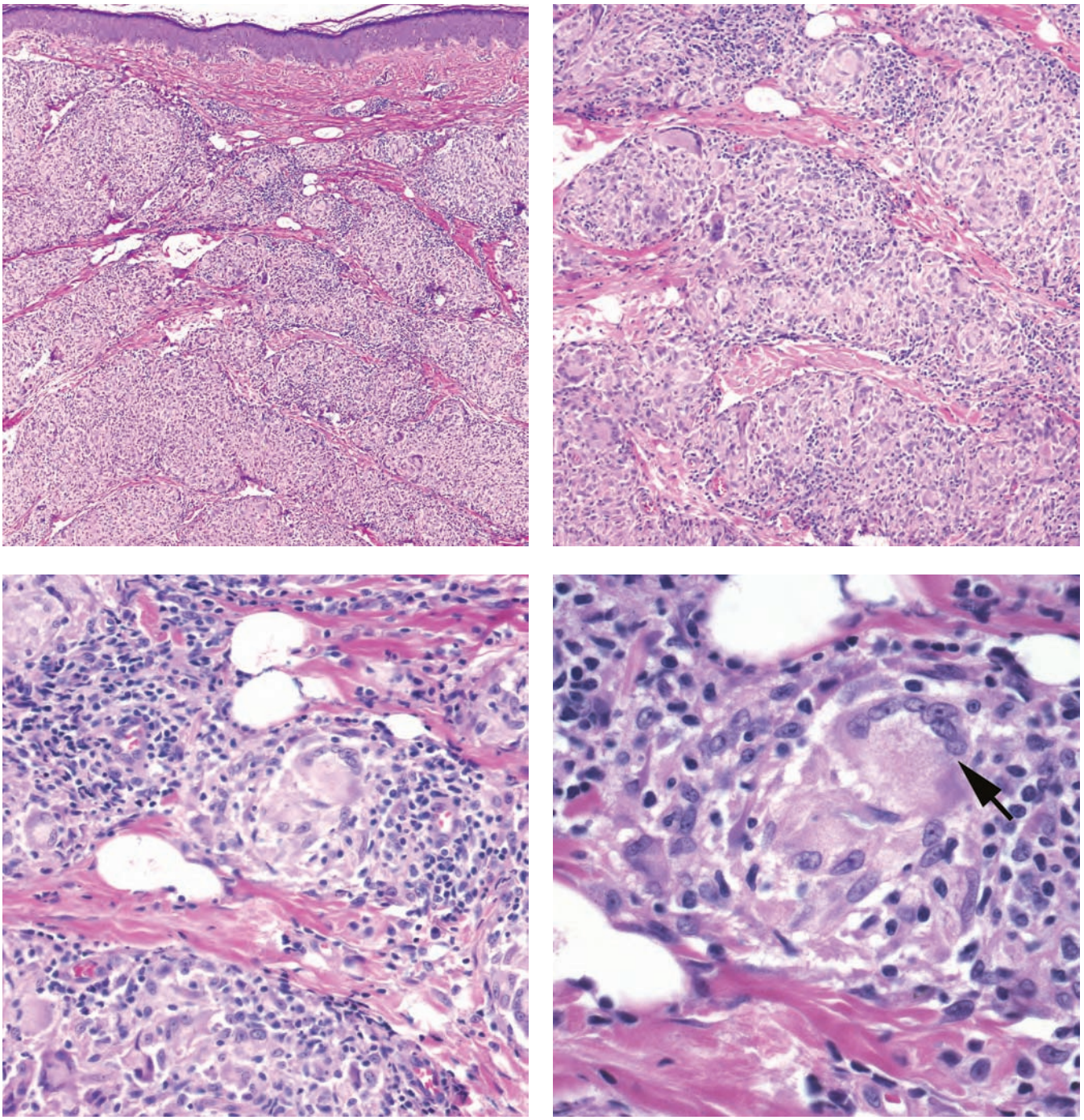

- Langhans giant cells (nuclei arranged in a horseshoe shape) (arrow)
- Epidermis usually normal
- Giant cells within collections of histiocytes that are usually "naked" (lacking surrounding lymphocytes)

Sarcoidosis

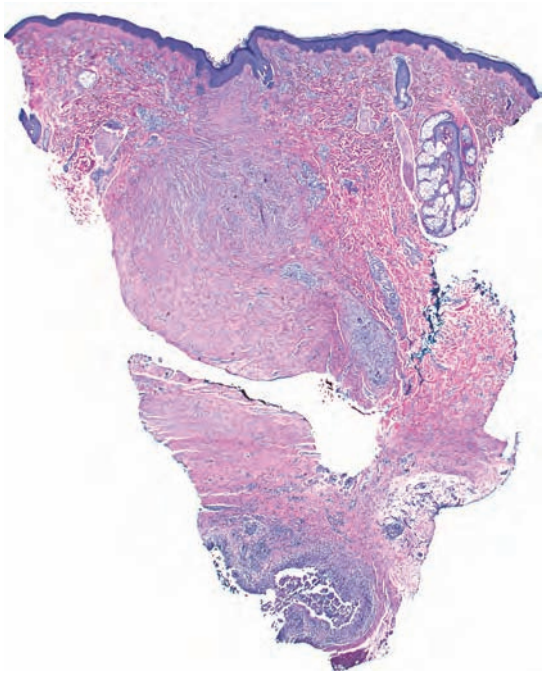

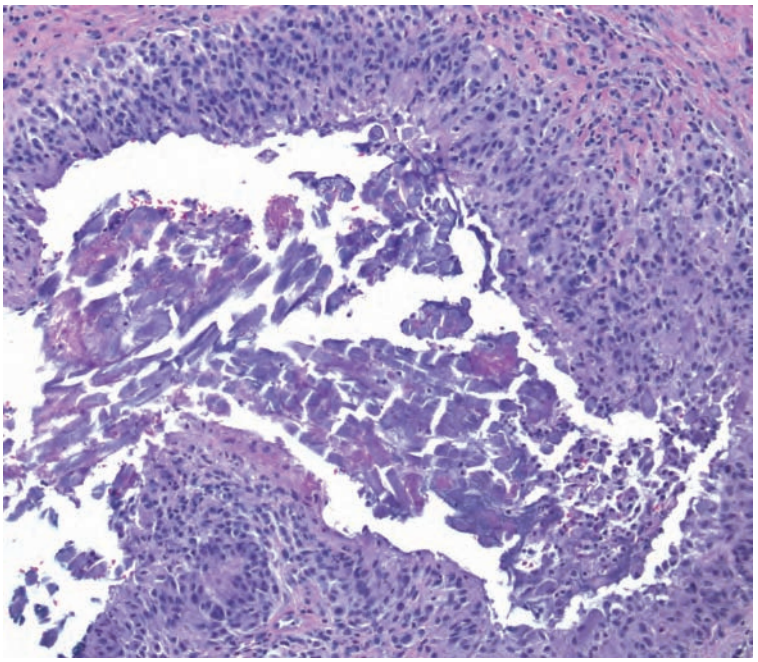

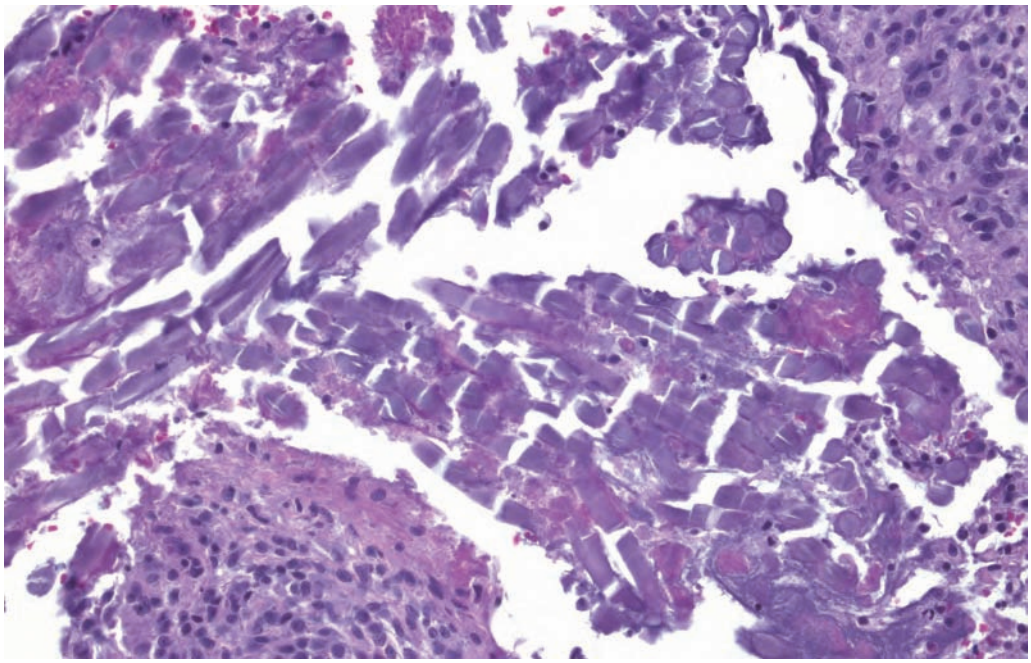

- Foreign-body giant cells
- Cells surrounding suture material (braided in this case)

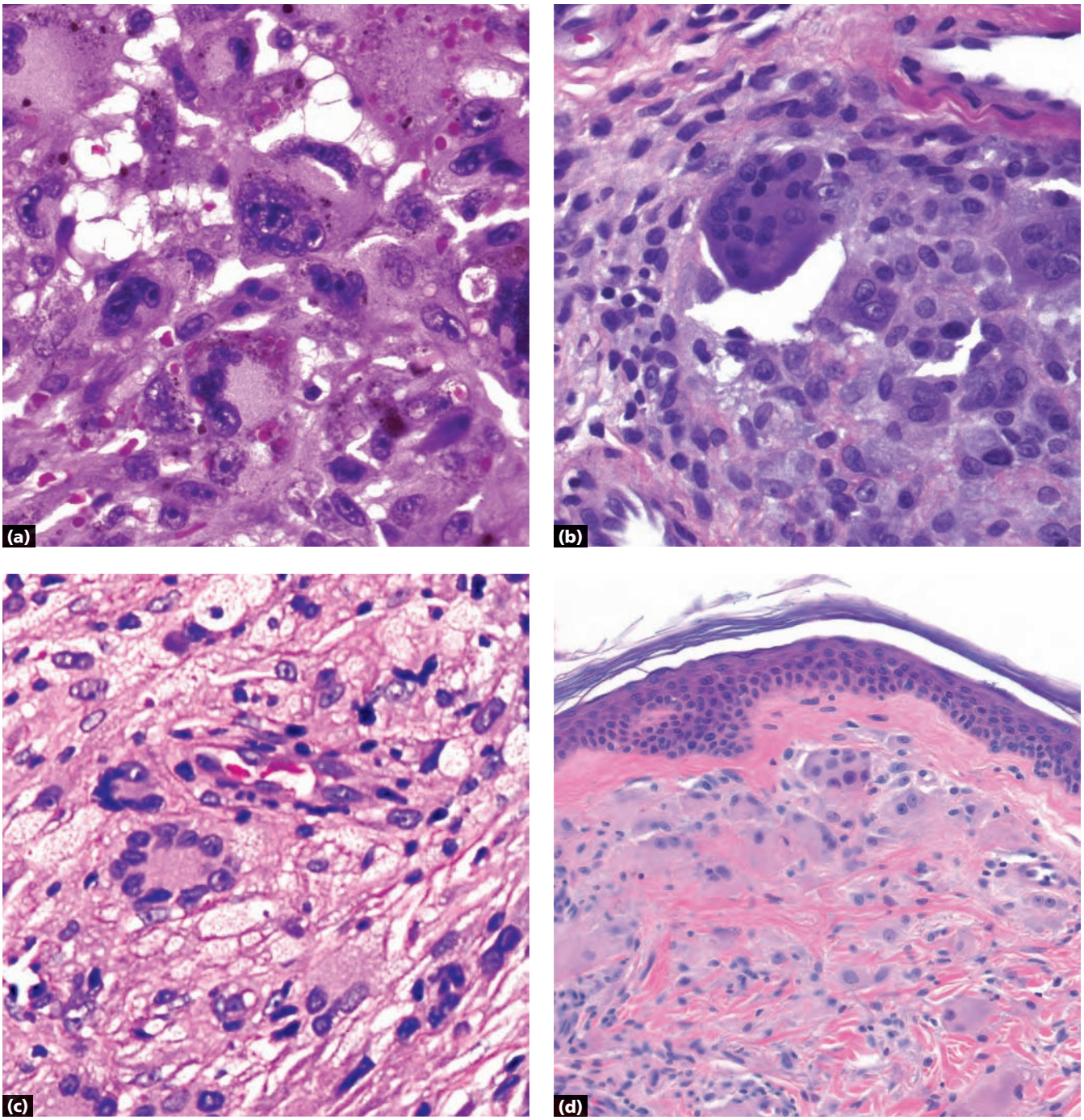

a Atypical fibroxanthoma: atypical nuclei, mitoses
b Giant cell tumor of tendon sheath: osteoclastic giant cells
c Juvenile xanthogranuloma: Touton giant cells
d Reticulohistiocytosis: oncocytic giant cells

Key differences

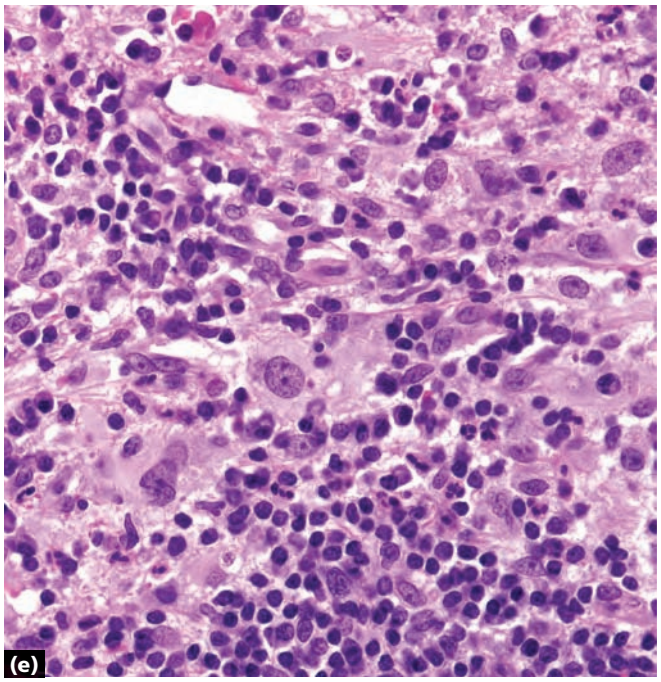

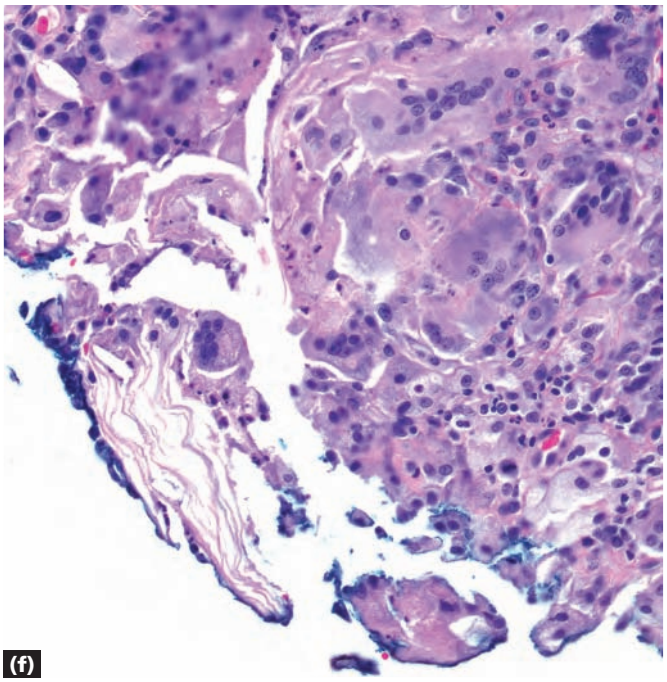

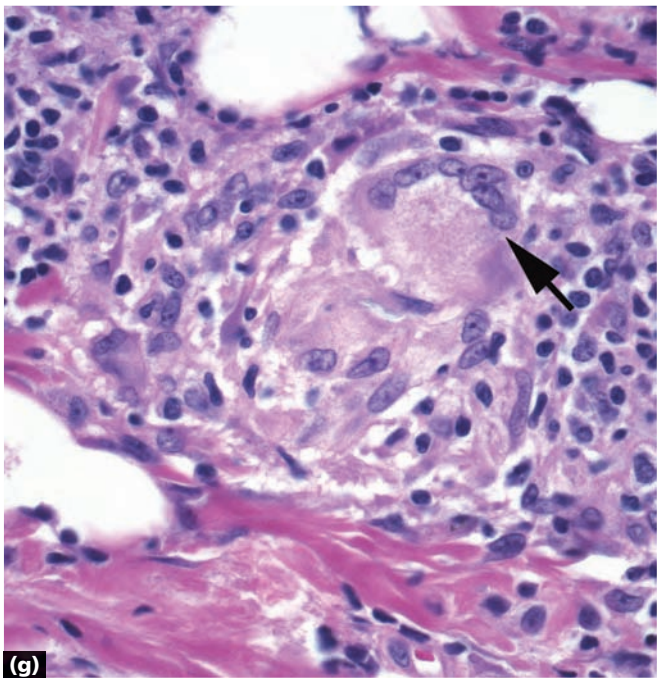

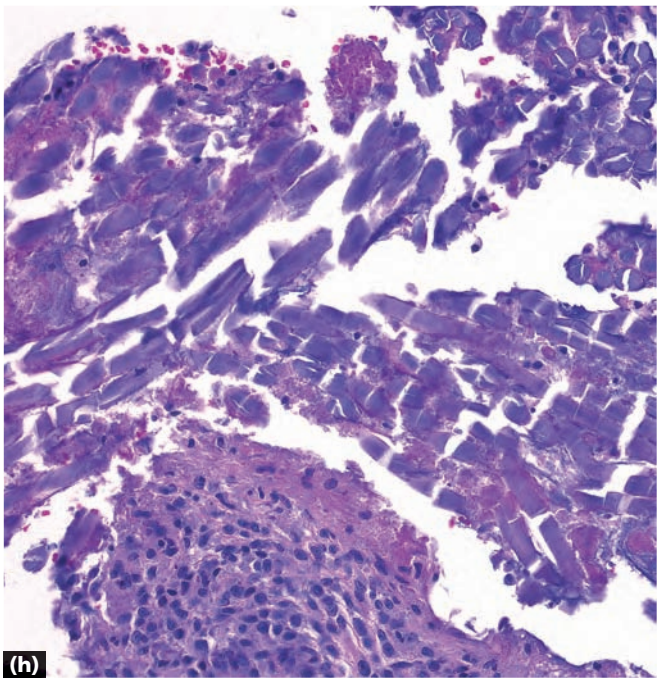

e Rosai-Dorfman disease: giant cells with emperipolesis (other inflammatory cells within the cytoplasm)
f Ruptured cyst/keratin granuloma: foreign-body giant cells, keratin spicules
g Sarcoidosis: Langhans giant cells, naked granulomas (arrow)
h Suture granuloma: foreign-body giant cells, suture material

Note Infections and scars are other common entities that frequently have giant cells.
Note This list is of the classical type of giant cell for each entity; none of the giant cells are pathognomonic.

Key differences, *continued*

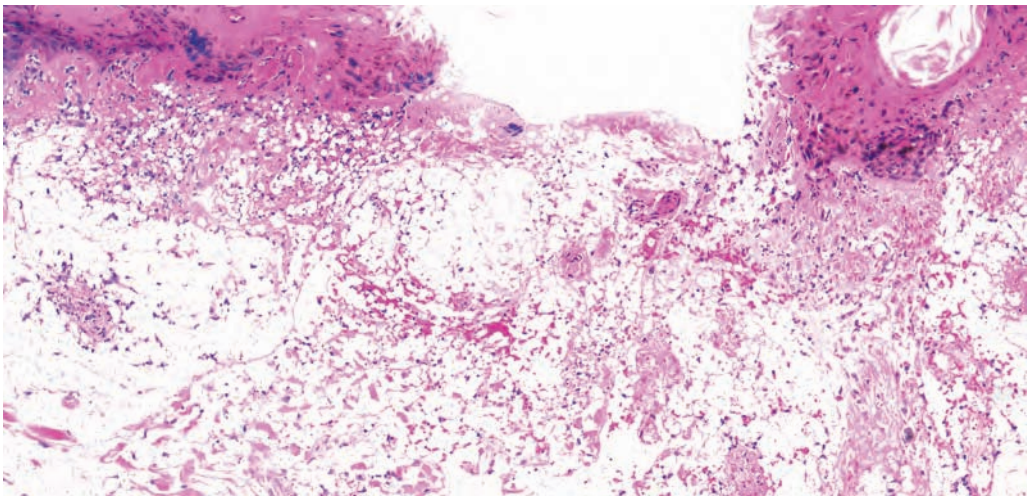

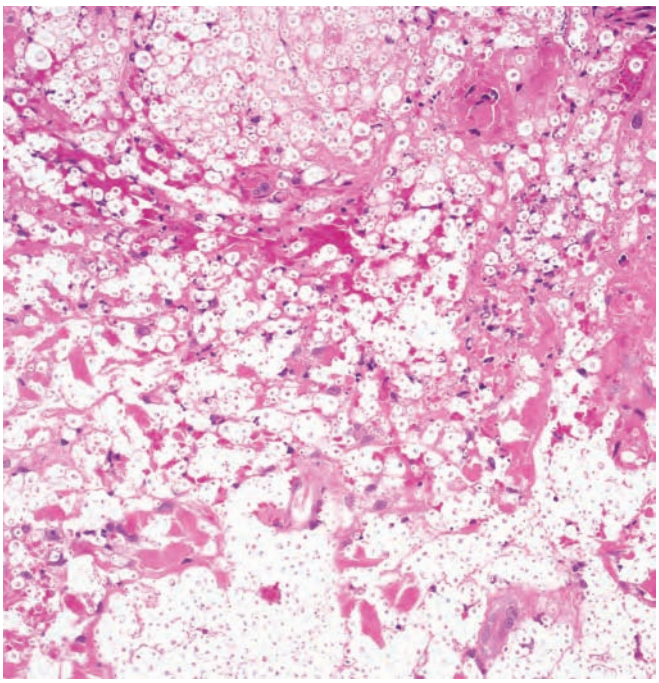

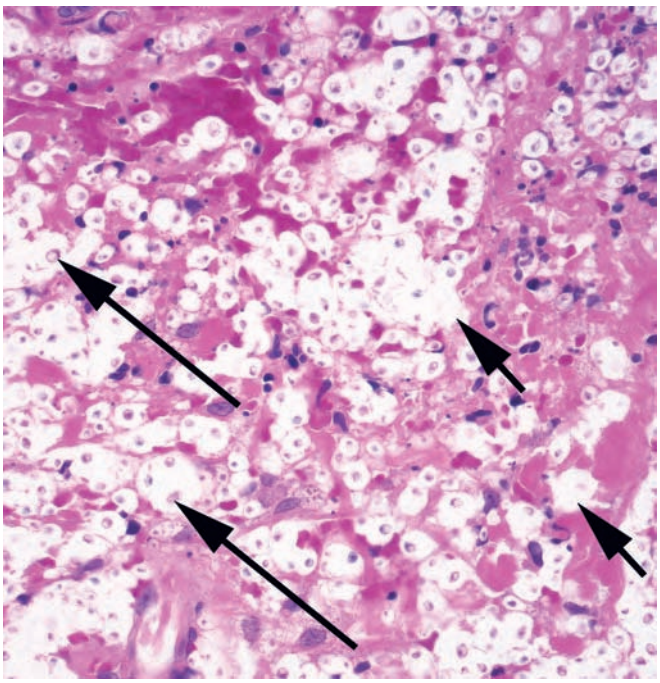

- Clear "cells"
- The organisms (long arrows) are surrounded by capsules, which are seen in sections as clear spaces (short arrows)

Cryptococcosis, gelatinous

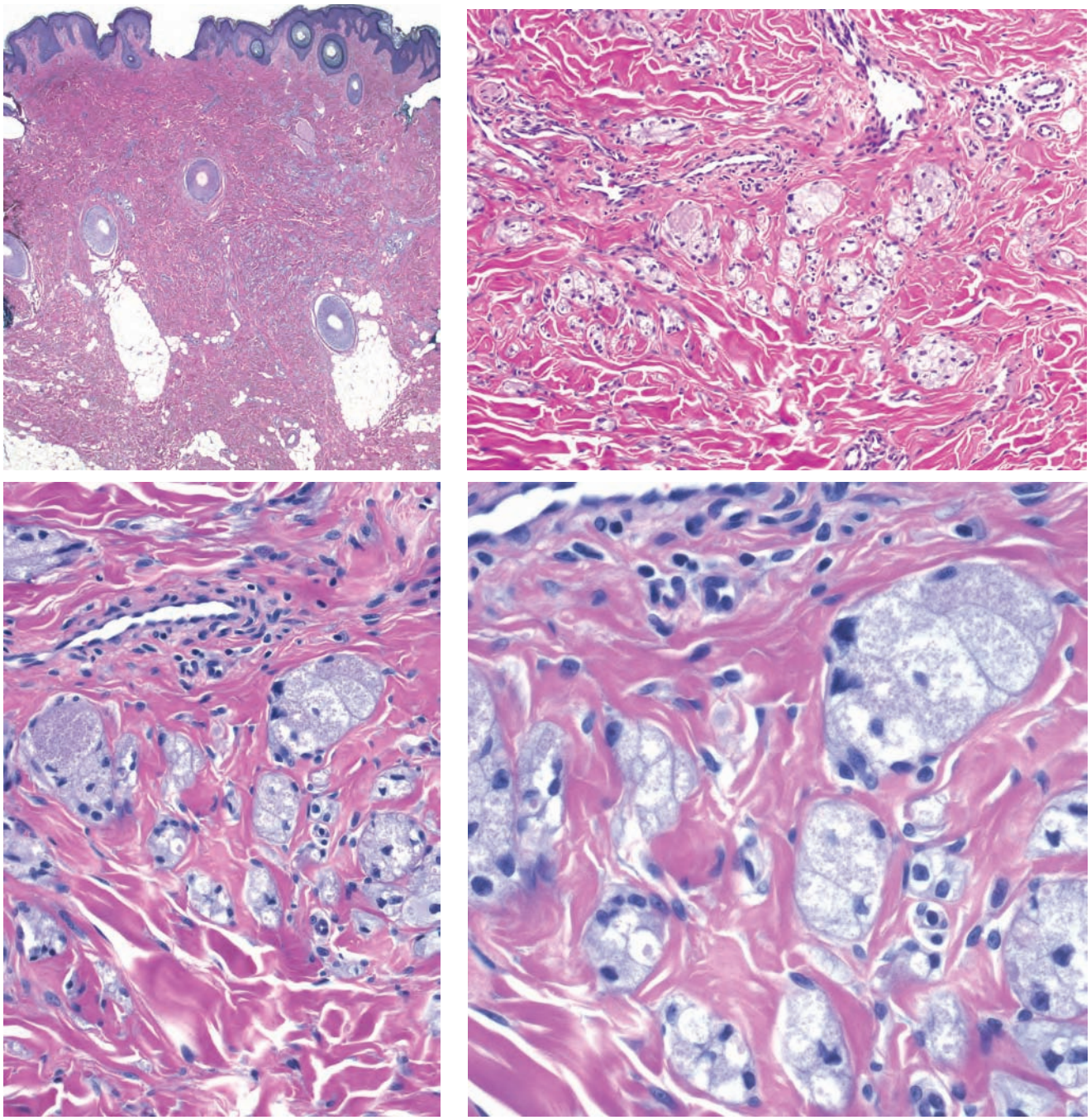

- "Clear" cells
- Epidermis may be acanthotic or display pseudoepitheliomatous hyperplasia
- Cells are polygonal to oval and contain a granular pink material (phagolysosomes)
- Large granules are surrounded by haloes

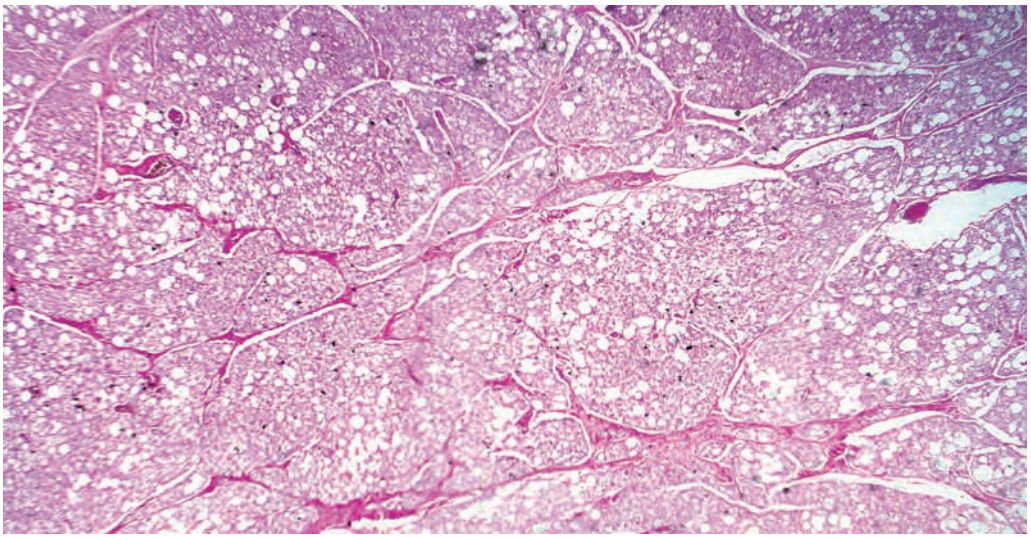

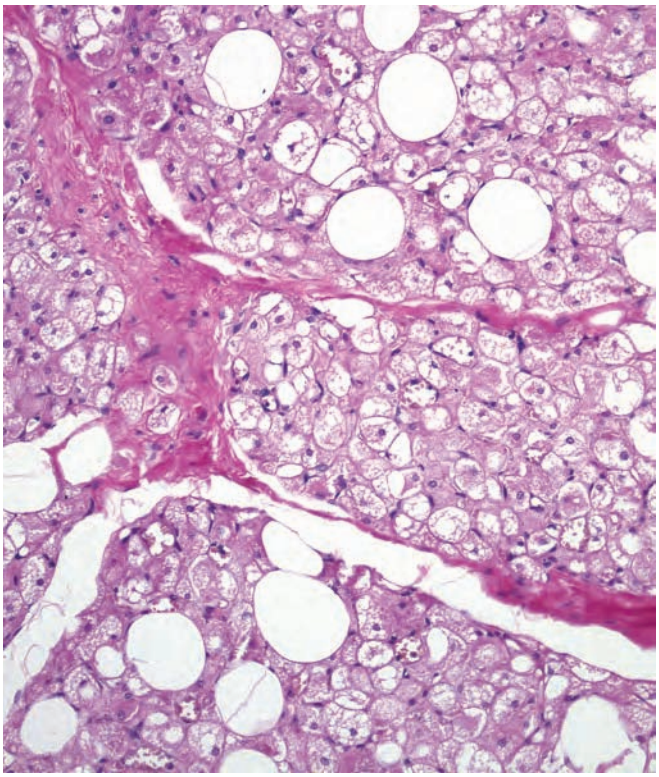

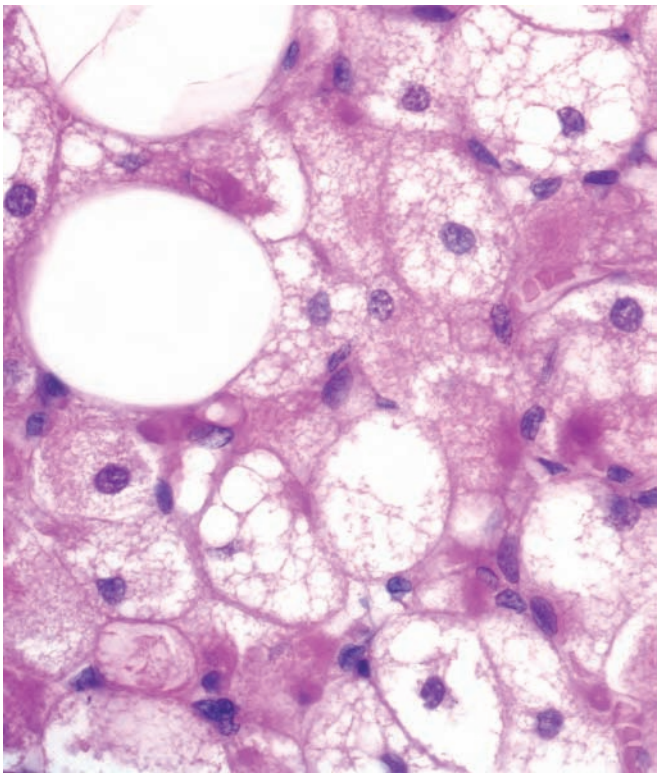

- "Clear" cells
- Cells are adipocytes that are so-called "mulberry" cells, with a net-like vacuolar pattern around the nuclei

Hibernoma

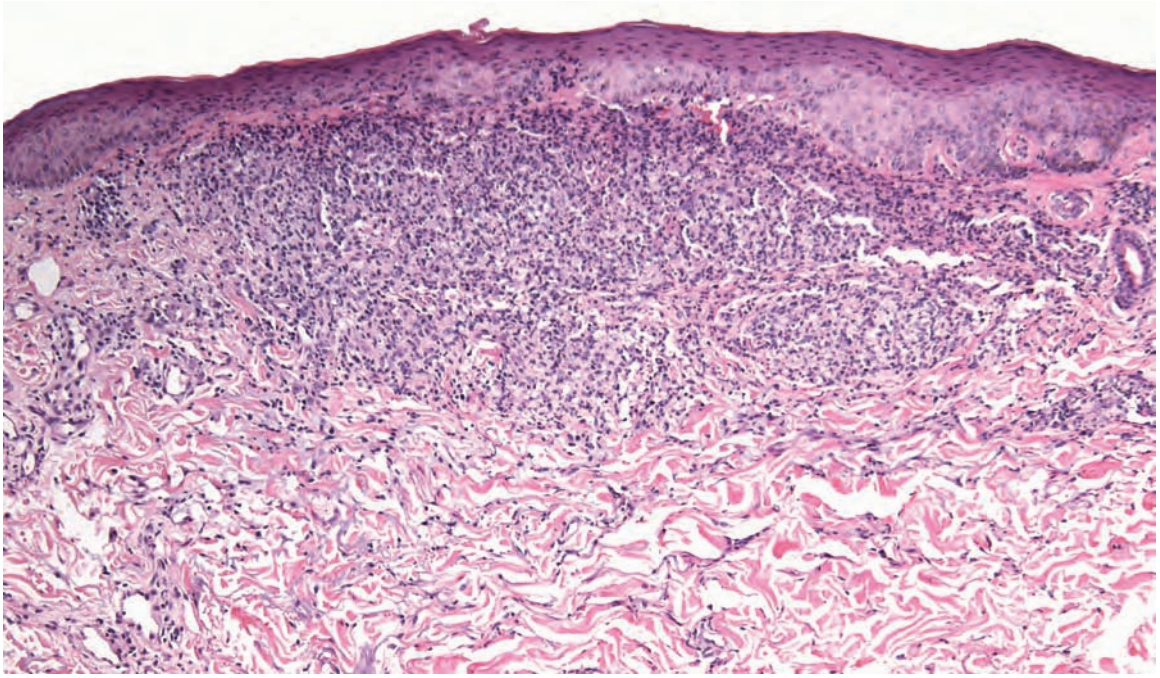

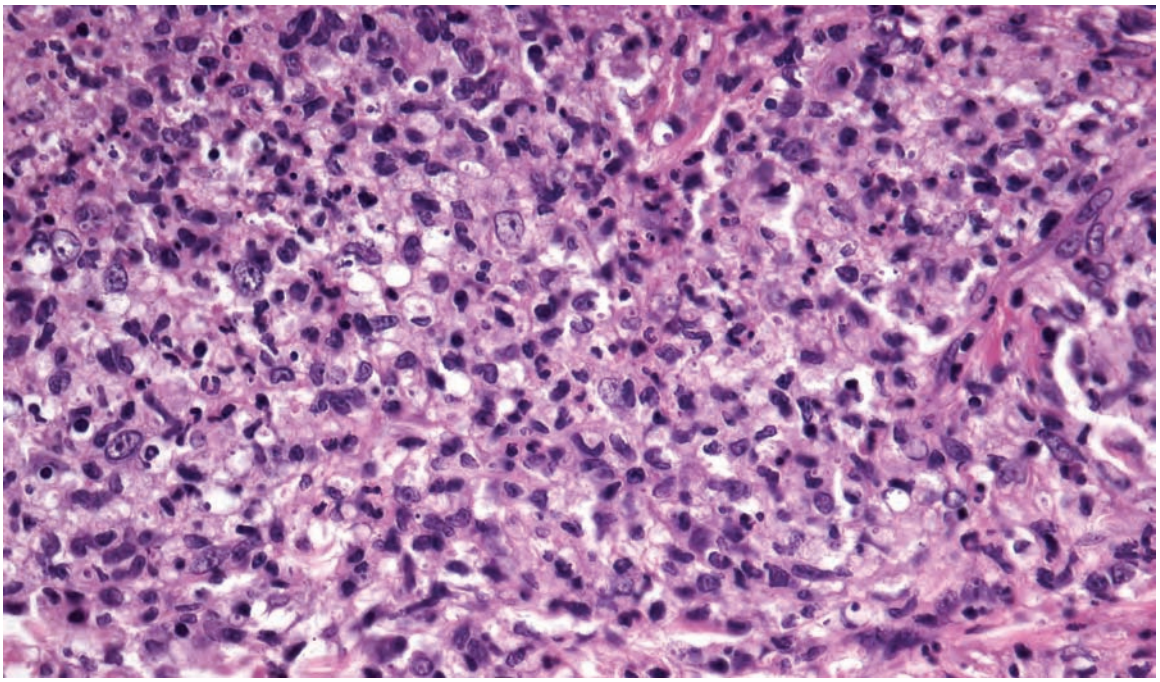

- "Clear" cells
- Cells are macrophages that contain the organisms
- Organism is encapsulated so is often surrounded by a clear space

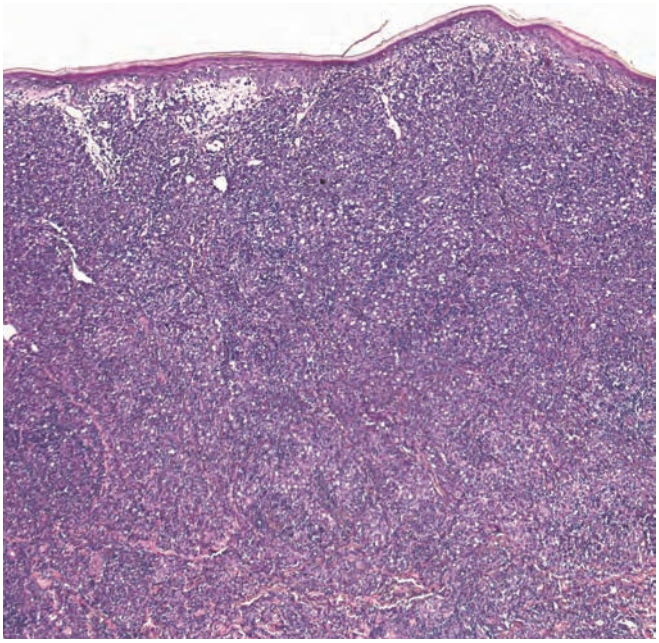

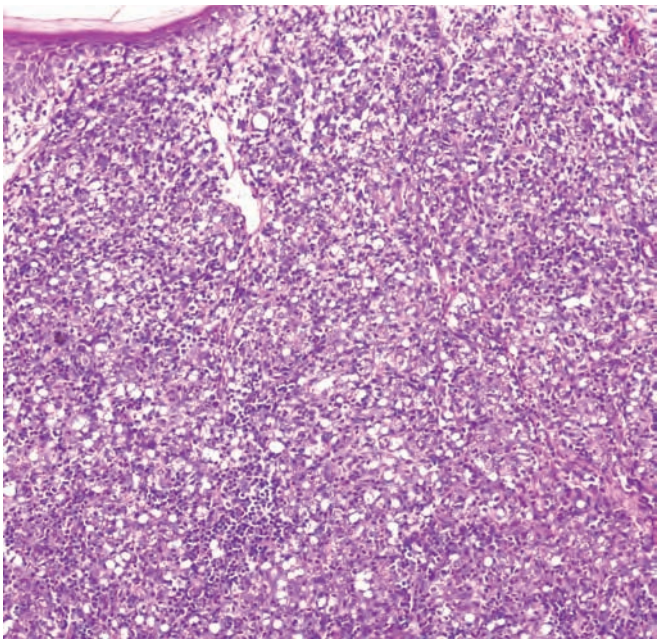

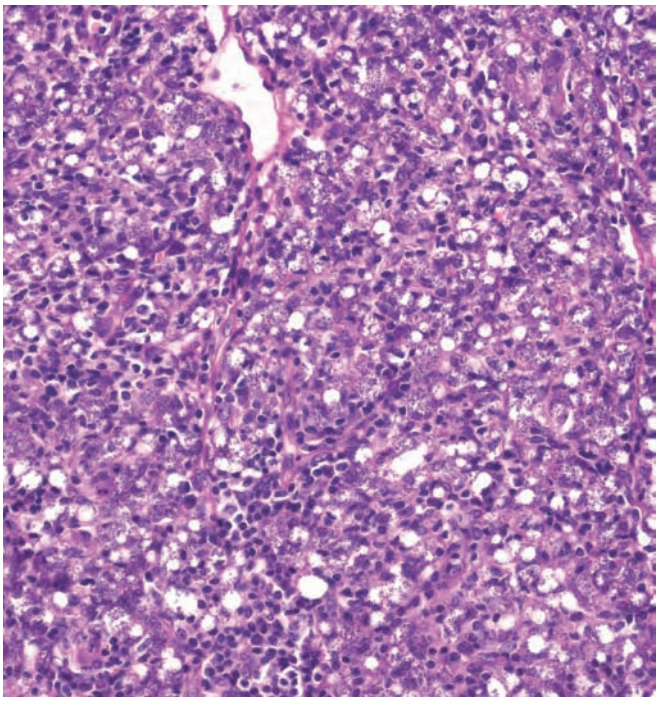

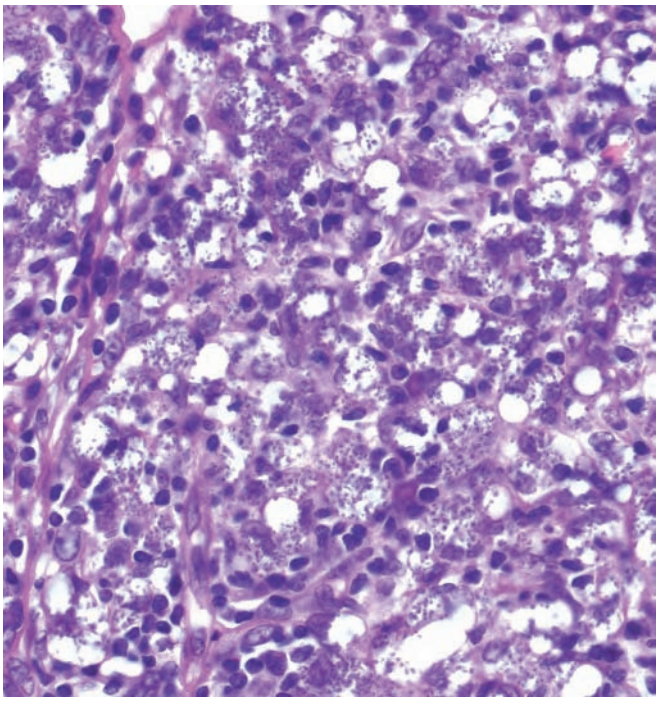

- "Clear" cells
- Cells are macrophages that contain the organisms
- Organisms may cluster at periphery of the macrophages

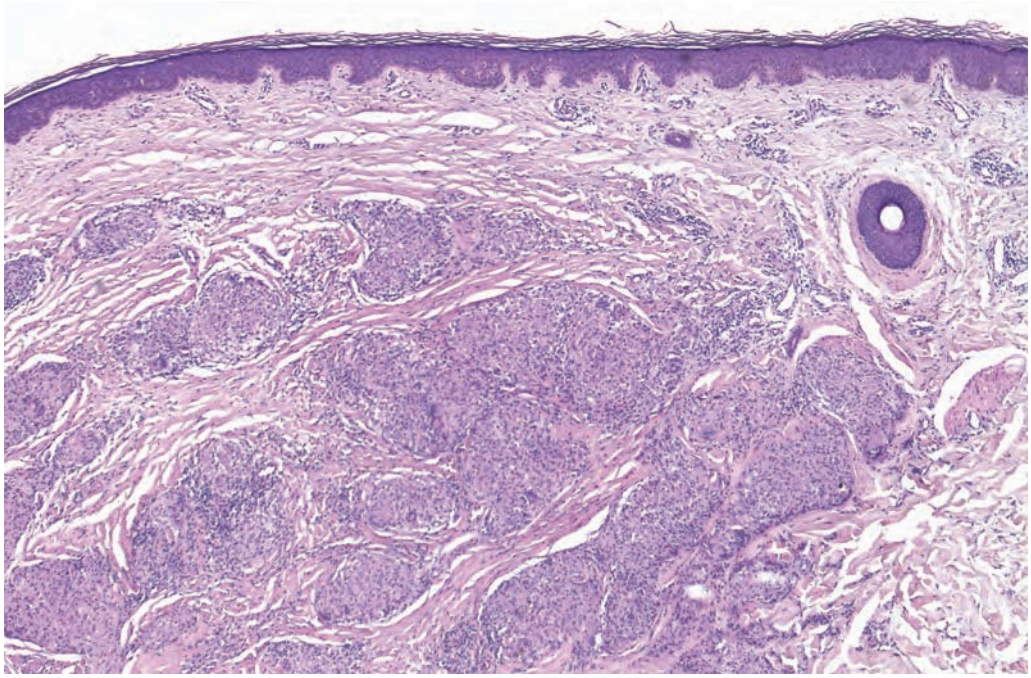

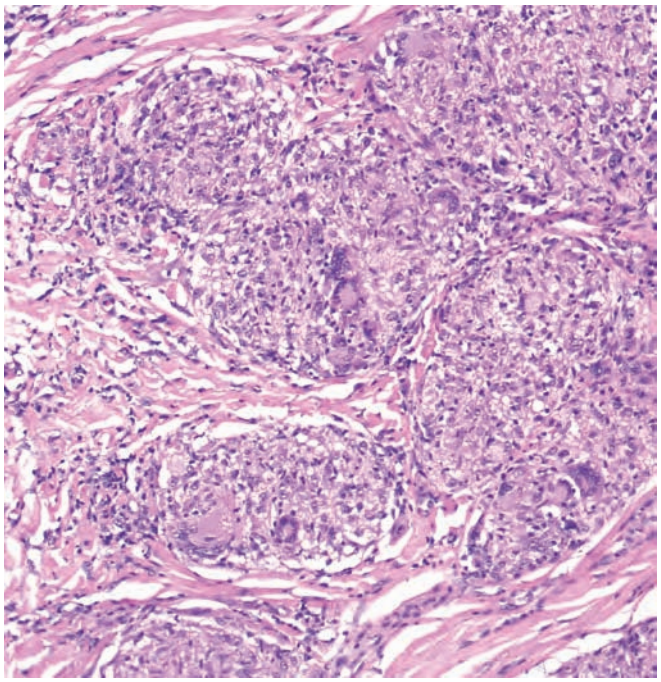

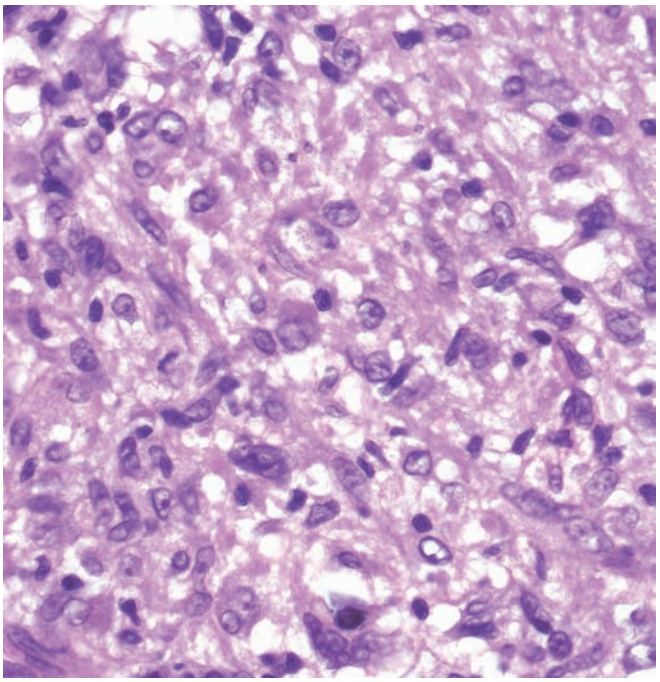

- "Clear" cells
- Cells are histiocytes ("Virchow cells") that look subtly foamy and are filled with organisms (seen with special stains)
- Vacuoles with clusters of organisms (globi)
- On low power, the histiocytes are arranged in linear configurations
- Grenz zone present
- Nerves may appear thickened

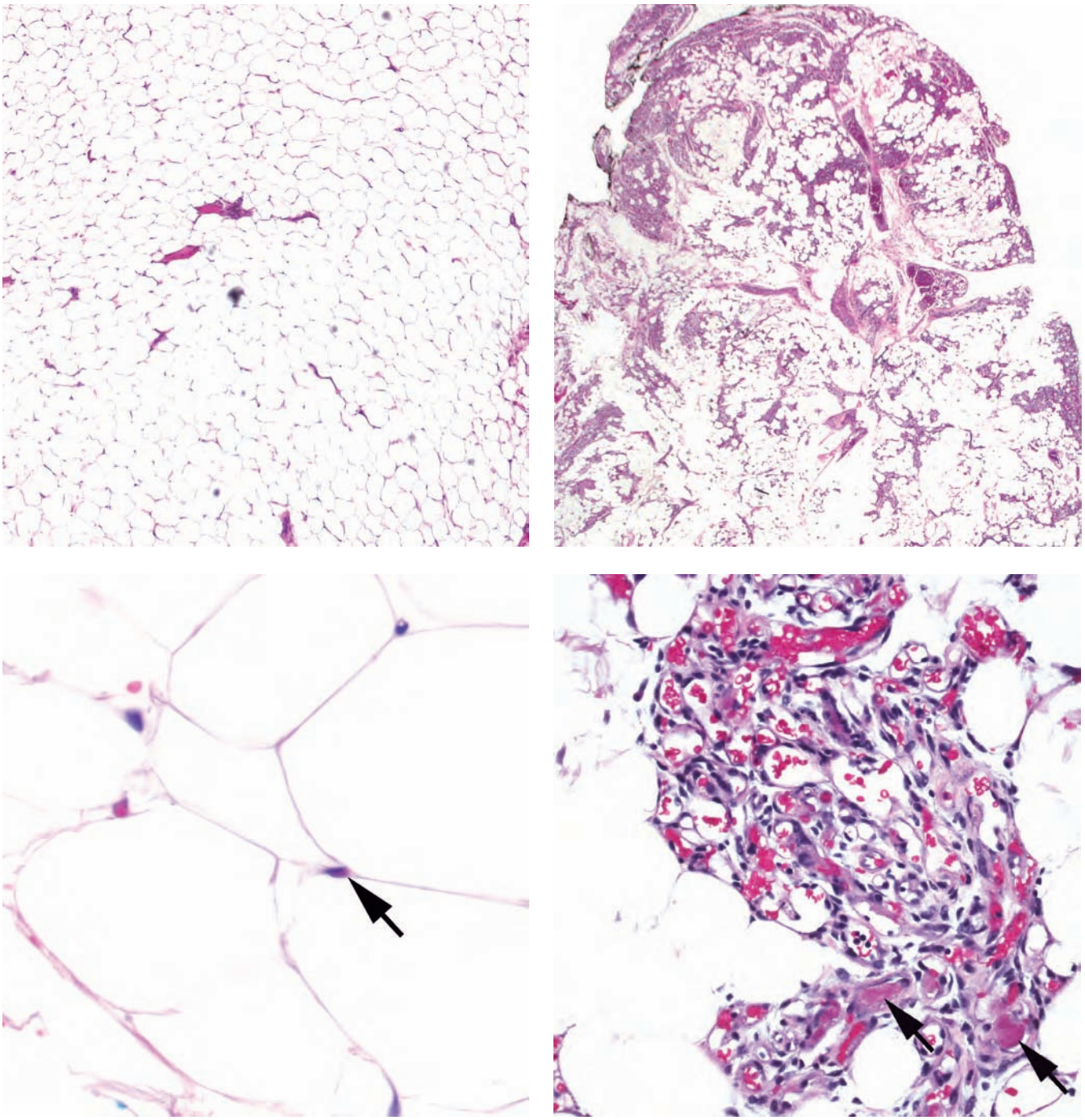

- "Clear" cells with compressed peripheral nucleus (arrow, left lower image)
- Clear cells are adipocytes, arranged in lobules
- Decreased/absent septae
- Angiolipoma also has an increased number of small vessels, some containing fibrin (arrows, right lower image)

Lipoma (left) / Angiolipoma (right)

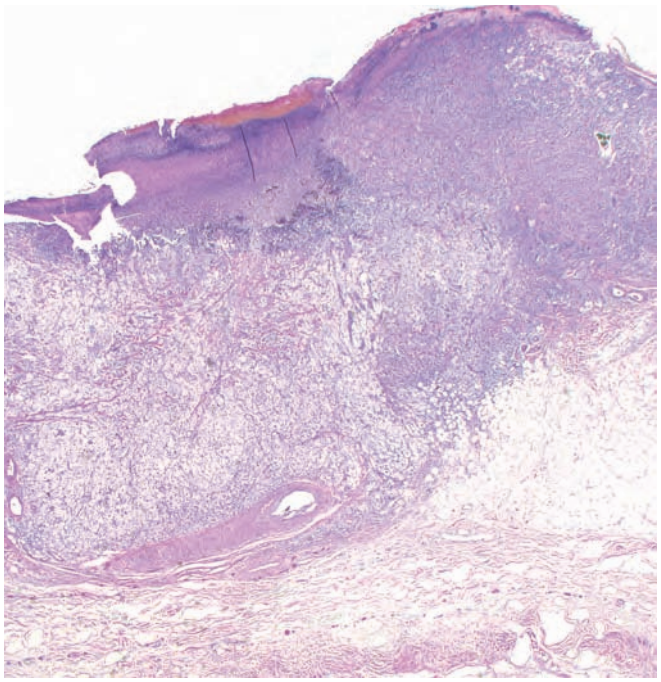

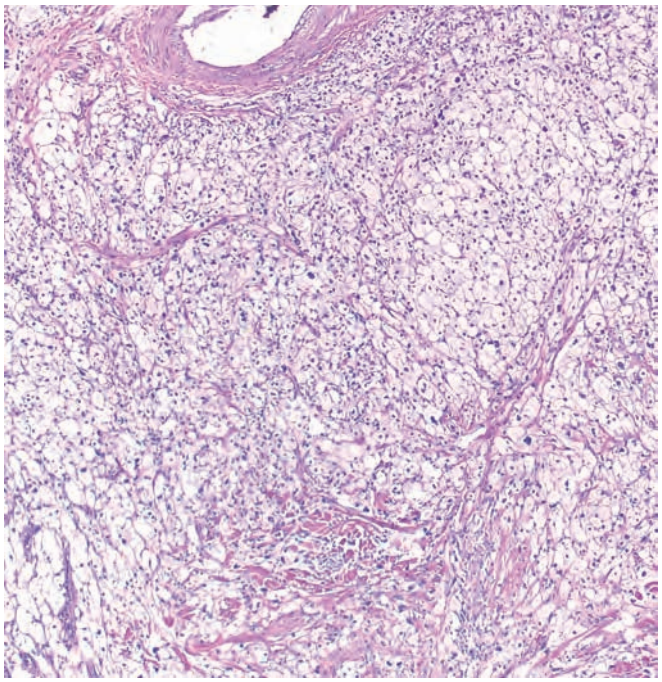

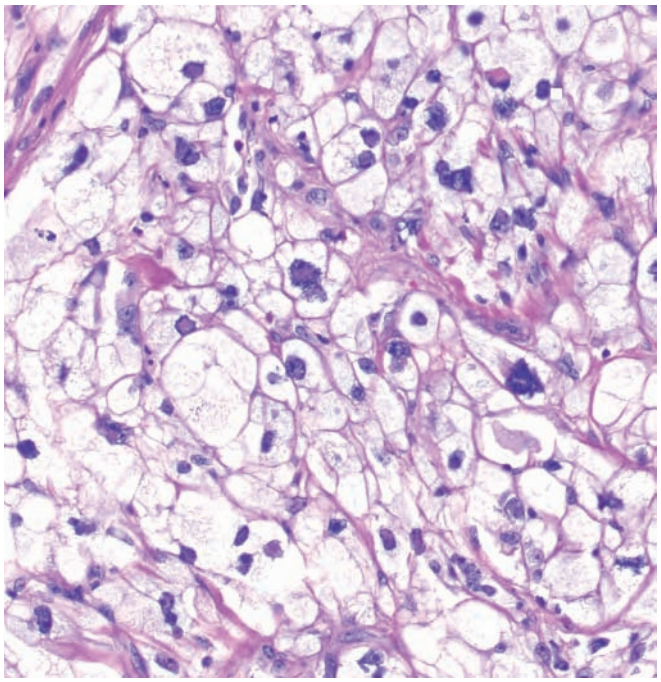

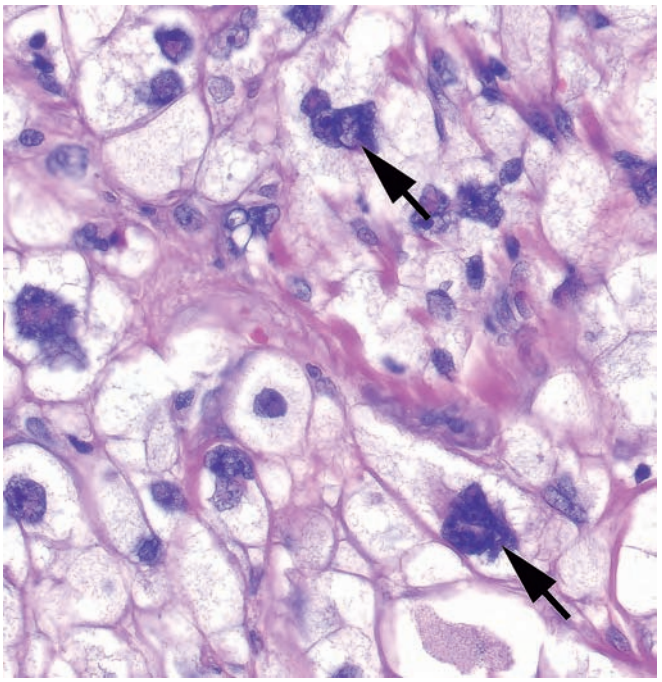

- "Clear" cells
- Cells are melanocytes that have clear/foamy cytoplasm
- Cells have atypical nuclei (arrows)
- Special stains may be necessary to confirm the diagnosis
- Foci of conventional melanoma or a junctional component as clues

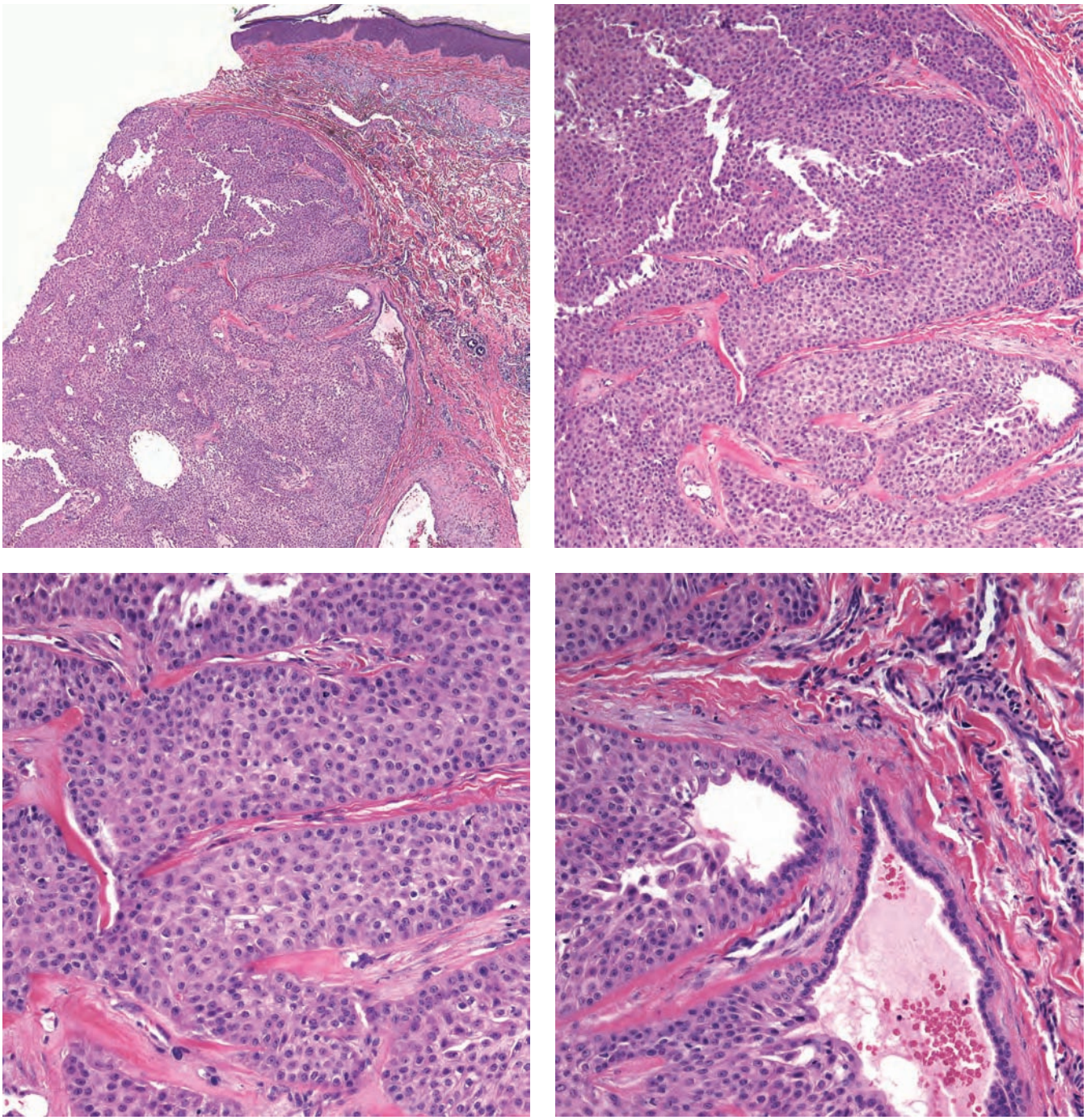

- "Clear" cells
- Cells are arranged in lobules with areas of ductal differentiation
- Hyalinized collagen often present

Nodular hidradenoma

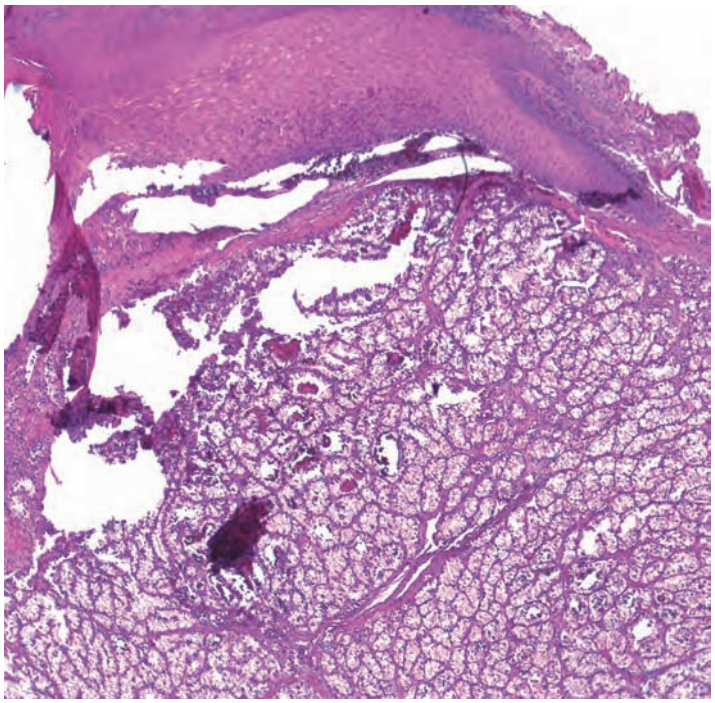

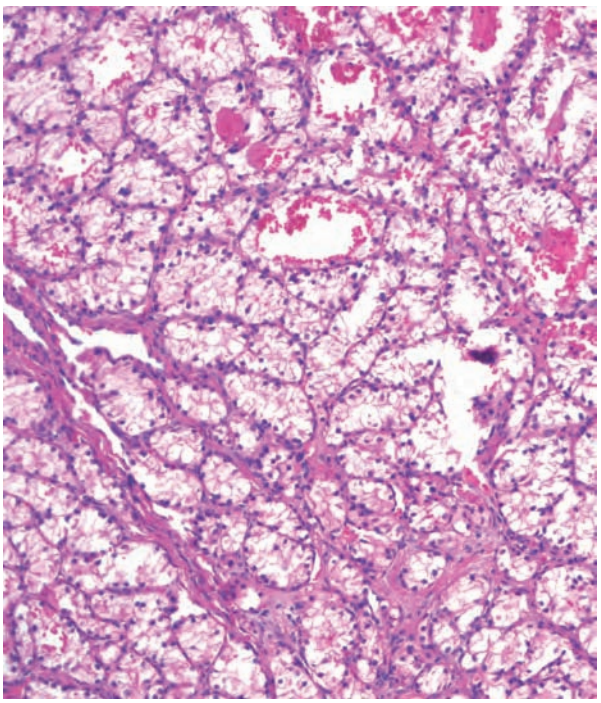

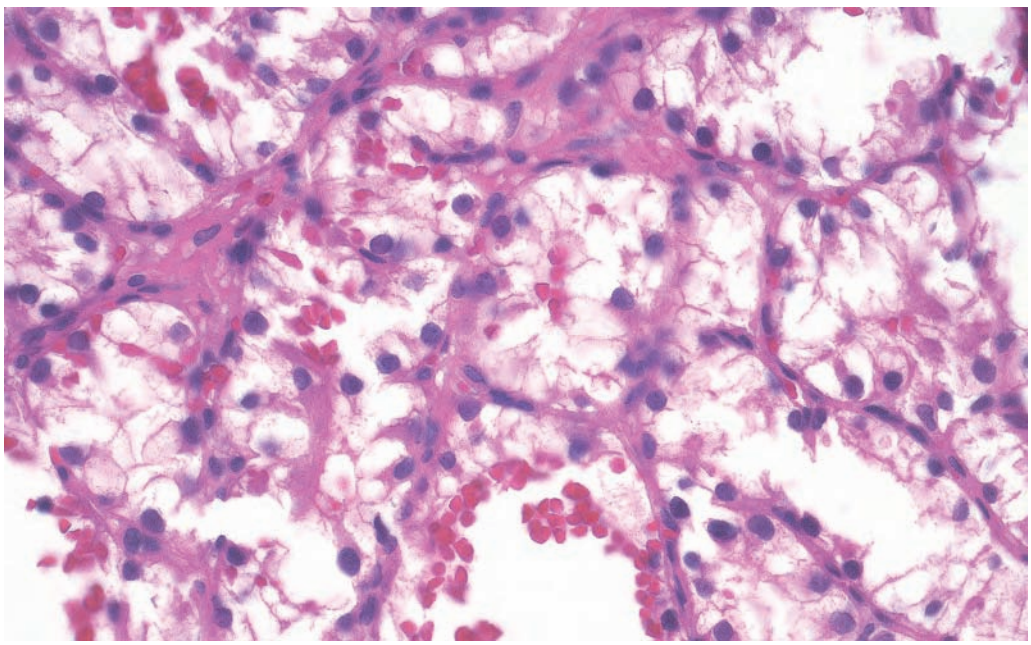

- "Clear" cells
- Often in cords, islands or pseudoglandular structures
- Cells are of renal origin and are surrounded by prominent blood vessels/extravasated erythrocytes

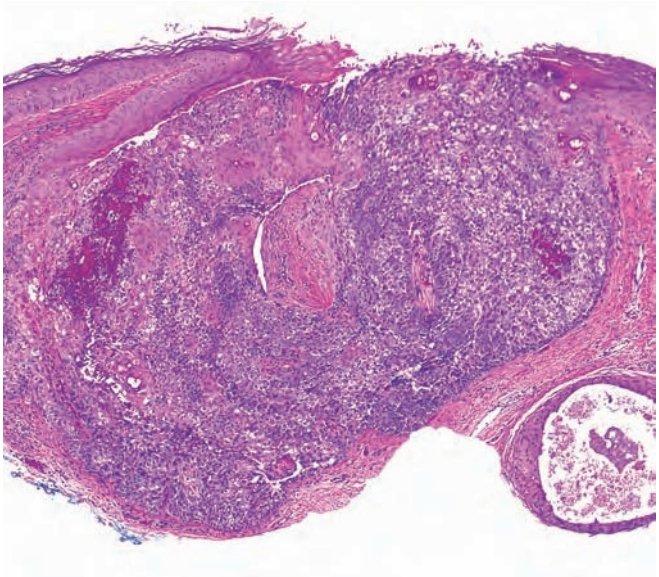

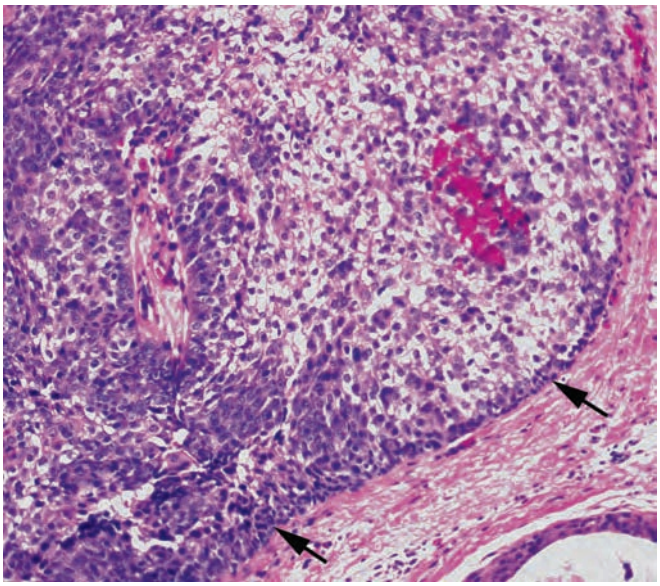

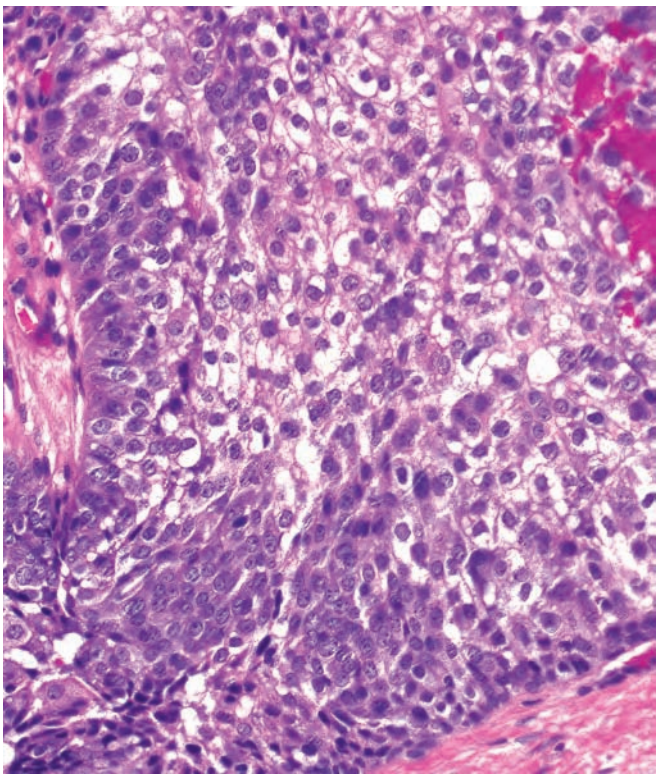

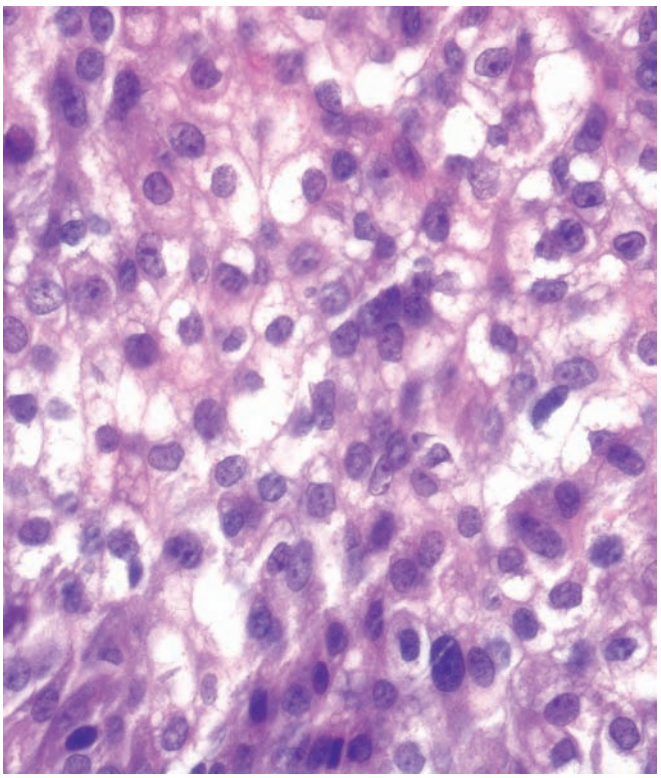

- "Clear" cells
- Cells are sebocytes often with spiky/scalloped nuclei bordered by several layers of basaloid cells (arrows)
- Generally on low power is a downward lobular proliferation from the epidermis

Sebaceous adenoma

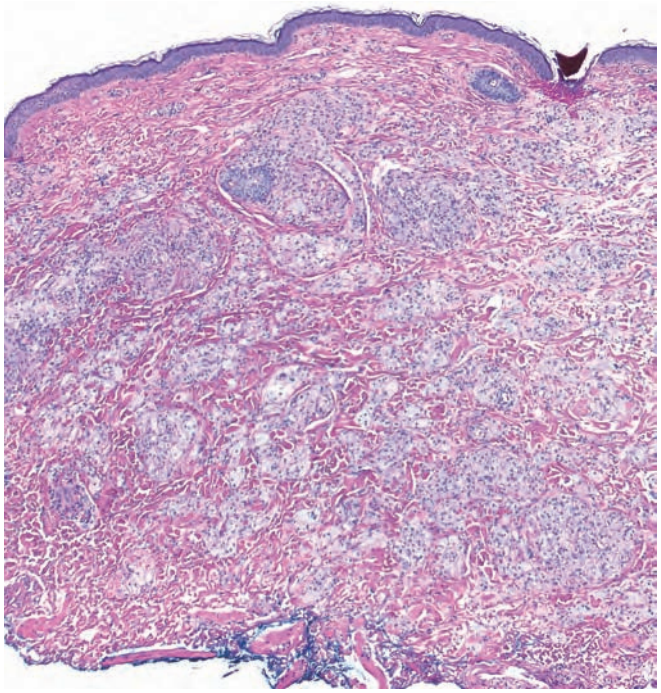

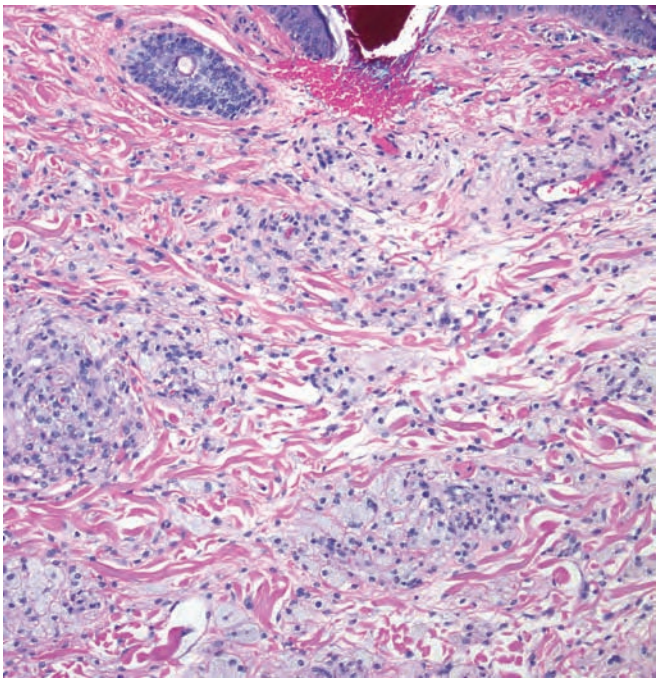

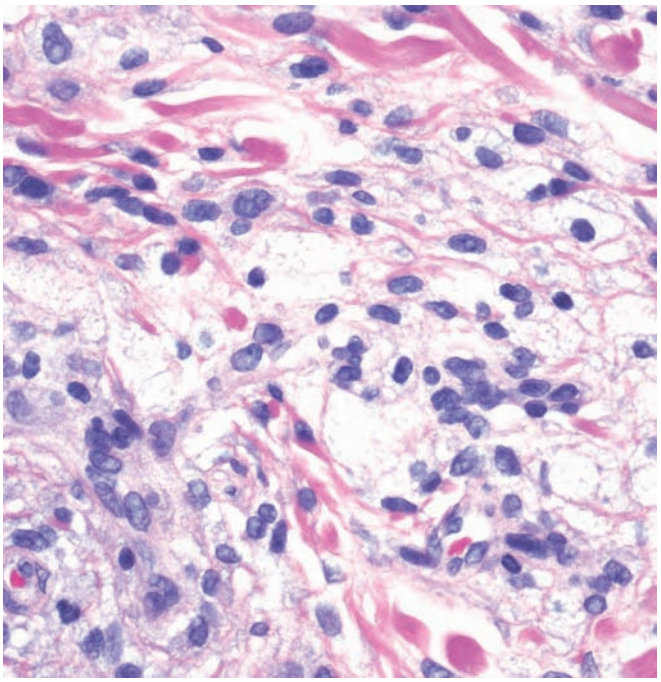

- "Clear" cells
- Cells are foamy histiocytes (filled with lipid), arranged in between collagen bundles
- Often a thin epidermis (eyelid skin)
- Vellus hairs may be present (eyelid skin)

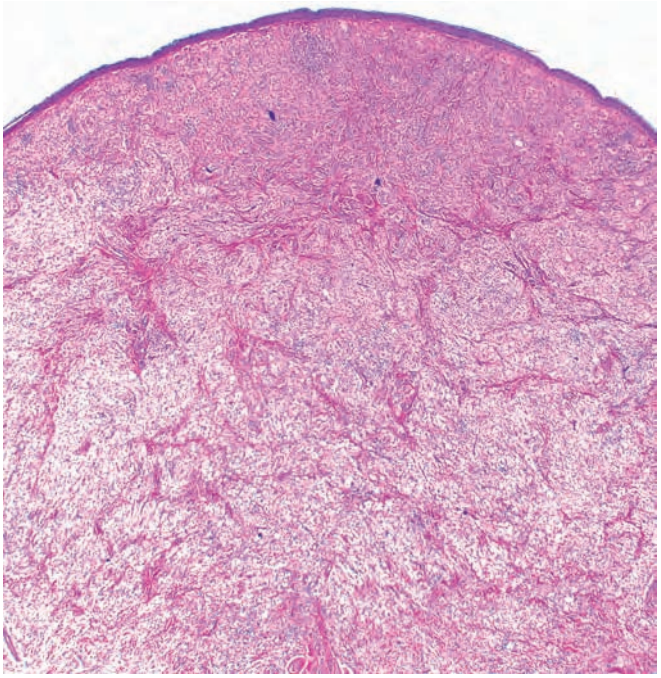

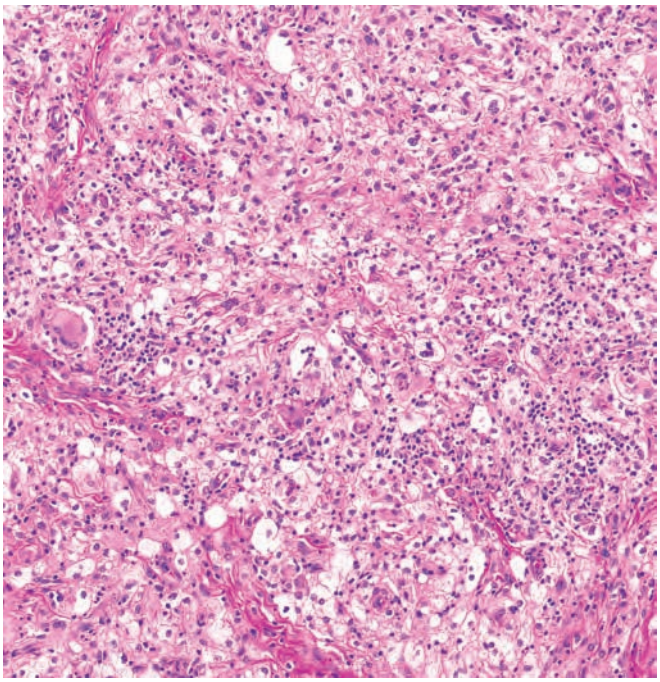

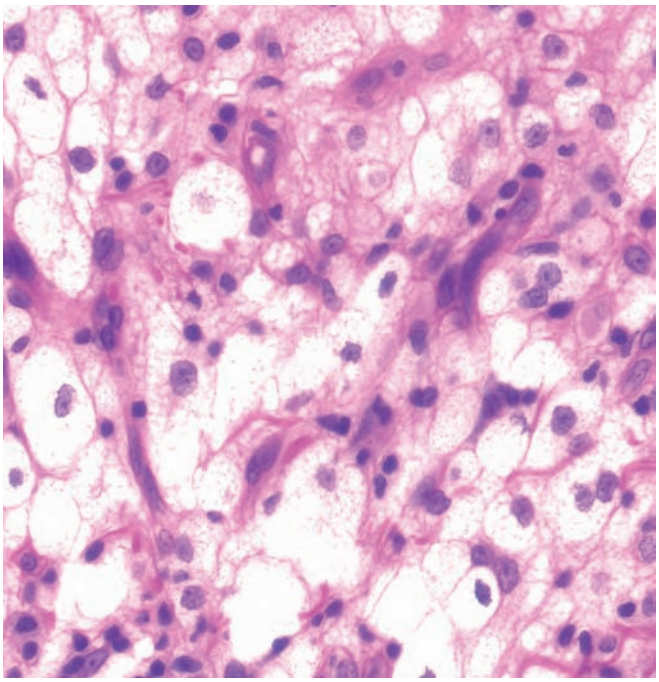

- "Clear" cells
- Cells are histiocytes, arranged in a well-circumscribed mass in the upper dermis
- Touton giant cells and eosinophils often seen

Xanthogranuloma (older lesion)

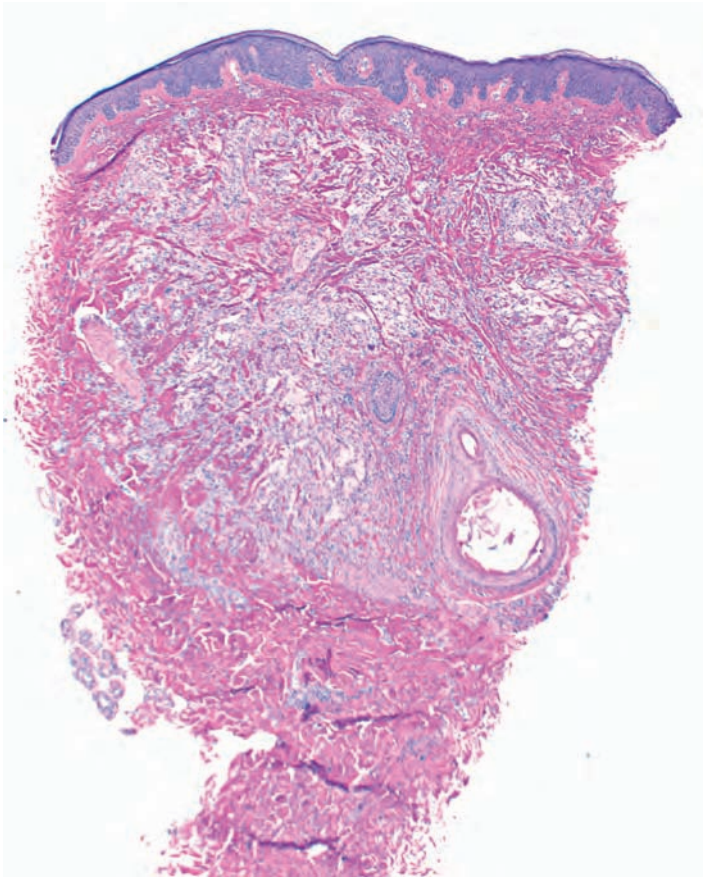

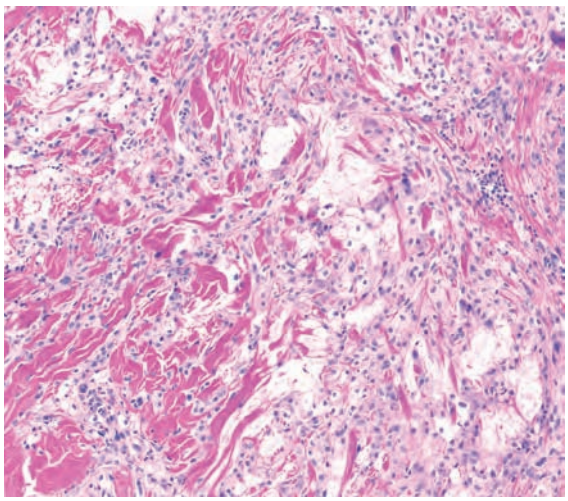

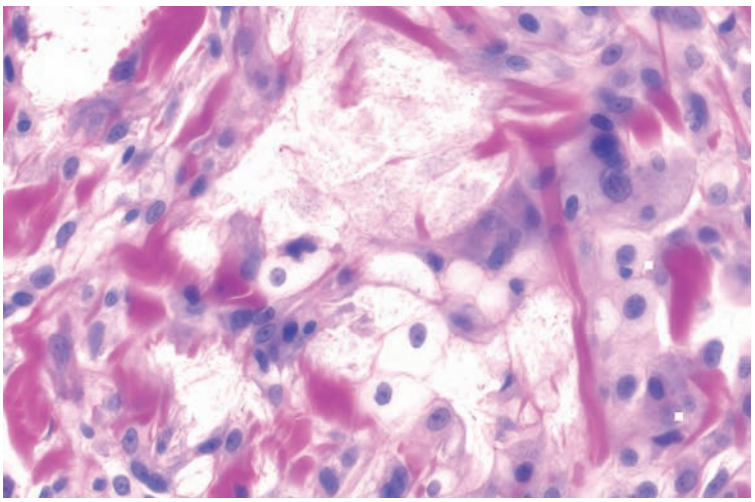

- "Clear" cells
- Cells are foamy histiocytes (filled with lipid), in clusters in the dermis
- Free lipid is present in eruptive xanthomas

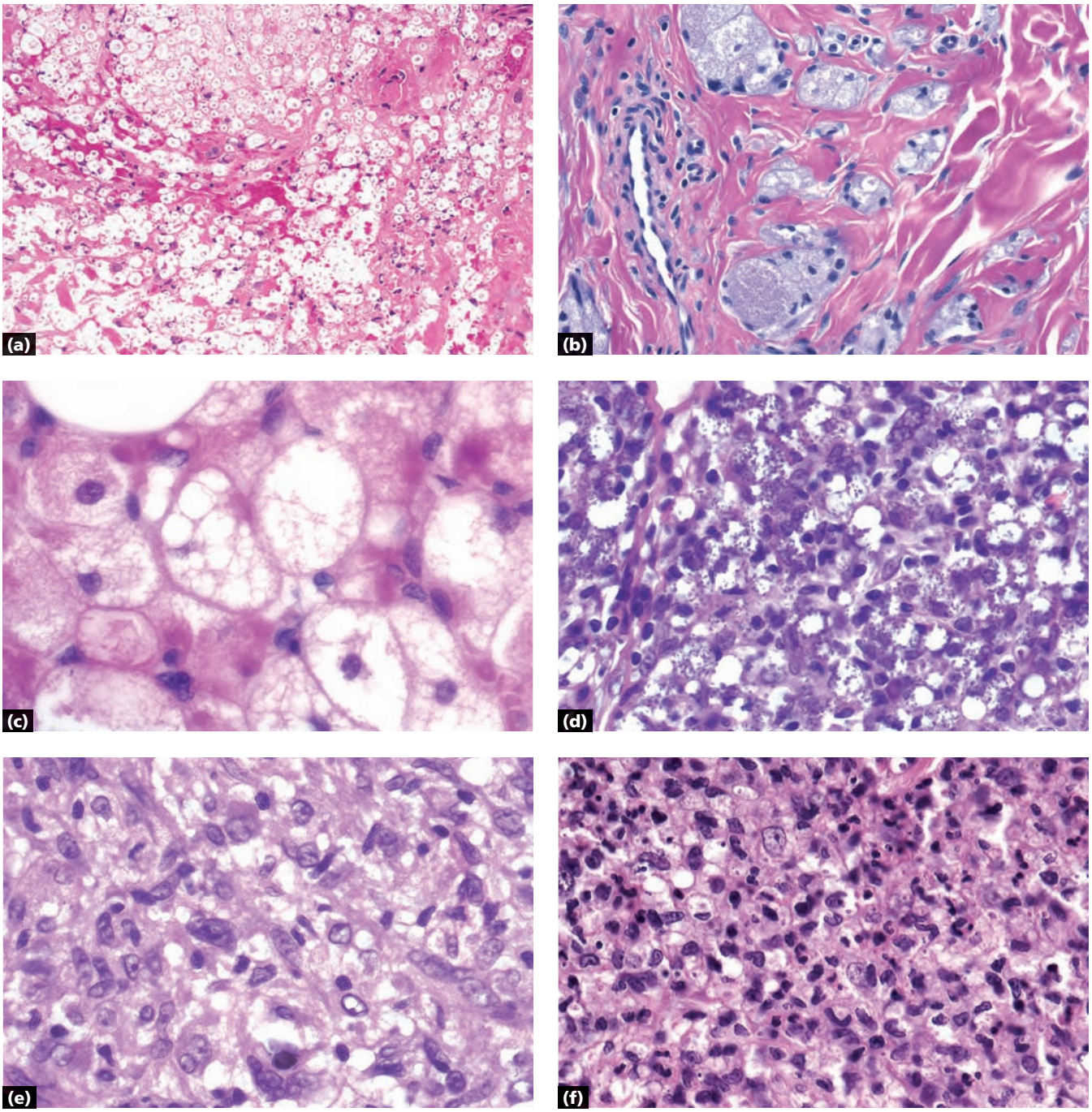

a Cryptococcosis, gelatinous: clear spaces representing the capsule of the organism
b Granular cell tumor: cells with grainy cytoplasm
c Hibernoma: cells with net-like vaculolated cytoplasm
d Leishmaniasis: macrophages filled with organisms
e Lepromatous leprosy: histiocytes filled with organisms; linear arrangement on low power
f Histoplasmosis: histiocytes with intracytoplasmic round organisms; organisms often surrounded by a clear space (the capsule)

Key differences

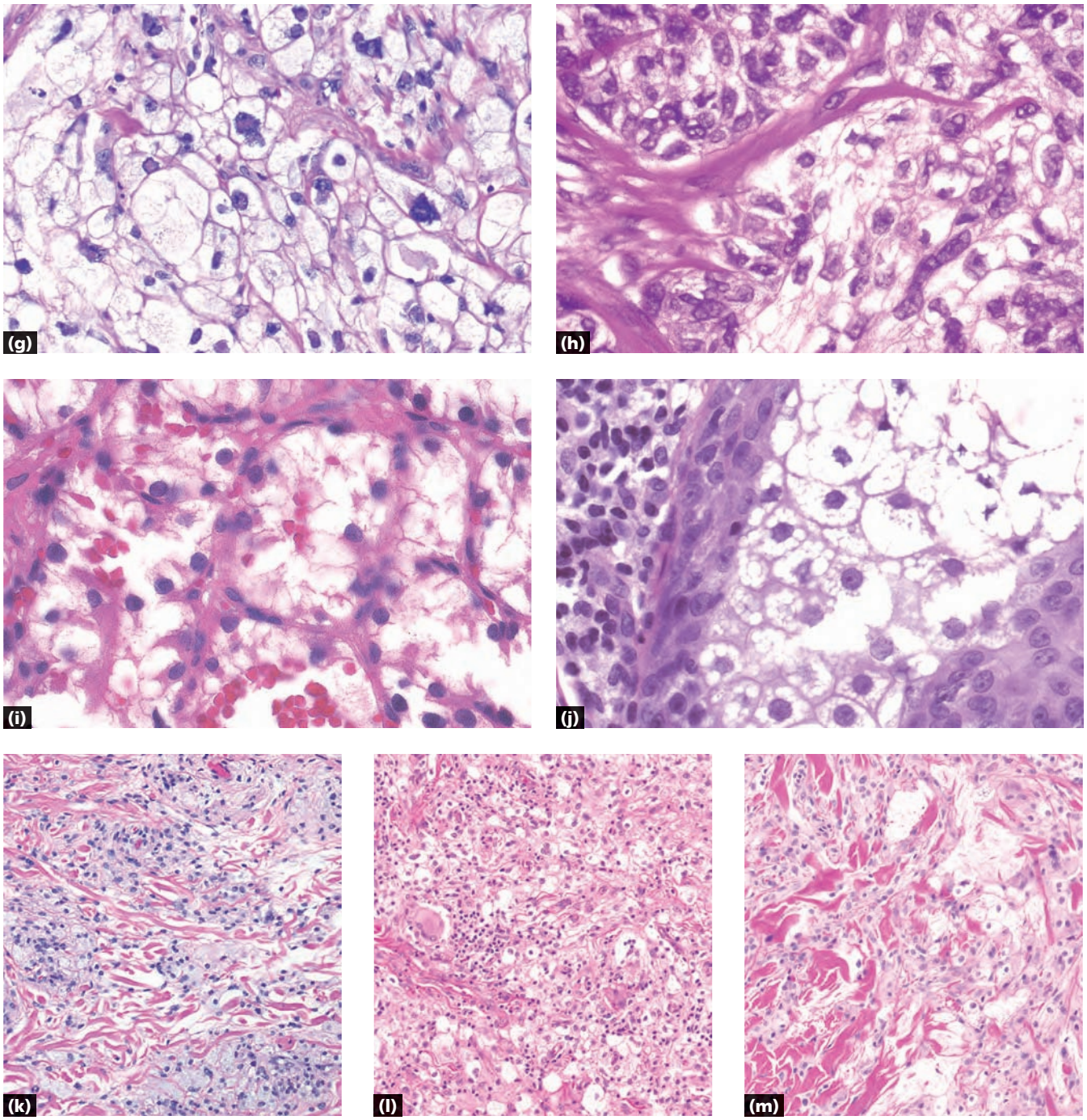

g Melanoma, balloon cell: atypical nuclei with clear cytoplasm
h Nodular hidradenoma: clear cells with interspersed ducts and hyalinized collagen
i Renal cell carcinoma: clear cells with extravasated erythrocytes
j Sebaceous adenoma: clear sebocytes with star-shaped nuclei with a rim of basaloid cells
k Xanthelasma: foamy cells interspersed in eyelid skin
l Xanthogranuloma: foamy cells with some Touton cells
m Xanthoma: foamy cells and extracellular lipid

Key differences, *continued*

4 Top-Down

- Hyperkeratosis/parakeratosis, 221
- Upper epidermal change, 228
- Acantholysis, 238
- Subepidermal space/cleft, 248
- Granular "material" in cells, 255
- "Busy" dermis, 260
- Dermal material, 263
- Fat necrosis, 276

Dermatopathology: Diagnosis by First Impression, Third Edition. By Christine J. Ko and Ronald J. Barr.
© 2017 John Wiley & Sons, Ltd. Published 2017 by John Wiley & Sons, Ltd.
Companion website: www.wiley.com/go/ko/dermatopathology3e

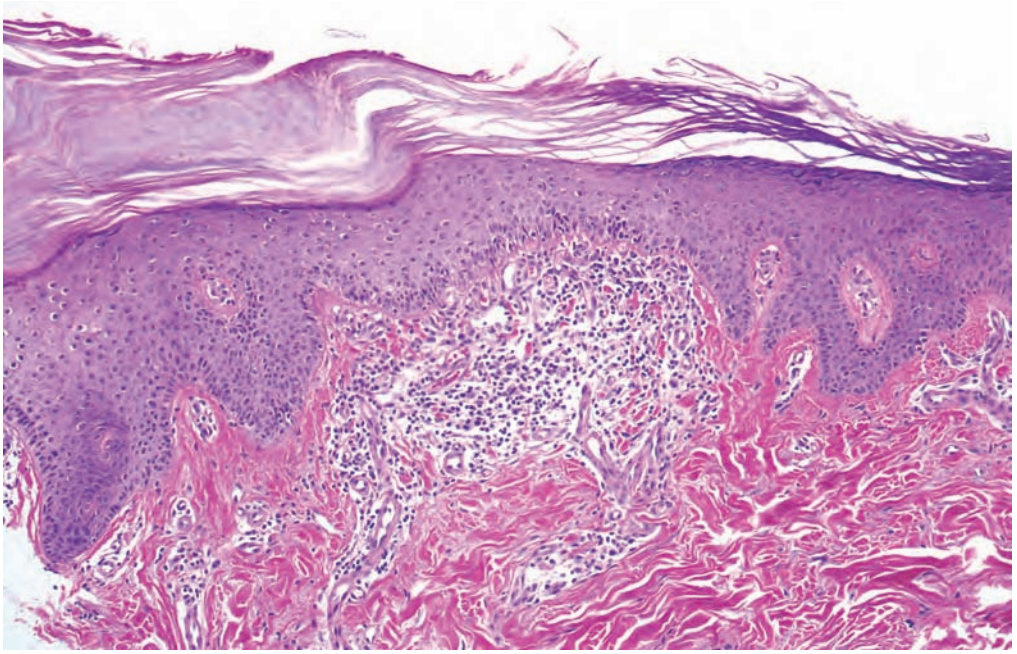

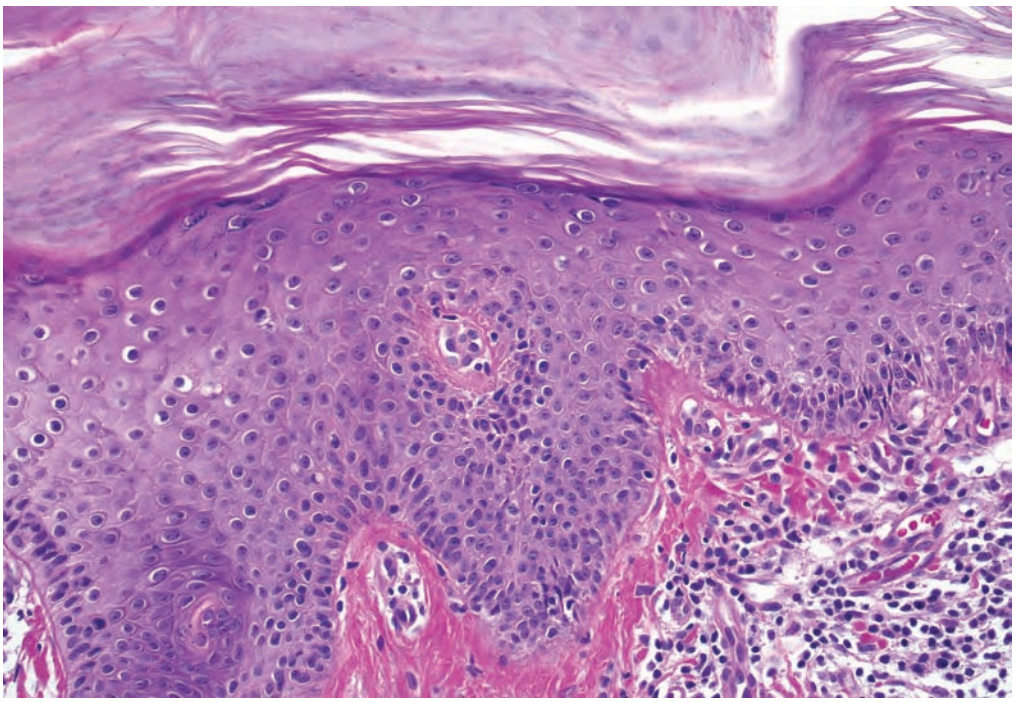

- Hyperkeratosis and variable lymphocytic infiltrate
- Scattered "dyskeratotic" keratinocytes may be present
- Atrophic or acanthotic epidermis

Flegel disease

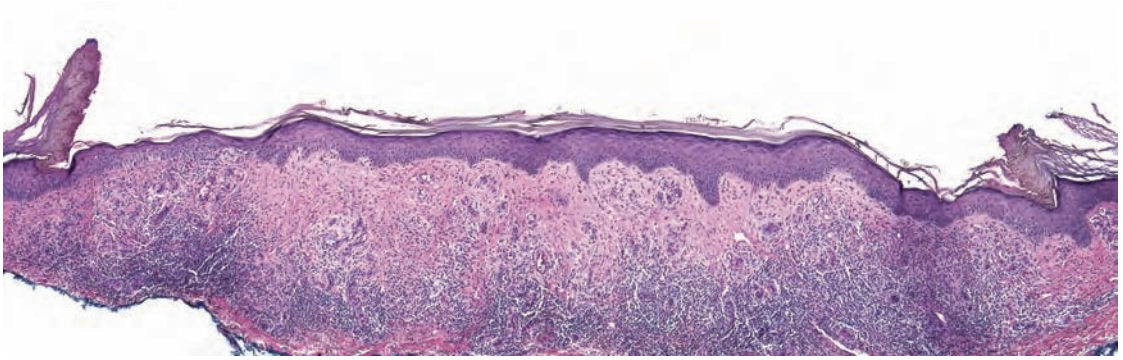

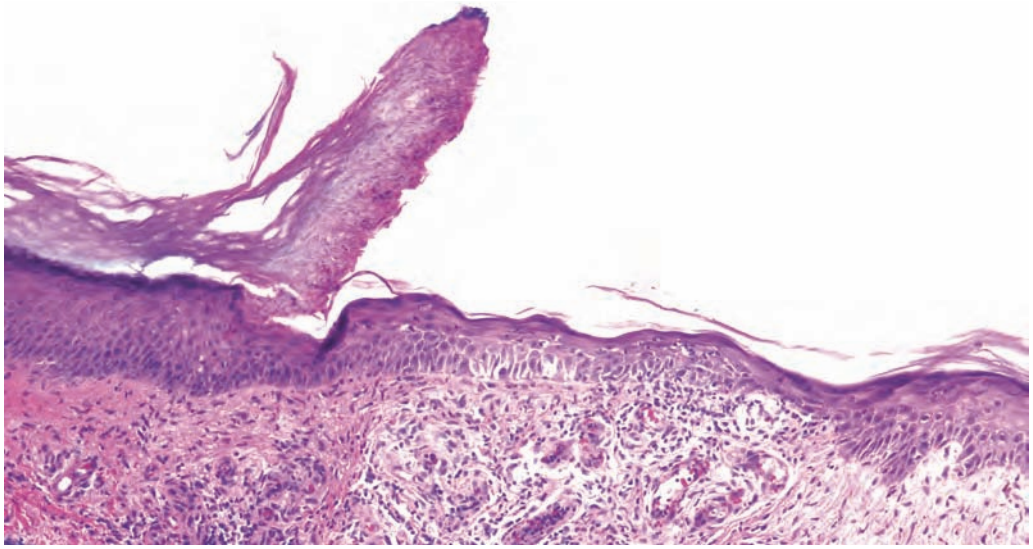

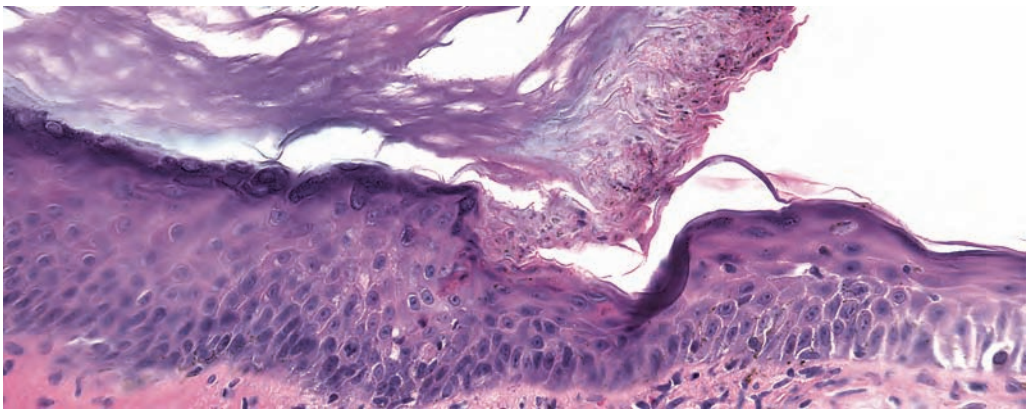

- Hyperkeratosis/parakeratosis (cornoid lamellae) and lymphocytic infiltrate
- Cornoid lamellae (tiered parakeratosis above altered granular layer) (arrow)
- A lichenoid infiltrate may be present

Porokeratosis

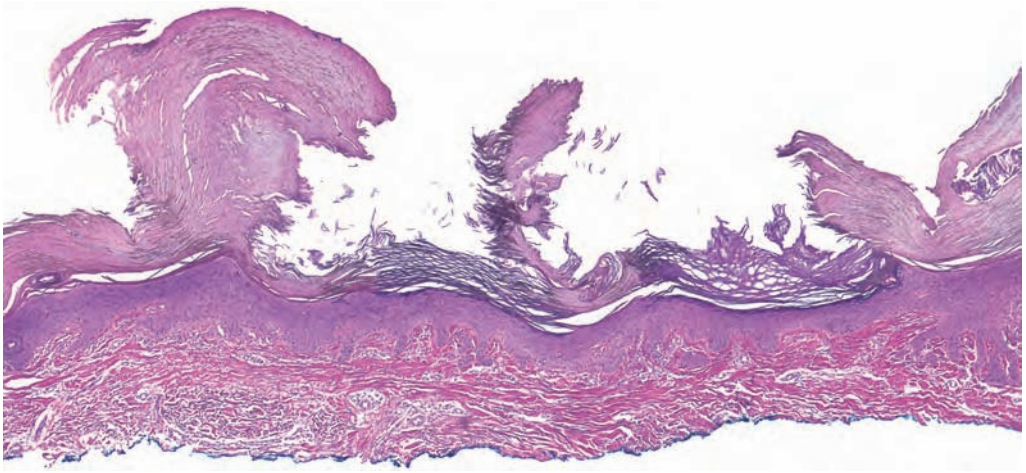

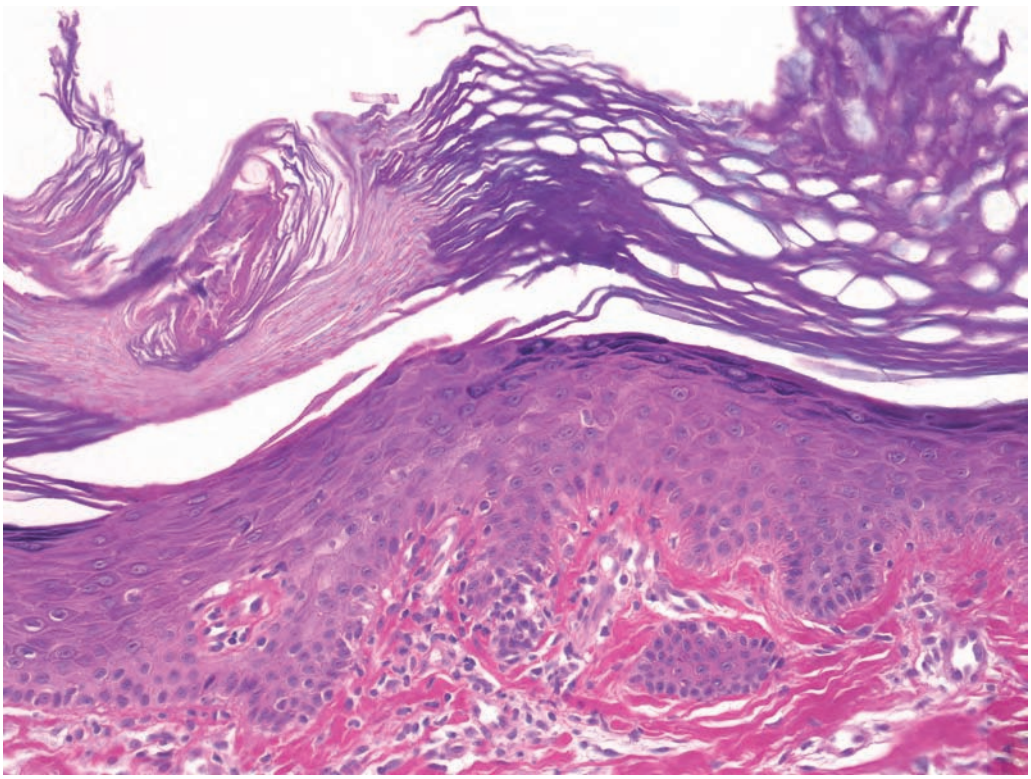

- Hyperkeratosis alternating with parakeratosis
- Acanthotic epidermis

Inflammatory linear verrucous epidermal nevus

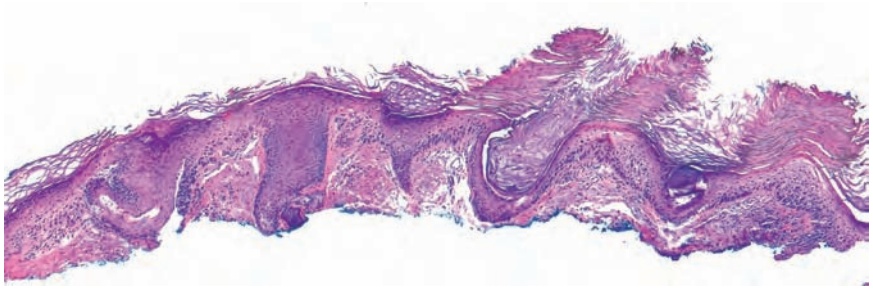

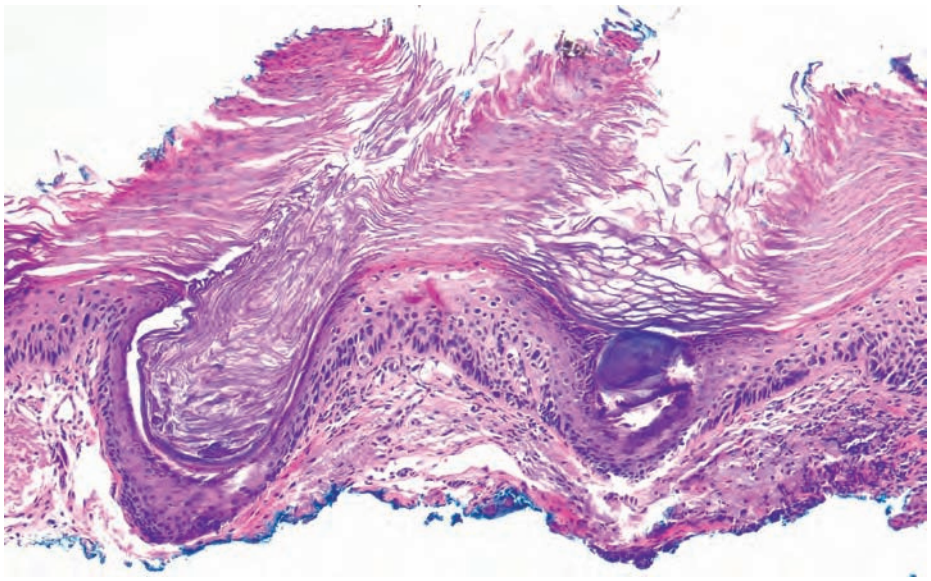

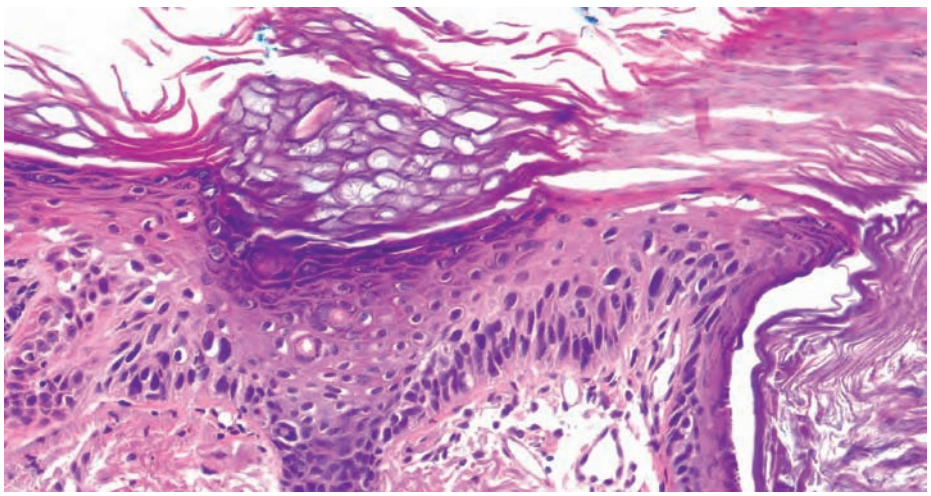

- Hyperkeratosis alternating with parakeratosis (alternating pink and blue stratum corneum)
- Beneath parakeratosis, atypical keratinocytes in lower epidermis
- Orthokeratosis above banal keratinocytes in adnexal structures

Actinic keratosis

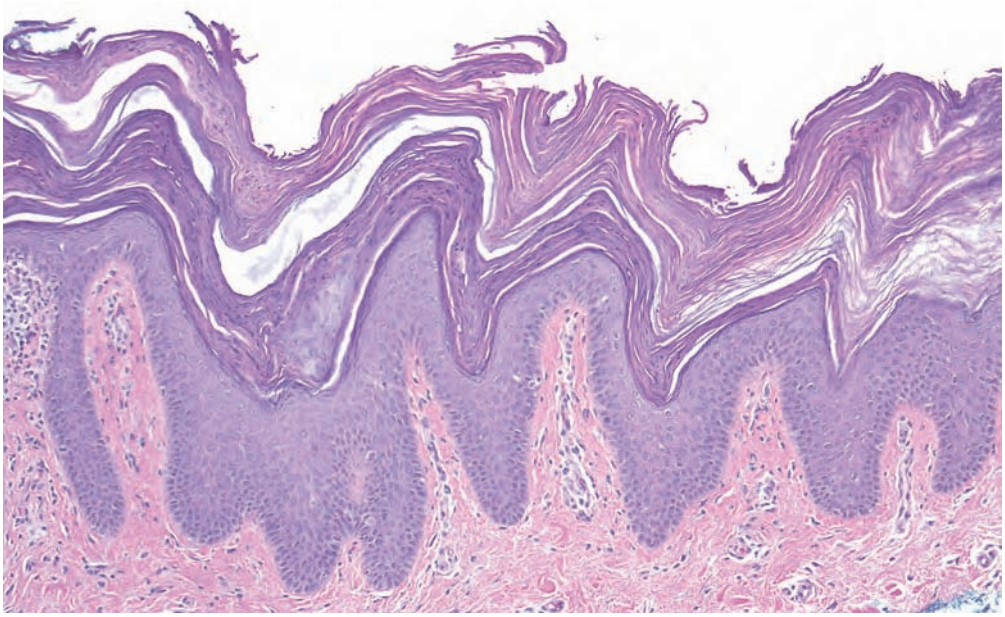

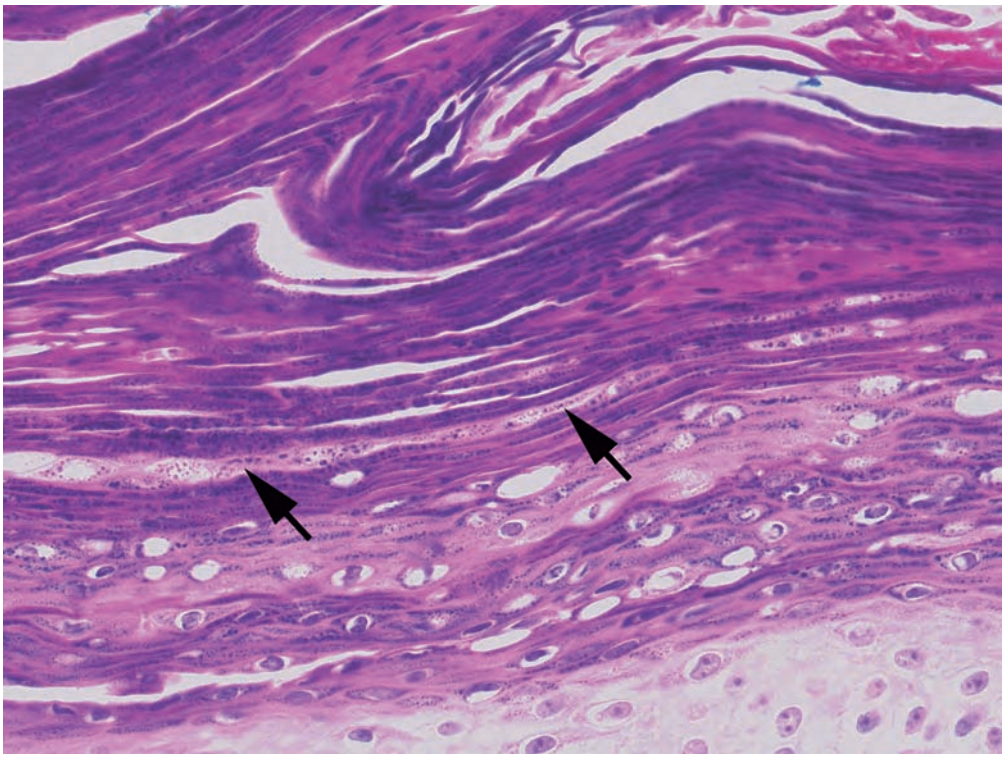

- Parakeratosis with granules
- Granules retained in the stratum corneum (arrows)

Axillary granular parakeratosis

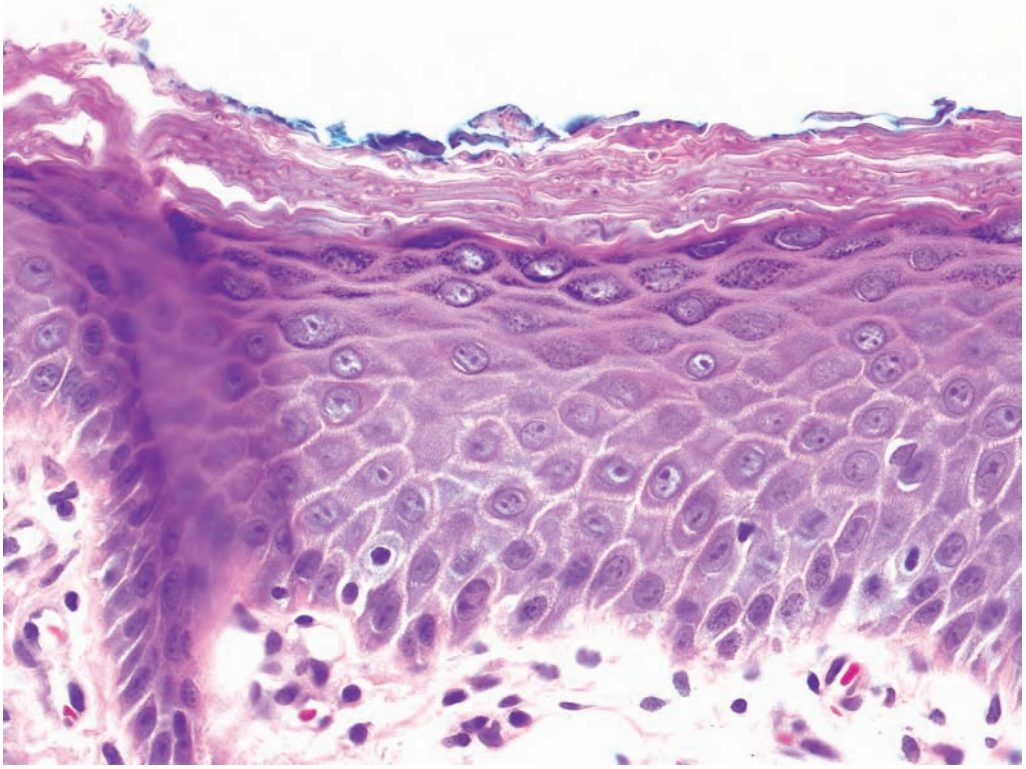

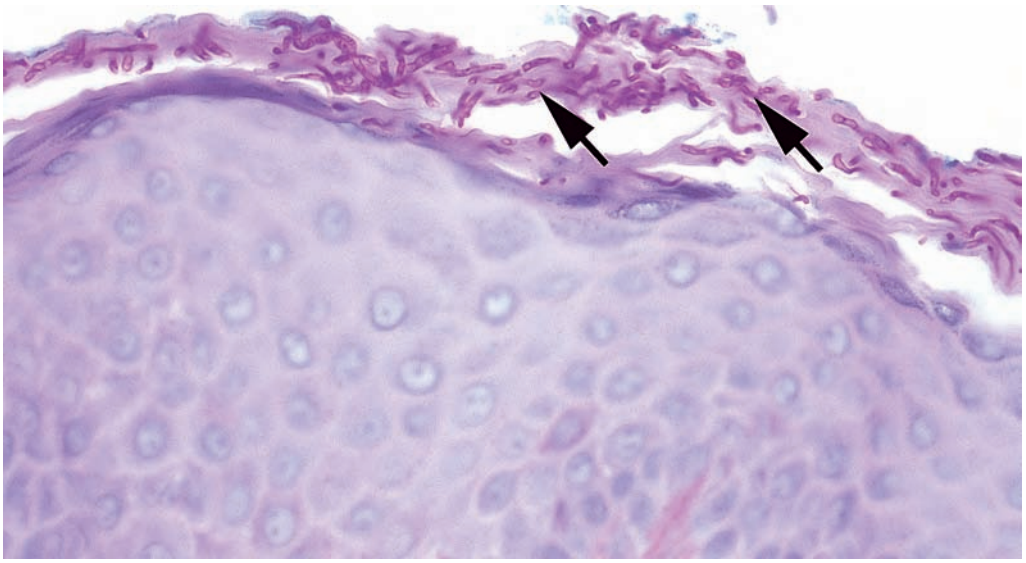

- Parakeratosis with organisms
- Slightly refractile organisms (spheres and tubules) in stratum corneum
- Parakeratosis may be seen above orthokeratosis ("sandwich sign")
- Obvious organisms on PAS (arrows)

Dermatophytosis

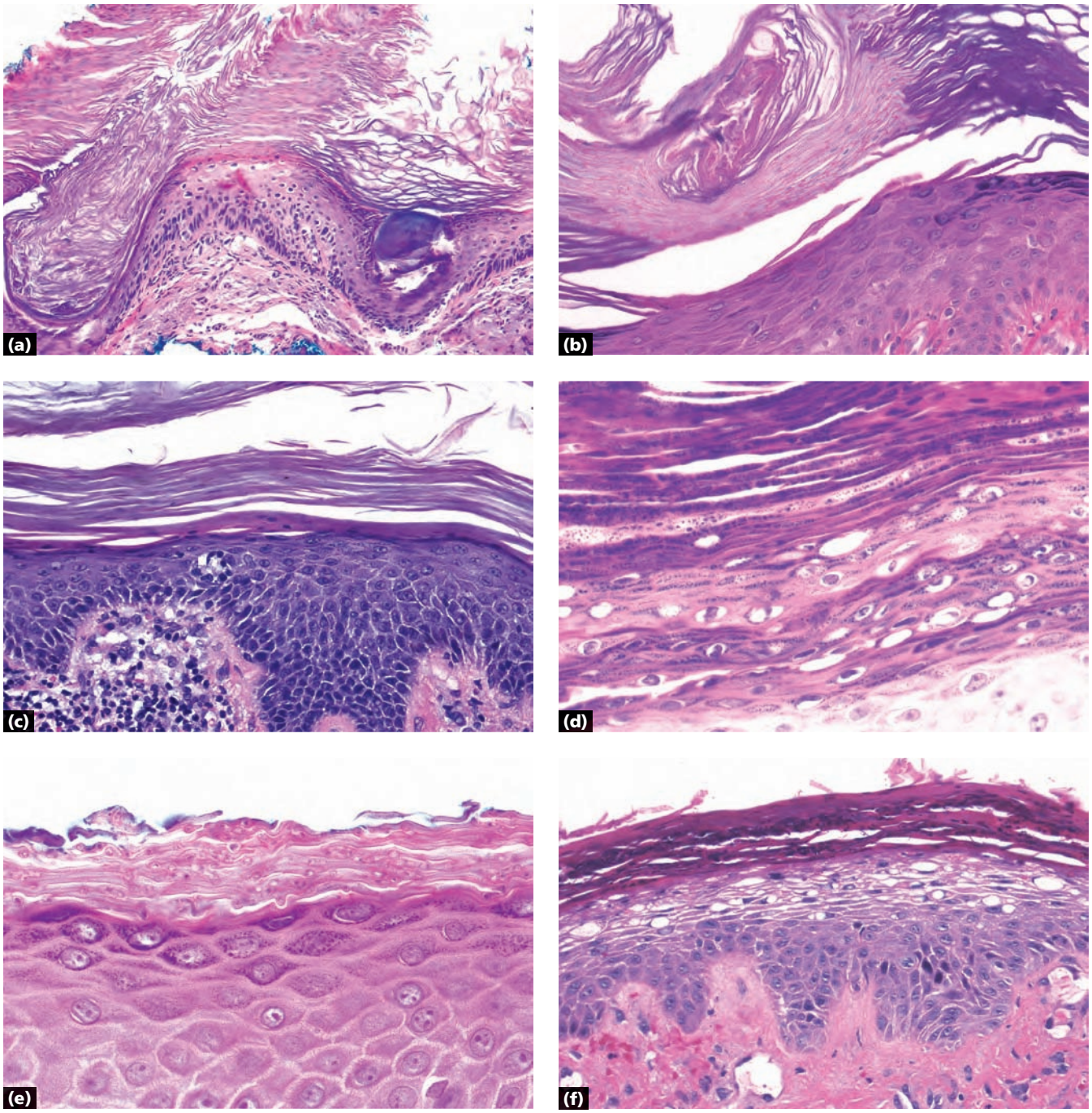

a Actinic keratosis: alternating pink and blue stratum corneum above buds of atypical keratinocytes and banal keratinocytes in spared adnexal structures
b Inflammatory linear verrucous epidermal nevus: hyperkeratosis alternating with parakeratosis over acanthosis without atypia
c Pityriasis rubra pilaris: checkerboard parakeratosis and hyperkeratosis, irregular acanthosis (see page 108)
d Axillary granular parakeratosis: retained granules in stratum corneum
e Dermatophytosis: circles and linear hyphae in stratum corneum
f Nutritional deficiency: upper epidermal parakeratosis/necrosis with pallor (see page 321)

Note Tinea versicolor (has yeast and hyphal forms) is in the differential; dermatophytosis and tinear versicolor may be subtle and appear like "normal" skin on low power.

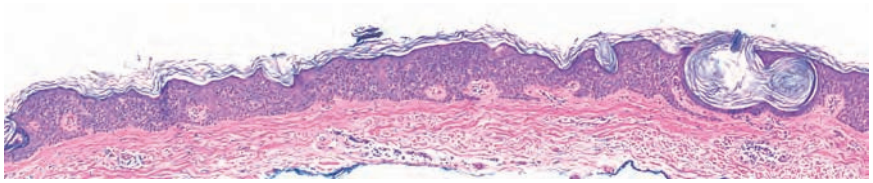

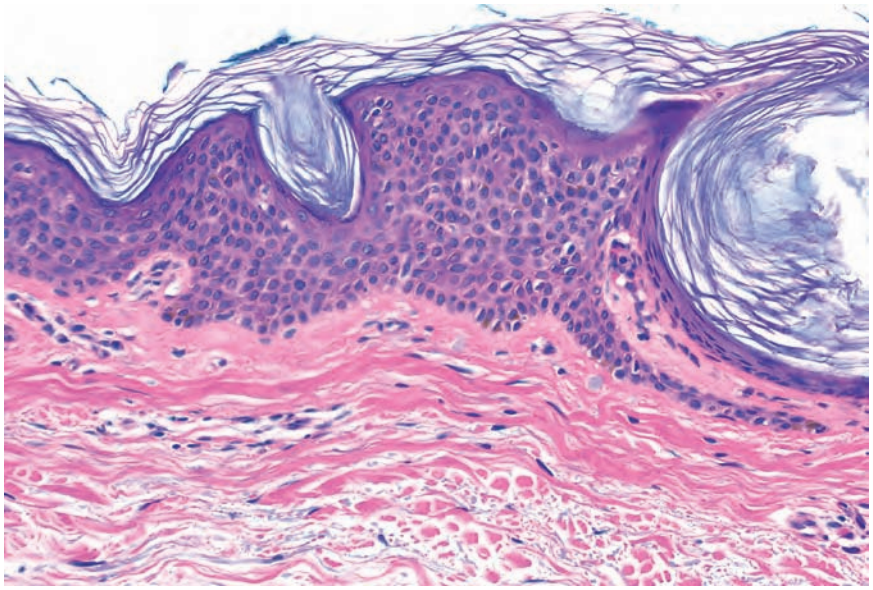

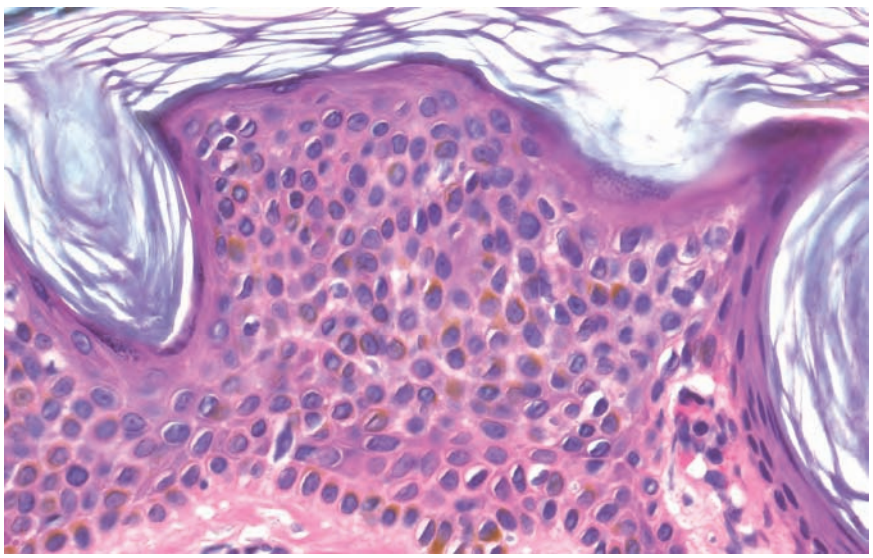

- Upper epidermal change of nests of keratinocytes that may be slightly paler than surrounding keratinocytes
- Nests are composed of monomorphous, typical keratinocytes

Clonal seborrheic keratosis

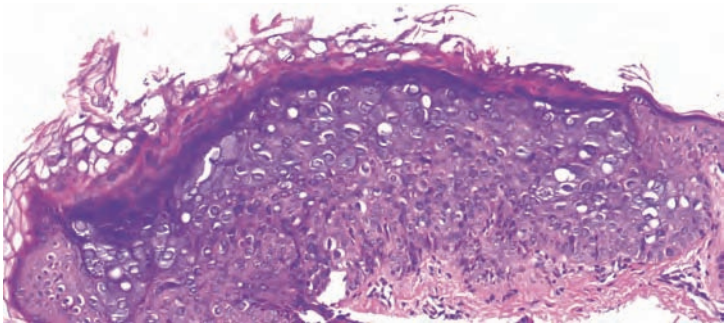

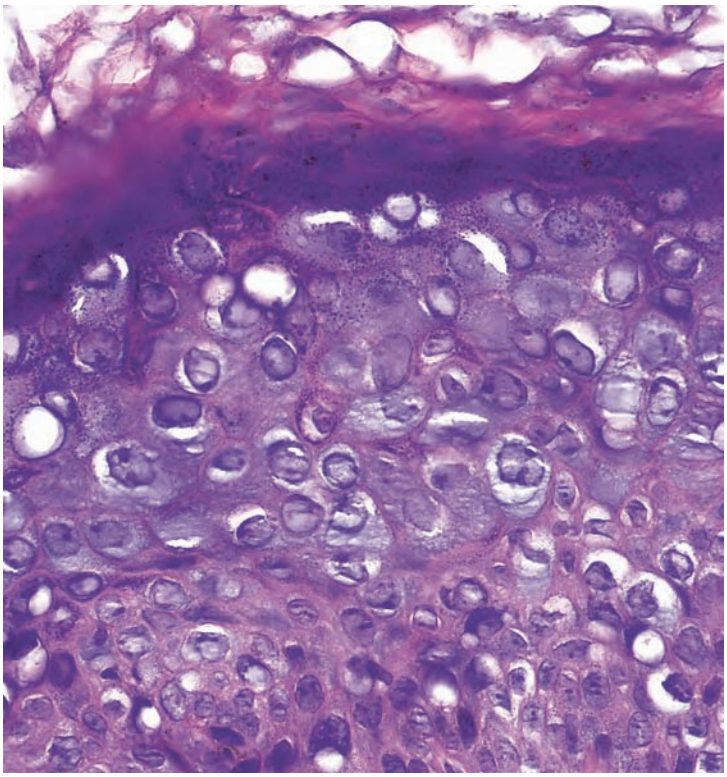

- Upper epidermal change of keratinocytes with blue-gray expanded cytoplasm and haloes around nuclei

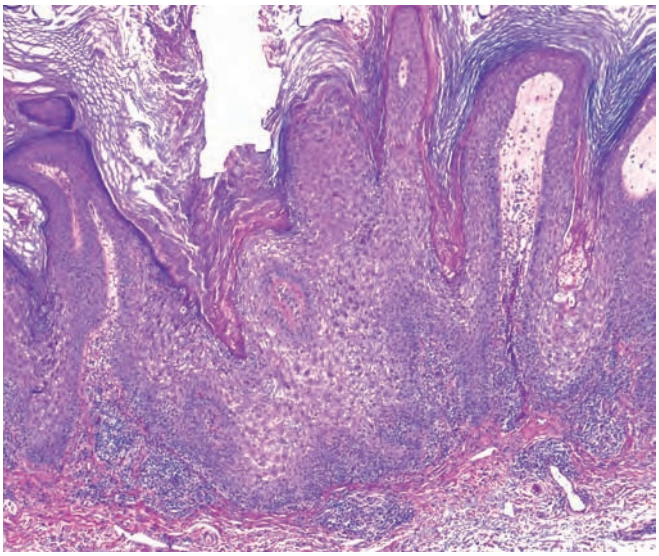

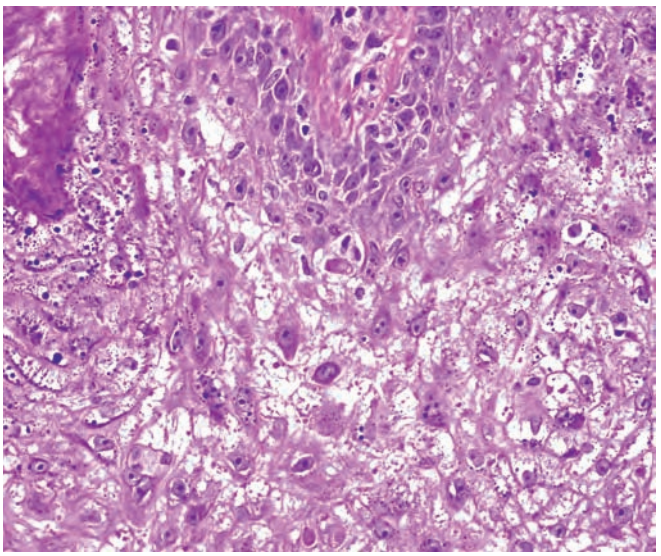

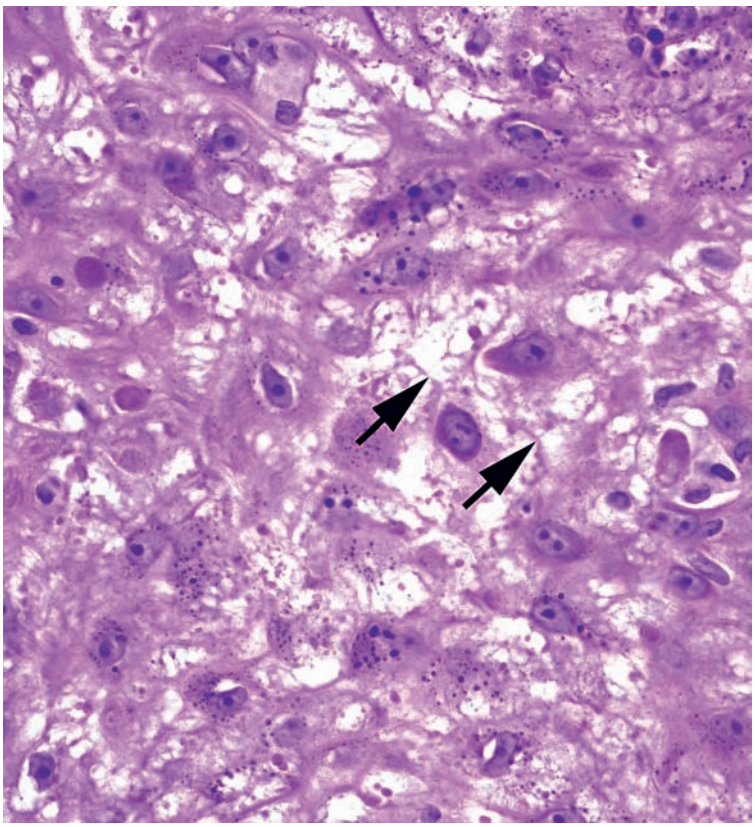

- Upper epidermal change of prominent keratohyaline granules and chicken-wire cell membranes – granular-vacuolar change (arrows)

Epidermolytic hyperkeratosis

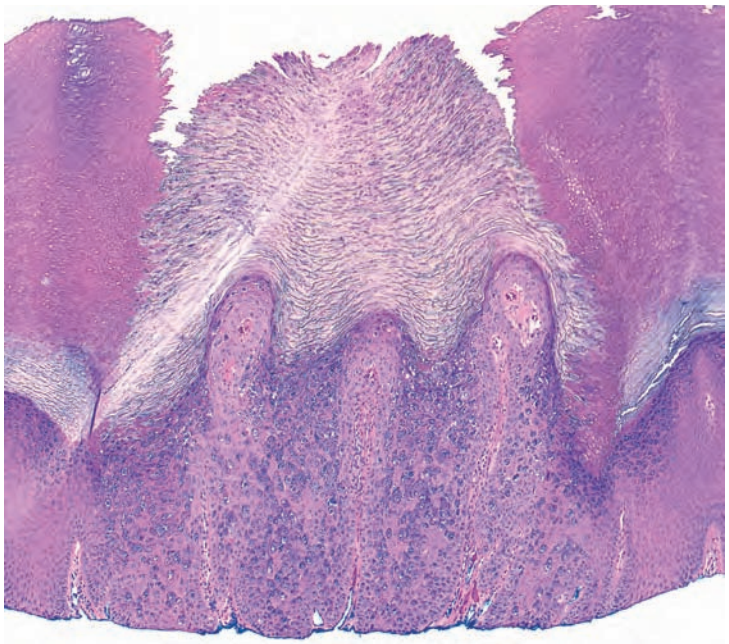

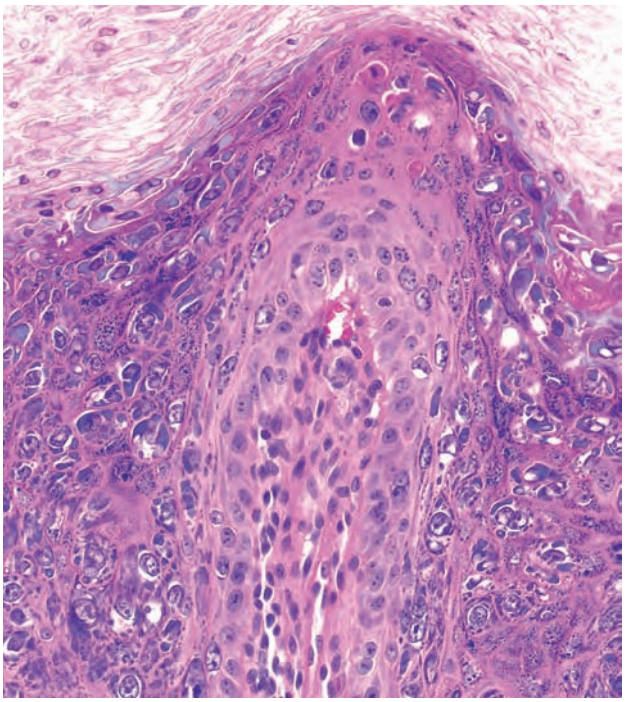

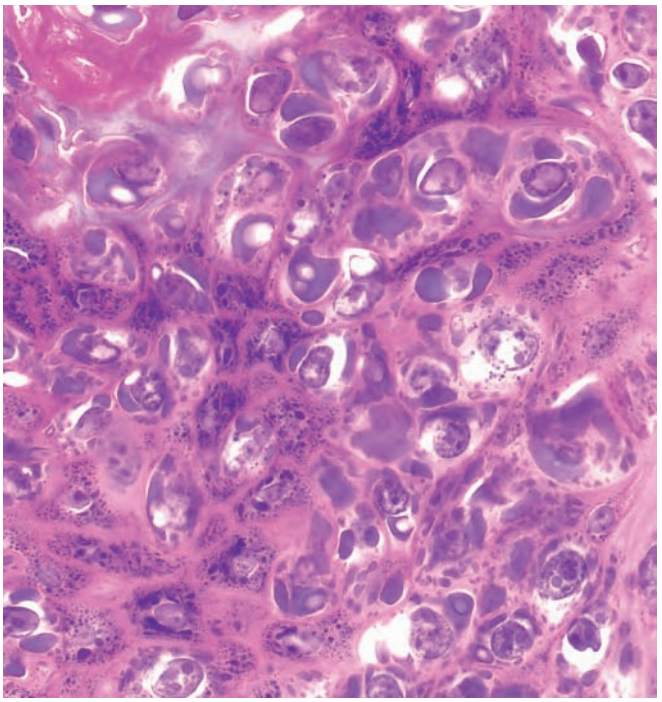

- Upper epidermal change of koilocytes with very prominent keratohyaline granules

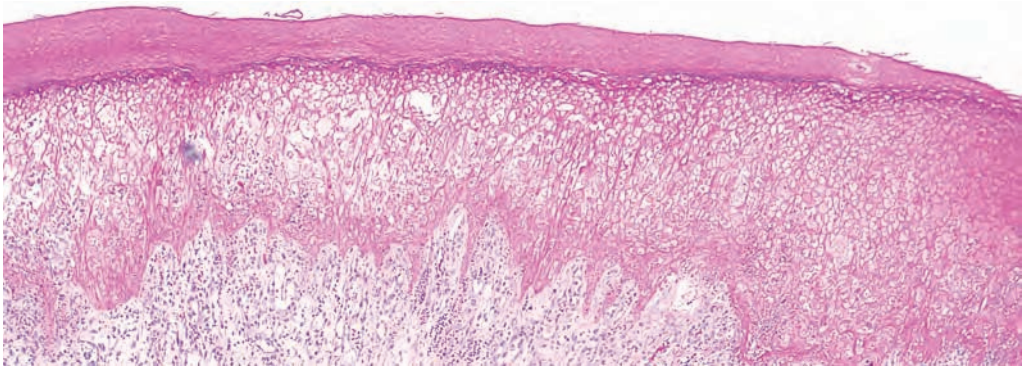

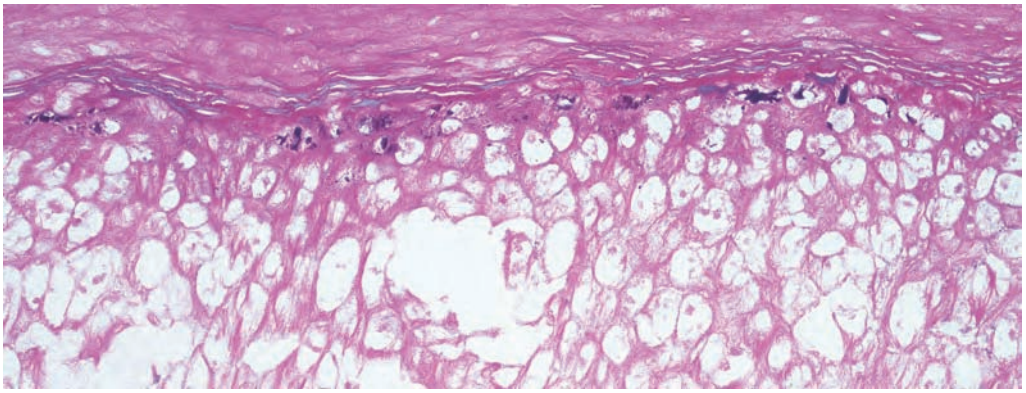

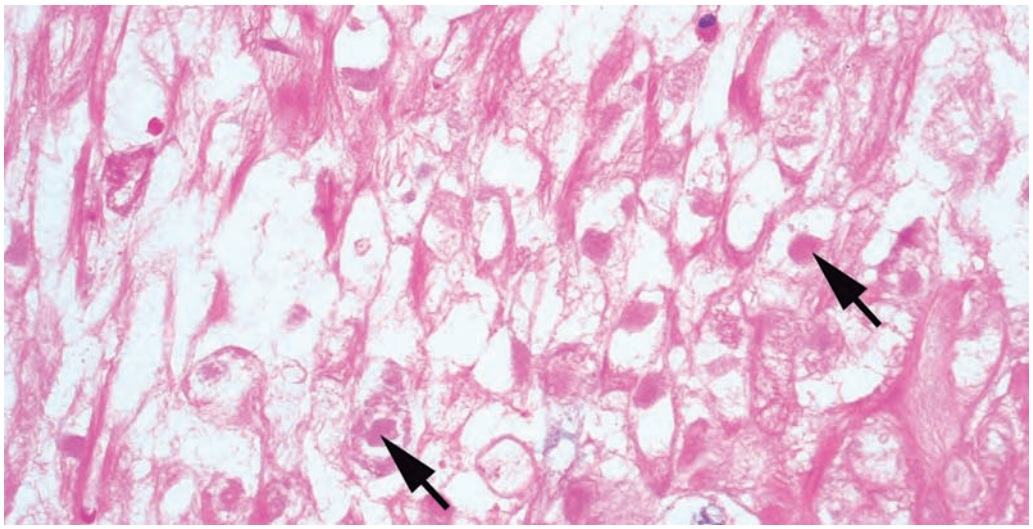

- Upper epidermal change of reticular degeneration (edema of the cells with retention of cell membranes) and pink intracytoplasmic globules (arrows)
- Usually acral skin

Orf

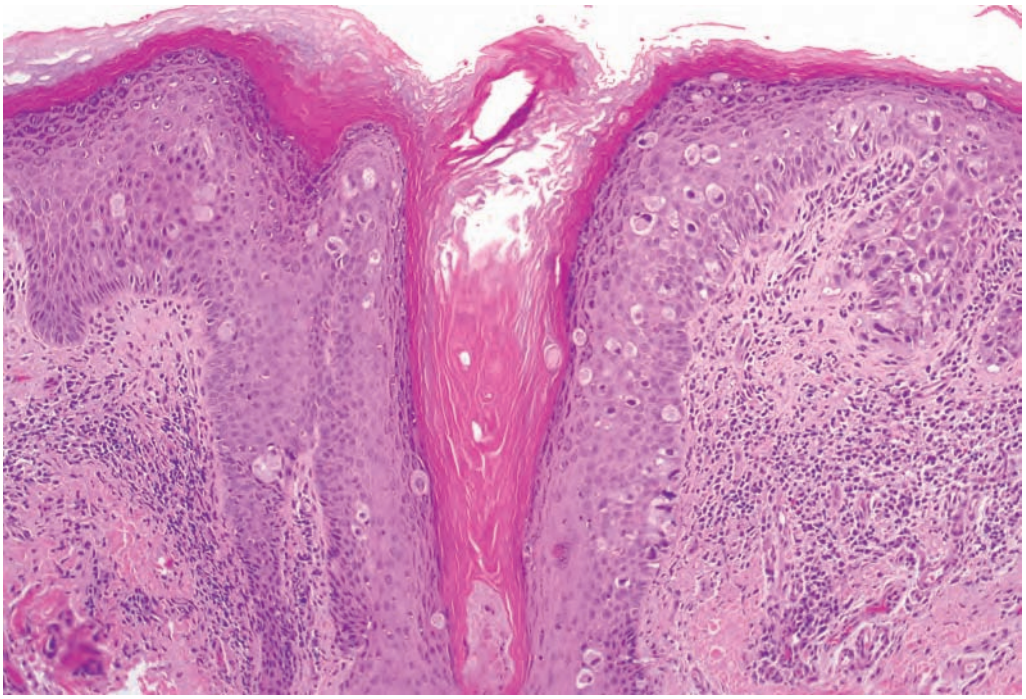

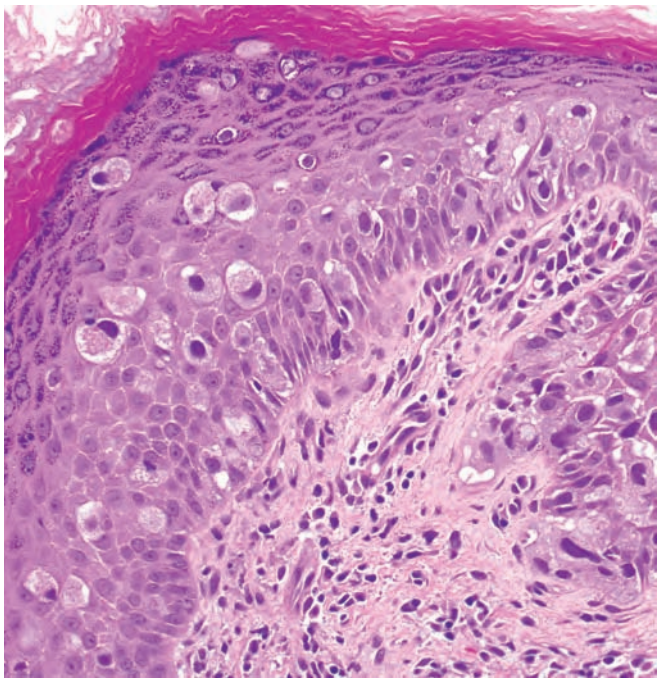

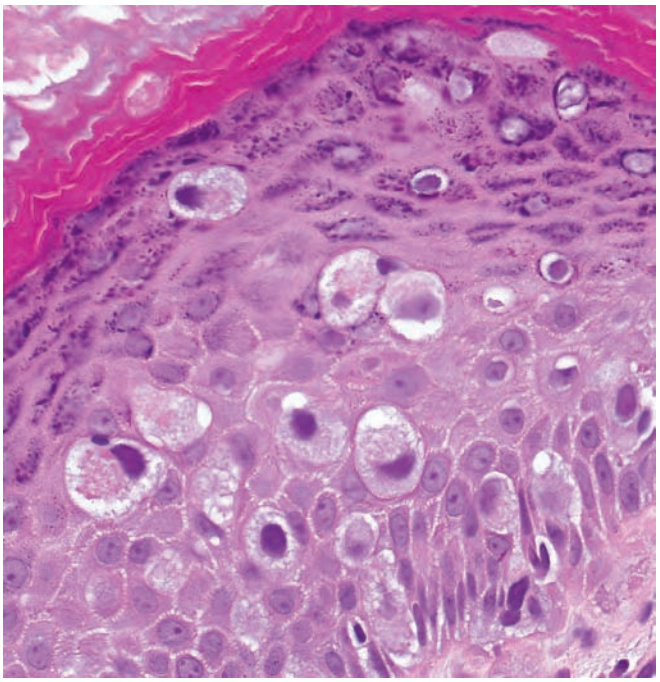

- Upper epidermal change of scattered large cells singly and in nests
- May be able to see a compressed basal layer beneath nests (eye-liner)
- Large cells have expanded cytoplasm and nuclei at periphery

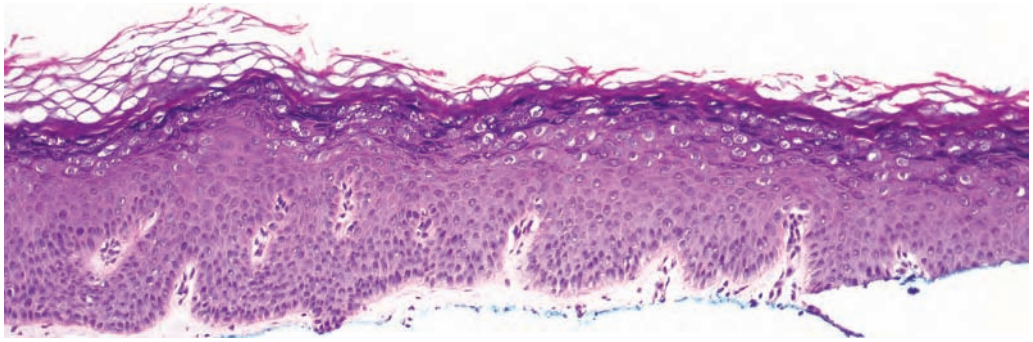

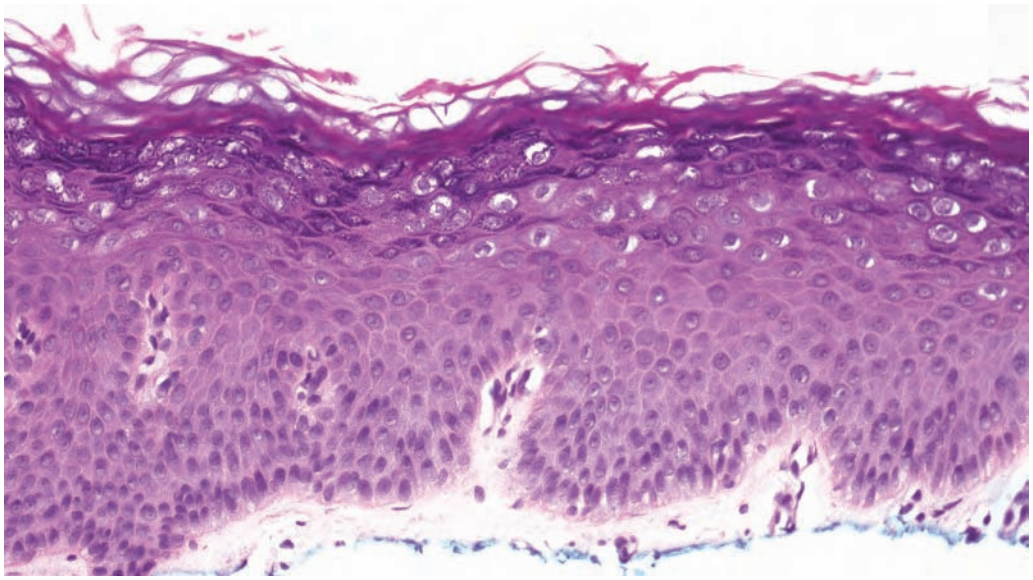

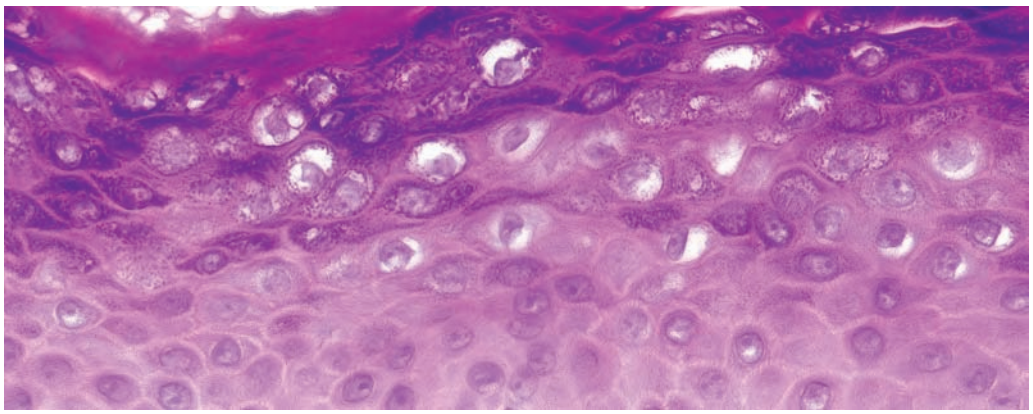

- Upper epidermal change of koilocytes – cells with haloes around nuclei
- Epidermal surface is flat to only slightly papillated
- Hypergranulosis

Verruca plana

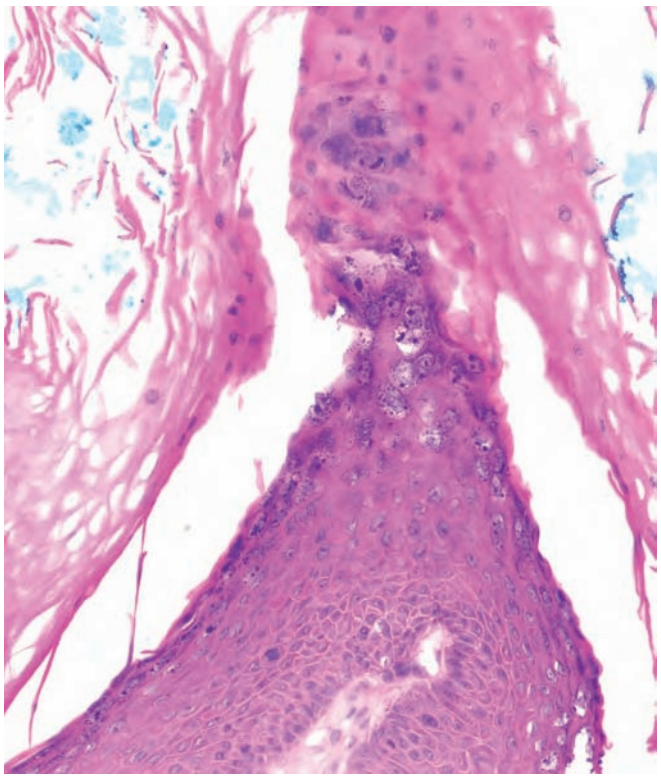

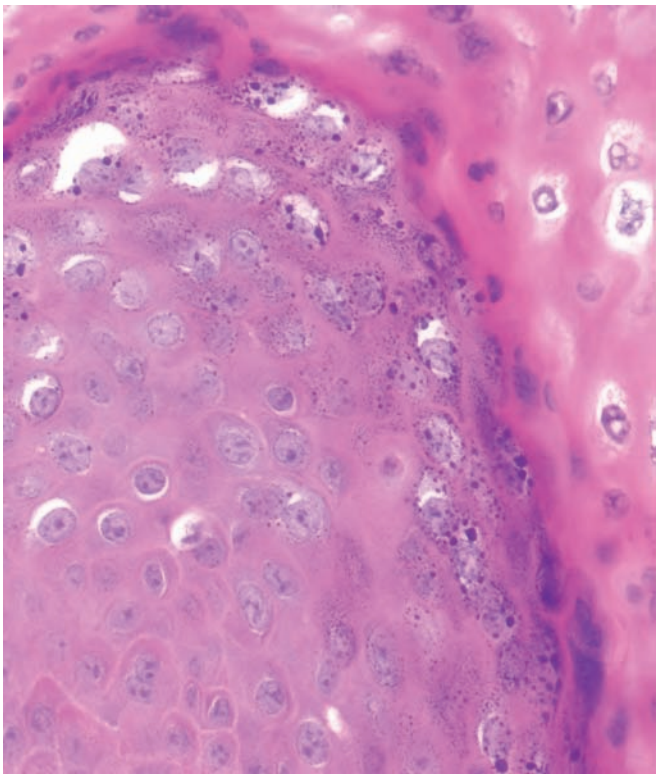

- Upper epidermal change of koilocytes
- Epidermal surface papillated
- Hypergranulosis
- Toeing-in (arborization) of rete ridges

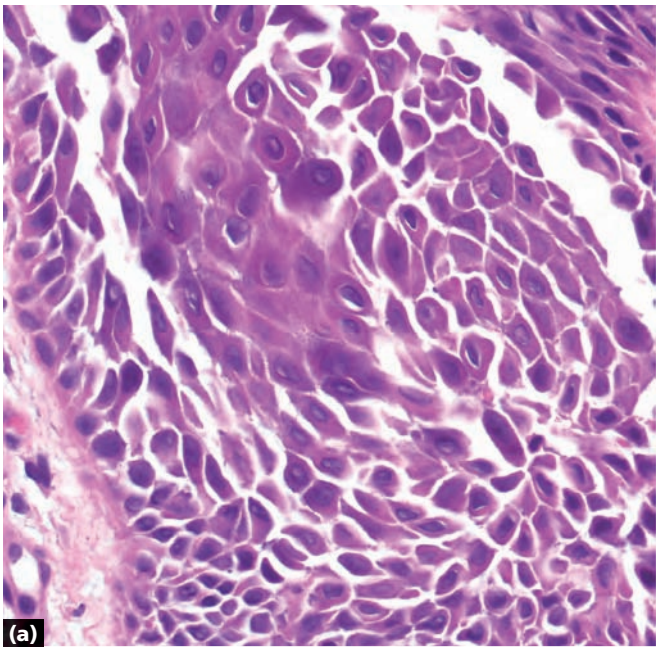

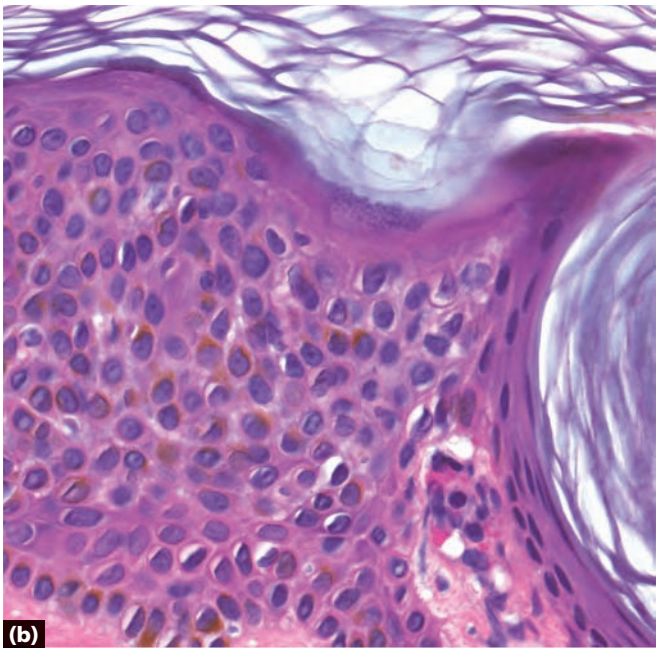

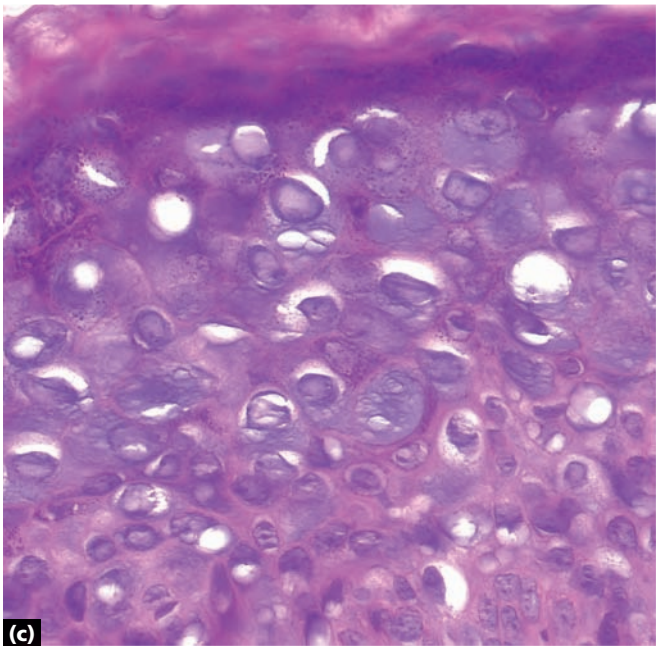

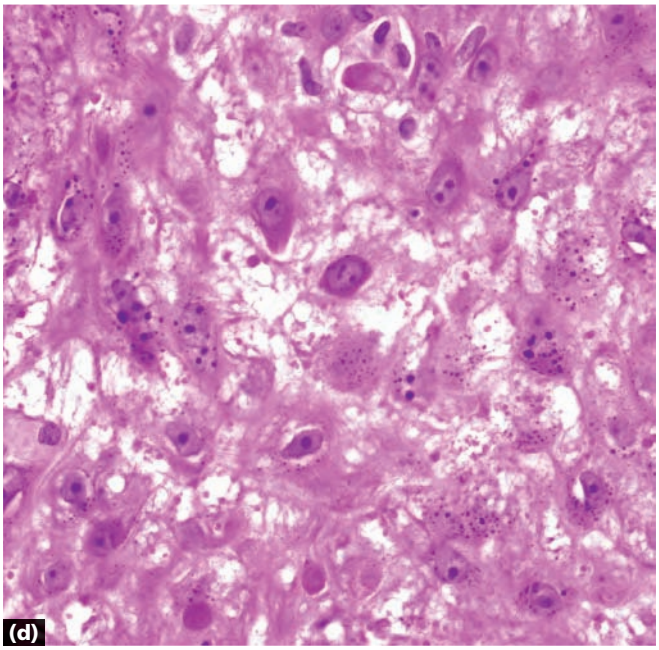

a Hailey-Hailey disease: acantholysis (rounding up and separation of individual keratinocytes); (see page 240)
b Clonal seborrheic keratosis: nests of typical, monomorphous keratinocytes
c Epidermodysplasia verruciformis: expanded blue-gray cytoplasm, some perinuclear haloes
d Epidermolytic hyperkeratosis: strung-out cell membranes, loss of nuclei, granular-vacuolar change

Key differences

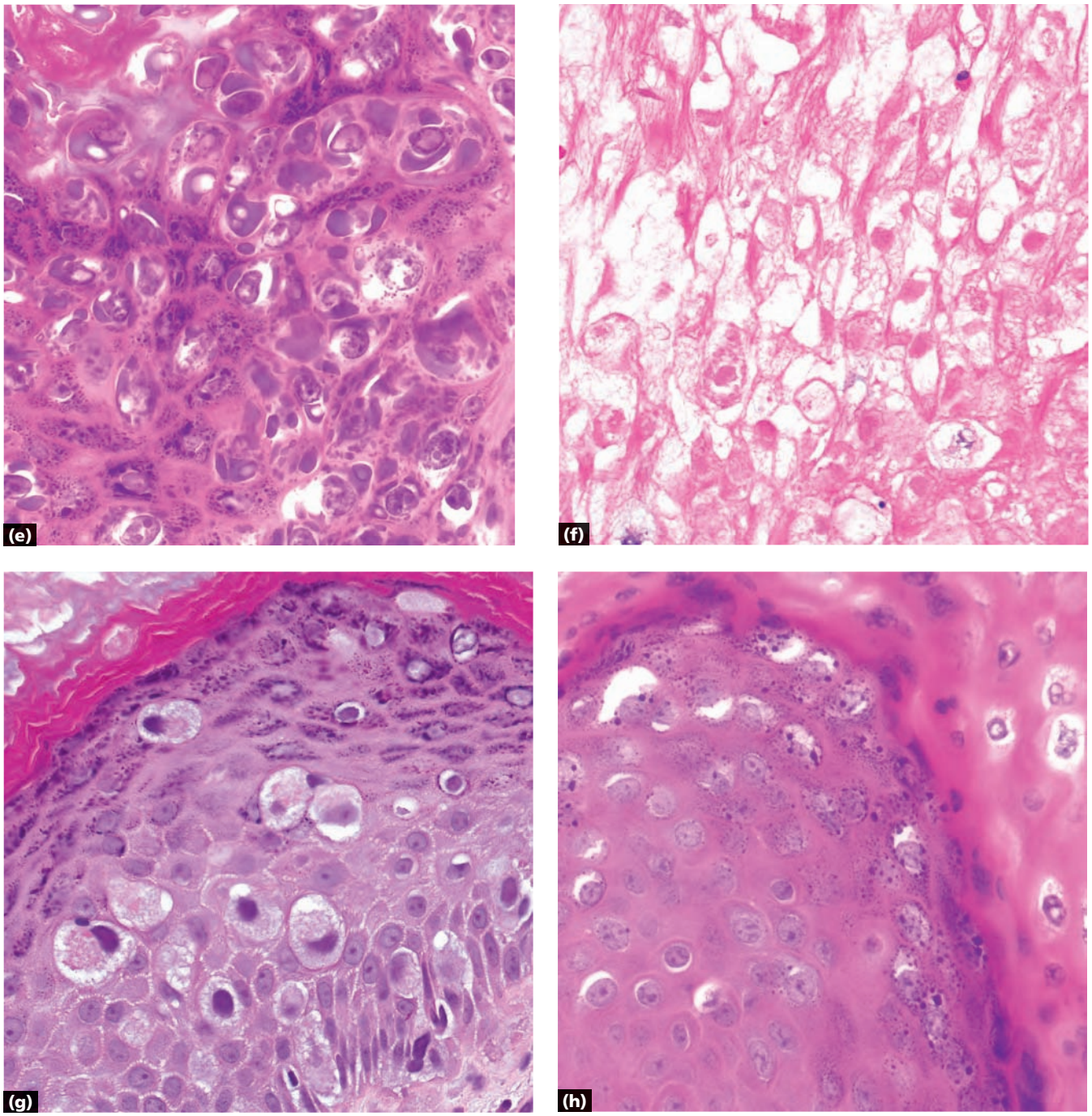

e Myrmecium: very prominent keratohyaline granules and intracytoplasmic, angular inclusions

f Orf: reticular degeneration (pink cell membranes with loss of nuclei) with scattered inclusions

g Paget's disease: scattered cells that lack intercellular bridges with prominent grayish cytoplasm

h Verruca: Koilocytes

Key differences, *continued*

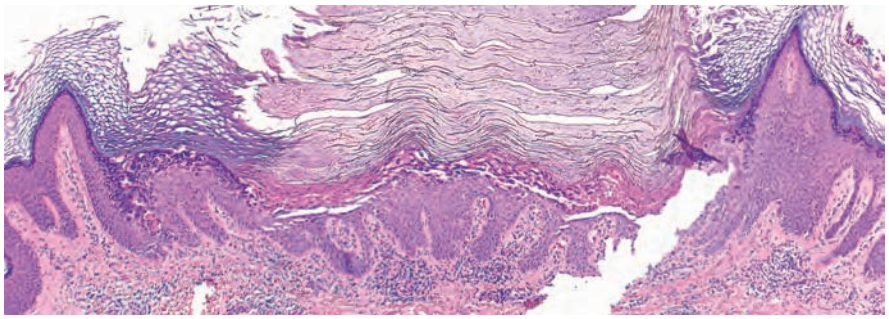

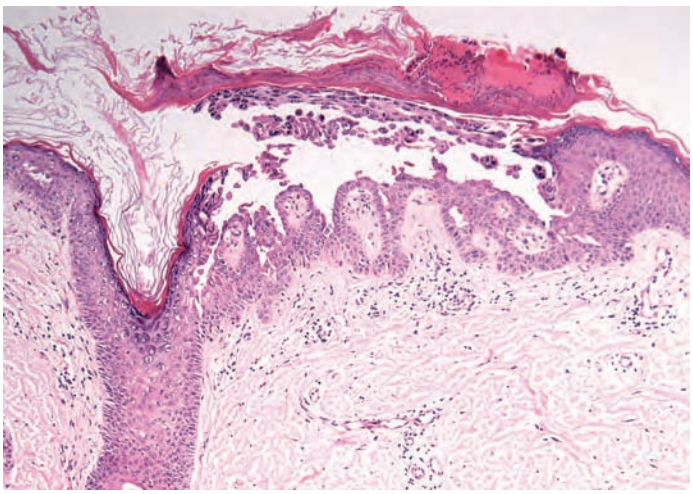

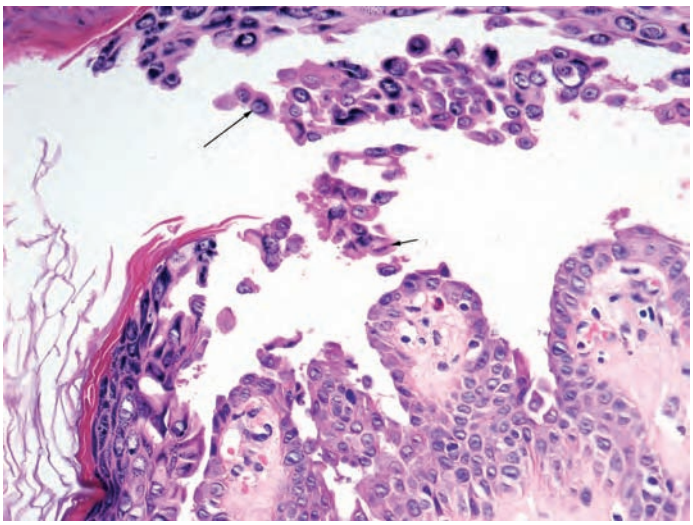

- Benign acantholytic dyskeratosis with corp ronds (long arrow) and grains (short arrow)
- Parakeratosis/crust above the acantholytic dyskeratosis
- Villi (projections of dermis lined by basal cells) may be present at the base

Darier disease

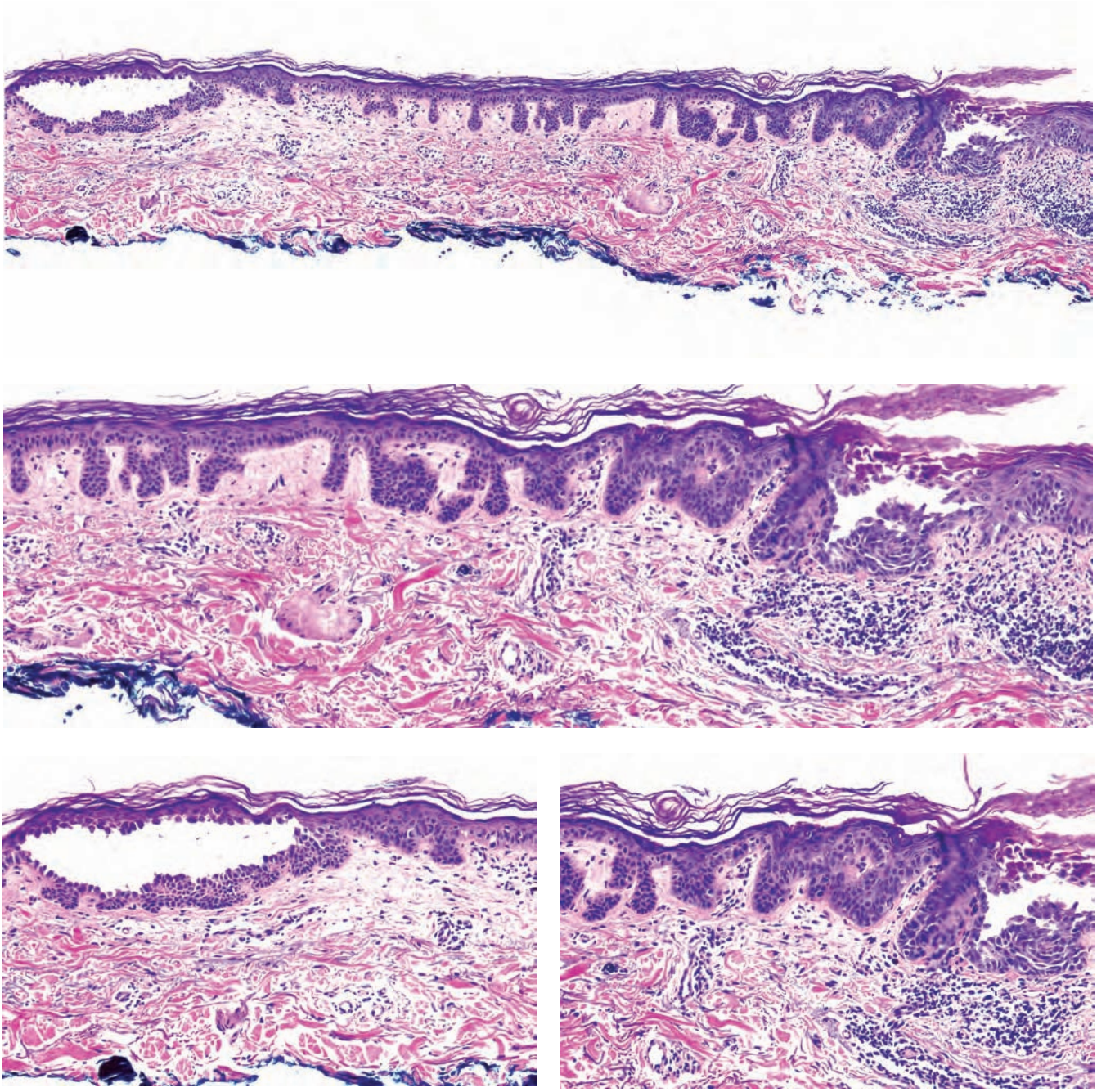

- Benign acantholytic dyskeratosis in small foci
- Also foci of spongiosis, acantholysis without dyskeratosis (Hailey-Hailey pattern and pemphigus patterns)

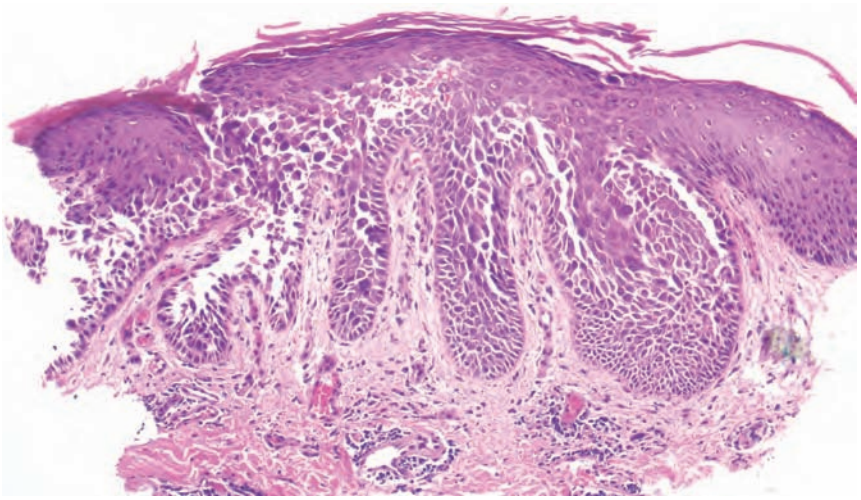

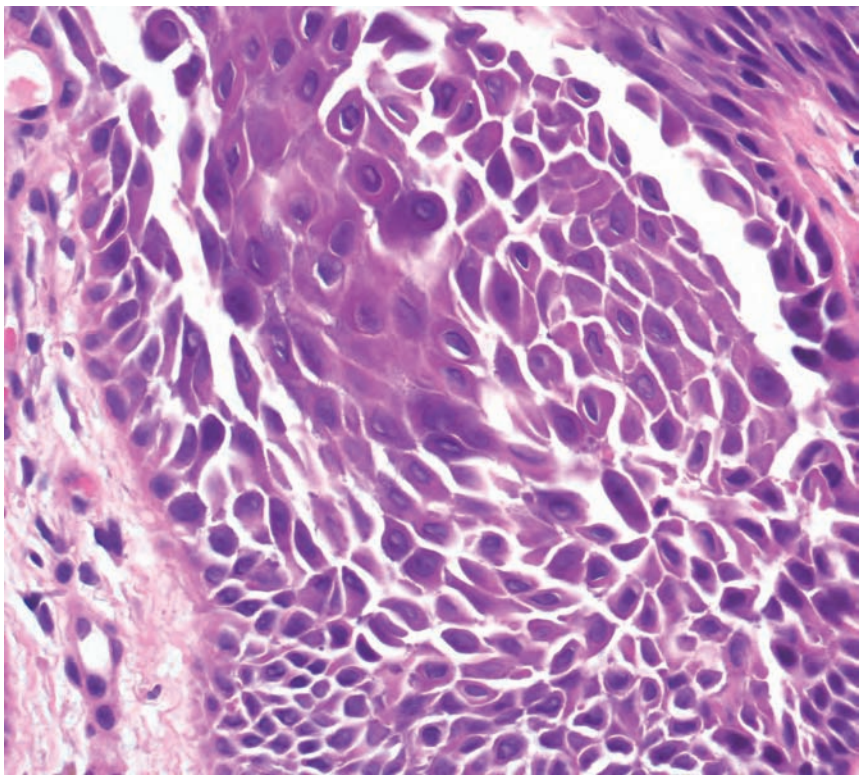

- Benign acantholysis (sometimes with dyskeratosis) involving at least 2/3 or the full thickness of the epidermis
- Resembles a "dilapidated brick wall"

Hailey-Hailey disease

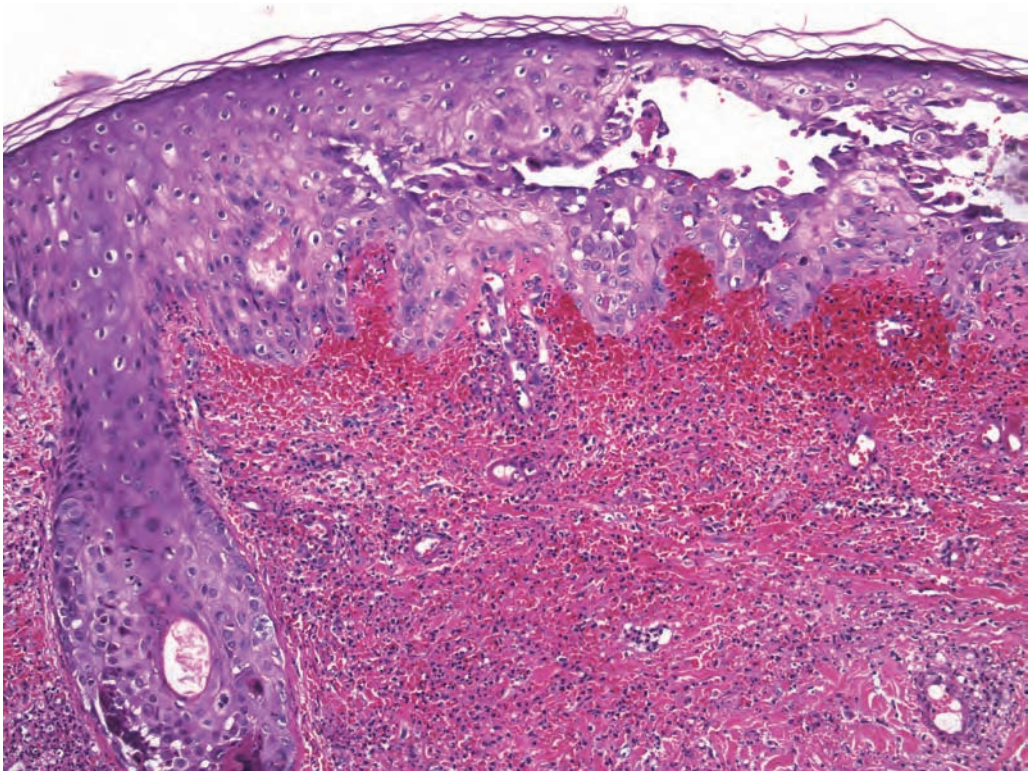

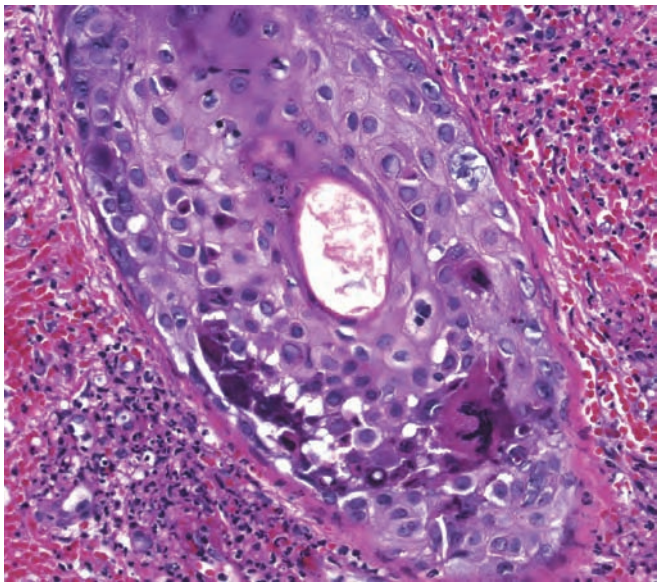

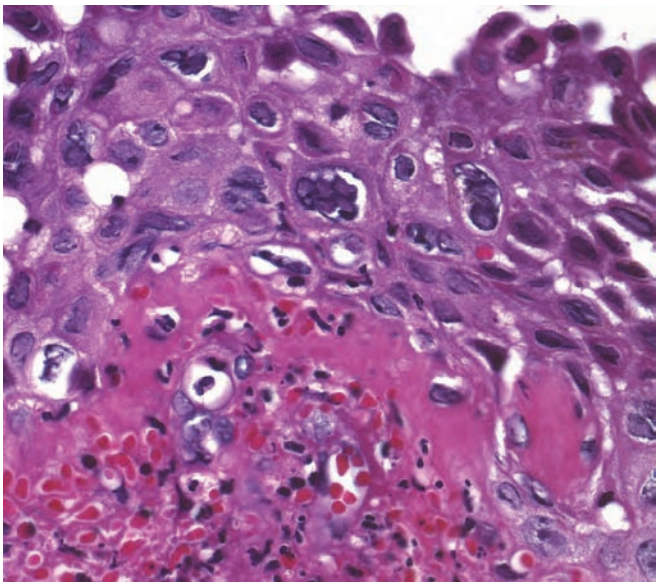

- Benign non-dyskeratotic acantholysis with ballooning degeneration
- Multinucleated cells with rimming of chromatin
- Follicular necrosis/acantholysis is a clue
- Often involves and destroys basal cells, which are spared in pemphigus vulgaris

Herpes virus infection

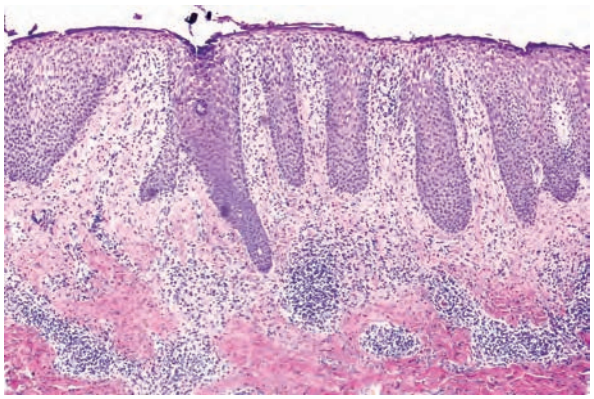

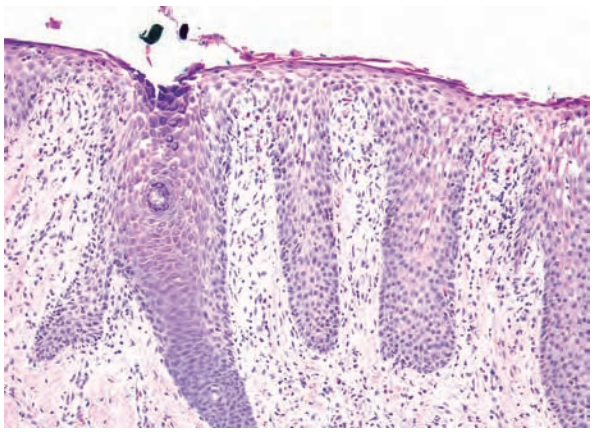

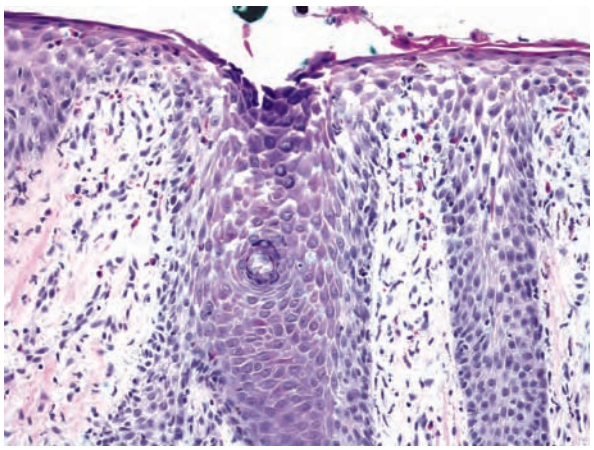

- Benign acantholysis in the upper stratum spinosum, making the granular layer appear altered
- May see "cling-ons" (acantholytic cells on roof of split)

Pemphigus foliaceus

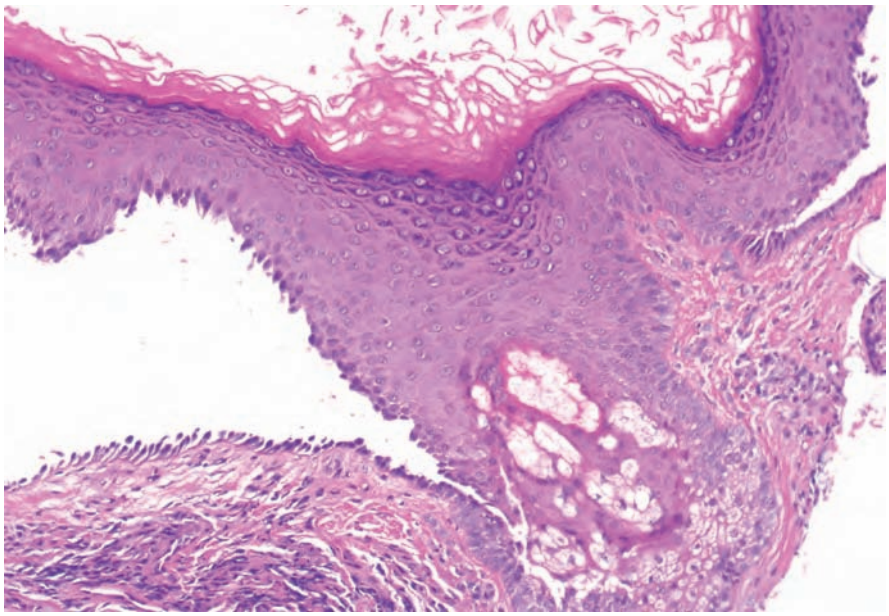

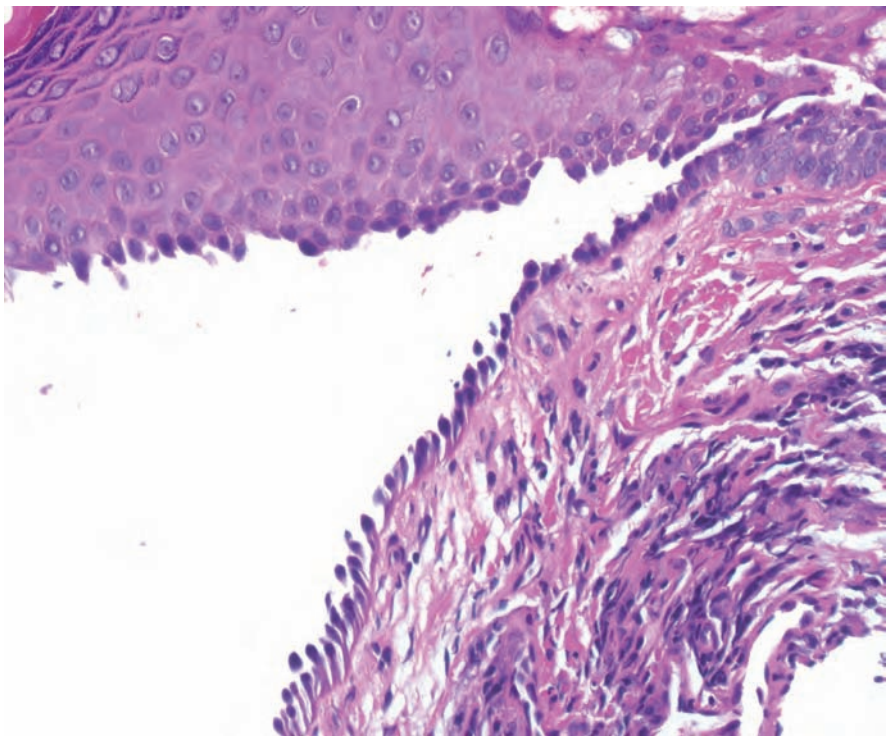

- Benign acantholysis above the basal layer
- Basal layer intact and appears like "tombstones"

Pemphigus vulgaris

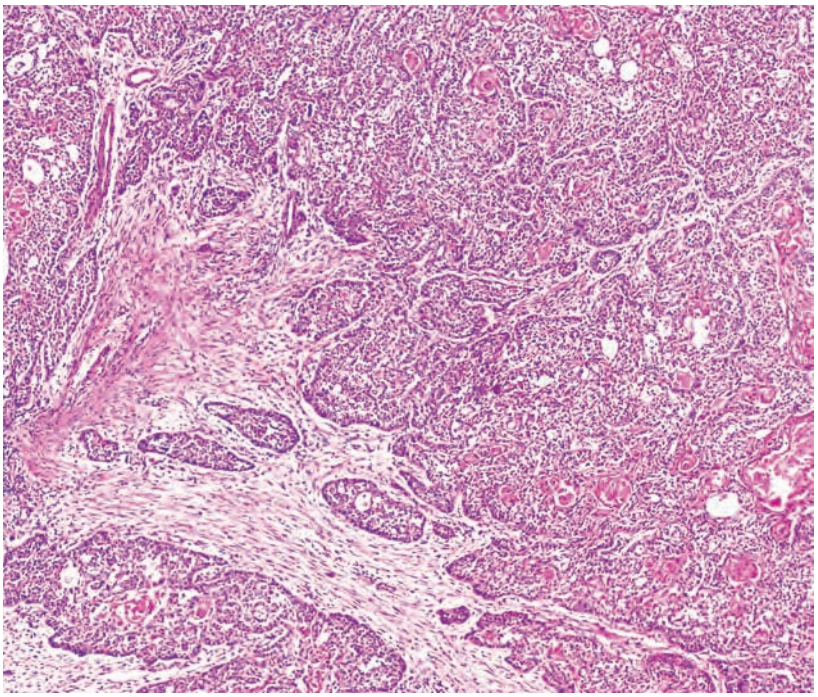

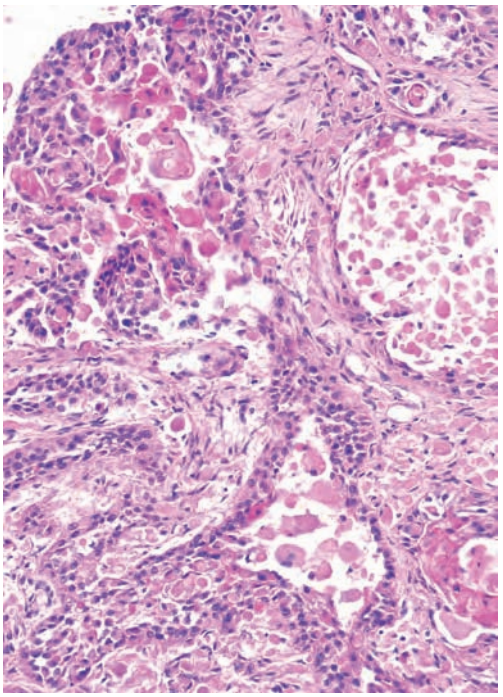

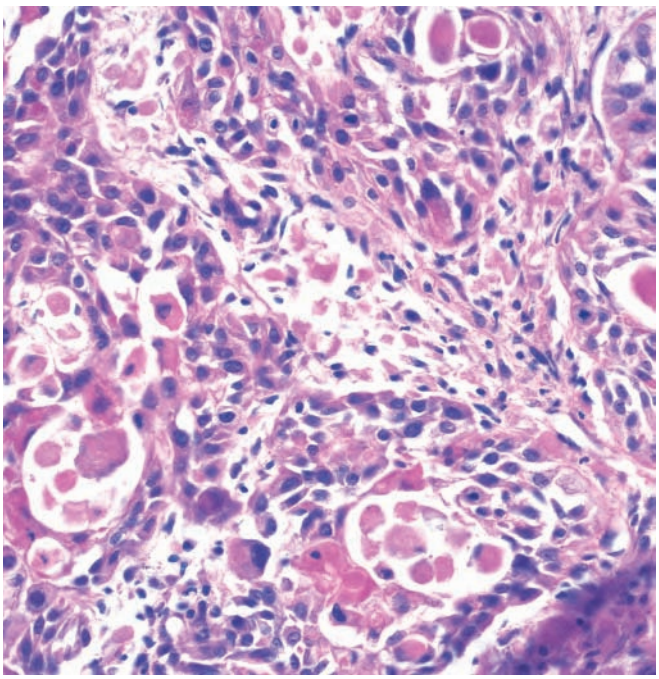

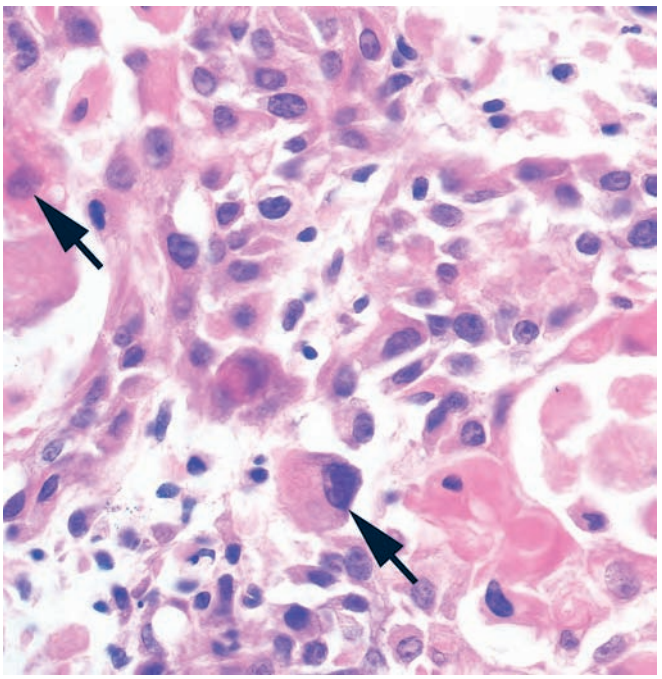

- Malignant dyskeratotic acantholysis in a large, infiltrative tumor
- Prominent atypical cells (arrows) and mitoses

Squamous cell carcinoma (adenoid or pseudoglandular or acantholytic)

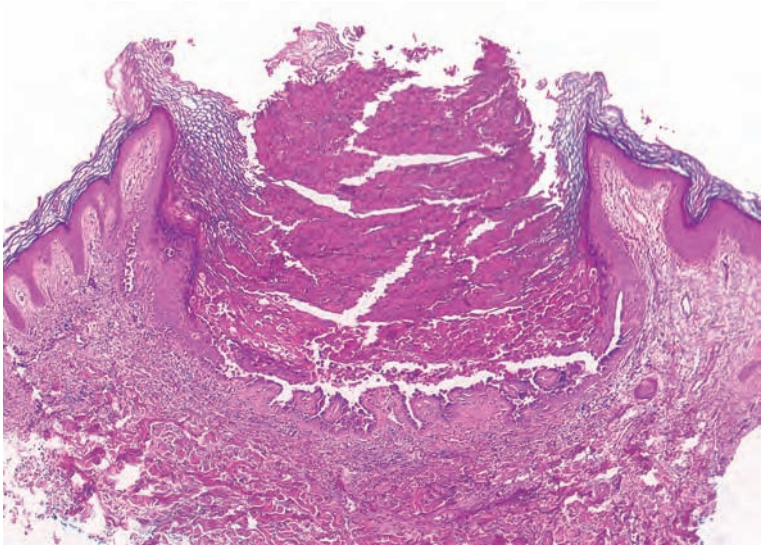

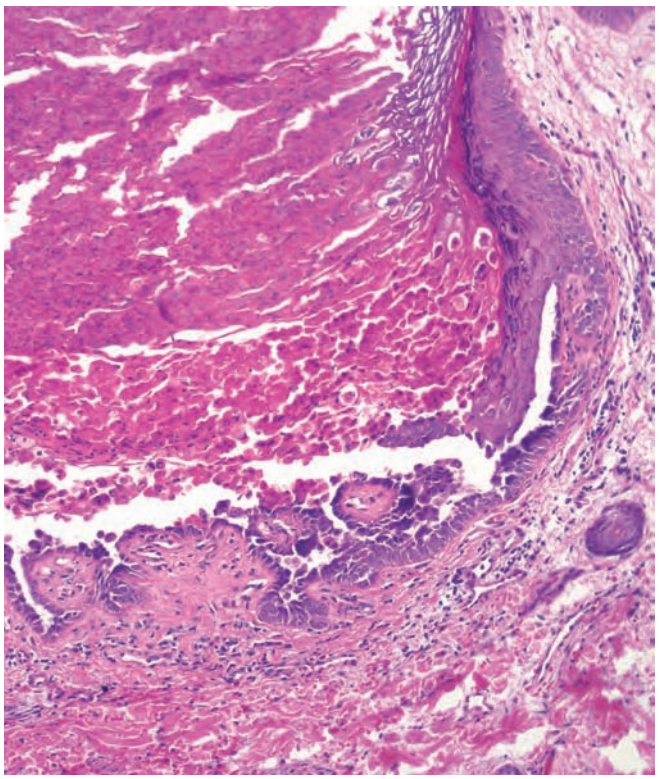

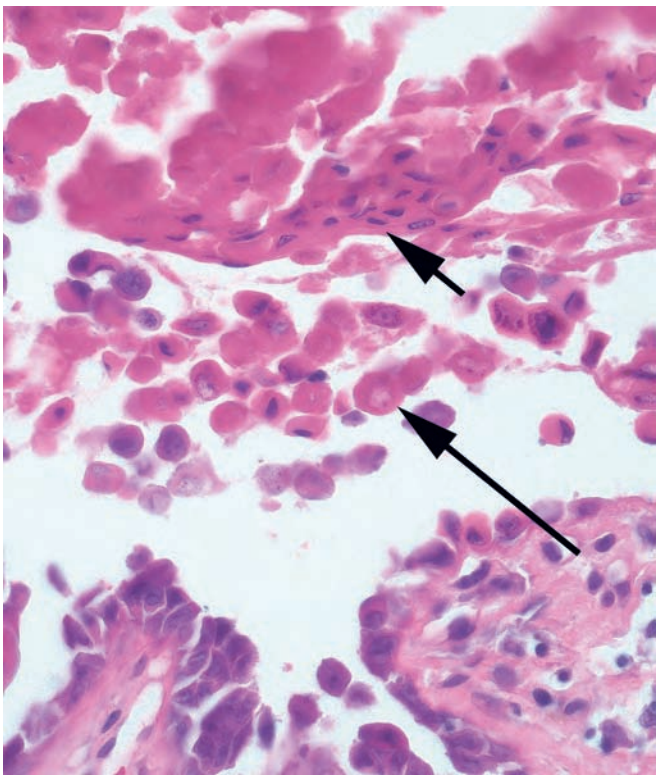

- Histologically like Darier disease with corp ronds (long arrow) and grains (short arrow) but may have more prominent cup-shape and/or follicular involvement
- Clinically a solitary lesion

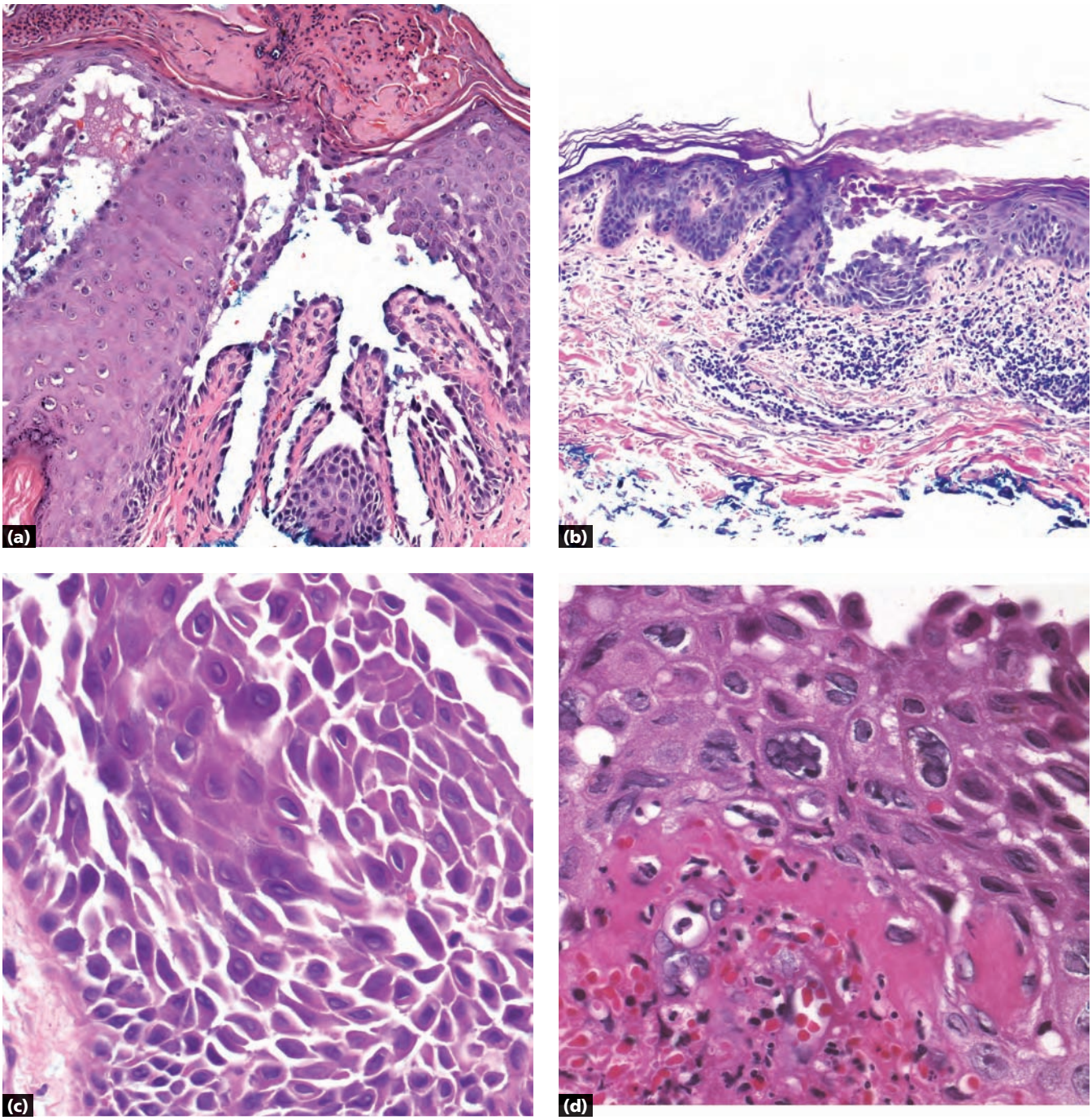

a Darier disease: prominent parakeratosis/crust above corp ronds and grains ("benign dyskeratotic acantholysis"); villi may be evident

b Grover disease: multiple patterns of acantholysis (Darier like, Hailey-Hailey-like, pemphigus-like) and spongiosis in small foci

c Hailey-Hailey disease: majority of epidermis involved by acantholysis (usually non-dyskeratotic acantholysis)

d Herpes virus infection: ballooning degeneration, multinucleated cells with chromatin rimming

Key differences

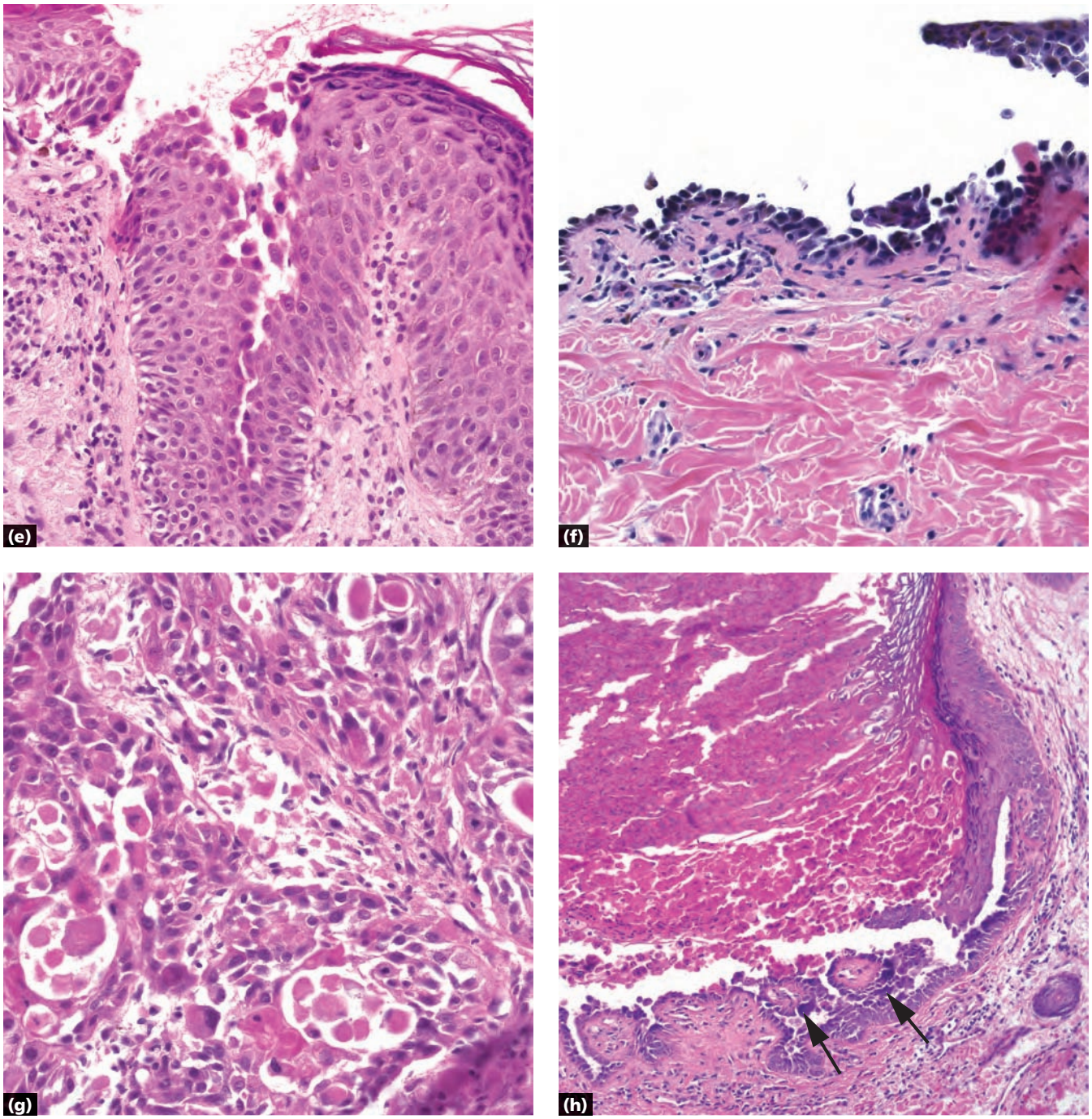

e Pemphigus foliaceus: granular layer prominent with acantholysis

f Pemphigus vulgaris: non-dyskeratotic acantholysis above tombstoned basal layer; follicles may be involved

g Squamous cell carcinoma: acantholysis and squamous pearls, atypical keratinocytes and mitoses (malignant dyskeratotic acantholysis)

h Warty dyskeratoma: cup-shaped area of acantholysis and dyskeratosis ("benign dyskeratotic acantholysis"), villi (arrows) at base

Key differences, *continued*

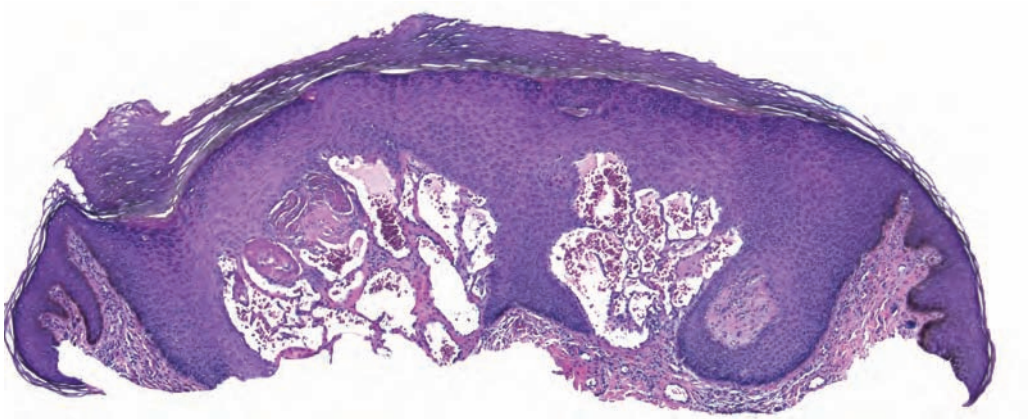

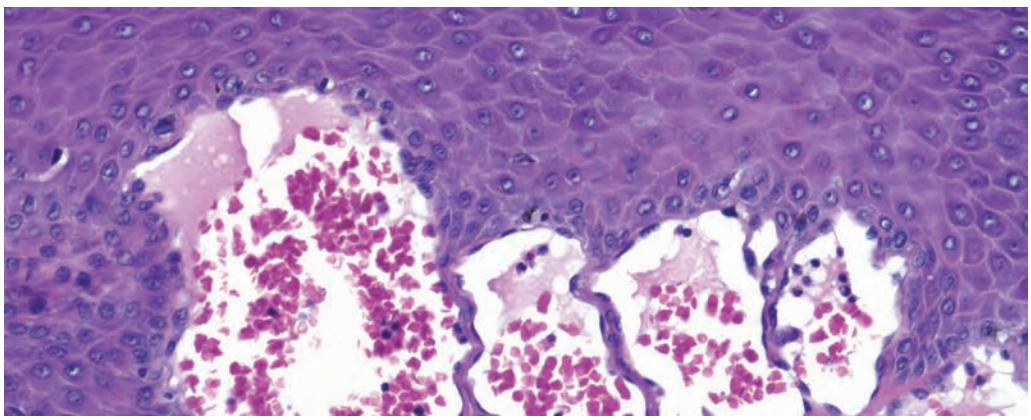

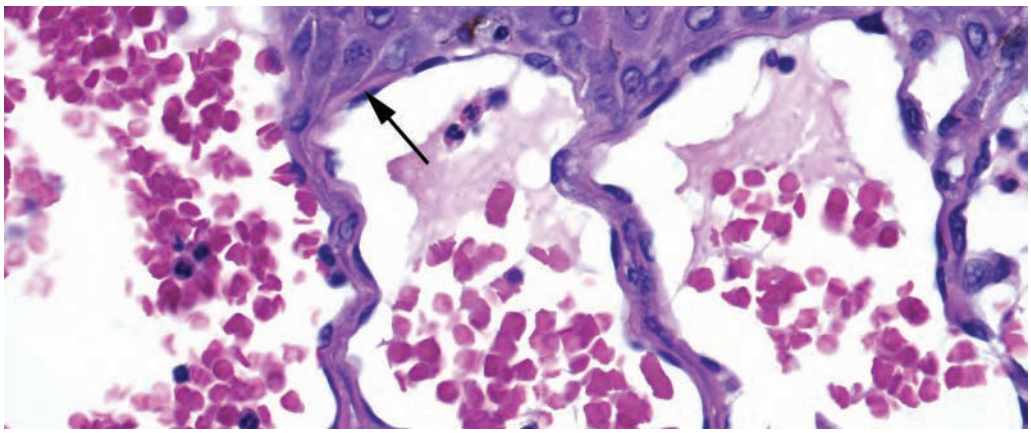

- Subepidermal space (can appear intraepidermal)
- Thin "grenz zone" (arrow)
- Filled with erythrocytes

Angiokeratoma

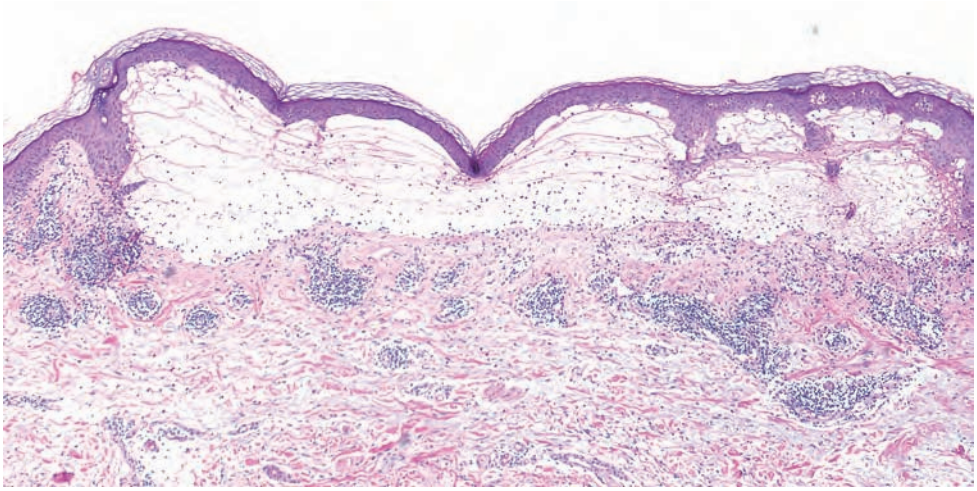

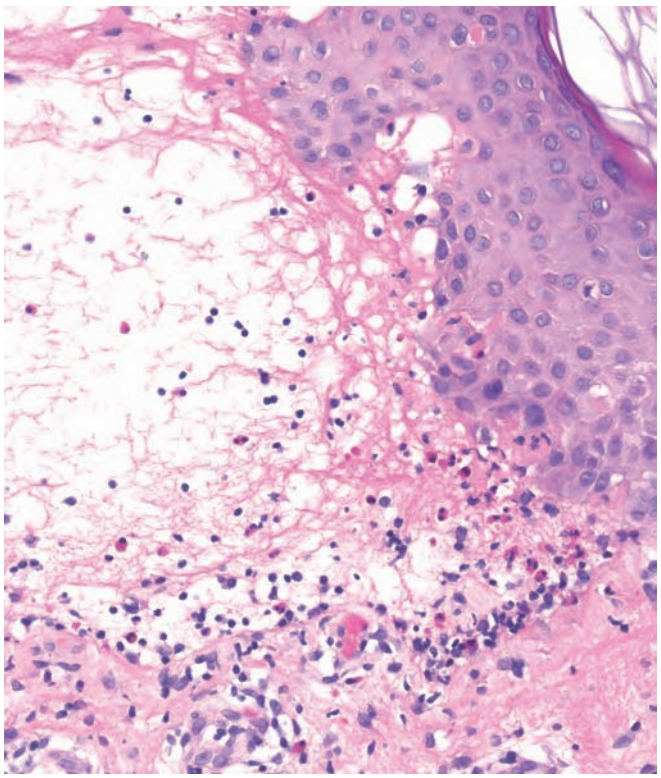

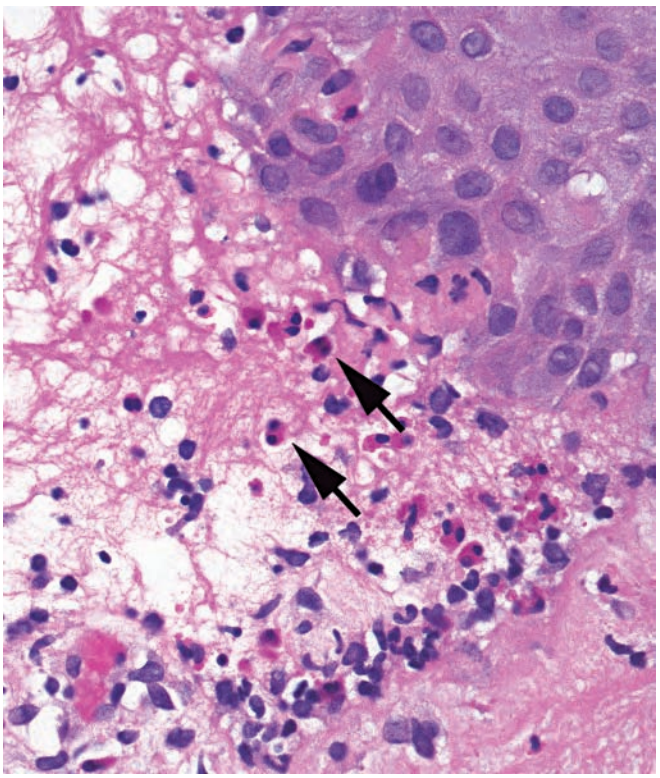

- Subepidermal space
- Eosinophils (arrows) are prominent at the base
- May see festooning (papillated bulla base)

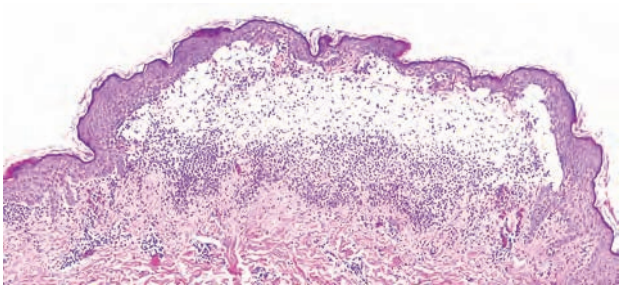

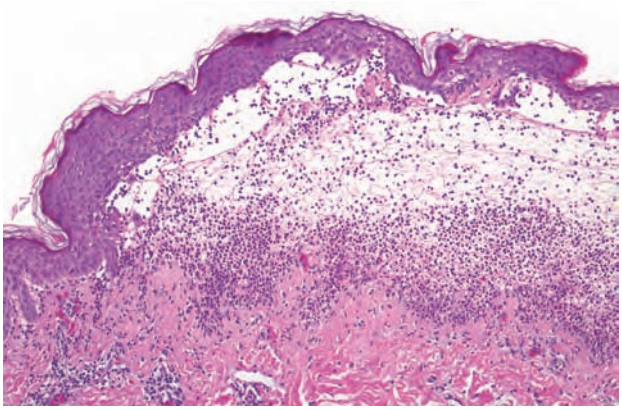

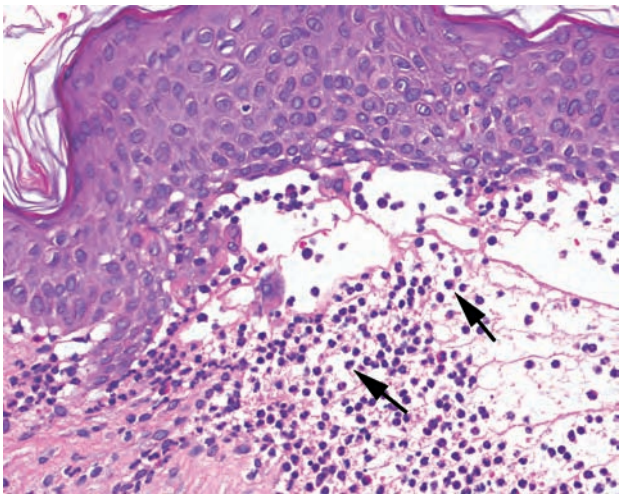

- Subepidermal space
- Neutrophils (arrows) are prominent at the base
- May see clusters of neutrophils in papillae adjacent to blister
- Note that this same histologic pattern can be seen with linear IgA disease, neutrophil-rich bullous pemphigoid, bullous lupus erythematosus, and epidermolysis bullosa acquisita
- May see reverse festooning (papillated inferior surface of bulla roof)

Dermatitis herpetiformis

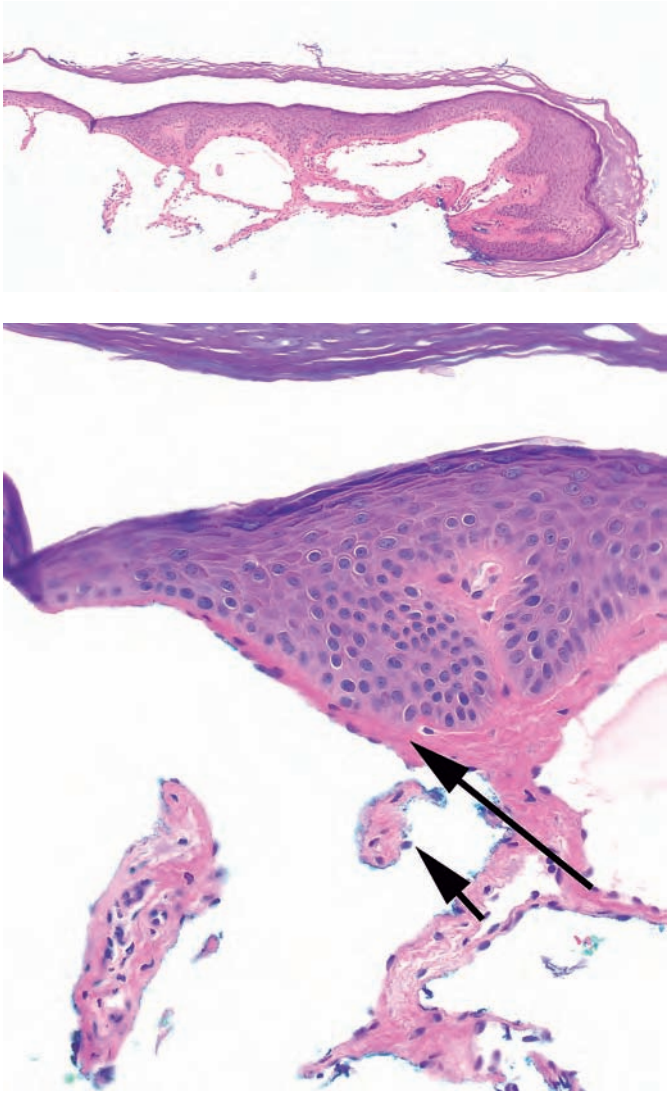

- Subepidermal space with internal papillations
- Thin "grenz zone" (long arrow)
- Spaces lined by endothelial cells (short arrow) and may contain a few erythrocytes

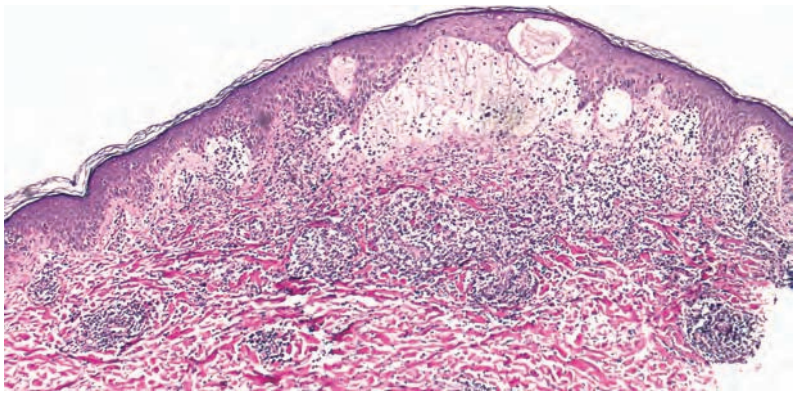

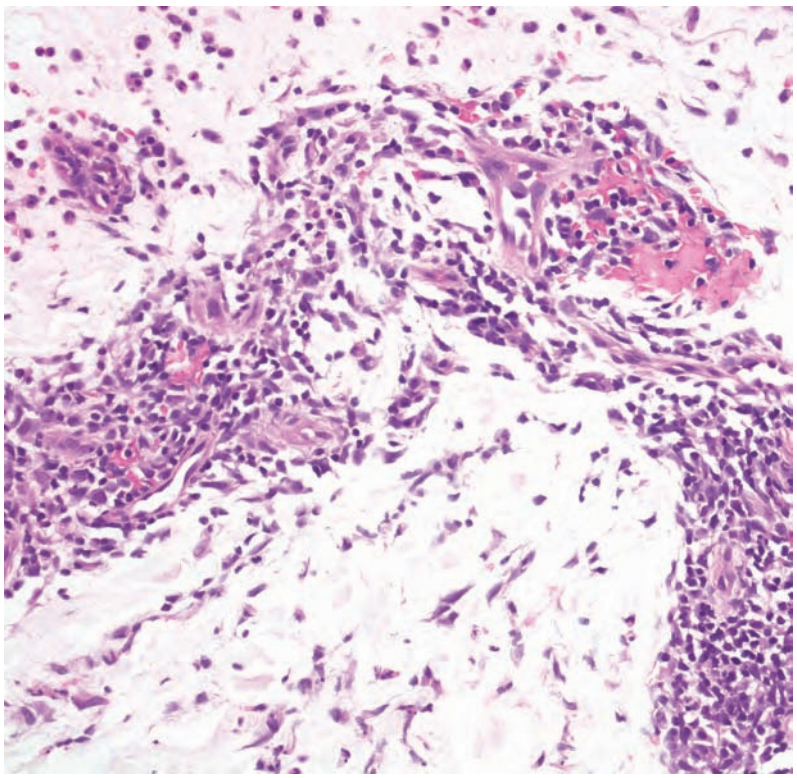

- Subepidermal space (edema)
- Superficial and deep vessels surrounded by lymphocytes

Polymorphous light eruption

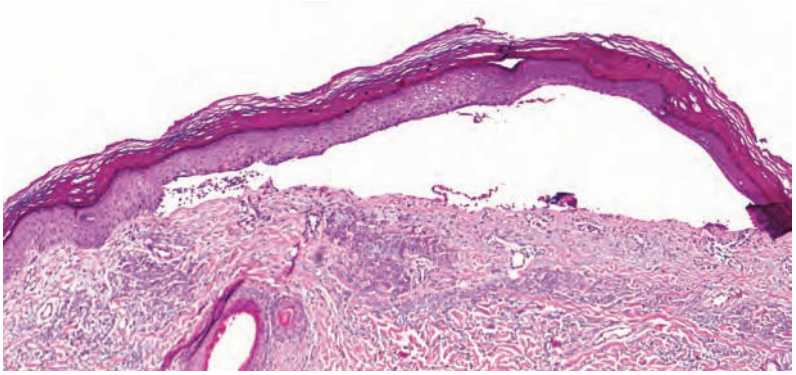

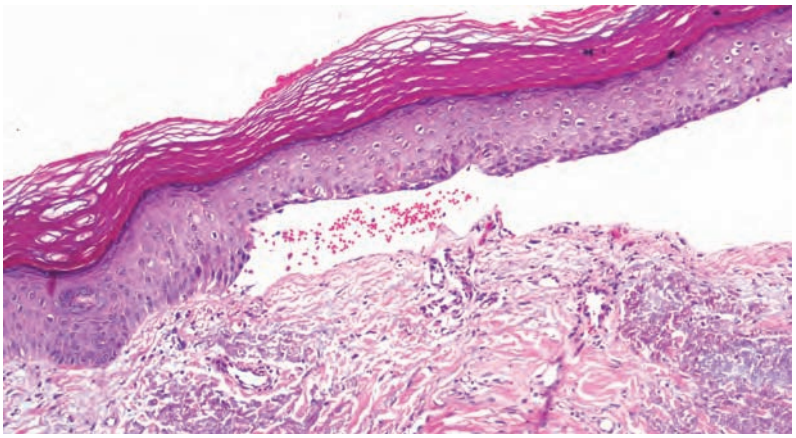

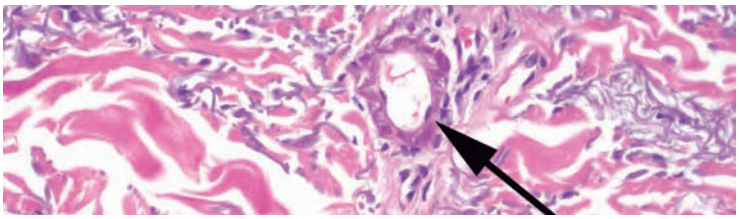

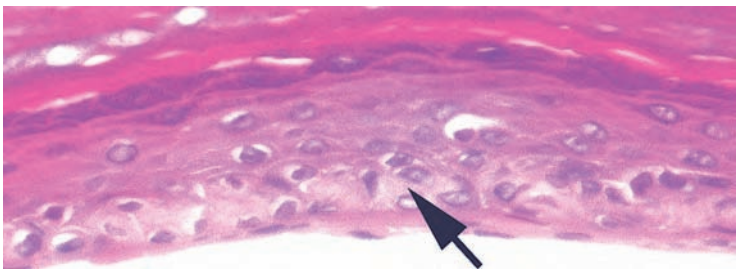

- Subepidermal space
- Non-inflammatory base
- Festooning of papillary dermis
- Thickened vessel walls (long arrow)
- Caterpillar bodies in epidermis (short arrow)

Note Differential diagnosis of a non-inflammatory subepidermal bulla includes non-inflammatory bullous pemphigoid, epidermolysis bullosa acquisita, diabetic bullae, and epidermolysis bullosa subtypes.

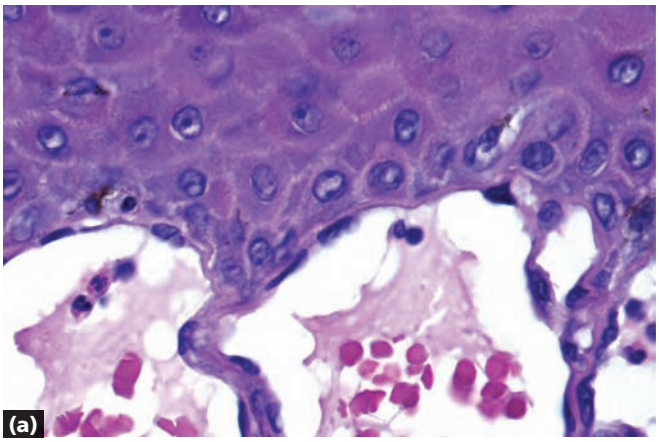

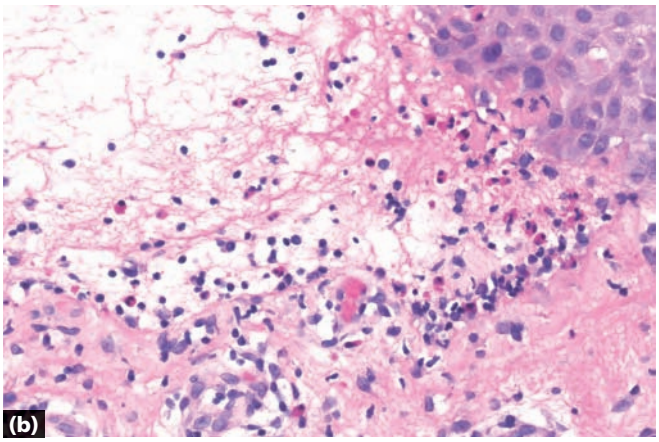

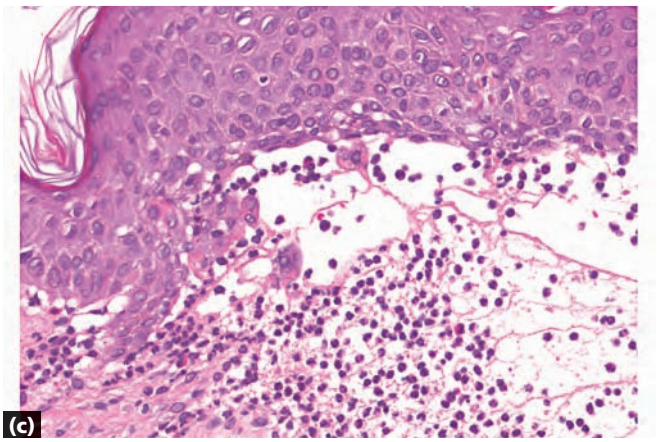

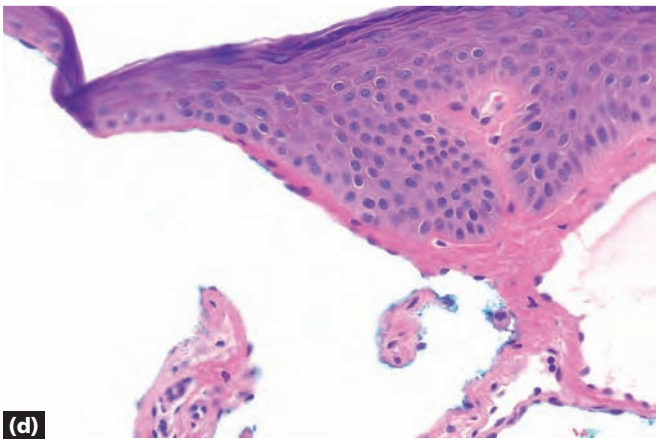

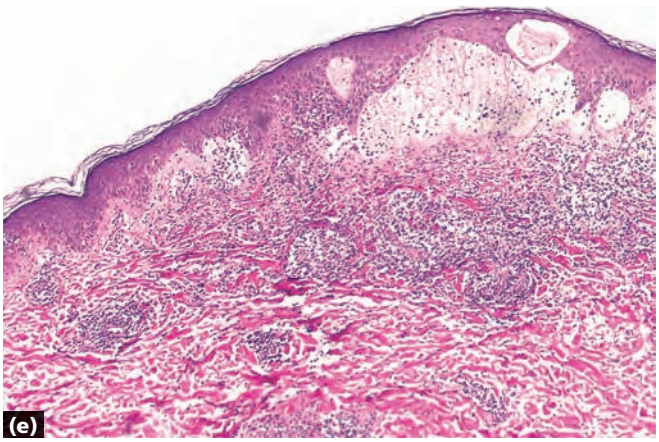

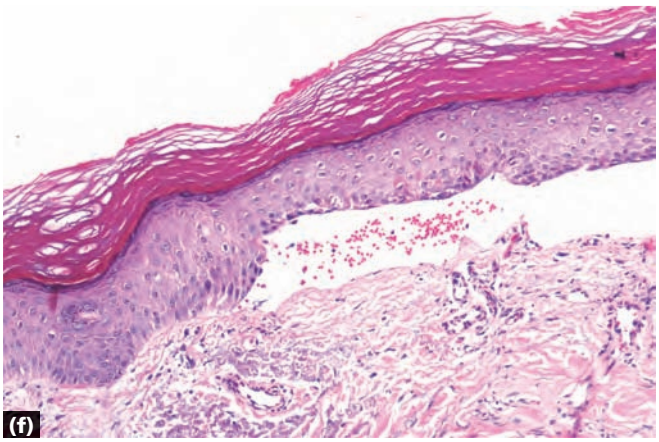

a Angiokeratoma: erythrocytes fill the spaces
b Bullous pemphigoid: eosinophils at base, festooning
c Dermatitis herpetiformis: neutrophils at base, reverse festooning
d Lymphangioma: empty spaces lined by endothelial cells
e Polymorphous light eruption: perivascular lymphocytes
f Porphyria cutanea tarda: non-inflammatory base, festooning, caterpillar bodies

Key differences

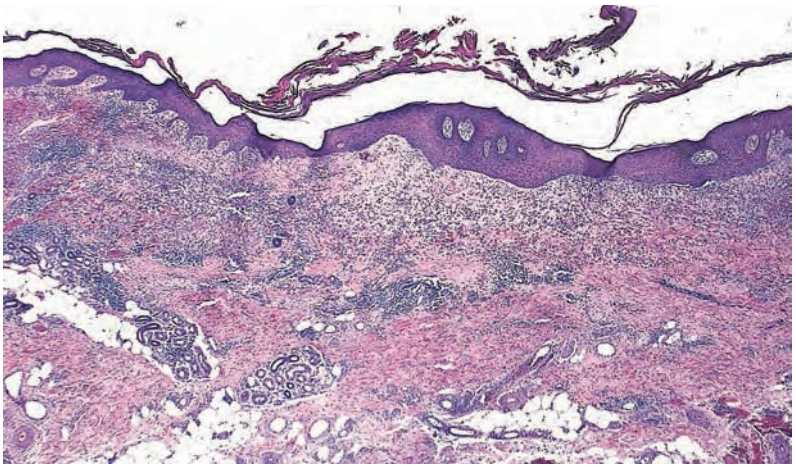

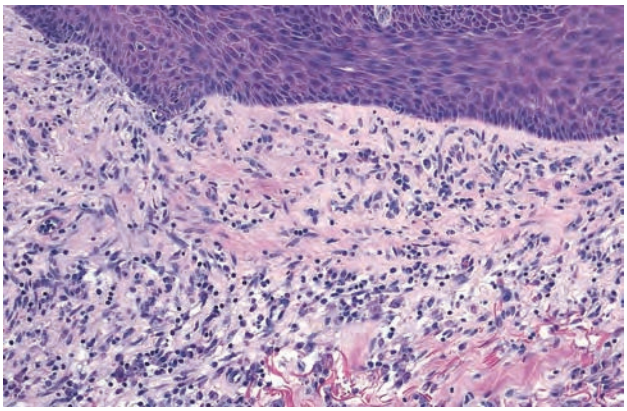

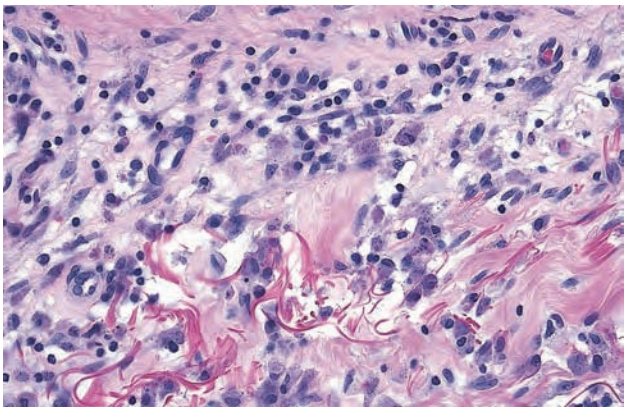

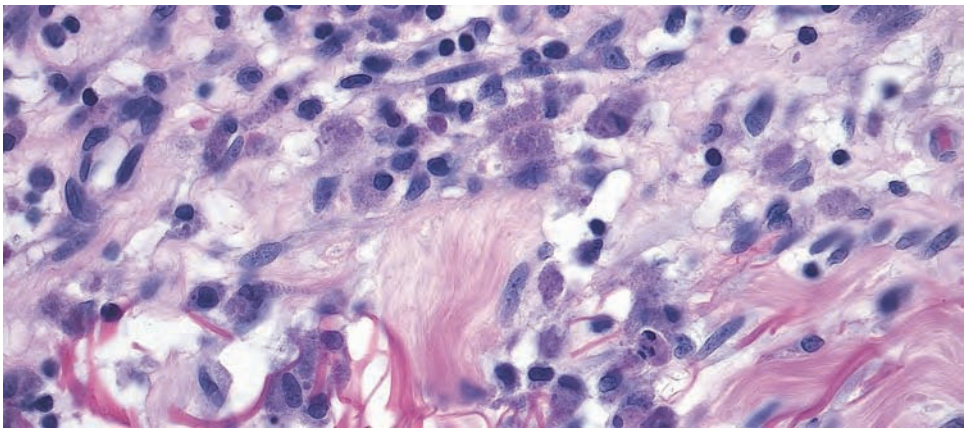

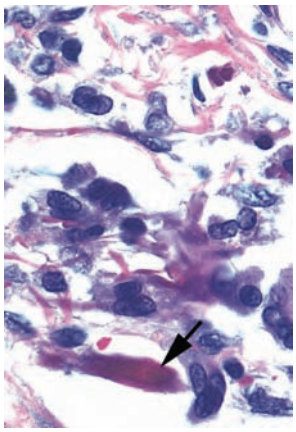

- Granular "material" in histiocytes
- Fine, bluish granules of similar size
- Large blue-purple collagen "concretions" (arrow)
- An adjacent scar is often evident

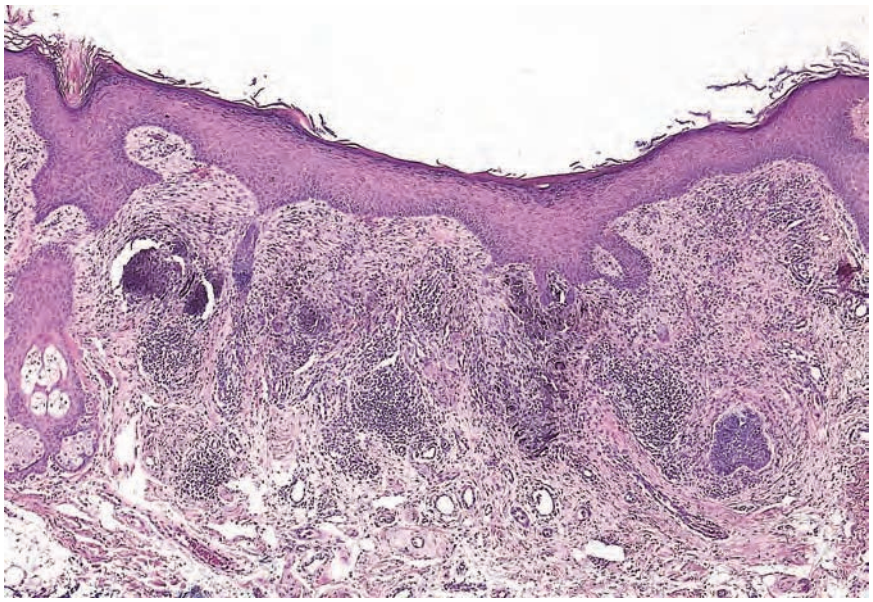

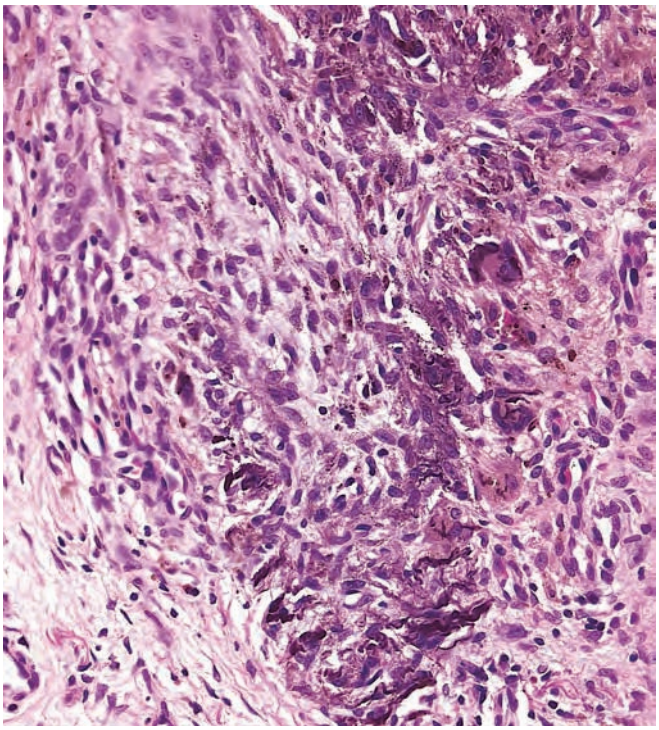

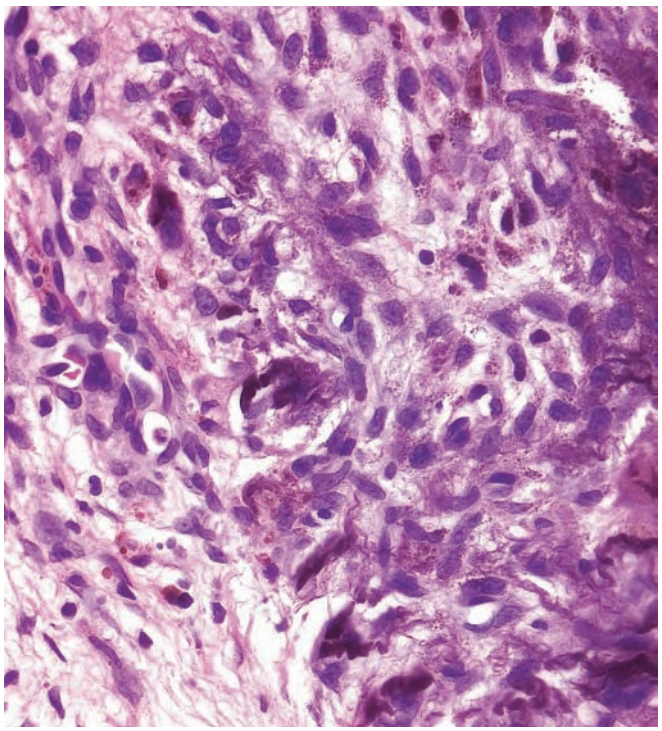

- Granular "material" in histiocytes and extracellularly
- Similar in staining quality to hemosiderin
- Larger collagen "concretions" of brown-yellow to black material may be present
- An adjacent scar is often evident

Ferric subsulfate (Monsel solution)

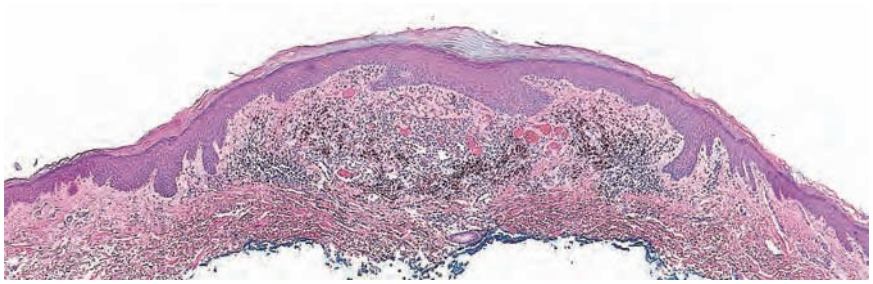

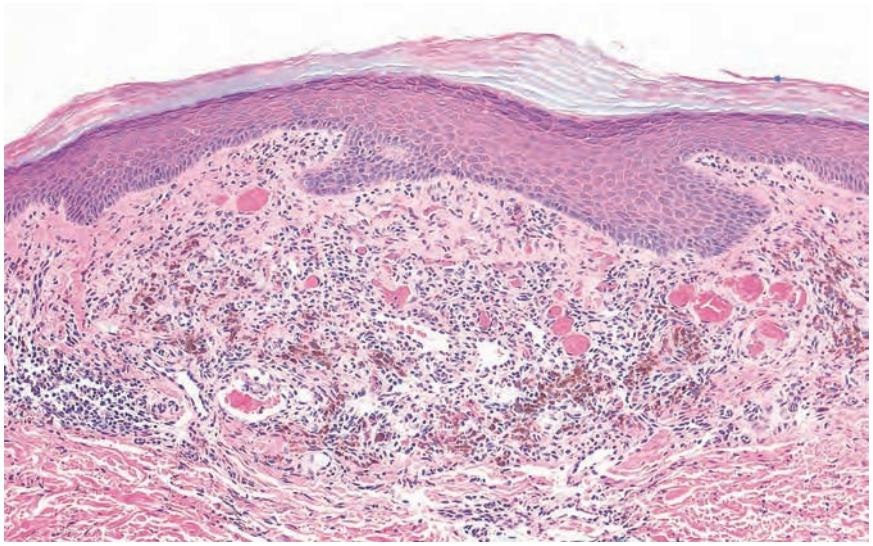

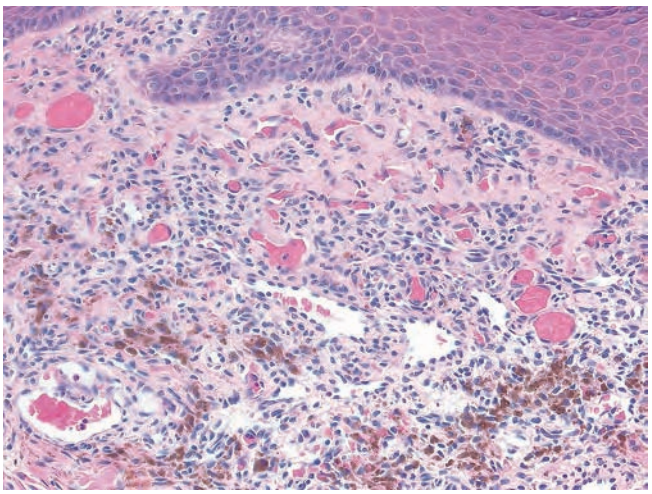

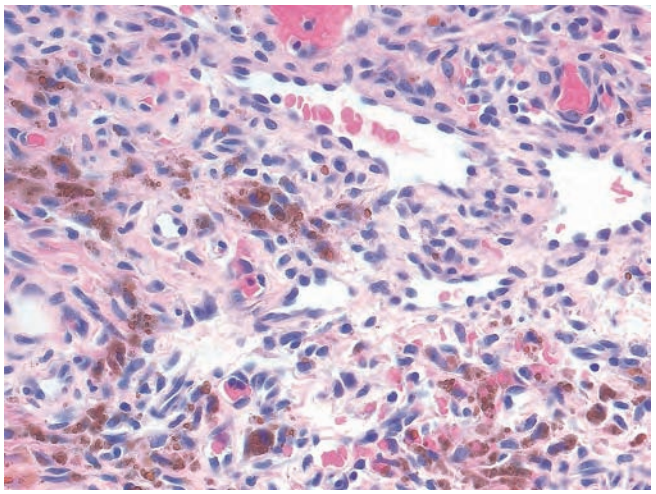

- Granular "material" in histiocytes (hemosiderophages)
- Yellow-brown, refractile globules and granules of varying sizes
- Appears green-yellow with microscope condenser lowered
- Extravasated erythrocytes may be present

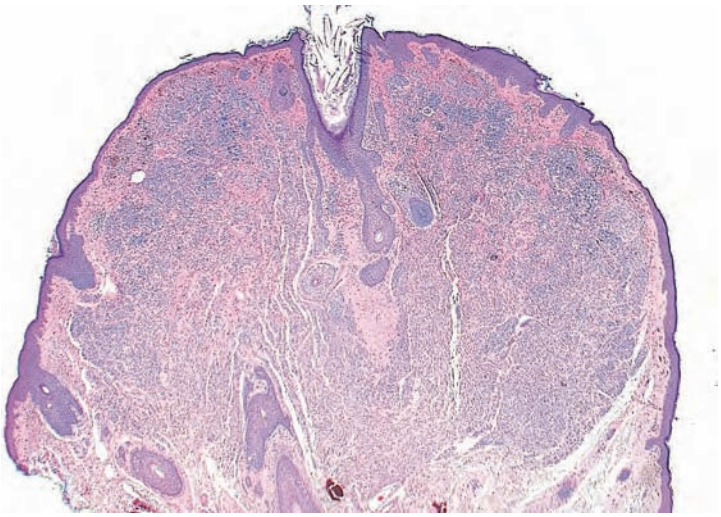

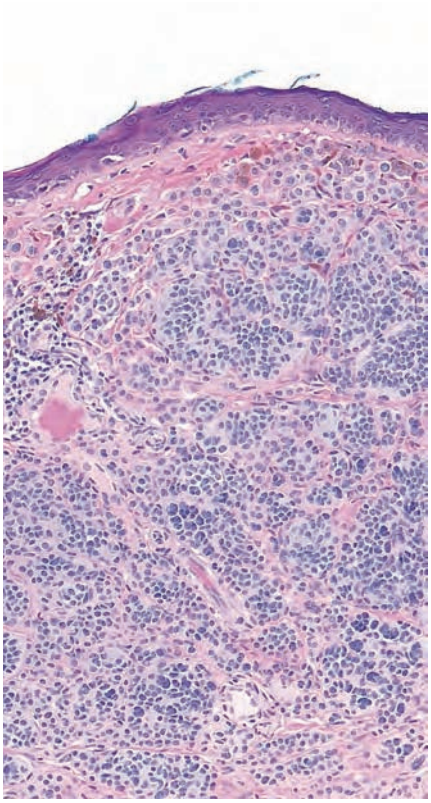

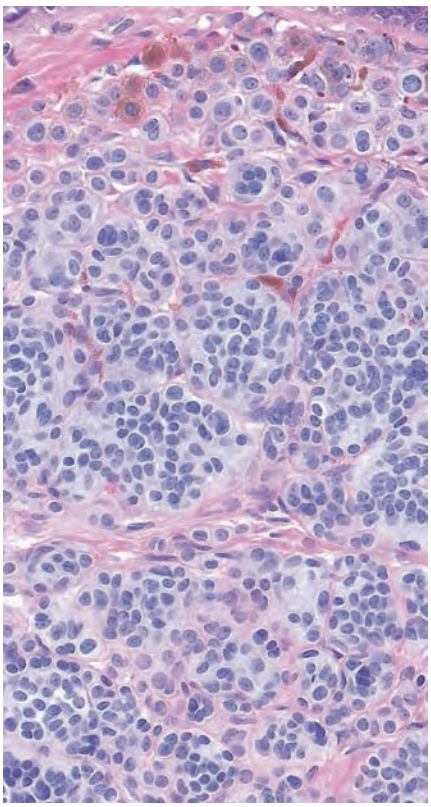

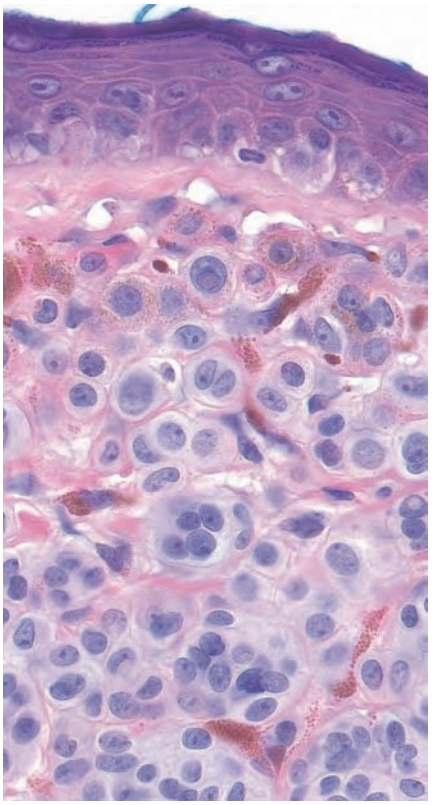

- Granular "material" in melanocytes and melanophages
- Brown, fine granules of similar size within nested (clustered) melanocytes with smaller cells toward base with individual cells splaying through collagen
- Appears darker brown to black with microscope condenser lowered

Melanin (in an intradermal melanocytic nevus)

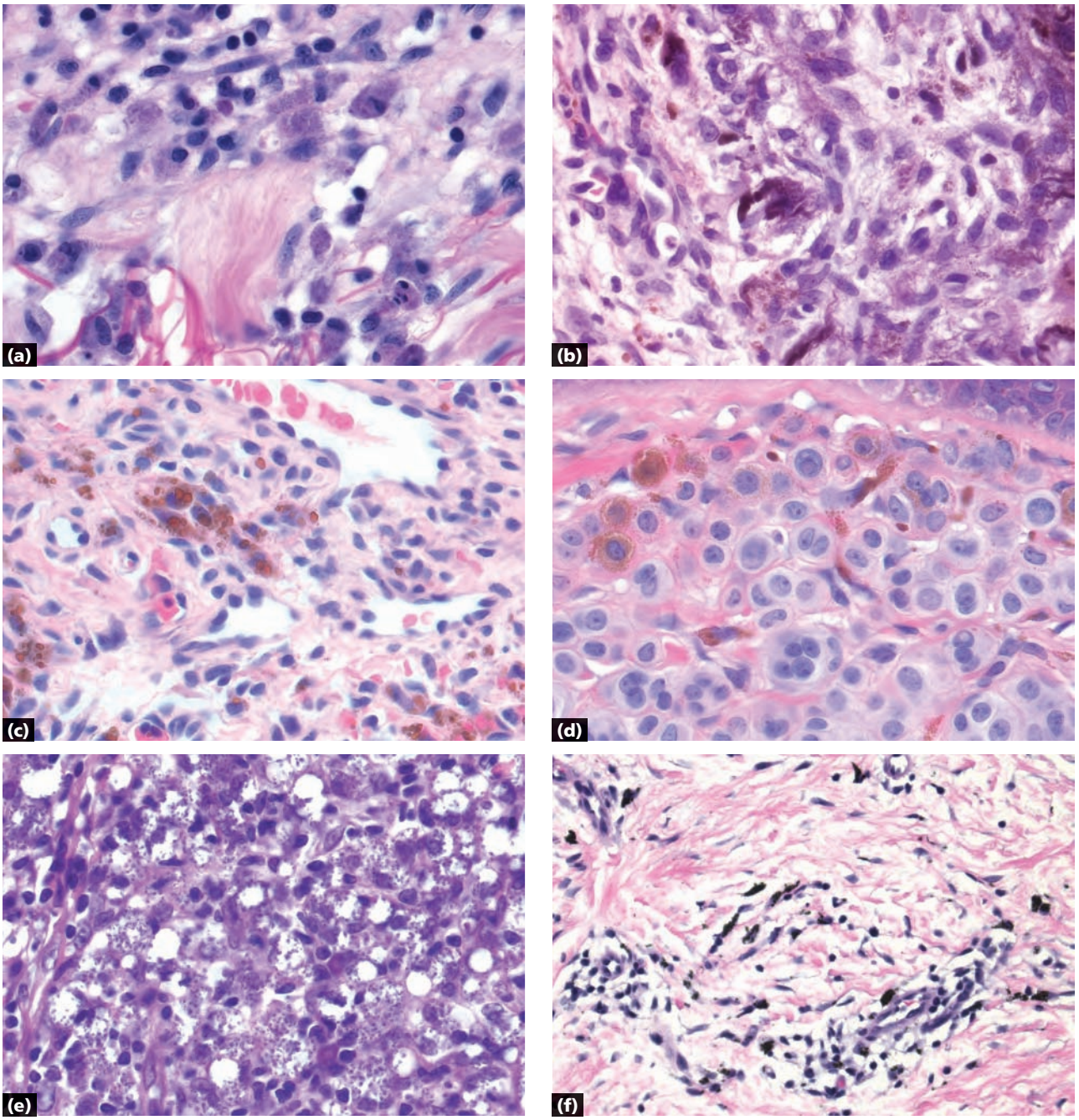

a Aluminum chloride (Drysol solution): presence of a scar with adjacent histiocytes containing fine, bluish granules; blue-purple collagen "concretions"

b Ferric subsulfate (Monsel solution): presence of a scar with adjacent histiocytes containing brown-yellow pigment; brown-yellow to black collagen "concretions"

c Hemosiderin: variably-sized, refractile globules and granules of yellow-brown pigment

d Melanin: non-refractile, similarly-sized circles of brown pigment

e Leishmaniasis: dot-like bluish organisms within sheets of histiocytes; scattered plasma cells (see page 206)

f Tattoo: black particles free in dermis and within macrophages (see page 273)

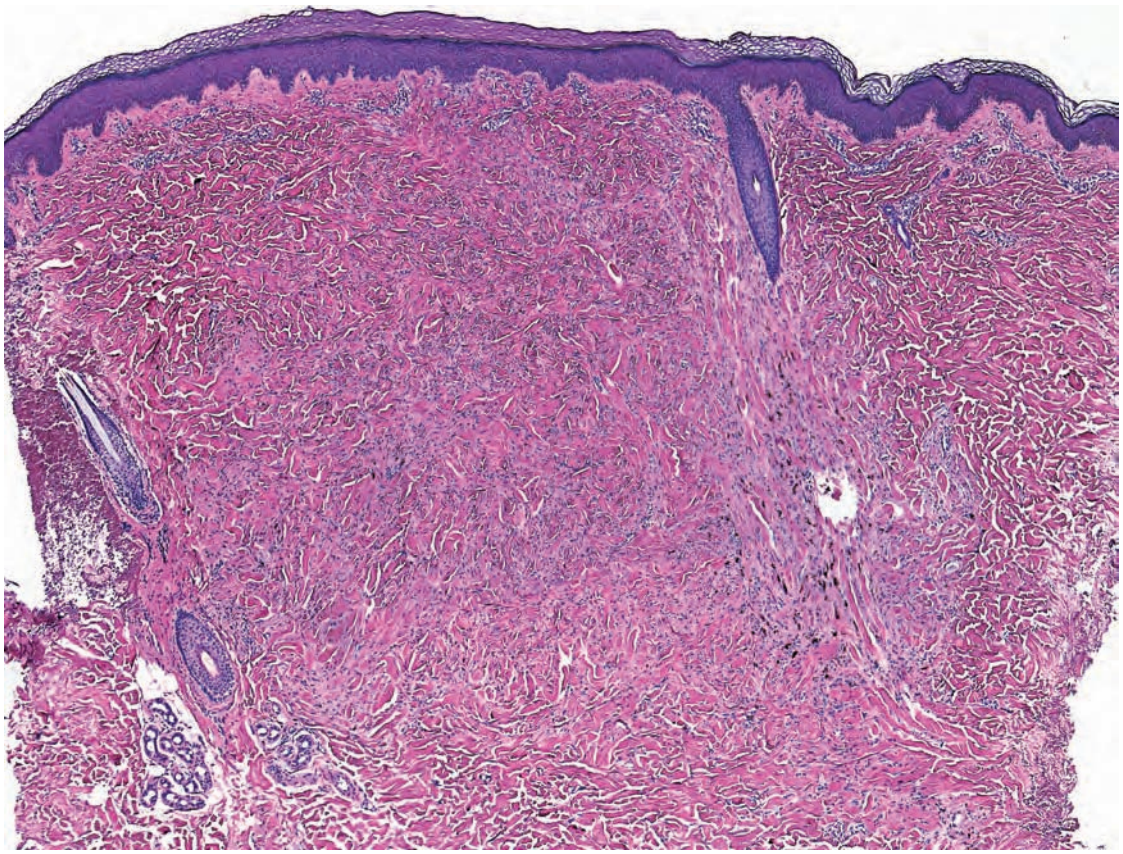

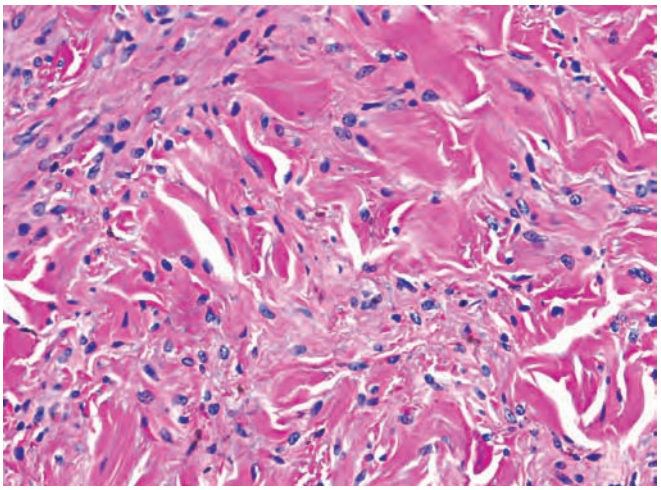

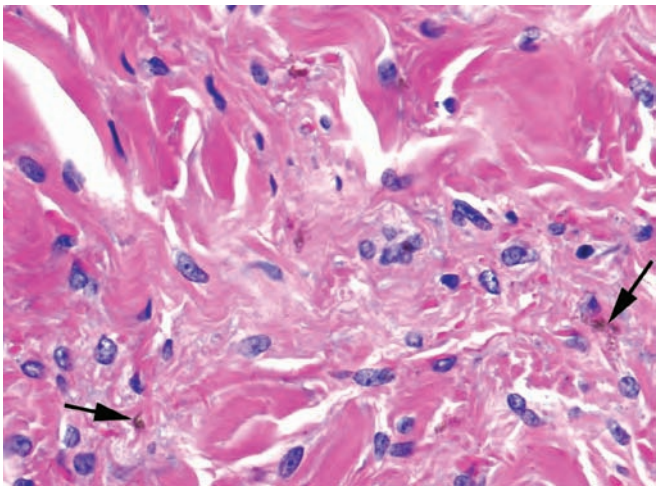

- "Busy" dermis
- Spindle cells with oval to round nuclei in clusters and splaying through sclerotic collagen
- Occasional cells with melanin pigment (arrows)

Blue nevus, hypopigmented

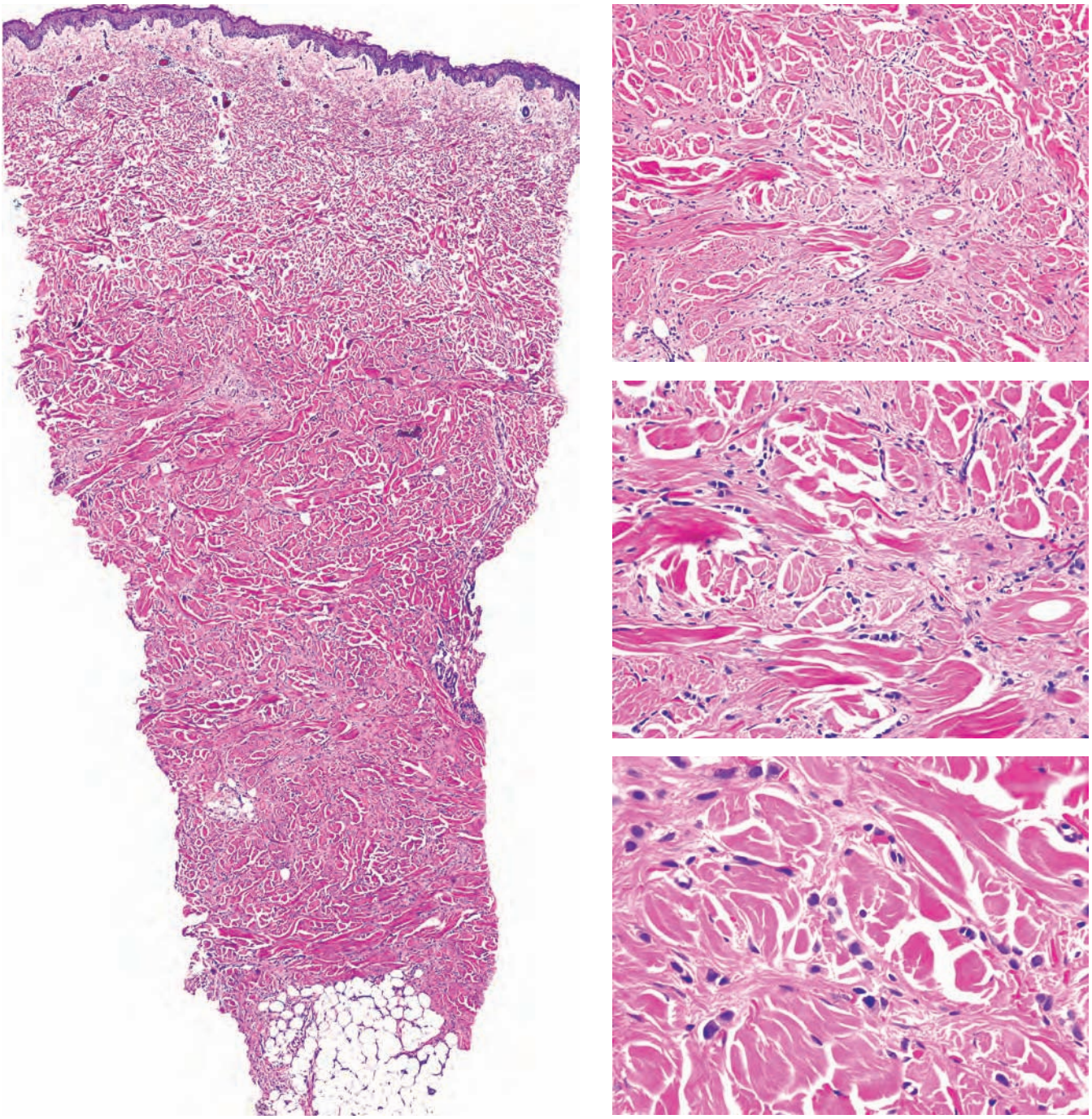

- "Busy" dermis
- Dense collagen with hyperchromatic cells interstitially
- Hyperchromatic cells display nuclear molding

Metastatic breast carcinoma, interstitial pattern (carcinoma *en cuirasse*)

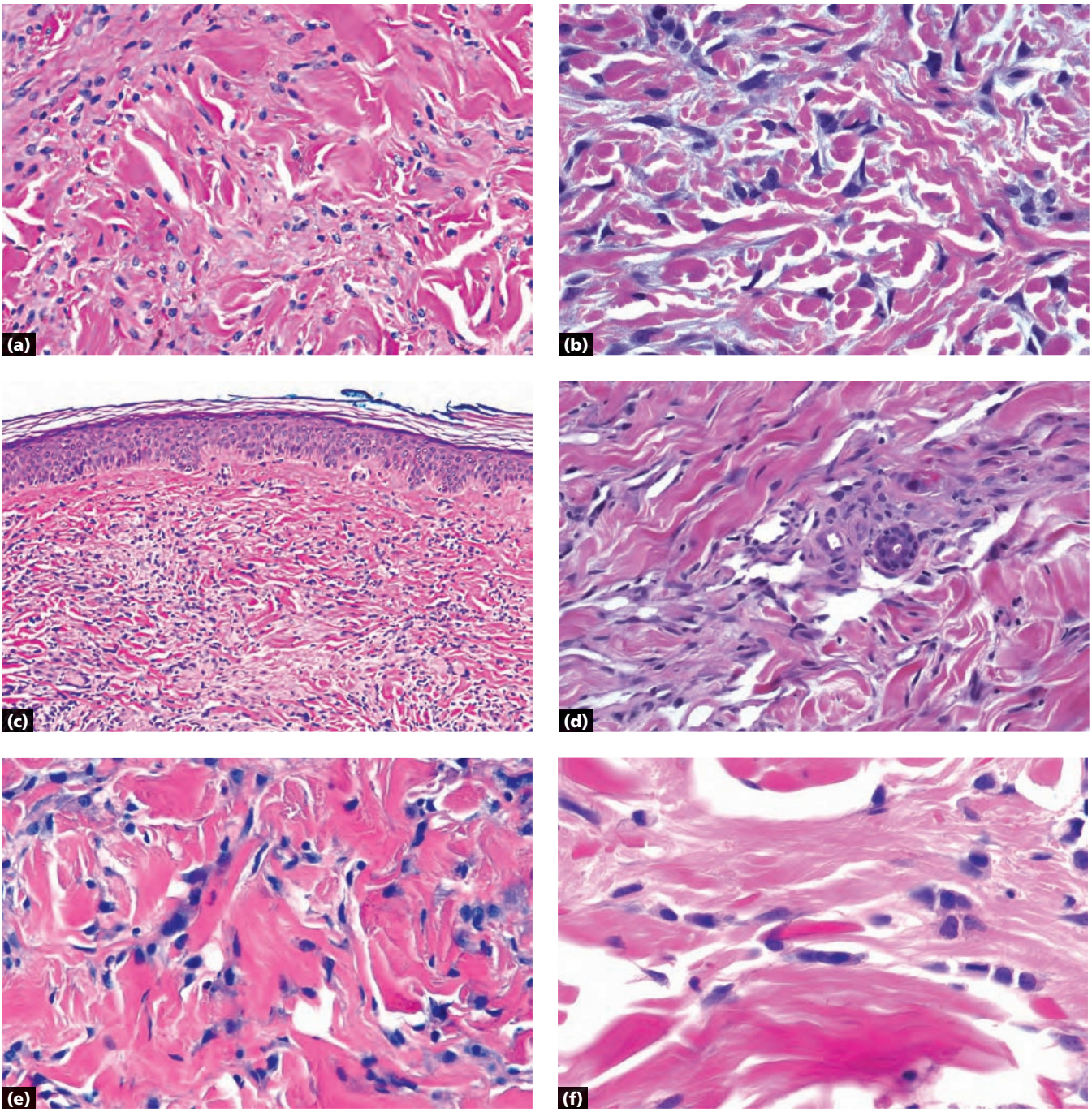

a Blue nevus, hypopigmented: occasional cells with melanin pigment
b Dermatofibroma: collagen entrapment (see page 166)
c Granuloma annulare: subtle hints of palisading, increased mucin (see page 89)
d Kaposi sarcoma: increased vessels (see page 186)
e Leukemia cutis: atypical cells with granular cytoplasm (see page 139)
f Metastatic breast carcinoma, interstitial pattern: hyperchromatic nuclei with molding

Key differences

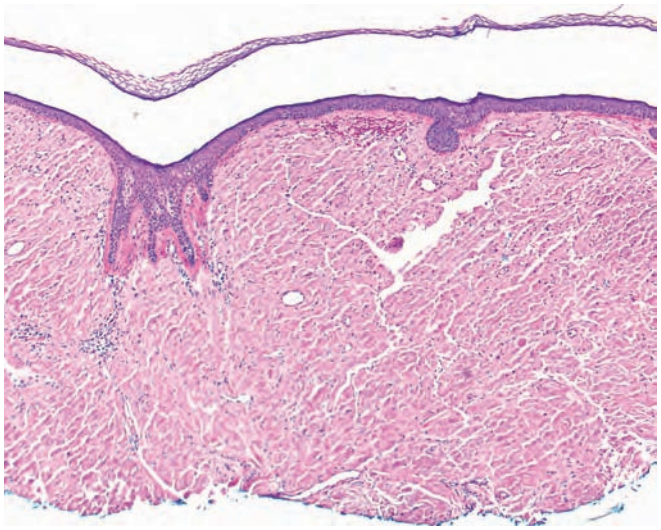

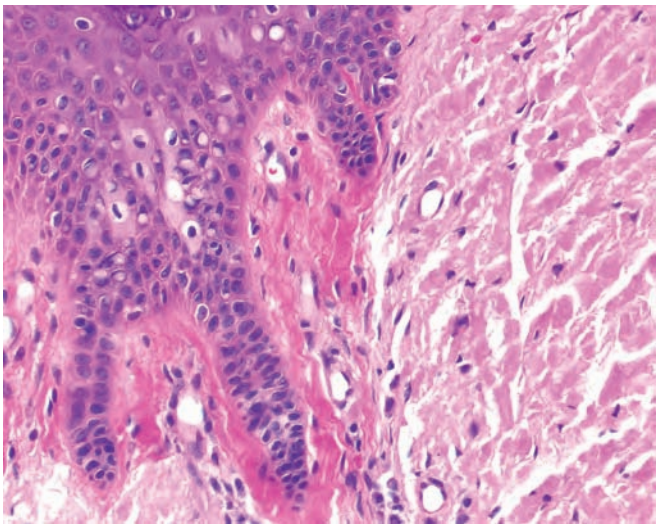

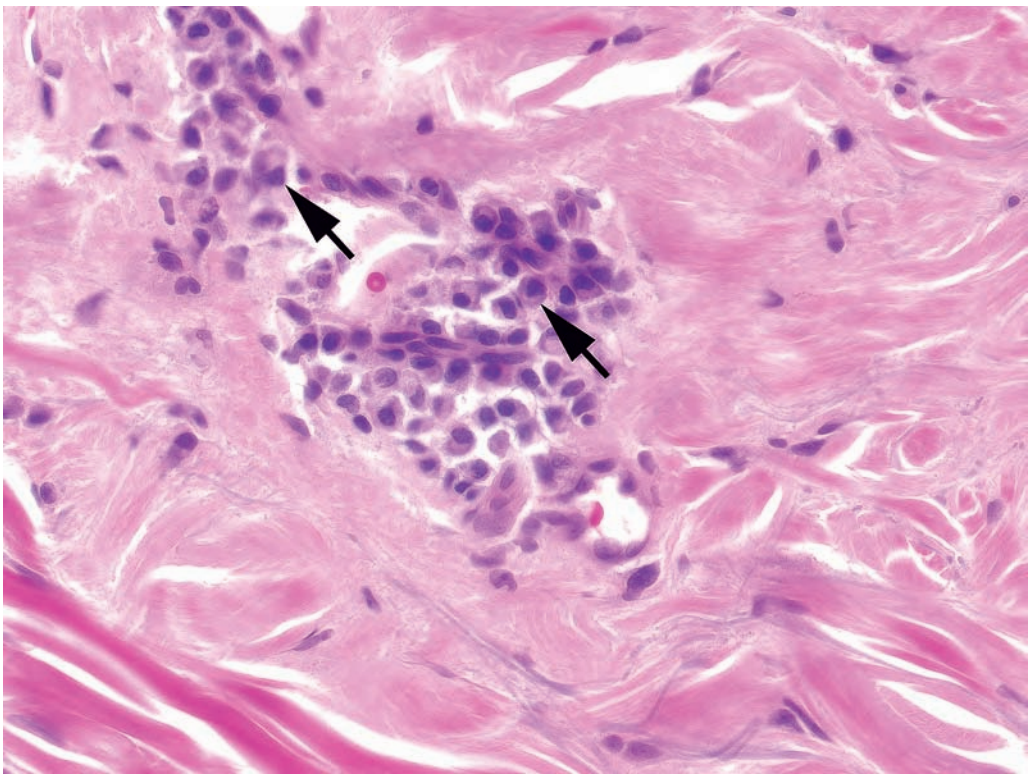

- Dermal material that is pink and amorphous, diffuse and perivascular
- Plasma cells (arrows) are often present around vessels

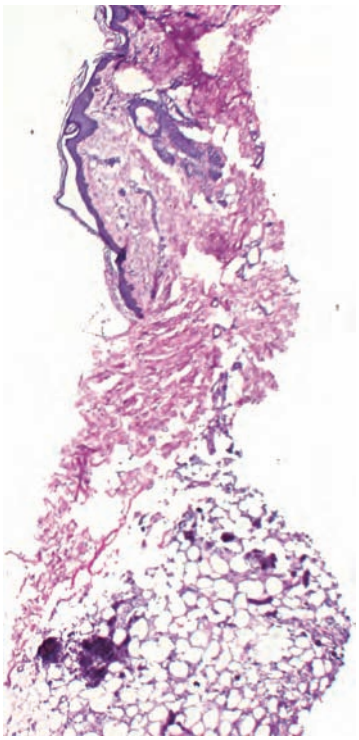

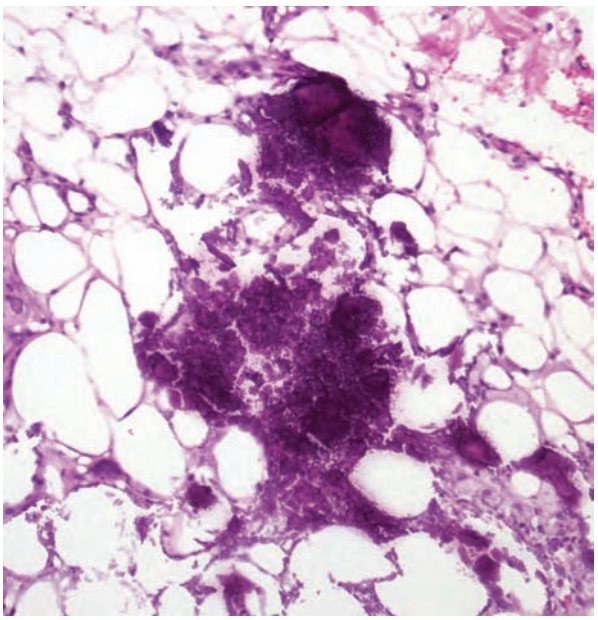

- Dermal material that is blue-purple and chunky
- Calcium deposits can be seen in adnexal tumors (trichoepithelioma, pilomatricoma)
- Calcium may be deposited on the altered elastic fibers in pseudoxanthoma elasticum

Calcinosis cutis

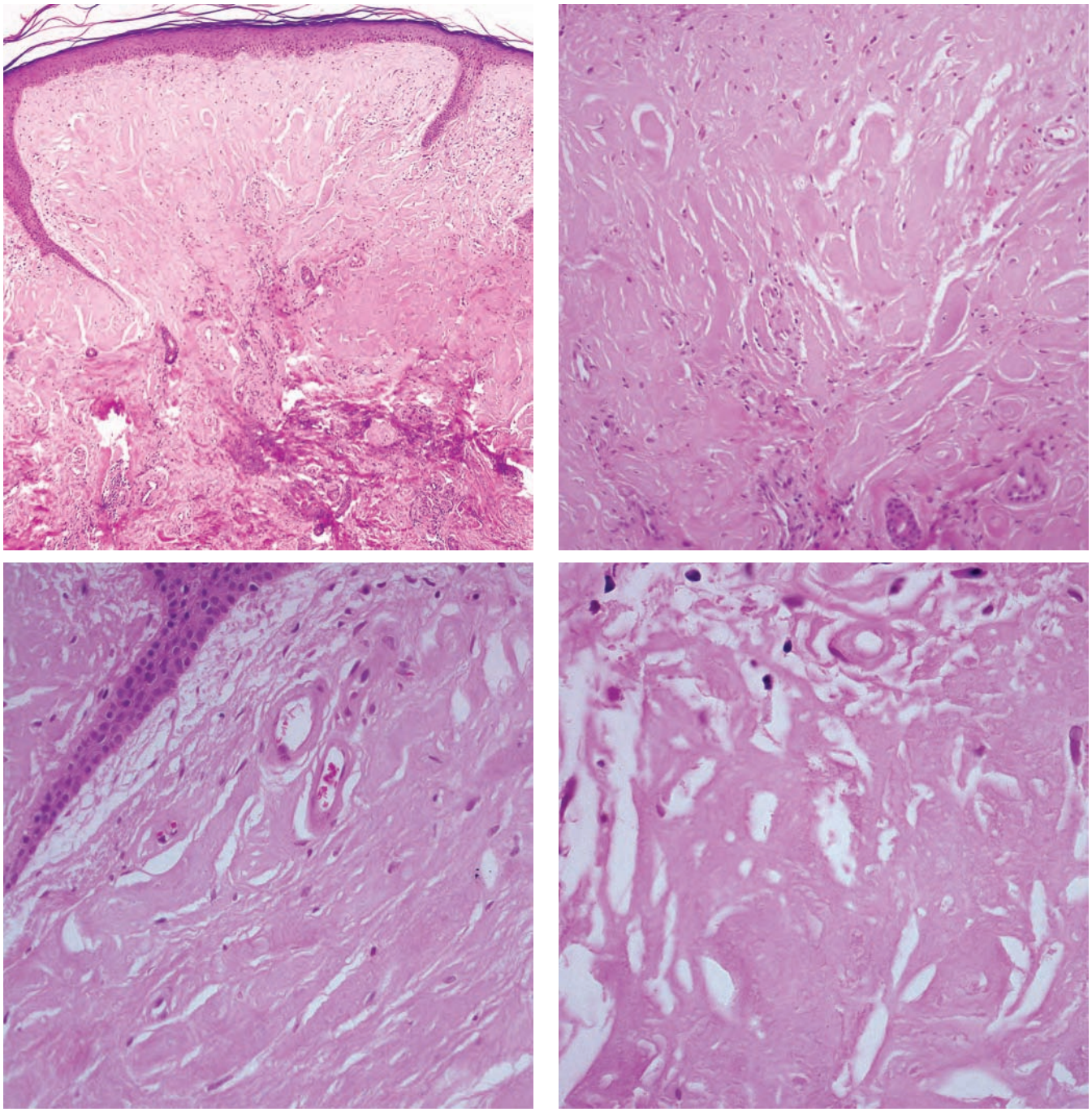

- Dermal material that is pink and amorphous and fills the upper half of the dermis
- Early lesions have pink material around vessels

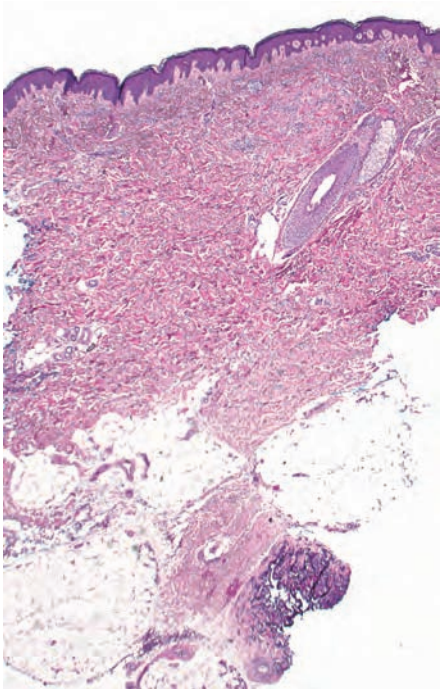

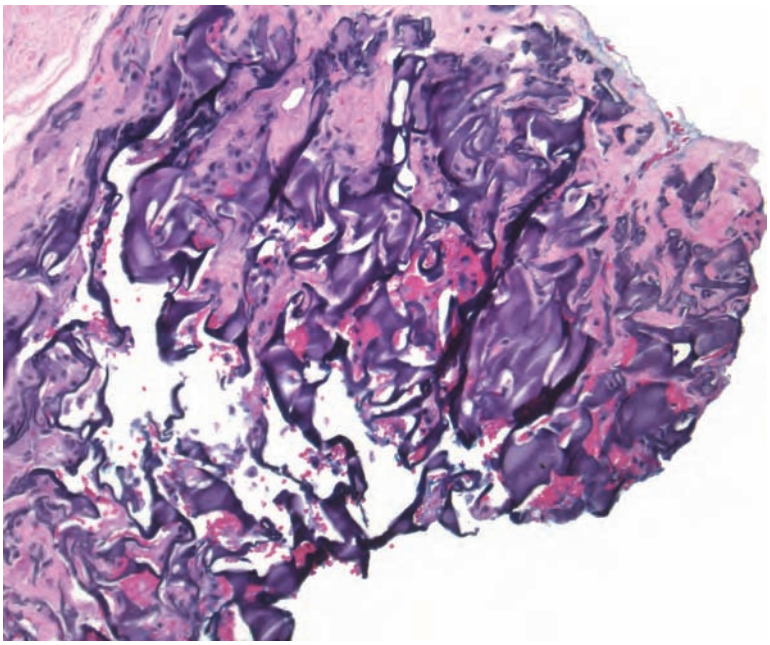

- Dermal material that is bluish, curvy and ribbon-like

Gel foam

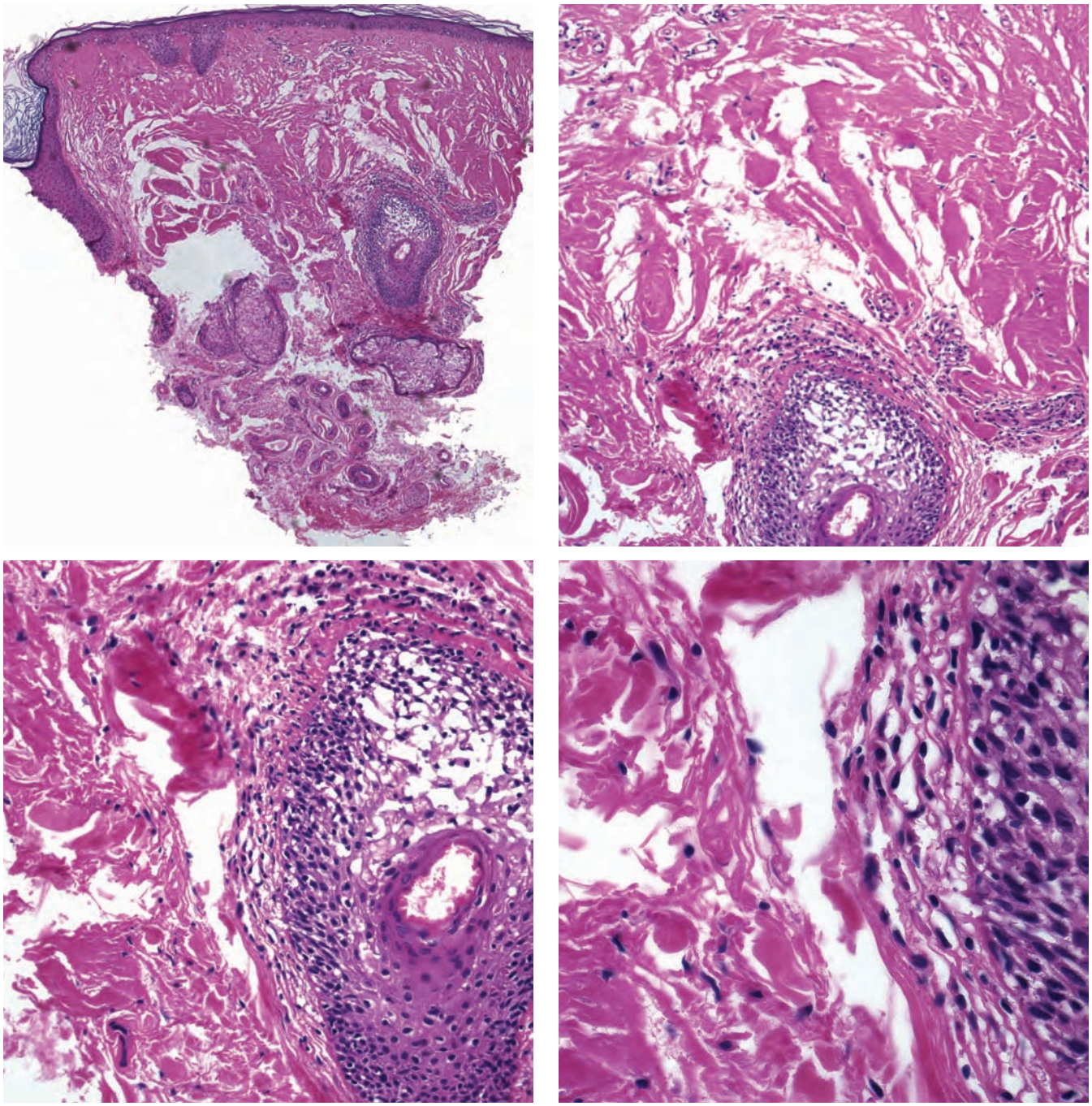

- Dermal material that is pink and amorphous, often filling the dermis full-thickness
- May be perpendicular to epidermis and around adnexae and vessels

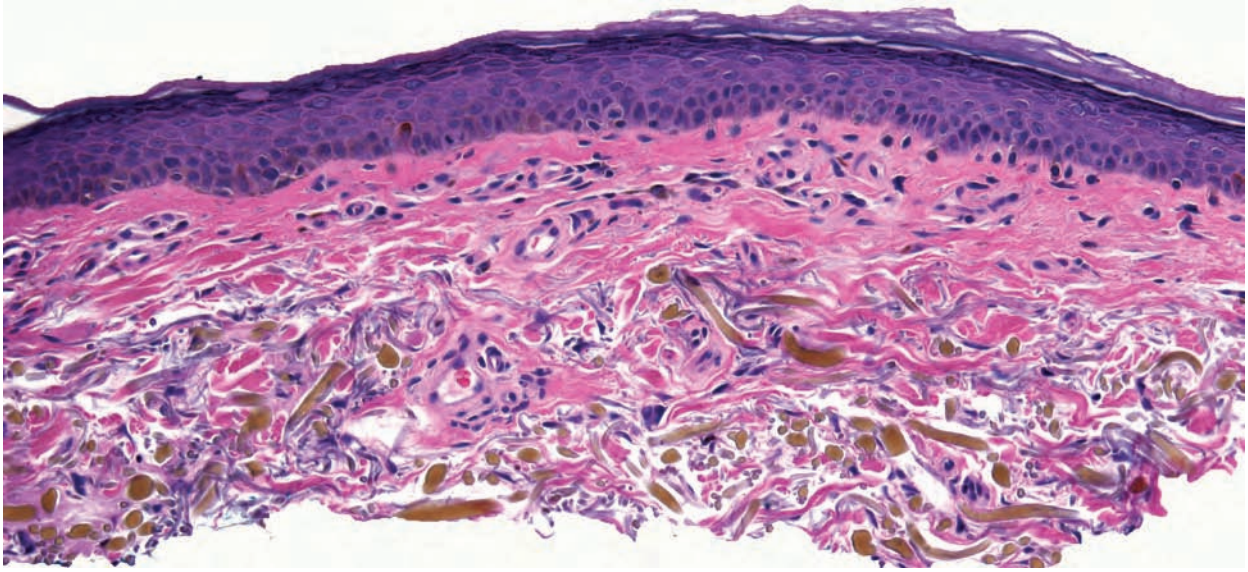

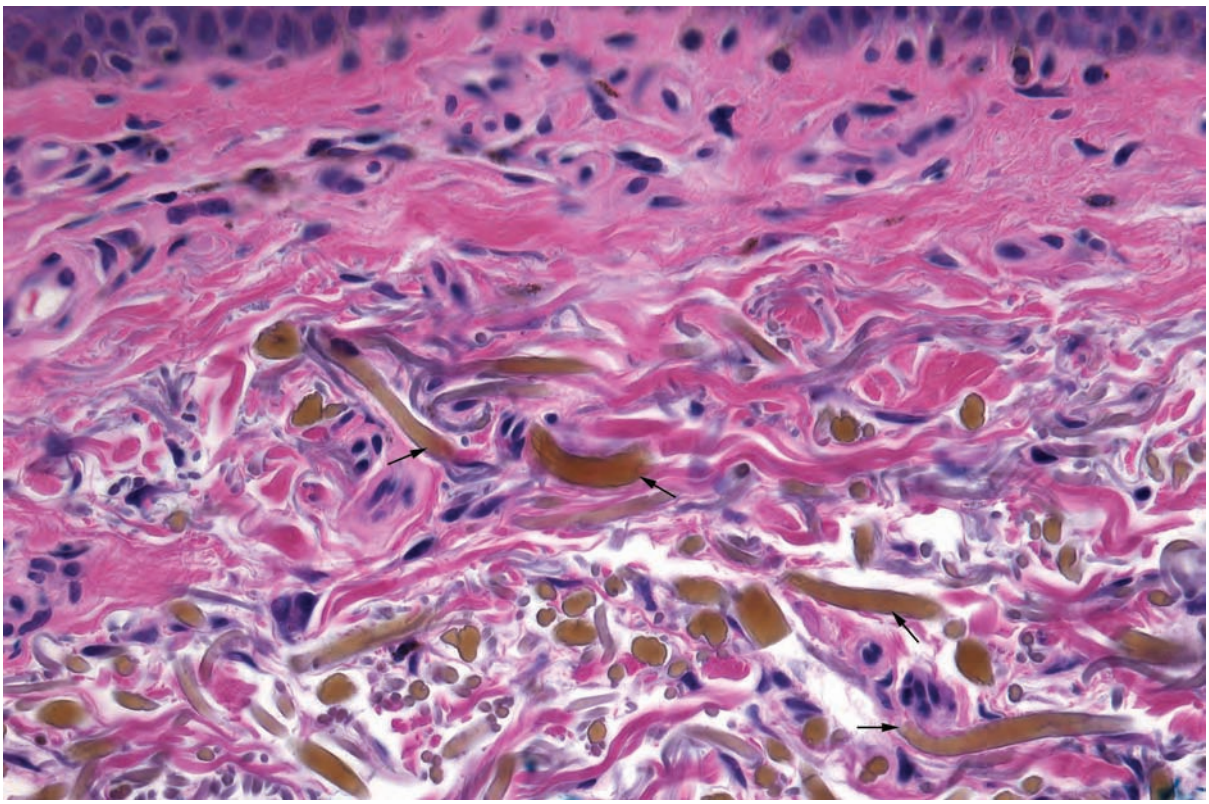

- Dermal material that is banana-shaped and brown-orange (altered collagen; arrows)

Ochronosis

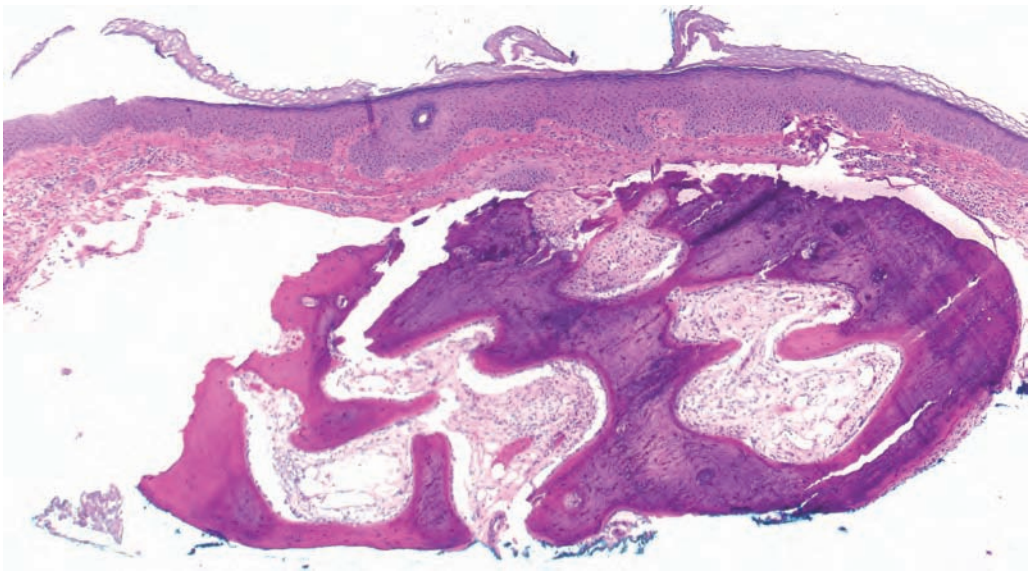

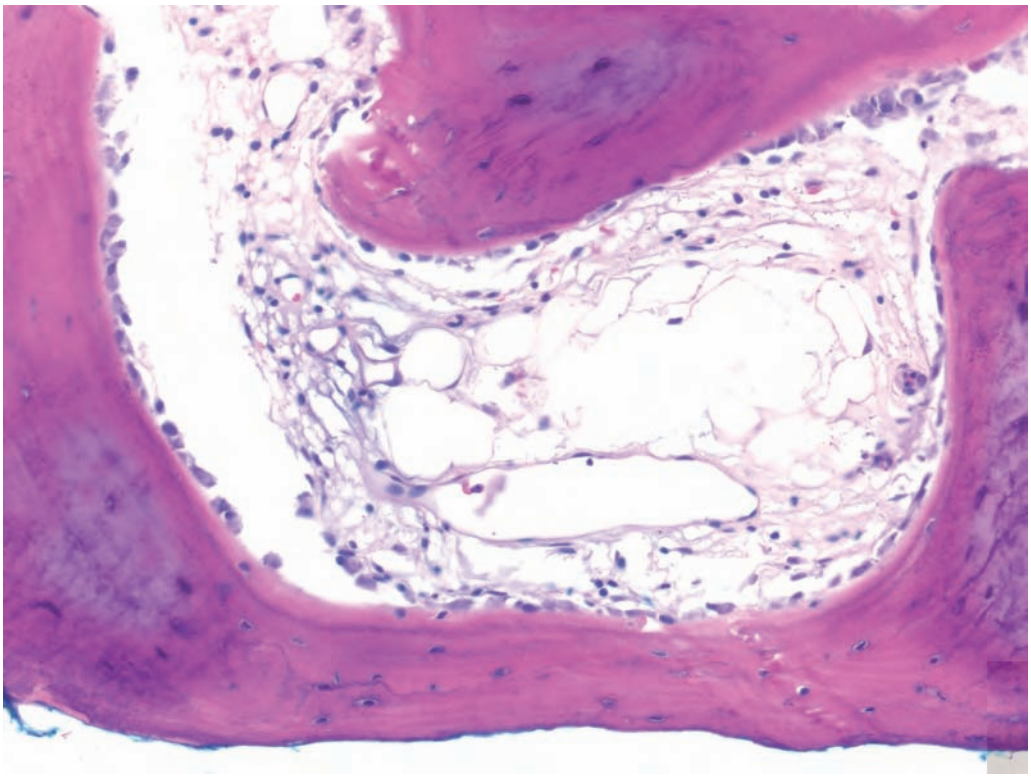

- Dermal material – bone, which has bright, dense pink trabeculae with nuclei with haloes around them (osteocytes)
- Differential diagnosis includes an ossified pilomatricoma, identifiable if keratin with shadow cells is present

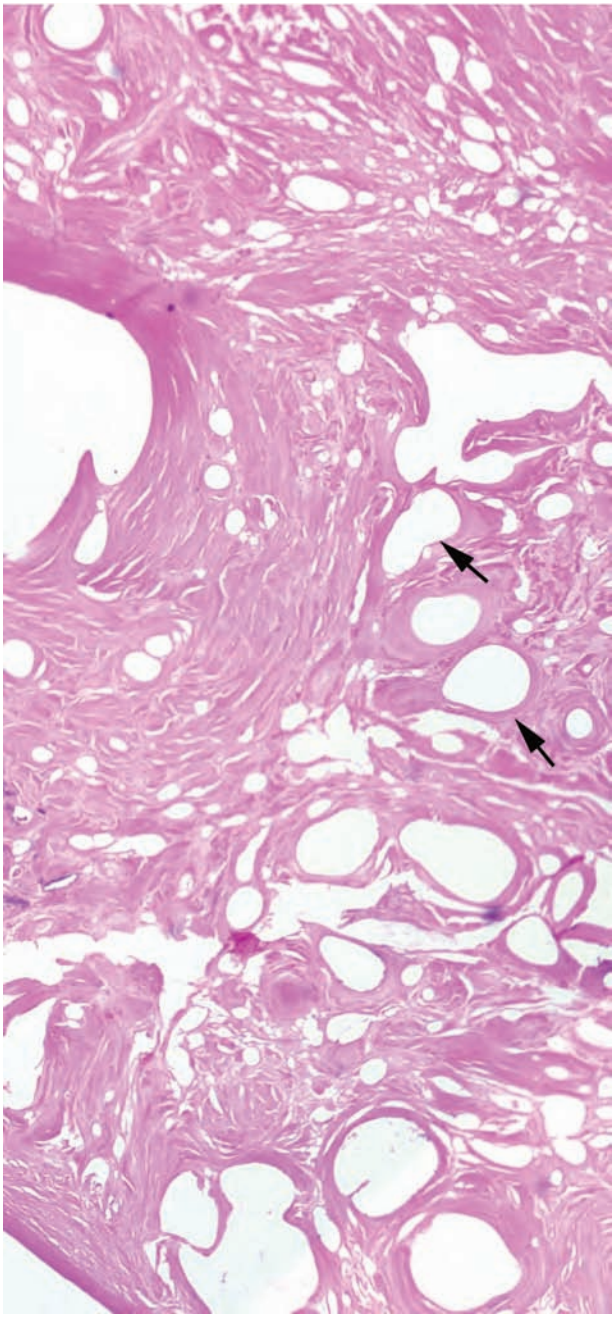

- Dermal material that is lost during processing and is "seen" as irregularly shaped circular spaces (arrows)
- Dark pink sclerotic stroma
- Swiss-cheese appearance

Paraffinoma

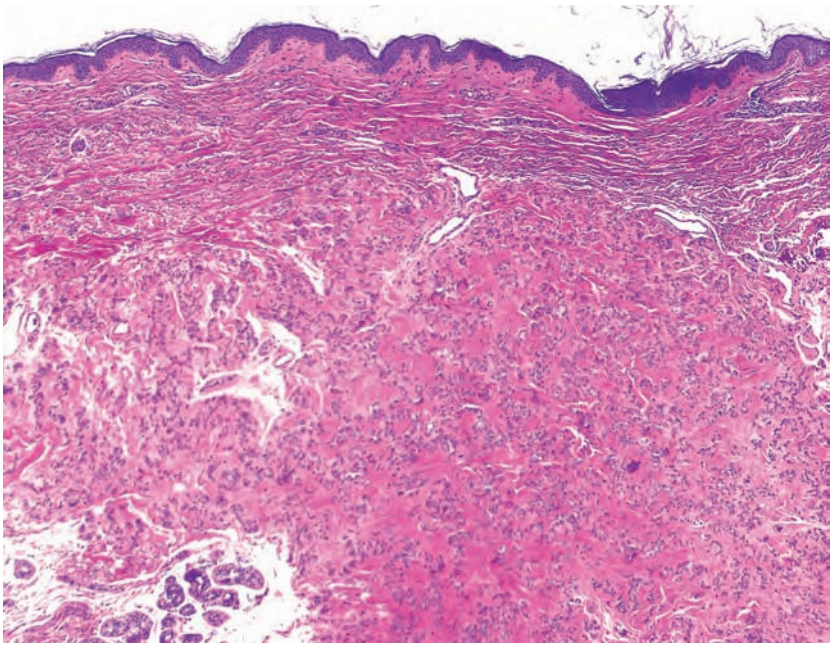

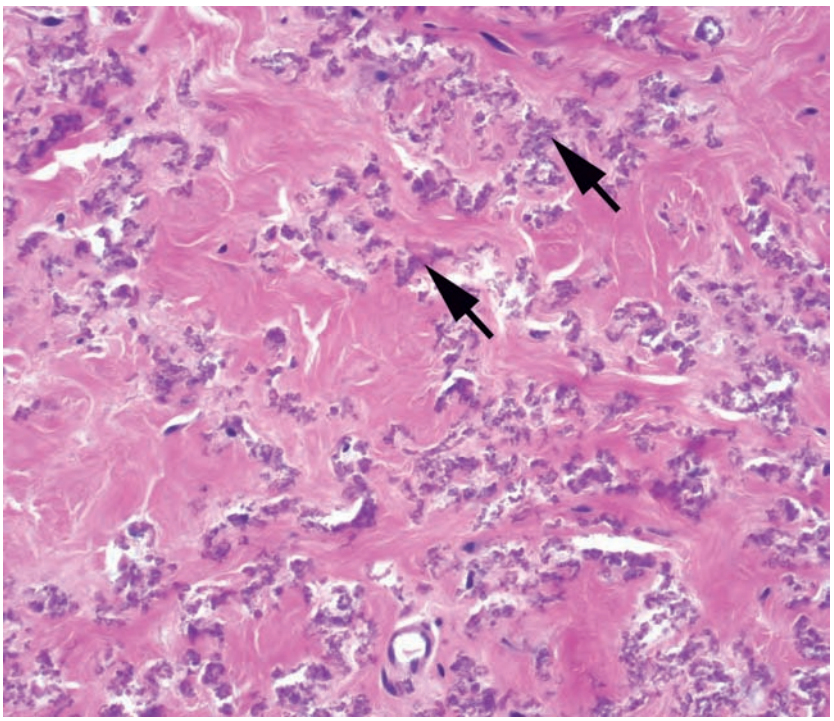

- Dermal material (altered elastic fibers) that is blue and squiggly (arrows)
- Sometimes the corkscrew fibers are calcified

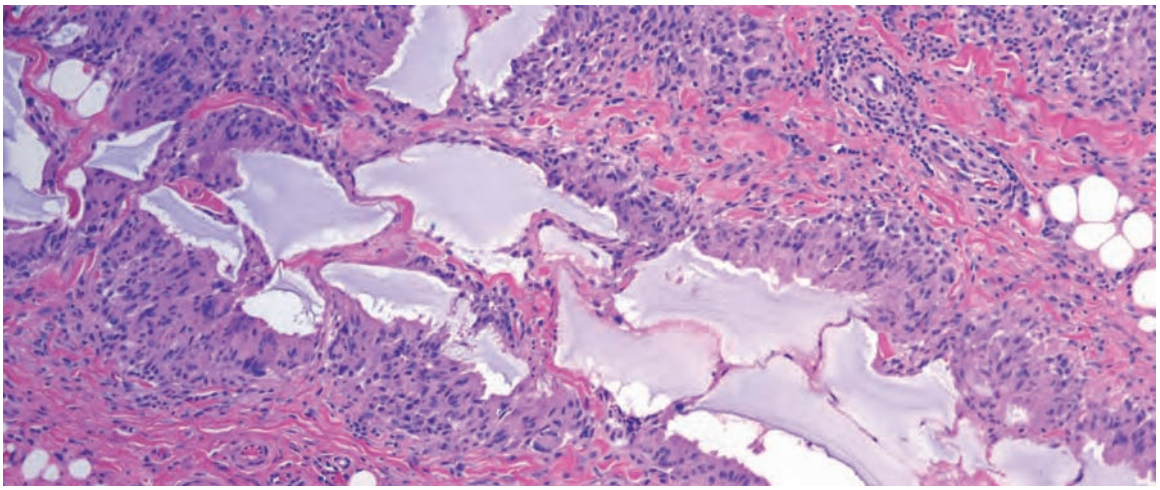

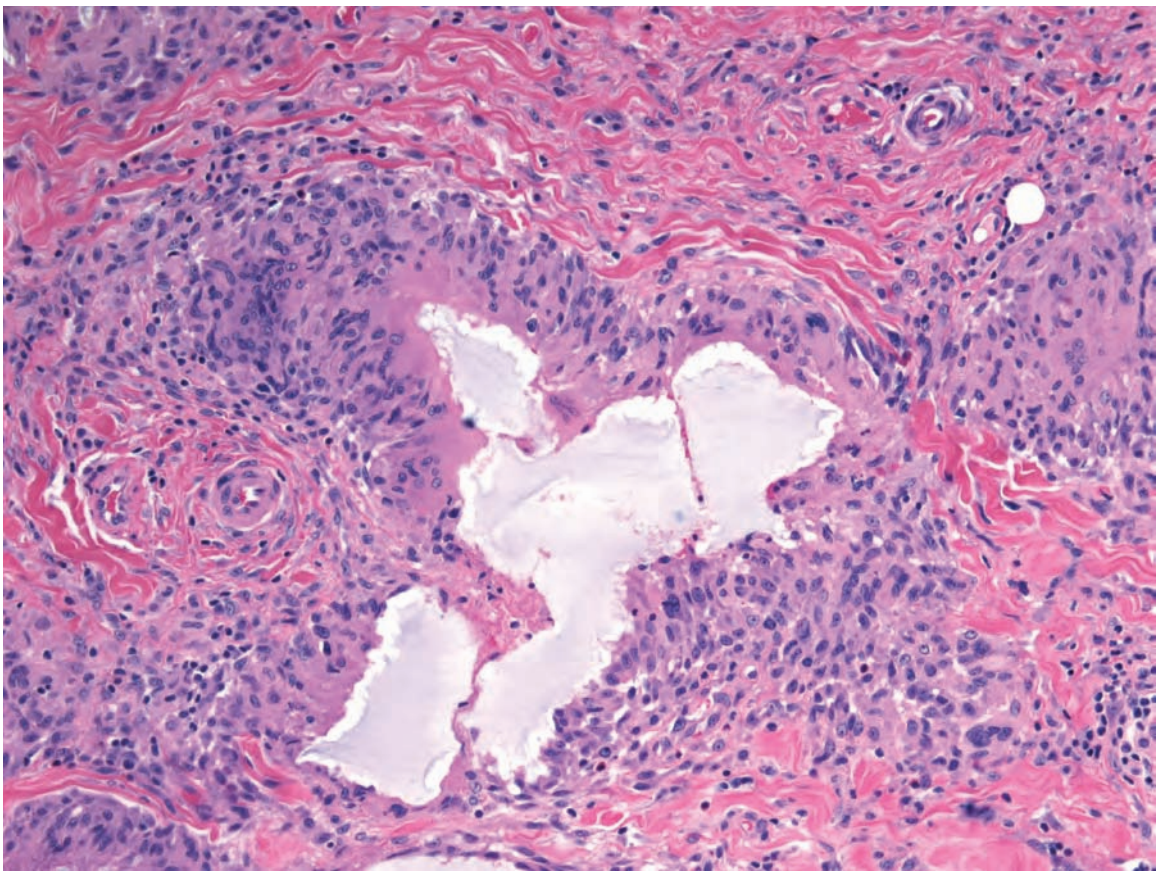

- Dermal material
- Material is light blue and in pools
- May have a surrounding foreign body giant cell reaction

Hyaluronic acid (dermal filler)

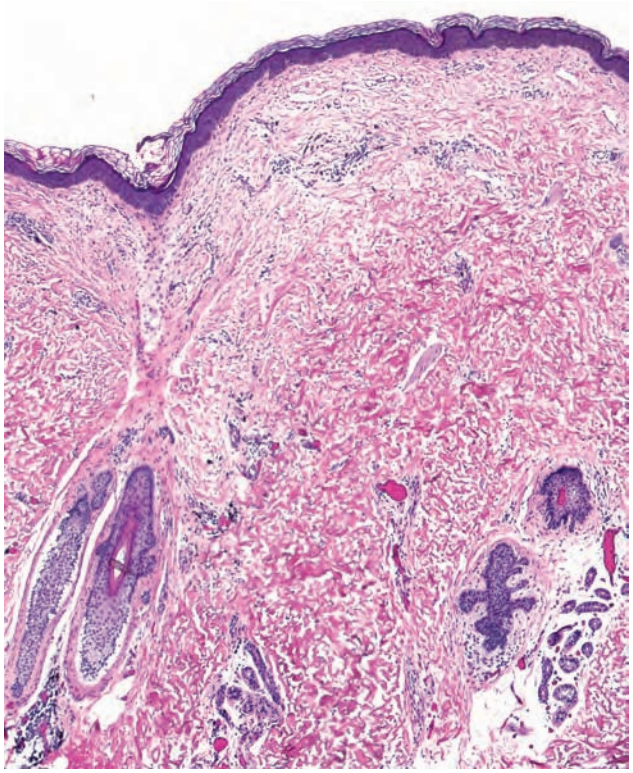

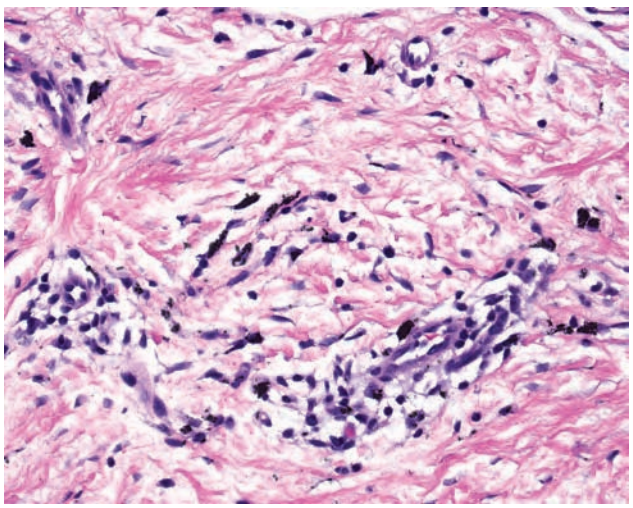

- Dermal material that is black (most commonly) and is free in the dermis as well as within macrophages

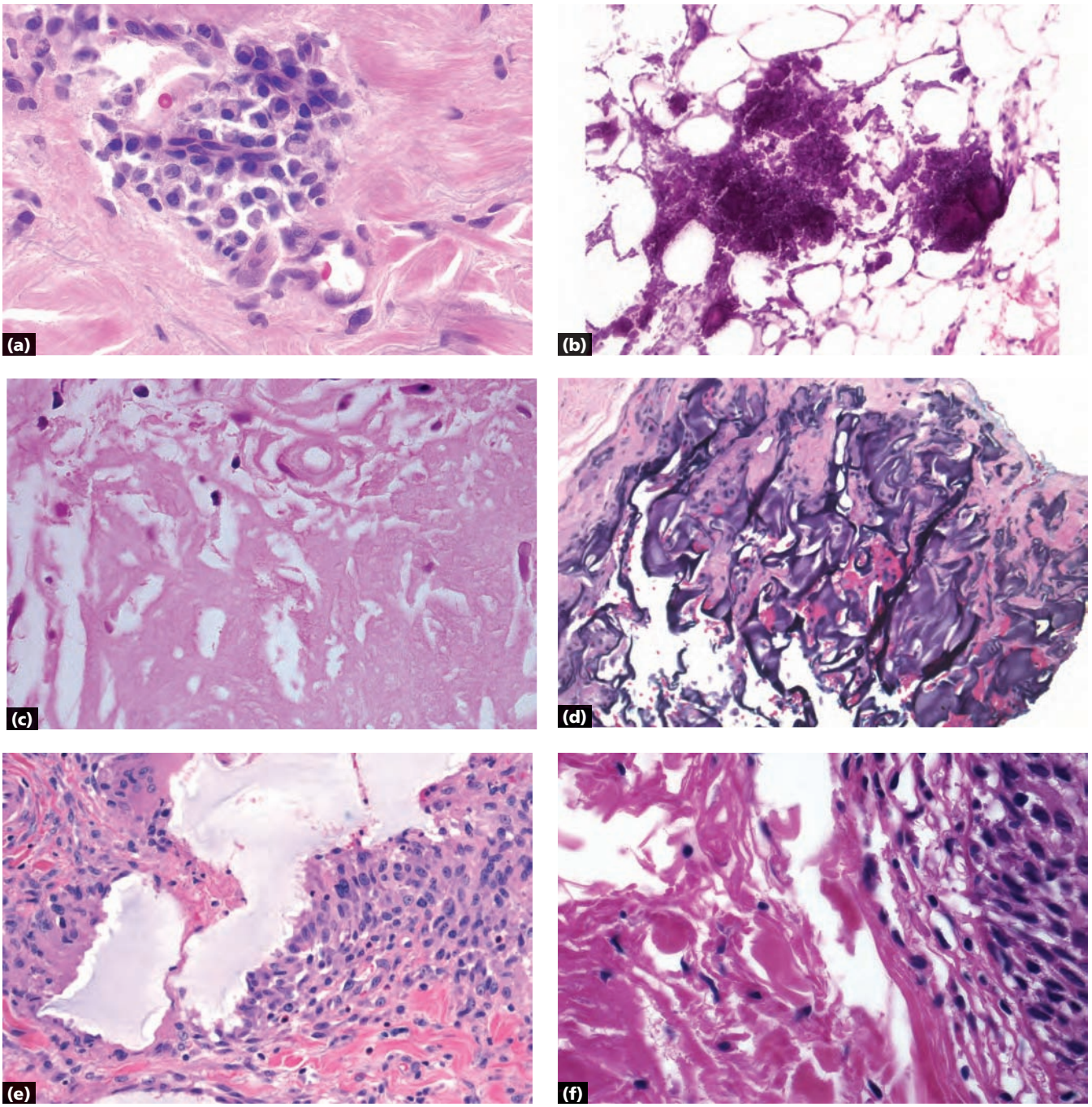

a Amyloidosis, nodular: amorphous pink material with plasma cells
b Calcinosis cutis: blue-purple chunks
c Erythropoietic protoporphyria: amorphous pink material around vessels and in upper dermis
d Gel foam: blue interconnected ribbons
e Hyaluronic acid: bluish material
f Lipoid proteinosis: amorphous pink material filling the entire dermis; often around adnexae

Key differences

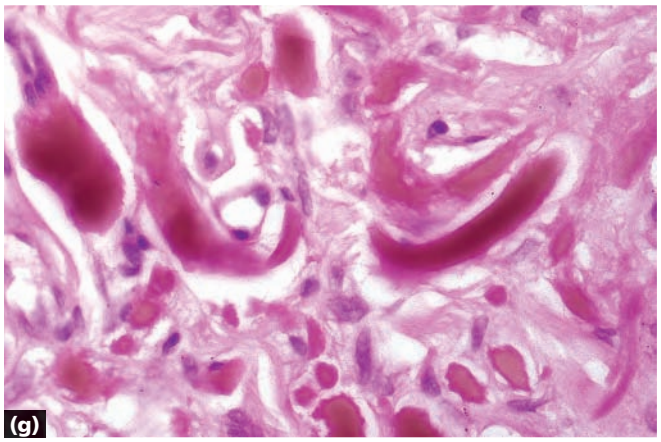

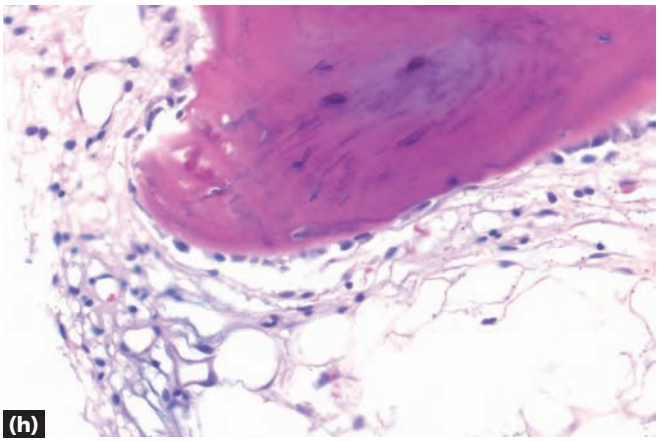

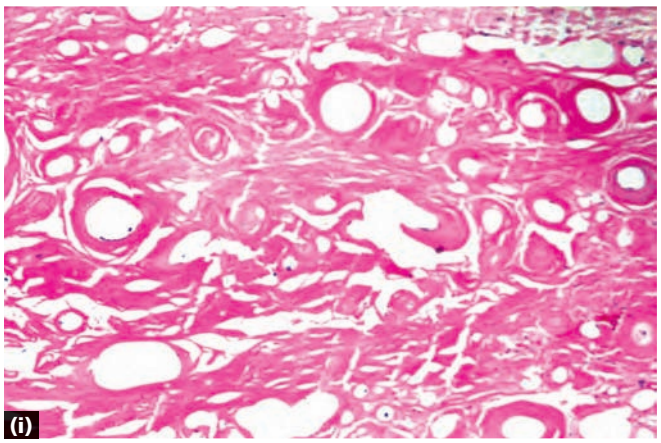

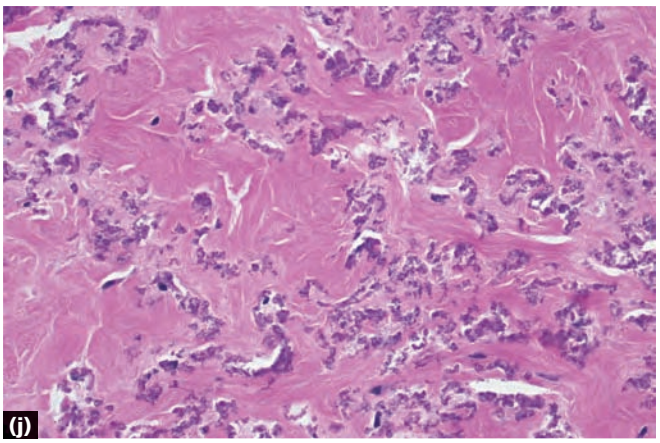

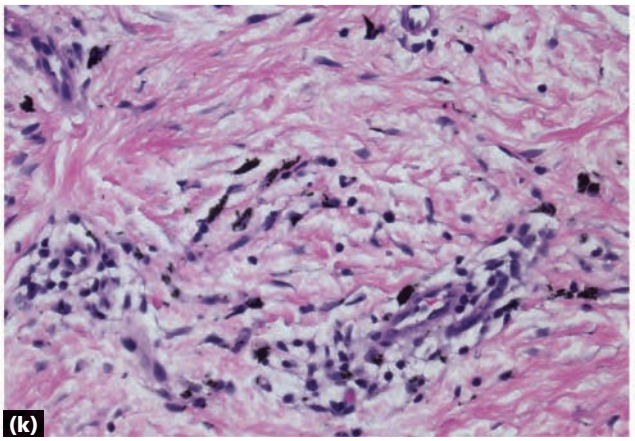

g Ochronosis: brown-orange banana-shapes
h Osteoma cutis: well-defined pink shapes with nuclei
i Paraffinoma: irregular circular spaces like Swiss cheese
j Pseudoxanthoma elasticum: squiggly blue lines
k Tattoo: black particles within macrophages and free in dermis

Key differences, *continued*

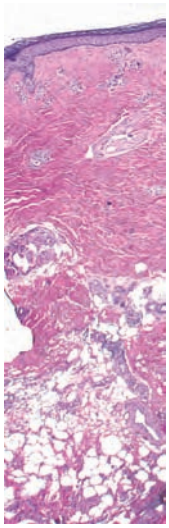

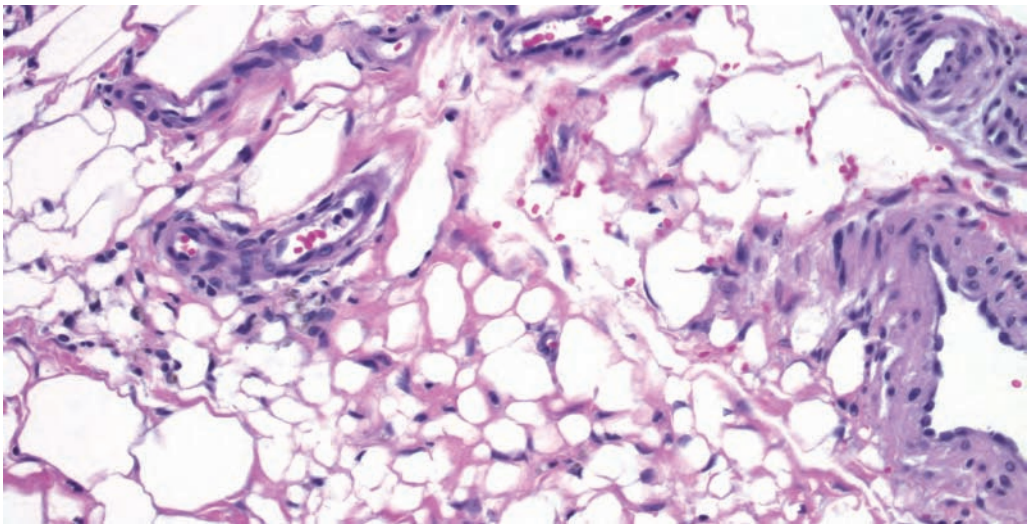

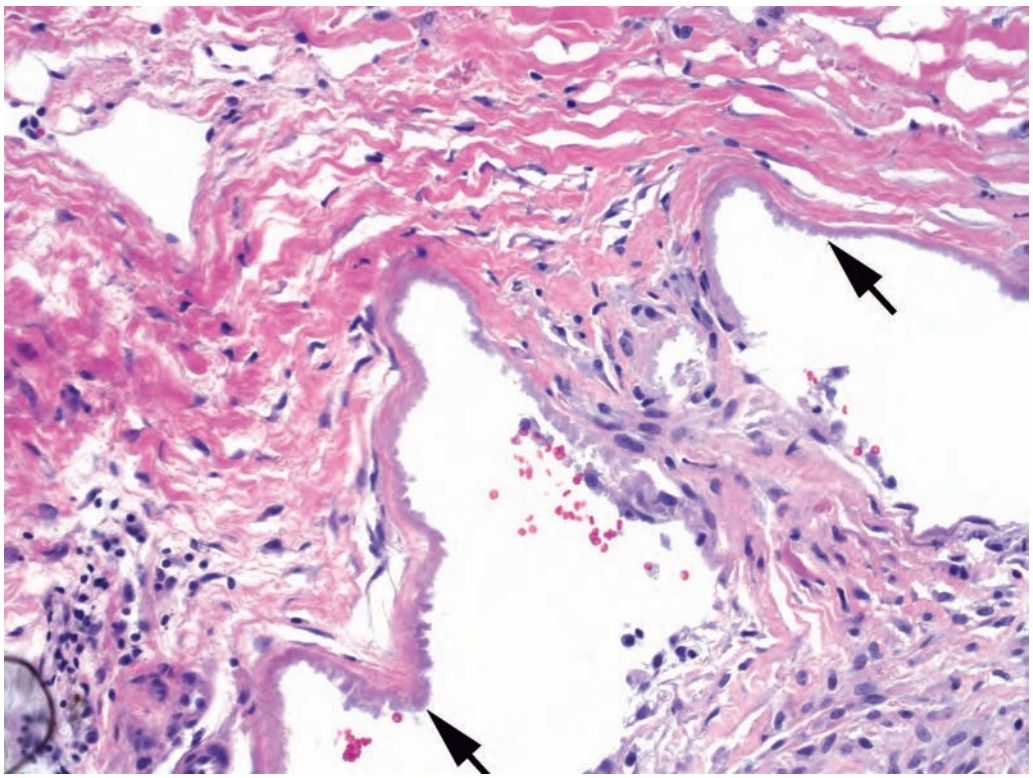

- Fat necrosis
- Individual adipocytes are lost and replaced by arabesques of pink, ruffled membranes (lipomembranous fat necrosis) (arrows)

Lipodermatosclerosis

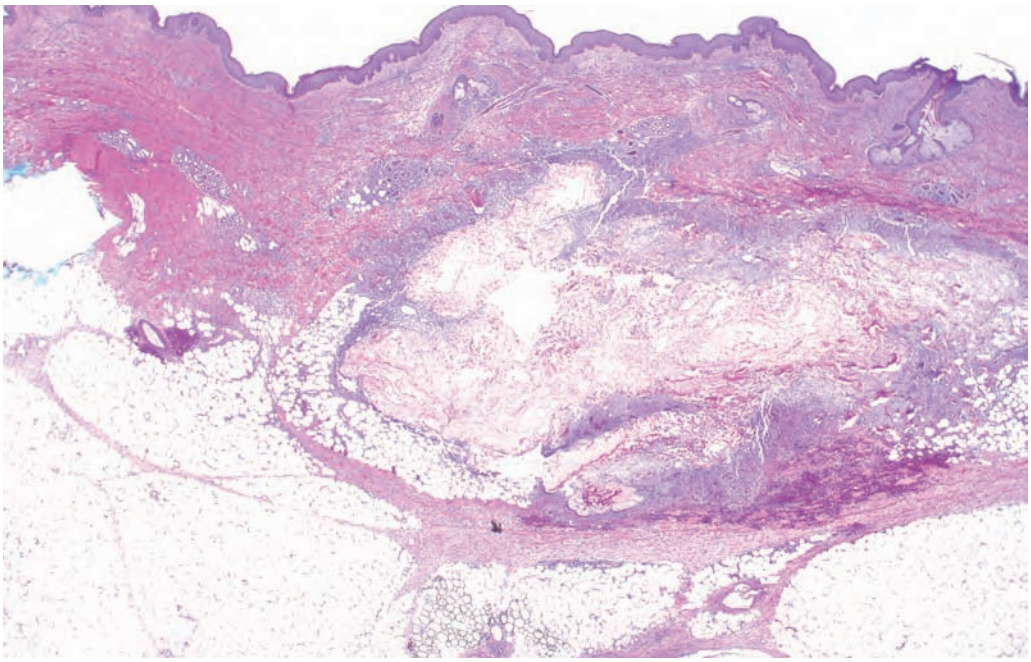

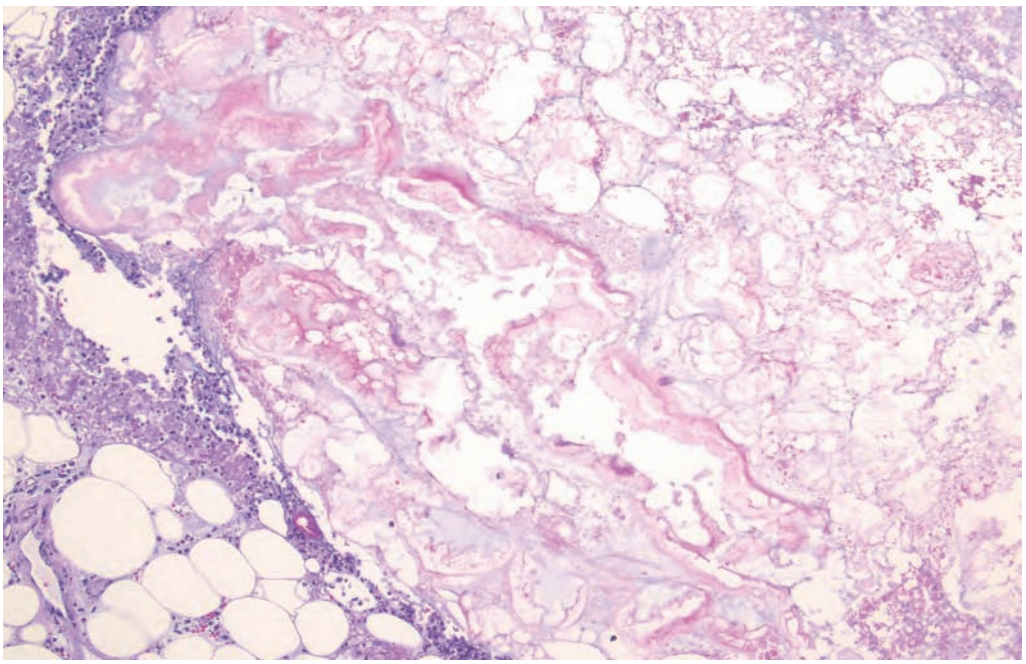

- Fat necrosis
- Necrosis of the fat with "ghost-like" shadows of fat cells remaining
- Calcification/neutrophils/eosinophils may be present
- Septal vessels are inflamed

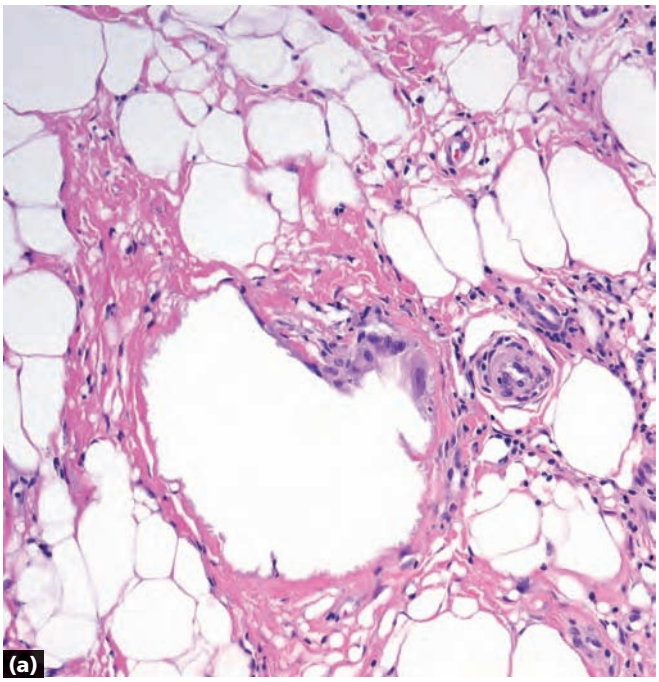

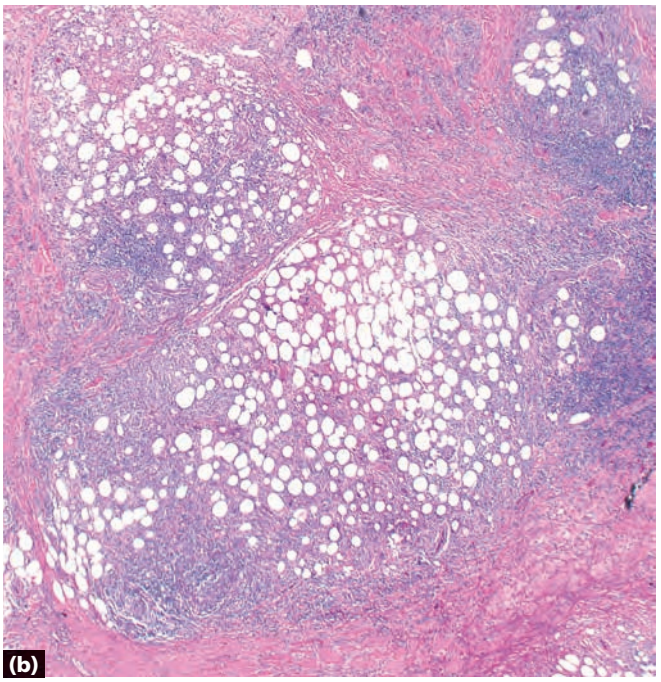

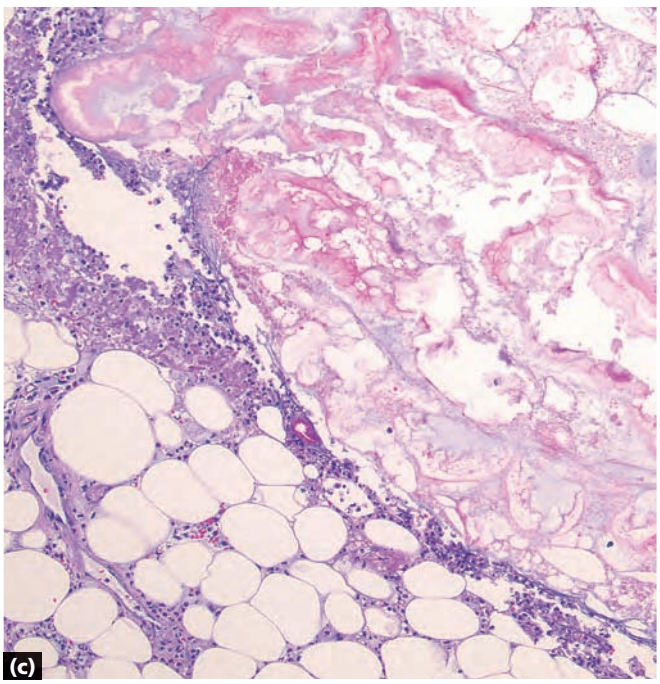

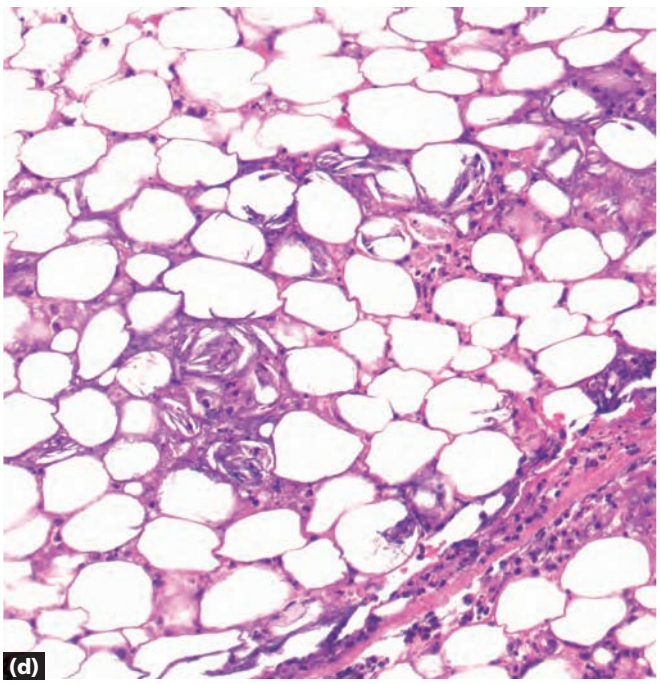

a Lipodermatosclerosis: pink arabesques of membranes replacing adipocytes
b Lupus profundus: hyaline fat necrosis, lymphocytic lobular infiltrate (see page 146)
c Pancreatic fat necrosis: ghost-like necrosis of fat, +/–calcification
d Subcutaneous fat necrosis of the newborn: crystalline shapes and inflammation within fat lobules (see page 148)

Key differences

5 Color – Blue

- Blue tumor, 281
- Mucin and glands or ducts, 291
- Mucin, 295

Dermatopathology: Diagnosis by First Impression, Third Edition. By Christine J. Ko and Ronald J. Barr.
© 2017 John Wiley & Sons, Ltd. Published 2017 by John Wiley & Sons, Ltd.
Companion website: www.wiley.com/go/ko/dermatopathology3e

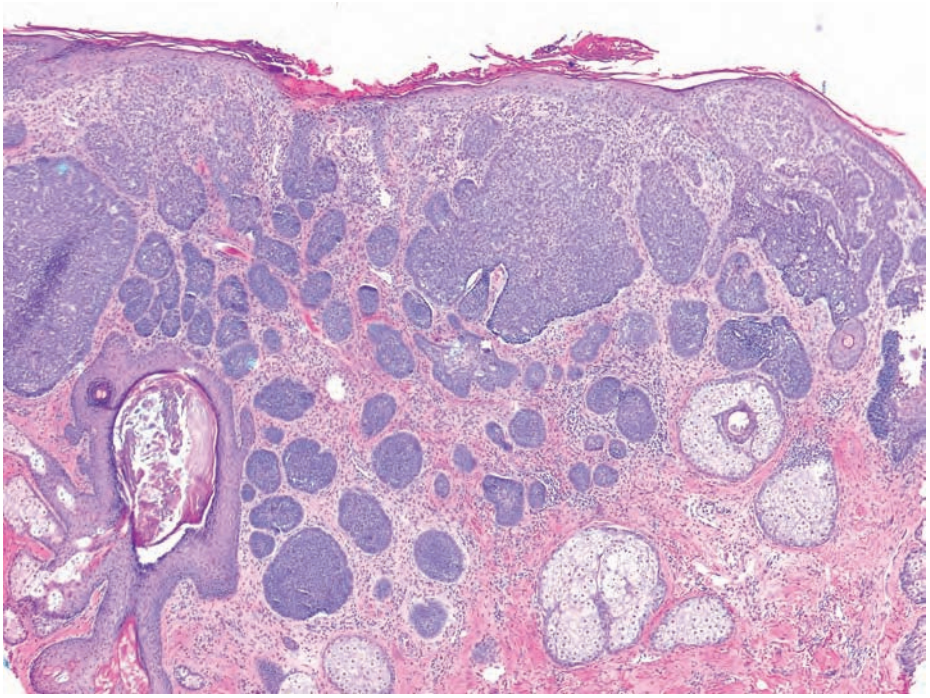

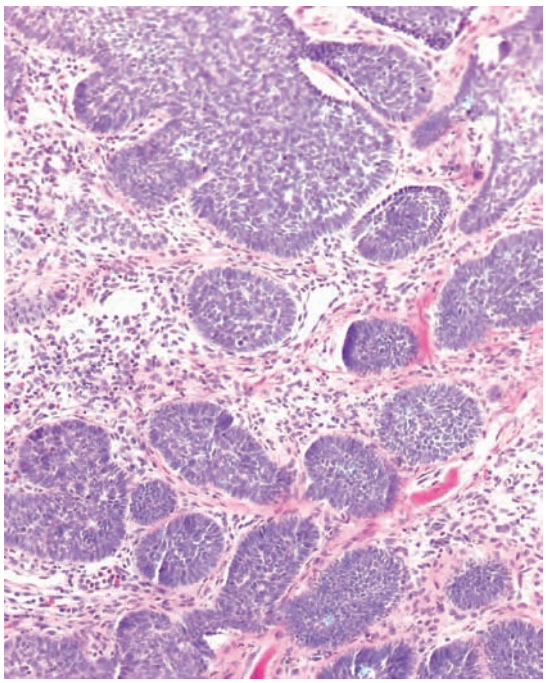

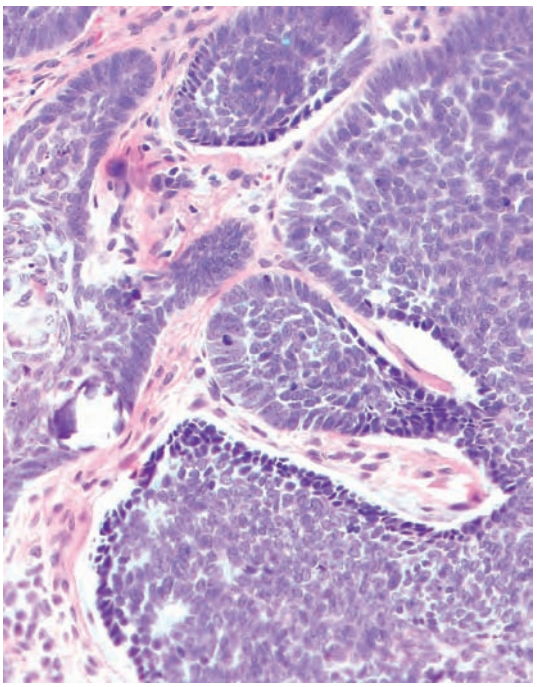

- Blue tumor
- Peripheral palisading
- Retraction of stroma around individual islands
- Stroma often mucinous
- Islands may contain mitoses and individually necrotic cells

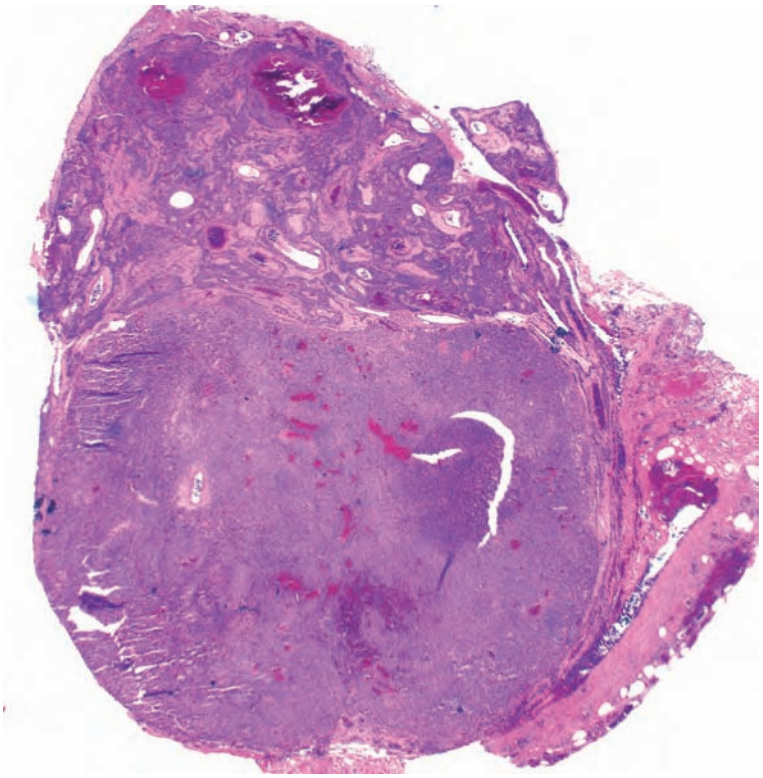

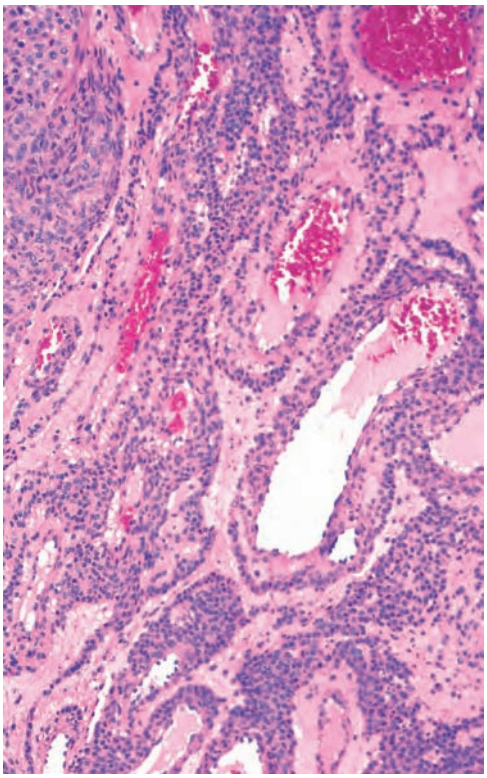

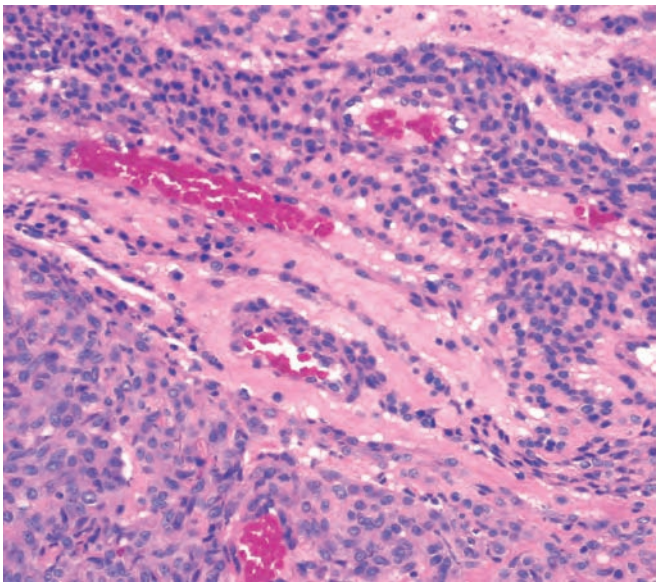

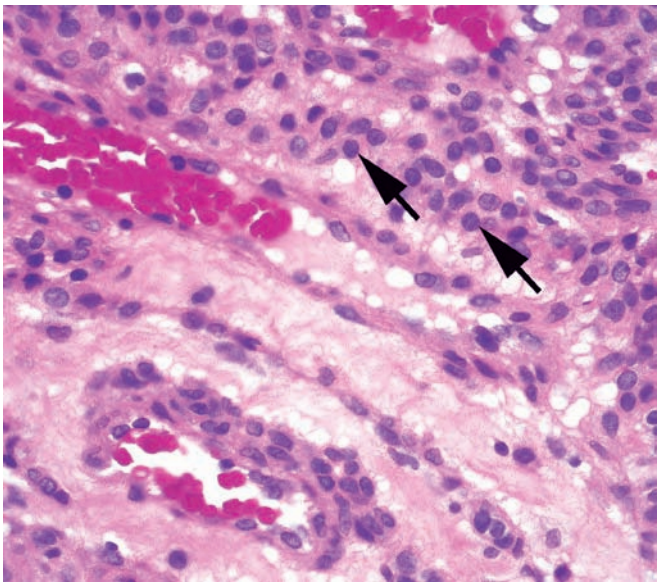

- Blue tumor
- Tumor composed of cells with monomorphous, centrally-located, round nuclei (arrows)
- Cells surround vascular spaces

Glomus tumor

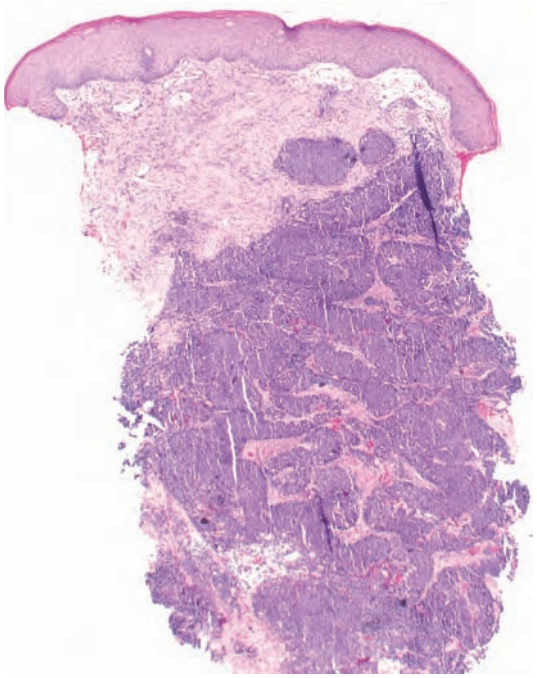

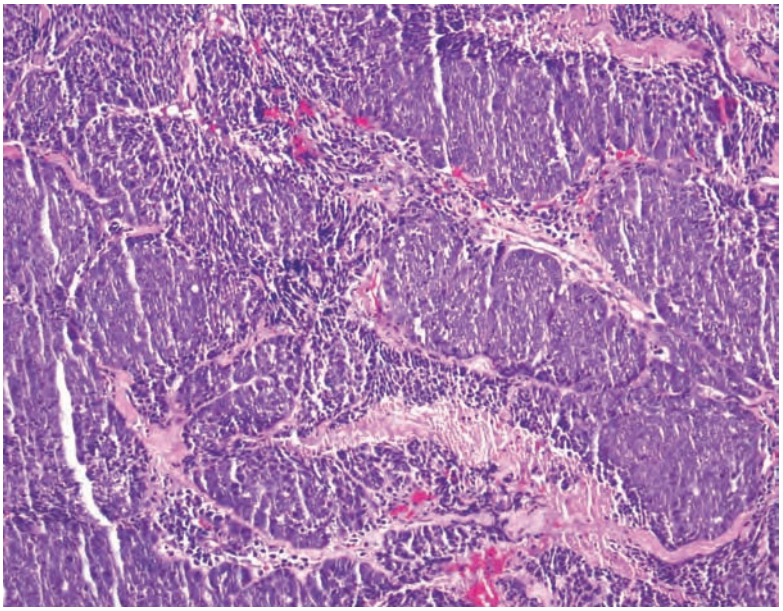

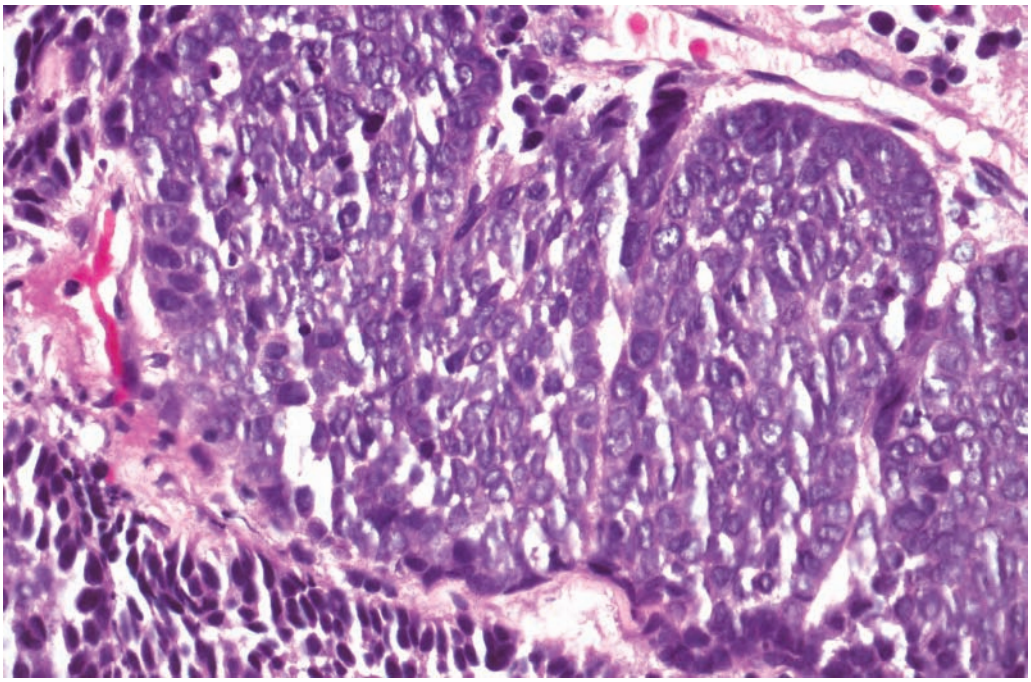

- Blue tumor
- Trabecular or nodular pattern on low power
- Tumor composed of cells with pale nuclei and scant cytoplasm on high power
- Nuclei have a "salt and pepper" look
- Numerous scattered mitoses and necrotic cells
- Cells often overlapping/pushing into each other

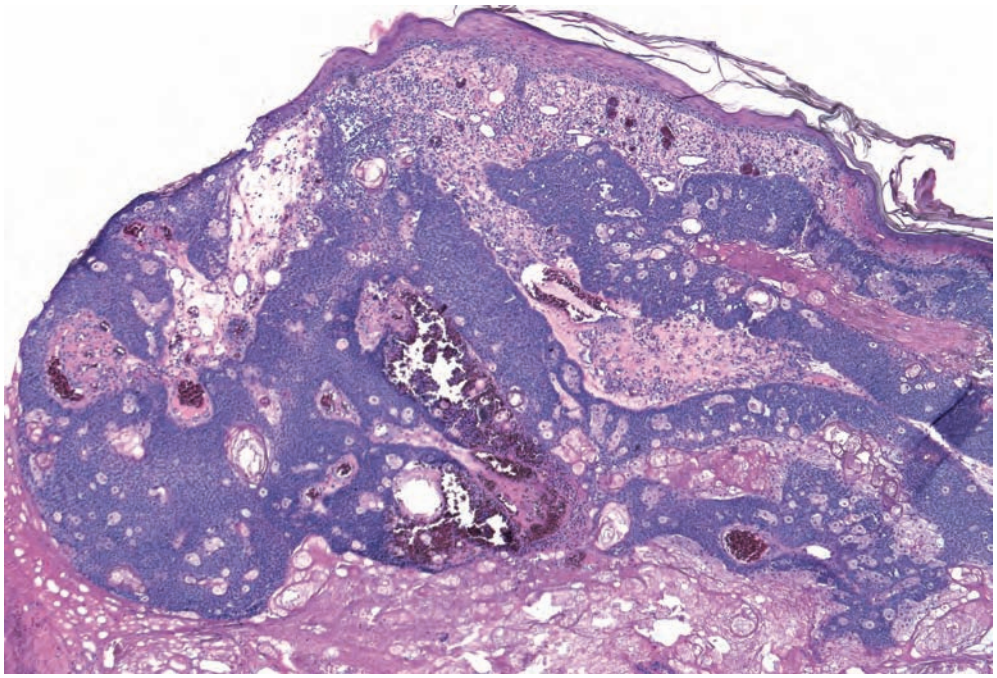

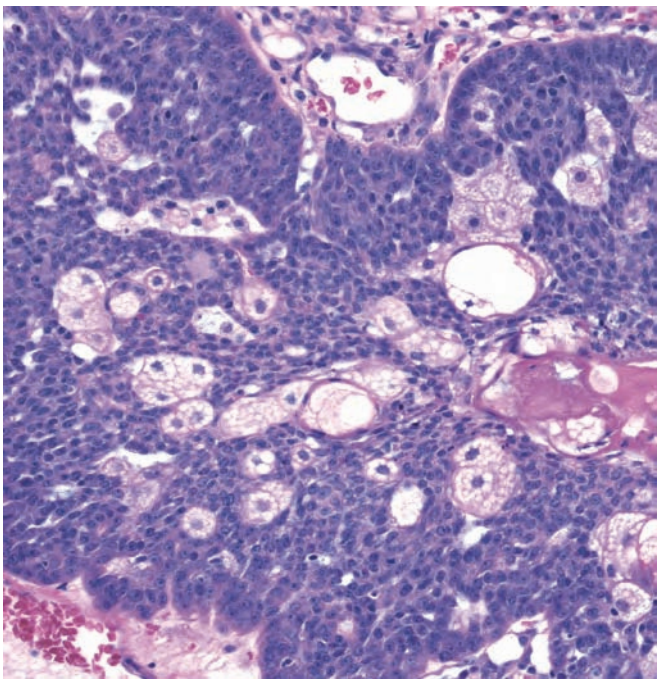

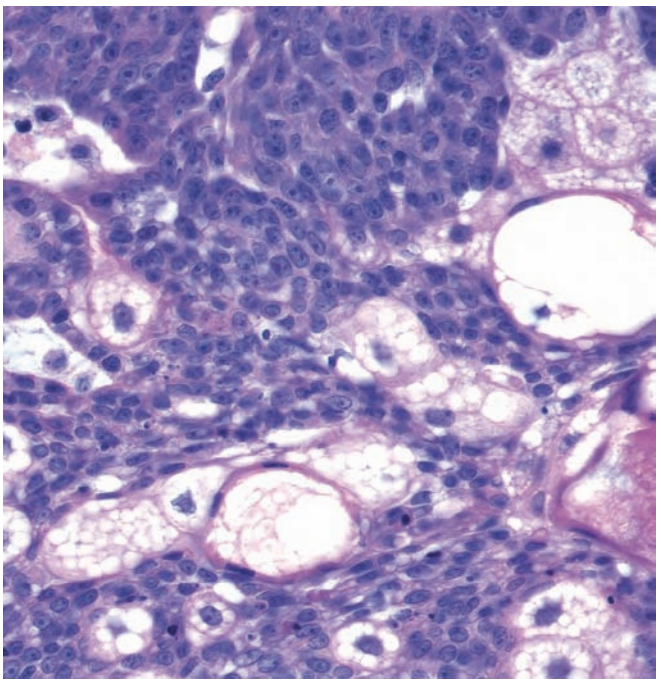

- Blue tumor
- Scattered sebocytes among smaller, blue cells
- Presence of sebaceous ducts
- Tends to be localized to the upper dermis below the epidermis

Sebaceoma (sebaceous epithelioma)

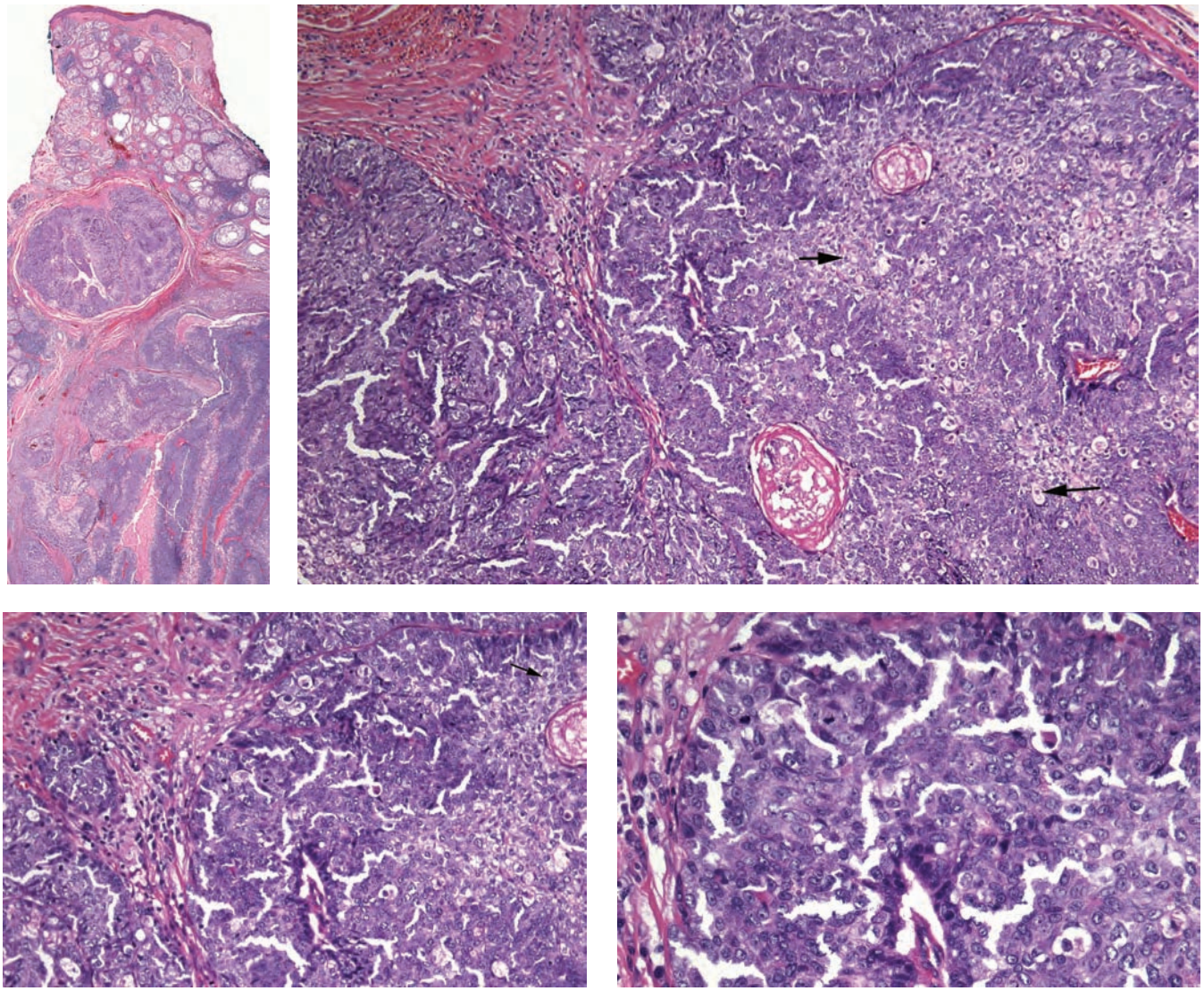

- Blue tumor
- Sebocytes (arrows) among atypical blue cells; sebaceous ducts may be evident
- Necrosis and atypical cells
- Infiltrative pattern and/or situated in reticular dermis/ subcutaneous tissue

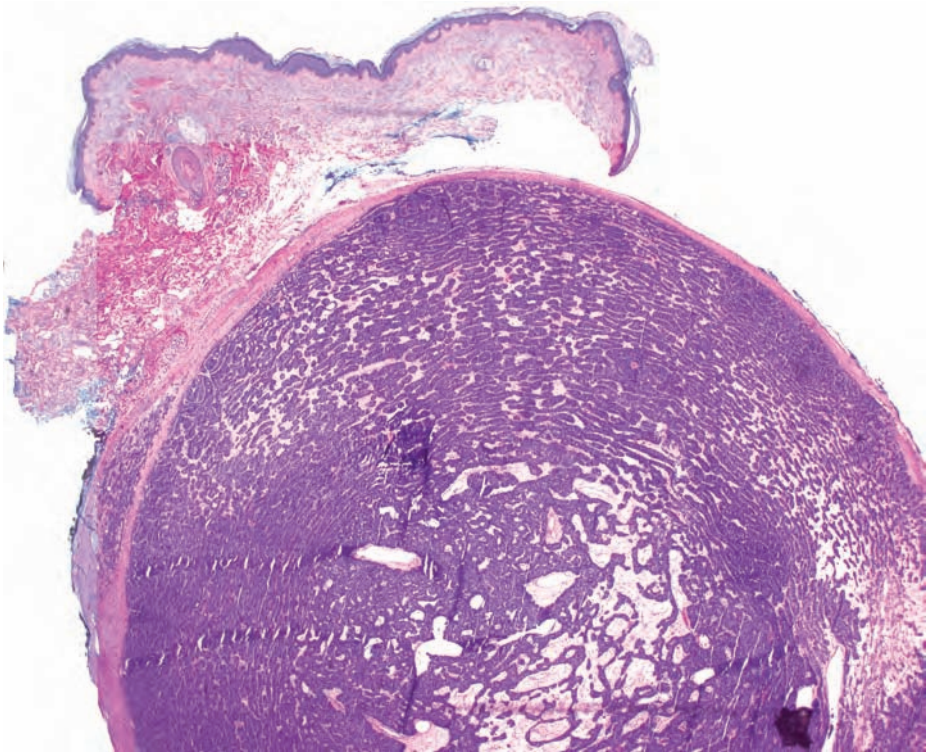

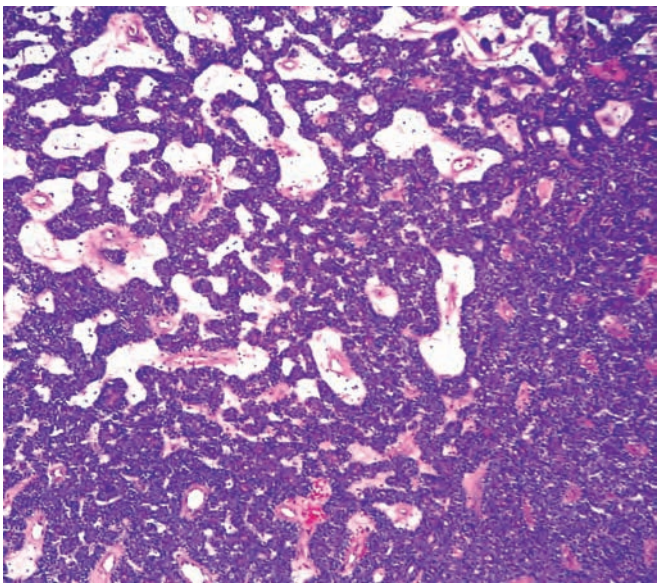

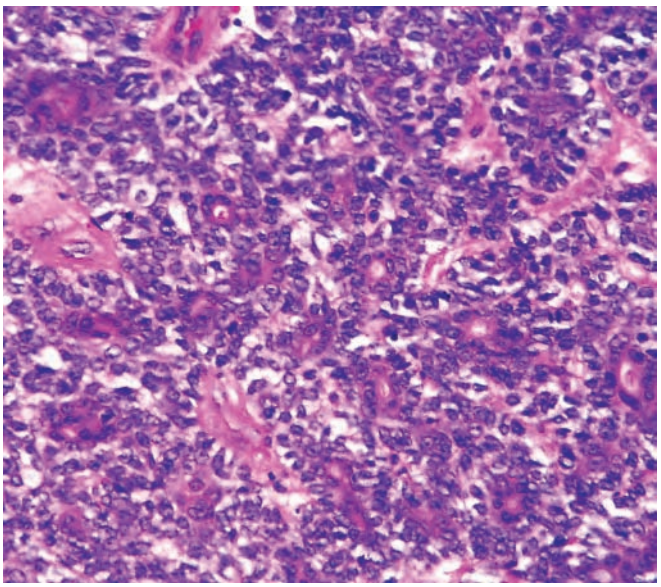

- Blue tumor
- "Blue balls" in the dermis
- Islands of tumor may be peppered by lymphocytes and hyaline pink droplets
- Tumor composed of more peripheral blue cells and more central pale/clear cells that may be arranged in a trabeculated pattern
- Occasional ductal components

Spiradenoma

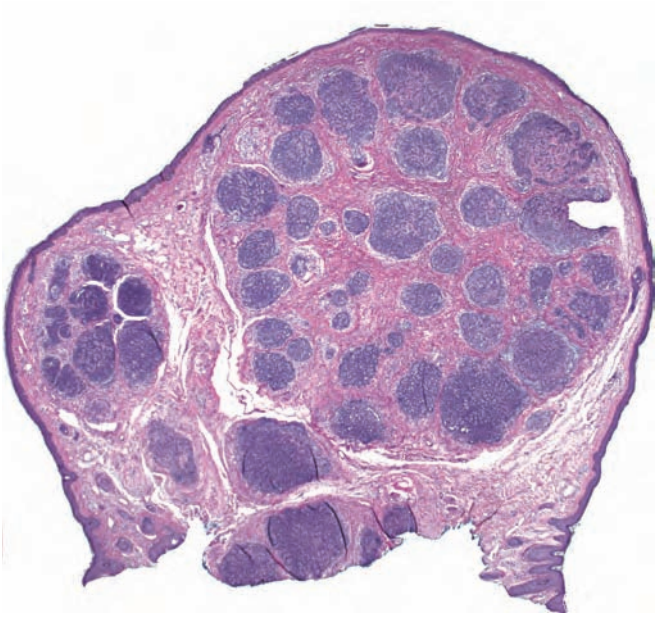

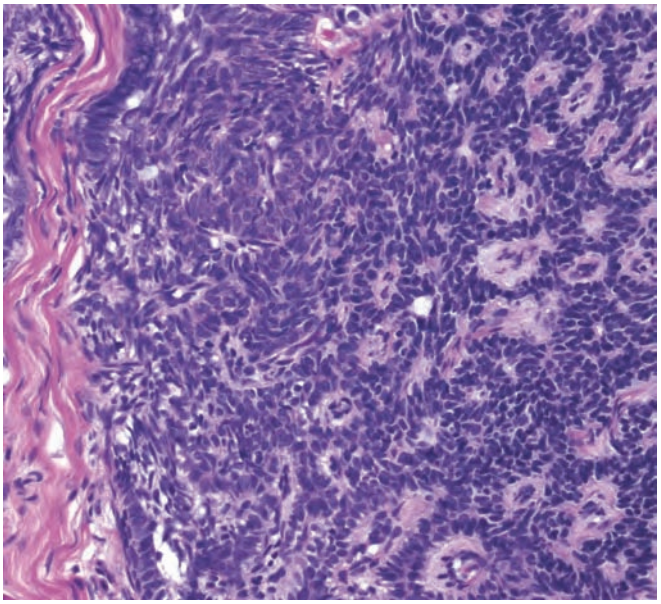

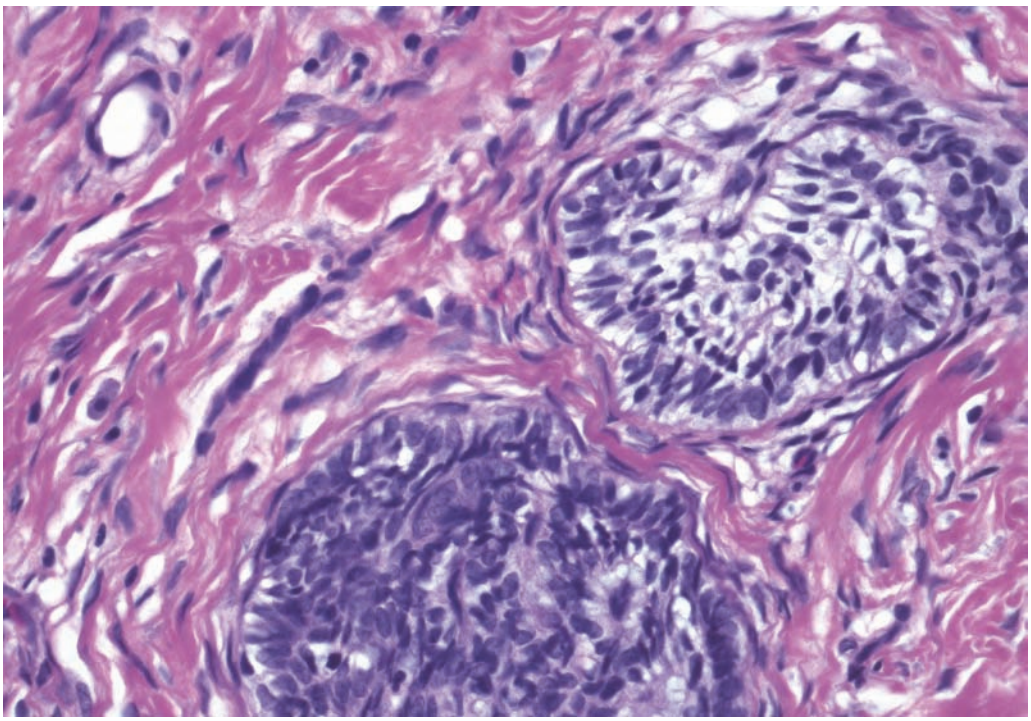

- Blue tumor
- Peripheral palisading
- Generally no epidermal connection
- Well-circumscribed with clefts between the tumor as a whole and the normal dermis
- Less differentiation to basaloid islands compared to trichoepithelioma
- Papillary mesenchymal bodies (small finger-like invagination of dermis pushing into a small basaloid island) may be seen

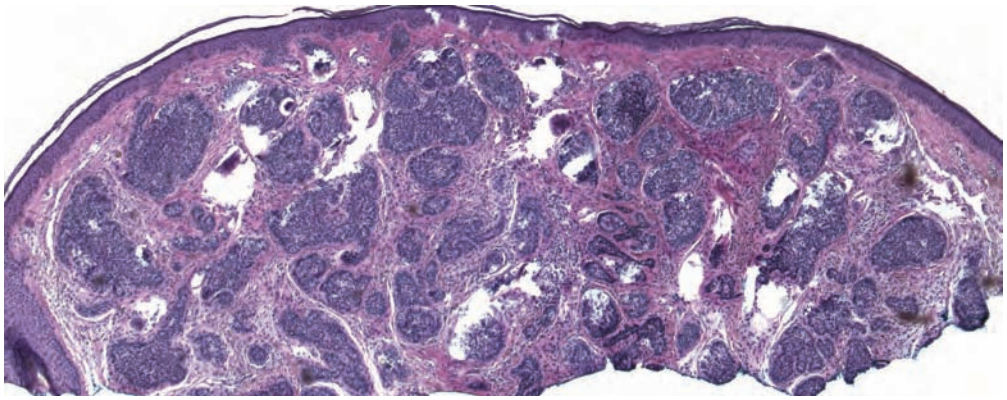

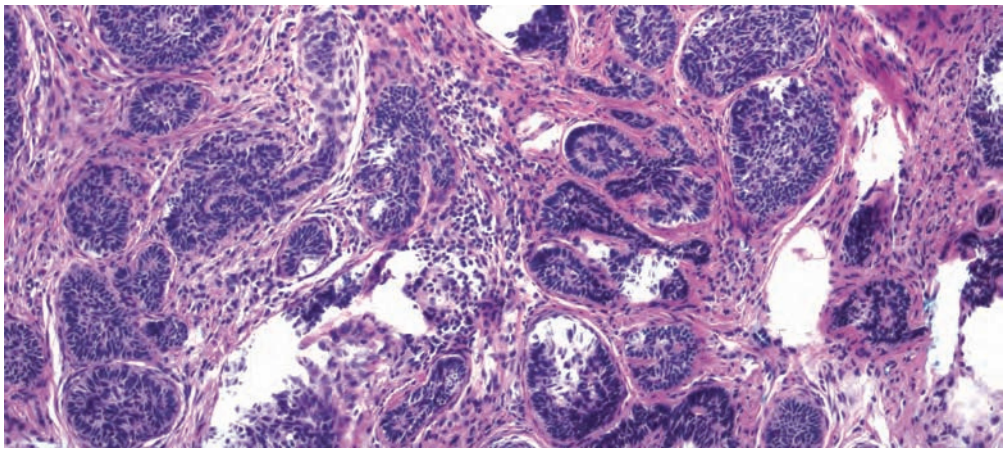

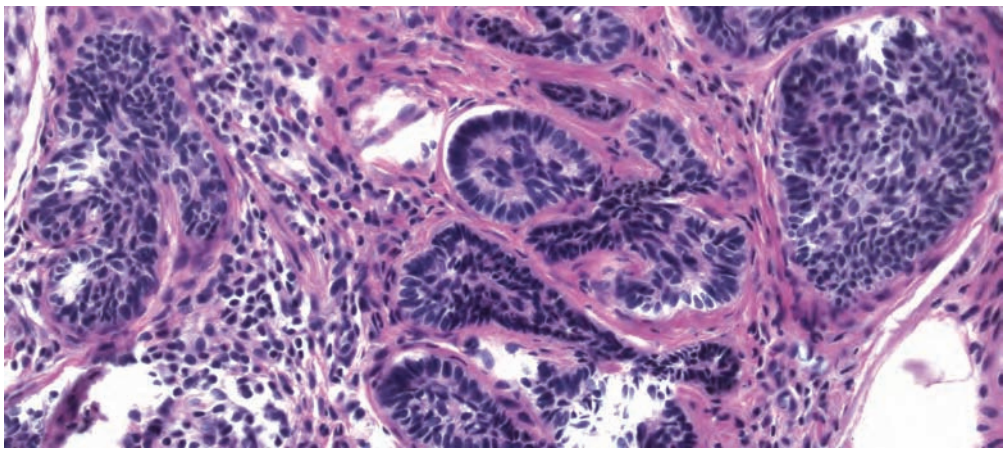

- Blue tumor
- Often an epidermal connection
- Grape-like fronds of cells or reticulated islands of basaloid cells with peripheral palisading
- Fibrotic stroma
- Clefting between the fibrotic stroma and bordering normal dermis
- Papillary mesenchymal bodies may be seen

Trichoepithelioma

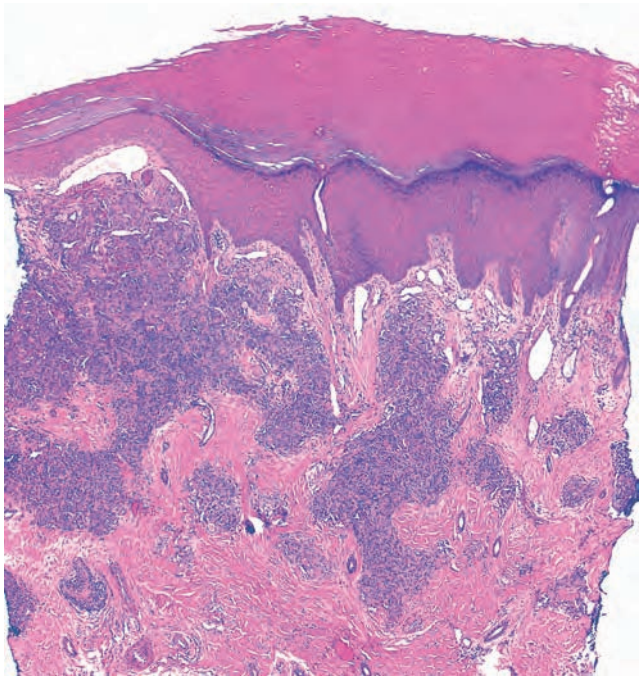

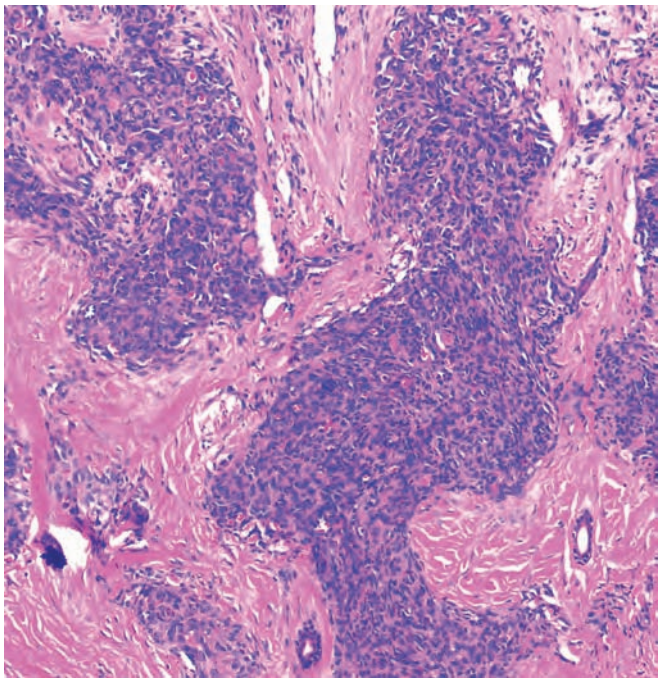

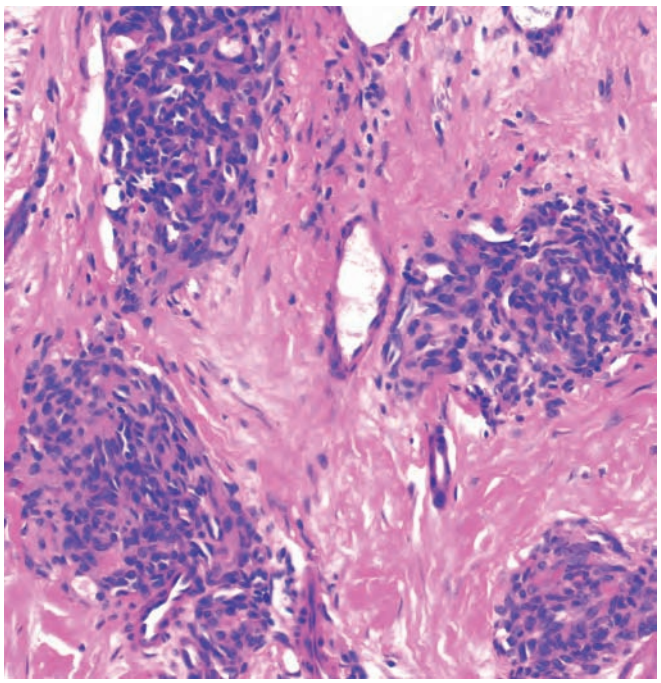

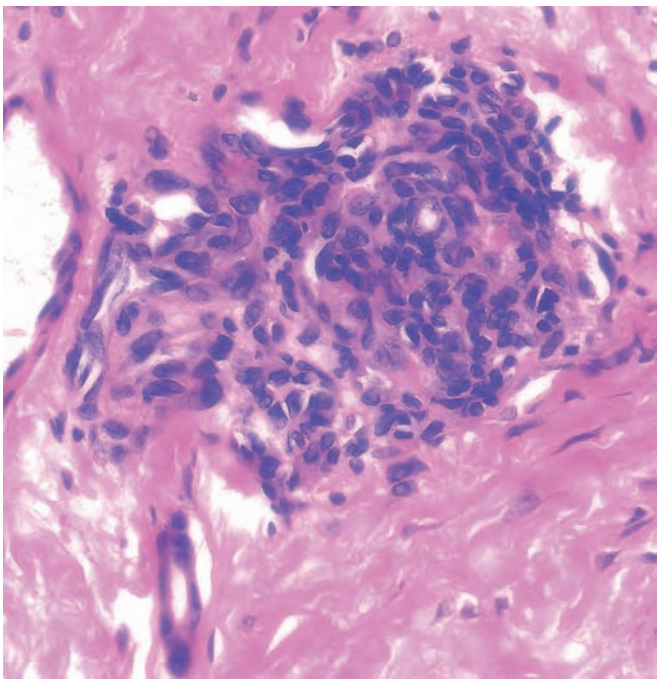

- Blue tumor
- Groups of cells in dermis (cannon balls) forming small vascular spaces with erythrocytes
- Clefts (lymphatic space) may be seen around the groups of cells
- May resemble Kaposiform hemangioendothelioma (usually a deeper, larger tumor)

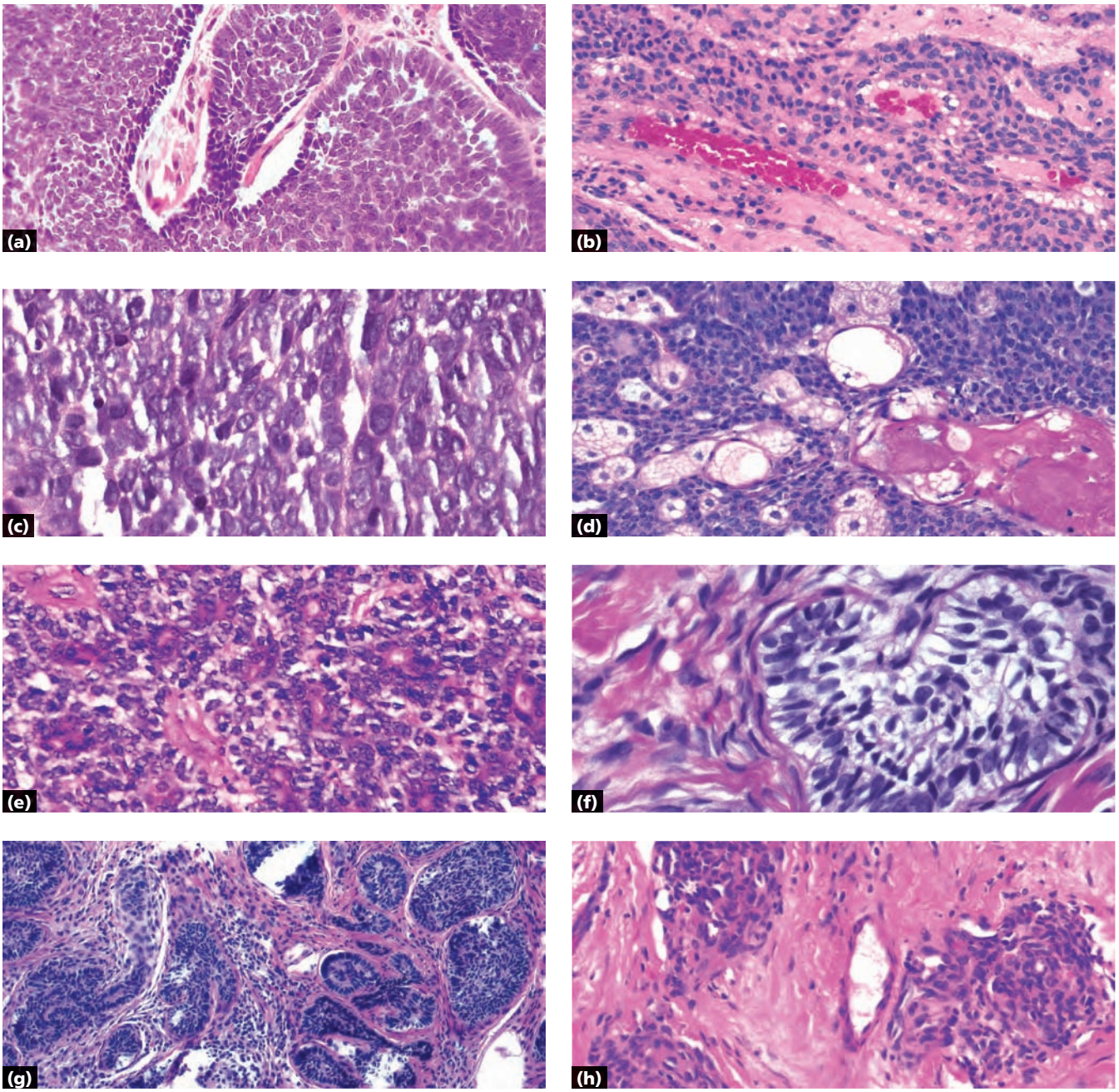

a Basal cell carcinoma: peripheral palisading, clefts between blue islands and stroma
b Glomus tumor: round monomorphous cells
c Merkel cell carcinoma: pale salt and pepper nuclei
d Sebaceoma (sebaceous epithelioma): blue cells with occasional interspersed sebocytes
e Spiradenoma: two cell types – pale and blue
f Trichoblastoma: peripheral palisading, papillary mesenchymal bodies
g Trichoepithelioma: grape-like fronds of cells with peripheral palisading, fibrotic stroma
h Tufted angioma: "Cannonballs" of blue cells forming vascular spaces

Note Some pathologists consider trichoepithelioma to be a variant of trichoblastoma.

Key differences

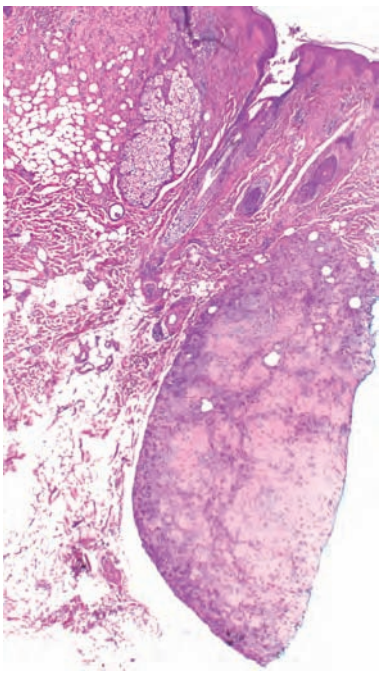

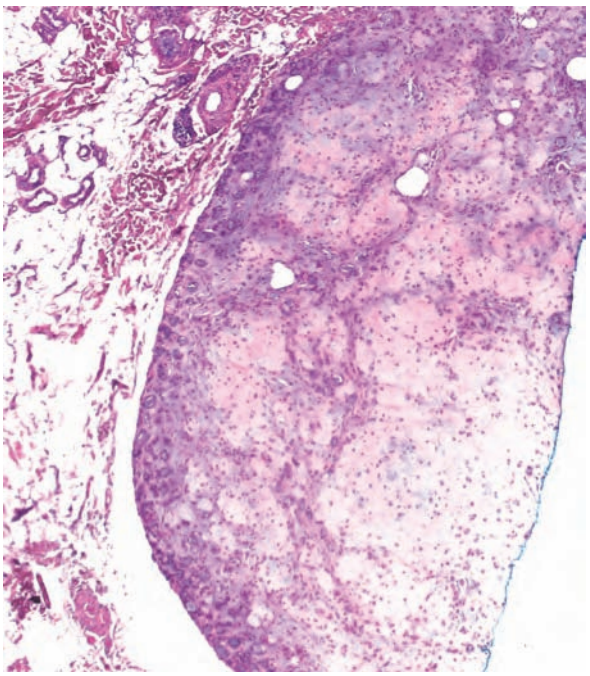

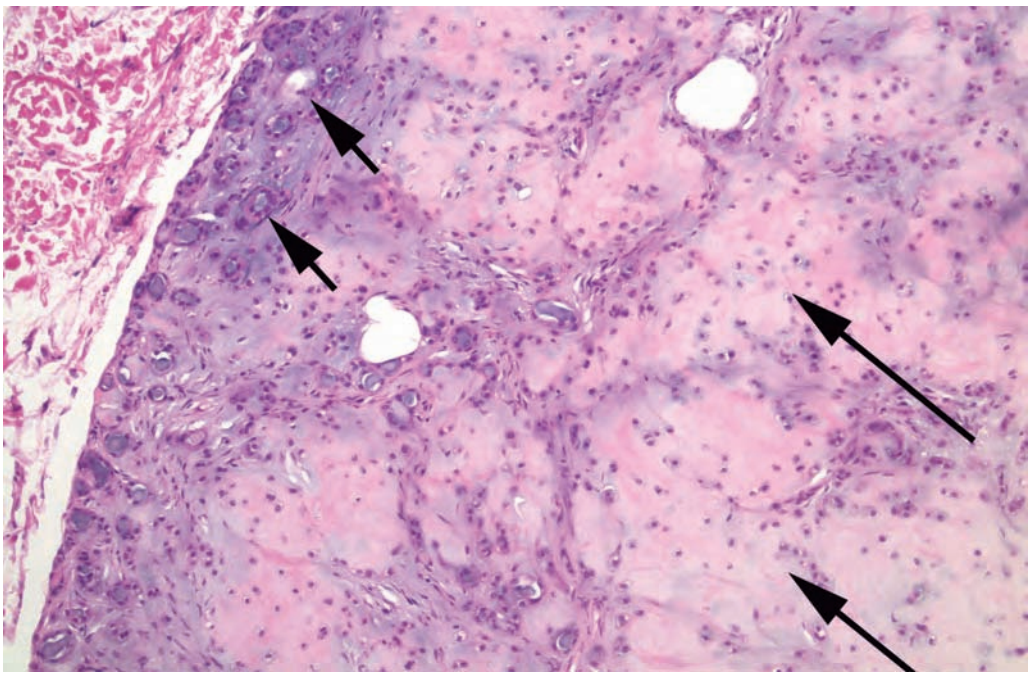

- Bluish-pink chondroid areas (long arrows) and duct-like spaces (short arrows)
- Well-circumscribed

Chondroid syringoma (mixed tumor of skin)

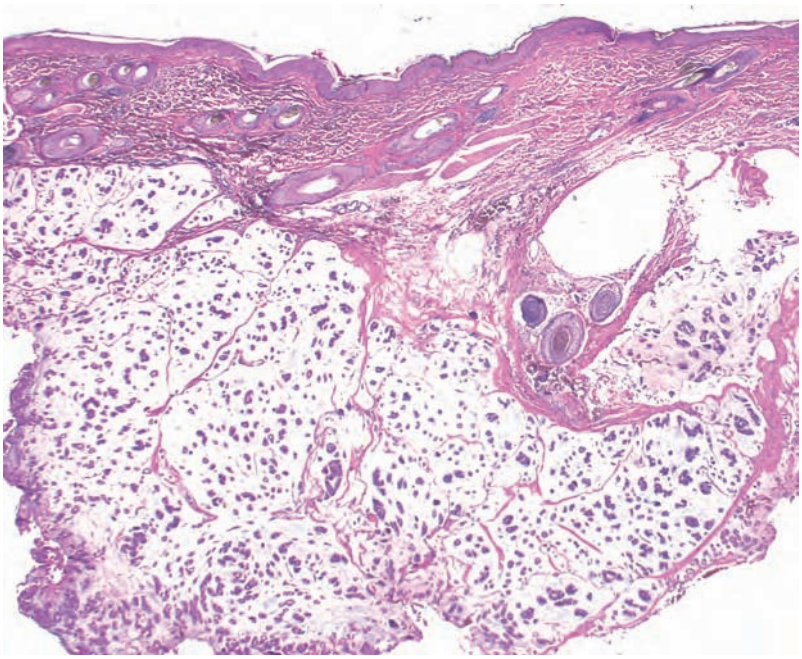

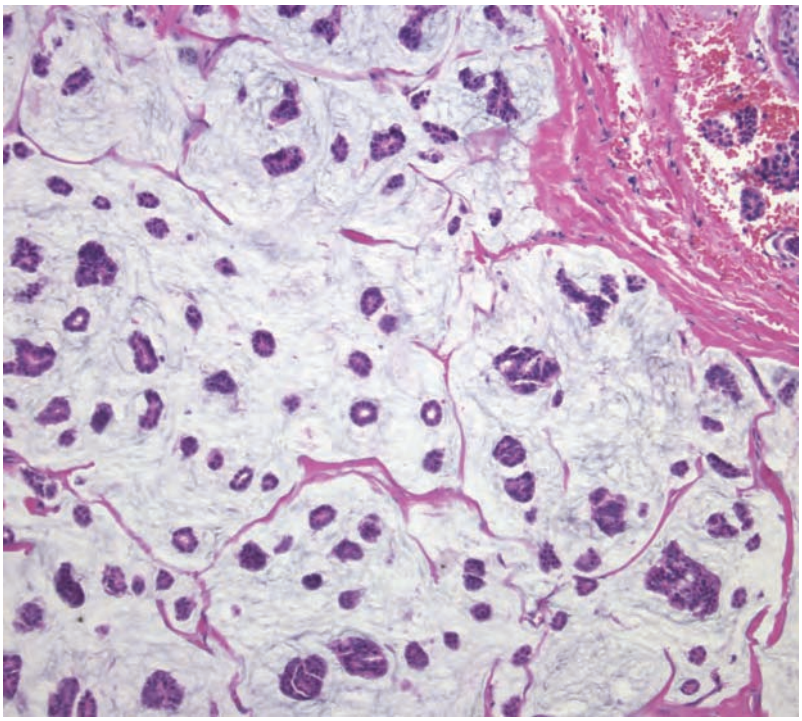

- Mucin in pools
- In center of pools, there are epithelial islands with variable ductal differentiation

Mucinous carcinoma

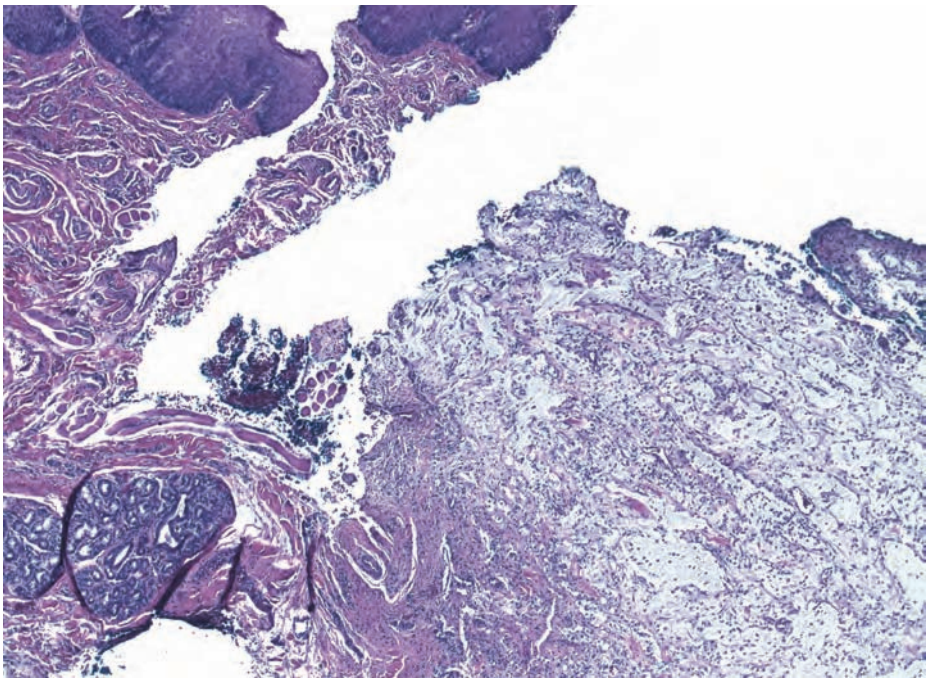

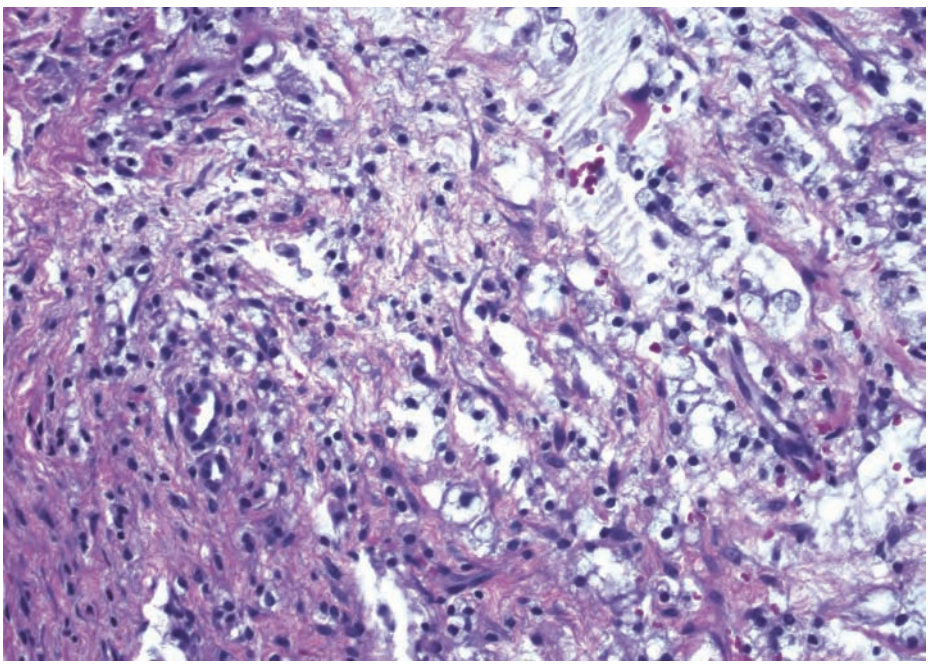

- Mucin
- Mucin often surrounded by giant cells
- May see mucosal epithelium and/or minor salivary glands

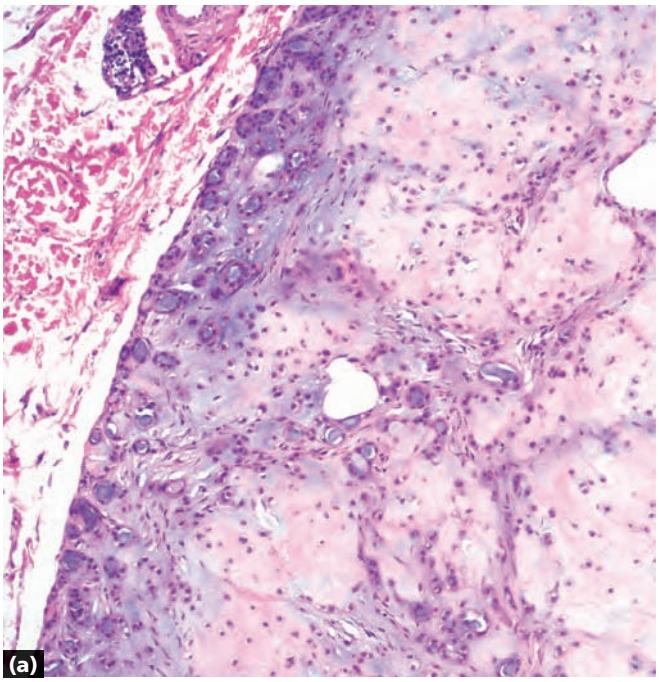

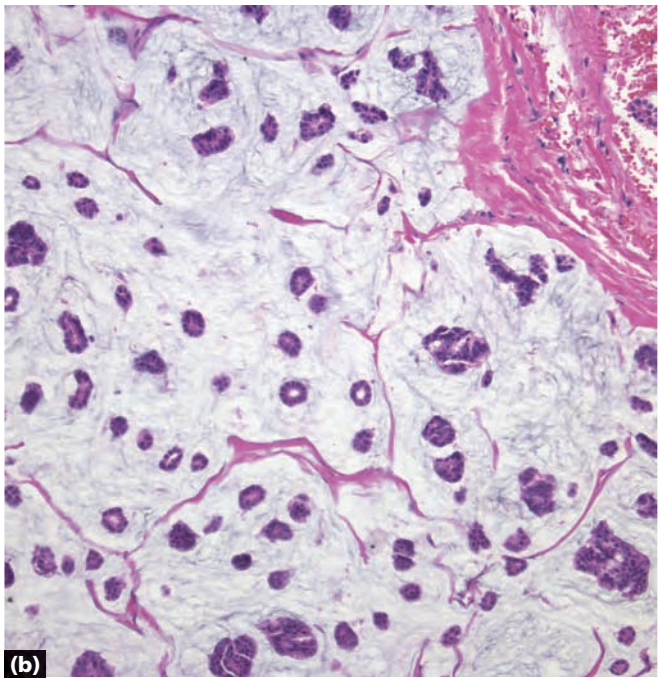

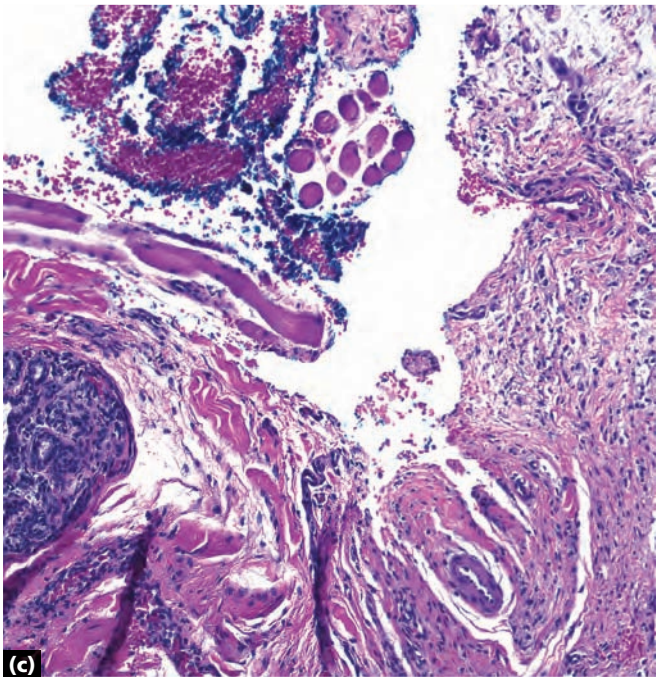

a Chondroid syringoma: well-circumscribed blue-pink cartilaginous area containing duct-like spaces
b Mucinous carcinoma: pools of mucin containing epithelial islands
c Mucocele: pool of mucin with surrounding fibrosis/inflammation; adjacent salivary glands

Key differences

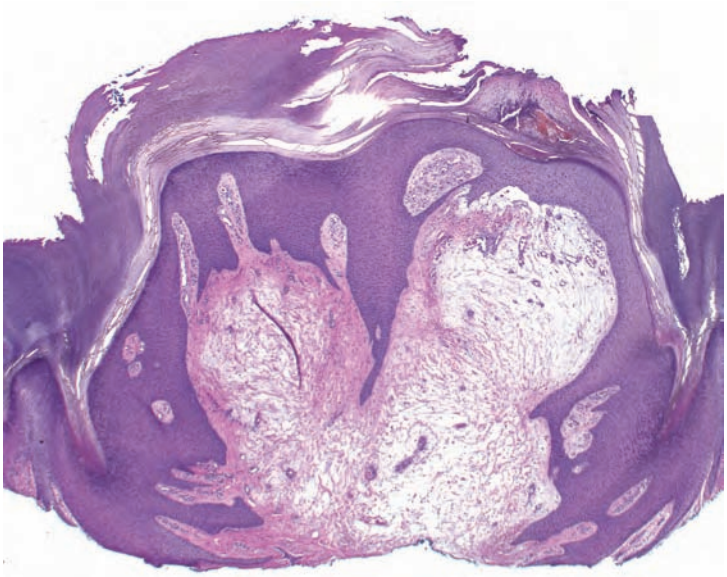

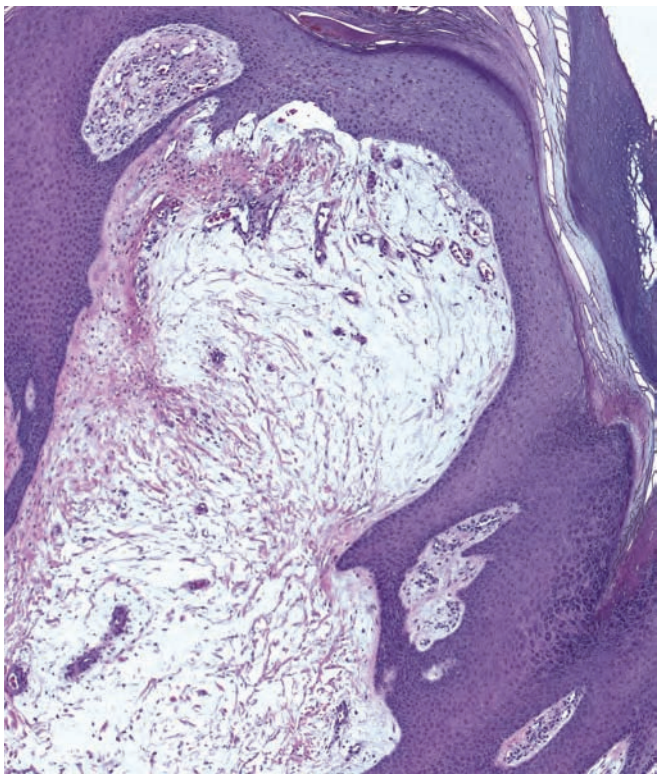

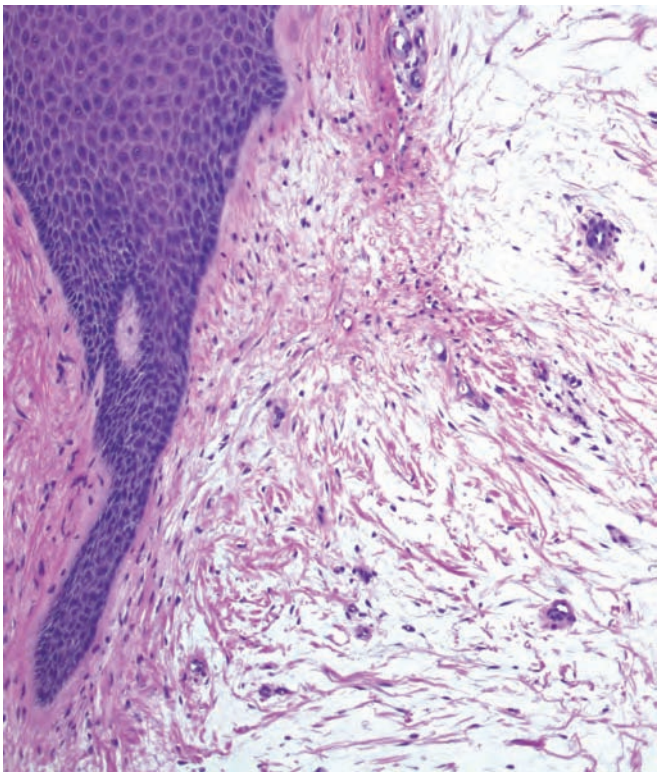

- Well-circumscribed mucin (blue, lacy appearance)
- Acral skin
- Not a true cyst (no epithelial lining)

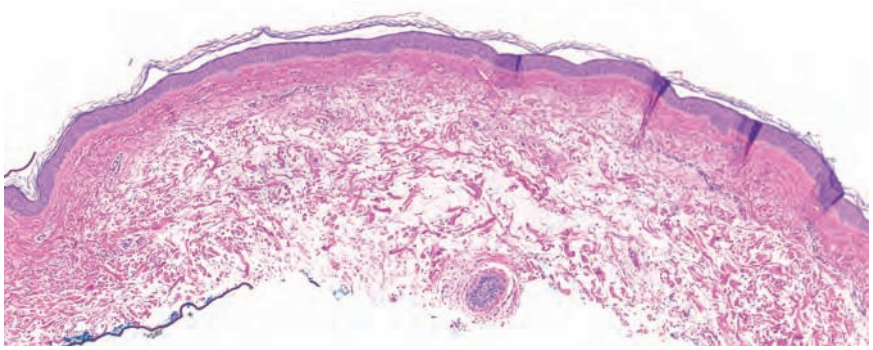

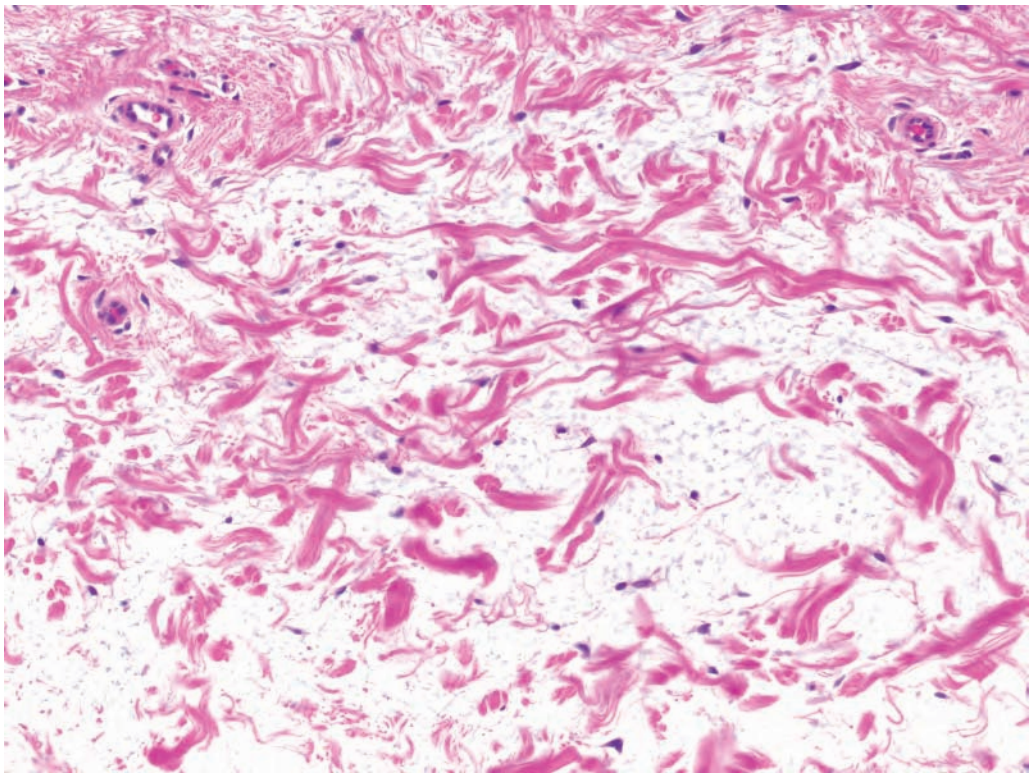

- Well-circumscribed mucin and stellate fibroblasts
- Non-acral location

Focal cutaneous mucinosis

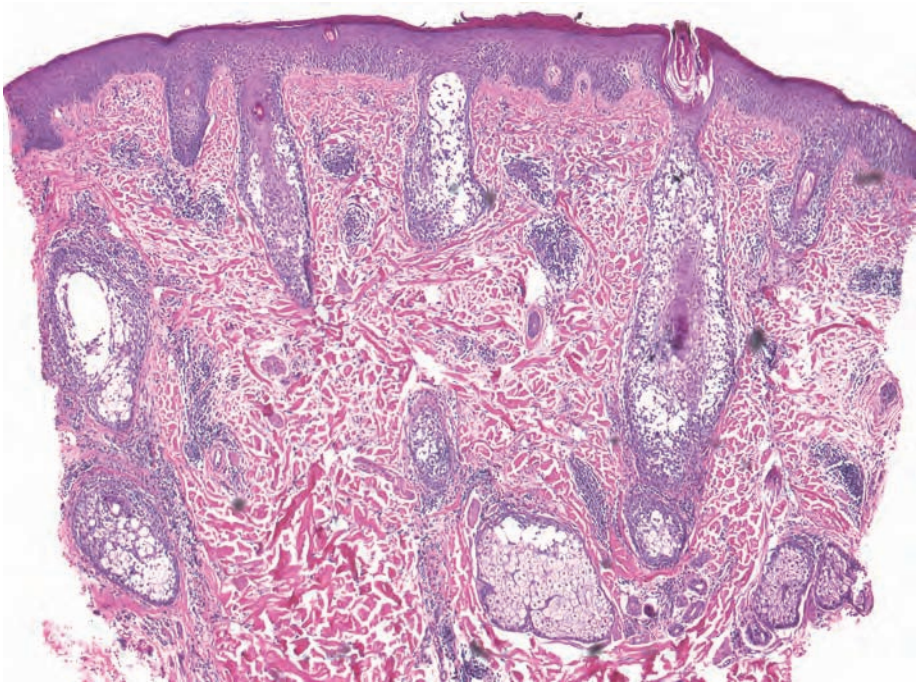

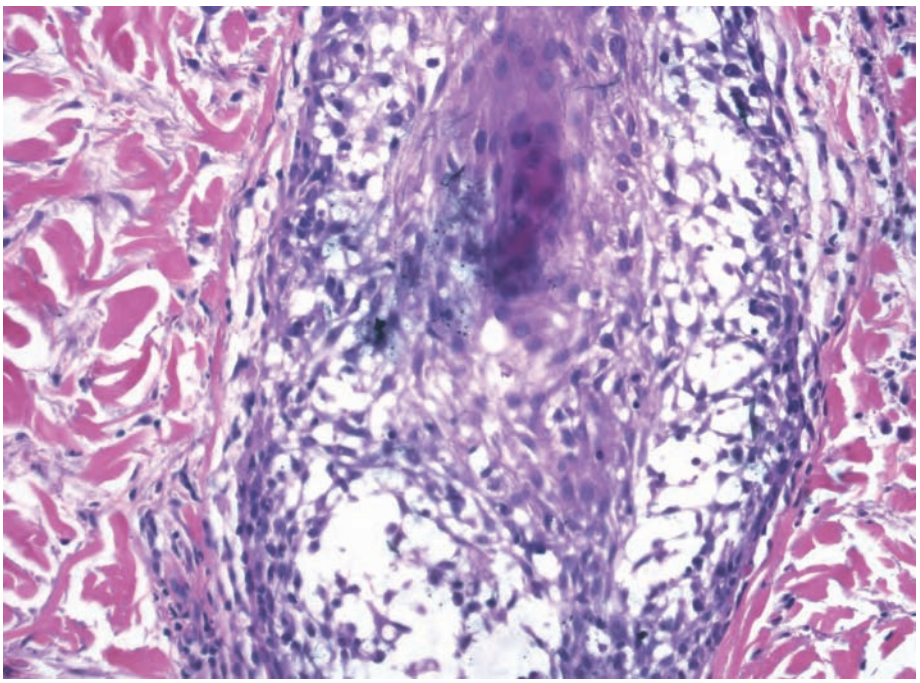

- Mucin within a distorted hair follicle

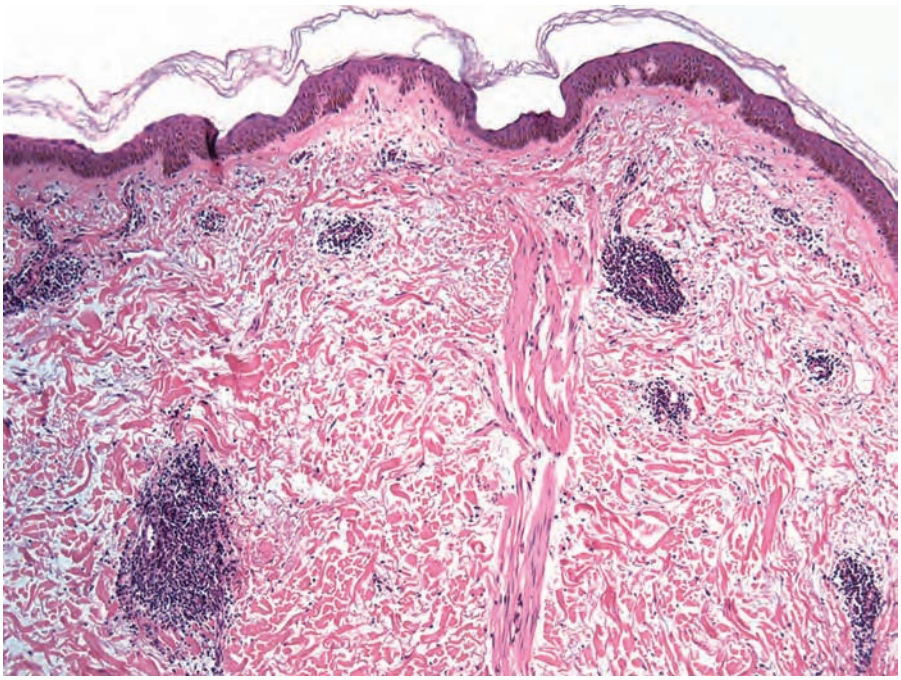

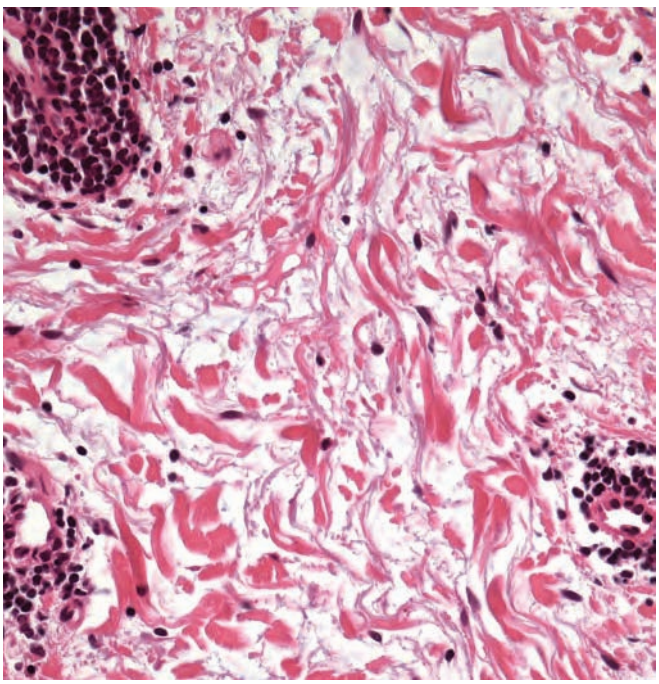

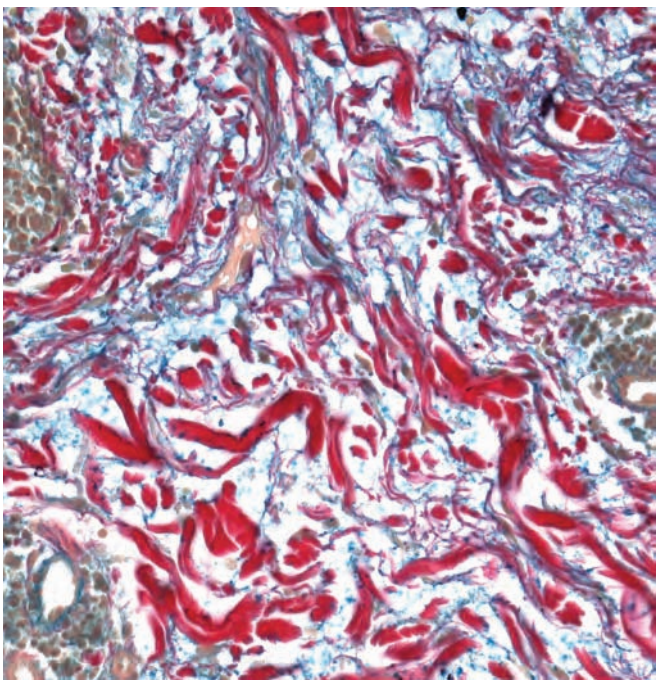

- Mucin between collagen bundles
- Perivascular lymphocytes
- Mucin can be highlighted by colloidal iron (or other mucin stains) as in the bottom right image

Source: Case courtesy of Whitney High, MD, JD.

Lupus tumidus

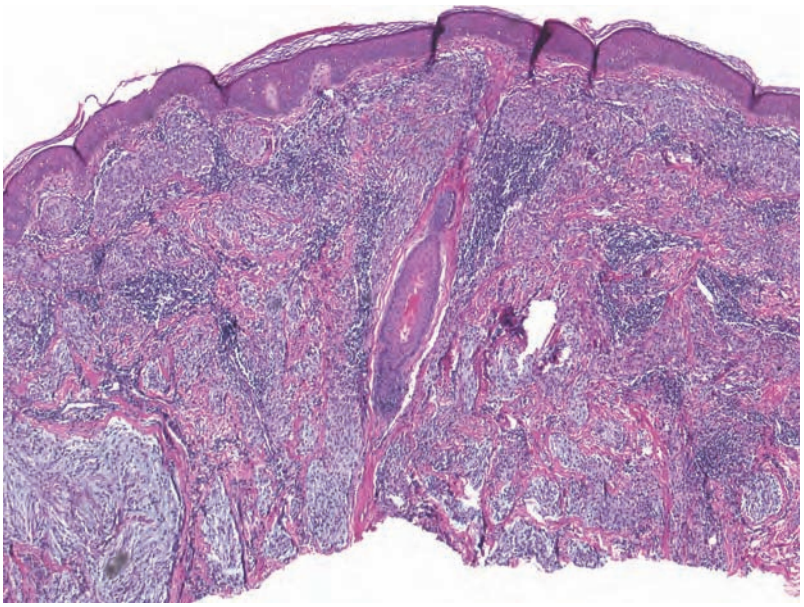

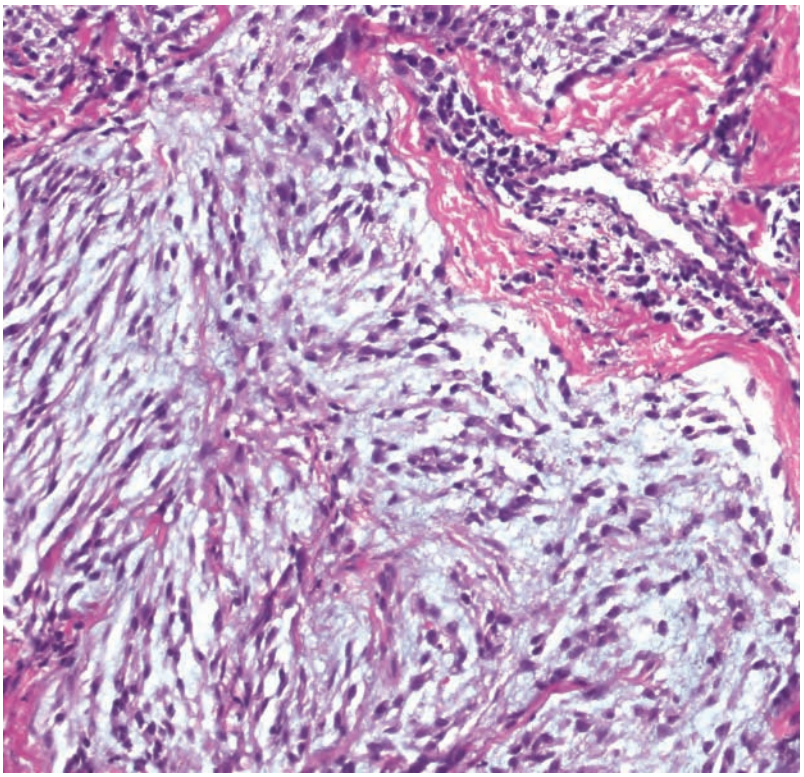

- Variable mucin in nodular collections with spindle cells
- Nodules separated by fibrosis

Note Lesions with abundant mucin are probably best-termed nerve sheath myxomas.

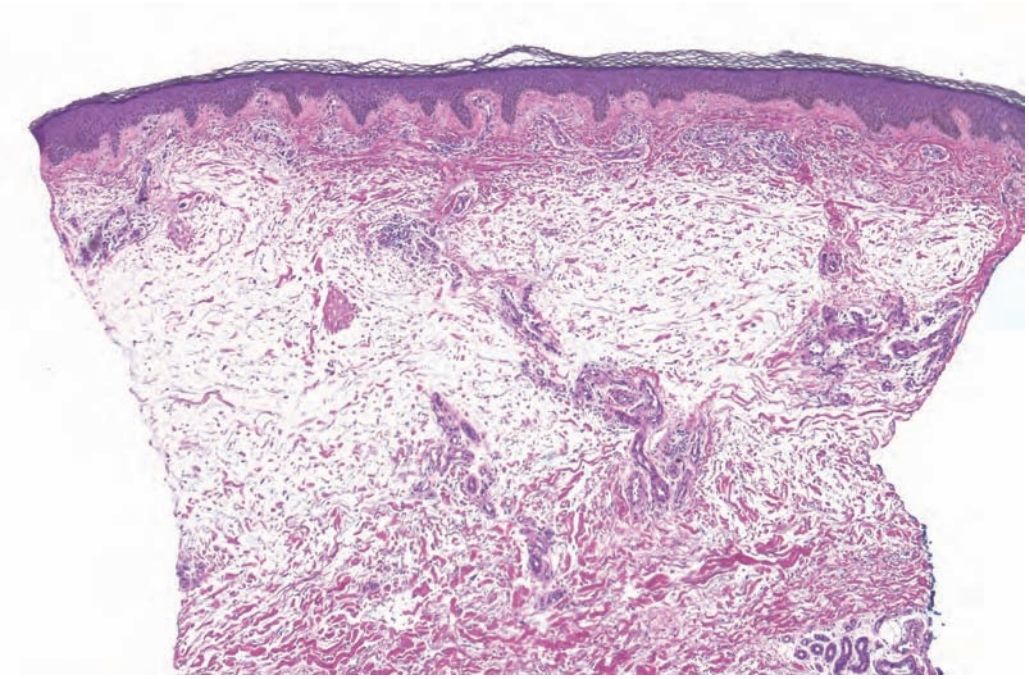

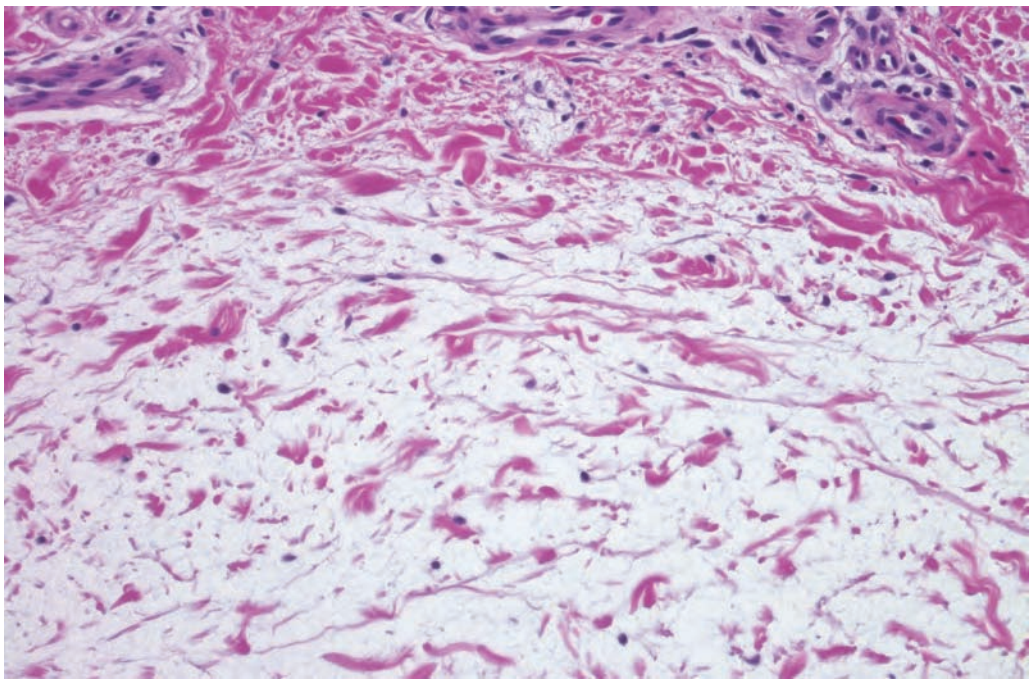

- Mucin filling the dermis (spares papillary dermis)

Pretibial myxedema

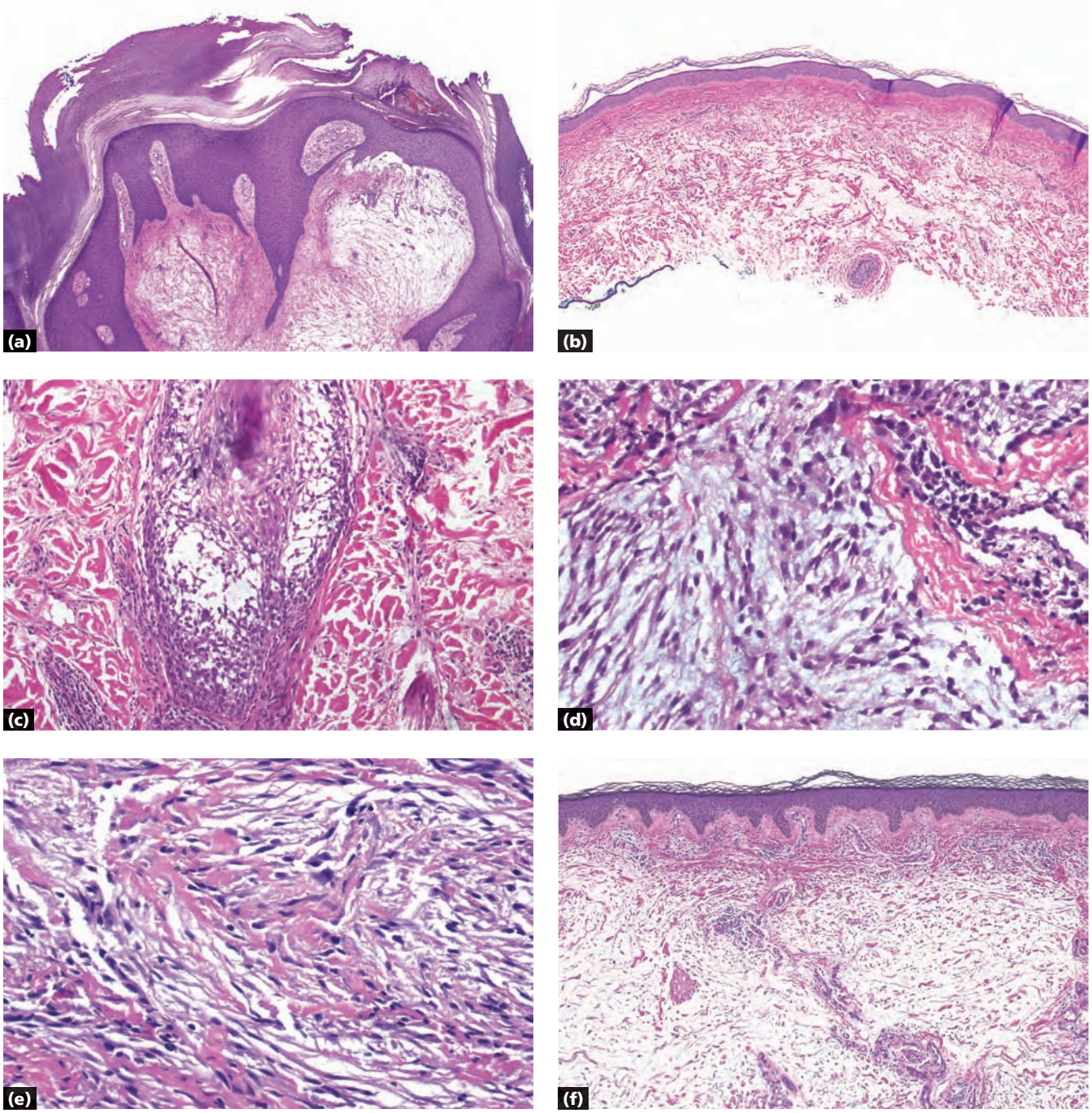

a Digital mucous cyst: acral location
b Focal cutaneous mucinosis: non-acral location
c Follicular mucinosis: mucin within follicle
d Neurothekeoma: nodules of spindle or epithelioid cells in variable myxoid background
e Nodular fasciitis: elongated "tissue culture" cells in myxoid background (see page 170)
f Pretibial myxedema: mucin filling reticular dermis

6 Color – Pink

- Pink ball of spindle cells, 305
- Pink material, 308
- Pink dermis, 315
- Epidermal necrosis, 317

Dermatopathology: Diagnosis by First Impression, Third Edition. By Christine J. Ko and Ronald J. Barr.
© 2017 John Wiley & Sons, Ltd. Published 2017 by John Wiley & Sons, Ltd.
Companion website: www.wiley.com/go/ko/dermatopathology3e

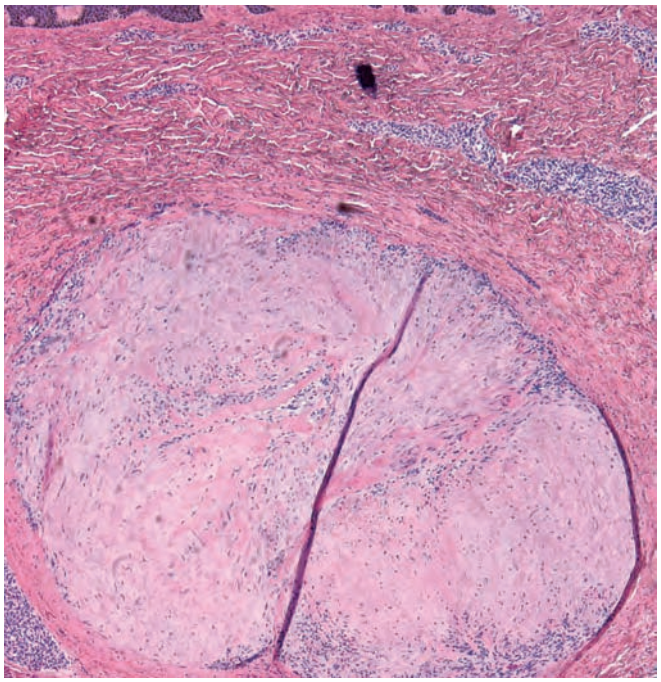

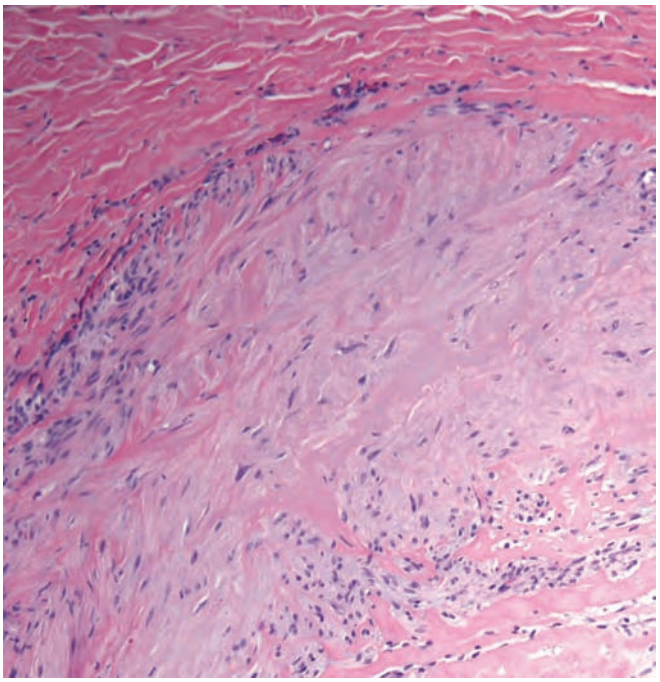

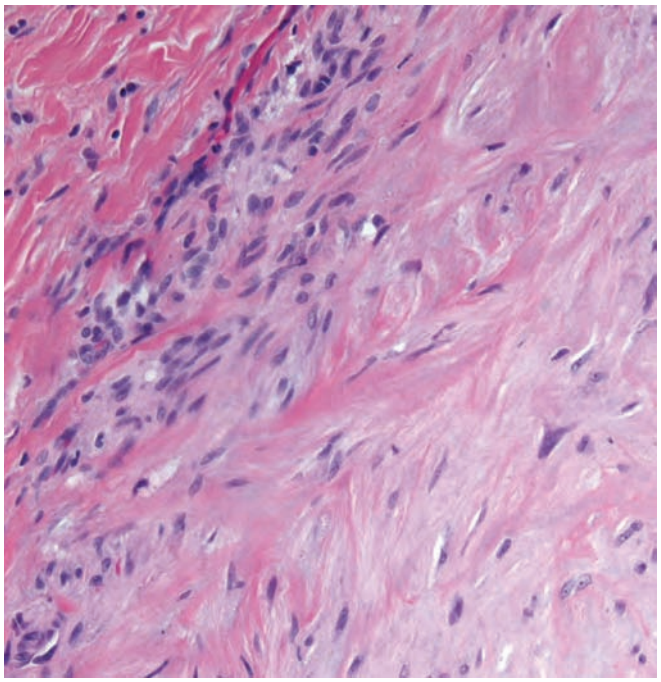

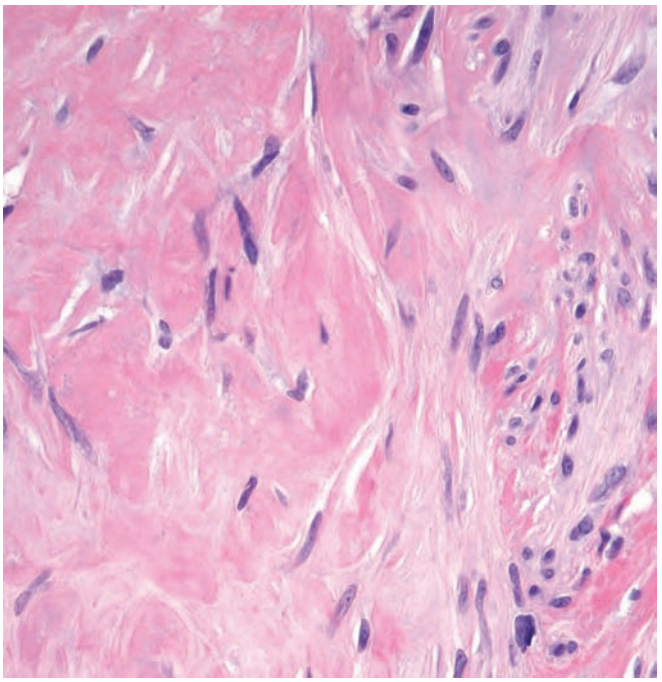

- Pink ball of spindle cells (myofibroblasts)
- Some nuclei resemble those of smooth muscle cells with some cigar shapes
- Some nuclei resemble those of fibroblasts, with closely associated pink collagen
- Increased vessels, often particularly at the periphery of the pink ball

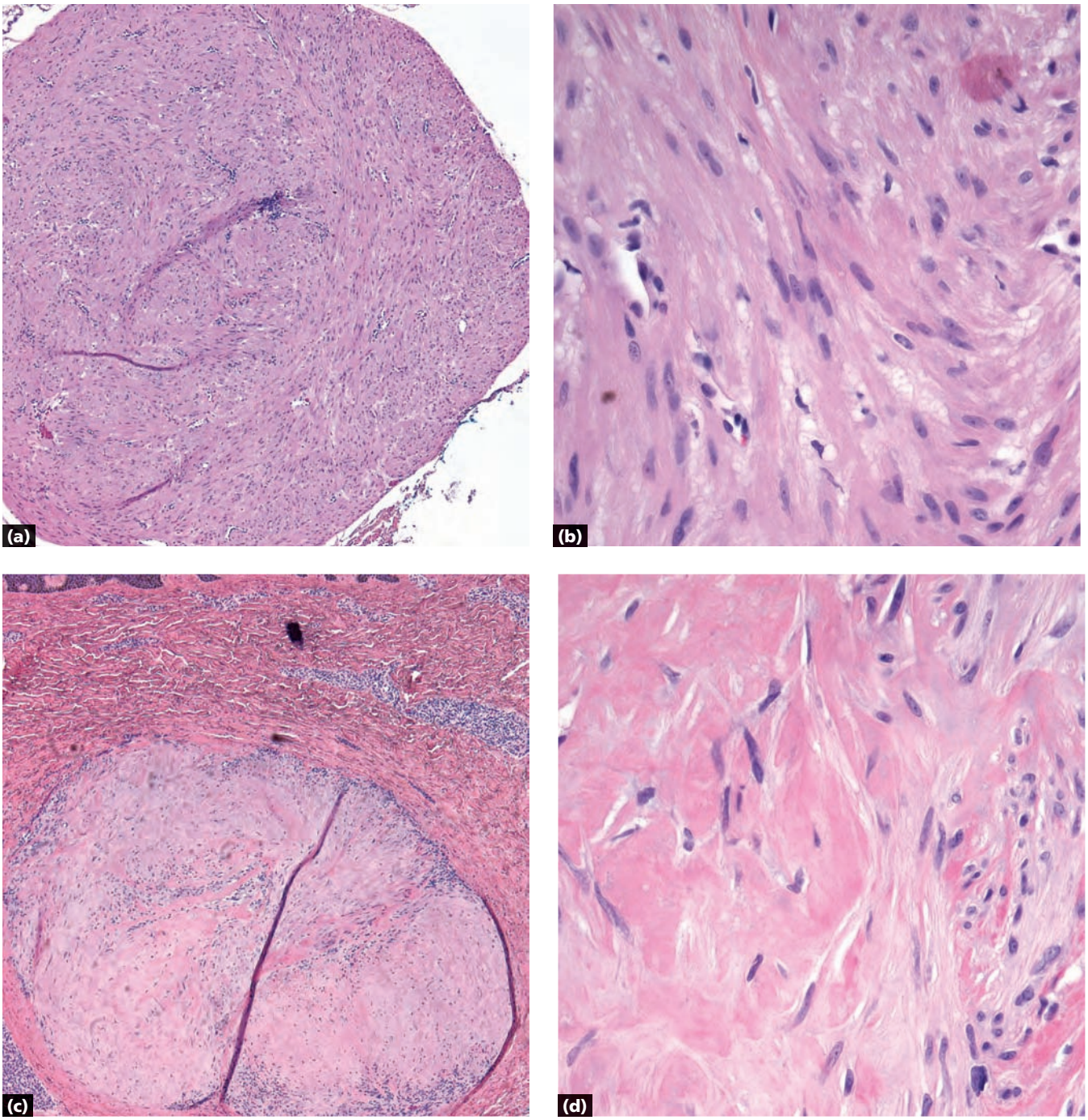

a, b Angioleiomyoma: smooth muscle cells with abundant cytoplasm, perinuclear vacuole, interspersed vessels (see page 178)

c, d Myofibroma: cells resemble both fibroblasts and smooth muscle cells, peripheral vessels

Key differences

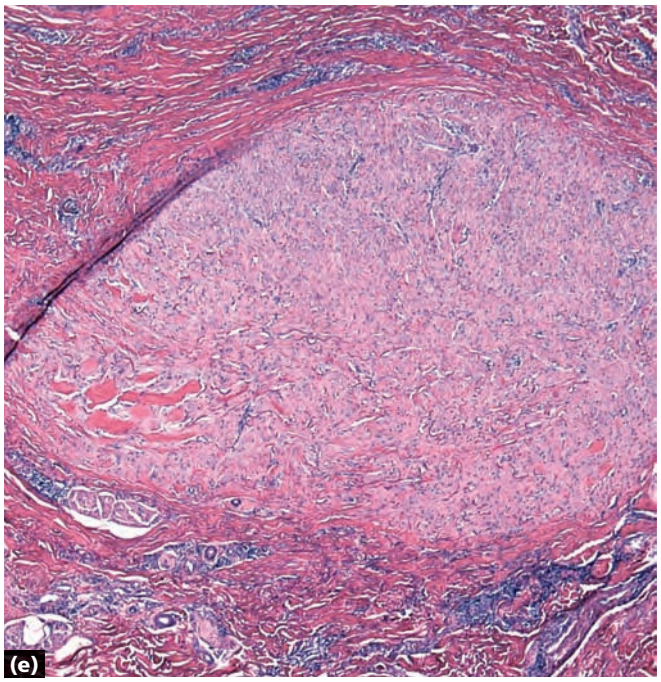

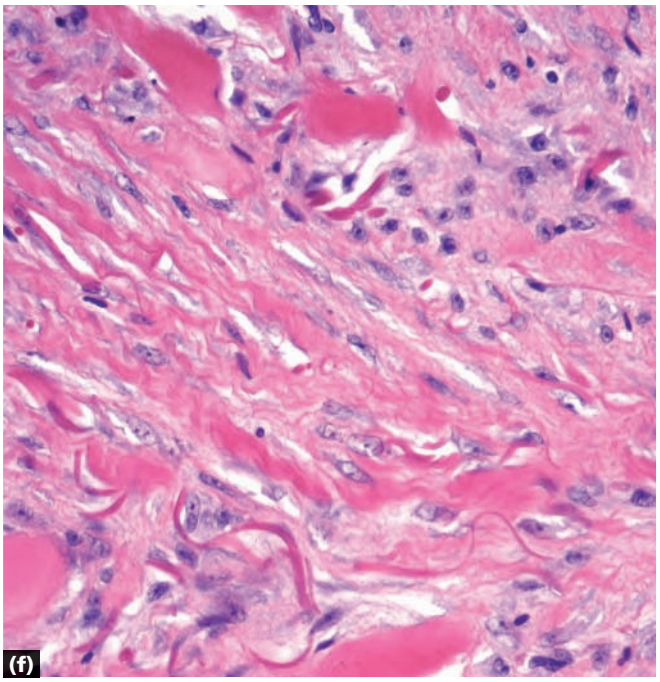

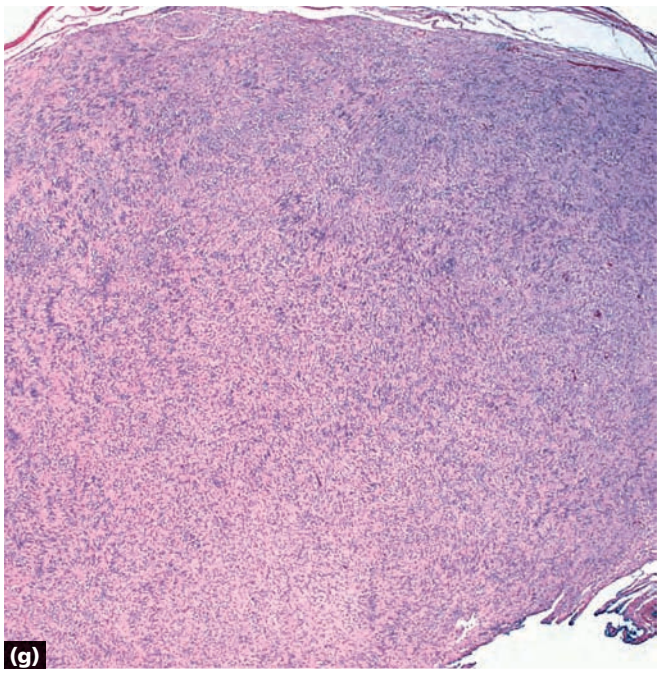

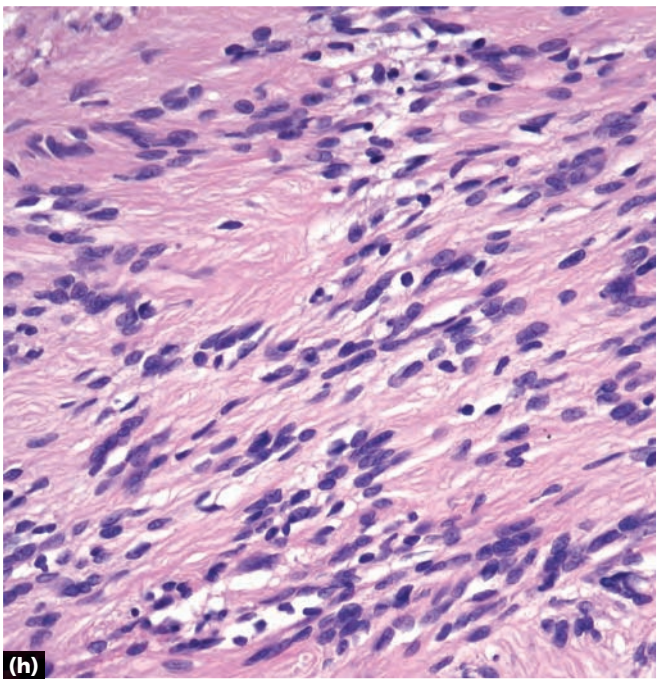

e, f Scar, hypertrophic: can sometimes form a "pink ball"; fibroblasts with closely associated collagen that may be keloidal

g, h Schwannoma (neurilemmoma): encapsulated pink ball; cells are skinny and tapered; Verocay bodies and myxoid areas may be evident (see page 174)

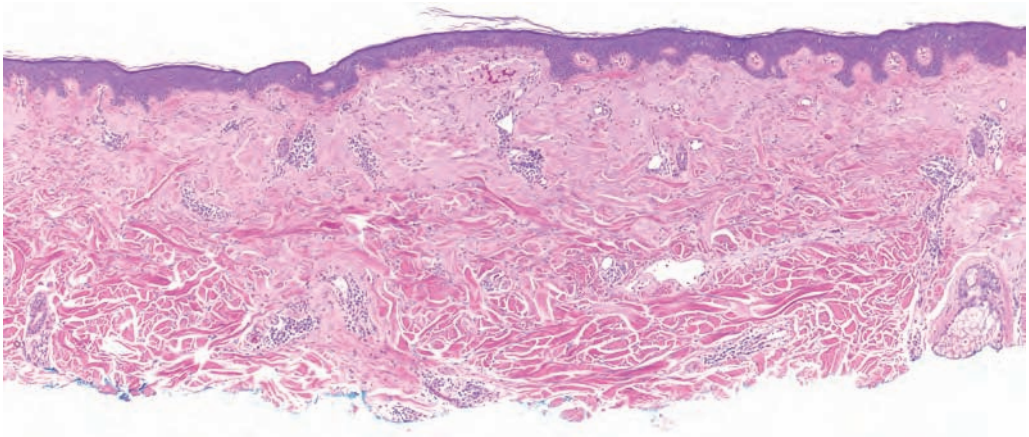

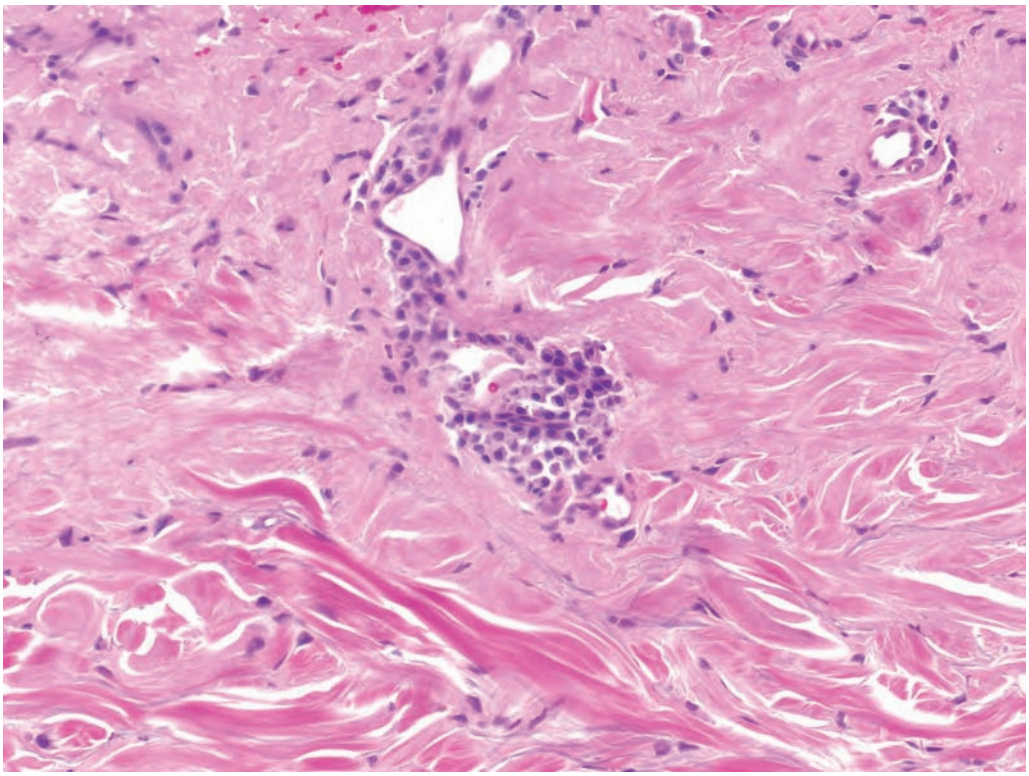

- Amorphous pink material in upper dermis
- Plasma cells

Amyloid

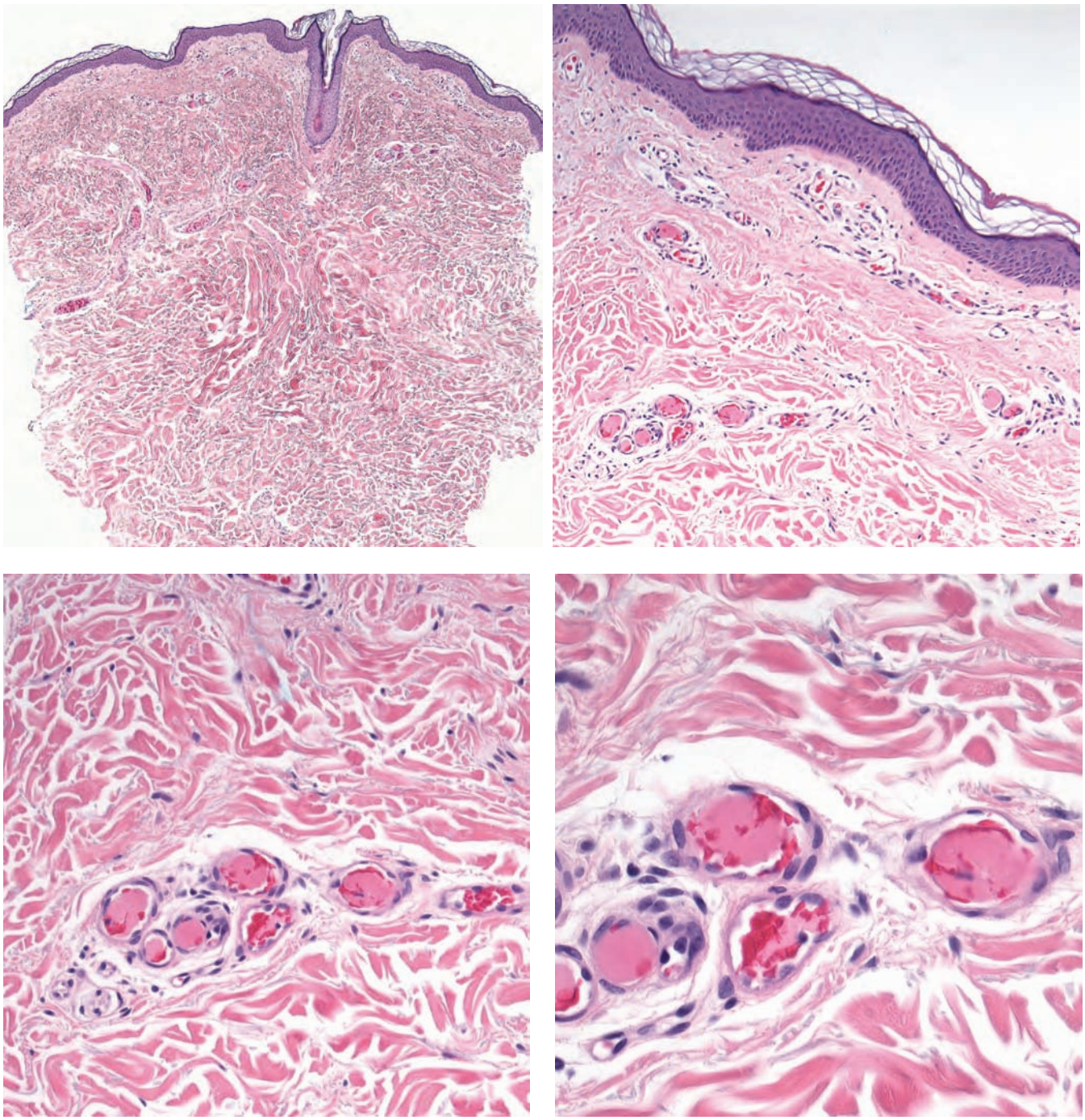

- Glassy, smooth pink material within vessels
- Minimal inflammation

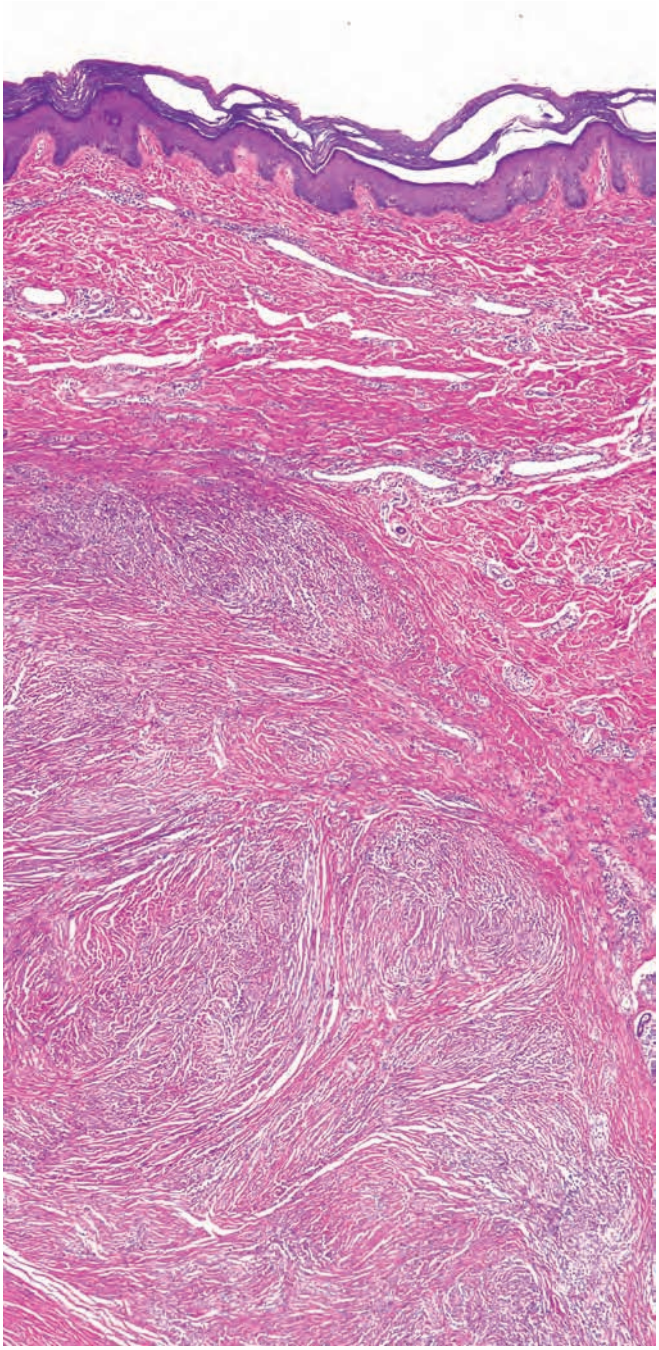

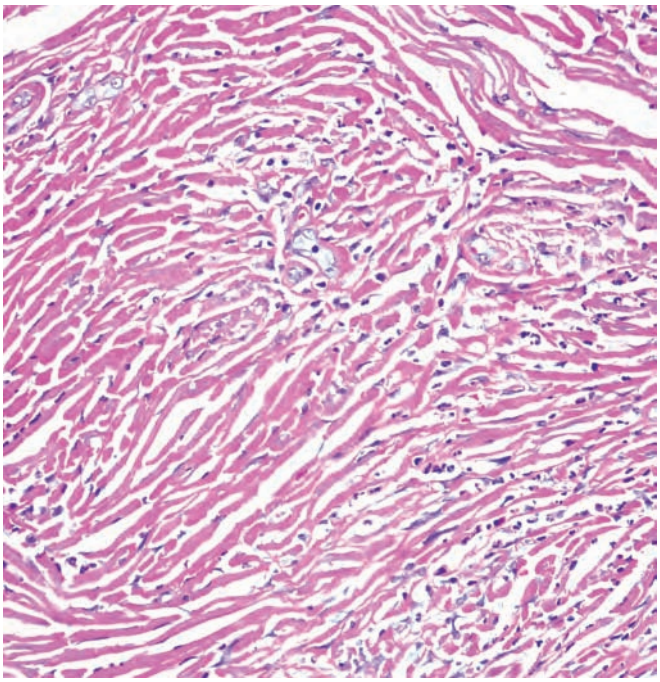

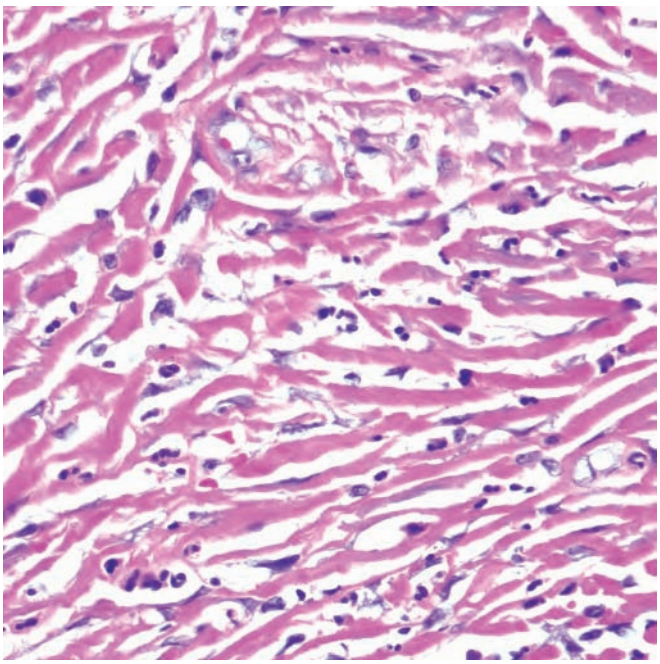

- Pink material in the dermis with clefting (later lesions)
- Late stage has neutrophils interspersed with prominent fibrosis and "cholesterol clefts"
- Palisading of neutrophils and nuclear dust around altered collagen (earlier lesions)
- Swollen vessel walls and fibrin deposits (earlier lesions)

Erythema elevatum diutinum (extracellular cholesterolosis)

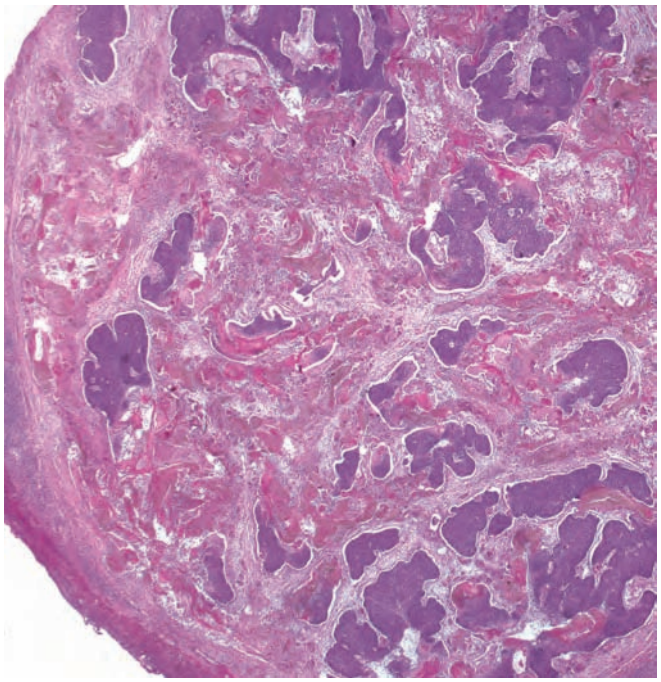
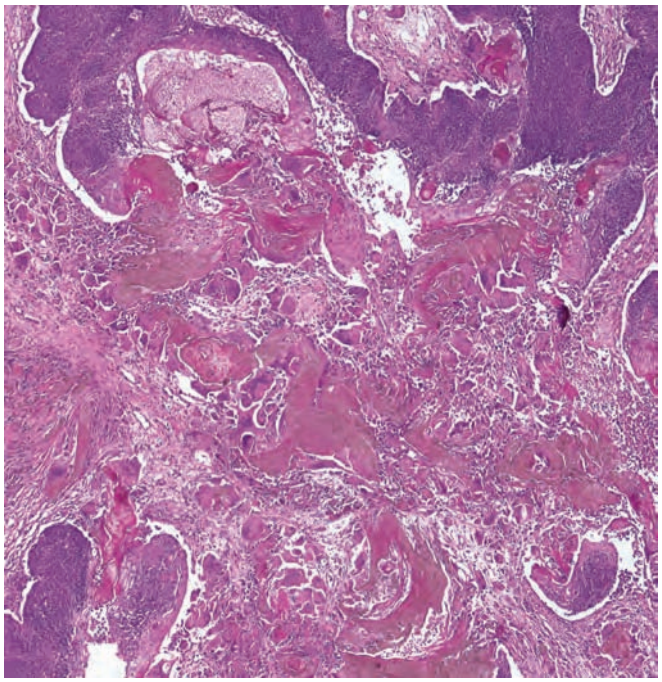
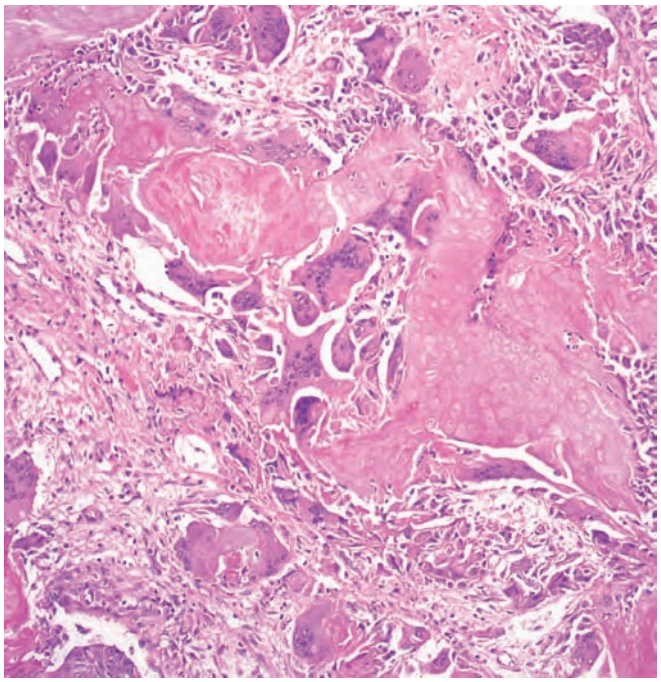
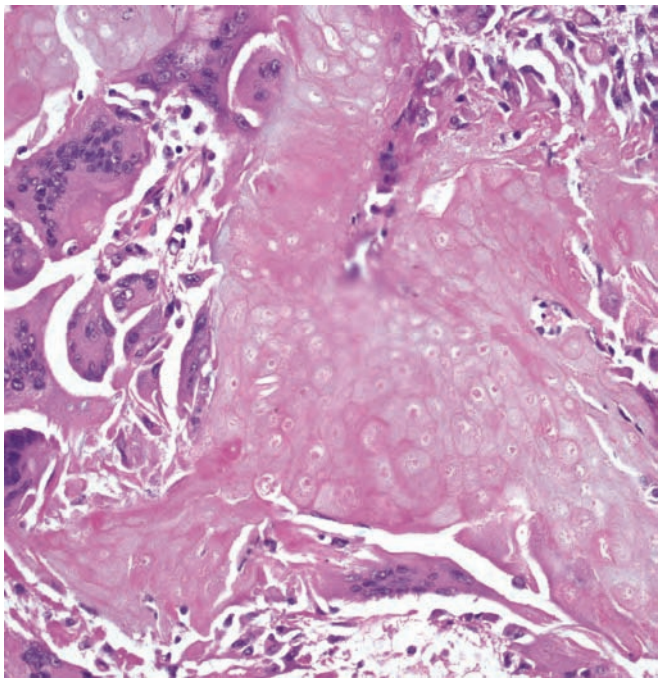

- Pink material with shadows of nuclei within, may have a "butterscotch" color ("pilomatrical keratin")
- Basaloid cells (not always present)
- Calcification or ossification may be present
- Giant cells often seen

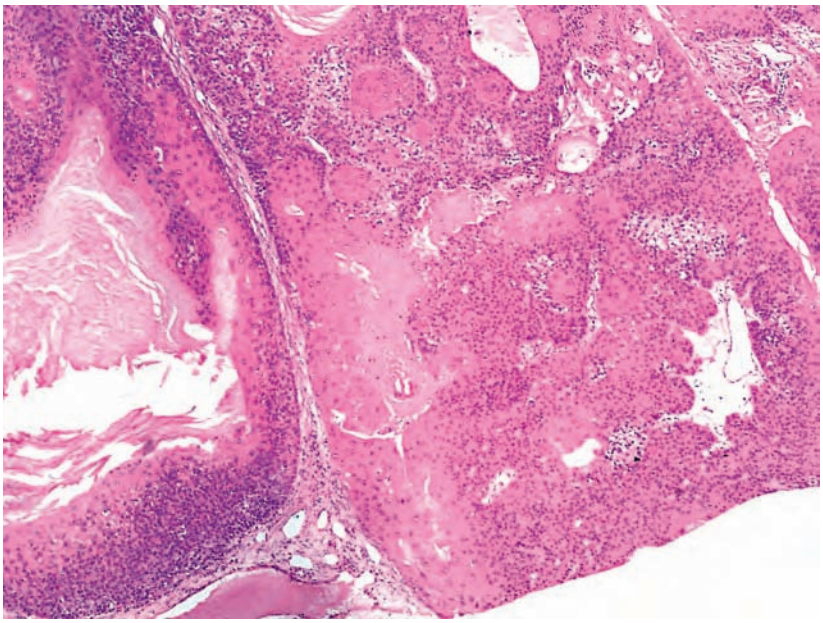

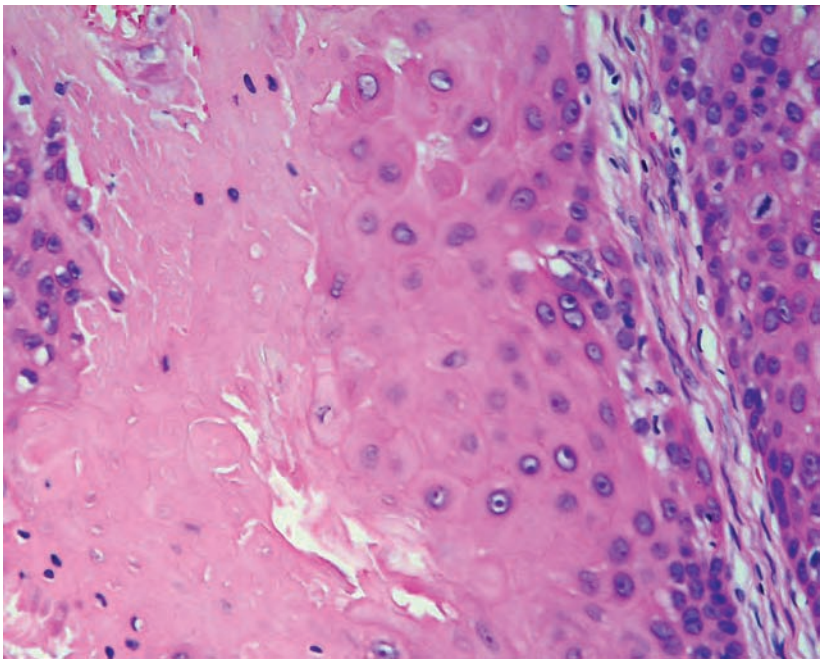

- Pink material that is dense keratin
- Stratified squamous epithelium with no granular layer (tricholemmal differentiation)

Proliferating pilar tumor

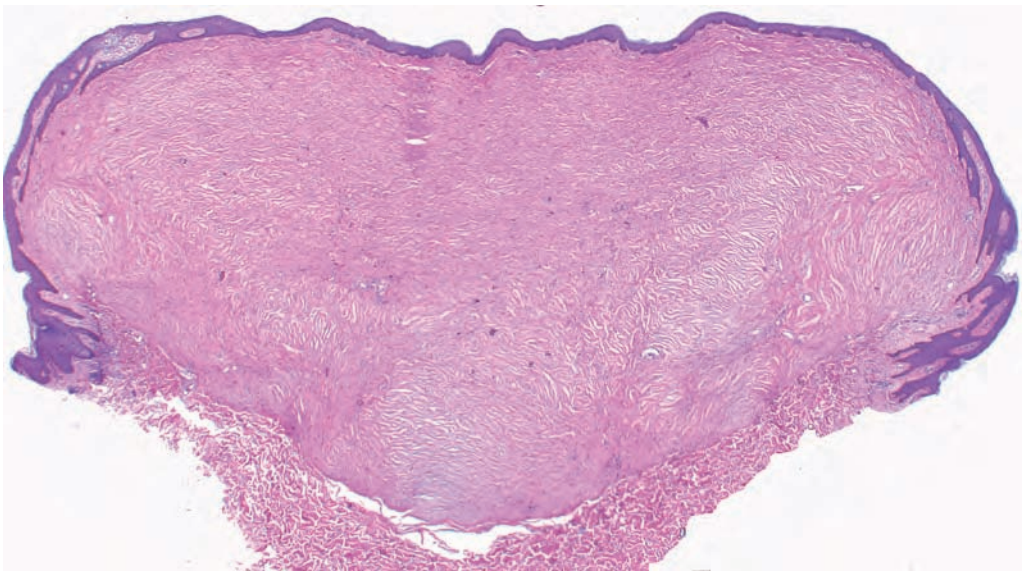

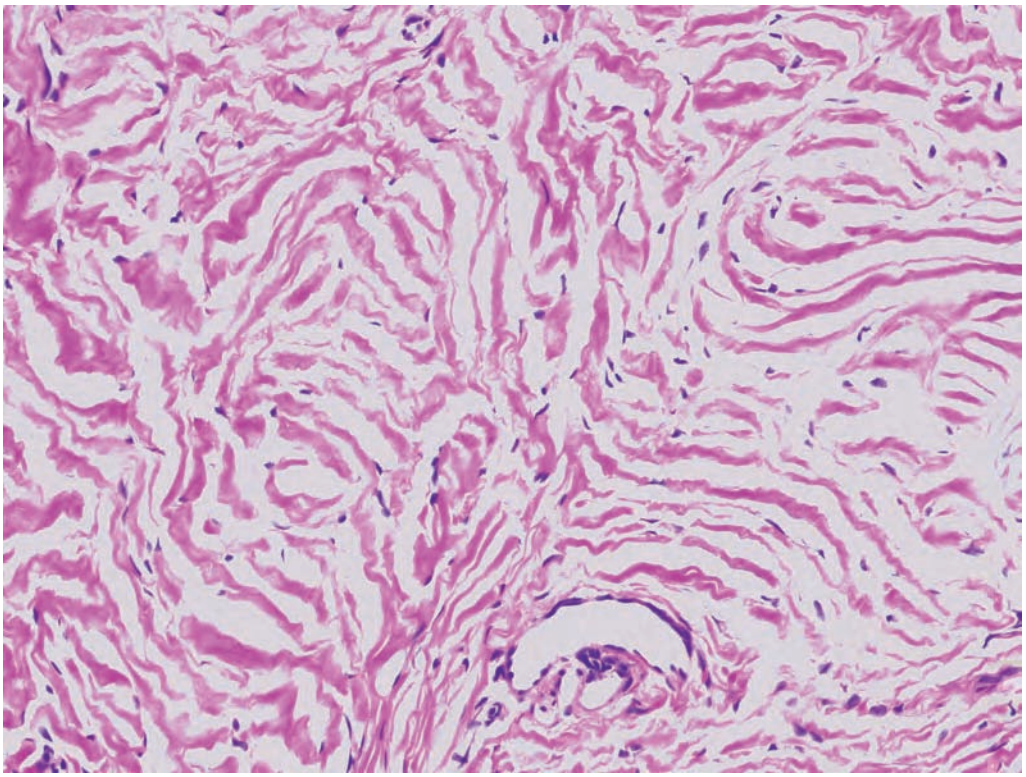

- Pink material arranged in a fenestrated or clefted fashion
- Hyalinized, relatively acellular collagen

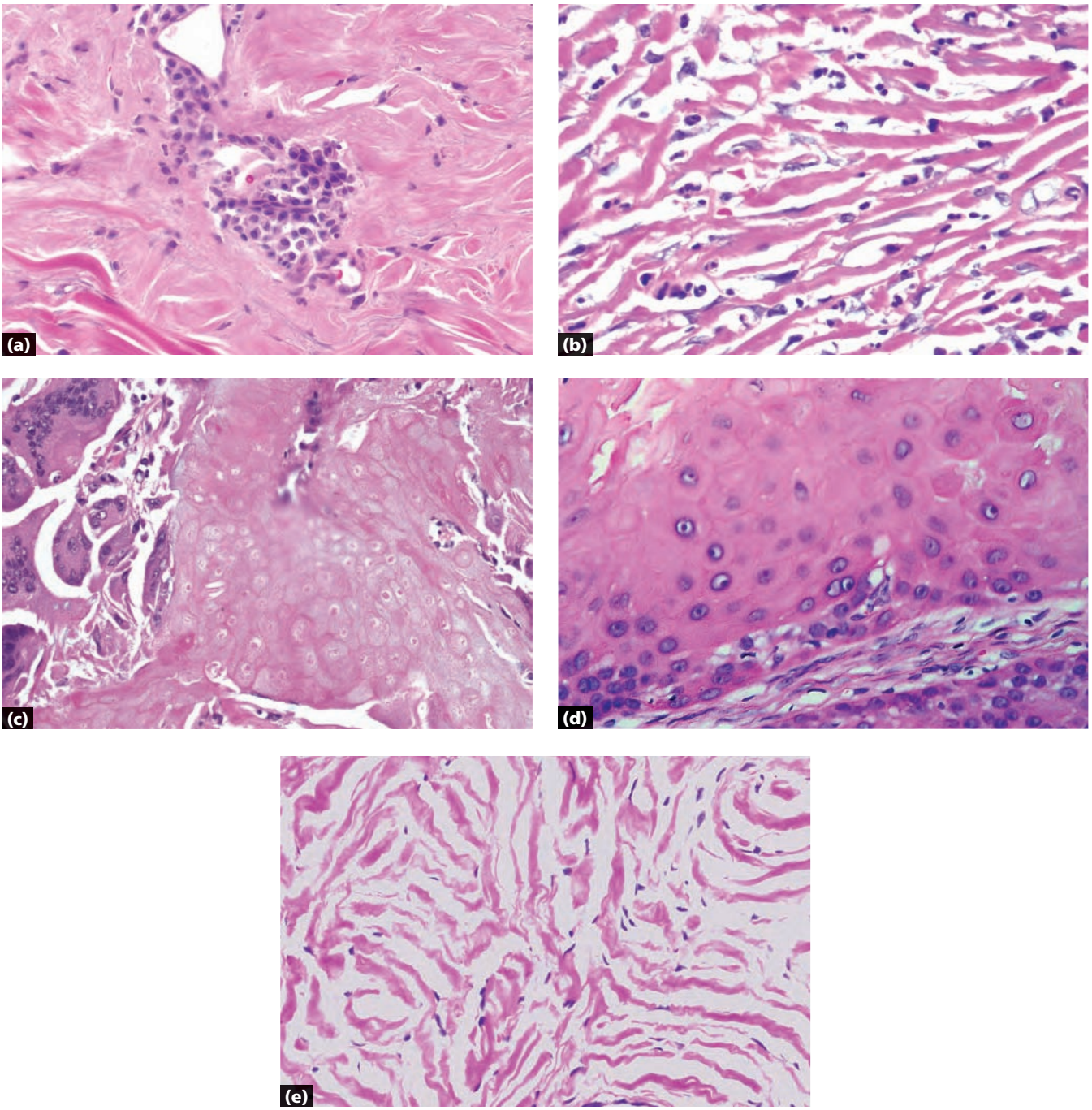

a Amyloid: amorphous pink material, plasma cells
b Erythema elevatum diutinum (late stage): fibrosis with clefting and interspersed neutrophils
c Pilomatricoma: shadow cells, basaloid cells
d Proliferating pilar tumor: dense pink keratin, no granular layer between keratin and epithelium
e Sclerotic fibroma: clefts between strands of sclerotic collagen

Key differences

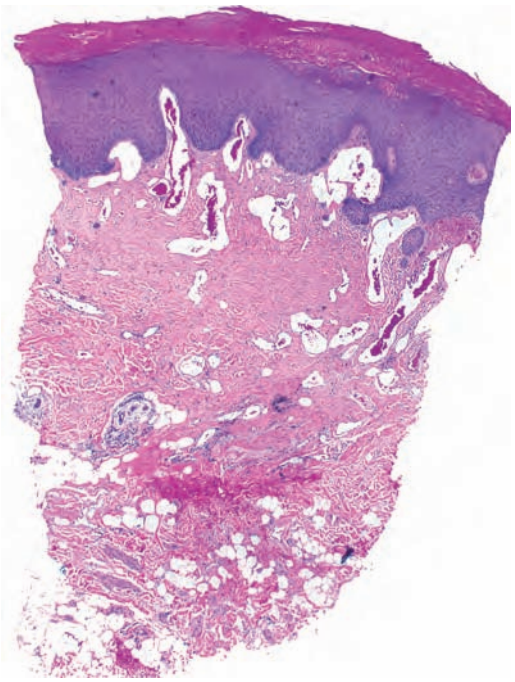

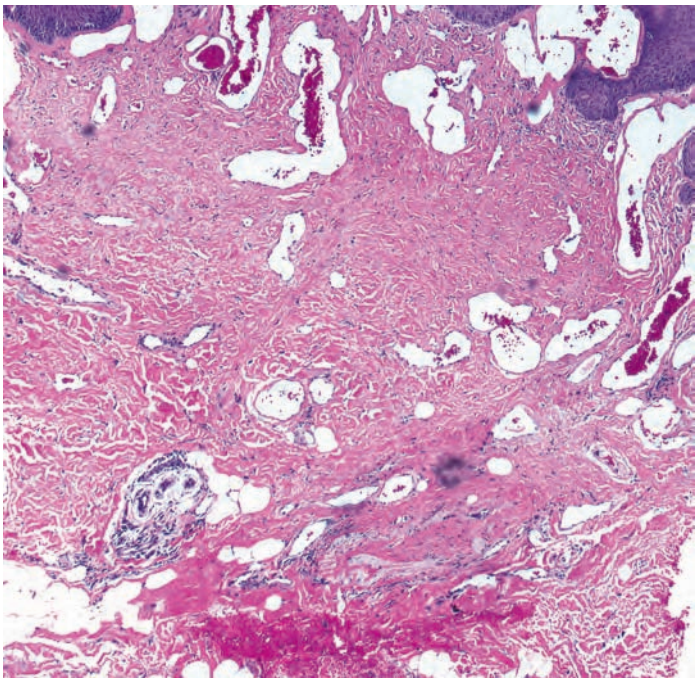

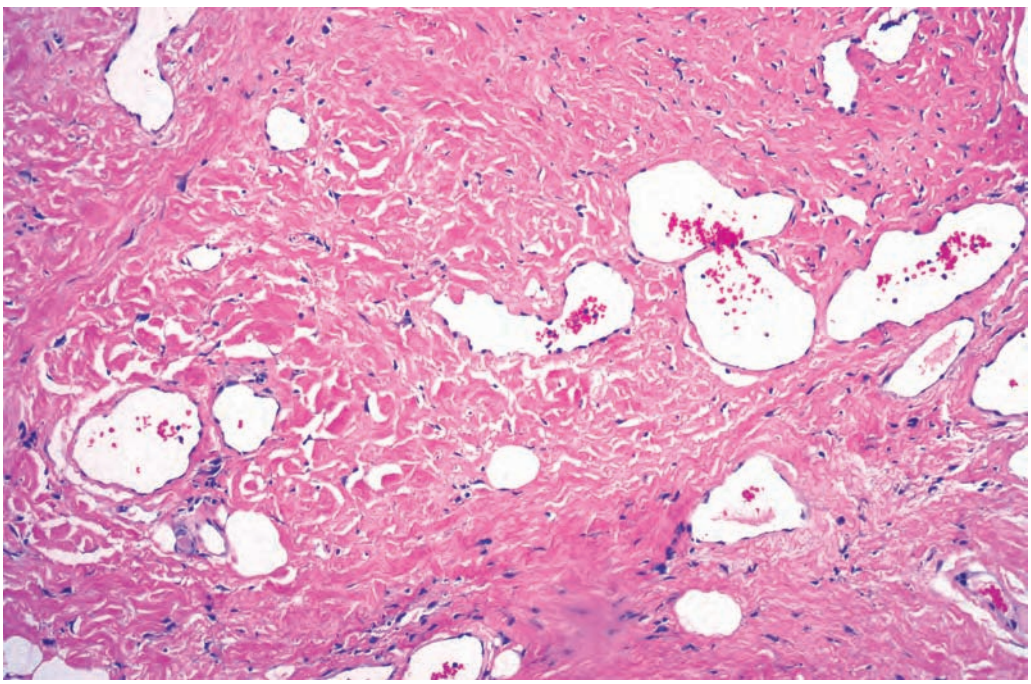

- Pink dermis
- Atypical, bizarre fibroblasts within dermis
- Dilated vessels with plump endothelial cells
- Adnexal structures often absent

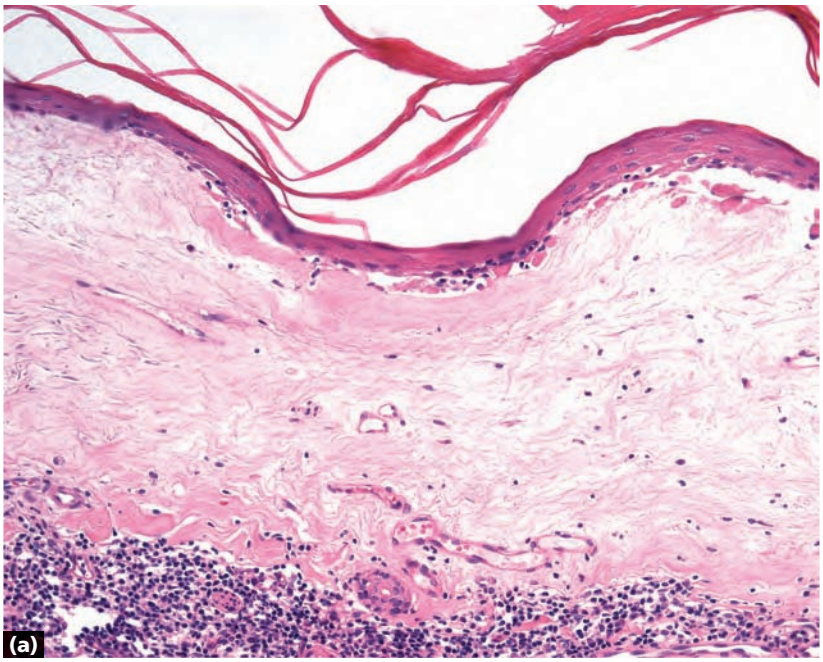

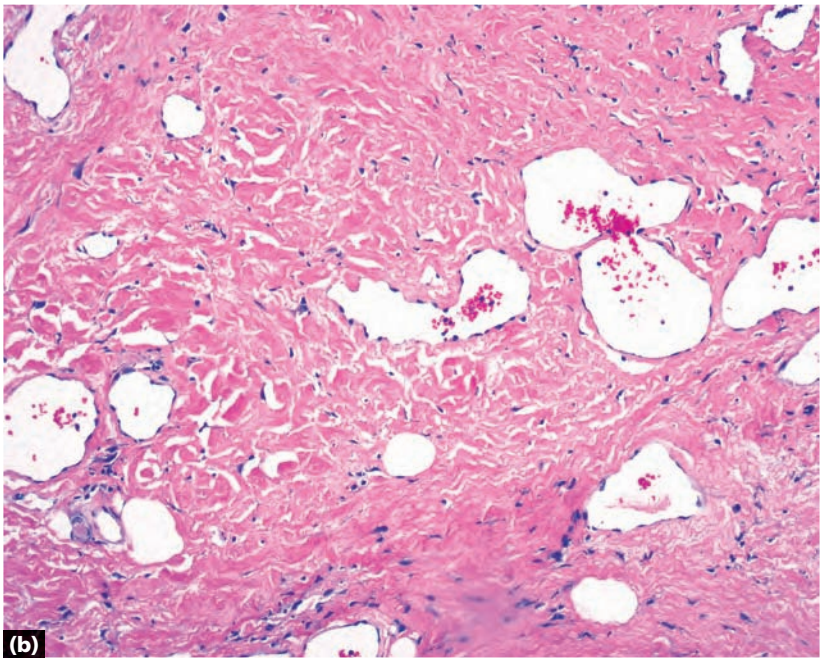

a Lichen sclerosus et atrophicus: pink band of dermis with inflammation below it (see also page 115)
b Radiation dermatitis: pink dermis with dilated vessels; atypical fibroblasts on higher power

Key differences

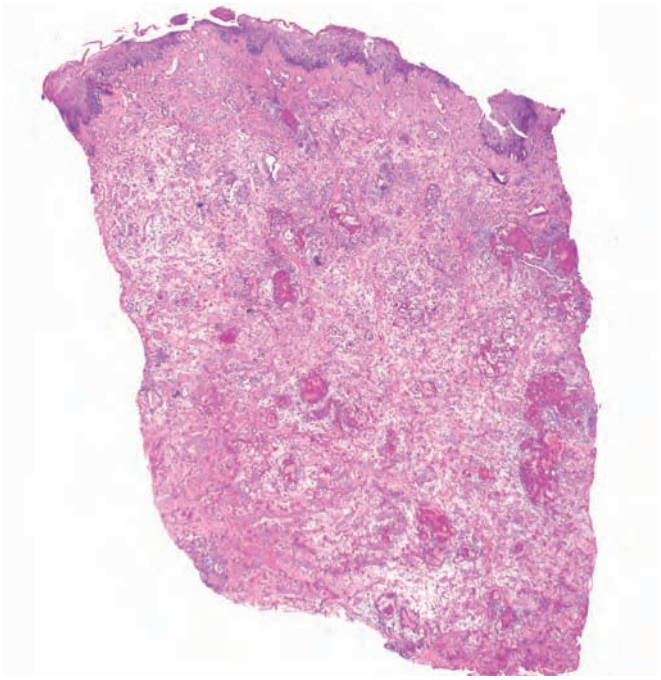

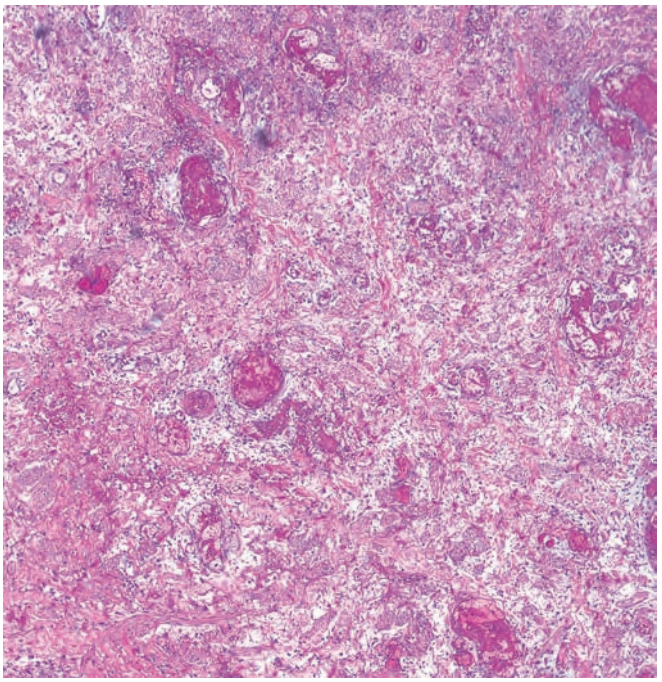

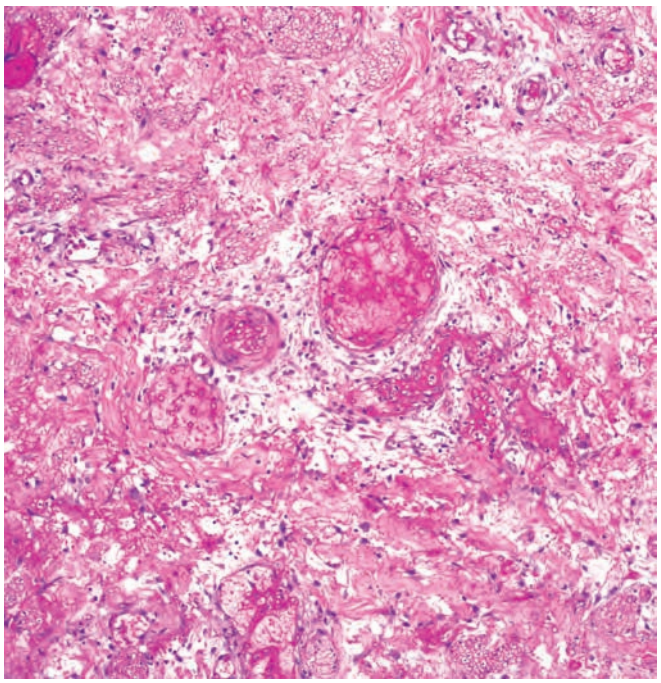

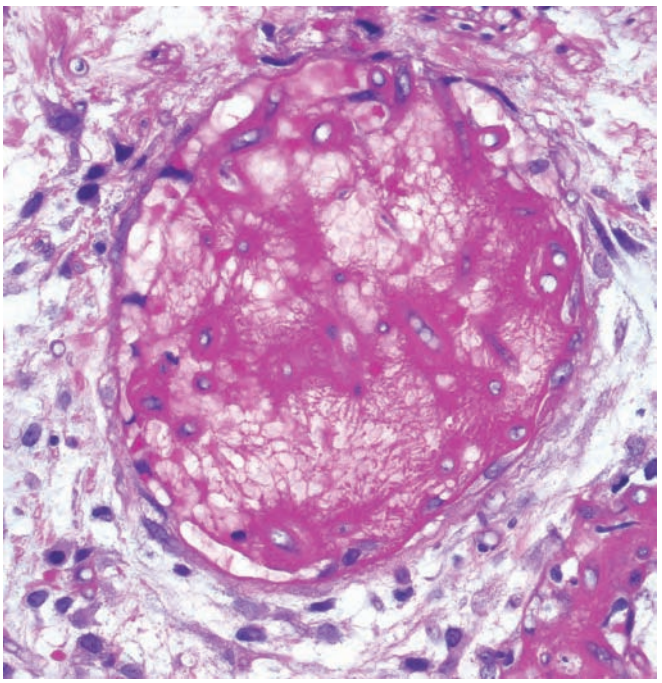

- Epidermal and dermal necrosis
- Vessels necrotic with extravasated erythrocytes and visible fungal hyphae that are septate and branching

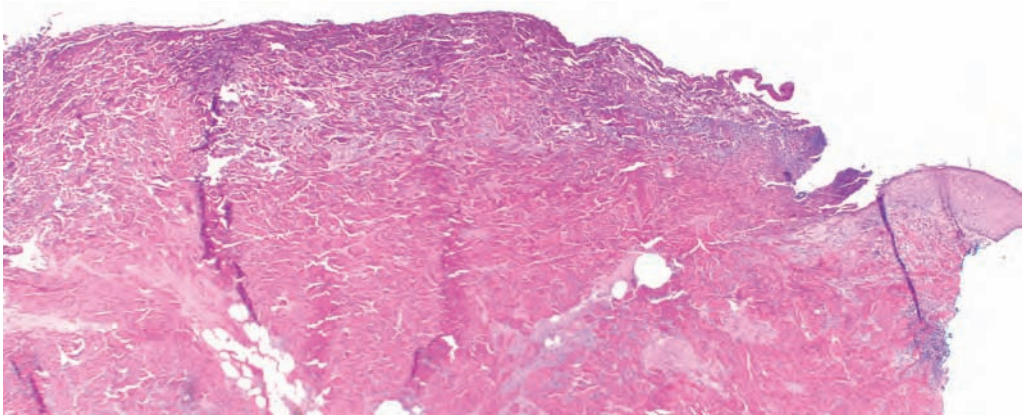

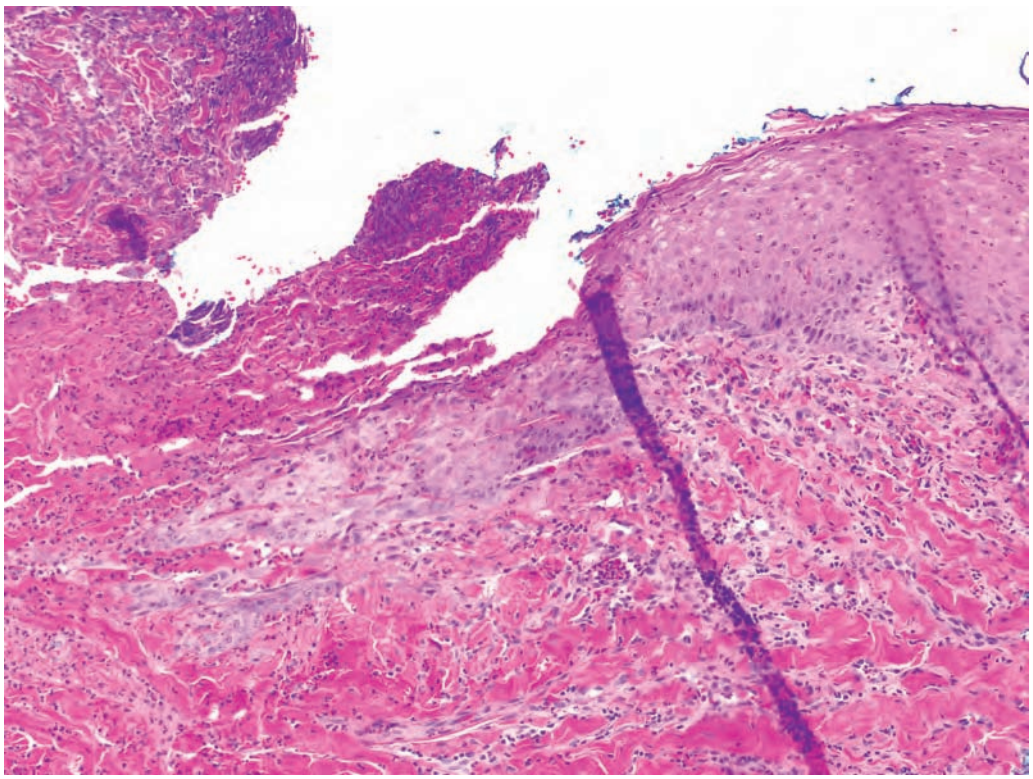

- Epidermal necrosis with variable dermal change
- Reversal of epidermal staining (more basophilic superficially than deep)
- Acute lesions are non-inflammatory

Burn

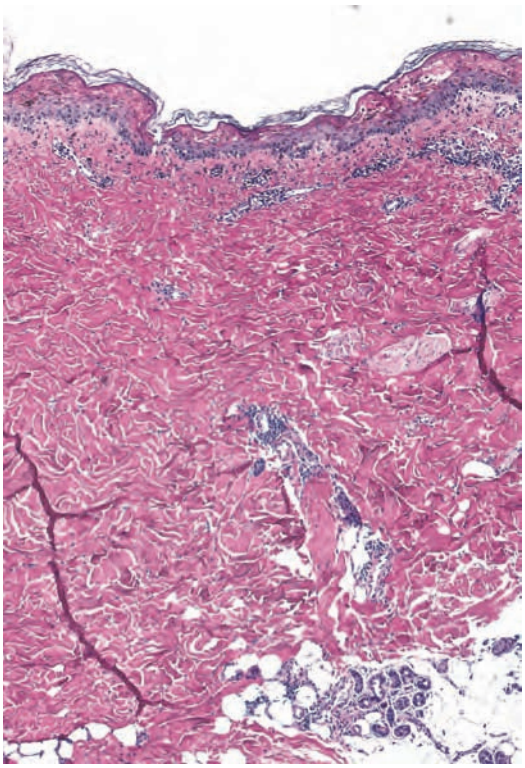

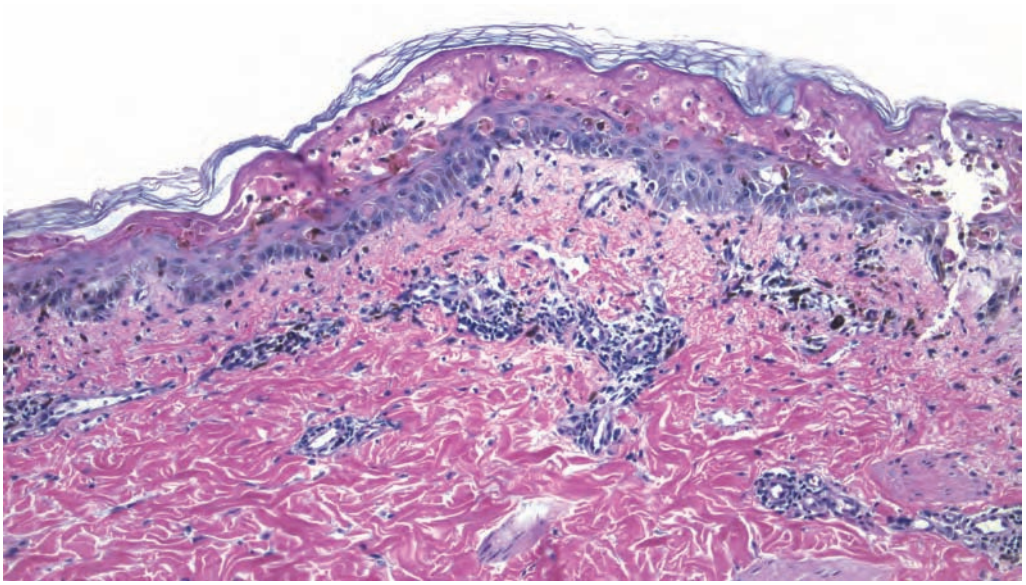

- Epidermal necrosis below basket-weave stratum corneum

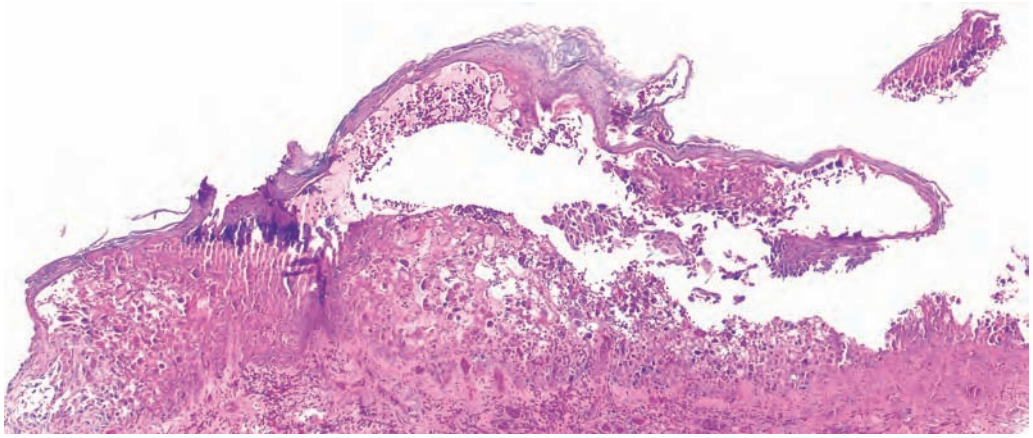

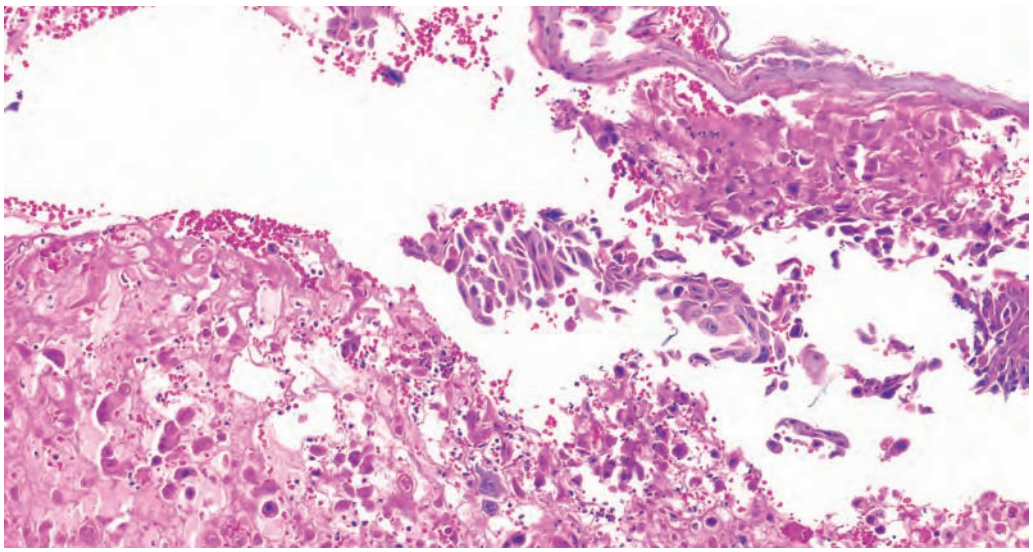

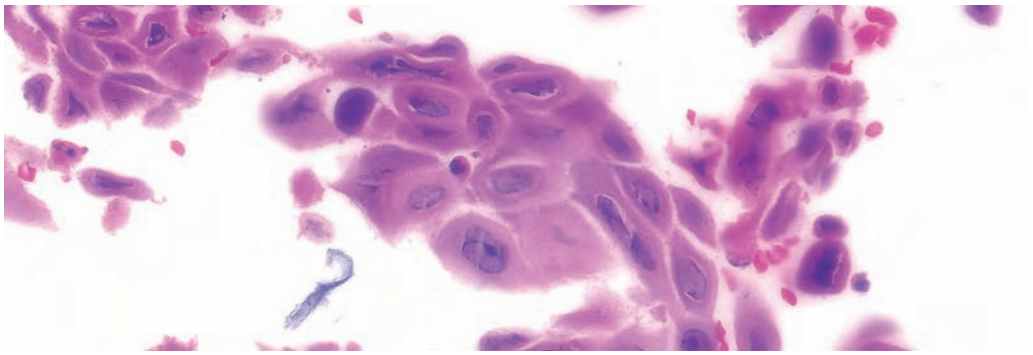

- Epidermal necrosis with acantholytic cells and multinucleated cells
- Follicular necrosis is a clue

Herpes simplex infection

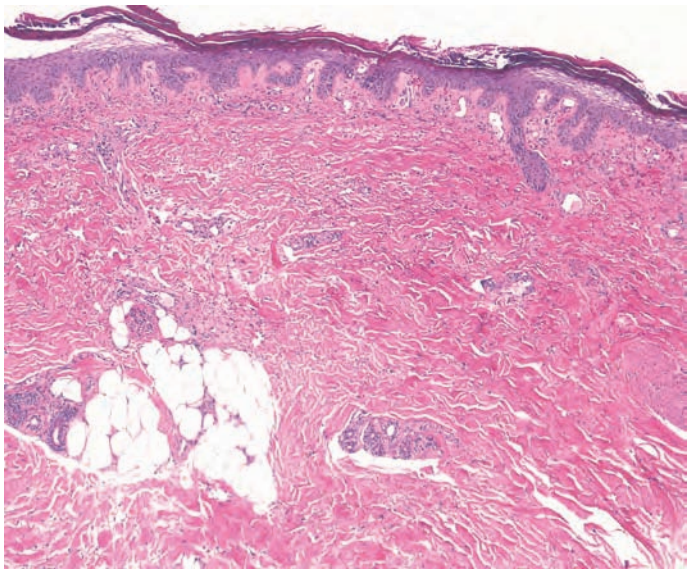

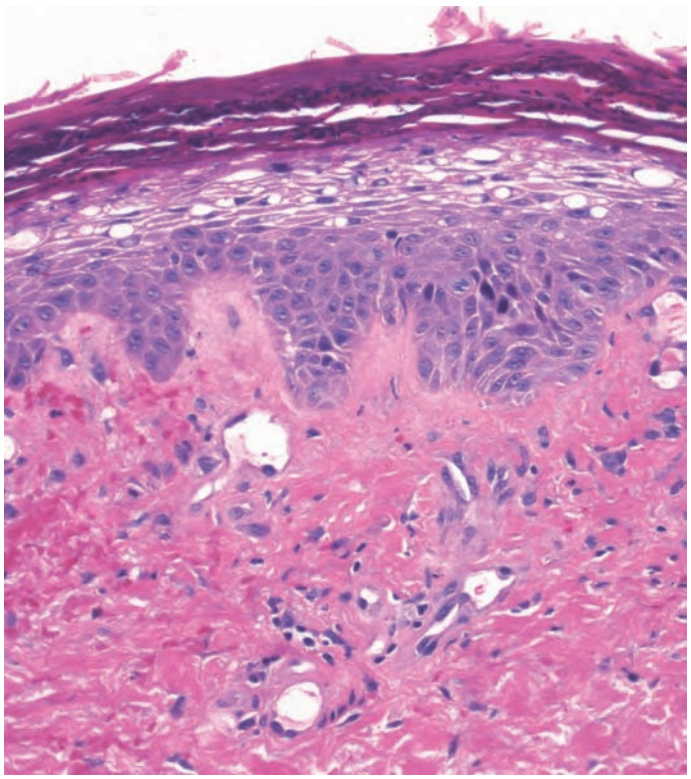

- Epidermal necrosis or pallor underlying parakeratosis
- Basal layer relatively normal
- Inflammation not prominent
- Similar changes can be seen in necrolytic migratory erythema

Nutritional deficiency (zinc deficiency, acrodermatitis enteropathica, essential fatty acid deficiency)

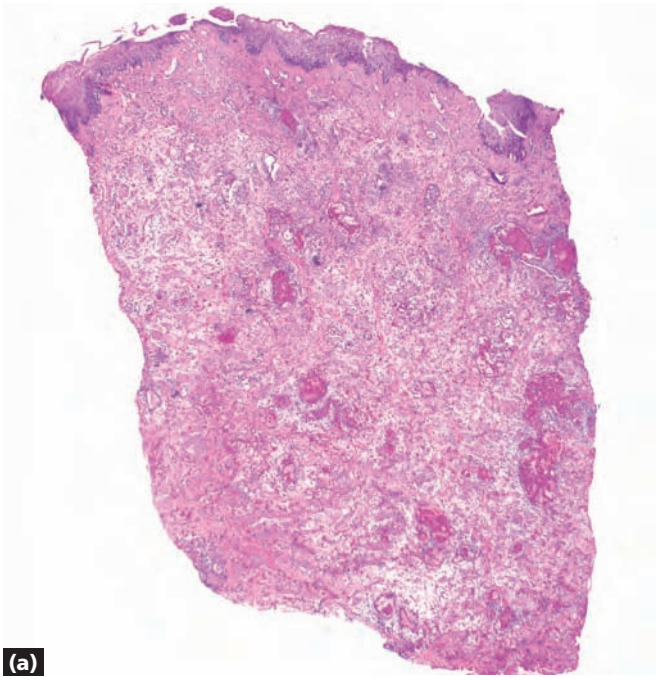

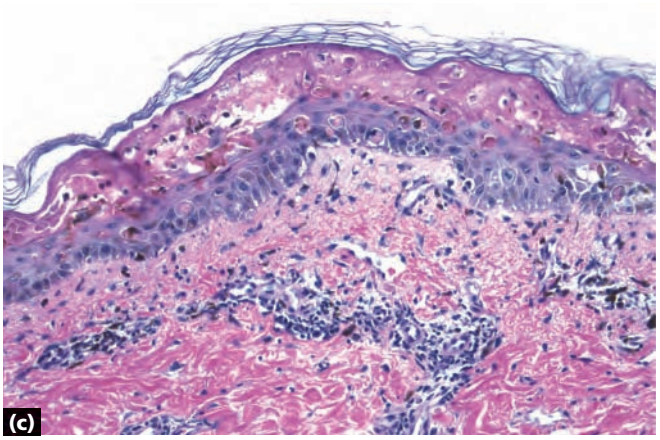

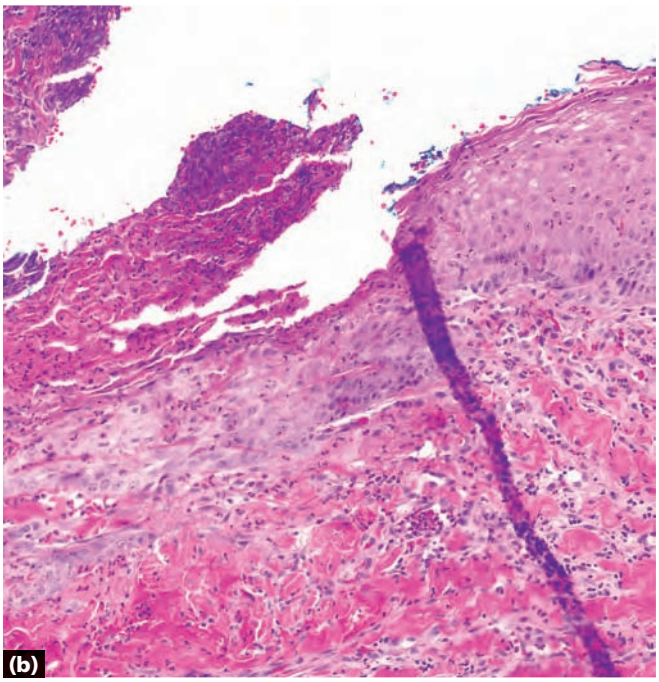

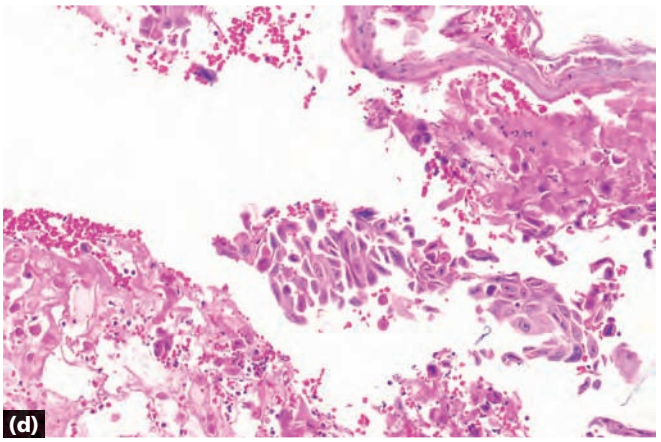

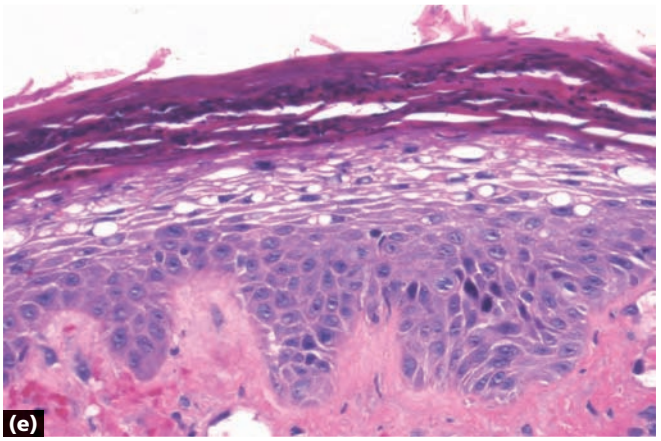

a Aspergillosis: epidermal and dermal necrosis with fungi in areas of destroyed vessels
b Burn: epidermal necrosis, sharp demarcation from normal skin
c Erythema multiforme: basket-weave stratum corneum, apoptotic keratinocytes
d Herpes simplex infection: acantholysis and multinucleated cells with rimmed chromatin (margination)
e Nutritional deficiency: parakeratosis above epidermal necrosis, basal layer often unaffected

Key differences

Index by Pattern

Acantholysis
Actinic keratosis, 224, 227
Darier disease, 238, 246
Grover disease, 239, 246
Hailey-Hailey disease, 240, 246
Herpes virus infection, 241, 246, 320, 322
Pemphigus foliaceus, 242, 247
Pemphigus vulgaris, 243, 247
Pityriasis rubra pilaris, 108, 111, 227
Squamous cell carcinoma, 244, 247
Warty dyskeratoma, 245, 247

Acanthosis, regular epidermal
Bowen disease, 25, 28
Clear cell acanthoma, 26, 28
Inflammatory linear verrucous epidermal nevus, 223, 227
Psoriasis, 27, 28, 100, 101, 105, 109, 111

Band-like dermal/papillary dermal infiltrate
Langerhans cell histiocytosis, 131, 136
Lichen nitidus, 132
Mastocytosis, 133, 136
Mycosis fungoides, 134, 136
Zoon balanitis, 135, 136

Blue dense infiltrate *see* **Diffuse/nodular infiltrate**

Blue tumor
Basal cell carcinoma, 281, 290
Glomus tumor, 282, 290
Lymphoma, 140, 143
Merkel cell carcinoma, 283, 290
Sebaceoma (sebaceous epithelioma), 284, 290
Sebaceous carcinoma, 285
Spiradenoma, 286, 290
Trichoblastoma, 287, 290
Trichoepithelioma, 288, 290
Tufted angioma, 289, 290

"Busy" dermis
Blue nevus, hypopigmented, 260, 262
Dermatofibroma, 166, 176, 262
Granuloma annulare, 89, 92, 130, 262
Kaposi sarcoma, 175, 176, 186, 191, 262
Leukemia cutis, 262
Metastatic breast carcinoma, interstitial pattern (carcinoma *en cuirasse*), 261, 262

Central pore
Dilated pore of Winer, 42, 45
Pilar sheath acanthoma, 43, 45
Trichofolliculoma, 44, 45

Change in the fat *see* **Fat, change in the**

Circular dermal islands
Adenoid cystic carcinoma, 49, 52
Cylindroma, 50, 52
Spiradenoma, 286, 290
Trichoadenoma, 51, 52
Trichoblastoma, 287, 290

"Clear cells"
Angiolipoma, 208
Clear cell acanthoma, 26, 28
Cryptococcosis, gelatinous, 202, 216
Granular cell tumor, 203, 216
Hibernoma, 204, 216
Histoplasmosis, 205, 216
Leishmaniasis, 206, 216, 259
Lepromatous leprosy, 207, 216
Lipoma, 208
Melanoma, balloon cell, 209, 217
Nodular hidradenoma, 210, 217
Renal cell carcinoma, 211, 217
Sebaceous adenoma, 212, 217
Trichilemmoma, 33, 34
Xanthelasma, 213, 217
Xanthogranuloma, 214, 217
Xanthoma, 215, 217

Cords/tubules and comma shapes
Desmoplastic trichoepithelioma, 53, 58
Metastatic breast carcinoma, 54, 58

Dermatopathology: Diagnosis by First Impression, Third Edition. By Christine J. Ko and Ronald J. Barr.
© 2017 John Wiley & Sons, Ltd. Published 2017 by John Wiley & Sons, Ltd.
Companion website: www.wiley.com/go/ko/dermatopathology3e

Microcystic adnexal carcinoma, 55, 58
Morpheaform basal cell carcinoma, 56, 58
Syringoma, 57, 58

Dermal material
Amyloidosis, nodular, 263, 274
Calcinosis cutis, 264, 274
Cryoglobulinemia (type I), 309
Erythropoietic protoporphyria, 265, 274
Gel foam, 266, 274
Gout, 88, 92
Hyaluronic acid (dermal filler), 272, 274
Lipoid proteinosis, 267, 274
Ochronosis, 268, 275
Osteoma cutis, 269, 275
Paraffinoma, 270, 275
Pseudoxanthoma elasticum, 271, 275
Tattoo, 259, 273, 275
see also **Mucin; Pink material**

Diffuse/nodular infiltrate
Acne keloidalis, 137, 142
Discoid lupus erythematosus, 117, 122, 142
Granuloma faciale, 138, 142
Leukemia (myelogenous), 139, 142
Lymphoma, 140, 143
Mastocytoma, 143
Sweet syndrome, 141, 143

Endothelial cells (suggestion of vessels)
Angioleiomyoma, 178, 190, 306
Angiolymphoid hyperplasia with eosinophilia, 179, 190
Angiosarcoma, 180, 190
Bacillary angiomatosis, 181, 190
Chondrodermatitis nodularis helicis, 182, 190
Dermatofibroma, hemosiderotic, 183, 190
Fibrous papule, 184, 191
Glomus tumor/glomuvenous malformation (glomangioma), 69, 282, 290
Infantile hemangioma, 185, 191
Kaposi sarcoma, 175, 176, 186, 191, 262
Lichen sclerosus, 115, 116, 316
Pyogenic granuloma, 187, 191
Radiation dermatitis, 315, 316
Stasis dermatitis, 188, 191
Targetoid hemosiderotic hemangioma (hobnail angioma), 189, 191

Eosinophils, epidermal
Allergic contact dermatitis, 102, 105, 126
Arthropod bite reaction, 103, 126
Bullous pemphigoid, 126, 249, 254
Incontinentia pigmenti, 123, 126
Pemphigus vegetans, 124, 126
Scabies, 125, 126

Epidermal necrosis
Aspergillosis, 317, 322
Burn, 318, 322
Erythema multiforme, 112, 116, 319, 322
Herpes simplex infection, 320, 322
Nutritional deficiency, 227, 321, 322

Epidermal perforation
Calcinosis cutis, perforating, 48
Elastosis perforans serpiginosa, 46, 48
Granuloma annulare, perforating, 48
Reactive perforating collagenosis, 47, 48

Fat, change in the
Angiolipoma, 208
Dermatofibrosarcoma protuberans (often extends into the fat), 167, 176
Erythema induratum, 144, 150
Erythema nodosum, 145, 150
Hibernoma, 204, 216
Lipodermatosclerosis, 276, 278
Lupus profundus, 146, 151, 278
Nodular fasciitis (often deep in the fat), 170, 177, 301
Pancreatic fat necrosis, 277, 278
Polyarteritis nodosa, 147, 150
Post-steroid panniculitis, 148
Sclerema neonatorum, 148
Subcutaneous fat necrosis of newborn, 148, 151, 278
Subcutaneous T-cell lymphoma, 149, 151

Giant cells
Atypical fibroxanthoma, 192, 200
Erythema nodosum, 145, 150
Giant cell tumor of tendon sheath, 193, 200
Juvenile xanthogranuloma, 194, 200
Mucocele, 293, 294
Necrobiosis lipoidica, 83, 87, 92
Necrobiotic xanthogranuloma, 90, 92
Pilomatricoma, 311, 314
Reticulohistiocytosis, 195, 200
Rosai-Dorfman disease, 196, 201
Ruptured cyst/keratin granuloma, 197, 201
Sarcoidosis, 198, 201
Scar, 168, 177, 307
Suture granuloma, 199, 201

Granular "material" in cells
Aluminum chloride (Drysol solution), 255, 259
Ferric subsulfate (Monsel solution), 256, 259
Granular cell tumor, 203, 216
Hemosiderin, 257, 259
Leishmaniasis, 206, 216, 259
Melanin, 258, 259
Tattoo, 259, 273, 275

Hyperkeratosis/parakeratosis
Actinic keratosis, 224, 227
Axillary granular parakeratosis, 225, 227
Bowen disease, 25, 28
Chondrodermatitis nodularis helicis, 182, 190
Dermatophytosis, 226, 227
Discoid lupus erythematosus, 117, 122, 142
Epidermolytic hyperkeratosis, 230, 236
Flegel disease, 221
Ichthyosis vulgaris, 19, 22
Inflammatory linear verrucous epidermal nevus, 223, 227
Lichen planus, 119, 122
Lichen sclerosus, 115, 116, 316
Nutritional deficiency, 227, 321, 322
Pityriasis lichenoides et varioliformis acuta, 121, 122
Pityriasis rubra pilaris, 108, 111, 227
Porokeratosis, 222
Tinea versicolor, 20, 22, 227
see also **Parakeratosis**

Interface (lichenoid) change
Discoid lupus erythematosus, 117, 122, 142
Halo nevus, 118, 122
Lichen planus, 119, 122
Lichen striatus, 120, 122
Pityriasis lichenoides et varioliformis acuta, 121, 122

Interface (vacuolar) change
Erythema multiforme, 112, 116, 319, 322
Fixed drug reaction, 113, 116
Graft-versus-host disease, 114, 116
Lichen sclerosus, 115, 116, 316

Lichenoid interface change *see* **Interface (lichenoid) change**

Lobular proliferation (proliferation downward from epidermis)
Inverted follicular keratosis, 29, 34
Molluscum contagiosum, 30, 34
Poroma, 31, 34
Seborrheic keratosis, acanthotic, 32, 34
Trichilemmoma, 33, 34

Melanocytes
Blue nevus, 155, 162
Blue nevus, cellular, 164, 176
Deep penetrating nevus, 156, 162
Intradermal nevus, 162, 258
Melanoma, 157, 163
Melanoma, balloon cell, 209, 216
Melanoma, desmoplastic, 162, 165, 176
Mongolian spot, 158, 162
Pigmented spindle cell nevus of Reed, 159, 163
Recurrent nevus, 160, 163
Spitz nevus, 161, 163

Mucin
Digital mucous cyst, 295, 301
Focal cutaneous mucinosis, 296, 301
Follicular mucinosis, 297, 301
Lichen myxedematosus, 86
Lupus tumidus, 298
Neurothekeoma, 299, 301
Nodular fasciitis, 170, 177, 301
Pretibial myxedema, 300, 301
Scleromyxedema, 86, 87

Mucin and glands or ducts
Chondroid syringoma, 291, 294
Mucinous carcinoma, 292, 294
Mucocele, 293, 294

"Normal" skin on low power
Argyria, 18, 22
Dermatophytosis/tinea versicolor*, 20, 22, 226, 227
Ichthyosis vulgaris, 19, 22
Macular amyloidosis* (not pictured), 22
Scleredema, 85, 87
Urticaria, 21, 22
Vitiligo (not pictured), 18

*when subtle

Palisading reactions
Gout, 88, 92
Granuloma annulare, 89, 92, 130, 262
Necrobiosis lipoidica, 83, 87, 92
Necrobiotic xanthogranuloma, 90, 92
Rheumatoid nodule, 91, 92

Papillary dermal infiltrate *see* **Band-like dermal/papillary dermal infiltrate**

Papillated dermal tumor
Aggressive digital papillary adenocarcinoma, 70, 76
Erosive adenomatosis of the nipple (nipple adenoma), 71, 76
Hidradenoma papilliferum, 72, 76
Papillary eccrine adenoma, 73, 76
Syringocystadenoma papilliferum, 74, 76
Tubular apocrine adenoma, 75, 76

Papulosquamous (psoriasiform) change
Chronic spongiotic dermatitis, 105, 106, 111
Lichen simplex chronicus, 105, 107
Pityriasis rubra pilaris, 108, 111, 227
Psoriasis, 27, 28, 100, 101, 105, 109, 111
Secondary syphilis, 110, 111

Parakeratosis
Psoriasis, 27, 28, 100, 101, 105, 109, 111
Spongiotic dermatitis, 99, 101
see also **Hyperkeratosis/parakeratosis**

Perivascular infiltrate
Granuloma annulare, 89, 92, 130, 262
Gyrate erythema, 127, 130
Leukocytoclastic vasculitis, 128, 130
Perniosis, 130
Pigmented purpuric dermatosis, 129, 130
Pityriasis rosea, 104, 105, 130
Polymorphous light eruption, 252, 254

Pink ball of spindle cells
Angioleiomyoma, 178, 190, 306
Myofibroma, 305, 306
Scar, hypertrophic, 307
Schwannoma, 174, 177, 307

Pink dermis
Lichen sclerosus, 115, 116, 316
Morphea, 82, 87
Radiation dermatitis, 315, 316

Pink material
Amyloid, 275, 286, 308, 314
Cryoglobulinemia (type I), 309
Erythema elevatum diutinum, 310, 314
Erythropoietic protoporphyria, 265, 274
Gout, 88, 92
Lichen sclerosus, 115, 116, 316
Lipoid proteinosis, 267, 274
Pilomatricoma, 311, 314
Proliferating pilar tumor, 312, 314
Radiation dermatitis, 315, 316
Rheumatoid nodule, 91, 92
Sclerotic fibroma, 313, 314

Polypoid shape (dome-shaped)
Accessory digit, 77, 81
Accessory nipple, 78, 81
Accessory tragus, 79, 81
Digital fibrokeratoma, 80, 81
Fibrous papule, 184, 191
Intradermal nevus, 162, 258
Neurofibroma, 172, 177
Pyogenic granuloma, 187, 191

Proliferation downward from epidermis *see* **Lobular proliferation**

Pseudoepitheliomatous hyperplasia above abscesses
Blastomycosis, 93, 96
Chromomycosis, 94, 96
Coccidioidomycosis, 95, 96

Psoriasiform change *see* **Papulosquamous**

Regular epidermal acanthosis *see* **Acanthosis, regular epidermal**

Reticulated epidermal proliferation
Fibroepithelioma of Pinkus, 35, 41
Fibrofolliculoma, 36, 41
Nevus sebaceus of Jadassohn, 37, 41
Seborrheic keratosis, reticulated, 38, 41
Syringofibroadenoma, 39, 41
Tumor of the follicular infundibulum, 40, 41

Space with a lining
Apocrine hidrocystoma, 59, 68
Auricular pseudocyst, 60, 68
Branchial cleft cyst, 61, 68
Bronchogenic cyst, 69
Cutaneous ciliated cyst, 62, 68
Cutaneous endometriosis, 63, 68
Dermoid cyst, 64, 69
Epidermal inclusion cyst, 65, 69
Glomangioma, 69
Pilar cyst, 66, 69
Steatocystoma, 67, 69
Venous lake, 69

Spindle cells
Angioleiomyoma, 178, 190, 306
Atypical fibroxanthoma, 192, 200
Blue nevus, cellular, 164, 176
Dermatofibroma, 166, 176, 262
Dermatofibrosarcoma protuberans, 167, 176
Fibrous papule, 184, 191
Infantile digital fibromatosis, 169, 176
Kaposi sarcoma, 175, 176, 186, 191, 262
Leiomyoma, 171, 177
Melanoma, desmoplastic, 162, 165, 176
Neurofibroma, 172, 177
Neurothekeoma, 299, 301
Nodular fasciitis, 170, 177, 301
Palisaded encapsulated neuroma, 173, 177
Scar, 168, 177
Schwannoma, 174, 177, 307
Squamous cell carcinoma, 244, 247
see also **Pink ball of spindle cells**

Spongiosis
Allergic contact dermatitis, 102, 105, 126
Arthropod bite reaction, 103, 126
Guttate psoriasis, 104
Lichen simplex chronicus, 105, 107
Pityriasis rosea, 104, 105, 130
Psoriasis, 105

Square/rectangular shape
Lichen myxedematosus, 86
Morphea, 82, 87
Necrobiosis lipoidica, 83, 87, 92
Normal back skin, 84, 87
Radiation dermatitis, 315, 316
Scleredema, 85, 87
Scleromyxedema, 86, 87

Subcutaneous inflammation
Erythema induratum, 144, 150
Erythema nodosum, 145, 150
Lupus profundus, 146, 151, 278
Polyarteritis nodosa, 147, 150
Post-steroid panniculitis, 148
Subcutaneous fat necrosis of newborn, 148, 151, 278
Subcutaneous T-cell lymphoma, 149, 151

Subepidermal space/cleft
Angiokeratoma, 248, 254
Bullous pemphigoid, 126, 249, 254
Dermatitis herpetiformis, 250, 254
Erythema multiforme, 112, 116, 319, 322
Herpes gestationis, 249
Lymphangioma, 251, 254
Pemphigoid gestationis, 249
Polymorphous light eruption, 252, 254
Porphyria cutanea tarda, 253, 254
Sweet syndrome, 141, 143

Upper epidermal change
Bowen disease, 25, 28
Clonal seborrheic keratosis, 228, 236
Epidermodysplasia verruciformis, 229, 236
Epidermolytic hyperkeratosis, 230, 236
Myrmecium, 231, 237
Orf, 232, 237
Paget disease, 233, 237
Verruca plana, 234
Verruca vulgaris, 235, 237

Vacuolar interface change *see* **Interface (vacuolar) change**

Vessels, suggestion of *see* **Endothelial cells**

Index by Histological Category

Acantholytic disorders
Darier disease, 238, 246
Grover disease, 239, 246
Hailey-Hailey disease, 240, 246
Herpes virus infection, 241, 246, 320, 322
Pemphigus foliaceus, 242, 247
Pemphigus vegetans, 124, 126
Pemphigus vulgaris, 243, 247
Squamous cell carcinoma, acantholytic, 244, 247
Warty dyskeratoma, 245, 247

Connective tissue disorders
Discoid lupus erythematosus, 117, 122, 142
Lichen sclerosus, 115, 116, 316
Lupus profundus, 146, 151, 278
Lupus tumidus, 298
Morphea, 82, 87
Polyarteritis nodosa, 147, 150
Rheumatoid nodule, 91, 92
Scleredema, 22, 85, 87
Scleromyxedema, 86, 87

Depositions

Endogenous material
Amyloidosis, 263, 274, 308, 314
Calcinosis cutis, 48, 264, 274
Cryoglobulinemia, 309
Digital mucous cyst, 295, 301
Erythropoietic protoporphyria, 265, 274
Focal cutaneous mucinosis, 296, 301
Follicular mucinosis, 297, 301
Gout, 88, 92
Hemosiderin, 257, 259
Lipoid proteinosis, 267, 274
Melanin, 258, 259
Mucocele, 293, 294
Osteoma cutis, 269, 275
Pretibial myxedema, 300, 301
Pseudoxanthoma elasticum, 271, 275

Foreign material
Aluminum chloride (Drysol solution), 255, 259
Argyria, 18, 22
Ferric subsulfate (Monsel solution), 256, 259
Gel foam, 266, 274
Hyaluronic acid (dermal filler), 272, 274
Ochronosis, 268, 275
Paraffinoma, 270, 275
Tattoo, 259, 273, 275

Genodermatoses
Epidermolytic hyperkeratosis, 230, 236
Erythropoietic protoporphyria, 265, 274
Ichthyosis vulgaris, 19, 22
Incontinentia pigmenti, 123, 126
Lipoid proteinosis, 267, 274

Granulomatous
Granuloma annulare, 48, 89, 92, 130, 262
Necrobiosis lipoidica, 83, 87, 92
Necrobiotic xanthogranuloma, 90, 92
Rheumatoid nodule, 91, 92
Ruptured cyst/keratin granuloma, 197, 201
Sarcoidosis, 198, 201
Suture granuloma, 199, 201

Histiocytic
Juvenile xanthogranuloma, 194, 200
Langerhans cell histiocytosis, 131, 136
Reticulohistiocytosis, 195, 200
Rosai-Dorfman disease, 196, 201
Xanthelasma, 213, 217
Xanthogranuloma, 214, 217
Xanthoma, 215, 217

Infections
Aspergillosis, 317, 322
Bacillary angiomatosis, 181, 190
Blastomycosis, 93, 96

Dermatopathology: Diagnosis by First Impression, Third Edition. By Christine J. Ko and Ronald J. Barr.
© 2017 John Wiley & Sons, Ltd. Published 2017 by John Wiley & Sons, Ltd.
Companion website: www.wiley.com/go/ko/dermatopathology3e

Chromomycosis, 94, 96
Coccidioidomycosis, 95, 96
Cryptococcosis, gelatinous, 202, 216
Dermatophytosis, 226, 227
Epidermodysplasia verruciformis, 229, 236
Herpes virus infection, 241, 246, 320, 322
Histoplasmosis, 205, 216
Kaposi sarcoma, 175, 176, 186, 191, 262
Leishmaniasis, 206, 216, 259
Lepromatous leprosy, 207, 216
Molluscum contagiosum, 30, 34
Myrmecium, 231, 237
Orf, 232, 237
Scabies, 125, 126
Secondary syphilis, 110, 111
Tinea versicolor, 20, 22, 227
Verruca plana, 234
Verruca vulgaris, 235, 237

Inflammatory disorders

Blistering disorders
Bullous pemphigoid, 126, 249, 254
Dermatitis herpetiformis, 250, 254
Herpes gestationis, 249
Porphyria cutanea tarda, 253, 254

Interface reactions
Discoid lupus erythematosus, 117, 122, 142
Erythema multiforme, 112, 116, 319, 322
Fixed drug reaction, 113, 116
Graft-versus-host disease, 114, 116
Lichen nitidus, 132
Lichen planus, 119, 122
Lichen striatus, 120, 122
Pigmented purpuric dermatosis, 129, 130
Pityriasis lichenoides et varioliformis acuta, 121, 122
Porokeratosis, 222

Miscellaneous
Acne keloidalis, 137, 142
Axillary granular parakeratosis, 225, 227
Burn, 318, 322
Chondrodermatitis nodularis helicis, 182, 190
Elastosis perforans serpiginosa, 46, 48
Erythema elevatum diutinum, 310, 314
Flegel disease, 221
Granuloma faciale, 138, 142
Gyrate erythema, 127, 130
Mastocytosis, 133, 136
Nutritional deficiency, 227, 321, 322
Perniosis, 130
Pigmented purpuric dermatosis, 129, 130
Polymorphous light eruption, 252, 254
Porokeratosis, 222
Radiation dermatitis, 315, 316
Reactive perforating collagenosis, 47, 48
Scabies, 125, 126
Sweet syndrome, 141, 143
Urticaria, 21, 22
Zoon balanitis, 135, 136

Panniculitis and other disorders of adipose tissue
Erythema induratum, 144, 150
Erythema nodosum, 145, 150
Lipodermatosclerosis, 276, 278
Lupus profundus, 146, 151, 278
Pancreatic fat necrosis, 277, 278
Polyarteritis nodosa, 147, 150
Subcutaneous fat necrosis of newborn, 148, 151, 278
Subcutaneous T-cell lymphoma, 149, 151

Papulosquamous disorders
Chronic spongiotic dermatitis, 105, 106, 111
Inflammatory linear verrucous epidermal nevus, 223, 227
Lichen simplex chronicus, 105, 107
Pityriasis rubra pilaris, 108, 111, 227
Psoriasis, 27, 28, 100, 101, 105, 109, 111

Spongiotic disorders
Allergic contact dermatitis, 101, 105, 126
Arthropod bite reaction, 103, 126
Chronic spongiotic dermatitis, 105, 106, 111
Eosinophilic spongiosis, 126
Pityriasis rosea, 104, 105, 130
Spongiotic dermatitis, 99, 101
Stasis dermatitis, 188, 191

Vasculitis
Erythema induratum, 144, 150
Granuloma faciale, 138, 142
Leukocytoclastic vasculitis, 128, 130
Polyarteritis nodosa, 147, 150

Malformations
Accessory digit, 77, 81
Accessory nipple, 78, 81
Accessory tragus, 79, 81
Branchial cleft cyst, 61, 68
Bronchogenic cyst (not pictured), 69
Dermoid cyst, 64, 69

Tumors

Benign tumors
Adipose tumors
Angiolipoma, 208
Hibernoma, 204, 216
Lipoma, 208

Adnexal tumors
Follicular
Desmoplastic trichoepithelioma, 53, 58
Fibroepithelioma of Pinkus, 35, 41
Fibrofolliculoma, 36, 41
Pilar sheath acanthoma, 43, 45
Pilomatricoma, 311, 314
Trichilemmoma, 33, 34
Trichoadenoma, 51, 52
Trichoblastoma, 287, 290
Trichoepithelioma, 288, 290
Trichofolliculoma, 44, 45
Tumor of the follicular infundibulum, 40, 41

Glandular (apocrine and eccrine)
Apocrine hidrocystoma, 59, 68
Chondroid syringoma, 291, 294
Cylindroma, 50, 52
Hidradenoma papilliferum, 72, 76
Nodular hidradenoma, 210, 217
Papillary eccrine adenoma, 73, 76
Poroma, 31, 34
Spiradenoma, 286, 290
Syringocystadenoma papilliferum, 74, 76
Syringofibroadenoma, 39, 41
Syringoma, 57, 58
Tubular apocrine adenoma, 75, 76

Sebaceous
Nevus sebaceus of Jadassohn, 37, 41
Sebaceoma (sebaceous epithelioma), 284, 290
Sebaceous adenoma, 212, 217

Fibrous tumors
Dermatofibroma, 166, 176, 262
Dermatofibroma, hemosiderotic, 183, 190
Dermatofibrosarcoma protuberans, 167, 176
Digital fibrokeratoma, 80, 81
Fibrous papule, 184, 191
Giant cell tumor of tendon sheath, 193, 200
Infantile digital fibromatosis, 169, 176
Nodular fasciitis, 170, 177, 301
Scar, 168, 177, 307
Sclerotic fibroma, 313, 314

Melanocytic tumors
Blue nevus, 155, 162
Blue nevus, cellular, 164, 176
Blue nevus, hypopigmented, 260, 262
Deep penetrating nevus, 156, 162
Halo nevus, 118, 122
Intradermal nevus, 162, 258
Mongolian spot, 158, 162
Pigmented spindle cell nevus of Reed, 159, 163
Recurrent nevus, 160, 163
Spitz nevus, 161, 163

Miscellaneous tumors/lesions
Auricular pseudocyst, 60, 68
Bronchogenic cyst (not pictured), 69
Clear cell acanthoma, 26, 28
Cutaneous ciliated cyst, 62, 68
Cutaneous endometriosis, 63, 68
Dilated pore of Winer, 42, 45
Epidermoid inclusion cyst, 65, 69
Florid papillomatosis (erosive adenomatosis) of the nipple, 71, 76
Granular cell tumor, 203, 216
Inverted follicular keratosis, 29, 34
Mastocytoma, 143
Myofibroma, 305, 306
Nipple adenoma, 71, 76
Pilar cyst, 66, 69
Seborrheic keratosis, acanthotic, 32, 34
Seborrheic keratosis, clonal, 228, 236
Seborrheic keratosis, reticulated, 38, 41
Steatocystoma, 67, 69
Venous lake (not pictured), 69

Neural tumors
Accessory digit, 77, 81
Neurofibroma, 172, 177
Neurothekeoma, 299, 301
Palisaded encapsulated neuroma, 173, 177
Schwannoma, 174, 177, 307

Smooth muscle tumors
Accessory nipple, 78, 81
Angioleiomyoma, 178, 190, 306
Leiomyoma, 171, 177

Vascular tumors
Angiokeratoma, 248, 254
Angiolymphoid hyperplasia with eosinophilia, 179, 190
Glomus tumor/glomuvenous malformation (glomangioma), 69, 282, 290
Infantile hemangioma, 185, 191
Lymphangioma, 251, 254
Pyogenic granuloma, 187, 191
Targetoid hemosiderotic hemangioma (hobnail angioma), 189, 191
Tufted angioma, 289, 290

Premalignant lesions/indeterminate biologic behavior
Actinic keratosis, 224, 227
Langerhans cell histiocytosis, 131, 136
Proliferating pilar tumor, 312, 314

Malignant tumors

Carcinomas

Adenoid cystic carcinoma, 49, 52
Aggressive digital papillary adenocarcinoma, 70, 76
Basal cell carcinoma, 281, 290
Basal cell carcinoma, morpheaform, 56, 58
Bowen disease, 25, 28
Merkel cell carcinoma, 283, 290
Metastatic breast carcinoma, 54, 58, 261, 262
Microcystic adnexal carcinoma, 55, 58
Mucinous carcinoma, 292, 294
Paget disease, 233, 237
Sebaceous carcinoma, 285
Squamous cell carcinoma, acantholytic, 244, 247

Melanocytic tumors

Melanoma, 157, 163
Melanoma, balloon cell, 209, 217
Melanoma, desmoplastic, 162, 165, 176

Miscellaneous

Atypical fibroxanthoma, 192, 200
Leukemia, 139, 142, 262
Lymphoma, 140, 143
Mycosis fungoides, 134, 136
Renal cell carcinoma, 211, 217
Subcutaneous T-cell lymphoma, 149, 151

Vascular tumors

Angiosarcoma, 180, 190
Kaposi sarcoma, 175, 176, 186, 191, 262

Alphabetical Index

Acantholysis, 236
Accessory digit, 77, 81
Accessory nipple, 78, 81
Accessory tragus, 79, 81
Acne keloidalis, 137, 142
Acral skin, 14
Actinic keratosis, 224, 227
Adenoid cystic carcinoma, 49, 52
Adipocytic tumors, 7
Adnexal carcinoma, microcystic, 55, 58
Aggressive digital papillary adenocarcinoma, 70, 76
Allergic contact dermatitis, 102, 105, 126
Aluminum chloride (Drysol solution), 255, 259
Amyloid, 308, 314
Amyloidosis, macular (not pictured), 22
Amyloidosis, nodular, 263, 274
Angiokeratoma, 248, 254
Angioleiomyoma, 178, 190, 306
Angiolipoma, 208
Angiolymphoid hyperplasia with eosinophilia, 179, 190
Angiosarcoma, 180, 190
Apocrine adenoma, tubular, 75, 76
Apocrine gland and duct, 9
Apocrine hidrocystoma, 59, 68
Argyria, 18, 22
Arthropod bite reaction, 103, 126
Aspergillosis, 317, 322
Atypical fibroxanthoma, 192, 200
Auricular pseudocyst, 60, 68
Axillary granular parakeratosis, 225, 227
Axillary skin, 17

Bacillary angiomatosis, 181, 190
Back skin, normal, 84, 87
Balanitis circumscripta plasmacellularis, 135, 136
Basal cell carcinoma, 281, 290
Basal cell carcinoma, morpheaform, 56, 58
Benign tumors, 5, 10
Blastomycosis, 93, 96
Blue nevus, 155, 162
Blue nevus, cellular, 164, 176
Blue nevus, hypopigmented, 260, 262
Bowen disease, 25, 28
Branchial cleft cyst, 61, 68
Breast carcinoma, metastatic *see* Metastatic breast carcinoma
Bronchogenic cysts (not pictured), 69
Bullous pemphigoid, 126, 249, 254
Burn, 318, 322

Calcinosis cutis, 48, 264, 274
Carcinoma *en cuirasse*, breast (metastatic breast carcinoma, interstitial pattern), 261, 262
Cholesterolosis, extracellular (erythema elevatum diutinum), 310, 314
Chondrodermatitis nodularis helicis, 182, 190
Chondroid syringoma, 291, 294
Chromomycosis, 94, 96
Chronic spongiotic dermatitis, 105, 106, 111
Ciliated cyst, cutaneous, 62, 68
Clear cell acanthoma, 26, 28
Clonal seborrheic keratosis, 228, 236
Coccidioidomycosis, 95, 96
Cryoglobulinemia (type I), 309
Cryptococcosis, gelatinous, 202, 216
Cylindroma, 50, 52

Darier disease, 238, 246
Deep penetrating nevus, 156, 162
Dermal filler (hyaluronic acid), 272, 274
Dermatitis herpetiformis, 250, 254
Dermatofibroma, 166, 176, 262
Dermatofibroma, hemosiderotic, 183, 190
Dermatofibrosarcoma protuberans, 167, 176
Dermatophytosis, 226, 227
Dermoid cyst, 64, 69
Desmoplastic trichoepithelioma, 53, 58
Digit, accessory, 77, 81
Digital fibrokeratoma, 80, 81
Digital mucous cyst, 295, 301
Digital papillary adenocarcinoma, aggressive, 70, 76
Dilated pore of Winer, 42, 45

Dermatopathology: Diagnosis by First Impression, Third Edition. By Christine J. Ko and Ronald J. Barr.
© 2017 John Wiley & Sons, Ltd. Published 2017 by John Wiley & Sons, Ltd.
Companion website: www.wiley.com/go/ko/dermatopathology3e

Discoid lupus erythematosus, 117, 122, 142
Drysol solution (aluminum chloride), 255, 259

Eccrine adenoma, papillary, 73, 76
Eccrine gland and duct, 9
Elastosis perforans serpiginosa, 46, 48
Endometriosis, cutaneous, 63, 68
Endothelial cells, 8
Eosinophils, 13
Epidermal inclusion cyst, 65, 69
Epidermodysplasia verruciformis, 229, 236
Epidermolytic hyperkeratosis, 230, 236
Erosive adenomatosis of the nipple, 71, 76
Erythema elevatum diutinum, 310, 314
Erythema induratum, 144, 150
Erythema multiforme, 112, 116, 319, 322
Erythema nodosum, 145, 150
Erythropoietic protoporphyria, 265, 274
Eyelid skin, 16

Ferric subsulfate (Monsel solution), 256, 259
Fibroblasts, 8
Fibroepithelioma of Pinkus, 35, 41
Fibrofolliculoma, 36, 41
Fibrous papule, 184, 191
Fibroxanthoma, atypical, 192, 200
Fixed drug reaction, 113, 116
Flegel disease, 221
Florid papillomatosis (erosive adenomatosis) of the nipple, 71, 76
Focal cutaneous mucinosis, 296, 301
Follicular infundibulum, tumor of, 40, 41
Follicular mucinosis, 297, 301

Gel foam, 266, 274
Giant cells, 13
Giant cell tumor of tendon sheath, 193, 200
Glomangioma, 69
Glomus tumor, 282, 290
Gout, 88, 92
Graft-versus-host disease, 114, 116
Granular cell tumor, 203, 216
Granuloma annulare, 48, 89, 92, 130, 262
Granuloma faciale, 138, 142
Grover disease, 239, 246
Guttate psoriasis (not pictured), 104
Gyrate erythema, 127, 130

Hailey-Hailey disease, 240, 246
Hair follicles, 9
Halo nevus, 118, 122
Hemangioma, infantile, 185, 191
Hemangioma, targetoid, 189, 191
Hemosiderin, 257, 259
Herpes (pemphigoid) gestationis, 249
Herpes simplex virus infection, 241, 246, 320, 322
Hibernoma, 204, 216
Hidradenoma, nodular, 210, 217
Hidradenoma papilliferum, 72, 76
Histiocytes, 13
Histoplasmosis, 205, 216
Hyaluronic acid (dermal filler), 272, 274

Ichthyosis vulgaris, 19, 22
Incontinentia pigmenti, 123, 126
Infantile digital fibromatosis, 169, 176
Infantile hemangioma, 185, 191
Inflammatory cells, 13
Inflammatory disorders, 2, 11–13
Inflammatory linear verrucous epidermal nevus, 223, 227
Interface (lichenoid) change, 11
Interface (vacuolar) change, 11
Interstitial inflammation, 12
Intradermal nevus, 162, 258
Inverted follicular keratosis, 29, 34

Juvenile xanthogranuloma, 194, 200

Kaposi sarcoma, 262
Kaposi sarcoma, nodular, 175, 176
Kaposi sarcoma, patch/plaque, 186, 191
Keratin granuloma, 197, 201
Keratinocytic tumors, 7

Langerhans cell histiocytosis, 131, 136
Leiomyoma, 171, 177
Leishmaniasis, 206, 216, 259
Lepromatous leprosy, 207, 216
Leukemia, 139, 142, 262
Leukocytoclastic vasculitis, 128, 130
Lichen myxedematosus (not pictured), 86
Lichen nitidus, 132
Lichenoid drug reactions (not pictured), 119
Lichenoid interface change, 11
Lichenoid keratosis, benign (not pictured), 119
Lichen planus, 119, 122
Lichen sclerosus et atrophicus, 115, 116, 316
Lichen simplex chronicus, 105, 107
Lichen striatus, 120, 122
Lip, 15
Lipodermatosclerosis, 276, 278
Lipoid proteinosis, 267, 274
Lipoma, 208
Lupus profundus, 146, 151, 278
Lupus tumidus, 298
Lymphangioma, 251, 254
Lymphocytes, 13
Lymphoma, 140, 143

Malignant tumors, 5, 10
Mastocytoma, 143
Mastocytosis, 133, 136
Meissner's corpuscles, 14
Melanin, 258, 259
Melanocytic tumors, 7
Melanoma, 157, 163
Melanoma, balloon cell, 209, 217
Melanoma, desmoplastic, 162, 165, 176
Melanoma cells, malignant, 10
Merkel cell carcinoma, 283, 290
Metastatic breast carcinoma, 54, 58
Metastatic breast carcinoma, interstitial pattern, 261, 262
Microcystic adnexal carcinoma, 55, 58
Molluscum contagiosum, 30, 34
Mongolian spot, 158, 162
Monsel solution (ferric subsulfate), 256, 259
Morphea, 82, 87
Morpheaform basal cell carcinoma, 56, 58
Mucinous carcinoma, 292, 294
Mucocele, 293, 294
Mycosis fungoides, 134, 136
Myofibroma, 305, 306
Myrmecium, 231, 237

Necrobiosis lipoidica, 83, 87, 92
Necrobiotic xanthogranuloma, 90, 92
Nephrogenic systemic fibrosis (not pictured), 86
Neural cells, 8
Neurilemmoma *see* Schwannoma
Neurofibroma, 172, 177
Neuroma, palisaded encapsulated, 173, 177
Neurothekeoma, 299, 301
Neutrophils, 13
Nevomelanocytes, benign, 10
Nevus sebaceus of Jadassohn, 37, 41
Newborn, subcutaneous fat necrosis of, 148, 151, 278
Nipple, accessory, 78, 81
Nipple adenoma, 71, 76
Nodular fasciitis, 170, 177, 301
Nodular hidradenoma, 210, 217
Nodular inflammation, 12
"Normal" appearing skin, 18–22
Nutritional deficiency, 227, 321, 322

Ochronosis, 268, 275
Orf, 232, 237
Osteoma cutis, 269, 275

Pacinian corpuscles, 14
Paget disease, 233, 237
Palisaded encapsulated neuroma, 173, 177
Pancreatic fat necrosis, 277, 278
Papillary eccrine adenoma, 73, 76
Papulosquamous changes, 11
Paracoccidioidomycosis (not pictured), 96
Paraffinoma, 270, 275
Parakeratosis, 11
Pemphigoid (herpes) gestationis, 249
Pemphigus foliaceus, 242, 247
Pemphigus vegetans, 124, 126
Pemphigus vulgaris, 243, 247
Perifollicular inflammation, 12
Perivascular inflammation, 12
Perniosis, 130
Pigmented purpuric dermatosis, 129, 130
Pigmented spindle cell nevus of Reed, 159, 163
Pilar cyst, 66, 69
Pilar sheath acanthoma, 43, 45
Pilomatricoma, 311, 314
Pityriasis lichenoides et varioliformis acuta, 121, 122
Pityriasis rosea, 104, 105, 130
Pityriasis rubra pilaris, 108, 111, 227
Plasma cells, 13
Polyarteritis nodosa, 147, 150
Polymorphous light eruption, 252, 254
Porokeratosis, 222
Poroma, 31, 34
Porphyria cutanea tarda, 253, 254
Pretibial myxedema, 300, 301
Proliferating pilar tumor, 312, 314
Pseudoxanthoma elasticum, 271, 275
Psoriasis, 27, 28, 100, 101, 105, 109, 111
Pyogenic granuloma, 187, 191

Radiation dermatitis, 315, 316
Rash, 2, 11–13
Reactive perforating collagenosis, 47, 48
Recurrent nevus, 160, 163
Renal cell carcinoma, 211, 217
Reticulohistiocytosis, 195, 200
Rheumatoid nodule, 91, 92
Rosai-Dorfman disease, 196, 201
Ruptured cyst, 197, 201

Sarcoidosis, 198, 201
Scabies, 125, 126
Scar, 168, 177
Scar, hypertrophic, 307
Schwannoma, 174, 177, 307
Scleredema, 22, 85, 87
Sclerema neonatorum (not pictured), 148
Scleromyxedema, 86, 87
Sclerotic fibroma, 313, 314
Sebaceoma (sebaceous epithelioma), 284, 290
Sebaceous adenoma, 212, 217
Sebaceous carcinoma, 285

Sebocytes, 9
Seborrheic keratosis, acanthotic, 32, 34
Seborrheic keratosis, clonal, 228, 236
Seborrheic keratosis, reticulated, 38, 41
Smooth muscle tumors, 7
Spiradenoma, 286, 290
Spitz nevus, 161, 163
Spongiosis, 11, 105
Spongiotic dermatitis, 99, 101
Sporotrichosis (not pictured), 96
Squamous cell carcinoma, 244, 247
Stasis dermatitis, 188, 191
Steatocystoma, 67, 69
Subcutaneous fat necrosis of newborn, 148, 151, 278
Subcutaneous inflammation, 12
Subcutaneous T-cell lymphoma, 149, 151
Suture granuloma, 199, 201
Sweet syndrome, 141, 143
Syphilis, secondary, 110, 111
Syringocystadenoma papilliferum, 74, 76
Syringofibroadenoma, 39, 41
Syringoma, 57, 58

Targetoid hemosiderotic hemangioma, 189, 191
Tattoo, 259, 273, 275
Tinea versicolor, 20, 22, 227
Tragus, accessory, 79, 81
Trichilemmoma, 33, 34
Trichoadenoma, 51, 52
Trichoblastoma, 287, 290
Trichoepithelioma, 288, 290
Trichoepithelioma, desmoplastic, 53, 58
Trichofolliculoma, 44, 45
Tuberculosis verrucosa cutis (not pictured), 96
Tubular apocrine adenoma, 75, 76
Tufted angioma, 289, 290
Tumor of the follicular infundibulum, 40, 41
Tumors, 2–10

Urticaria, 21, 22

Vacuolar interface change, 11
Venous lakes (not pictured), 69
Verruca plana, 234
Verruca vulgaris, 235, 237
Vitiligo (not pictured), 18

Warty dyskeratoma, 245, 247

Xanthelasma, 213, 217
Xanthogranuloma, 214, 217
Xanthogranuloma, juvenile, 194, 200
Xanthogranuloma, necrobiotic, 90, 92
Xanthoma, 215, 217

Zoon balanitis, 135, 136