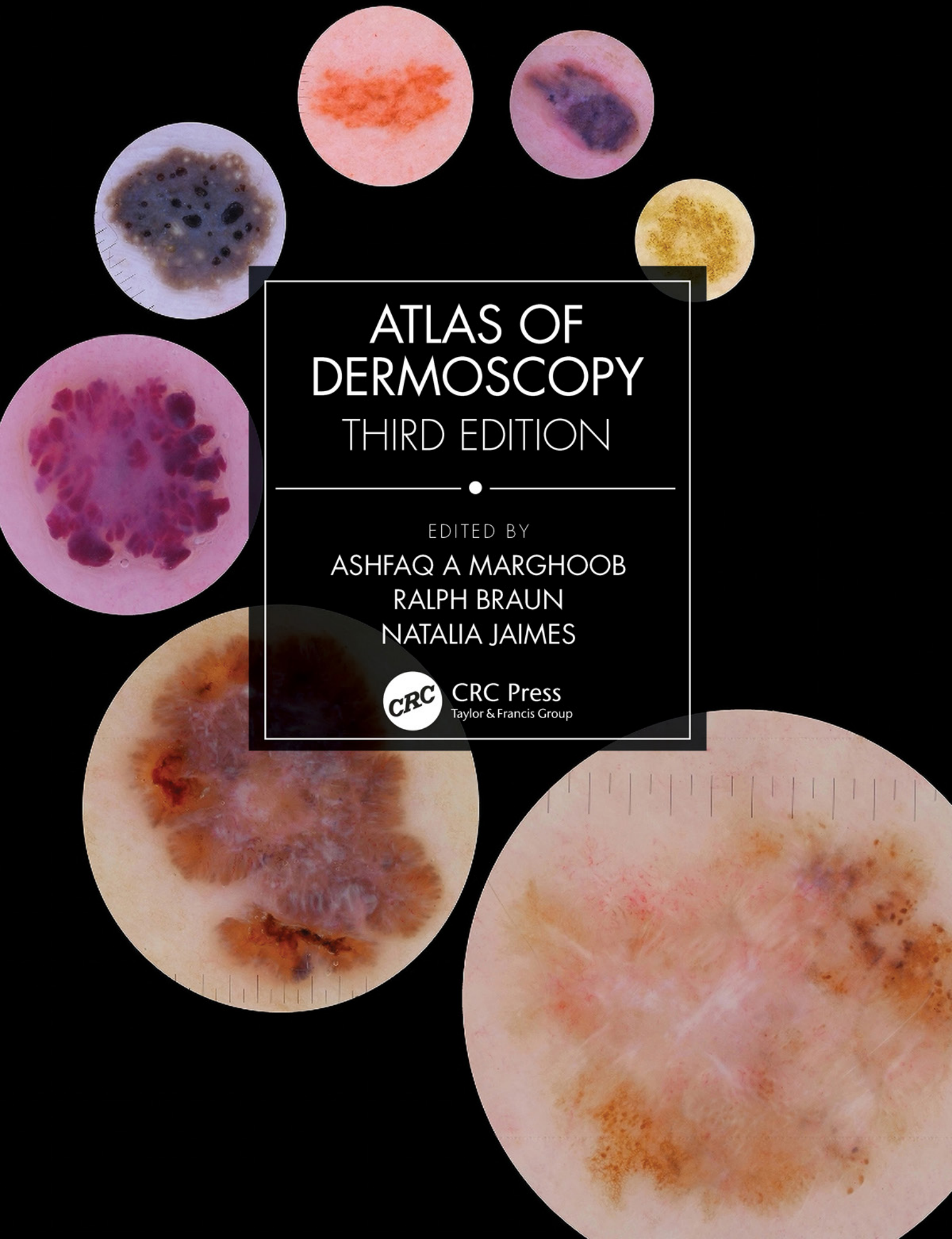

ATLAS OF DERMOSCOPY

THIRD EDITION

EDITED BY
ASHFAQ A MARGHOOB
RALPH BRAUN
NATALIA JAIMES

CRC Press
Taylor & Francis Group

Atlas of Dermoscopy

The much-awaited third edition of the leading reference book in dermoscopy has undergone comprehensive revisions to all chapters, with updates and expanded content providing the reader with a more comprehensive and in-depth coverage of skin conditions, ranging from skin neoplasia to hair, nails, infections, and inflammatory diseases. This compilation of contemporary dermoscopy knowledge will benefit the novice in building expertise and benefit experienced practitioners also by providing nuanced insights. Prepare to embark on a journey of learning as leading international experts in the field of dermoscopy explain via text and annotated exemplar images the amazing world of subsurface cutaneous colors and structures visible through a dermatoscope!

Dedicated to

'The Chosen One', my granddaughter, Madeline Sophie Marghoob

AAM

My son, Alex, and my parents, Ulrike and Fred, for their unconditioned support - you mean the world to me

RB

My husband and daughters, Francisco, Mariana, and Alicia, for being part of my life
My parents and sister, Rey, Olga, and Juli, for showing me different paths of life
My friends, Ash and Harold, for your friendship and endless mentoring
My patients, for being a source of inspiration

NJ

Atlas of Dermoscopy

Third Edition

Edited by

Ashfaq A Marghoob MD
Dermatology, Memorial Sloan Kettering Cancer Centers in Manhattan
Director of the Outpatient Memorial Sloan Kettering Skin Cancer Center in Hauppauge
New York, New York, USA

Ralph Braun MD, PhD
Dermatology, University Hospital Zürich,
Zürich, Switzerland

Natalia Jaimes MD, MS
Dr Phillip Frost Department of Dermatology and Cutaneous Surgery
Sylvester Comprehensive Cancer Center
University of Miami Miller School of Medicine
Miami, Florida, USA

CRC Press
Taylor & Francis Group
Boca Raton London New York

CRC Press is an imprint of the
Taylor & Francis Group, an **informa** business

Third edition published 2023
by CRC Press
6000 Broken Sound Parkway NW, Suite 300, Boca Raton, FL 33487-2742

and by CRC Press
4 Park Square, Milton Park, Abingdon, Oxon, OX14 4RN

CRC Press is an imprint of Taylor & Francis Group, LLC

© 2023 selection and editorial matter, Ashfaq A Marghoob, Ralph Braun, Natalia Jaimes individual chapters, the contributors

First edition published by CRC Press 2004
Second edition published by Routledge 2012

This book contains information obtained from authentic and highly regarded sources. While all reasonable efforts have been made to publish reliable data and information, neither the author[s] nor the publisher can accept any legal responsibility or liability for any errors or omissions that may be made. The publishers wish to make clear that any views or opinions expressed in this book by individual editors, authors or contributors are personal to them and do not necessarily reflect the views/opinions of the publishers. The information or guidance contained in this book is intended for use by medical, scientific or health-care professionals and is provided strictly as a supplement to the medical or other professional's own judgement, their knowledge of the patient's medical history, relevant manufacturer's instructions and the appropriate best practice guidelines. Because of the rapid advances in medical science, any information or advice on dosages, procedures or diagnoses should be independently verified. The reader is strongly urged to consult the relevant national drug formulary and the drug companies' and device or material manufacturers' printed instructions, and their websites, before administering or utilizing any of the drugs, devices or materials mentioned in this book. This book does not indicate whether a particular treatment is appropriate or suitable for a particular individual. Ultimately it is the sole responsibility of the medical professional to make his or her own professional judgements, so as to advise and treat patients appropriately. The authors and publishers have also attempted to trace the copyright holders of all material reproduced in this publication and apologize to copyright holders if permission to publish in this form has not been obtained. If any copyright material has not been acknowledged please write and let us know so we may rectify in any future reprint.

Except as permitted under U.S. Copyright Law, no part of this book may be reprinted, reproduced, transmitted, or utilized in any form by any electronic, mechanical, or other means, now known or hereafter invented, including photocopying, microfilming, and recording, or in any information storage or retrieval system, without written permission from the publishers.

For permission to photocopy or use material electronically from this work, access www.copyright.com or contact the Copyright Clearance Center, Inc. (CCC), 222 Rosewood Drive, Danvers, MA 01923, 978-750-8400. For works that are not available on CCC please contact mpkbookspermissions@tandf.co.uk

Trademark notice: Product or corporate names may be trademarks or registered trademarks and are used only for identification and explanation without intent to infringe.

ISBN: 978-1-138-59598-9 (hbk)
ISBN: 978-0-429-48787-3 (ebk)

DOI: 10.1201/9780429487873

Typeset in Warnock Pro
by Deanta Global Publishing Services, Chennai, India

CONTENTS

Contributors vii
Foreword ix

1 Introduction 1
Ashfaq A Marghoob, Ralph P Braun, and Natalia Jaimes

2 Principles of Dermoscopy and Dermoscopic Equipment 2
Neda Shahriari, Jane M. Grant-Kels, Harold Rabinovitz, Margaret Oliviero, and Alon Scope

3 Histopathologic Correlations of Dermoscopic Structures 9
Daniel Morgado-Carrasco, Constanza Riquelme-Mc Loughlin, Ralph P. Braun, and Oriol Yélamos

4 Primary Diagnostic Algorithms
4a Pattern Analysis Revised 42
Harald Kittler, Cliff Rosendahl, and Alan Cameron
4b Top-Down 2-Step Pattern Analysis Algorithm 50
Ashfaq A. Marghoob, Natalia Jaimes, and Ralph P. Braun
4c A Decision Algorithm for Nonpigmented Skin Lesions 61
Cliff Rosendahl and Aksana Marozava

5 Triage Algorithms
5a A Decision Algorithm for Pigmented Lesions Based on Revised Pattern Analysis ("Chaos and Clues") 70
Cliff Rosendahl and Aksana Marozava
5b Triage Amalgamated Dermoscopy Algorithm (TADA) 81
Natalia Jaimes and Ashfaq Marghoob
5c Other Dermoscopic Algorithms in Skin Cancer Triage 86
Natalia Jaimes

6 Nonmelanocytic Lesions
6a Dermatofibroma 90
Silvia E. Mancebo and Michael A. Marchetti
6b Basal Cell Carcinoma 97
Cristian Navarrete-Dechent, Konstantinos Liopyris, and Ashfaq A. Marghoob
6c Actinic Keratosis 102
Olivier Gaide, Adèle Rakosi, and François Kuonen
6d Actinic Keratosis, Bowen's Disease, Keratoacanthoma, and Squamous Cell Carcinoma 108
Iris Zalaudek, Alan Cameron, Cliff Rosendahl, Shushanik Karapetyan, and Pawel Pietkiewicz
6e Solar Lentigines, Seborrheic Keratoses, and Lichen Planus–Like Keratosis 116
Sarah N. Hocker, Harold S. Rabinovitz, Margaret C. Oliviero, and Ashfaq A. Marghoob
6f Vascular Lesions 125
Nicole Nagrani, Natalie M. Williams, and Natalia Jaimes
6g Clear Cell Acanthoma, Poroma, Sebaceous Hyperplasia, and Other Adnexal Neoplasms 132
Constanza Riquelme-Mc Loughlin, Daniel Morgado-Carrasco, Susana Puig, and Cristina Carrera

7 Benign Melanocytic Lesions
7a Congenital Melanocytic Nevi 139
Natalia Jaimes and Ashfaq A. Marghoob
7b Melanocytic Nevi 146
Konstantinos Liopyris, Cristian Navarrete-Dechent, Silvia E. Mancebo and Michael A. Marchetti
7c Intradermal Nevus 157
Rainer Hofmann-Wellenhof
7d Blue Nevi and Variants 164
Josep Riera-Monroig, Alicia Barreiro, Josep Malvehy, and Cristina Carrera
7e Spitz and Reed Nevi 169
Chryssoula Papageorgiou and Aimilios Lallas
7f Other Nevi 176
Valeria De Bedout and Natalia Jaimes

8 Melanocytic Lesions
8a Superficial Spreading Melanomas....180
Natalia Jaimes and Scott W. Menzies
8b Nodular Melanoma....187
Natalia Jaimes and Scott W. Menzies
8c Lentigo Maligna or Lentiginous Melanoma on Sun-Damaged Skin....190
Rachel Fayne and Natalia Jaimes
8d Acrolentiginous Melanoma....196
Ralph P. Braun, Susana Puig, and Josep Malvehy
8e Other Melanoma Subtypes....202
Cristian Navarrete-Dechent, Konstantinos Liopyris, Natalia Jaimes, and Ashfaq A. Marghoob
8f Amelanotic and Hypomelanotic Melanoma....210
Natalia Jaimes, Juergen F. Kreusch, Giuseppe Argenziano, and Scott W. Menzies

9 Methods to Differentiate Nevi from Melanoma
9a Pattern Analysis and Melanoma-Specific Criteria....216
Konstantinos Liopyris, Cristian Navarrete-Dechent, Natalia Jaimes, and Ashfaq A. Marghoob
9b Rules and Algorithms....220
Natalia Jaimes
9c Rules to Avoid Missing a Melanoma....224
Gabriella Brancaccio, Teresa Russo, Elvira Moscarella, and Giuseppe Argenziano
9d Methods to Improve Sensitivity and Specificity in Melanoma Diagnosis....230
Neda Shahriari, Jane M. Grant-Kels, Harold Rabinovitz, Margaret C. Oliviero, and Alon Scope

10 Collision Tumors and Exceptions to Rules: False Positive and False Negative....237
Andrea Combalia, Xavier Fustà, Alicia Barreiro, and Cristina Carrera

11 Special Locations
11a Face....243
Sarah N. Hocker, Harold S. Rabinovitz, Margaret C. Oliviero, and Ashfaq A. Marghoob
11b Palms and Soles (Volar Surface)....253
Ralph P. Braun, Josep Malvehy, and Susana Puig
11c Mucosal Surfaces and Glabrous Skin on Glans and Labia....263
Natalia Jaimes and Michael A. Marchetti
11d Nails....268
Amélie Boespflug, Félix Pham, Ralph P. Braun, and Luc Thomas
11e Hair and Scalp (Trichoscopy)....281
Anna Waśkiel-Burnat, Lidia Rudnicka, Małgorzata Olszewska, Adriana Rakowska, Ralph M. Trüeb, and Isabel Kolm

12 Dermoscopy in General Dermatology
12a Infectious Diseases....294
Iris Zalaudek, Nicola di Meo, and Paola Corneli
12b Inflammatory Dermatoses (Inflammoscopy)....299
Konstantinos Lallas, Zoe Apalla, and Aimilios Lallas

13 Digital Monitoring: Short- and Long-Term....309
Harald Kittler and Scott W. Menzies

Index....317

CONTRIBUTORS

Zoe Apalla
Hospital of Skin and Venereal Diseases
Thessaloniki, Greece

Giuseppe Argenziano
Department of Physical and Mental Health and Preventive Medicine
University of Campania "Luigi Vanvitelli"
Naples, Italy

Alicia Barreiro
Dermatology Service
Hospital Clinic Barcelona
Barcelona, Spain

Amélie Boespflug
Gustave Roussy Institute
Villejuif, France

Gabriella Brancaccio
Department of Physical and Mental Health and Preventive Medicine
University of Campania "Luigi Vanvitelli"
Naples, Italy

Alan Cameron
School of Medicine
University of Queensland
Brisbane, Australia

Cristina Carrera
Dermatology Service
Hospital Clinic Barcelona
Medicine Department
University of Barcelona

and

Centre for Biomedical Network Research on Rare Diseases (CIBERER)
Carlos III Health Institute
Madrid, Spain

Andrea Combalia
Dermatology Service
Hospital Clinic Barcelona
Barcelona, Spain

Paola Corneli
University of Trieste
Trieste, Italy

Valeria De Bedout
University of Miami Miller School of Medicine
Miami, FL

Nicola di Meo
Giuliano Isontina University Healthcare Company
Policlinico of Milan
Trieste, Italy

Rachel Fayne
University of Michigan School of Medicine
Ann Arbor, MI

Xavier Fustà
Dermatology Service
Hospital Clinic Barcelona
Barcelona, Spain

Olivier Gaide
Dermato-oncology/Interventional Dermatology Unit
Department of Dermatology and Venereology
Lausanne University Hospital
Lausanne, Switzerland

Jane M. Grant-Kels
Dermatology Department
University of Connecticut School of Medicine
Farmington, Connecticut

and

Department of Dermatology
University of Florida College of Medicine
Gainesville, Florida

Sarah N Hocker
Everett, PA

Rainer Hofmann-Wellenhof
Medical University of Graz
Graz, Austria

Shushanik Karapetyan
Association of Dermatovenereology
Yerevan, Republic of Armenia

Harald Kittler
Medical University of Vienna
Vienna, Austria

Isabel Kolm
University of Zürich
Zürich, Switzerland

Juergen F. Kreusch
University of Luebeck
Luebeck, Germany

François Kuonen
Dermato-oncology/Interventional Dermatology Unit
Department of Dermatology and Venereology
Lausanne University Hospital
Lausanne, Switzerland

Aimilios Lallas
Aristotle University
Thessaloniki, Greece

Konstantinos Lallas
Aristotle University
Thessaloniki, Greece

Konstantinos Liopyris
Andreas Syggros Hospital of Skin and Venereal Diseases
University of Athens
Athens, Greece

Josep Malvehy
Dermatology Service
Hospital Clinic Barcelona
Medicine Department
University of Barcelona
Barcelona, Spain

and

Centre for Biomedical Network Research on Rare Diseases (CIBERER)
Carlos III Health Institute
Madrid, Spain

Silvia E. Mancebo
SUNY Downstate Medical Center
Brooklyn, NY

Michael A. Marchetti
Memorial Sloan Kettering Cancer Center
New York, NY

Aksana Marozava
Melanoma Signature Skin Cancer Centre
Capalaba, Australia

Scott W Menzies
Sydney Melanoma Diagnostic Centre
Royal Prince Alfred Hospital
Sydney, Australia

and

Sydney Medical School
The University of Sydney
Sydney, Australia

Daniel Morgado-Carrasco
Dermatology Service
Hospital Clinic Barcelona
Barcelona, Spain

Elvira Moscarella
Department of Physical and Mental Health and Preventive Medicine
University of Campania "Luigi Vanvitelli"
Naples, Italy

Nicole Nagrani
University of Miami Miller School of Medicine
Miami, FL

Cristian Navarrete-Dechent
Melanoma and Skin Cancer Unit
Faculty of Medicine
Pontifical Catholic University of Chile
Santiago, Chile

Margaret C. Oliviero
Skin and Cancer Associates
Plantation, Florida

Małgorzata Olszewska
Medical University of Warsaw
Warsaw, Poland

Chryssoula Papageorgiou
Aristotle University of Thessaloniki
Thessaloniki, Greece

Félix Pham
Public hospitals of Lyon
France

Pawel Pietkiewicz
Greater Poland Cancer Centre
Poznań, Poland

Susana Puig
Dermatology Service
Hospital Clinic Barcelona
Medicine Department
University of Barcelona
Barcelona, Spain

and

Centre for Biomedical Network Research on Rare Diseases (CIBERER)
Carlos III Health Institute
Madrid, Spain

Harold S. Rabinovitz
Medical College of Georgia
Augusta, Georgia

Adèle Rakosi
Dermato-oncology/Interventional Dermatology Unit
Department of Dermatology and Venereology
Lausanne University Hospital
Lausanne, Switzerland

Adriana Rakowska
Medical University of Warsaw
Warsaw, Poland

Josep Riera-Monroig
Dermatology Service
Hospital Clinic Barcelona
Medicine Department
University of Barcelona
Barcelona, Spain

Constanza Riquelme-Mc Loughlin
Dermatology Service
Hospital Clinic Barcelona
Barcelona, Spain

Cliff Rosendahl
School of Clinical Medicine
The University of Queensland
Brisbane, Australia

and

Tehran University of Medical Sciences
Tehran, Iran

Lidia Rudnicka
Medical University of Warsaw
Warsaw, Poland

Teresa Russo
Department of Physical and Mental Health and Preventive Medicine
University of Campania "Luigi Vanvitelli"
Naples, Italy

Alon Scope
The Kittner Skin Cancer Screening & Research Institute, Sheba Medical Center

and

Tel Aviv University School of Medicine
Tel Aviv, Israel

Neda Shahriari
Department of Dermatology
Brigham and Women's Hospital
Harvard Medical School
Boston, Massachusetts

Luc Thomas
Lyon Sud Hospital Centre
Pierre Bénite, France

Ralph M. Trüeb
Center for Dermatology and Hair Diseases Professor Trüeb

and

University of Zürich
Zürich, Switzerland

Anna Waśkiel-Burna
Medical University of Warsaw
Warsaw, Poland

Natalie M Williams
University of Miami Miller School of Medicine
Miami, FL

Oriol Yélamos
de la Santa Creu i Sant Pau Hospital
Autonomous University of Barcelona
Barcelona, Spain

and

Teknon-Quirónsalud Medical Centre
Barcelona, Spain

Iris Zalaudek
Department of Dermatology and Center of Sexually Transmitted Diseases + HIV/AIDS
University of Trieste
Trieste, Italy

FOREWORD

Science is naturally dynamic and evolving. New observations, discoveries, controversies, and reversals of previous theories and concepts are simply the way science evolves. So, it is no surprise that dermatology today is very different than a few decades ago in terms of knowledge and available tools used by the dermatologist at the bedside. The impact, however, that each development or discovery has on the applied science varies significantly, since it depends on numerous additional factors other than the novelty of the discovery itself.

Dermoscopy was one of these discoveries that can be viewed as revolutionary, since not only did it radically modify pre-existing knowledge, but it also transformed the way dermatology is practiced around the world. Today, many clinicians would agree that the morphologic assessment of any skin lesion is incomplete without dermoscopy. Younger colleagues who use dermoscopy from the beginning of their training in dermatology cannot even imagine how dermatology was practiced in the pre-dermoscopy era.

And this is not a matter of numbers, i.e., how much dermoscopy adds to the diagnostic sensitivity or specificity for melanoma or any other tumor or disease. It never was. Most of the studies done to measure the added diagnostic value of dermoscopy served mainly to convince those who refused to accept the obvious truth: Additional morphologic information makes for a better clinician. Today, the use of dermoscopy is rapidly expanding beyond evaluation of tumors to the evaluation of inflammatory, infiltrative, and infectious skin disorders. It is safe to say that dermatology is being re-discovered through the magic lens of the dermatoscope.

The first edition of the *Atlas of Dermoscopy* was written in the era when dermoscopy was considered a "newborn" tool. It was read, re-read, cited, and mimicked by many clinicians, researchers, and authors. Both the first and second editions contributed to the acceptance of dermoscopy all around the world. Since the printing of the second edition of this atlas, the group of dermoscopy adopters, including clinicians and researchers, has grown, and they have contributed enormously to the expansion of dermoscopy knowledge.

In such a rapidly changing field, there was an obvious need for an updated version of one of the most important dermoscopy books. Today, a fresh third edition is released, edited by Natalia Jaimes, Ashfaq A. Marghoob, and Ralph Braun. Not much needs to be said about the editors of this book. Their profound knowledge, brilliant research ideas, and long-standing efforts, as well as their teaching qualities, are known and appreciated worldwide. To me, they are also close friends and precious collaborators. I only need to thank them for putting in all the required effort to provide this masterpiece, which will be, once again, read, re-read, cited, and imitated.

Enjoy reading it!

Aimilios Lallas
Associate Professor of Dermatology
President of the International Dermoscopy Society



Taylor & Francis
Taylor & Francis Group
http://taylorandfrancis.com

1 INTRODUCTION

Ashfaq A Marghoob, Ralph P Braun, and Natalia Jaimes

Dermoscopy has evolved to become an indispensable technique used in the evaluation of skin lesions, rashes, nails, and hair disorders. While the early adopters of dermoscopy were dermatologists specializing in the evaluation of pigmented lesions, today, dermatoscopes can be found in the hands of many general dermatologists as well as many primary care physicians and physician extenders. The dermatoscope has proven to be a cost-effective tool that increases clinicians' diagnostic accuracy and improves their benign-to-malignant biopsy ratio by helping them detect early skin cancers while at the same time minimizing the unnecessary removal of benign lesions.[1–6] The use of this simple looking glass, which is easy to use and implement into clinical practice, has even become a standard technique recommended by various skin cancer screening guidelines for the early detection of skin cancer.[7–9]

As is true for any discipline, the mastery of dermoscopy requires training and practice. This in turn permits the dermoscopist not only to understand the diagnostic significance of what they are seeing through the lens of the dermatoscope but also to gain insights into the histopathology and biology of lesions. In the third edition of this *Atlas of Dermoscopy*, the reader is introduced to the basic principles of dermoscopy, the histopathological correlations of the structures encountered in dermoscopy, and the varied algorithms that have been created to help differentiate benign from malignant skin lesions. These initial chapters serve as the foundation upon which the rest of the chapters in this atlas are based. Subsequent chapters highlight the salient dermoscopic features associated with a myriad of benign and malignant skin lesions, nail lesions, inflammatory lesions, infectious diseases, and hair disorders. In addition, the dermoscopic criteria of lesions on facial skin and the glabrous skin of the palms, soles, and mucosal surfaces differ from the criteria found on nonglabrous skin, and thus, individual chapters are dedicated to assist the clinician in the evaluation of lesions encountered on these so-called special sites.

We encourage readers to reinforce their newly acquired knowledge by using dermoscopy in the evaluation of as many lesions as possible on a daily basis and in as many patients as possible. In addition, viewing dermoscopy images, freely available at sites such as the International Dermoscopy Society, Dermoscopedia.org, and the International Skin Imaging Collaboration, among others, can prove beneficial in learning and knowledge retention. Lastly, taking part in structured dermoscopy courses taught by experts in the field, learning at the patient's bedside with a dermoscopy mentor, and acquiring images of interesting cases and discussing them with colleagues are indispensable methods to acquire expertise in this field.

We are confident that mastering the information in this book will lead to improvements in your diagnostic accuracy and will allow you to deliver the best care possible to your patients. This third edition has been completely rewritten and updated with valuable insights and contributions provided by leading dermoscopy experts from around the world. Newly created schematics and select new exemplar images have been incorporated into this atlas to help facilitate the learning process. Enjoy!

References

1. Noor O, Nanda A, Rao BK. A dermoscopy survey to assess who is using it and why it is or is not being used. *Int J Dermatol.* 2009;48:951–2.
2. Carli P, de Giorgi V, Chiarugi A, et al. Addition of dermoscopy to conventional naked-eye examination in melanoma screening: a randomized study. *J Am Acad Dermatol.* May 2004;50(5):683–9. doi:10.1016/j.jaad.2003.09.009. S0190962203033140 [pii].
3. Argenziano G, Puig S, Zalaudek I, et al. Dermoscopy improves accuracy of primary care physicians to triage lesions suggestive of skin cancer. *J Clin Oncol.* Apr 20 2006;24(12):1877–82. doi:10.1200/JCO.2005.05.0864. 24/12/1877 [pii].
4. Carli P, Mannone F, De Giorgi V, Nardini P, Chiarugi A, Giannotti B. The problem of false-positive diagnosis in melanoma screening: the impact of dermoscopy. *Melanoma Res.* Apr 2003;13(2):179–82. doi:10.1097/01.cmr.0000056224.78713.0b.
5. Benvenuto-Andrade C, Marghoob AA. Ten reasons why dermoscopy is beneficial for the evaluation of skin lesions. *Exp REv Dermatol.* 2006;1(3):369–74.
6. Carli P, De Giorgi V, Crocetti E, et al. Improvement of malignant/benign ratio in excised melanocytic lesions in the "dermoscopy era": a retrospective study 1997-2001. *Br J Dermatol.* 2004;150(4):687–92.
7. Watts CG, Dieng M, Morton RL, Mann GJ, Menzies SW, Cust AE. Clinical practice guidelines for identification, screening and follow-up of individuals at high risk of primary cutaneous melanoma: a systematic review. *Br J Dermatol.* Jan 2015;172(1):33–47. doi:10.1111/bjd.13403.
8. Dinnes J, Deeks JJ, Chuchu N, et al. Dermoscopy, with and without visual inspection, for diagnosing melanoma in adults. *Cochrane Database Syst Rev.* Dec 4 2018;12:CD011902. doi:10.1002/14651858.CD011902.pub2.
9. Clinical Practice Guidelines for the Management of Melanoma in Australia and New Zealand. *Australian Cancer Network Melanoma Guidelines Revision Working Party Sydney and New Zealand Guidelines Group.* Wellington: Cancer Council Australia and Australia Cancer Network; 2008.

DOI: 10.1201/9780429487873-1

2 PRINCIPLES OF DERMOSCOPY AND DERMOSCOPIC EQUIPMENT

Neda Shahriari, Jane M. Grant-Kels, Harold Rabinovitz, Margaret Oliviero, and Alon Scope

Contents

Introduction . . . 2
Principles of nonpolarized dermoscopy . . . 2
Principles of polarized dermoscopy . . . 3
Polarized versus nonpolarized dermoscopy . . . 4
Capturing dermoscopic images . . . 6
Conclusions . . . 7
References . . . 7

Introduction

Dermatoscopy, also known as dermoscopy, uses a handheld microscope called a dermatoscope that is equipped with a magnification lens and a light source. Although unaided (naked-eye) visual inspection of the skin affords the clinician an appreciation of the gross morphologic features of lesions, such as their size, symmetry, shape, colors, contour, and surface topography, dermoscopy is unique in allowing the clinician to see structures not visible to the naked eye. This device allows the observer to survey the subsurface primary morphology of cutaneous lesions through an examination of the stratum corneum to the level of the superficial dermis. For this reason, in the hands of experienced users, dermoscopy can improve the clinician's diagnostic accuracy [3, 11] and confidence level [5] for pigmented [7, 17, 19] and nonpigmented skin lesions.

In the 1970s, Rona MacKie was one of the first clinicians to recognize the advantages of dermoscopy for the preoperative evaluation of equivocal pigmented skin lesions [12, 13]. Thereafter, many clinicians and researchers worldwide have studied it extensively, and significant progress has been made in defining benign and malignant dermoscopic structures and patterns of pigmented and nonpigmented skin lesions. Today, there remains little doubt that dermoscopy is a valuable clinical tool for the noninvasive, in vivo evaluation and diagnosis of cutaneous lesions.

In order to effectively utilize a dermatoscope, every clinician should understand the optical principles of the device. Furthermore, familiarity with both nonpolarized dermoscopy and polarized dermoscopy is crucial to understanding pertinent applications of each modality in the evaluation of pigmented and nonpigmented skin lesions.

Principles of nonpolarized dermoscopy

Dermoscopy provides additional information beyond that gleaned by evaluating the lesion through a simple magnifying lens. To grasp how dermoscopy provides this information requires an understanding of its optical principles, in particular, the interactions of light with the skin. Because the refractive index of the stratum corneum is higher than that of air, much of the incident light is reflected off the surface of the skin (Figure 2.1) [2, 15]; this diffuse backscattered light overwhelms the retina and thereby obscures the visualizing of light that is reflected from the deeper layers of the skin. Consequently, with naked-eye examination, we are mostly able to observe the morphologic features manifest on the surface layer of the skin (stratum corneum) and only minimally able to appreciate the colors and structures located in the deeper layers of the epidermis and the dermis.

The first handheld dermatoscope introduced into clinical practice used a nonpolarized light source to illuminate the skin. Most nonpolarized dermatoscopes (NPD) today contain light-emitting diodes (LEDs) to provide illumination and a 10× magnification lens. Examining lesions with NPD necessitates direct contact of the dermatoscope's glass plate with the skin, and the presence of a liquid interface between them is required; ideally, this immersion liquid should have a refractive index equal to that of skin (Figure 2.2). This setup replaces the normal skin–air interface with a skin–liquid interface. Because there is a closer match of refractive indices within the

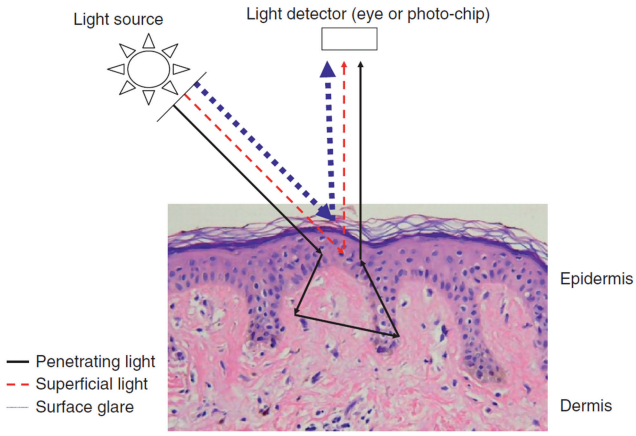

FIGURE 2.1 Schematic representation of optical properties of light without the use of dermoscopy. The arrows indicate the pathway of light through the skin. Some of the light is absorbed by the superficial layers of the epidermis and is scattered only slightly (thin red line), and some of the light penetrates more deeply and undergoes more scattering events (thin black line). However, most of the incident light is reflected off the stratum corneum (thick blue line); this surface glare overwhelms the retina and thereby precludes the observer from visualizing the light reflected from the deeper layers of the skin (red and black lines). Thus, the clinical (nondermoscopic) examination of the skin with or without a magnifying lens only sees the light that is reflected from the skin surface (thick blue line), and therefore, most subsurface structures remain hidden from view.



FIGURE 2.2 Physician examining the skin with a contact nonpolarized dermatoscope.

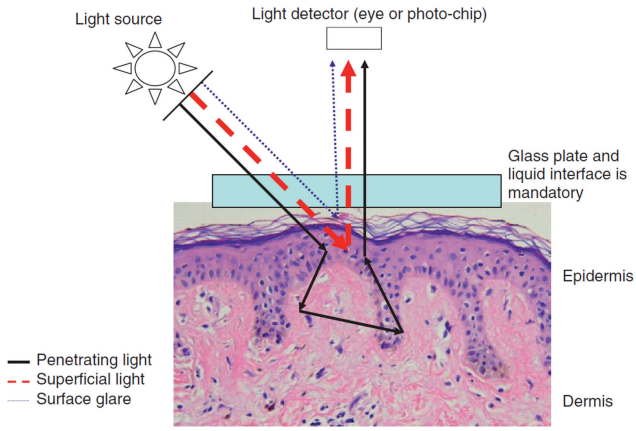

FIGURE 2.3 Schematic representation of optical properties of light during the use of contact NPD with a liquid interface. The arrows indicate the pathway of light through the skin. Most of the light is absorbed and reflected from the superficial layers of the epidermis after undergoing minimal scattering events (thick red line). Some of the light is reflected off the stratum corneum (thin blue line), but this surface glare is insufficient to interfere with the ability to visualize subsurface dermoscopic structures. Some of the light penetrates more deeply and is absorbed and reflected back after multiple scattering events (thin black line); however, the light from the deeper layer contributes only a small fraction to that detected with NPD, and most of the light reaching our eye is from the more superficial, minimally scattered light (thick red line). Abbreviation: NPD, nonpolarized dermoscopy.

skin–liquid–glass interface, light reflection is decreased. As a result, glare is minimized, which in turn makes the stratum corneum appear more translucent. This optical setup permits the observer to see deeper structures in the skin (Figure 2.3). When utilizing NPD, it is imperative that air pockets (i.e., air bubbles) present between the dermoscope's glass plate, the liquid, and the skin be eliminated; such air pockets create a skin–air interface that will preclude the observer from visualizing structures below the stratum corneum.

Different immersion liquids can be used for dermoscopy, including water, mineral oil, alcohol, or gel (i.e., ultrasound gel, antibacterial gel). In one study [8], 70% alcohol was reported to be the best immersion liquid, since it yielded fewer air bubbles and provided clearer images. An added benefit of alcohol is the potential for it to reduce bacterial contamination, and thus, it is more hygienic as compared with other liquids [18]. However, for examination of the nail apparatus, ultrasound or antibacterial gels are superior to alcohol [10, 16], because the gel's viscosity prevents it from rolling off the convex nail surface. It is common to have air bubbles trapped in the gel; the bubbles can be distracting and may prevent the observer from getting a clear view of the lesion. To minimize the number of air bubbles in the gel, it is best to store the gel bottles upside down, to avoid shaking the bottle, and to squeeze out a small amount of the gel before use so as to discard remnant dried gel.

Principles of polarized dermoscopy

Polarized dermoscopy (PD) units were introduced into the clinical arena around the year 2000. These handheld dermatoscopes rely on a different set of optical principles than those described for NPD. The PD devices use two polarizers to achieve cross-polarization. The two polarizers—known as the '"source" polarized filter and the cross-polarized "detector" filter—are oriented perpendicular to each other. The light emitted from the dermatoscope initially passes through the "source" filter, leading to the production of a polarized, unidirectional light, which subsequently interacts with the skin. The reflected light from the skin must then pass through the second "detector" filter in order to be visualized by our eye. For light to pass through the "detector" filter, which is orthogonal to the "source" filter, it must undergo optical rotation. Such 90-degree rotation in the direction of the light wave is dependent on sufficient scattering events through collisions of the light wave with several tissue structures. The light reflected from the stratum corneum or superficial layers of the epidermis does not undergo sufficient scattering events to cause the required optical rotation for passage through the "detector" filter. Hence, light reflected back from the surface and superficial layers of the epidermis is blocked from view by the "detector" filter. However, light penetrating at deeper levels, the dermal epidermal junction (DEJ) and superficial dermis, undergoes sufficient scattering events to allow 90-degree optical rotation and can pass through the "detector" filter (Figure 2.4). On average, polarized light must transverse a distance of between 0.06 and 0.1 mm of skin before sufficient polarized light changes its angle of polarization. Hence, PD allows the backscattered light from the deeper layers of the skin to be captured, and therefore, visualization of the DEJ and dermal structures (e.g. blood vessels) is enhanced. In contrast, superficial structures are poorly visualized (e.g., comedo-like openings in a seborrheic keratosis).

Since surface glare is blocked by cross-polarization, the cross-polarized system does not mandate the use of a liquid interface and does not require direct contact with the skin (Figure 2.5). These innovations may enable the examiner to scan lesions at a relatively faster pace than with NPD. However, PD typically requires stronger LED lighting to compensate for the photons blocked by cross-polarization. It is recommended to ask the patient to close their eyes during examination of the face to avoid directly looking into this strong light source.

Although PD does not mandate direct contact and a liquid interface, the authors' personal experience is that with some dermatoscopes, PD provides higher-quality visualization of dermoscopic structures and colors when used with immersion fluid (e.g., alcohol 70%) and direct skin contact.

More recently, hybrid dermatoscopes have been developed that allow the user to toggle between PD and NPD. These

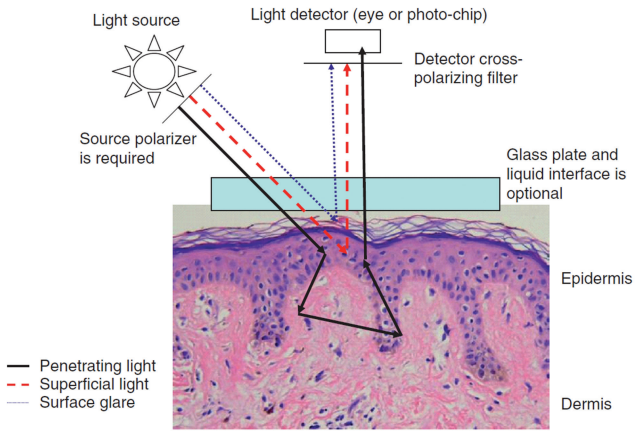

FIGURE 2.4 Schematic representation of optical properties of light during the use of polarized dermoscopy. Light emitted from the dermoscopy unit (source) passes through a polarizer, resulting in the generation of polarized (unidirectional) light. Light reflecting back toward our eye (detector) must first pass through a cross-polarized filter whose direction is perpendicular (orthogonal) to that of the source polarizer. Thus, polarized light cannot pass through the cross-polarizing filter unless the light changes its direction by 90°, which can only occur if the original polarized light undergoes sufficient scattering that changes its direction (i.e., randomization of polarization). Light reflected from the stratum corneum that maintains its original polarization cannot pass through the cross-polarized filter (blue line). Similarly, light that is absorbed by the superficial layers of the epidermis, but does not undergo enough scattering events to result in randomization of polarization, will also be blocked by the cross-polarizing filter (red line). Only light penetrating more deeply and/or undergoing multiple scattering events will result in randomization of polarization (black line). When this light is reflected back, it will be able to pass through the cross-polarization filter, thus allowing the observer to visualize dermoscopic structures. While PD does not require direct contact and a liquid interface, some of the devices have the option for contact PD.



FIGURE 2.5 Physician examining a cutaneous lesion with a polarized noncontact dermatoscope.

"hybrid" dermatoscopes should be applied using direct skin contact with a liquid interface. If this is not done, then the user will see dermoscopic structures only in the polarized mode, and no dermoscopic structures will be discernible with the nonpolarized mode; instead, the observer will simply see a magnified clinical (not dermoscopic) image of the surface of the lesion.

Polarized versus nonpolarized dermoscopy

For most pigmented and nonpigmented skin lesions, PD and NPD offer overall similar images. However, there are some important differences between the two types of dermoscopes (Table 2.1; Figure 2.6) [1, 4, 20].

In general, epidermal structures such as comedo-like openings and milia-like cysts (Figure 2.7a, b) are more conspicuous under NPD due to their epidermal location. A whitish veil due to orthokeratosis (Figure 2.6a, b) is also better seen with NPD. In contrast, dermal structures such as blood vessels (Figure 2.8a, b), vascular blush due to increased blood volume (Figure 2.9a, b), and shiny white structures (previously called crystalline structures) (Figure 2.6a, b) are more conspicuous under PD. The gray-blue granularity (peppering) due to regression (i.e., free melanin in dermis or within melanophages in the superficial dermis) is slightly more conspicuous with NPD, although this will vary depending on the thickness of the skin (epidermis together with the stratum corneum) and the location of the melanin within the dermis. For example, peppering located in the superficial papillary dermis within thin sun-damaged skin of the face will be more conspicuous with NPD.

Besides the features mentioned, there are also slight color differences between PD and NPD. The PD system displays melanin pigment with varying and darker shades of brown and blue compared with NPD (Figures 2.10, 2.11). Although most of the aforementioned differences between PD and NPD are mainly due to the inherent properties of polarized versus nonpolarized light, some of the differences are also due to the effects of pressure being placed (contact dermoscopy) or not being placed (noncontact dermoscopy) onto the skin surface (Figures 2.8–2.15). As mentioned previously, NPD requires a liquid interface and contact with the skin. The pressure applied from the NPD scope against the skin can compress small blood vessels in a lesion, making it difficult to visualize them (Figure 2.8). In fact, as little as 18 mmHg pressure is required to blanch out the blood volume within a lesion (Figure 2.9). Since PD does not require direct contact with the skin, blood vessels and pink color are more evident under PD.

Under PD, a set of dermoscopic structures known collectively as white shiny structures [14] may be seen. The category of shiny white structures includes short shiny white lines, shiny white blotches and strands, and rosettes. These structures will completely disappear when viewed with NPD. This effect is not due to the selective visualization of anatomic depth of PD versus NPD but due to the unique optical properties of polarized light. Polarized light rapidly randomizes its polarization (i.e., causing optical rotation) when it encounters a birefringent structure, such as collagen, and this in turn will make the structure appear bright white. The birefringence of collagen means that its ability to rotate polarized light depends on the orientation of the collagen fibers. Therefore, polarized light will only detect collagen fibers with certain orientations relative to the filter. This property helps explain why white shiny lines seen under PD display only two orthogonal orientations. Also, a user rotating the dermatoscope on its axis while viewing shiny white lines with PD will notice angular dependence, with some shiny white lines disappearing while at the same time a new set of lines appears, with all lines maintaining their orthogonal orientation (Figure 2.6). However, not all shiny white structures are due to collagen. The shiny white blotches and strands seen in basal cell carcinomas (BCC) are likely due

TABLE 2.1: Differences between Nonpolarized Dermoscopy and Polarized Dermoscopy

Colors and structures	Nonpolarized dermoscopy	Polarized dermoscopy
Colors		
Melanin	+	++
Red/pink	+	+++
Blue-white veil (due to melanin underlying orthokeratosis)	+++	+
Gray-blue hue due to dermal regression	+++	++
Structures		
Granularity	+++	++
White shiny lines and strands	–	+++
Blood vessels	+	+++
Milia-like cyst	+++	+/–

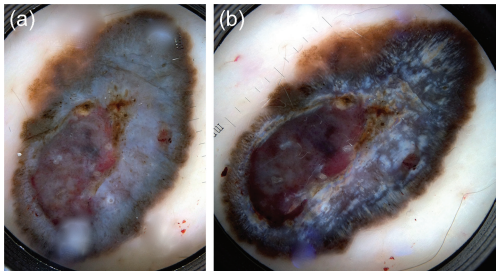

FIGURE 2.6 This is a melanoma 0.9 mm in thickness. Notice that the blue-white veil at the center of the lesion is more conspicuous under NPD and is difficult to appreciate with PD. However, white shiny lines (known also as crystalline structures) can only be seen with PD. Since the whitish veil is due to orthokeratosis overlying the dermal melanin, it will be most conspicuous when viewed with a device that preferentially images the superficial layers (NPD). In contrast, shiny white lines corresponding to altered stromal collagen will only be visible with a device that captures the birefringence of collagen (PD). Image taken with (a) NPD and (b) PD. Abbreviations: PD, polarized dermoscopy; NPD, nonpolarized dermoscopy.

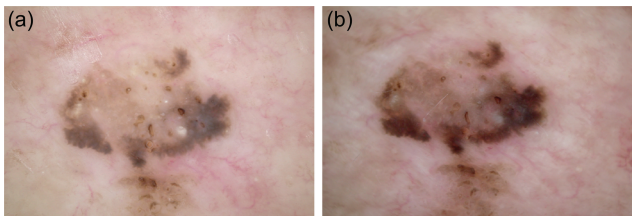

FIGURE 2.7 This is a seborrheic keratosis. Because milia-like cysts are not as visible under PD, this lesion could be misdiagnosed as a melanoma. However, with NPD, the milia-like cysts are readily identifiable, and the correct diagnosis can be rendered with ease. Image taken with (a) NPD and (b) PD. Abbreviations: PD, polarized dermoscopy; NPD, nonpolarized dermoscopy.

to a combination of mucin and the BCC matrix. The rosettes, a shiny white structure composed of four perpendicular white dots, correspond to either keratin-filled adnexal openings or concentric perifollicular fibrosis [9].

Although most lesions can be correctly diagnosed using NPD or PD, the differences between PD and NPD will have an impact on the diagnostic accuracy and level of diagnostic confidence [20]. For example, some seborrheic keratoses may

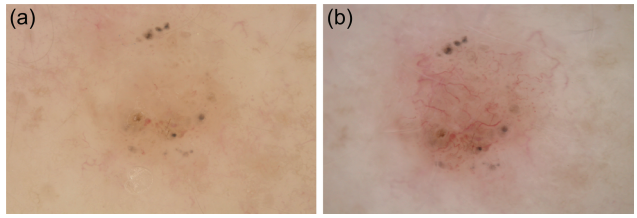

FIGURE 2.8 This is a basal cell carcinoma. Notice that the arborizing blood vessels are better seen with PD than with NPD. This is partially due to the compression of blood vessels during the examination with NPD and partially due to the enhanced ability to visualize deeper structures with PD. Image taken with (a) NPD and (b) PD. Abbreviations: PD, polarized dermoscopy; NPD, nonpolarized dermoscopy.

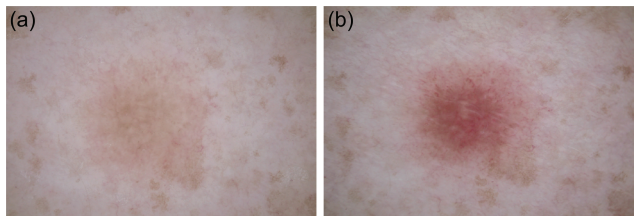

FIGURE 2.9 This is a melanoma 0.3 mm in thickness. Notice that the vascular blush (pink veil due to vasodilation) is better seen with PD than with NPD. This is partially due to the compression of blood vessels during the examination with NPD and partially due to the enhanced ability to visualize blood vessels and red colors with PD. Image taken with (a) NPD and (b) PD. Abbreviations: PD, polarized dermoscopy; NPD, nonpolarized dermoscopy.

be misdiagnosed with PD due to the inability to visualize the milia-like cysts and comedo-like openings with polarized light (Figure 2.7b). However, the same seborrheic keratosis is likely to be easily diagnosed with NPD (Figure 2.7a). The study by Wang et al. showed a statistically significant difference in the diagnostic accuracy of seborrheic keratosis using NPD versus PD (75% vs 59%, P-value <0.0001) [20]. As another example, some amelanotic or structureless melanomas may only be identifiable due to the presence of dotted or polymorphous blood vessels, vascular blush, and/or white shiny lines. These structures can be readily appreciated with PD and are often difficult or impossible to visualize with NPD (Figures 2.6 and 2.9). In the same study by Wang et al., PD had a higher (statistically significant) diagnostic accuracy for the assessment of melanoma versus NPD (34% vs 23%, P-value 0.0008) [20].



FIGURE 2.10 Three images of the same melanoma 1.65 mm in thickness arising in a pre-existing nevus. Image (a) was captured with an NPD using alcohol as the liquid interface. Image (b) was captured using NPD and ultrasound gel as the liquid interface. Image (c) is taken with PD without any direct contact with the skin. These images highlight the effects of placing pressure on the lesion. PD without direct skin contact (image c) allows the blood vessels and vascular blush to be most apparent. Using gel as the liquid interface during NPD allows the operator to apply less pressure on the lesion as compared with NPD when alcohol is used as the fluid interface. As can be seen in the figure, minimizing the pressure being applied onto the skin during NPD examination (image b) will greatly enhance the ability to visualize the blood vessels. Besides the effects of pressure, this case also highlights some of the inherent differences between nonpolarized and polarized light. Notice that white shiny structure can be seen in the PD image (bottom) but is not apparent in the two NPD images. Abbreviations: PD, polarized dermoscopy; NPD, nonpolarized dermoscopy.

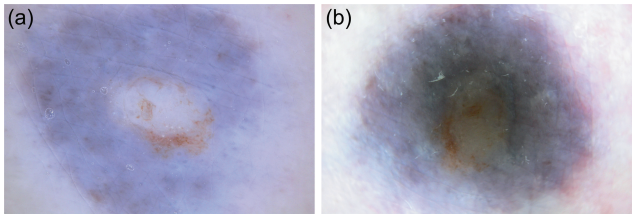

FIGURE 2.11 This is a combined blue nevus. Blue nevi can appear differently on NPD and PD. Under NPD, the lesion has a more homogeneous blue appearance, whereas under PD, the lesion displays varying shades of brown and blue. Image taken with (a) NPD and (b) PD. Abbreviations: PD, polarized dermoscopy; NPD, nonpolarized dermoscopy.

It is clear that PD and NPD can provide complementary and additive information. PD provides maximum sensitivity for detecting a cutaneous malignancy, while NPD provides maximum specificity by correctly identifying lesions such as a seborrheic keratosis. Thus, using both may provide the clinician with the highest diagnostic accuracy. The emergence of "hybrid" dermatoscopes has made this easier by allowing the user to toggle back and forth between PD and NPD. These dermatoscopes can be utilized with direct contact to the skin and a liquid interface to allow both NPD and PD view modes to be effectively and efficiently utilized to view structures at all depths of the skin. NPD will facilitate viewing structures from the stratum corneum to the DEJ, while PD will highlight structures further down, including the DEJ and superficial dermis, as well as birefringent structures. Since NPD is able to highlight milia-like cysts, toggling back and forth on "hybrid" dermoscopes "lights up" the milia-like cysts in seborrheic keratosis, resulting in the "blink sign" [6]. Furthermore, in the case of melanoma or dermatofibroma, toggling highlights shiny white lines, which can be highly informative.

Capturing dermoscopic images

Many clinicians are inclined to document the dermoscopic appearance of lesions by capturing an image of the lesion with a camera. Fortunately, adapters are available for most handheld dermoscopes that permit coupling of the dermatoscope to the camera. In addition, dedicated dermoscopic camera lenses are also available and may be less cumbersome to use as compared with handheld units attached to a camera. These dedicated lenses generally result in the easier acquisition of sharper and clearer images as compared with images acquired through handheld units. Lastly, numerous companies are now producing dermoscopic lenses that can easily be attached to smartphones. The dermoscopic image quality acquired via the

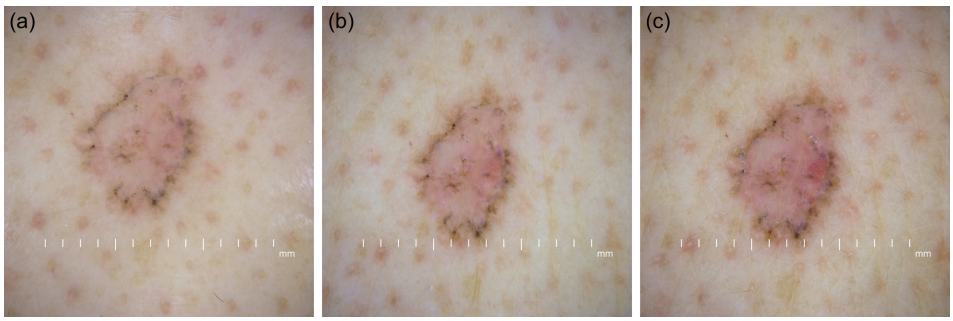

FIGURE 2.12 Dermoscopic images of a superficial basal cell carcinoma. (a) Image with NPD reveals in-focus brown dots, leaf-like areas, and spoke wheel structures. Images (b) and (c) were taken with PD, both of which demonstrate white and pink structures (i.e., shiny white structures, short fine telangiectasias, and vascular blush) in addition to the brown structures seen with NPD (i.e., leaf-like areas and in-focus dots). The main difference of the two PD images is that white and pink/red structures are more conspicuous with noncontact mode (c) than with contact mode (b).

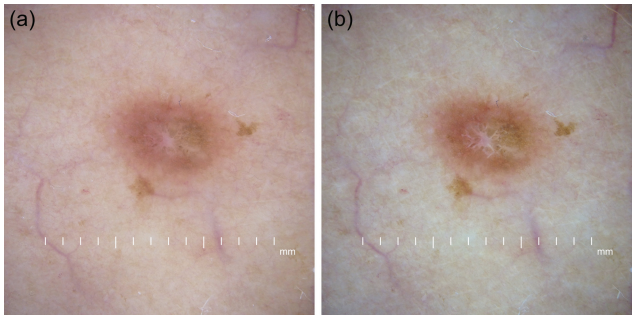

FIGURE 2.13 Dermoscopic images of a dermatofibroma taken with NPD (a) and PD (b). Notice that shiny white lines are only seen with PD (b).

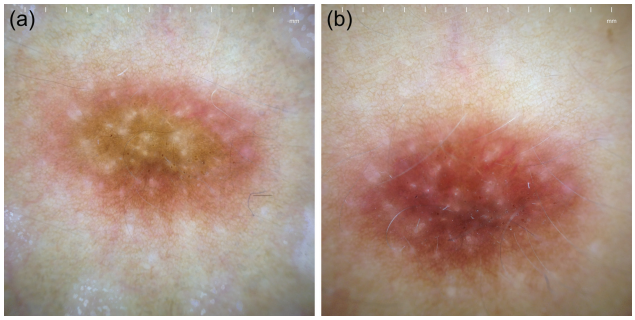

FIGURE 2.14 Dermoscopic images of a dermatofibroma taken with PD contact (a) and noncontact mode (b). Notice that vascular structures (i.e., vascular blush, red colors) are less evident under the contact mode (a) due to compression effects; in contrast, vascular structures (i.e., red color) are enhanced and more conspicuous with noncontact mode (b).

camera on a mobile phone device is on a par with those taken via more traditional methods.

Most images captured today are digitally acquired. These images can easily be stored in the cloud or on hard drives. However, easy retrieval of relevant images may pose a challenge. Multiple image database programs are available that can facilitate the process of organizing and retrieval of images. In addition, multiple systems are commercially available consisting of a dermoscopic imaging device, which is directly linked to a computer. These systems simplify the process of image acquisition, storage, organization, retrieval, and image viewing. Many of these systems have the added benefit of providing computer-based analytical algorithms to assist clinicians in managing skin lesions. Finally, many of the newer total body digital systems afford the acquisition of dermoscopy and the ability to perform serial dermoscopy and link the images to the clinical lesion.

A review on the different types of dermoscopic equipment may be found at: https://dermoscopedia.org/Dermoscopic_equipment

Conclusions

1. Dermoscopy allows the visualization of colors and structures in the subsurface epidermis and dermis.
2. Correct interpretation of structures seen under dermoscopy can improve the clinician's diagnostic accuracy and confidence level for both malignant and benign pigmented and nonpigmented skin lesions.
3. There are differences between the images seen with nonpolarized and polarized dermoscopes. The two types of devices provide complementary information. In general, structures in the superficial epidermis (e.g., milia-like cysts) are more conspicuous with nonpolarized dermoscopes, and deeper structures (e.g., blood vessels) and structures displaying birefringent properties (e.g., collagen) are more conspicuous with polarized devices.
4. To capture dermoscopic images, various imaging devices are available.

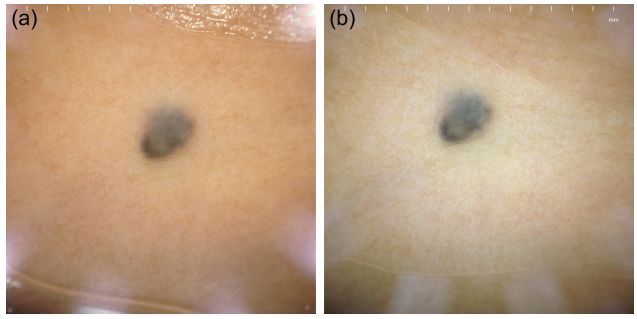

FIGURE 2.15 Dermoscopic image of a blue nevus. NPD demonstrates the classic homogeneous blue steel pattern (a); in contrast, more blue hues are observed with PD (b).

References

1. Agero AL, Taliercio S, Dusza SW, Salaro C, Chu P, Marghoob AA. Conventional and polarized dermoscopy features of dermatofibroma. *Arch Dermatol*. 2006;142:1431–7.
2. Anderson RR, Parrish JA. The optics of human skin. *J Invest Dermatol*. 1981;77:13–19.
3. Bafounta ML, Beauchet A, Aegerter P, Saiag P. Is dermoscopy (epiluminescence microscopy) useful for the diagnosis of melanoma? Results of a metaanalysis using techniques adapted to the evaluation of diagnostic tests. *Arch Dermatol*, 2001;137:1343–50.
4. Benvenuto-Andrade C, Dusza SW, Agero AL, Scope A, Rajadhyaksha M, Halpern AC, Marghoob AA. Differences between polarized light dermoscopy and immersion contact dermoscopy for the evaluation of skin lesions. *Arch Dermatol*. 2007;143:329–38.
5. Benvenuto-Andrade C, Dusza SW, Hay JL, Agero AL, Halpern AC, Kopf AW, Marghoob AA. Level of confidence in diagnosis: clinical examination versus dermoscopy examination. *Dermatol Surg*. 2006;32:738–44.
6. Braun RP, Scope A, Marghoob AA. The "blink sign" in dermoscopy. *Arch Dermatol*. 2011;147(4):520.
7. Carli P, De Giorgi V, Crocetti E, et al. Improvement of malignant/benign ratio in excised melanocytic lesions in the 'dermoscopy era': a retrospective study 1997–2001. *Br J Dermatol*. 2004;150(4), 687–92.
8. Gewirtzman AJ, Saurat JH, Braun RP. An evaluation of dermoscopy fluids and application techniques. *Br J Dermatol*. 2003;149:59–63.
9. Haspeslagh M, Noe M, De Wispelaere I, Degryse N, Vossaert K, Lanssens S, Facchetti F, Van Den Bossche K, Brochez L. Rosettes and other white shiny structures in polarized dermoscopy: histological correlate and optical explanation. *JEADV*. 2016;30(2), 311–3.
10. Kelly SC, Purcell SM. Prevention of nosocomial infection during dermoscopy? *Dermatol Surg*. 2006;32:552–5.

11. Kittler H, Pehamberger H, Wolff K, Binder M. Diagnostic accuracy of dermoscopy. *Lancet Oncol*. 2002;3:159–65.
12. MacKie RM. An aid to the preoperative assessment of pigmented lesions of the skin. *Br J Dermatol*. 1971;85:232–8.
13. MacKie RM. Cutaneous microscopy in vivo as an aid to preoperative assessment of pigmented lesions of the skin. *Br J Plast Surg*. 1972;25:123–9.
14. Marghoob AA, Cowell L, Kopf AW, Scope A. Observation of chrysalis structures with polarized dermoscopy. *Arch Dermatol*. 2009;145:618.
15. Pan Y, Gareau DS, Scope A, Rajadhyaksha M, Mullani NA, Marghoob AA. Polarized and nonpolarized dermoscopy: the explanation for the observed differences. *Arch Dermatol*. 2008;144:828–9.
16. Ronger S, Touzet S, Ligeron C, Balme B, Viallard AM, Barrut D, Colin C, Thomas L. Dermoscopic examination of nail pigmentation. *Arch Dermatol*. 2002;138:1327–33.
17. Salerni G, Teran T, Puig S, et al. Meta-analysis of digital dermoscopy follow-up of melanocytic skin lesions: a study on behalf of the International Dermoscopy Society. *J Eur Acad Dermatol Venereol*. 2013;27(7):805–814.
18. Stauffer F, Kittler H, Forstinger C, Binder M. The dermatoscope: a potential source of nosocomial infection? *Melanoma Res*. 2001;11:153–6.
19. Vestergaard ME, Macaskill P, Holt PE, et al. Dermoscopy compared with naked eye examination for the diagnosis of primary melanoma: a meta-analysis of studies performed in a clinical setting. *Br J Dermatol*. 2008;159:669–76.
20. Wang SQ, Dusza SW, Scope A, Braun RP, Kopf AW, Marghoob AA. Differences in dermoscopic images from nonpolarized dermoscope and polarized dermoscope influence the diagnostic accuracy and confidence level: a pilot study. *Dermatol Surg*. 2008;34:1389–95.

3 HISTOPATHOLOGIC CORRELATIONS OF DERMOSCOPIC STRUCTURES

Daniel Morgado-Carrasco, Constanza Riquelme-Mc Loughlin, Ralph P. Braun, and Oriol Yélamos

Contents

Introduction . . . 10
Colors in dermoscopy . . . 10
Correlates in cutaneous neoplasms . . . 10
- Melanocytic neoplasms . . . 10
  - Pigmented network . . . 10
  - Negative network . . . 11
  - Angulated lines . . . 11
  - Globules . . . 11
  - Dots . . . 13
  - Streaks . . . 13
  - Homogeneous blue pattern . . . 13
  - Blotches . . . 13
  - Regression structures: Granularity/peppering and scarlike depigmentation . . . 15
  - Shiny white structures . . . 15
  - Blue-whitish veil . . . 18
- Melanocytic neoplasms located on special sites . . . 18
  - Facial skin . . . 18
  - Volar skin . . . 19
  - Mucosal sites . . . 22
  - Nails . . . 23
- Nonmelanocytic neoplasms . . . 24
  - Basal cell carcinoma . . . 24
  - Keratinizing tumors . . . 28
  - Seborrheic keratoses . . . 29
  - Angioma and angiokeratoma . . . 29
  - Dermatofibroma . . . 29
  - Lichen planus-like keratosis . . . 30
  - Clear cell acanthoma . . . 30
  - Sebaceous neoplasms . . . 30
  - Porokeratosis . . . 31

Correlates in inflammoscopy . . . 31
- Psoriasis . . . 31
  - Monomorphic red dots . . . 31
- Dermatitis . . . 32
  - Irregularly distributed red dots . . . 32
- Lichen planus . . . 32
- Rosacea . . . 32
  - Polygonal vessels . . . 32
- Granulomatous skin diseases . . . 32
  - Orange-yellowish patches . . . 32

Correlates in infectious skin diseases . . . 32
- Molluscum contagiosum . . . 32
  - White/yellow amorphous structures . . . 32
- Warts . . . 32
  - Multiple dark dots . . . 32
- Scabies . . . 32
  - Dark brown triangular structures . . . 32

DOI: 10.1201/9780429487873-3

Correlates in trichoscopy . . . 34
Yellow dots . . . 34
Black dots . . . 34
Pinpoint white dots . . . 34
White patches . . . 34
Blue-gray dots . . . 34
Empty follicles . . . 35
Absence of follicular openings . . . 35
Peripilar casts . . . 35
Peripilar sign . . . 35
Follicular keratotic plugging . . . 35
Importance of knowing the dermoscopy–histological correlates . . . 35
Conclusion . . . 36
Key points . . . 37
References . . . 37

Introduction

Dermoscopy is a noninvasive, rapid, and inexpensive diagnostic tool that uses a handheld magnification lens attached to a polarized and/or nonpolarized light source. Studies have shown that dermoscopy improves diagnostic sensitivity and specificity for skin cancer [9, 109]. Additionally, it has been used ex vivo in dermatopathology as a tool to select areas for step-sectioning [20, 35]. Since dermoscopy provides a horizontal view (*en face*) of skin lesions and allows the visualization of epidermal and dermal structures invisible to the naked eye, it is the perfect link between the clinical examination and histopathology, because most structures observed under dermoscopy have a direct histopathological correlate. Knowledge of these histopathological correlates can be helpful in accurately interpreting the clinical and dermoscopic information. Dermoscopy can also be beneficial for dermatopathologists, since most dermoscopic structures are visible on the ex vivo specimen. The dermoscopic view of the ex vivo lesion can provide the pathologist with an overview of the lesion before tissue processing and can also help direct the step-sectioning process [118].

In this chapter, we review the dermoscopic and histopathological correlates.

Colors in dermoscopy

Colors can provide valuable information for the dermoscopist. Melanin produces the colors brown, black, gray, and blue, depending on the amount of melanin and its depth within the skin. Lipids, lymph, and keratin produce yellow to orange colors. Collagen appears white and blood as red on dermoscopy [62, 116]. The quantity and location of these chromophores present the spectrum of colors observed with dermoscopy. For example, melanin located in the stratum corneum or the upper epidermis appears black under dermoscopy; when it is located in the mid- or low epidermis, it presents with brown colors, and when it is present in the dermis, it appears as blue or blue-gray colors (Figures 3.1, 3.2) [61, 116].

Some colors, primarily when associated with specific dermoscopic structures, also have essential histopathologic correlates such as white globules, which are associated with balloon cell changes in nevi [39]. Other associations include homogeneous yellow to orange areas linked with cell xanthomization [11] and black lacunae associated with thrombosed vascular spaces in angiomas.

Correlates in cutaneous neoplasms

Melanocytic neoplasms

Pigmented network

The pigment network consists of intersecting brown lines creating a reticular grid-like or fishnet-like pattern with hypopigmented "holes" [48]. Histologically, the lines correspond to melanin within the keratinocytes and the melanocytes

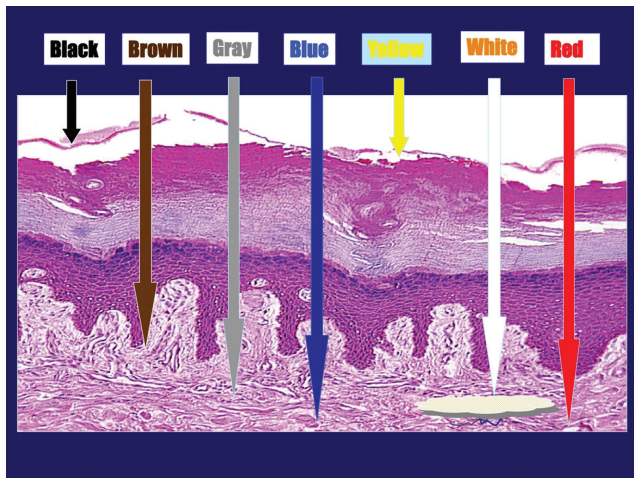

FIGURE 3.1 The quantity and location of melanin, blood vessels, vascular volume, keratinocytes, and collagen all contribute to the colors seen under dermoscopy. The stratum corneum, devoid of blood and melanin, appears yellow. In addition, areas with sebaceous differentiation can also manifest a yellow hue. Blood vessels and vascular volume are responsible for the red and pink hues. White color is due to depigmentation, fibrosis, alterations in the collagen matrix, or keratin within cysts. Melanin appears black when located in the stratum corneum, brown when located at the dermo-epidermal junction, gray when located in the papillary dermis, and blue when located in the deeper dermis. Melanin, when present in multiple layers of the skin, can also appear black. In addition, a jet black color is usually due to congealed blood, and orange hues are due to serum present in erosions or superficial ulcerations.

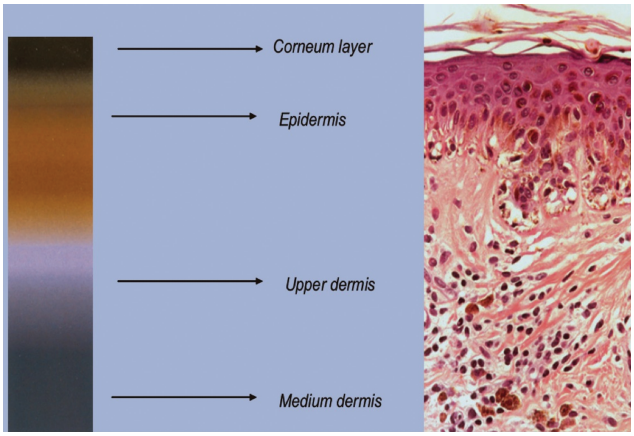

FIGURE 3.2 Colors in dermoscopy depending on the location o melanin in the skin.

along the rete ridges (Table 3.1). The "holes" of the network correspond to the suprapapillary plates (Figures 3.3, 3.4) [63]. The pigmented network can be typical or atypical. The **typical or regular pigment network** is characterized by lines that have minimal variation in their width and color. The typical pigmented network is the hallmark of benign melanocytic nevi with a junctional component. Besides nevi, pigment network can also be seen in nonmelanocytic lesions such as ink- spot lentigo, dermatofibroma, and supernumerary nipple (Table 3.2) [89, 123]. Histologically, the brown lines of the typical network correspond to regular uniform rete ridges [116].

The **atypical pigment network** is irregularly meshed with increased variability in thickness, color (mainly gray color), and distribution. It is associated with dysplastic nevi and superficial spreading melanoma [48]. The histopathology of the atypical pigment network corresponds to disarrangement of the rete ridges, a confluence of melanocytic nests, and changes in melanin distribution within the epithelium [85] (Figure 3.5).

The pigment network is usually absent in the skin of the face due to the presence of a normally flattened dermal-epidermal junction (DEJ) on facial skin. The presence of epidermal pigment in a flattened DEJ together with numerous adnexal openings devoid of pigment, which characterizes facial skin, creates the so-called **pseudonetwork pattern**. Pigment network is also uncommon on the palms and soles due to a specific type of rete ridge anatomy that creates the dermatoglyphics and results in a parallel pigment pattern seen with dermoscopy on volar skin (see later).

Negative network

Negative network, formerly known as "inverse network," consists of elongated to curvilinear brown globular structures with relative hypopigmentation surrounding them. When focusing on the hypopigmented area, it can take on the appearance of serpiginous lighter "lines" surrounding hyperpigmented globular structures [79] (Table 3.1, Figure 3.6). The negative network is most commonly associated with melanoma, especially melanomas arising in nevi [94], and Spitz nevi. Occasionally, it is seen in small congenital-type nevi [79]. Histologically, the hypopigmented lines of the negative network correlate with broadened epidermal rete ridges, which often contain overlying surface dells and wedge-shaped hypergranulosis. The pigmented globules of the negative network correlate with a predominantly junctional proliferation of melanocytes along and between elongated rete ridges [24]. A negative network–like appearance is also seen when there is bridging of adjacent rete ridges or when large melanocytic nests are present within widened dermal papillae that are straddled by thin elongated rete ridges [62] (Figures 3.7, 3.8).

The negative network can be seen with both polarized and nonpolarized light. Another pattern sometimes confused with a negative network is when multiple parallel and orthogonally oriented shiny white lines, seen only with polarized light, intersect, resulting in a grid-like pattern. The shiny white lines (see later section on shiny white structures) are thought to represent collagen and are most often seen in melanoma, Spitz nevi, and dermatofibromas. It is quite common for melanoma and Spitz nevi to manifest both a negative network and shiny white lines within the same lesion.

Another structure that can resemble a negative network is the so-called reticular depigmentation. This structure is most often seen in fibroepithelioma of Pinkus and likely represents the intersecting basaloid cords that characterize this basal cell carcinoma (BCC) subtype. However, a similar feature can also be seen in Spitz nevi and melanoma, and the exact histopathology correlation still requires elucidation. Reticular depigmentation can be seen with both polarized and nonpolarized light, but it is more conspicuous with polarized light, since it is often also associated with shiny white lines.

Angulated lines

Angulated lines are brown to brownish-gray dots that coalesce, forming lines that intersect at acute angles creating a zig-zag pattern, and can further coalesce to create polygonal shapes such as rhomboids [40, 48]. Angulated lines are associated with lentigo maligna (LM) on the head and neck area or with lentiginous melanomas on chronically sun-damaged skin [88, 96]. The angulated lines forming polygons in locations other than the head and neck tend to be larger than the rhomboids seen in LM on the face [40]. Histologically, the angulated to polygonal nature of these lines is still unknown. However, insights from confocal microscopy suggest that they may correspond to the pagetoid spread of melanoma cells within the interfollicular epidermis extending from one follicle to the next [77]. The lines themselves correspond with a constellation of histopathology findings including a flat dermo-epidermal junction (DEJ), the presence of single-cell proliferation of melanocytes along the DEJ with or without pagetoid spread, and the presence of melanophages in the superficial dermis [106] (Figure 3.9).

Globules

Globules are round to oval well-demarcated structures larger than 0.1 mm in diameter. They are usually aggregated or at the periphery of a melanocytic lesion [48]. On histologic evaluation, brown or black globules correspond to nests of melanocytes at the epidermis or DEJ (Figures 3.10, 3.11). Blue globules represent melanocytic nests in the dermis [116]. White globules correspond to melanocytes displaying balloon cell changes. The location and distribution of globules provide valuable information, with globules located along the periphery indicative of horizontal growth in a nevus or a superficial spreading melanoma.

In melanoma, globules vary in size, shape, and color, and are frequently found focally and randomly distributed at

TABLE 3.1: Dermoscopic Structures in Melanocytic Neoplasms

Schematic illustration	Metaphoric term (descriptive term) and histopathological correlate
	Pigment network (lines, reticular) *Lines: pigmented keratinocytes and/or melanocytes along the dermo-epidermal junction* *Spaces between the lines: suprapapillary plate*
	Negative pigment network (lines, reticular, hypopigmented, around brown clods) *Correlation unclear. Suggested to correspond to hypopigmented elongated rete ridges bridging and surrounding large nests of melanocytes within the dermal papillae*
	Angulated lines (lines, angulated or polygonal) *Atypical melanocytes and melanophages in the basal layer*
	Globules (clods, round or oval, aggregated or circumferential) *Nests of nevomelanocytes at the dermo-epidermal junction or dermis*
	
	Streaks (lines, radial [always at periphery]) Radial streaming (lines, radial and segmental)Pseudopods (lines, radial and segmental with knobs at their tips) *Confluent junctional nests of melanocytes growing at the periphery*
	Homogeneous blue pattern (structureless blue) *Dermal population of densely pigmented melanocytes*

Source: Partially reprinted from Dermoscopedia.org with permission of Ralph Braun.

the periphery of the lesion [116]. A focal cluster of globules located eccentrically at the periphery of a raised, otherwise homogeneous melanocytic lesion should raise suspicion for a BAP1-inactivated melanocytic tumor (BIMT), also known informally as a "bapoma" [120] (Figure 3.12). BIMTs are a particular subset of melanocytic nevi with a biphasic cell population consisting of a more banal-appearing dermal cell population corresponding with the globular component and a spitzoid population containing the loss of expression of BAP1 and corresponding with the homogeneous area of the lesion. These lesions may also reveal shiny white areas when viewed with polarized light. Multiple BIMTs have been associated

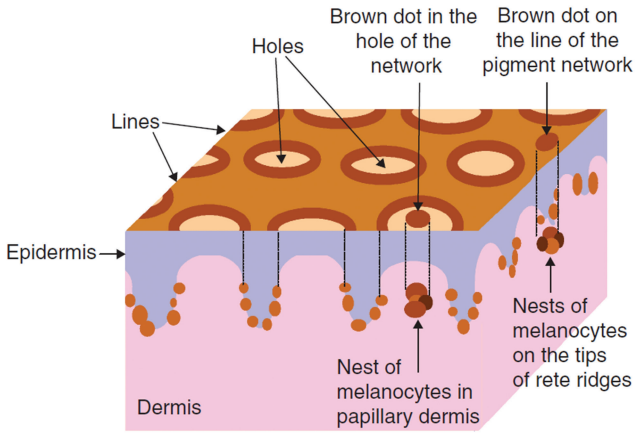

FIGURE 3.3 Schematic representation of the normal pigment network. The lines of the network reflect melanin along the rete ridges, and the holes correspond to the tips of dermal papillae and the overlying suprapapillary plate. The width of the network lines reflects the width of the rete ridges. Brown dots on the network correspond to melanocytic nests at the tip of rete ridges. Brown dots in the hole of the network correspond to small nevomelanocytic nests situated in the papillary dermis.

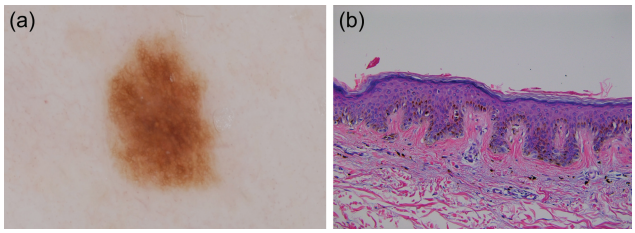

FIGURE 3.4 (a) Dermoscopy shows a regular homogeneous honeycomb-like pigment network thinning out at the periphery. (b) Histology shows the rete ridge pattern. There is more pigment per unit area overlying the rete ridge, and this results in the dermoscopic observation of network lines. There is less pigment per unit area overlying the suprapapillary plate, and this corresponds to the dermoscopic holes in the network (Figure 3.3).

with a cancer syndrome with increased risk for uveal melanoma, cutaneous melanoma, mesothelioma, and renal cell carcinoma, among others [112, 113].

Globules are most commonly found in melanocytic tumors, but blue-grayish globules can also be found in BCC. In BCC, the blue-gray globules are randomly distributed, not aggregated, and correspond to melanin/melanocyte-containing basal cell tumor islands in superficial and early nodular BCC.

Dots

Dots are small, round, and well-circumscribed structures smaller than globules (less than 0.1 mm in diameter, similar to the diameter of a terminal hair follicle) [48]. Their color varies from brown, black, gray, and blue to red. Histologically, brown, black, gray, and blue dots correspond to melanin in different levels of the epidermis or dermis. Specifically, black dots correspond to melanin in the upper epidermis or stratum corneum, brown dots to small melanocytic nests in the epidermis or the DEJ (Figure 3.13), and blue-gray dots to melanin in the upper dermis or in dermal melanophages (e.g., peppering, granularity, regression structures) (Figure 3.14). In nevi, dots are usually associated with a typical network (Figure 3.15). They are clustered in the center, on top of the network lines, or in the holes of the network. In melanomas, dots are distributed in a disorganized manner, maybe found focally at the periphery of the lesions, often not associated with a network, or associated with an atypical network. While brown, black, and blue dots are most often associated with a melanocytic tumors, blue-gray and brown dots can also be seen in BCC. In BCC, the dots are distributed in a random, birdshot scatter pattern and correspond with small aggregates of pigmented superficial BCC cells.

Red dots correlate with vessels in cutaneous tumors and inflammatory conditions [63, 117].

Streaks

Streaks are linear pigmented projections located at the periphery of superficial spreading melanomas or Reed's nevi. They project from the tumor and radiate out towards normal skin. The term *streaks* encompasses radial streaming and pseudopods. Pseudopods correspond to linear projections that contain a bulbous terminal ending (Figures 3.16, 3.17, 3.18), and radial streaming corresponds to linear extensions without such a bulbous ending. Streaks are associated with the radial growth phase of Reed's nevi (Figure 3.19) and superficial spreading melanomas. Histologically, they correspond to linearly confluent junctional nests of pigmented melanocytes at the periphery of the lesion [43, 63]. Symmetrical distribution of streaks around the entire perimeter of a melanocytic lesion favors the diagnosis of a Reed's nevus. Streaks distributed asymmetrically or focally at the periphery favor the diagnosis of superficial spreading melanoma [18] (Figure 3.20).

Homogeneous blue pattern

A homogeneous blue pattern (structureless blue) is characterized by the presence of blue color with the absence of other dermoscopic structures throughout the entire lesion when viewed with nonpolarized light [48]. When viewed with polarized light, one can, on occasion, see shiny white lines. Histologically, a homogeneous blue pattern corresponds to densely pigmented melanocytes or melanophages in the dermis (Figure 3.21). Dermoscopic differential diagnosis is broad and includes blue nevi, areas of extensive regression, pigmented nodular melanoma, epidermotropic metastatic melanoma, nodular pigmented BCC, and radiation tattoos [89, 116].

Blotches

Blotches are heavily pigmented dark brown to black structureless areas occupying more than 10% of the lesion's surface area that preclude the visualization of any other structure [48]. Blotches can be seen in melanocytic lesions, seborrheic keratoses (SK), angiokeratomas, and pigmented BCCs. Blotches can be regular or irregular.

Regular blotch consists of an isolated symmetric, homogeneous, and centrally located blotch, usually seen in melanocytic nevi with a reticular pattern at the periphery. **Irregular blotches** are asymmetric, heterogeneous, and off-centered pigmented areas. The presence of multiple blotches is also considered atypical. Irregular blotches are most frequently associated with melanoma or dysplastic nevi.

TABLE 3.2: Dermoscopic Features with High Specificity for Melanocytic Neoplasms Present in Other Nonmelanocytic Lesions, and Their Histopathologic Correlates

Schematic illustration	Dermoscopic feature	Cutaneous neoplasm or dermatosis and histopathologic correlate
	Pigment network	**Seborrheic keratosis** *Coalescence of rete ridges with pigmented basaloid cells* **Accessory nipple** *Areolar epidermal hyperplasia* **Ink spot lentigo** *Hyperpigmentation of basal keratinocytes* **Dermatofibroma** *Hyperpigmentation of basal keratinocytes*
	Pigmented globules	**Basal cell carcinoma** *Small, pigmented tumor islands* **Dermatofibroma** *Flattened, confluent, hyperpigmented rete ridges* **Clonal seborrheic keratosis** *Compact nests of pigmented keratinocytes*
		
	Streaks	**Basal cell carcinoma** *Tumor nests at the periphery of the lesion* **Seborrheic keratosis** *Coalescence of rete ridges with pigmented basaloid cells*
	Homogeneous blue	**Seborrheic keratosis** *Compact areas of pigmented keratinocytes* **Radiation tattoo** *Ink deposited in the dermis* **Basal cell carcinoma** *Dermal pigmented tumor nests with melanocytes and melanophages*

Source: Partially reprinted from Dermoscopedia.org with permission of Ralph Braun.

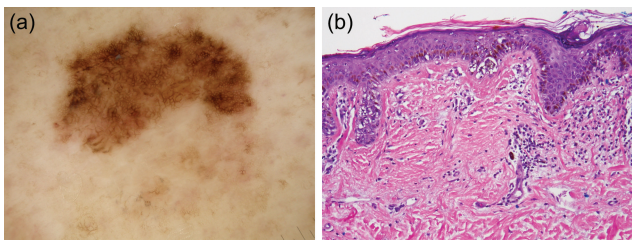

FIGURE 3.5 (a) The dermoscopic appearance of this lesion reveals an atypical network. (b) The atypical network corresponds histologically to melanin along rete ridges that vary in size, amount of melanin, and spacing. These architectural changes explain the atypical pigment network as seen in dermoscopy.

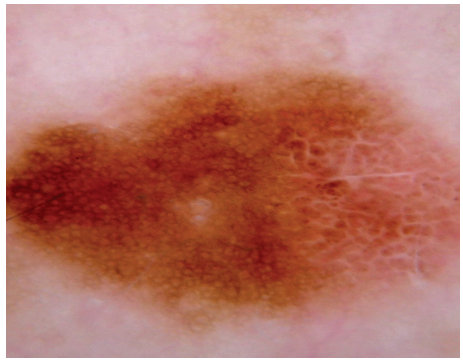

FIGURE 3.6 Dermoscopy shows a pigmented lesion with a reticular architecture on the left side and a negative pigment network on the right side.

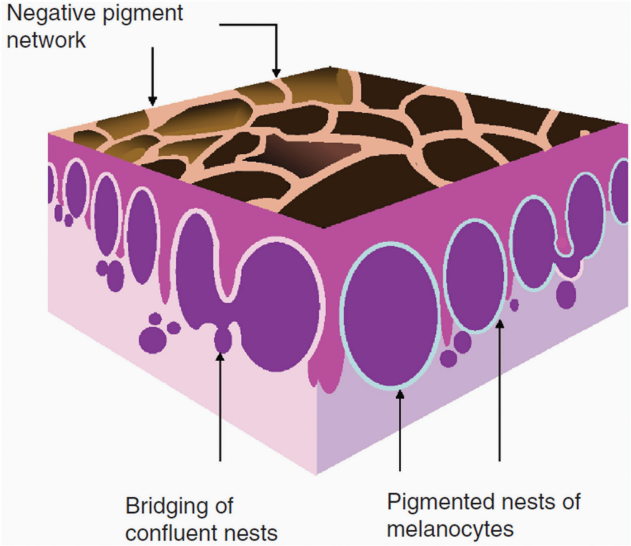

FIGURE 3.7 Schematic drawing of a negative pigment network.

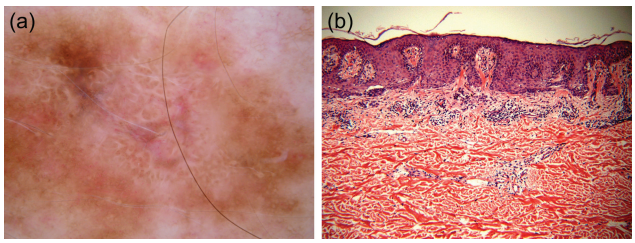

FIGURE 3.8 (a) Dermoscopy image of a melanoma with a negative pigment network. (b) Histopathologically, the negative network appears to correspond to elongated rete ridges accompanied by large melanocytic nests within a widened papillary dermis or to bridging of adjacent rete ridges.

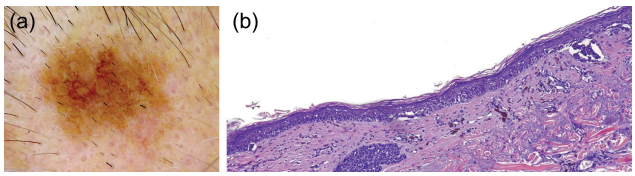

FIGURE 3.9 (a) Dermoscopic image of a lentigo maligna melanoma on the head, showing angulated lines. (b) Histopathologically, angulated lines correspond to a flattened dermo-epidermal junction (DEJ), presence of single-cell proliferation of melanocytes along the DEJ, and the presence of melanophages in the superficial dermis.

Histologically, blotches correspond to abundant melanin in one or more layers of the epidermis with or without pigment in the underlying dermis [117] (Figure 3.22). A specific type of blotch known as black lamella arises due to the presence of excessive melanin in the stratum corneum. This is usually a transient structure seen in some nevi after excessive ultraviolet exposure resulting in the accumulation of melanin in the stratum corneum, forming black dots and lamellar blotches. Since black lamella and black dots are due to melanin in the stratum corneum, they can be removed by tape-stripping off the upper layers of the stratum corneum. Removing the lamella via the tape-stripping procedure permits visualizing the underlying dermoscopic structures [32, 46] (Figure 3.23). Blotches due to excessive melanin in areas below the stratum corneum cannot be tape-stripped away.

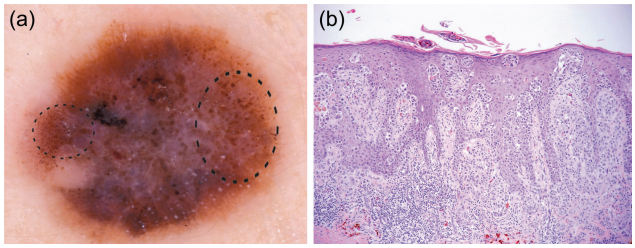

FIGURE 3.10 (a) Superficially spreading melanoma (Breslow 1.1 mm). Dermoscopy shows multiple dots and globules (area enclosed by dashed oval) varying in size and irregularly distributed throughout the lesion. (b) Histology shows nested melanocytes in stratum corneum and in the epidermis, resulting in dots and globules as seen under dermoscopy.

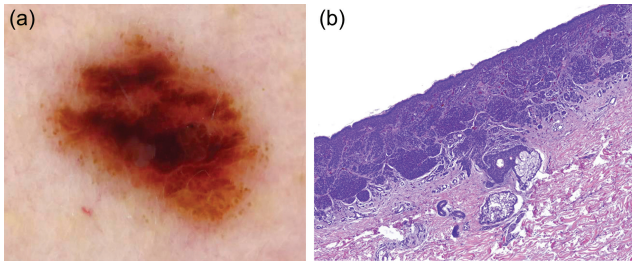

FIGURE 3.11 (a) Dermoscopy of a compound melanocytic nevus with multiple globules and dots in the periphery. (b) Histology shows multiple nested melanocytes in superficial dermis.

Regression structures: Granularity/ peppering and scarlike depigmentation

Regression structures encompass granularity, also known as peppering, and scarlike depigmentation. These two dermoscopic structures can occur together or independently of each other. The areas displaying regression structures will be flat and nonpalpable.

Granularity or peppering consists of multiple tiny gray dots. Histopathologically, granularity/peppering correlates with free melanin in the dermis or within melanophages and can be seen in regression areas within a melanoma, in lichen planus-like keratosis (LPLK) (Figure 3.24), and occasionally in melanocytic nevi, among others [125].

Scarlike depigmentation or scarlike areas are white structureless areas that are lighter in color compared with surrounding perilesional skin. This scarlike area often has a porcelain-white color. In melanocytic lesions, the scarlike areas usually will not display shiny white lines or vessels [48]. Histopathologically, scarlike areas correspond to dermal fibrosis [63] (Figures 3.25, 3.26), and sectioning through the scarlike area will often reveal nondiagnostic features.

Shiny white structures

Shiny white structures (SWS), formerly known as crystalline structures and chrysalis, are only seen with polarized

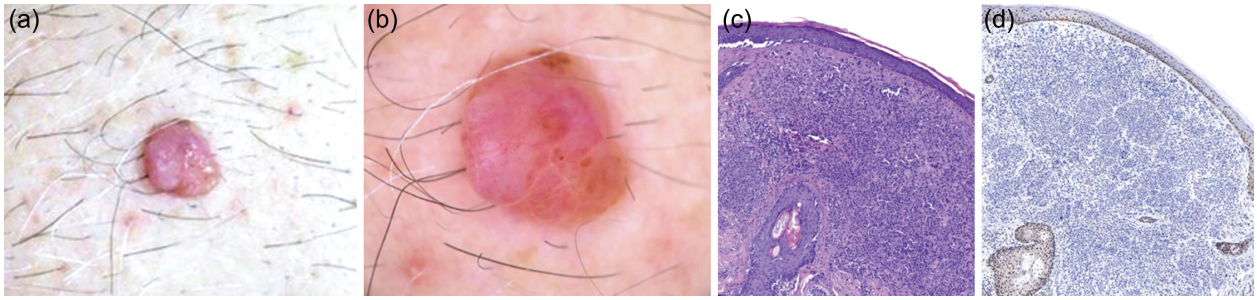

FIGURE 3.12 (a) Clinical image of a BAP1-inactivated melanocytic tumor or "bapoma." (b) Dermoscopy shows focal cluster of globules located eccentrically at the periphery of a raised homogeneous lesion. (c) Histology reveals a central atypical melanocytic proliferation surrounded by a banal-looking proliferation at the periphery. (d) The central atypical population shows loss of BAP-1 immunostain, correlating with the central homogeneous area seen in dermoscopy.

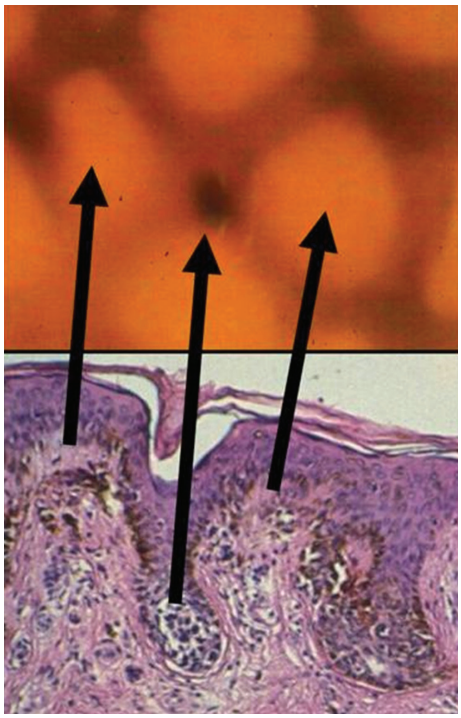

FIGURE 3.13 This shows the correlation between dermoscopy and histology: brown dots, resulting from nevus nests located at the tips of rete ridges, will appear to be situated overlying the network lines.

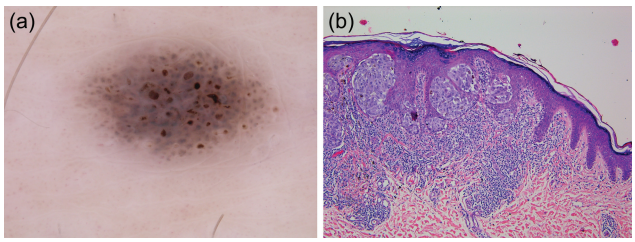

FIGURE 3.14 (a) Dermoscopy reveals a Spitz nevus with a globular pattern. The globules display different sizes, shapes, and colors, including browns, black, and blue-gray. (b) The globules correlate with nests of melanocytes in the dermis. The different colors of the globules are a function of the degree of melanization and the depth within the dermis where they are located.

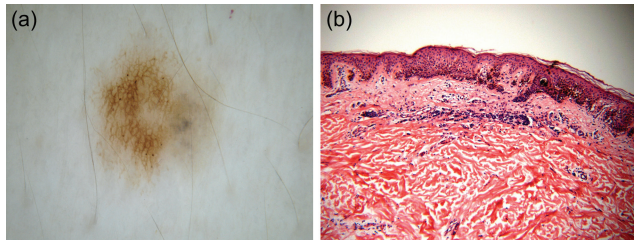

FIGURE 3.15 (a) Dermoscopy of this junctional nevus reveals multiple black dots overlying the pigment network. (b) Histology shows accumulations of melanin pigment within the stratum corneum.

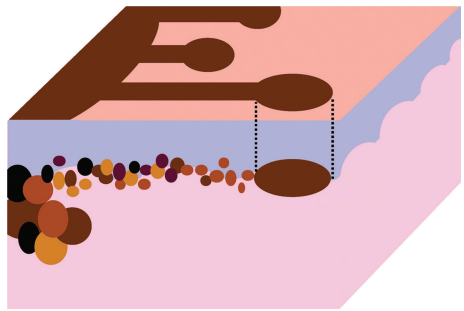

FIGURE 3.16 Schematic drawing of a pseudopod, showing horizontal confluent nests of melanocytes.

dermoscopy. Three morphologies of SWS have been identified: 1) **shiny white blotches and strands,** seen primarily in BCC; 2) **rosettes,** seen primarily in actinic keratosis (AK)/squamous cell carcinoma (SCC); and 3) **shiny white lines,** seen in melanoma, Spitz nevi, LPLK, and dermatofibroma, among others [79, 93] (Figure 3.27).

Shiny white lines manifest as short white lines that are oriented parallel or orthogonal to each other [48]. These lines also display angular dependence, which means that the lines will become more or less conspicuous as the polarized dermatoscope is rotated around the lesion while keeping your eye in one fixed position. These parallel and orthogonally oriented short white lines can sometimes intersect, creating square-shaped structures. When many such structures are present adjacent to each other, they can create what looks like a white grid-like pattern. This grid-like pattern should not be confused with a negative network or with reticular depigmentation, neither of which

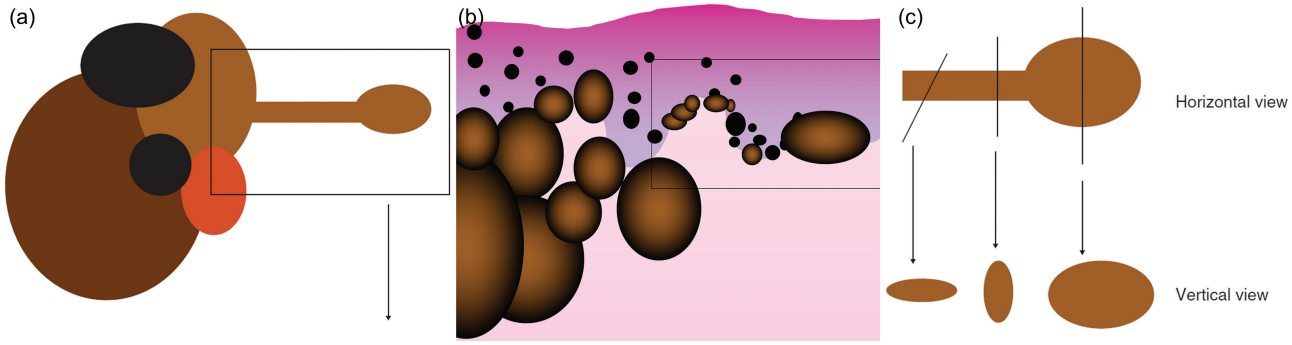

FIGURE 3.17 Schematic representation of pseudopods (a), which correspond to confluent junctional nests of melanocytes (b). Depending on which area of the pseudopod is sectioned on histology (c), the pathologist will see this structure either as a circular cluster of cells of varying diameters or as an oval-shaped cluster of cells. Only if the pathology section passes exactly through the longitudinal axis of a pseudopod will the pathologist be able to recognize this structure as confluent junctional nests.

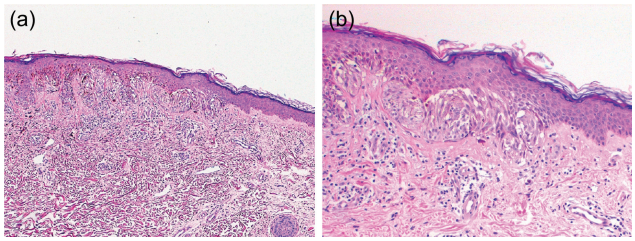

FIGURE 3.18 (a) and (b) Histology of a pseudopod at different sections, showing confluent junctional nests of melanocytes.

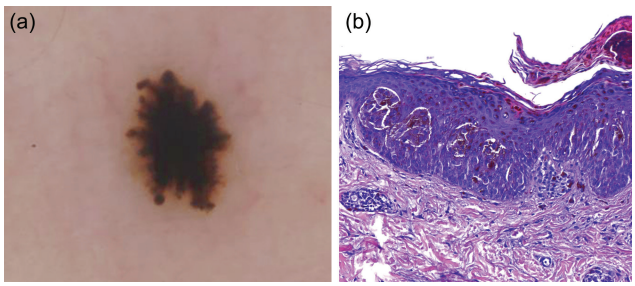

FIGURE 3.19 (a) Dermoscopy of a Reed nevus, revealing pseudopods at the periphery of the lesion. (b) Histology of the pseudopods shows linearly confluent melanocytic nests at the periphery.

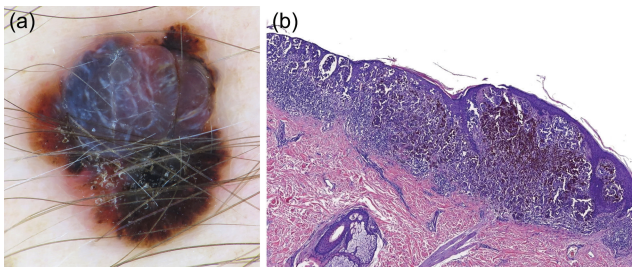

FIGURE 3.20 (a) Clinical image of a large superficial spreading melanoma 8 cm in diameter (Breslow 1.7 mm). The boxed-in area is highlighted in Figure 3.18b. (b) Dermoscopy shows multiple pseudopods at the periphery. (c) The pseudopods correlate on histology to junctional confluent radial nests of melanocytes.

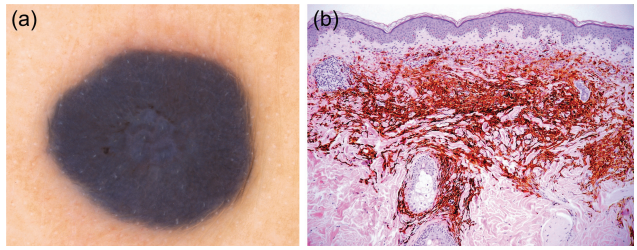

FIGURE 3.21 (a) Blue nevus. Dermoscopy shows a homogeneous blue-white veil encompassing the entire surface area of the lesion. (b) Histology shows pigmented dendritic spindle-shaped cells in the dermis.

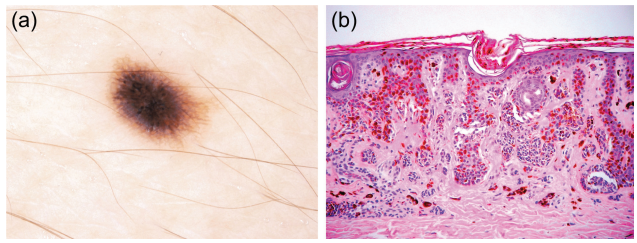

FIGURE 3.22 (a) Dermoscopy shows a dark central hyperpigmentation area (blotch) that is obscuring the ability to visualize any underlying structures. (b) Histology image showing melanin pigment in the stratum corneum, epidermis, and dermis.

displays angular dependence. Histologically, shiny white lines are presumed to correspond to birefringent collagen bundles, which are thought to be altered or new as a result of the tumor's influence on the fibroblast and/or stroma [79]. In melanomas, the presence of shiny white lines is often associated with dermal invasion [10].

Shiny white blotches and strands are associated with BCC. The strands are thought to correspond to stromal alternation. The blotches may represent stromal alteration around BCC tumor islands or may represent collections of mucin.

Rosettes are produced when polarized light interacts with keratin-filled ostial openings. While multiple keratin-filled ostial openings are commonly found in AK and SCC, isolated

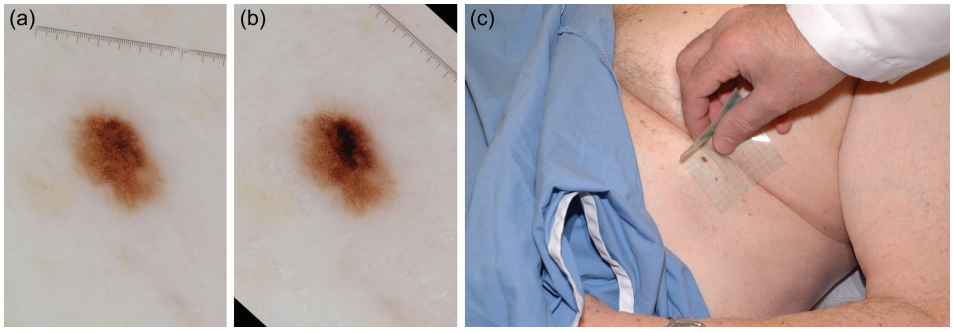

FIGURE 3.23 (a) This melanocytic lesion appears to have an off-center located blotch, making it suspicious for melanoma. (b) However, a simple tape-stripping procedure discloses that the presumed blotch is actually a black lamella. (c) After removal of the black lamella, the underlying typical network becomes apparent, thus obviating the need for a biopsy of this benign reticulated nevus. The black lamella will usually reappear 3–12 months after the tape-stripping procedure.

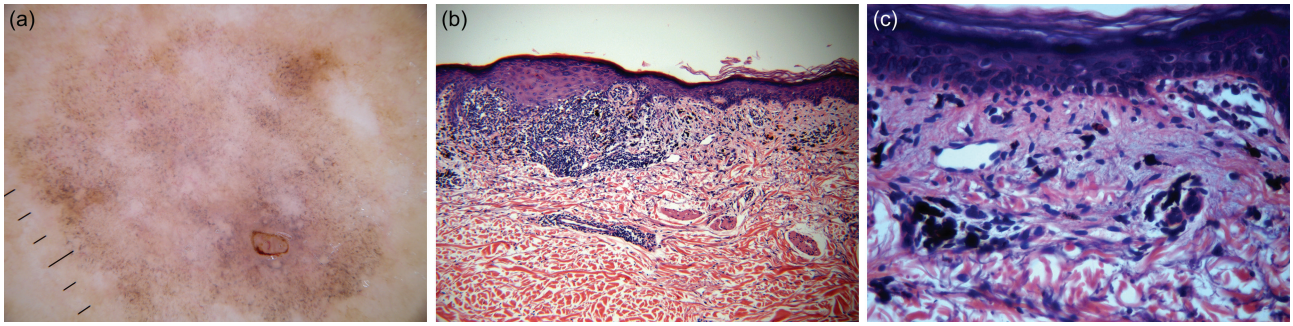

FIGURE 3.24 (a) Dermoscopy of this lichen planus–like keratosis reveals multiple blue-gray dots and granules (also called "granularity") throughout the lesion. (b, c) On histopathology, the granularity correlates with melanophages and free melanin in the dermis.

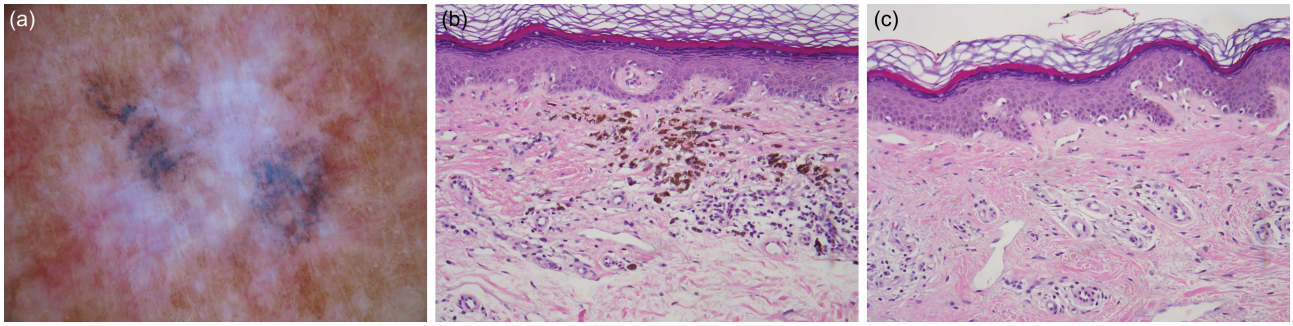

FIGURE 3.25 (a) Dermoscopy of a melanoma revealing regression structures consisting of both scarlike depigmentation and peppering (granularity). (b, c) The histology shows fibrosis and melanosis.

keratin-filled ostial openings can be found in actinically damaged skin and even occasionally in normal skin.

Blue-whitish veil

The blue-whitish veil (BWV) consists of a structureless blue area with an overlying white "ground-glass" haze. Clinically, the BWV corresponds to the raised/palpable areas of a pigmented lesion [18] (Figure 3.28). Histologically, it corresponds to heavily pigmented melanocytes in the dermis in combination with acanthosis and compact orthokeratosis [63, 64] (Figure 3.29). The BWV is most often associated with melanoma but can also be seen in Reed's nevi. A BWV-like appearance can occasionally be seen in heavily pigmented nodular BCC [18, 124] or heavily pigmented SK (melanoacanthoma); however, in pigmented SKs, the BWV is almost never structureless but is studded with multiple comedo-like openings and milia-like cysts [5].

Melanocytic neoplasms located on special sites

The microanatomy of the rete ridge pattern of facial, volar, mucosal, and nail lesions differs from that of the remaining nonglabrous skin. As a result, in these special locations, the pigmented network is usually absent, and lesions tend to display their own unique dermoscopic patterns depending on the anatomic site (Table 3.3).

Facial skin

Facial skin is characterized by a thin epidermis with a thin stratum corneum, relatively flat DEJ, and multiple pilosebaceous

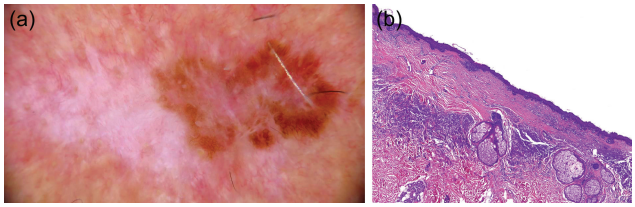

FIGURE 3.26 (a) Dermoscopy of a melanoma (Breslow 0.3 mm) showing scarlike depigmentation on the left. (b) On histopathology, extensive dermal fibrosis is observed within that area.

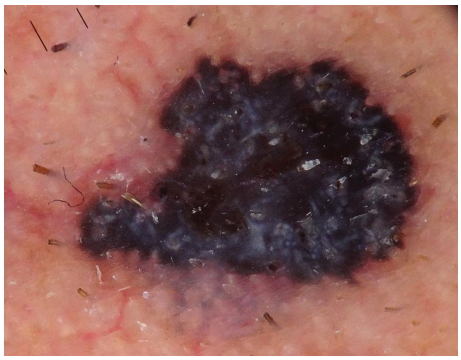

FIGURE 3.27 Dermoscopy of a melanoma (Breslow 0.6 mm) revealing shiny white lines/streaks and rosettes. Shiny white lines have been associated with invasive melanomas, whereas rosettes can occur in any sun-damaged tissue.

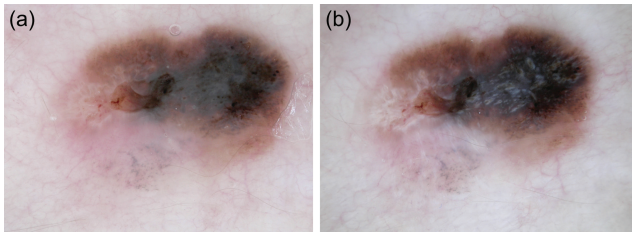

FIGURE 3.28 (a) Nonpolarized dermoscopy image reveals a conspicuous blue-white veil. (b) The blue-white veil becomes less obvious in polarized dermoscopy. Polarized light dermoscopy image showing multiple shiny white lines (chrysalis/crystalline-like structures). Notice that the crystalline structure can only be seen in polarized dermoscopy.

units. These unique microanatomical features result in the so-called **pseudonetwork pattern**. Thus, the pseudonetwork pattern emerges when brown structureless/homogeneous pigmented areas are interrupted by hypopigmented holes corresponding to the adnexal openings [48]. Histologically, the pseudonetwork pattern corresponds to pigmented cells/melanin located in the epidermis with a flattened DEJ interrupted by adnexal/follicular openings [62, 88]. Diagnosis of pigmented tumoral lesions located on the face can be challenging, since most display a pseudonetwork pattern. However, evaluating the local features around and between follicular openings can assist in the diagnosis.

While intradermal nevi (IDN) are commonly found on the face, acquired lentiginous junctional nevi are rarely found on facial skin. Thus, for lentiginous facial lesions, the main differential lies between a solar lentigo and LM. The features associated with LM range from peri-adnexal changes to interfollicular changes, both of which lead to disruption of the regular/organized pseudonetwork pattern [28, 88].

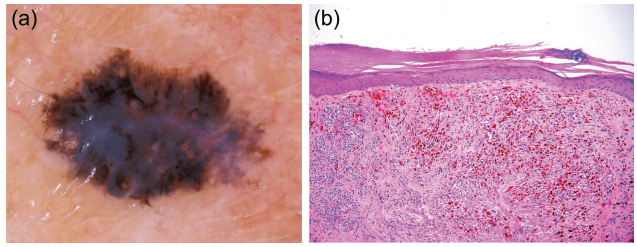

FIGURE 3.29 (a) Dermoscopy of a superficial spreading melanoma (Breslow 0.3 mm) showing a central blue-white veil. (b) Histology reveals aggregation of heavily pigmented cells in the dermis in association with compact orthokeratosis.

The **annular-granular pattern** is the earliest change in LM, consisting of perifollicular changes characterized by tiny gray to brown dots around follicular openings, asymmetric pigmentation around follicular openings (incomplete circles), gray circles, concentric circles (circle within circle or isobar), and target-like pattern (dot within a circle). Histologically, gray dots correspond to free melanin in the dermis or within melanophages. Brown dots likely correspond to small aggregates/nests of melanocytes. The asymmetric pigmentation, which often has a gray hue around follicular openings, corresponds with melanocytes extending focally down one portion of the hair follicle [43].

The **concentric circles** correspond to increased pigmentation (i.e., increased number of melanocytes) in the follicular epithelium together with increased pigmentation in a rete ridge surrounding the follicle [75]. While rete ridges are not common on the face, for unknown reasons, they can be seen on occasion around follicles that harbor melanoma.

Interfollicular changes start to become apparent on dermoscopy as LM advances. The earliest of these changes consists of pigmented follicular extensions, which are seen best when the dermoscopic image is magnified (Figure 3.30) [77]. This feature is often associated with concentric circles. Next, pigmentation starts to appear between follicles, creating **angulated lines** (Figure 3.9). These angulated lines correspond to a constellation of findings on histopathology, including flattening of the DEJ, pagetoid spread of melanoma, and presence of melanophages in the dermis [106]. These angulated lines often coalesce to form polygonal shapes, with the most common being a rhomboid (Figure 3.31). The pigmentation eventually coalesces further into **dark blotches**. Initially, these blotches will still reveal preserved follicular openings, but as the melanoma advances, the follicles get obliterated, and the blotch becomes a solid dark area. The features of LM are summarized in Table 3.3 (face) [56, 88, 103].

Volar skin

The palmoplantar skin is characterized by a thick cornified layer, the presence of dermatoglyphics, and the absence of hair follicles. Two main patterns have been described for melanocytic lesions on volar skin: the parallel furrow pattern and the parallel ridge pattern.

The **parallel furrow pattern** is characterized by thin parallel pigmented lines in the furrows, and it is generally associated

TABLE 3.3: Dermoscopic Structures Present in Melanocytic Neoplasms Located in Special Sites

	Schematic illustration	Metaphoric term (descriptive term) and histopathological correlate
Volar skin		Parallel Furrow Pattern (lines, parallel, thin, in the furrows) *Pigmented keratinocytes and melanocytes in the furrows (crista limitans)*
		Parallel Ridge Pattern (lines, parallel, thick, on the ridges) *Melanocytes around the rete ridges associated with the acrosyringia (crista intermedia)*
Face Lentigo maligna Benign feature		Pseudonetwork (structureless, brown, interrupted by follicular openings) *Pigmented cells in the epidermis and the dermal-epidermal junction interrupted by follicular openings*
		Concentric circles or circles within circles (circles, concentric) *Junctional proliferation of atypical melanocytes along the dermal-epidermal junction with varying degrees of follicular and dermal invasion* Gray circles (circles, gray) *Junctional proliferation of atypical melanocytes along the dermal-epidermal junction with varying degrees of follicular and dermal invasion* Asymmetric pigmented follicular openings (circles, incomplete) *Junctional proliferation of atypical melanocytes along the dermal-epidermal junction with varying degrees of follicular and dermal invasion*
		Rhomboids/zig-zag pattern (lines, angulated or polygonal, surrounding adnexal openings) *Junctional proliferation of atypical melanocytes along the dermal-epidermal junction with varying degrees of follicular and dermal invasion*
		Blotches with obliteration of follicles (structureless zone, brown-black, with loss of visible adnexal openings) *Junctional proliferation of atypical melanocytes along the dermal-epidermal junction with varying degrees of follicular and dermal invasion*
Mucosa		Dotted/globular patterns (dots or clods, round or oval, brown) *Aggregates of melanin in the upper lamina propria*
		Homogeneous pattern (structureless area, brown) *Flattened rete ridges and acanthosis*

TABLE 3.3 (Continued): Dermoscopic Structures Present in Melanocytic Neoplasms Located in Special Sites

	Schematic illustration	Metaphoric term (descriptive term) and histopathological correlate
		Ring-like pattern (circles, brown) *Hyperpigmented epithelial cells and broadened rete ridges that skip the papillae*
		Fish scale–like pattern (half circles, brown) *Hyperpigmented epithelial cells and broadened rete ridges that skip the papillae*
		Parallel, reticular-like or hyphal pattern (lines, slightly angulated, brown) *Hyperpigmentation of the tip of the rete ridges, which are distributed obliquely*
		Homogeneous pattern with the presence of blue, gray, or white colors (structureless areas with blue, gray, or white color) *Suspicious for mucosa melanoma*
Nails	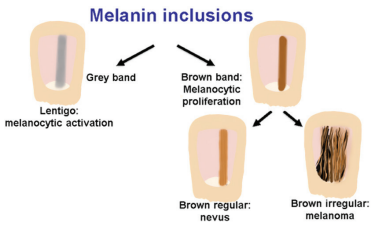	Regular pigmented bands (parallel lines originating from the proximal nail fold without variation in colors, thickness, or spacing) *Most likely reveals a benign condition in the nail matrix* Irregular pigmented bands Most likely reveals a melanoma in the nail matrix

Source: Partially reprinted from Dermoscopedia.org with permission of Ralph Braun.

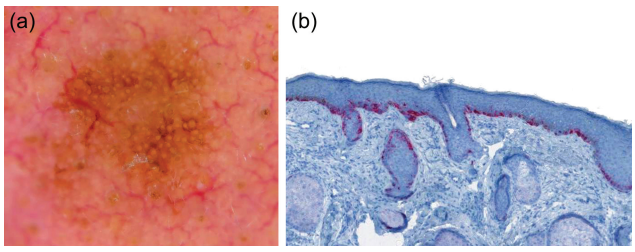

FIGURE 3.30 (a) Dermoscopy of a lentigo maligna showing perifollicular and interfollicular pigmentation. (b) Immunohistochemistry reveals lentiginous spread of melanocytes surrounding hair follicles (Melan-A).

with benign melanocytic lesions. Histologically, the parallel furrow pattern corresponds to nevomelanocytes located in the rete ridges called crista limitans, which corresponds to the dermatoglyphic furrows (sulcus superficialis). It is interesting to note that nevomelanocytes located in the crista limitans transfer pigment to overlying keratinocytes, but the nevomelanocytes located in the rete ridges named crista profunda intermedia, which correspond to the crista superficialis (ridge), do not. It is because of this that the presence of a furrow pattern is associated with nevi on volar skin [38]. In contrast, melanoma believed to arise from stem cells residing around the eccrine ducts within the crista profunda intermedia results in the observation of pigment on the ridges, creating the **parallel ridge pattern** associated with acral melanoma [76] (Figure 3.32). Histologically, the parallel ridge pattern reveals melanocyte proliferation around the rete ridges associated with the acrosyringia (crista profunda intermedia) [38] (Figure 3.33).

A variant of the parallel furrow pattern is the **lattice-like pattern,** which is characterized by parallel pigmented lines in the furrows accompanied by pigmented lines crossing the ridges connecting one parallel furrow to another. Whereas the lattice-like pattern is commonly seen in nevi located on the arch of the foot, the furrow pattern is commonly seen between the

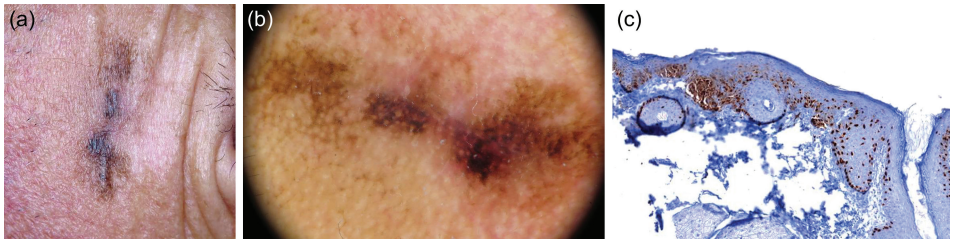

FIGURE 3.31 (a) Clinical image of a preauricular lentigo maligna. Dermoscopy shows dark brown polygonal structures and obliteration of follicular openings. (b) On immunohistochemistry, a lentiginous spread of melanocytes, together with nests and pagetoid spread of atypical cells surrounding hair follicles, is observed (HMB-45).

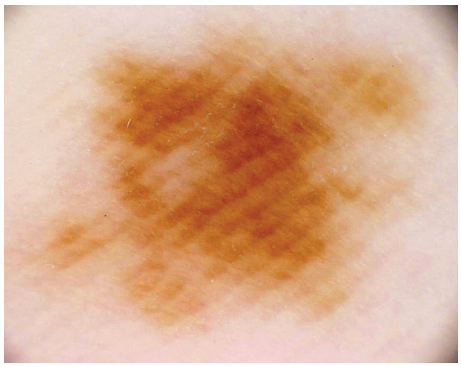

FIGURE 3.32 Dermoscopy of an acral melanoma revealing a parallel ridge pattern.

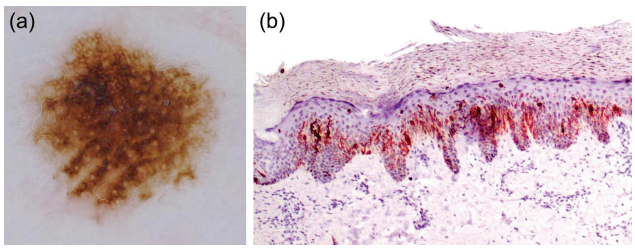

FIGURE 3.33 (a) Dermoscopy of an acral melanoma with parallel ridge pattern. (b) Immunohistochemistry reveals melanocytic pagetoid spread and melanocyte proliferations around the rete ridges (Melan-A).

the lattice-like pattern can be considered an anatomical variant of the parallel furrow pattern (Figure 3.34) [86].

Melanocytic lesions on weight-bearing surfaces on the sole or lesions on the palms that are chronically subjected to shearing frictional forces display a pattern called the fibrillar pattern. The **fibrillar pattern** consists of pigmented lines that are oriented diagonally across both the furrows and the ridges. All the thin fibrillar lines are oriented in the same tangential direction. This pattern arises due to repetitive mechanical pressure, resulting in the thickened stratum corneum growing out at a slant. In other words, as the vertically oriented epidermal keratinocyte melanin pigment columns enter the stratum corneum, they start to angle towards the direction of the mechanical frictional forces. This is the histopathologic correlate of the fibrillar pattern. The fibrillar pattern can be seen in both nevi and melanomas located on the pressure-bearing surfaces of volar skin. Applying the dermatoscope to the skin and viewing the lesion at an angle or applying pressure counter to the

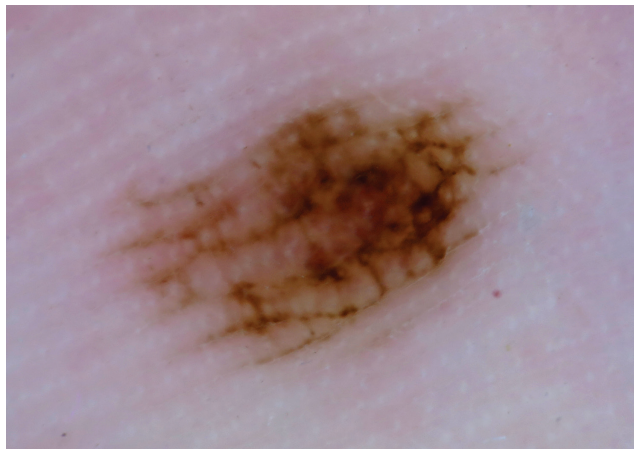

FIGURE 3.34 Dermoscopy of a plantar nevus shows a lattice-like pattern (a variant of the parallel furrow pattern).

frictional forces may assist in determining whether the fibrillar pattern is arising from columns of pigment in the furrows or from the ridges [49, 65, 70, 78].

Mucosal sites

The microanatomy of mucosal skin differs from that of other sites on the skin in that it usually lacks a corneal layer. In addition, the rete ridge pattern can be attenuated or consist of widened or thin rete ridges. This unique microanatomy accounts for the principal structures seen with dermoscopy, including structureless brown areas, dots, globules, lines, and circles [119]. The patterns observed in benign melanocytic lesions on mucosae are listed in Table 3.3.

The **homogeneous pattern** is composed of structureless brown areas on dermoscopy. Histologically, it reveals flattened rete ridges with acanthosis [60]. The **ring-like pattern** presents with pigmented circles. A variant of the ring-like pattern is the **fish scale–like pattern**, which consists of half circles. Both the ring-like (circle pattern) and the fish-scale (half circles) pattern share the same histopathological correlation, revealing hyperpigmented widened rete ridges with skip areas of pigmentation at the top of narrow dermal papillae [25, 60]. The **parallel pattern** is composed of brown linear to slightly curved lines [25] (Figure 3.35), and the **hyphal pattern** consists of nonlinear lines resembling fungal hyphae. Histologically, they correspond to hyperpigmentation at the tip of the obliquely elongated rete [60]. Lastly, the **dotted-globular pattern** presents with multiple dots/globules with similar sizes and shapes and corresponds to locally aggregated melanin in the upper dermis [60].

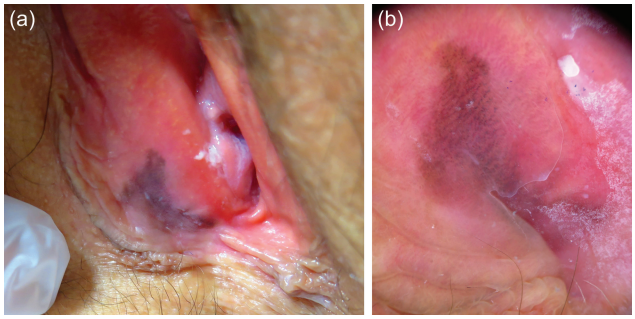

FIGURE 3.35 (a) Clinical image of a vulvar melanosis. (b) Dermoscopy showing a brownish parallel pattern (top of the lesion) and grayish lines and dots.

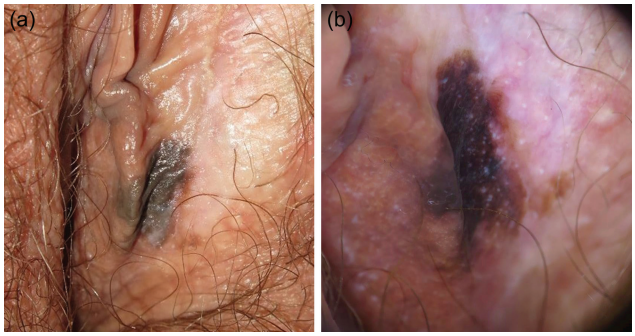

FIGURE 3.36 (a) Clinical image of a vulvar melanoma. (b) Dermoscopy shows an asymmetric ill-delimited pigmented lesion with a multicomponent pattern, multiple colors, and structureless areas. (c) Immunohistochemistry reveals an atypical melanocytic proliferation with pagetoid spread and fusion of rete ridges (Melan-A).

A **multicomponent pattern** consisting of blue, gray, and white colors, regression structures, BWV, and structureless areas is associated with mucosal melanomas [14, 60] (Figure 3.36). Recently, a study of 14 early-stage vulvar melanoma dermoscopies most often revealed structureless areas, gray globules and areas, blue and white structures, and red areas and irregular black–brown dots [105]. Histologically, the correlation is similar to that described for nonmucosal locations.

Nails

The diagnosis of melanonychia striata is challenging due to the fact that under normal circumstances, the source of the pigment is often not directly visible, since it is usually located in the nail matrix, which is located below the cuticle and nail plate. The resulting pigment observed in the nail plate can be due to *melanocytic activation* in the matrix (i.e., lentigo, drug-induced, post-inflammatory pigmentation) or *melanocytic proliferation* in the matrix (i.e., nevus, melanocytic hyperplasia, or melanoma [2, 16]. However, the source of pigment in, on, or under the nail plate. is not always from the matrix; it can also arise from trauma (i.e., blood), infection (i.e., fungal, *Pseudomonas*), or exogenous sources. In addition, while melanoma isolated to the nail bed likely does not exist, melanoma arising from the skin of the hyponychium or paronychium can spread to involve the nail bed and result in melanonychia striata [44].

Melanonychia striata due to melanocytic proliferation in the nail matrix results in a longitudinal brown to black pigmented band that usually contains multiple linear striations and tiny fine brown to black granules within it. The brown to black granules presenting within a brown or black band correlate with a melanocytic proliferative process [16]. Melanonychia striata due to melanocytic activation in the matrix results in a homogeneous gray band containing tiny gray granules and faint to no linear striations.

Histopathology of the matrix in cases of melanocytic activation (i.e., lentigo, drug-induced pigmentation, post-inflammatory pigment) reveals epithelial hyperpigmentation with a normal density of melanocytes. In contrast, the histopathology related to melanocytic proliferation in the nail matrix reveals an increased density of melanocytes. In melanocytic proliferations, an irregular pigmented band with multiple colors, variable thickness of the striated lines, and loss of parallelism of these striated lines are suggestive of nail apparatus melanoma (NAM) (Figure 3.37, Table 3.3), corresponding to the chaotic growth of the melanoma in the matrix [16].

Micro-Hutchinson's sign is the presence of periungual skin pigmentation on the hyponychium (pigmentation of the cuticle) that is visible primarily with dermoscopy [16]. While this feature may be seen in some congenital nevi involving the nail unit, it is associated with NAM in adults. It needs to be underscored that in cases of NAM, a biopsy of the cuticle displaying the micro-Hutchinson's sign may not necessarily reveal the underlying diagnosis. In other words, while biopsy of the pigment in the cuticle may confirm the diagnosis of melanoma, a negative biopsy cannot be used to exclude melanoma in the matrix [98].

The evaluation of the free edge of the nail plate with dermoscopy can assist in determining whether the lesion is located in the proximal or distal nail matrix, and this information can be used to guide where exactly to biopsy. Histologically, the proximal nail matrix is responsible for producing the keratin that forms the top surface of the nail plate, and the distal nail matrix is responsible for producing the keratin that forms the undersurface of the nail plate. Thus, pigmentation localized to the upper part of the nail´s free edge correlates with melanocytic proliferations located in the proximal portion of the nail matrix, and pigmentation of the lower part of the nail´s free edge correlates histologically with melanocytes proliferating distally in the nail matrix [17].

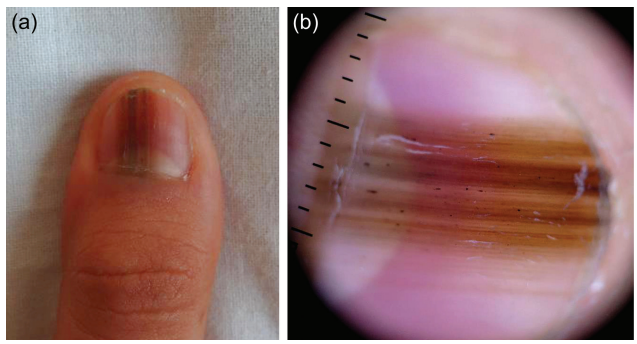

FIGURE 3.37 (a) Clinical image of a subungual melanoma in situ. (b) Dermoscopy shows irregular bands of different colors (gray, dark and light brown) and dark globules and dots.

Dermoscopy can also be used as an intraoperative procedure to directly evaluate the structures and patterns of pigmentation of the nail matrix once the nail plate has been removed. This can help guide the surgeon in the best place to perform the biopsy. Direct dermoscopy of the nail matrix reveals four dermoscopic patterns (36, 37):

1) A *regular gray pattern* (fine regular grayish lines) corresponds to pigmentation in the basal layer (melanocytic activation) with an absence of melanocytic hyperplasia or nesting.
2) A *regular brown pattern* (regular brown lines) corresponds to benign melanocytic hyperplasia with the absence of melanocytic nests.
3) A *regular brown pattern with dots/globules or blotches* (regular longitudinal brown lines and presence of dots/globules or blotches of regular size and distribution) is associated with melanocytic nevi. Histologically, the globules correlate with nevus nests. The blotches correlate with the presence of increased focal concentrations of melanin.
4) An irregular pattern (longitudinal lines of irregular color and thickness, with or without irregular dots/globules or blotches) corresponds to a disorganized proliferation of atypical melanocytes and irregular size, shape, and distribution of nests. The irregular lines reveal atypical melanocyte proliferation producing thick longitudinal lines with the spread of the pigmentation to adjacent areas. The irregular pattern was associated with high sensitivity and specificity for melanoma [37].

Nonmelanocytic neoplasms

Basal cell carcinoma

Leaf-like areas, spoke wheel areas, and concentric globules

Leaf-like areas are brown to blue-gray linear to bulbous projections connected radially to an off-center base [48]. **Spoke wheel areas** are a variant of the leaf-like areas where the radial projections converge towards a central darker hub. If the individual spokes (radial projections) are not discernable, the spoke wheel–like area is called a **concentric globular structure**. These concentric globules present as dark globules located inside lighter-colored globules (clod within a clod). In the absence of a pigment network, leaf-like areas and spoke wheel structures (including concentric globules) are diagnostic of pigmented BCC [57]. Histologically, they represent aggregates of pigmented BCC nests at the DEJ and papillary dermis (Figures 3.38, 3.39) and thus, are associated with the superficial component of BCCs (Table 3.4) [55].

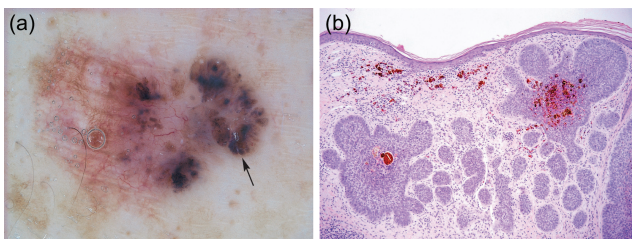

FIGURE 3.38 (a) Dermoscopy of a pigmented basal cell carcinoma showing leaf-like areas (*arrow*). (b) Histology shows nests of pigmented epithelial nodules of basal cell carcinoma.

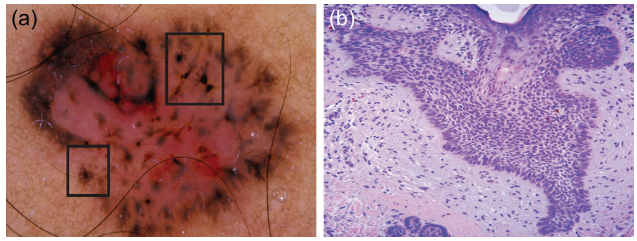

FIGURE 3.39 (a) Dermoscopy shows multiple spoke wheel–like structures (*squares*). (b) Histology image of a spoke wheel area corresponding to nests of basal cell carcinoma radiating off the undersurface of the epidermis.

Blue-gray ovoid nests, multiple blue-gray globules, and dots

Pigmented BCC often displays blue-gray dots, globules, or ovoid nests. The **blue-gray dots** are pinpoint small structures that are distributed in a buckshot scatter pattern. They are associated with small BCC aggregates at the DEJ and/or papillary dermis and thus correspond with superficial BCC. The **blue-gray globules** are larger than dots but smaller than ovoid nests (Figures 3.40, 3.41) and are usually nonaggregated. Histologically, they correspond to pigmented BCC tumor aggregates in the dermis, and thus, the presence of this structure is suggestive of a nodular growth pattern. **Blue-gray ovoid nests** are well-circumscribed blue-gray oval clods that occupy at least 10% of the surface area of the BCC. Histologically, the ovoid nest corresponds with large, pigmented BCC tumor nodules in the dermis (pigmented nodular BCC) [52].

Ulcerations and erosions

Ulcerations are caused by a loss of the entire epidermis. They manifest dermoscopically with a structureless red to orange color, and they are often covered with a serous or hemorrhagic crust (Figure 3.42). In contrast, erosions are due to the partial loss of a portion of the epidermis. They manifest dermoscopically as small brown-red to orange-yellow crusts (Figure 3.43).

The presence of ulceration, in general, is indicative of nodular BCC. In contrast, multiple smaller erosions are generally indicative of superficial BCC. Needless to say, ulceration and erosions are not completely specific for BCC, since they can also be observed in melanoma, SCC, or any traumatized lesion (Table 3.5) [1, 52].

Shiny white blotches and strands

Shiny white blotches and strands can only be seen with polarized light. Shiny white blotches consist of white homogeneous clods (Figure 3.44). Strands are parallel and linear white areas that, unlike shiny white lines, are usually longer and do not intersect at orthogonal angles [58]. The combined presence of shiny white blotches and strands is associated with high diagnostic specificity for BCC [74]. The exact histopathological correlate remains to be elucidated, but preliminary work suggests that strands correspond to stromal alternation and blotches correspond to either stromal alteration around BCC tumor islands or collections of mucin.

Multiple aggregated yellowish-whitish globules (MAY globules)

Some BCC reveal multiple aggregated yellowish to whitish globules (MAY globules) (Figure 3.45) [13]. These clustered MAY globules can be seen with both polarized and nonpolarized light. While their presence is strongly associated with BCC,

TABLE 3.4: Dermoscopic Structures with High Specificity for Nonmelanocytic Neoplasms

	Schematic illustration	Metaphoric term (descriptive term) and histopathological correlate
Basal cell carcinoma		Blue-gray ovoid nests, multiple blue-gray globules and dots (clods, dots, blue/gray, not aggregated) *Large (ovoid nests) or small (globules, dots) basal cell carcinoma nodules in the dermis*
		Leaf-like areas (lines, radial, connected to a common base) *Pigmented basal cell carcinoma nests connected to each other in the dermal-epidermal junction and papillary dermis*
		Spoke wheel areas (lines, radial, converging to a central dot or clod), concentric structures (clod within a clod) *Pigmented basal cell carcinoma nests and cords connecting to each other in the dermal-epidermal junction and upper dermis*
Actinic keratosis		Strawberry pattern (structureless, red, interrupted by follicular openings) *Localized increase of vasculature*
SCC		White circles *Acanthosis and hypergranulosis of the infundibular epidermis*
Bowen disease		Linear dark dots/globules (dots, clods, peripheral, arranged in lines) *Atypical basal pigmented keratinocytes*
Seborrheic keratosis		Fissures and ridges (lines, curved and thick) *Epidermal clefts often filled with keratin due to papillomatosis*
		Milia-like cysts (dots or clods, white, clustered or disseminated) *Intraepidermal keratin cysts*

(*Continued*)

TABLE 3.4 (Continued): Dermoscopic Structures with High Specificity for Nonmelanocytic Neoplasms

	Schematic illustration	Metaphoric term (descriptive term) and histopathological correlate
		Comedo-like openings/crypts (clods, brown, yellow, or orange, rarely black) *Epidermal invaginations filled with keratin*
DF		Central white patch (structureless zone, white, central) *Prominent fibrosis in the papillary dermis*

Source: Partially reprinted from Dermoscopedia.org with permission of Ralph Braun.
Abbreviations: SCC, squamous cell carcinoma; DF, dermatofibroma.

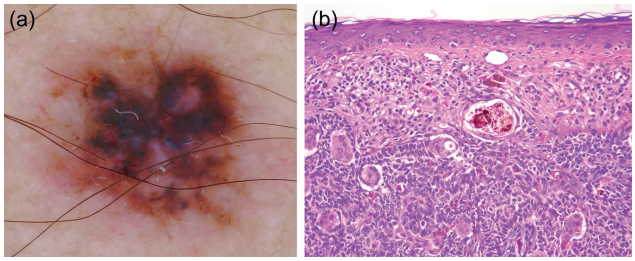

FIGURE 3.40 (a) Dermoscopy of a pigmented basal cell carcinoma with multiple brown dots and globules. (b) On histology, pigmented basal cell carcinoma tumor aggregates are observed in the dermis.

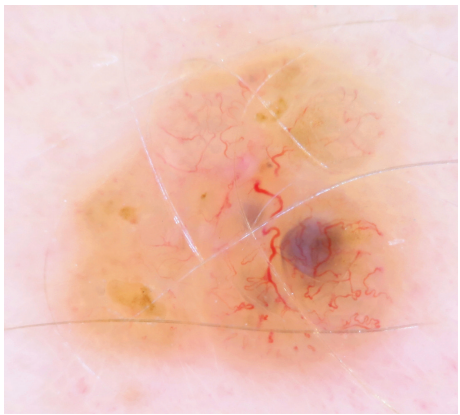

FIGURE 3.41 Dermoscopy of a nodular basal cell carcinoma revealing blue-gray ovoid nests together with arboriform vessels.

they have also been seen in desmoplastic trichoepitheliomas. In BCC, their presence is negatively associated with superficial BCC and positively associated with deeper-seated, histologically higher-grade BCC tumor subtypes. Histologically, these MAY globules correspond to calcifications and keratocysts.

Arborizing vessels

Arborizing vessels are bright red large-diameter vessels with distinct treelike branching into more delicate capillaries. They



FIGURE 3.42 Dermoscopy of a nodular basal cell carcinoma showing an ulceration (hemorrhagic crust) on the left, arborizing vessels, and shiny white lines.

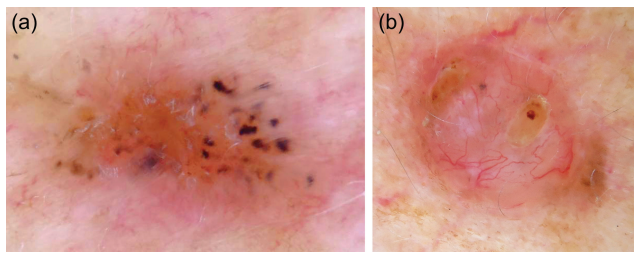

FIGURE 3.43 (a) Dermoscopy of a basal cell carcinoma with an erosion (structureless orange color) at the center of the lesion. (b) Multiple erosions and telangiectatic vessels in a superficial basal cell carcinoma.

appear as sharply in-focus branching vessels on dermoscopy. Their presence is highly suggestive of nodular BCC, but they can also be seen in other tumoral and nontumoral dermatosis such as melanoma, hypertrophic scars/keloids, epidermal cysts, actinic keratoses, and intradermal nevi, among others [42]. Histologically, in BCC, the arborizing vessels correspond to the neovascular vessels surrounding BCC tumor aggregates in the dermis [66].

TABLE 3.5: Nonspecific Dermoscopic Structures

Schematic illustration	Metaphoric term (descriptive term) and histopathological correlate
	Blotch (structureless zone, brown or black) *Aggregates of melanin in the stratum corneum or throughout all layers of the skin*
	Dots (dots, black or brown) *Aggregates of melanocytes or melanin granules. If black, in upper epidermis; if brown, in lower epidermis*
	Peppering/ granularity (dots, gray) and scarlike depigmentation (structureless zone, white) *Peppering/granularity: regression with melanophages* *Scarlike depigmentation: fibrotic papillary dermis*
	Shiny white streaks (lines, white, perpendicular) *Unclear. Suspected increased collagen and dermal fibroplasia*
	Rosettes: dots, white (four arranged in a square) *Hyperkeratosis in the follicular openings alternating with the normal surrounding stratum corneum*
	Shiny white blotches and strands (clods, white, shiny) *Unclear. Suspected to be fibrosis in the underlying stroma*
	Blue-whitish veil (structureless zone, blue) *Heavily pigmented dermal cells combined with compact orthokeratosis*
	Scale (homogeneous opaque yellow to brown structures) *Hyperkeratosis and parakeratosis*

(*Continued*)

TABLE 3.5 (Continued): Nonspecific Dermoscopic Structures

Schematic illustration	Metaphoric term (descriptive term) and histopathological correlate
	Erosion/Ulceration (structureless dark red to brown areas with a serous crust)
	*Erosion: loss of the epidermis* *Ulceration: loss of the epidermis and superior dermis*

Source: Partially reprinted from Dermoscopedia.org with permission of Ralph Braun.

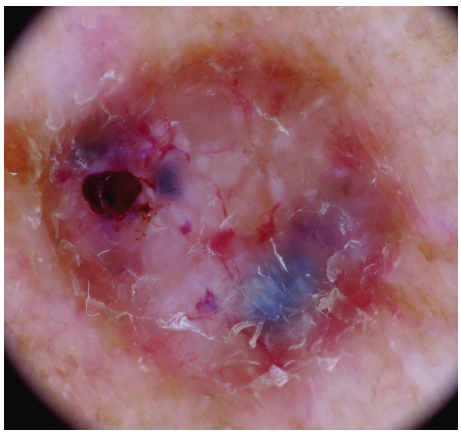

FIGURE 3.44 Dermoscopy of an infiltrating basal cell carcinoma showing shiny white blotches, blue-gray ovoid nests, arborizing vessels, and erosions.

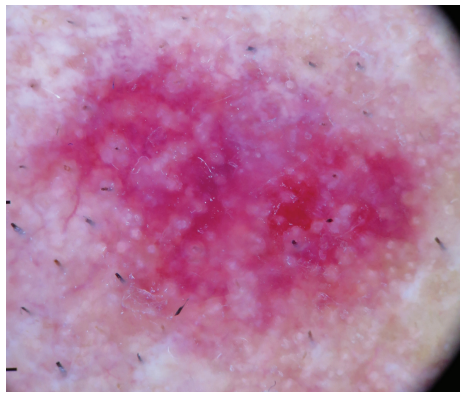

FIGURE 3.46 Dermoscopy of a nonpigmented actinic keratosis showing a strawberry pattern and multiple rosettes.

Keratinizing tumors

White circles

White circles are bright white circles surrounding yellow/orange keratin plugs [83]. Histopathologically, they correspond with acanthosis and hypergranulosis of the infundibular epidermis. Their presence is highly suggestive of well-differentiated SCC and keratoacanthoma (Table 3.4) [83].

Dark dots/globules or circles in a linear arrangement

Brown dots/globules arranged linearly are frequently found in pigmented SCC in situ/Bowen disease [21]. Histologically, they correspond to aggregates of atypical basal pigmented keratinocytes. Pigmented Bowen's disease can also reveal small brown circles. Pigmented basal keratinocytes, in combination with foci of undulated DEJ, correlate to these brown rings, which can be seen with dermatoscopy [26].

Strawberry pattern

The strawberry pattern is a reddish pseudonetwork interrupted by prominent follicular openings [48]. Histologically, it corresponds to a localized increase in the cutaneous vasculature surrounding dilated adnexal openings filled with keratin. The strawberry pattern is highly suggestive of nonpigmented actinic keratosis (Figure 3.46) [126].

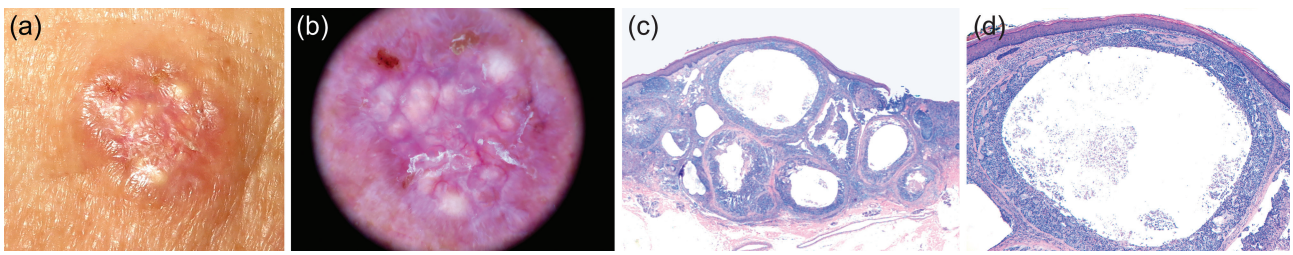

FIGURE 3.45 (a) Clinical image of a basal cell carcinoma on the front. (b) Dermoscopy shows multiple aggregated yellowish to whitish globules and arboriform vessels. (c, d) Histology reveals a nodular basal cell carcinoma with multiple cystic structures.

Rosettes

Rosettes are seen as four bright white dots or clods arranged together as a four-leaf clover (or as a square). This structure can only be seen with polarized light (Figure 3.46). Histologically, a rosette corresponds with hyperkeratosis of the follicular opening [58, 59]. One study using ex vivo dermoscopy and transverse histological sections showed that smaller rosettes correspond to concentric horn material in adnexal openings (follicular or eccrine ducts) and larger rosettes to concentric perifollicular fibrosis [34]. Multiple rosettes are commonly seen in actinically damaged skin and in actinic lesions such as AK and SCC. However, isolated rosettes can also be seen in BCC, melanoma, and inflammatory and infectious dermatosis [30, 35].

Scale

Scales are homogeneous opaque yellow/brown structures. Histologically, they correspond with hyperkeratosis and parakeratosis [99, 115]. Scale is commonly seen in AKs, SCC, and inflammatory dermatosis.

Inner gray halo

Inner gray halo is the presence of a grayish hue visible on the inner side of the follicular opening and is associated with pigmented AK (see Chapter 6c). Histologically, the inner gray halo is associated with hypergranulosis in conjunction with the pigmentation of the basal keratinocytes of the infundibular opening [73]. This structure should not be confused with circle within a circle or with gray-colored follicular openings associated with melanoma (see facial skin section earlier).

Seborrheic keratoses

Fissures and ridges

Fissures (formerly sulci) and ridges (formerly gyri) correspond to the invaginations of the epidermis and the raised portions of the epidermis, respectively (Figure 3.47). They are most commonly seen in SK [48, 61]. Histopathologically, they correspond to a thickened epidermis with epidermal clefts that are filled with keratin [67].

Milia-like cysts

Milia-like cysts are shiny whitish to yellowish round structures. They are more conspicuous when viewed with nonpolarized dermoscopy [19]. Histopathologically they correspond with intraepidermal keratin pseudocysts [67] (Figure 3.48). While the presence of multiple milia-like cysts is highly suggestive of SK, a few isolated milia cysts can also be observed in BCC, congenital nevi, papillomatous melanocytic nevi, and even melanoma [22].

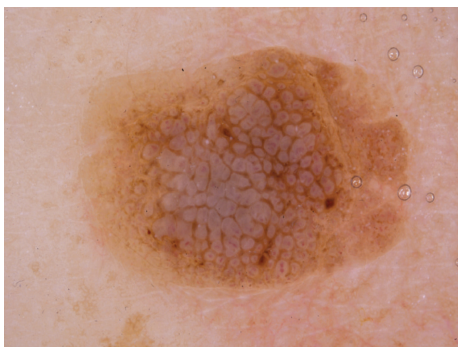

FIGURE 3.47 Dermoscopy of a seborrheic keratosis showing multiple gyri and sulci creating a brain-like appearance to the lesion. Hairpin blood vessels on the gyri can also be seen.

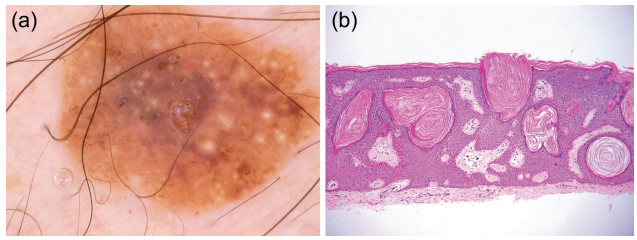

FIGURE 3.48 (a) Dermoscopy shows multiple milia-like cysts, comedo-like openings, and some fissures (sulci). (b) Histology reveals numerous milia-like cysts and comedo-like openings.

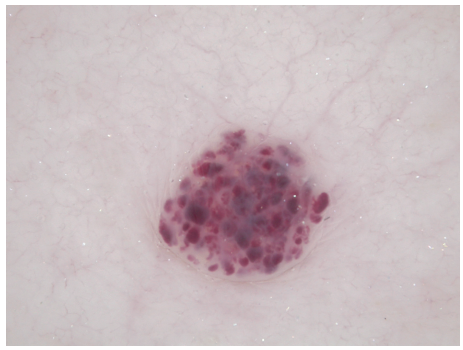

FIGURE 3.49 Dermoscopy of an angioma revealing multiple well-demarcated lacunae.

Comedo-like openings and crypts

Comedo-like openings are dark brown/black round to oval invaginations (Figure 3.48). Crypts are similar but appear more elongated [48]. Histologically, they correspond to epidermal invaginations filled with keratin [67]. While the presence of multiple comedo-like openings is associated with SKs, they can also be seen in any papillomatous lesion, including intradermal nevi and melanoma [22].

Angioma and angiokeratoma

Lacunae

Lacunae are multiple well-demarcated round to oval reddish structures arranged in clusters and separated from each other by a whitish rim called septae. Histologically, lacunae correspond to dilated, thin-walled vessels in the papillary dermis. Lacunae are the hallmark of vascular tumors, mainly angiomas (Figure 3.49). Dark violaceous, blue-black or black lacunae (Figure 3.50) are seen in thrombosed angiomas and in angiokeratomas. Histologically, they reveal partially or completely thrombosed dermal vessels, [121]. In targetoid hemosiderotic angiokeratomas, a central dark lacuna is surrounded by a peripheral red-brownish homogeneous area. Histopathologically, they reveal less dilated angulated vascular spaces, hemosiderin deposition, and extravasated erythrocytes in the mid and deep dermis [122].

Dermatofibroma

Central white patch

A central white patch is a white structureless area located in the center of a lesion that is surrounded by a thin tan

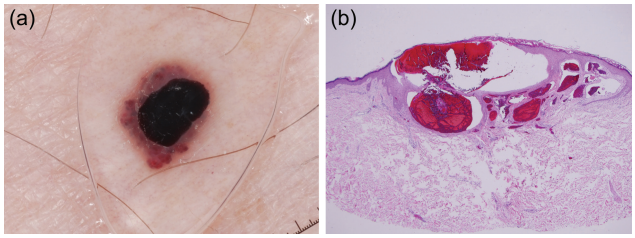

FIGURE 3.50 (a) Dermoscopy image of angiokeratoma showing blue-black lacunae. (b) Histology shows large, dilated, cavernous blood vessels.

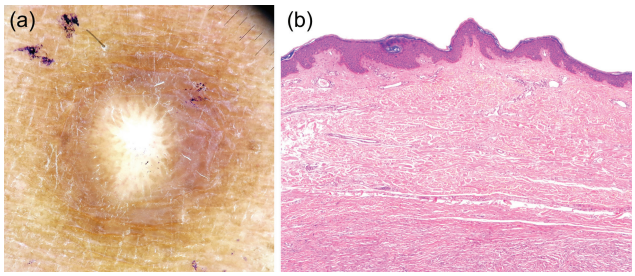

FIGURE 3.51 (a) Dermoscopy of a dermatofibroma showing a central white patch and a delicate light brown peripheral network. (b) Histology reveals extensive dermal fibrosis.

network [48]. Histopathologically, this feature corresponds to fibrosis in the papillary dermis (Figure 3.51) [123].

Peripheral delicate network and ring-like globules

The delicate peripheral network consists of thin brown lines forming a meshwork pattern at the periphery of a lesion (Figure 3.51). Histologically, it corresponds to the hyperpigmentation of basal keratinocytes. A central white patch, together with a delicate peripheral network, is highly suggestive of dermatofibroma [123]. This network can transition from thin lines at the periphery to larger donut-shaped ringed globular structures towards the central scarlike area. These ring-like globules correspond with the broadened rete ridges associated with dermatofibromas [91].

Lichen planus-like keratosis

Diffuse gray dots

LPLK is an inflammatory process that often occurs when a solar lentigo or a SK undergoes involution/regression. Diffuse fine to coarse gray dots are the most prevalent finding in LPLK.

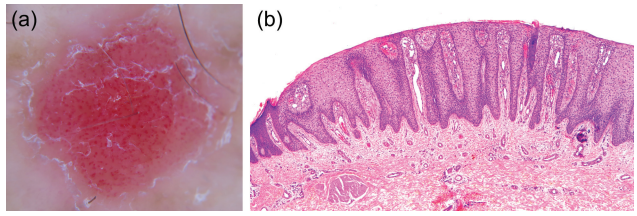

FIGURE 3.53 (a) Dermoscopy of a clear cell acanthoma showing dotted vessels following a serpiginous arrangement (string of pearls). (b) On histology, multiple dilated vessels filling the tips of dermal papillae are observed.

Histologically, they correspond to melanophages in the papillary dermis and correspond with the final stages in the regression process of an LPLK [111]. Dermoscopy of LPLK can also show pinkish areas, an annular/granular pattern, gray pseudonetwork, and shiny white structures (Figure 3.52). These patterns correlate with evolving stages of inflammation and regression, including capillary dilatation and lichenoid inflammation, melanophages surrounding the hair follicles, aggregates of melanophages in the papillary dermis, and stromal alteration, respectively [111].

Clear cell acanthoma

Vessels in a string of pearls arrangement

The string of pearls vascular pattern is characterized by dotted or glomerular vessels following a serpiginous arrangement. Histologically, they correspond to dilated vessels filling the tips of dermal papillae [6] (Figure 3.53).

Sebaceous neoplasms

Crown vessels

Crown vessels are radial, serpentine, or arborizing vessels at the periphery of the lesion that radiate toward the center but do not cross the midline of the lesion [48]. Histologically, crown vessels reveal dermal vessels displaced by aggregated lobules of hyperplastic sebaceous glands. These vessels are associated with sebaceous neoplasms such as sebaceous hyperplasia, nevus sebaceous, and sebaceous adenoma (Figure 3.54) [45, 47].

"Popcorn-like structures" (yellowish to whitish lobulated structures)

Popcorn-like structures, also known as cloud structures, are polylobular yellowish to whitish structures, commonly found in sebaceous neoplasms (Figure 3.54). Histopathologically, they correspond to hypertrophied dermal sebaceous glands [47].

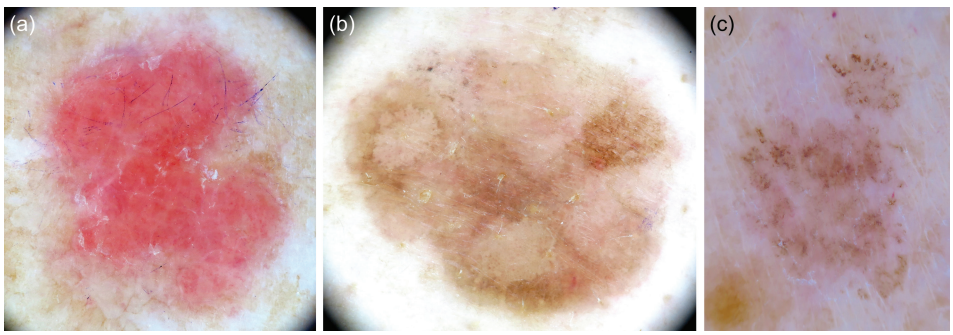

FIGURE 3.52 Dermoscopy of evolving stages of lichen planus–like keratoses. (a). Inflammatory stage. Dermoscopy showing pinkish areas. (b, c) Regression stage. Dermoscopy revealing an annular/granular pattern and a brown-gray pseudonetwork.

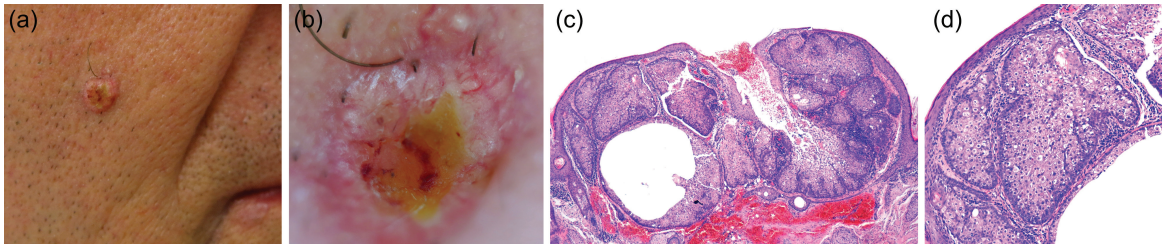

FIGURE 3.54 (a) Clinical image of an eroded sebaceous adenoma on the cheek of a patient with Muir-Torre syndrome. (b) Dermoscopy shows polylobular yellowish to whitish structures (popcorn structures), crown vessels, and a central crust. (c, d) Histology reveals a well-delimitated lobulated tumor; lobules are comprised of basaloid cells and mature sebaceous cells.

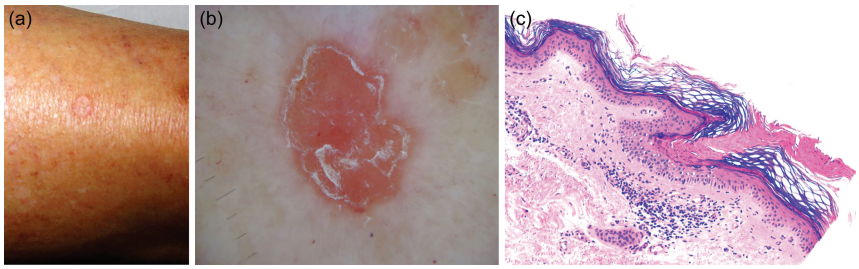

FIGURE 3.55 (a) Clinical image of an actinic porokeratosis. (b) Dermoscopy reveals a peripheral annular double rim ("white track"). (c) Histology shows the cornoid lamella.

TABLE 3.6: Histologic Correlation of Dermatoscopic Findings in Inflammatory Dermatoses

Inflammoscopy and description	Histologic correlation	Associated disorders
Red dots + **White scales** Monomorphic and symmetrically distributed red dots over an erythematous background and with scaling	Spiraled capillaries in the papillary dermis, psoriasiform epidermal hyperplasia, and parakeratosis	Psoriasis
Red dots + **Yellow scales** Irregularly distributed red dots and yellow crusts/scales	Dilatation of the subpapillary vessels, and spongiosis in epidermis	Acute/subacute Ddermatitis
Red dots/lines + **Reticular or annular whitish structures (Wickham striae)** Dotted/linear vessels and round, linear, reticular or annular pearly-whitish structures	Compact orthokeratosis above zones of wedge-shaped hypergranulosis and acanthosis	Lichen planus
Polygonal vessels Lineal vessels arranged in horizontal and vertical lines forming a geometrical pattern	Increased vascularization	Rosacea
Peripheral annular rim ("white track") Well-defined, thin, white-yellow annular structure surrounding a brownish or whitish area	Cornoid lamella	Porokeratosis
Orange-yellowish patches Round to oval orange-yellow patches	Granulomas located superficially in the dermis	Granulomatous cutaneous disorders (leishmaniasis, sarcoidosis, lupus vulgaris, granuloma faciale, granulomatous rosacea)

Porokeratosis

Peripheral annular double-rim

Peripheral annular double-rim ("white track") is a well-defined, thin white-yellow annular structure surrounding a pink to whitish central flat area. This structure is often slightly raised with a rough texture. Histologically, it correlates with the cornoid lamella typically seen in porokeratosis [53] (Figure 3.55).

Correlates in inflammoscopy

The use of dermoscopy is not limited to the field of dermato-oncology. Inflammoscopy is the dermoscopic evaluation of inflammatory dermatoses, and it can provide useful information to assist in accurately differentiating between the different inflammatory dermatoses (Table 3.6) [92].

Psoriasis

Monomorphic red dots

Monomorphic and symmetrically distributed red dots over an erythematous background, together with white adherent scales, are the hallmark pattern of psoriasis. Histologically, they correspond to the presence of capillaries in the papillary dermis, psoriasiform epidermal hyperplasia, and parakeratosis [92] (Figure 3.56).

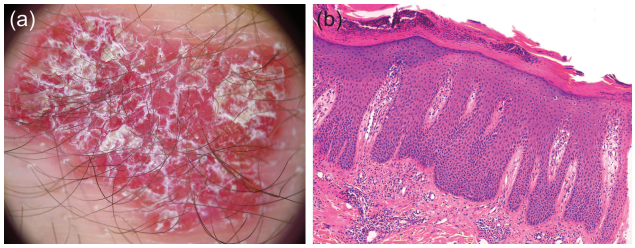

FIGURE 3.56 (a) Dermoscopy of psoriasis showing white scales over an erythematous background. (b) On histology, multiple capillaries in the papillary dermis and psoriasiform epidermal hyperplasia and parakeratosis are observed.

Dermatitis

Irregularly distributed red dots

Irregularly distributed red dots and yellow crusts/scales are the most frequent dermoscopic features of dermatitis (allergic/contact dermatitis, atopic dermatitis, and seborrheic dermatitis). Yellow crusts/scales are frequent in the acute stages of dermatitis [54]. Histologically, irregular distributed red dots correspond to slight dilatation of the subpapillary vessels, and yellow crusts/scale to the epidermal spongiotic reaction [29, 92] (Figure 3.57).

Lichen planus

Peripheral dotted/linear vessels together with round, linear, reticular, or annular pearly-whitish structures are characteristic of lichen planus [53] (Figure 3.58). Histopathologically, whitish structures correspond with compact orthokeratosis above zones of wedge-shaped hypergranulosis and acanthosis. This feature is the equivalent of Wickham striae [108].

Rosacea

Polygonal vessels

Polygonal vessels are lineal vessels arranged in horizontal and vertical lines forming a geometrical pattern. Polygonal vessels, in the absence of scale, are highly specific for erythemato-telangiectatic rosacea. Histologically, they correlate with intense vasodilatation [53].

Granulomatous skin diseases

Orange-yellowish patches

Round to oval orange-yellowish patches/plaques are characteristic dermoscopic findings in many granulomatous cutaneous disorders (leishmaniasis (Figure 3.59a–c), sarcoidosis, lupus vulgaris (Figure 3.59d), granuloma faciale, granulomatous rosacea, granuloma annulare). Histologically, they correlate to granulomas located superficially in the dermis [11].

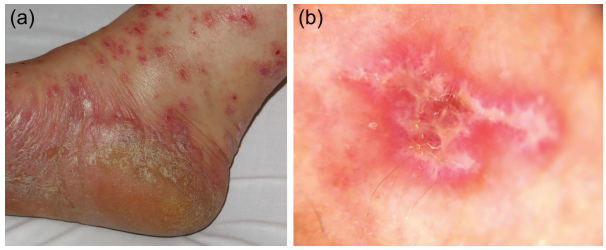

FIGURE 3.58 (a) Clinical image of lichen planus. (b) Dermoscopy reveals peripheral linear vessels and reticular pearly-whitish structures.

Correlates in infectious skin diseases

Entomodermoscopy has been used as a synonym for the dermoscopic study of infectious skin diseases, although it derives from the word "entomology," which is the science that studies insects. Nevertheless, dermoscopy has also been shown to be useful to diagnose several infectious dermatoses, most of them caused by insects (Table 3.7).

Molluscum contagiosum

White/yellow amorphous structures

White to yellow amorphous structures are polylobular whitish to yellowish structures surrounding a central indentation or dell. Linear or branched vessels ("red corona" or crown vessels) are seen at the periphery [107]. This is the typical dermoscopic pattern of molluscum contagiosum. Histologically, these white structures correspond to endophytic lobules of hyperplastic squamous epithelium expanding into the dermis, displacing dermal dilated vessels [71] (Figure 3.60). The dermoscopic morphology of molluscum and sebaceous hyperplasia can mimic each other.

Warts

Multiple dark dots

Multiple dark dots are black/red dots within a well-defined yellowish area that are characteristic of plantar warts (Figure 3.61). Recently, a histopathologic study of 18 palmoplantar warts found no thrombosed vessels, suggesting that the presence of dark dots is secondary to intracorneal hemorrhages and not to dermal microthrombi [27].

Scabies

Dark brown triangular structures

A small brown triangular structure ("delta-wing jet sign") located at the end of the whitish curved line is characteristic of scabies. The sensitivity of dermoscopy in the diagnosis of scabies can be as high as 0.91 (higher than the sensitivity of skin

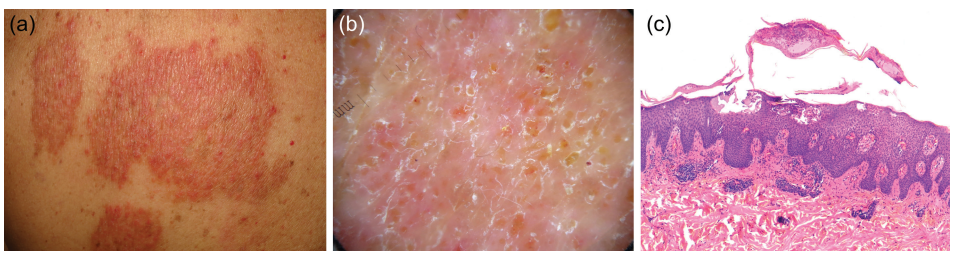

FIGURE 3.57 (a) Clinical image of eczema. (b) Dermoscopy of dermatitis (nummular eczema) showing yellowish scales and irregularly distributed red dots. (c) Histology reveals epidermal spongiotic reaction, crusts, and dilatation of the subpapillary vessels.

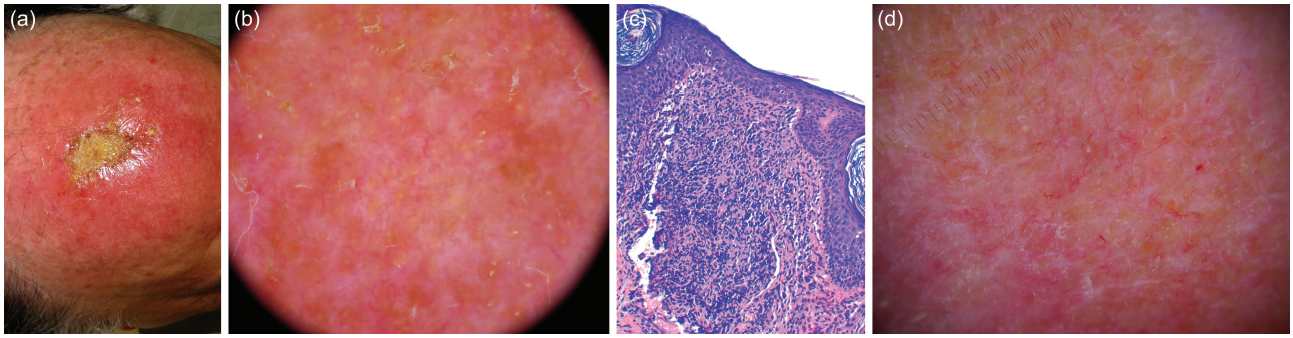

FIGURE 3.59 (a) Clinical image of cutaneous leishmaniasis on the scalp. (b) Dermoscopy shows orange-yellowish patches distributed along the lesion. (c) Histology reveals a granulomatous infiltrate in the dermis. (d) Dermoscopy of lupus vulgaris also shows orange-yellowish patches.

TABLE 3.7: Histologic Correlates in Skin Infectious Diseases

Schematic illustration	Entomodermoscopy and description	Histologic correlation	Infection/infestation
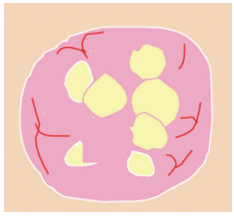	**White/yellow amorphous structures** + **"Red corona"** Polylobular whitish to yellowish structures surrounding a central pore. Linear or branched vessels in the periphery	Endophytic lobules of hyperplastic squamous epithelium and dilated vessels in dermis	Molluscum contagiosum
	**Dark brown triangular structures ("delta-wing jet")** Small brown triangular structure located at the end of a subtle whitish curved line	Pigmented anterior part of the mite. Burrow of the parasite	Scabies
	**Multiple dark dots** Black/red dots within a well-defined yellowish area	Intracorneal hemorrhages	Palmoplantar warts

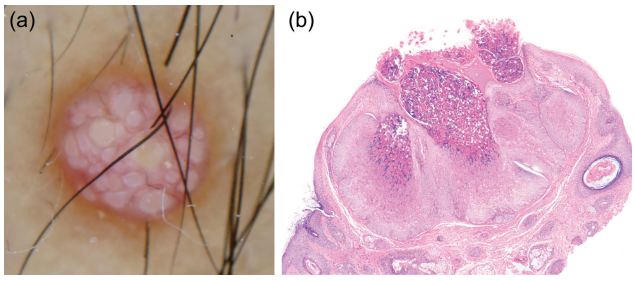

FIGURE 3.60 (a) Dermoscopy of molluscum contagiosum showing polylobular whitish to yellowish amorphous structures and linear vessels ("red corona" or crown vessels) at the periphery. (b) On histopathology, infundibular hyperplasia and papillomatosis with central umbilication together with characteristic intracytoplasmic bodies are observed.

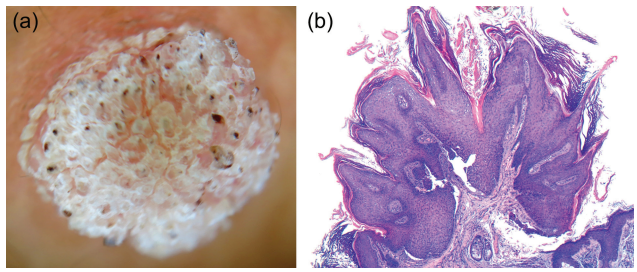

FIGURE 3.61 (a) Dermoscopy of viral wart with multiple dark dots within a well-defined yellow-white area. (b) Histology reveals elongated rete ridges, acanthosis, hypergranulosis, hyperkeratosis with focal parakeratosis, and dilated blood vessels at the dermal-epidermal junction. According to a recent article, the presence of dark dots in dermoscopy is secondary to intracorneal hemorrhages (not shown in the image).

scraping) [100]. The specificity of dermoscopy in this context is approximately 0.46 [114]. Histopathologically, the brown triangle corresponds to the pigmented anterior part of the scabies mite (Figure 3.62). The whitish curved line corresponds to the burrow of the mite [7, 8].

Correlates in trichoscopy

Trichoscopy is the dermoscopic study of inflammatory, infectious, and artefactual hair and scalp disorders. Dermoscopy can help in the diagnosis and follow-up of hair diseases [68, 72, 82, 84, 101, 102] (Table 3.8).

Yellow dots

Yellow dots are round yellowish to pinkish structures. Histologically, they correspond to a distended follicular infundibulum plugged with keratin and sebum [102]. Yellow dots are characteristic of alopecia areata (AA) (Figure 3.63), although they can be seen in androgenetic alopecia and other scalp disorders [84, 110].

Black dots

Black dots, also known as "cadaverized" hairs, are round dark structures inside the follicular ostia (Figure 3.63). Histopathologically, they reveal stubs of hairs that are fractured before their emergence from the scalp. Black dots are seen in AA and are a sign of disease activity [41, 69].

Pinpoint white dots

Pinpoint white dots are small round whitish structures (Figure 3.64). Histologically, they correspond to follicular and sweat gland openings and are seen in healthy scalp and all types of alopecia [51].

White patches

White patches are large and irregular pale structures. Histologically, they represent destroyed follicles replaced by fibrous tracts and the focal absence of melanin [50]. White patches are seen in cicatricial alopecias such as frontal fibrosing alopecia (Figure 3.65).

Blue-gray dots

Blue-gray dots are round grayish structures. They can present in a target pattern or in a speckled pattern. Blue-gray corresponds to the presence of melanophages in dermis. The target pattern is due to the presence of melanin around the hair follicle and is

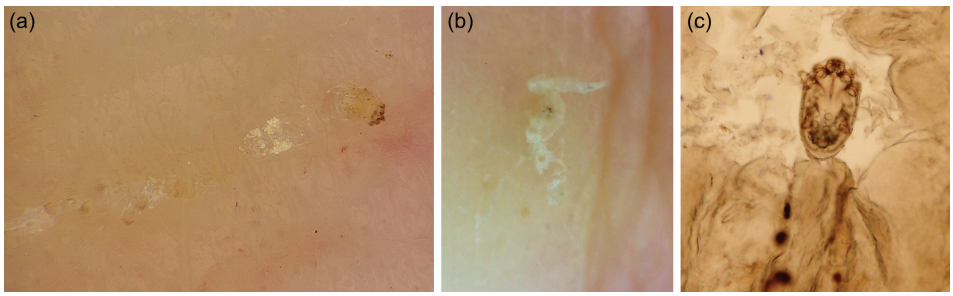

FIGURE 3.62 (a) Videodermoscopy of scabies (FotoFinder Medicam 1000) showing the "delta-wing jet sign." (b) Dermoscopy of scabies revealing similar findings, a brown structure at the end of a whitish curved line. (c) The brown structure corresponds to the parasite (*Sarcoptes scabiei*) (skin scraping test).

TABLE 3.8: Histologic Correlation in Trichoscopy

Trichoscopy and description	Histologic correlation	Associated disorders
Pigment pattern or honeycomb pattern Meshwork composed of brown lines and holes	Lines correspond to pigmented rete ridges	Ultraviolet exposure
Yellow dots Round yellowish to pinkish structures	Distended follicular infundibulum plugged with keratin and sebum	Alopecia areata Androgenetic alopecia
Black dots Round dark structures ("cadaverized hairs")	Stubs of hairs that are fractured before their emergence from the scalp	Alopecia areata
Red dots Round red structures, regularly distributed around follicular openings	Widened follicular ostia surrounded by dilated vessels	Discoid lupus erythematosus
Pinpoint white dots Small round whitish structures	Follicular and sweat gland openings	Normal scalp and all types of alopecia
White patches Large and irregular pale structures	Destroyed follicles replaced, dermal fibrosis and focal absence of melanin	Cicatricial alopecia
Blue-gray dots		
Round grayish structures	Presence of melanophages in dermis	Lichen planus pilaris
Target pattern	Melanin around the hair follicle. Pigmentary incontinence restricted to the follicular units	Discoid lupus erythematosus
Speckled pattern	Melanin in interfollicular areas	
Empty follicles Skin-colored small depressions without hairs	Empty infundibula	Alopecia areata Androgenetic alopecia Telogen effluvium
Absence of follicular opening	Dermal fibrosis	Cicatricial alopecia
Peripilar casts Concentrically arranged scales surrounding the hair shaft	Inflammation in perifollicular area	Lichen planus pilaris Frontal fibrosing alopecia Keratinizing disorders
Follicular keratotic plugging Keratotic masses plugging follicular openings	Hyperkeratosis and keratin material occluding dilated infundibular openings	Discoid lupus erythematosus

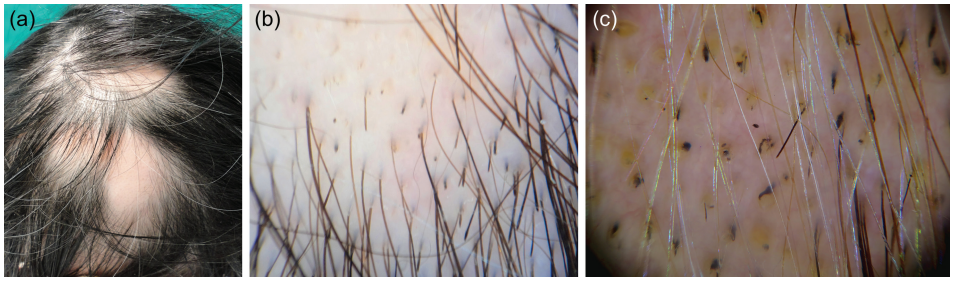

FIGURE 3.63 (a) Clinical image of an alopecia areata. (b, c) Dermoscopy shows black dots, yellow dots, and exclamation mark hairs.



FIGURE 3.64 Dermoscopy of alopecia areata showing a honeycomb pigment pattern and multiple pinpoint white dots.

observed in lichen planopilaris (LPP) (Figure 3.66). The speckled pattern is secondary to the presence of melanin in interfollicular areas and is seen in discoid lupus erythematosus [4, 84].

Empty follicles

Empty follicles are seen dermoscopically as skin-colored small depressions without hairs and can be observed in AA, telogen effluvium, and androgenetic alopecia. Empty follicles correspond to an empty infundibulum [41].

Absence of follicular openings

Dermoscopy demonstrates a lack of hair follicles. Histopathology reveals dermal fibrosis and is characteristic of scarring alopecia [101].

Peripilar casts

Peripilar hair casts are concentrically arranged scales surrounding the hair shaft. Histologically, they correspond to perifollicular inflammation. They are frequently seen in LPP, although they can be present in other scarring alopecias and keratinization disorders [72, 101].

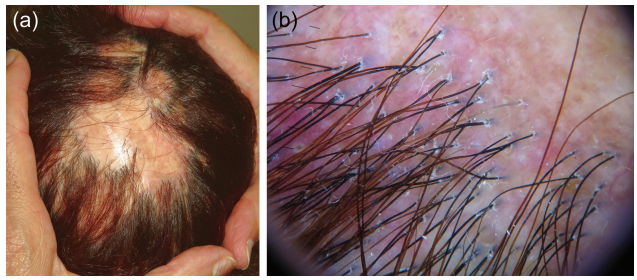

FIGURE 3.66 (a) Clinical image of a lichen planopilaris. (b) Dermoscopy shows follicular hyperkeratosis, erythema, and blue-gray dots around hair follicles.

Peripilar sign

The peripilar sign is a brown halo surrounding the follicular ostium. Histopathologically, it reveals perifollicular inflammation. The peripilar sign is often seen in androgenetic alopecia [72].

Follicular keratotic plugging

Follicular keratotic plugs are yellow-brownish round structures, larger than dots [72], and can be observed in discoid lupus erythematosus. Histologically, they reveal hyperkeratosis and keratin material occluding dilated infundibular openings [84].

Importance of knowing the dermoscopy–histological correlates

Diagnostic improvement

Dermoscopy evaluates the entire lesion on a horizontal plane. This permits guided biopsies of concerning areas within larger lesions and/or provides information to guide the pathologist in selecting the most appropriate areas to section [12, 97, 35, 90]. Dermoscopy can also be performed on ex vivo formalin-fixed specimens [35] (Figure 3.67). Ex vivo dermoscopy (EVD) can

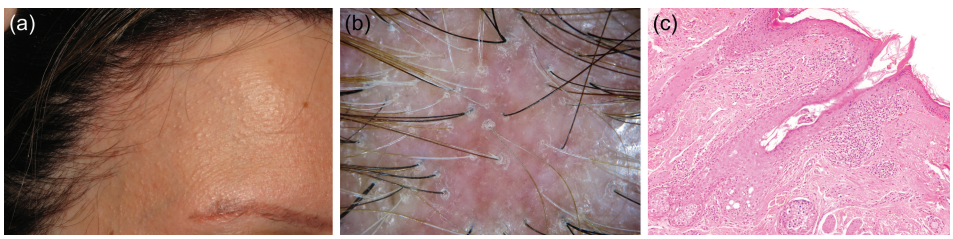

FIGURE 3.65 (a) Clinical image of frontal fibrosing alopecia. (b) Dermoscopy shows perifollicular erythema, follicular hyperkeratosis, and white patches with absence of follicular openings. (c) Histology reveals perifollicular inflammatory infiltrate and dermal fibrosis.



FIGURE 3.67 Ex vivo dermoscopy using a dermatoscope attached to a smartphone. Dermoscopy can be performed on formalin-fixed specimens and is particularly useful when evaluating large and/or complex pigmented lesions, since clinicians and pathologists can mark the areas of interest and analyze them under the microscope.

prove beneficial when scarce or no clinical information is provided to the pathologist. In this setting, EVD can inform the pathologist whether the sample represents the entire lesion or only a portion of the lesion, and it can also help orient the step-sectioning process [3, 20]. EVD is particularly useful when evaluating large and/or complex pigmented lesions, since clinicians and pathologists can mark the areas of interest and analyze them under the microscope [33]. EVD has the potential to identify melanomas missed via conventional step-sectioning, improve the staging of melanomas [20], enhance the detection of positive margins [35], and reduce the costs of histologic processing.

Dermoscopy of the hair and scalp is a valuable tool in the diagnosis and follow-up of scalp and hair disorders [82, 102]. It can guide the location of the biopsy to ensure the highest diagnostic yield. Trichoscopy-guided biopsies can reach a definitive pathological diagnosis in 95% of the cases [68].

Provide prognostic information

Dermoscopic structures observed in melanocytic neoplasms can provide valuable prognostic information such as mitotic activity [23, 81], Breslow thickness [7, 95], dermal invasion [10], or presence of lymph node metastases [31] (Table 3.9).

Predict the histologic subtypes and guide treatment

Dermoscopy can help identify different subtypes of skin cancers, which can have important therapeutic implications. For example, dermoscopic structures more frequently associated with nonsuperficial, mostly nodular BCC are blue ovoid nests, arborizing vessels, MAY globules, and ulceration. On the other hand, the presence of leaf-like areas, spoke wheel–like structures, or multiple small erosions in a flat lesion is associated with superficial BCC (Table 3.10) [1, 53]. Dermoscopy may also help predict the response to treatment: the presence of ulceration in a nontreated BCC has been associated with an excellent response to imiquimod [104]. In SCC, dermoscopy can help differentiate between actinic keratosis and Bowen's disease [21, 128] and predict the degree of differentiation of infiltrating SCCs [52, 128] (Table 3.11). In melanoma, dermoscopy can predict genetic mutations associated with the tumor (Table 3.12) [15, 80, 87]. Lastly, dermoscopy of skin infections and infestations can help guide treatment and assess clinical response [127].

TABLE 3.9: Dermoscopy as a Predictor of Histologic Findings in Melanoma

Dermoscopic structures	Histologic correlation
Ulceration without a pigmented network Blotch	Positive sentinel lymph node
Milky-red areas Blue-whitish veil Streaks	Ulceration and mitosis
>2 dermoscopic structures >4 colors Atypical vessels Streaks Abrupt cut-off Milky-red areas Blue-whitish veil	Breslow index >0.75 mm
Irregular hyperpigmented areas Prominent skin markings	In situ melanoma
Streaks	Dermal invasion

TABLE 3.10: Dermoscopy as a Predictor of Histologic Subtypes in Basal Cell Carcinoma

Dermoscopic features	Histologic subtype
Multiple small erosions Flat surface Leaf-like structures Atypical vessels	Superficial basal cell carcinoma
Arborizing vessels Blue ovoid nest Ulceration	Nonsuperficial basal cell carcinoma

Conclusion

Dermoscopy is a valuable tool in the diagnosis and monitoring of tumoral, inflammatory, and infectious skin disorders as well as hair disorders. The knowledge of the histological

TABLE 3.11: Dermoscopy as a Predictor of Histologic Subtypes in Squamous Cell Carcinoma

Dermoscopic features	Histologic subtype
Glomerular vessels	Bowen disease
Dark dots/globules/circles linearly arranged	Pigmented Bowen disease
Strawberry pattern	Actinic keratosis
Bleeding Vessels in >50% of the tumor surface with a diffuse arrangement	Poorly differentiated squamous cell carcinoma
Looped vessels White circles	Well-differentiated squamous cell carcinoma

TABLE 3.12: Dermoscopy as a Predictor of Genetic Alterations in Melanoma

Dermoscopic feature	Genetic correlate
Dotted vessels	*BRAF* wild-type
Ulceration	*BRAF* mutations
Blue-whitish veil	
Irregular peripheral streaks	
Peppering/granularity	*BRAF* and *NRAS* mutations
Dark homogeneous streaks	*KIT* mutations

correlation of dermatoscopic structures and patterns can help the clinician improve their diagnostic accuracy, provide critical information to the pathologist, select the highest yield area within larger lesions to biopsy, as well as obtain important information relevant for the treatment and monitoring of skin conditions.

Key points

- Dermoscopy provides a horizontal view (*en face*) of skin lesions and permits visualization of epidermal and superficial dermal structures that are otherwise not routinely visible to the naked eye.
- Colors seen with dermoscopy depend mainly on the type, density, and location (depth) of chromophores (i.e., keratin, melanin, blood, collagen) in the skin.
- Most dermoscopic structures have direct histopathology correlates.
- Dermoscopy can help in selecting the most appropriate area to perform a biopsy or step-section a specimen in the laboratory for histopathological evaluation.
- Dermoscopy increases diagnostic accuracy, provides prognostic information, and guides management.

References

1. Ahnlide I, Zalaudek I, Nilsson F, Bjellerup M, Nielsen K. Preoperative prediction of histopathological outcome in basal cell carcinoma: flat surface and multiple small erosions predict superficial basal cell carcinoma in lighter skin types. *Br. J. Dermatol.* 2016;175:751–761. https://doi.org/10.1111/bjd.14499
2. Alessandrini A, Starace M, Piraccini BM. Dermoscopy in the evaluation of nail Disorders. *Skin Appendage Disord.* 2017;3:70–82. https://doi.org/10.1159/000458728
3. Amin K, Fraga GR. Ex vivo dermoscopy of cutaneous biopsies for melanocytic neoplasms: a retrospective review of 517 cases with histopathologic correlation. *Am. J. Dermatopathol.* 2012;34:710–715. https://doi.org/10.1097/DAD.0b013e3182476bba
4. Ankad BS, Beergouder SL, MoodalgiriVM. Lichen planopilaris versus discoid lupus erythematosus: a trichoscopic perspective. *Int. J. Trichology* 2013;5:204–207. https://doi.org/10.4103/0974-7753.130409
5. Aoyagi S, Hata H, Izumi K, Iitani MM, Shimizu H. Diagnostic pitfalls of using dermoscopic features to differentiate between malignant melanoma and pigmented seborrhoeic keratosis. *Acta Derm. Venereol.* 2010;90:440–441. https://doi.org/10.2340/00015555-0882
6. Ardigo M, Buffon RB, Scope A, Cota C, Buccini P, Berardesca E, Pellacani G, Marghoob AA, Gill M. Comparing in vivo reflectance confocal microscopy, dermoscopy, and histology of clear-cell acanthoma. *Dermatol. Surg.* 2009;35;952. https://doi.org/10.1111/j.1524-4725.2009.01162.x
7. Argenziano G, Fabbrocini G, Carli P, De Giorgi V, Delfino M. Epiluminescence microscopy: criteria of cutaneous melanoma progression. *J. Am. Acad. Dermatol.* 1997a;37:68–74.
8. Argenziano G, Fabbrocini G, Delfino M. Epiluminescence microscopy. A new approach to in vivo detection of Sarcoptes scabiei. *Arch. Dermatol.* 1997b;133:751–753.
9. Bafounta ML, Beauchet A, Aegerter P, Saiag P. Is dermoscopy (epiluminescence microscopy) useful for the diagnosis of melanoma? Results of a meta-analysis using techniques adapted to the evaluation of diagnostic tests. *Arch. Dermatol.* 2001;137:1343–1350.
10. Balagula Y, Braun RP, Rabinovitz HS, Dusza SW, Scope A, Liebman TN, Mordente I, Siamas K, Marghoob AA. The significance of crystalline/chrysalis structures in the diagnosis of melanocytic and nonmelanocytic lesions. *J. Am. Acad. Dermatol.* 2012;67:194.e1–8. https://doi.org/10.1016/j.jaad.2011.04.039
11. Bañuls J, Arribas P, Berbegal L, DeLeón FJ, Francés L, Zaballos P. Yellow and orange in cutaneous lesions: clinical and dermoscopic data. *J. Eur. Acad. Dermatol. Venereol. JEADV* 2015;29:2317–2325. https://doi.org/10.1111/jdv.13249
12. Bauer J, Metzler G, Rassner G, Garbe C, Blum A. Dermatoscopy turns histopathologist's attention to the suspicious area in melanocytic lesions. *Arch. Dermatol.* 2001;137:1338–1340.
13. Bellucci C, Arginelli F, Bassoli S, Magnoni C, Seidenari S. Dermoscopic yellow structures in basal cell carcinoma. *J. Eur. Acad. Dermatol. Venereol. JEADV* 2014;28:651–654. https://doi.org/10.1111/jdv.12092
14. Blum A, Simionescu O, Argenziano G, Braun R, Cabo H, Eichhorn A, Kirchesch H, Malvehy J, Marghoob AA, Puig S, Ozdemir F, Stolz W, Tromme I, Weigert U, Wolf IH, Zalaudek I, Kittler H. Dermoscopy of pigmented lesions of the mucosa and the mucocutaneous junction: results of a multicenter study by the International Dermoscopy Society (IDS). *Arch. Dermatol.* 2011;147:1181–1187. https://doi.org/10.1001/archdermatol.2011.155
15. Bombonato C, Ribero S, Pozzobon FC, Puig-Butille JA, Badenas C, Carrera C, Malvehy J, Moscarella E, Lallas A, Piana S, Puig S, Argenziano G, Longo C. Association between dermoscopic and reflectance confocal microscopy features of cutaneous melanoma with BRAF mutational status. *J. Eur. Acad. Dermatol. Venereol. JEADV* 2017;31:643–649. https://doi.org/10.1111/jdv.14028
16. Braun RP, Baran R, Le Gal FA, Dalle S, Ronger S, Pandolfi R, Gaide O, French LE, Laugier P, Saurat JH, Marghoob AA, Thomas L. Diagnosis and management of nail pigmentations. *J. Am. Acad. Dermatol.* 2007;56:835–847. https://doi.org/10.1016/j.jaad.2006.12.021
17. Braun RP, Baran R, Saurat JH, Thomas L. Surgical Pearl: dermoscopy of the free edge of the nail to determine the level of nail plate pigmentation and the location of its probable origin in the proximal or distal nail matrix. *J. Am. Acad. Dermatol.* 2006;55:512–513. https://doi.org/10.1016/j.jaad.2005.09.032
18. Braun RP, Rabinovitz HS, Oliviero M, Kopf AW, Saurat J-H. Dermoscopy of pigmented skin lesions. *J. Am. Acad. Dermatol.* 2005;52:109–121. https://doi.org/10.1016/j.jaad.2001.11.001
19. Braun RP, Scope A, Marghoob AA. The "blink sign" in dermoscopy. *Arch. Dermatol.* 2011;147:520. https://doi.org/10.1001/archdermatol.2011.82
20. Cabete J, Lencastre A, João A. Combined use of ex vivo dermoscopy and histopathology for the diagnosis of melanocytic tumors. *Am. J. Dermatopathol.* 2016;38:189–193. https://doi.org/10.1097/DAD.0000000000000336
21. Cameron A, Rosendahl C, Tschandl P, Riedl E, Kittler H. Dermatoscopy of pigmented Bowen's disease. *J. Am. Acad. Dermatol.* 2010;62:597–604. https://doi.org/10.1016/j.jaad.2009.06.008

22. Carrera C, Segura S, Aguilera P, Scalvenzi M, Longo C, Barreiro A, Broganelli P, Cavicchini S, Llambrich A, Zaballos P, Thomas L, Malvehy J, Puig S, Zalaudek I. Dermoscopic clues for diagnosing melanomas that resemble seborrheic keratosis. *JAMA Dermatol.* 2017;153:544–551. https://doi.org/10.1001/jamadermatol.2017.0129
23. Deinlein T, Arzberger E, Zalaudek I, Massone C, Garcias-Ladaria J, Oliveira A, Schulter G, Hofmann-Wellenhof R. Dermoscopic characteristics of melanoma according to the criteria "ulceration" and "mitotic rate" of the AJCC 2009 staging system for melanoma. *PloS One* 2017;12:e0174871. https://doi.org/10.1371/journal.pone.0174871
24. Farnetani F, Scope A, Mazzoni L, Mandel VD, Manfredini M, Magi S, et al. A comparative dermoscopic and reflectance confocal microscopy study of naevi and melanoma with negative pigment network. *J Eur Acad Dermatol Venereol JEADV.* 2019;33:2273–82.
25. Ferrari A, Agozzino M, Ardigò M, Covello R, Silipo V, Moscarella E, De Simone P, Catricalà C. Dermoscopic and confocal microscopy patterns of vulvar mucosal melanotic macules. *J. Am. Acad. Dermatol.* 2014;70:e81–e82. https://doi.org/10.1016/j.jaad.2013.10.038
26. Fraga-Braghiroli N, Stephens A, Oliviero M, Rabinovitz H, Scope A. Small brown circles: an important diagnostic clue for pigmented squamous cell carcinoma. *J. Am. Acad. Dermatol.* 2013;69:e161–163. https://doi.org/10.1016/j.jaad.2013.04.024
27. Fried I, Kasper RS, Hegyi I, Kempf W. Black dots in palmoplantar warts-challenging a concept: a histopathologic study. *J. Am. Acad. Dermatol.* 2018;79:380–382. https://doi.org/10.1016/j.jaad.2018.01.013
28. Gómez-Martín I, Moreno S, Andrades-López E, Hernández-Muñoz I, Gallardo F, Barranco C, Pujol RM, Segura S. Histopathologic and immunohistochemical correlates of confocal descriptors in pigmented facial macules on photodamaged skin. *JAMA Dermatol.* 2017;153:771–780. https://doi.org/10.1001/jamadermatol.2017.1323
29. Goncharova Y, Attia EAS, Souid K, Protzenko O, Koktishev I. Dermoscopic features of clinically inflammatory dermatoses and their correlation with histopathologic reaction patterns. *Arch. Dermatol. Res.* 2015;307:23–30. https://doi.org/10.1007/s00403-014-1513-3
30. González-Álvarez T, Armengot-Carbó M, Barreiro A, Alarcón I, Carrera C, García A, Malvehy J, Puig S. Dermoscopic rosettes as a clue for pigmented incipient melanoma. Dermatol. *Basel Switz.* 2014;228:31–33. https://doi.org/10.1159/000356822
31. González-Álvarez T, Carrera C, Bennassar A, Vilalta A, Rull R, Alos L, Palou J, Vidal-Sicart S, Malvehy J, Puig S. Dermoscopy structures as predictors of sentinel lymph node positivity in cutaneous melanoma. *Br. J. Dermatol.* 2015;172:1269–1277. https://doi.org/10.1111/bjd.13552
32. Guillod JF, Skaria AM, Salomon D, Saurat JH. Epiluminescence videomicroscopy: black dots and brown globules revisited by stripping the stratum corneum. *J. Am. Acad. Dermatol.* 1997;36:371–377.
33. Haspeslagh M, Degryse N, De Wispelaere I. Routine use of ex vivo dermoscopy with "derm dotting" in dermatopathology. *Am. J. Dermatopathol.* 2013;35:867–869. https://doi.org/10.1097/DAD.0b013e31827f0d27
34. Haspeslagh M, Noë M, De Wispelaere I, Degryse N, Vossaert K, Lanssens S, Facchetti F, Van Den Bossche K, Brochez L. Rosettes and other white shiny structures in polarized dermoscopy: histological correlate and optical explanation. *J. Eur. Acad. Dermatol. Venereol. JEADV* 2016;30:311–313. https://doi.org/10.1111/jdv.13080
35. Haspeslagh M, Vossaert K, Lanssens S, Noë M, Hoorens I, Chevolet I, De Wispelaere I, Degryse N, Facchetti F, Brochez L. Comparison of ex vivo and in vivo dermoscopy in dermatopathologic evaluation of skin tumors. *JAMA Dermatol.* 2016;152:312–317. https://doi.org/10.1001/jamadermatol.2015.4766
36. Hirata SH, Yamada S, Almeida FA, Enokihara MY, Rosa IP, Enokihara MMS, Michalany NS. Dermoscopic examination of the nail bed and matrix. *Int. J. Dermatol.* 2006;45:28–30. https://doi.org/10.1111/j.1365-4632.2004.02335.x
37. Hirata SH, Yamada S, Enokihara MY, Chiacchio ND, Almeida FA de, Enokihara MMSS, Michalany NS, Zaiac M, Tosti A. Patterns of nail matrix and bed of longitudinal melanonychia by intraoperative dermatoscopy. *J. Am. Acad. Dermatol.* 2011;65:297–303. https://doi.org/10.1016/j.jaad.2010.06.009
38. Ishihara Y, Saida T, Miyazaki A, Koga H, Taniguchi A, Tsuchida T, Toyama M, Ohara K. Early acral melanoma in situ: correlation between the parallel ridge pattern on dermoscopy and microscopic features. *Am. J. Dermatopathol.* 2006;28:21–27. https://doi.org/10.1097/01.dad.0000187931.05030.a0
39. Jaimes N, Braun RP, Stolz W, Busam KJ, Marghoob AA. White globules correlate with balloon cell nevi nests. *J. Am. Acad. Dermatol.* 2011;65:e119–e120. https://doi.org/10.1016/j.jaad.2011.03.018
40. Jaimes N, Marghoob AA, Rabinovitz H, Braun RP, Cameron A, Rosendahl C, Canning G, Keir J. Clinical and dermoscopic characteristics of melanomas on nonfacial chronically sun-damaged skin. *J. Am. Acad. Dermatol.* 2015;72:1027–1035. https://doi.org/10.1016/j.jaad.2015.02.1117
41. Jain N, Doshi B, Khopkar U. Trichoscopy in alopecias: diagnosis simplified. *Int. J. Trichology* 2013;5:170–178. https://doi.org/10.4103/0974-7753.130385
42. Jin H, Yang M-Y, Kim J-M, Kim G-W, Kim H-S, Ko H-C, Kim B-S, Kim M-B. Arborizing vessels on dermoscopy in various skin diseases other than basal cell carcinoma. *Ann. Dermatol.* 2017;29:288–294. https://doi.org/10.5021/ad.2017.29.3.288
43. Kasuya A, Aoshima M, Fukuchi K, Shimauchi T, Fujiyama T, Tokura Y. An intuitive explanation of dermoscopic structures by digitally reconstructed pathological horizontal top-down view images. *Sci. Rep.* 2019;9:19875. https://doi.org/10.1038/s41598-019-56522-8
44. Kazi R, Moghaddam S, Chu P, Marghoob AA. Histologic evidence of melanocytes isolated to the nail matrix. *JAMA Dermatol.* 2016;152:573–575. https://doi.org/10.1001/jamadermatol.2015.5869
45. Kelati A, Baybay, H, Gallouj, S, Mernissi, FZ. Dermoscopic analysis of nevus sebaceus of Jadassohn: a study of 13 cases. *Skin Appendage Disord.* 2017;3:83–91. https://doi.org/10.1159/000460258
46. Kilinc Karaarslan, I, Teban, L, Dawid, M, Tanew, A, Kittler, H. Changes in the dermoscopic appearance of melanocytic naevi after photochemotherapy or narrow-band ultraviolet B phototherapy. *J. Eur. Acad. Dermatol. Venereol. JEADV* 2007;21:526–531. https://doi.org/10.1111/j.1468-3083.2006.02020.x
47. Kim, NH, Zell, DS, Kolm, I, Oliviero, M, Rabinovitz, HS. The dermoscopic differential diagnosis of yellow lobularlike structures. *Arch. Dermatol.* 2008;144:962–962. https://doi.org/10.1001/archderm.144.7.962
48. Kittler, H, Marghoob, AA, Argenziano, G, Carrera, C, Curiel-Lewandrowski, C, Hofmann-Wellenhof, R, Malvehy, J, Menzies, S, Puig, S, Rabinovitz, H, Stolz, W, Saida, T, Soyer, HP, Siegel, E, Stoecker, WV, Scope, A, Tanaka, M, Thomas, L, Tschandl, P, Zalaudek, I, Halpern, A. Standardization of terminology in dermoscopy/dermatoscopy: results of the third consensus conference of the International Society of Dermoscopy. *J. Am. Acad. Dermatol.* 2016;74:1093–1106. https://doi.org/10.1016/j.jaad.2015.12.038
49. Kiyohara, T, Satoh, S, Yasuta, M, Kumakiri, M. Irregular fibrillar pattern is an artifactual expression of parallel ridge pattern on the pressure-loaded area of the sole: the efficacy of oblique view dermoscopy. *J. Dermatol.* 2012;39:927–928. https://doi.org/10.1111/j.1346-8138.2011.01469.x
50. Kossard, S, Zagarella, S. Spotted cicatricial alopecia in dark skin. A dermoscopic clue to fibrous tracts. *Australas. J. Dermatol.* 1993;34:49–51.
51. Lacarrubba, F, Micali, G, Tosti, A. Scalp dermoscopy or trichoscopy. *Curr. Probl. Dermatol.* 2015;47:21–32. https://doi.org/10.1159/000369402
52. Lallas, Aimilios, Apalla, Z, Ioannides, D, Argenziano, G, Castagnetti, F, Moscarella, E, Longo, C, Palmieri, T, Ramundo, D, Zalaudek, I. Dermoscopy in the diagnosis and management of basal cell carcinoma. *Future Oncol. Lond. Engl.* 2015;11:2975–2984. https://doi.org/10.2217/fon.15.193

53. Lallas, A, Giacomel, J, Argenziano, G, García-García, B, González-Fernández, D, Zalaudek, I, Vázquez-López, F. Dermoscopy in general dermatology: practical tips for the clinician. *Br. J. Dermatol.* 2014;170:514–526. https://doi.org/10.1111/bjd.12685
54. Lallas, A, Kyrgidis, A, Tzellos, TG, Apalla, Z, Karakyriou, E, Karatolias, A, Lefaki, I, Sotiriou, E, Ioannides, D, Argenziano, G, Zalaudek, I. Accuracy of dermoscopic criteria for the diagnosis of psoriasis, dermatitis, lichen planus and pityriasis rosea. *Br. J. Dermatol.* 2012;166:1198–1205. https://doi.org/10.1111/j.1365-2133.2012.10868.x
55. Lallas, A, Pyne, J, Kyrgidis, A, Andreani, S, Argenziano, G, Cavaller, A, Giacomel, J, Longo, C, Malvestiti, A, Moscarella, E, Piana, S, Specchio, F, Hofmann-Wellenhof, R, Zalaudek, I. The clinical and dermoscopic features of invasive cutaneous squamous cell carcinoma depend on the histopathological grade of differentiation. *Br. J. Dermatol.* 2015;172:1308–1315. https://doi.org/10.1111/bjd.13510
56. Lallas, A, Tschandl, P, Kyrgidis, A, Stolz, W, Rabinovitz, H, Cameron, A, Gourhant, JY, Giacomel, J, Kittler, H, Muir, J, Argenziano, G, Hofmann-Wellenhof, R, Zalaudek, I. Dermoscopic clues to differentiate facial lentigo maligna from pigmented actinic keratosis. *Br. J. Dermatol.* 2016;174:1079–1085. https://doi.org/10.1111/bjd.14355
57. Lallas, A, Tzellos, T, Kyrgidis, A, Apalla, Z, Zalaudek, I, Karatolias, A, Ferrara, G, Piana, S, Longo, C, Moscarella, E, Stratigos, A, Argenziano, G. Accuracy of dermoscopic criteria for discriminating superficial from other subtypes of basal cell carcinoma. *J. Am. Acad. Dermatol.* 2014;70:303–311. https://doi.org/10.1016/j.jaad.2013.10.003
58. Liebman, TN, Rabinovitz, HS, Dusza, SW, Marghoob, AA. White shiny structures: dermoscopic features revealed under polarized light. *J. Eur. Acad. Dermatol. Venereol. JEADV* 2012;26:1493–1497. https://doi.org/10.1111/j.1468-3083.2011.04317.x
59. Liebman, TN, Scope, A, Rabinovitz, H, Braun, RP, Marghoob, AA. Rosettes may be observed in a range of conditions. *Arch. Dermatol.* 2011;147:1468. https://doi.org/10.1001/archdermatol.2011.312
60. Lin, J, Koga, H, Takata, M, Saida, T. Dermoscopy of pigmented lesions on mucocutaneous junction and mucous membrane. *Br. J. Dermatol.* 2009;161:1255–1261. https://doi.org/10.1111/j.1365-2133.2009.09251.x
61. Malvehy, J, Braun, RP, Puig, S, Marghoob, AA, Kopf, AW. *Handbook of Dermoscopy*, 1st edition. New York: CRC Press; 2006.
62. Marghoob, AA, Braun, R (Eds.). *An Atlas of Dermoscopy*, 2nd edition. London: CRC Press; 2012.
63. Massi, D, De Giorgi, V, Carli, P, Santucci, M. Diagnostic significance of the blue hue in dermoscopy of melanocytic lesions: a dermoscopic-pathologic study. *Am. J. Dermatopathol.* 2001a;23:463–469.
64. Massi, D, De Giorgi, V, Soyer, HP. Histopathologic correlates of dermoscopic criteria. *Dermatol. Clin.* 2001b;19;259–268, vii.
65. Maumi, Y, Kimoto, M, Kobayashi, K, Ito, N, Saida, T, Tanaka, M. Oblique view dermoscopy changes regular fibrillar pattern into parallel furrow pattern. *Dermatol. Basel Switz.* 2009;218:385–386. https://doi.org/10.1159/000202986
66. Micantonio, T, Gulia, A, Altobelli, E, Cesare, AD, Fidanza, R, Riitano, A, Fargnoli, MC, Peris, K. Vascular patterns in basal cell carcinoma. *J. Eur. Acad. Dermatol. Venereol.* 2011;25:358–361. https://doi.org/10.1111/j.1468-3083.2010.03734.x
67. Minagawa, A. Dermoscopy-pathology relationship in seborrheic keratosis. *J. Dermatol.* 2017;44:518–524. https://doi.org/10.1111/1346-8138.13657
68. Miteva, M, Tosti, A. Dermoscopy guided scalp biopsy in cicatricial alopecia. *J. Eur. Acad. Dermatol. Venereol. JEADV* 2013;27:1299–1303. https://doi.org/10.1111/j.1468-3083.2012.04530.x
69. Miteva, M, Tosti, A. Hair and scalp dermatoscopy. *J. Am. Acad. Dermatol.* 2012;67:1040–1048. https://doi.org/10.1016/j.jaad.2012.02.013
70. Miyazaki, A, Saida, T, Koga, H, Oguchi, S, Suzuki, T, Tsuchida, T. Anatomical and histopathological correlates of the dermoscopic patterns seen in melanocytic nevi on the sole: a retrospective study. *J. Am. Acad. Dermatol.* 2005;53:230–236. https://doi.org/10.1016/j.jaad.2005.04.045
71. Morales, A, Puig, S, Malvehy, J, Zaballos, P. Dermoscopy of molluscum contagiosum. *Arch. Dermatol.* 2005;141:1644. https://doi.org/10.1001/archderm.141.12.1644
72. Mubki, T, Rudnicka, L, Olszewska, M, Shapiro, J. Evaluation and diagnosis of the hair loss patient: part II. Trichoscopic and laboratory evaluations. *J. Am. Acad. Dermatol.* 2014;71:431.e1–431.e11. https://doi.org/10.1016/j.jaad.2014.05.008
73. Nascimento, MM, Shitara, D, Enokihara, MMSS, Yamada, S, Pellacani, G, Rezze, GG. Inner gray halo, a novel dermoscopic feature for the diagnosis of pigmented actinic keratosis: clues for the differential diagnosis with lentigo maligna. *J. Am. Acad. Dermatol.* 2014;71:708–715. https://doi.org/10.1016/j.jaad.2014.05.025
74. Navarrete-Dechent, C, Bajaj, S, Marchetti, MA, Rabinovitz, H, Dusza, SW, Marghoob, AA. Association of shiny white blotches and strands with nonpigmented basal cell carcinoma: evaluation of an additional dermoscopic diagnostic criterion. *JAMA Dermatol.* 2016;152:546–552. https://doi.org/10.1001/jamadermatol.2015.5731
75. Navarrete-Dechent, C, Liopyris, K, Cordova, M, Busam, KJ, Marghoob, AA, Chen, C-SJ. Reflectance confocal microscopic and en face histopathologic correlation of the dermoscopic "Circle Within a Circle" in Lentigo Maligna. *JAMA Dermatol.* 2018;154:1092–1094. https://doi.org/10.1001/jamadermatol.2018.2216
76. Okamoto, N, Aoto, T, Uhara, H, Yamazaki, S, Akutsu, H, Umezawa, A, Nakauchi, H, Miyachi, Y, Saida, T, Nishimura, EK. A melanocyte–melanoma precursor niche in sweat glands of volar skin. *Pigment Cell Melanoma Res.* 2014;27:1039–1050. https://doi.org/10.1111/pcmr.12297
77. Persechino, F, De Carvalho, N, Ciardo, S, De Pace, B, Casari, A, Chester, J, Kaleci, S, Stanganelli, I, Longo, C, Farnetani, F, Pellacani, G. Folliculotropism in pigmented facial macules: differential diagnosis with reflectance confocal microscopy. *Exp. Dermatol.* 2018;27:227–232. https://doi.org/10.1111/exd.13487
78. Palleschi, GM, Cipollini, EM, Torchia, D, Torre, E, Urso, C. Fibrillar pattern of a plantar acquired melanocytic naevus: correspondence between epiluminescence microscopy and transverse section histology. *Clin. Exp. Dermatol.* 2006;31:449–451. https://doi.org/10.1111/j.1365-2230.2006.02060.x
79. Pizzichetta, MA, Canzonieri, V, Soyer, PH, Rubegni, P, Talamini, R, Massone, C. Negative pigment network and shiny white streaks: a dermoscopic-pathological correlation study. *Am. J. Dermatopathol.* 2014;36:433–438. https://doi.org/10.1097/DAD.0000000000000019
80. Pozzobon, FC, Puig-Butillé, JA, González-Alvarez, T, Carrera, C, Aguilera, P, Alos, L, Badenas, C, Grichnik, JM, Malvehy, J, Puig, S. Dermoscopic criteria associated with BRAF and NRAS mutation status in primary cutaneous melanoma. *Br. J. Dermatol.* 2014;171:754–759. https://doi.org/10.1111/bjd.13069
81. Ribero, S, Argenziano, G, Lallas, A, Moscarella, E, Benati, E, Raucci, M, Piana, S, Longo, C. Dermoscopic features predicting the presence of mitoses in thin melanoma. *J. Dermatol. Sci.* 2017;86:158–161. https://doi.org/10.1016/j.jdermsci.2017.01.013
82. Richarz, NA, Barboza, L, Monsonís, M, González-Enseñat, MA, Vicente, A. Trichoscopy helps to predict the time point of clinical cure of tinea capitis. *Australas. J. Dermatol.* 2018. https://doi.org/10.1111/ajd.12830
83. Rosendahl, C, Cameron, A, Argenziano, G, Zalaudek, I, Tschandl, P, Kittler, H. Dermoscopy of squamous cell carcinoma and keratoacanthoma. *Arch. Dermatol.* 2012;148:1386–1392. https://doi.org/10.1001/archdermatol.2012.2974
84. Rossi, A, Fortuna, MC, Pranteda, G, Garelli, V, Di Nunno, D, Mari, E, Calvieri, S, Carlesimo, M. Clinical, histological and trichoscopic correlations in scalp disorders. *Dermatol. Basel Switz.* 2015;231:201–208. https://doi.org/10.1159/000430909

85. Russo, T, Piccolo, V, Ferrara, G, Agozzino, M, Alfano, R, Longo, C, Argenziano, G. Dermoscopy pathology correlation in melanoma. *J. Dermatol.* 2017;44:507–514. https://doi.org/10.1111/1346-8138.13629
86. Saida, T, Koga, H. Dermoscopic patterns of acral melanocytic nevi: their variations, changes, and significance. *Arch. Dermatol.* 2007;143:1423–1426. https://doi.org/10.1001/archderm.143.11.1423
87. Sanchez, MI, Rabinovitz, HS, Oliviero, MC, Elgart, GW, Perez, C, Puig, S, Malvehy, J, Grichnik, JM. Dark homogeneous streak dermoscopic pattern correlating with specific KIT mutations in melanoma. *JAMA Dermatol.* 2014;150:633–639. https://doi.org/10.1001/jamadermatol.2013.8442
88. Schiffner, R, Schiffner-Rohe, J, Vogt, T, Landthaler, M, Wlotzke, U, Cognetta, AB, Stolz, W. Improvement of early recognition of lentigo maligna using dermatoscopy. *J. Am. Acad. Dermatol.* 2000;42:25–32.
89. Scope, A, Benvenuto-Andrade, C, Agero, ALC, Marghoob, AA. Nonmelanocytic lesions defying the two-step dermoscopy algorithm. *Dermatol. Surg. Off. Publ. Am. Soc. Dermatol. Surg.* 2006;Al 32:1398–1406. https://doi.org/10.1111/j.1524-4725.2006.32312.x
90. Scope, A, Busam, KJ, Malvehy, J, Puig, S, McClain, SA, Braun, RP, Marghoob, AA. Ex vivo dermoscopy of melanocytic tumors: time for dermatopathologists to learn dermoscopy. *Arch. Dermatol.* 2007;143:1548–1552. https://doi.org/10.1001/archderm.143.12.1548
91. Scope, A, Ardigo, M, Marghoob, AA. Correlation of dermoscopic globule-like structures of dermatofibroma using reflectance confocal microscopy. *Dermatol. Basel Switz.* 2008;216:81–82. https://doi.org/10.1159/000109364
92. Sgouros, D, Apalla, Z, Ioannides, D, Katoulis, A, Rigopoulos, D, Sotiriou, E, Stratigos, A, Vakirlis, E, Lallas, A. Dermoscopy of common inflammatory disorders. *Dermatol. Clin.* 2018. https://doi.org/10.1016/j.det.2018.05.003
93. Shitara, D, Ishioka, P, Alonso-Pinedo, Y, Palacios-Bejarano, L, Carrera, C, Malvehy, J, Puig, S. Shiny white streaks: a sign of malignancy at dermoscopy of pigmented skin lesions. *Acta Derm. Venereol.* 2014;94:132–137. https://doi.org/10.2340/00015555-1683
94. Shitara, D, Nascimento, M, Ishioka, P, Carrera, C, Alós, L, Malvehy, J, Puig, S. Dermoscopy of Naevus-associated melanomas. *Acta Derm. Venereol.* 2015;95:671–675. https://doi.org/10.2340/00015555-2009
95. Silva, VPM da, Ikino, JK, Sens, MM, Nunes, DH, Di Giunta, G. Dermoscopic features of thin melanomas: a comparative study of melanoma in situ and invasive melanomas smaller than or equal to 1mm. *An. Bras. Dermatol.* 2013;88:712–717. https://doi.org/10.1590/abd1806-4841.20132017
96. Slutsky, JB, Marghoob, AA. The zig-zag pattern of lentigo maligna. *Arch. Dermatol.* 2010;146:1444. https://doi.org/10.1001/archdermatol.2010.307
97. Soyer, HP, Massone, C, Ferrara, G, Argenziano, G. Limitations of histopathologic analysis in the recognition of melanoma: a plea for a combined diagnostic approach of histopathologic and dermoscopic evaluation. *Arch. Dermatol.* 2005;141:209–211. https://doi.org/10.1001/archderm.141.2.209
98. Starace, M, Dika, E, Fanti, PA, Patrizi, A, Misciali, C, Alessandrini, A, Bruni, F, Piraccini, BM. Nail apparatus melanoma: dermoscopic and histopathologic correlations on a series of 23 patients from a single centre. *J. Eur. Acad. Dermatol. Venereol. JEADV* 2018;32:164–173. https://doi.org/10.1111/jdv.14568
99. Tan, JM, Lambie, D, Sinnya, S, Sahebian, A, Soyer, HP, Prow, TW, Ardigò, M. Histopathology and reflectance confocal microscopy features of photodamaged skin and actinic keratosis. *J. Eur. Acad. Dermatol. Venereol. JEADV* 2016;30:1901–1911. https://doi.org/10.1111/jdv.13699
100. Thomas, C, Coates, SJ, Engelman, D, Chosidow, O, Chang, AY. Part I - Ectoparasites: scabies. *J. Am. Acad. Dermatol.* 2019. https://doi.org/10.1016/j.jaad.2019.05.109
101. Tosti, A. *Dermoscopy of the Hair and Nails*, Edición: 2. Boca Raton, FL: CRC Press; 2015.
102. Tosti, A. *Dermoscopy of Hair and Scalp Disorders: With Clinical and Pathological Correlations*, 1st edition. Boca Raton, FL: CRC Press; 2007.
103. Tschandl, P, Rosendahl, C, Kittler, H. Dermatoscopy of flat pigmented facial lesions. *J. Eur. Acad. Dermatol. Venereol. JEADV* 2015;29:120–127. https://doi.org/10.1111/jdv.12483
104. Urech, M, Kyrgidis, A, Argenziano, G, Reggiani, C, Moscarella, E, Longo, C, Alfano, R, Zalaudek, I, Lallas, A. Dermoscopic ulceration is a predictor of basal cell carcinoma response to imiquimod: a retrospective study. *Acta Derm. Venereol.* 2017;97:117–119. https://doi.org/10.2340/00015555-2464
105. Vaccari, S, Barisani, A, Salvini, C, Pirola, S, Preti, EP, Pennacchioli, E, Iacobone, AD, Patrizi, A, Tosti, G. Thin vulvar melanoma: a challenging diagnosis. Dermoscopic features of a case series. *Clin. Exp. Dermatol.* 2019 https://doi.org/10.1111/ced.14068
106. Vanden Daelen, A, Ferreira, I, Marot, L, Tromme, I. A digital dermoscopy follow-up illustration and a histopathologic correlation for angulated lines in extrafacial lentigo maligna. *JAMA Dermatol.* 2016;152:200–203. https://doi.org/10.1001/jamadermatol.2015.4132
107. Vázquez-López, F, Kreusch, J, Marghoob, AA. Dermoscopic semiology: further insights into vascular features by screening a large spectrum of nontumoral skin lesions. *Br. J. Dermatol.* 2004;150:226–231.
108. Vázquez-López, F, Manjón-Haces, JA, Maldonado-Seral, C, Raya-Aguado, C, Pérez-Oliva, N, Marghoob, AA. Dermoscopic features of plaque psoriasis and lichen planus: new observations. *Dermatol. Basel Switz.* 2003;207:151–156. https://doi.org/10.1159/000071785
109. Vestergaard, ME, Macaskill, P, Holt, PE, Menzies, SW. Dermoscopy compared with naked eye examination for the diagnosis of primary melanoma: a meta-analysis of studies performed in a clinical setting. *Br. J. Dermatol.* 2008;159:669–676. https://doi.org/10.1111/j.1365-2133.2008.08713.x
110. Waśkiel, A, Rakowska, A, Sikora, M, Olszewska, M, Rudnicka, L. Trichoscopy of alopecia areata: an update. *J. Dermatol.* 2018;45:692–700. https://doi.org/10.1111/1346-8138.14283
111. Watanabe, S, Sawada, M, Dekio, I, Ishizaki, S, Fujibayashi, M, Tanaka, M. Chronology of lichen planus-like keratosis features by dermoscopy: a summary of 17 cases. *Dermatol. Pract. Concept.* 2016;6:29–35. https://doi.org/10.5826/dpc.0602a06
112. Wiesner, T, Murali, R, Fried, I, Cerroni, L, Busam, K, Kutzner, H, Bastian, BC. A distinct subset of atypical Spitz tumors is characterized by BRAF mutation and loss of BAP1 expression. *Am. J. Surg. Pathol.* 2012;36:818–830. https://doi.org/10.1097/PAS.0b013e3182498be5
113. Wiesner, T, Obenauf, AC, Murali, R, Fried, I, Griewank, KG, Ulz, P, Windpassinger, C, Wackernagel, W, Loy, S, Wolf, I, Viale, A, Lash, AE, Pirun, M, Socci, ND, Rütten, A, Palmedo, G, Abramson, D, Offit, K, Ott, A, Becker, JC, Cerroni, L, Kutzner, H, Bastian, BC, Speicher, MR. Germline mutations in BAP1 predispose to melanocytic tumors. *Nat. Genet.* 2011;43:1018–1021. https://doi.org/10.1038/ng.910
114. Walter, B, Heukelbach, J, Fengler, G, Worth, C, Hengge, U, Feldmeier, H. Comparison of dermoscopy, skin scraping, and the adhesive tape test for the diagnosis of scabies in a resource-poor setting. *Arch. Dermatol.* 2011;147:468–473. https://doi.org/10.1001/archdermatol.2011.51
115. Wolner, ZJ, Yélamos, O, Liopyris, K, Rogers, T, Marchetti, MA, Marghoob, AA. Enhancing skin cancer diagnosis with dermoscopy. *Dermatol. Clin.* 2017;35:417–437. https://doi.org/10.1016/j.det.2017.06.003
116. Woltsche, N, Schmid-Zalaudek, K, Deinlein, T, Rammel, K, Hofmann-Wellenhof, R, Zalaudek, I. Abundance of the benign melanocytic universe: dermoscopic-histopathological correlation in nevi. *J. Dermatol.* 2017;44:499–506. https://doi.org/10.1111/1346-8138.13808

117. Yadav, S, Vossaert, KA, Kopf, AW, Silverman, M, Grin-Jorgensen, C. Histopathologic correlates of structures seen on dermoscopy (epiluminescence microscopy). *Am. J. Dermatopathol.* 1993;15:297–305.
118. Yélamos, O, Braun, RP, Liopyris, K, Wolner, ZJ, Kerl, K, Gerami, P, Marghoob, AA. Usefulness of dermoscopy/dermatoscopy to improve the clinical and histopathologic diagnosis of skin cancers. *J. Am. Acad. Dermatol.* 2018a. https://doi.org/10.1016/j.jaad.2018.07.072
119. Yélamos, O, Merkel, EA, Sholl, LM, Zhang, B, Amin, SM, Lee, CY, Guitart, GE, Yang, J, Wenzel, AT, Bunick, CG, Yazdan, P, Choi, J, Gerami, P. Nonoverlapping clinical and mutational patterns in melanomas from the female genital tract and atypical genital nevi. *J. Invest. Dermatol.* 2016;136:1858–1865. https://doi.org/10.1016/j.jid.2016.05.094
120. Yélamos, O, Navarrete-Dechent, C, Marchetti, MA, Rogers, T, Apalla, Z, Bahadoran, P, Blázquez-Sánchez, N, Busam, K, Carrera, C, Dusza, SW, Fouchardière, A de la, Ferrara, G, Gerami, P, Kittler, H, Lallas, A, Malvehy, J, Millán-Cayetano, JF, Nelson, KC, Quan, VL, Puig, S, Stevens, H, Thomas, L, Marghoob, AA. Clinical and dermoscopic features of cutaneous BAP1 inactivated melanocytic tumors: results of a multicenter case-control study by the International Dermoscopy Society (IDS). *J. Am. Acad. Dermatol.* 2018b. https://doi.org/10.1016/j.jaad.2018.09.014
121. Zaballos, P, Daufí, C, Puig, S, Argenziano, G, Moreno-Ramírez, D, Cabo, H, Marghoob, AA, Llambrich, Á, Zalaudek, I, Malvehy, J. Dermoscopy of solitary angiokeratomas: a morphological study. *Arch. Dermatol.* 2007;143:318–325. https://doi.org/10.1001/archderm.143.3.318
122. Zaballos, P, Llambrich, A, Pozo, LJ del, Landi, C, Pizarro, A, Vera, A, Bañuls, J. Dermoscopy of targetoid hemosiderotic hemangioma: a morphological study of 35 cases. *Dermatology* 2015;231:339–344. https://doi.org/10.1159/000439301
123. Zaballos, P, Puig, S, Llambrich, A, Malvehy, J. Dermoscopy of dermatofibromas: a prospective morphological study of 412 cases. *Arch. Dermatol.* 2008;144;75–83. https://doi.org/10.1001/archdermatol.2007.8
124. Zaballos, P, Rodero, J, Serrano, P, Cuellar, F, Guionnet, N, Vives, JM. Pyogenic granuloma clinically and dermoscopically mimicking pigmented melanoma. *Dermatol. Online J.* 2009;15:10.
125. Zalaudek, I, Argenziano, G, Ferrara, G, Soyer, HP, Corona, R, Sera, F, Cerroni, L, Carbone, A, Chiominto, A, Cicale, L, De Rosa, G, Ferrari, A, Hofmann-Wellenhof, R, Malvehy, J, Peris, K, Pizzichetta, MA, Puig, S, Scalvenzi, M, Staibano, S, Ruocco, V. Clinically equivocal melanocytic skin lesions with features of regression: a dermoscopic-pathological study. *Br. J. Dermatol.* 2004;150:64–71.
126. Zalaudek, I, Giacomel, J, Argenziano, G, Hofmann-Wellenhof, R, Micantonio, T, Di Stefani, A, Oliviero, M, Rabinovitz, H, Soyer, HP, Peris, K. Dermoscopy of facial nonpigmented actinic keratosis. *Br. J. Dermatol.* 2006;155:951–956. https://doi.org/10.1111/j.1365-2133.2006.07426.x
127. Zalaudek, I, Giacomel, J, Cabo, H, Di Stefani, A, Ferrara, G, Hofmann-Wellenhof, R, Malvehy, J, Puig, S, Stolz, W, Argenziano, G. Entodermoscopy: a new tool for diagnosing skin infections and infestations. *Dermatol. Basel Switz.* 2008;216:14–23. https://doi.org/10.1159/000109353
128. Zalaudek, I, Giacomel, J, Schmid, K, Bondino, S, Rosendahl, C, Cavicchini, S, Tourlaki, A, Gasparini, S, Bourne, P, Keir, J, Kittler, H, Eibenschutz, L, Catricalà, C, Argenziano, G. Dermatoscopy of facial actinic keratosis, intraepidermal carcinoma, and invasive squamous cell carcinoma: a progression model. *J. Am. Acad. Dermatol.* 2012;66:589–597. https://doi.org/10.1016/j.jaad.2011.02.011

4A PRIMARY DIAGNOSTIC ALGORITHMS: PATTERN ANALYSIS REVISED

Harald Kittler, Cliff Rosendahl, and Alan Cameron

Contents

Description of the method . . . 42
Basic elements . . . 42
Patterns formed by basic elements . . . 42
Colors . . . 43
An algorithmic approach using patterns, colors, and clues . . . 43
A short algorithm based on pattern analysis: "Chaos and Clues" . . . 45
How the system is applied . . . 45
Chaos . . . 45
Clues . . . 49
References . . . 49

Pattern analysis is known as the most powerful tool to analyze pigmented skin lesions by dermoscopy [15]. It is regarded as the method of experts, in contrast to simplified algorithms that are said to be more suitable for beginners [2–4]. Pattern analysis as originally formulated has developed organically as the field of dermoscopy has progressed. The lack of an overall structured logical approach to act as a basis for these additions makes it difficult to define exactly what now constitutes "pattern analysis."

This lack of clarity makes teaching beginners more difficult. Beginners in dermoscopy often are confused by opaque terminology and by the lack of precise, repeatable criteria. This language does not encourage the observer to formulate a precise description of lesions and on occasion, encourages or even requires the post hoc construction of a description to fit the diagnosis.

We propose a revised system of pattern analysis to offer this logical framework. It uses simple geometric terms and avoids subjective, metaphoric language. It is neither just a diagnosis by "Gestalt" nor justification of a diagnosis established at first glance. It is a way to take advantage of our human ability to recognize patterns and by formalizing the observation of these patterns, to interpret them in a meaningful way. This requirement of well-defined criteria expressed in simple language is not just a linguistic matter; it is a prerequisite for consistent logical analysis. Revised pattern analysis is a system based on terms defined clearly, precisely, and lucidly, which can be used for every morphologic aspect of dermoscopy [10]. It is designed to establish a standardized description language common to all diagnostic algorithms, to enhance communication, and to reduce errors. It is applicable to every pigmented lesion of the skin, melanocytic and nonmelanocytic [16], and on every anatomic site of the skin. It is also designed to reach the most specific diagnosis possible and not just classify lesions as "benign" or "malignant." In a consensus conference held in 2015, the International Society of Dermoscopy (IDS) included the descriptive terminology into the framework of standardized terms and provided a dictionary of suitable metaphoric and descriptive terms [12].

Description of the method

Basic elements

All patterns observed in dermoscopy are composed of five simple geometric elements. These basic elements are lines, pseudopods, circles, clods, and dots (Figure 4a.1). They are defined as follows:

(i) Line—a two-dimensional continuous object with length greatly exceeding width, extending in one direction.

(ii) Pseudopod—a line with a bulbous end.

(iii) Circle—a curved line equidistant from a central point.

(iv) Clod—any well-circumscribed, solid object larger than a dot. Clods may take any shape.

(v) Dot—an object too small to have a discernible shape.

The morphology of vessels is described using the same objective geometric terms as pigmented structures [11]. Additional line types (looped, serpentine, helical, and coiled) are defined for vessels, as these are rarely seen in pigmented structures (Figure 4a.2).

Patterns formed by basic elements

Every basic element may be part of a pattern (Figure 4a.3). A pattern is built up of multiple repetitions of the same single basic element. There is also a pattern "structureless," an area characterized by the absence of any of the basic elements or at least, with no basic element dominating. Lines form the most common and most specific patterns seen in dermatoscopy, so six patterns of lines are described: reticular, branched, angulated, parallel, radial, and curved (Figure 4a.4). Straight lines crossing each other in an angle of 90° forming a grid are termed "reticular," straight lines crossing each other in different angles are termed "branched," straight lines that do not cross each other are "parallel," and straight lines that converge to the center of the lesion or to a central dot or clod are called "radial." Lines that bend are not straight but "curved." Straight lines that do not intersect, and meet at angles larger than 90° in such a way that they form complete or incomplete polygonal shapes, are termed "angulated". One or two repetitions of a basic element are not sufficient to form a pattern;, a pattern has to cover a significant part of the lesion (25%). This means a pattern can be discerned by scanning the overall appearance of a lesion. Exceptions to this principle are: (i) any pseudopods or two or more radial lines are sufficient to constitute a pattern, and (ii) any lines that are reticular not due to collision with another lesion also constitute a pattern.

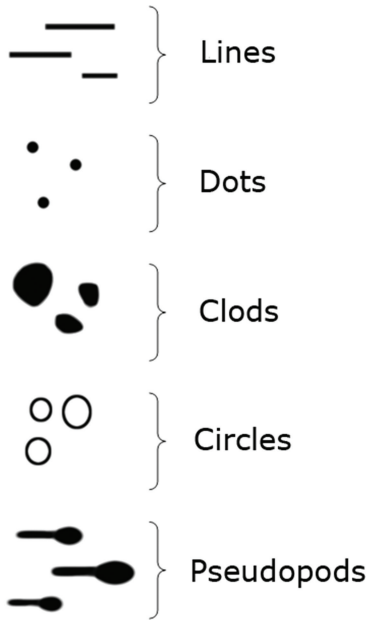

FIGURE 4A.1 Basic elements.

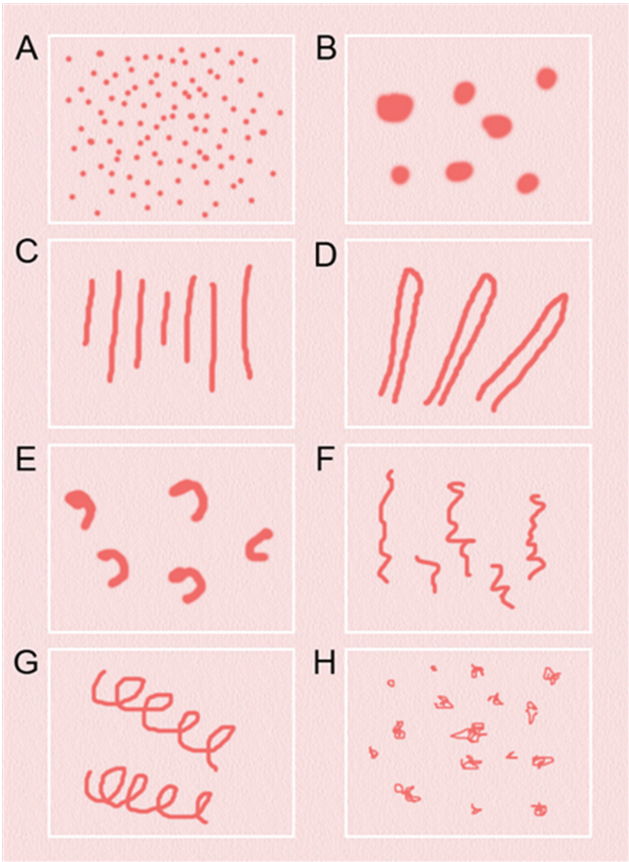

FIGURE 4A.2 Morphology of vessels described by simple geometric terms: (a) dots (vessels as dots), (b) clods (vessels as clods), (c–h) lines (vessels as lines). Vessels as lines can be (c) straight (no bend), (d) looped (one sharp bend), (e) curved (one gentle bend), (f) serpentine (multiple bends), (g) helical (multiple bends along a central axis, or (h) coiled (multiple, tight bends).

The same term is applied to patterns that are composed of the same type of basic element, regardless of color or diagnosis. For example, "brown globules" are brown clods, "red lacunes" are red clods, "blue ovoid nests" are blue clods, and "cobblestones" are large polygonal clods (Figure 4a.5). Every metaphoric expression can be replaced by simple terms (Table 4a.1).

Variations of basic patterns may be based either on morphologic appearance, for example, lines reticular may be thin or thick, or on variation in distribution of basic elements. For example, on acral skin, parallel lines may lie on ridges, in furrows, or may cross the ridges and furrows. Pigmented skin lesions may consist of a single pattern or of two or more patterns. Two or more patterns can be combined in a symmetric or asymmetric fashion (Figure 4a.6).

Colors

Colors seen in dermoscopy are created by various combinations of keratin, melanin, blood (including serum in crusts), collagen, and foreign material. The color of melanin as discerned by dermoscopy varies greatly depending on localization in the epidermis or dermis (Figure 4a.7); other materials show less variation. Variation in color description between dermoscopists is minimized by (i) not describing shades of brown, gray, and other colors, (ii) classifying number of colors only as either one or more than one color, and (iii) when relevant, classifying colors only as being predominantly those of melanin or predominantly not those of melanin.

An algorithmic approach using patterns, colors, and clues

By describing combinations of patterns and colors, the dermoscopic appearance of every pigmented lesion of the skin can be described in a simple, precise, logical, and repeatable fashion. Revised pattern analysis offers a flexible framework for constructing a personal algorithm to derive as specific a diagnosis as possible for all lesions, benign or malignant, melanocytic or nonmelanocytic. It is based on interpretation of patterns, colors, and clues. Diagnosis follows a defined series of simple steps in logical sequence. This sequence remains unchanged regardless of the nature of the lesion being analyzed. At each step, options are listed from those with the most diagnostic specificity to those with the least. Particular attention has been paid to making the decisions required of the dermoscopist as simple and unambiguous as possible. This reduces errors due to inevitable variations in perception between dermoscopists. It is important to note that there is no single true algorithm. The algorithm is not the method; the extraction of relevant dermoscopic features and formulation of a structured description in a form that permits logical analysis is the method of revised pattern analysis.

Diagnosis should start with description of the lesion's patterns and colors. Although description and analysis often proceed simultaneously in practice, in a logical sense, description should always precede analysis. This precedence of description over analysis becomes critically important in the assessment of difficult lesions. The clarity gained from a full formal description may lead to a diagnosis; if not, it ensures all relevant differential diagnoses are considered.

In this context, description is not to be interpreted as an attempt to convey a realistic "photographic" impression of the lesion's appearance. Rather, description is to be seen as the



FIGURE 4A.3 Patterns formed by basic elements: (a) dots, (b) clods, (c) circles, (d) pseudopods, and (e) absence of basic element, that is, structureless.



FIGURE 4A.4 Patterns formed by lines: (a) reticular, (b) branched, (c) angulated, (d) parallel, (e) radial, (f) curved.

extraction of features relevant to the diagnosis of skin lesions in the simplest possible terms.

First, pattern(s) of pigmentation are described. The first decision is to determine the number of patterns. For analytic purposes, only two options are considered: is there one pattern or more than one? Rarely is this decision at all ambiguous. Lesions with one pattern are further characterized by their color(s). By definition, lesions with one pattern and one color are symmetrical. If a lesion has more than one color, assessment of symmetry is the next step. A differential diagnosis is then formulated based on pattern and color(s).

A lesion with more than one pattern is analyzed similarly. The combination of patterns is assessed for symmetry or asymmetry. The higher the number of patterns, the more unlikely it is for the lesion to display symmetry. For lesions with more than one pattern, analysis proceeds on the basis of the most specific pattern in a lesion, not the most prominent (Figure 4a.8). As patterns are listed in order from most specific to least specific, proceeding stepwise through the algorithm achieves this automatically. Therefore, lesions with the pattern lines will be assessed by the differential diagnosis of this pattern. Only a lesion lacking the pattern lines is analyzed by the differential diagnosis of the pattern pseudopods. This process continues sequentially through circles, clods, and dots. A lesion that combines structureless with any other pattern is analyzed according to the other pattern, as structureless is the least specific pattern.

Assessment of patterns and colors may lead to a single diagnosis, but it also may lead to a narrow differential diagnosis. In this case, the lesion is then examined for clues to resolve the differential diagnosis. Sometimes, a pattern may also constitute a clue; for example, a structureless eccentric zone is both a pattern and a clue to the diagnosis of melanoma. Usually, however, clues are features too localized to constitute a pattern but nonetheless favoring one diagnosis over another.

For example, the pattern radial lines may equally be seen in melanoma, Reed nevus, and basal cell carcinoma (BCC). If these lines are centrally located or originate from a common base, this would be a clue to the diagnosis of BCC (Figure 4a.9). Often, however, clues are weak or even contradictory. For these cases, judgment is required in deciding how much weight to

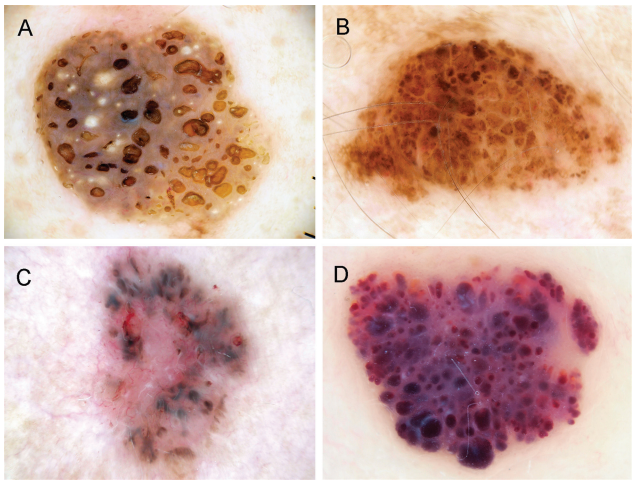

FIGURE 4A.5 Applied pattern analysis (one pattern: clods). Description of pattern should be independent of color and diagnosis. All four lesions have one pattern, clods (well-circumscribed, solid objects larger than a dot). (a) Yellow and white clods, seborrheic keratosis; (b) polygonal brown clods, nevus; (c) brown and gray clods, basal cell carcinoma; (d) red and purple clods, hemangioma. This terminology replaces metaphoric language such as comedo-like openings, crypts, milia-like cysts, red-blue lacunae, blue-gray ovoid nests, leaf-like areas, globules, and cobblestones.

be favored (Figure 4a.10). As a general principle, more weight should be given to the pattern overall than to any single clue. The most difficult part of dermoscopy is to correctly assign weight to clues, and particularly, to avoid overvaluing an unreliable or misleading clue. This is the role of experience in dermoscopy. As each dermoscopist's experience is different, reflecting different temperaments, teachers, practice styles, and locations, and almost certainly different interpretations of the same perceptual data, each dermoscopist will over time develop their own algorithm. Revised pattern analysis encourages this process; indeed, we consider this an essential step in truly learning dermoscopy. Revised pattern analysis offers a logical framework to make experience more than a series of anecdotes.

A short algorithm based on pattern analysis: "Chaos and Clues"

The authors also recognize a need for a simple diagnostic system based on pattern analysis. This has been achieved by simplifying the goal to that of identifying lesions requiring biopsy rather than reaching a specific diagnosis "Chaos and Clues" is a system that can be applied to every pigmented lesion (Chapter 5a). It does not require a decision as to whether a lesion is melanocytic, and it will detect pigmented malignancy with accuracy comparable to the earlier systems. The system has been tested on a set of consecutive pigmented lesions, including a significant proportion of benign and malignant nonmelanocytic lesions.

How the system is applied

Before application of the algorithmic method "Chaos and Clues," a lesion of concern is assessed for the dermatoscopic pattern recognition morphology of any of the five common benign lesions: nevus, benign keratinocytic (solar lentigo, seborrheic keratosis, etc.), dermatofibroma, hemangioma, and sebaceous gland hyperplasia). If none of those lesions can be identified, then the algorithmic method is applied.

TABLE 4A.1: Translation of Metaphoric Language into Simple Terminology Based on Simple Geometric Terms (Five Basic Elements)

Metaphoric language	Language using only simple geometric terms
Pseudonetwork	Circles, brown, and confluent
Strawberry pattern	Circles, red
Grapes	Circles, small
Blue-gray ovoid nests	Clods, blue
Comedo-like openings	Clods, brown or orange (rarely black), and circles
Cobblestone pattern	Clods, large, brown or skin colored, polygonal
Milky red globules	Clods, pink and small
Red lacunes	Clods, red
Globules	Clods, small, round, or oval
Milia-like cysts	Dots or clods, white
Peppering	Dots, gray
Annular–granular pattern	Dots, gray and circles, gray
Stars in the sky	Dots, white
Streaks	Lines
Branched streaks	Lines, branched
Brain-like appearance	Lines, curved, and thick
Fat fingers	Lines, curved, and thick
Fissures and ridges	Lines, curved, and thick
Fingerprinting	Lines, curved, and thin (plus circles occasionally)
Fibrillar pattern	Lines, parallel, crossing fissures, and ridges
Peripheral streaks	Lines, radial
Radial streaming	Lines, radial, and segmental
Starburst pattern	Lines, radial or pseudopods, peripheral
Leaf-like areas	Lines, radial, connect to a common base
Spoke wheel–like area	Lines, radial, converging to a central dot or clod
Pigment network	Lines, reticular
Atypical pigment network	Lines, reticular, and thick
Broadened pigment network	Lines, reticular, and thick
Delicate pigment network	Lines, reticular, and thin
Inverse pigment network	Lines, reticular, white or gray
Reticular depigmentation	Lines, reticular, and white
Negative pigment network	Lines, reticular, white or gray
Crypts	Lines, thick, and curved in combination with clods
Chrysalis/crystalline	Lines, white
Moth-eaten border	Sharply demarcated, scalloped border
Regular blotch	Structureless zone, centric
Irregular blotch	Structureless zone, eccentric
Blue hue	Structureless zone, blue
Blue-white veil	Structureless zone, blue
Milky red areas	Structureless zone, pink
Scarlike depigmentation	Structureless zone, white
Central white patch	Structureless zone, white, central

As suggested by the name, "Chaos and Clues" has two steps. First, each pigmented lesion is assessed for "chaos," defined as asymmetry of structure or color. If there is no such asymmetry, the lesion is considered to be benign. Lesions with chaos are further examined for the nine defined clues to malignancy. If one or more of these clues are present, then a biopsy is indicated on suspicion of malignancy. The more experienced dermoscopist then has the option of using revised pattern analysis to reach a specific diagnosis.

Chaos

Chaos is defined as the presence of dermatoscopic asym-



FIGURE 4A.6 Symmetry and asymmetry of pattern. Two patterns can be combined symmetrically in three ways, here illustrated by combinations of lines reticular and dots. (a) Dots at the periphery, lines reticular in the center; (b) dots in the center, lines reticular at the periphery; and (c) dots scattered evenly on lines reticular. All other combinations of two patterns will result in an asymmetric pattern.



FIGURE 4A.7 Colors seen by dermoscopy.

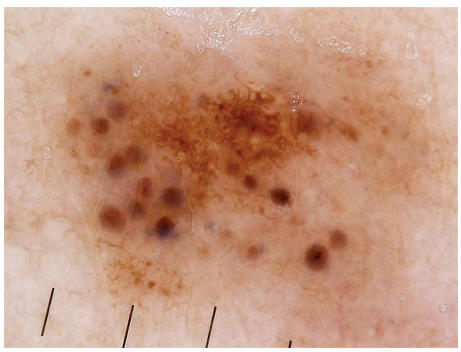

FIGURE 4A.8 Applied pattern analysis (more than one pattern). Although the pattern clods is the more prominent, lines reticular is the more specific pattern, so analysis is performed according to lines reticular. Clark nevus.

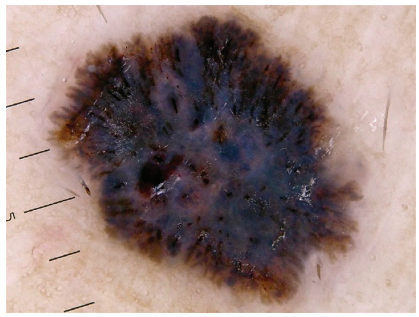

FIGURE 4A.9 Applied pattern analysis (more than one pattern). Using a two-step algorithm, the description of the peripheral structures determines the final diagnosis. Many would choose "radial streaming" (or "streaks") and not even consider the possibility of "leaf-like structures." Even if both possibilities are considered, simple observation of these peripheral structures will not assist in making this distinction. Objectively described, this lesion's patterns are peripheral radial lines distributed segmentally, and structureless. This description immediately leads to the differential diagnosis of basal cell carcinoma and melanoma, to be resolved by clues. Source: Pigmented basal cell carcinoma, image courtesy Dr Jean-Yves Gourhant.

abruptness. The shape of a lesion is not relevant, but any color other than skin color at the edge of a lesion (such as white) should be regarded as part of the lesion. Lesions without chaos are not analyzed any further. There are three exceptions where biopsy is indicated in lesions lacking chaos: (i) facial lesions with gray or blue structures, (ii) acral lesions with parallel lines on the ridges, and (iii) any elevated, firm, and continuously growing lesion [7]. Again, it is emphasized that these exceptions should only be invoked in a lesion that does not have the pattern recognition morphology of one of the five common

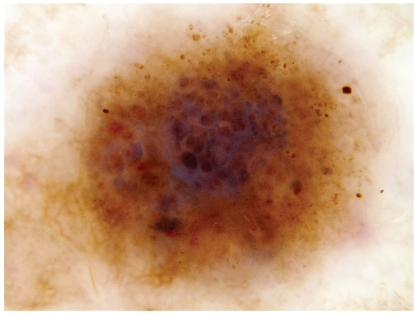

FIGURE 4A.10 Applied pattern analysis of more than one pattern. Pattern analysis is robust and minimizes errors of description. This lesion is most correctly analyzed as lines reticular plus clods (any lines reticular constitute a pattern, and this is a more specific pattern than clods) combined asymmetrically, with more than one color, leading to a differential diagnosis of melanoma and nevus. If the area of reticular lines is either not noted or not called a pattern, assessment then proceeds as for one pattern, clods. This leads to a differential diagnosis of BCC and melanoma. The same BCC/melanoma differential diagnosis is reached if the few dots are mistakenly accorded the status of a pattern. In all cases, the correct diagnosis of melanoma lies in the differential diagnosis. Breslow thickness 0.55 mm. Abbreviation: BCC, basal cell carcinoma.

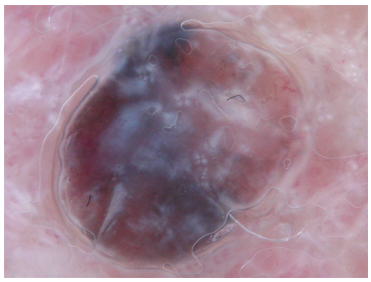

FIGURE 4A.11 Application of Chaos and Clues. Melanoma, invasive (Breslow thickness >1 mm) on the back. There is only one pattern (structureless), but chaos is produced by asymmetry of color. This combined with the clue of "gray lines" mandates biopsy.

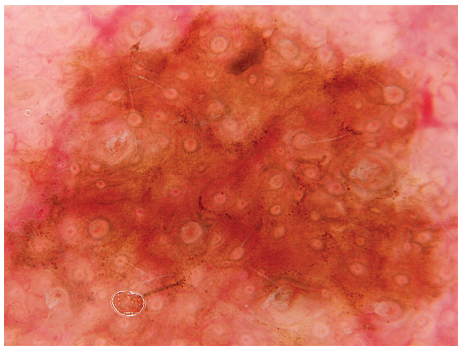

FIGURE 4A.12 Application of Chaos and Clues. Melanoma in situ (lentigo maligna) on the face. This lesion is arguably symmetrical by color and structure. However, on the face, melanomas may not exhibit chaos, and the presence of the clue of gray circles is sufficient to require biopsy.

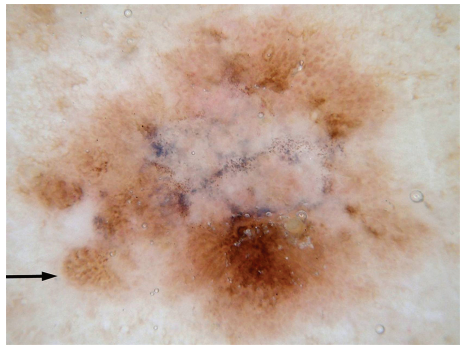

FIGURE 4A.13 Application of Chaos and Clues. pBD: There is chaos and the clue of gray dots, and therefore, a biopsy is required. Optionally, a specific diagnosis can be reached by applying pattern analysis to differentiate between melanoma, BCC, pBD, and lichen planus–like keratosis. Dots arranged in lines (arrow) are a clue to the diagnosis of pBD. Abbreviations: BCC, basal cell carcinoma; pBD, pigmented Bowen's disease.

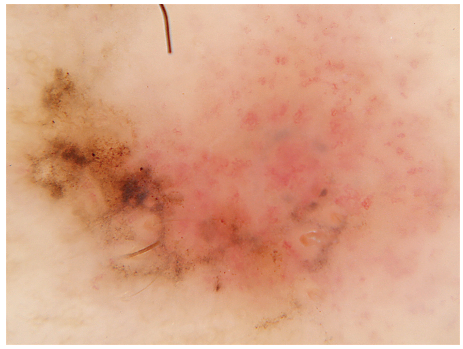

FIGURE 4A.14 Application of Chaos and Clues. Basal cell carcinoma: There is chaos and the clue of gray dots; therefore, the lesion requires biopsy. In this case, it is not possible to differentiate between the three types of pigmented malignancy (BCC, SCC, and melanoma) with pattern analysis. Even the distinction between melanocytic and nonmelanocytic cannot be made dermoscopically and must be left to the pathologist.

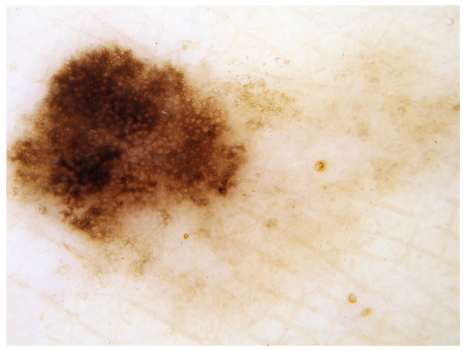

FIGURE 4A.15 Application of Chaos and Clues. Melanoma in situ. This lesion exhibits chaos and the clue of thick lines reticular and so, requires biopsy. In this case, the lesion can be classified as melanocytic by the dermoscopist with reasonable certainty, but this is not a part of the decision to biopsy. Reticular lines should not be depended upon to diagnose a lesion as melanocytic; they are also seen in nonmelanocytic

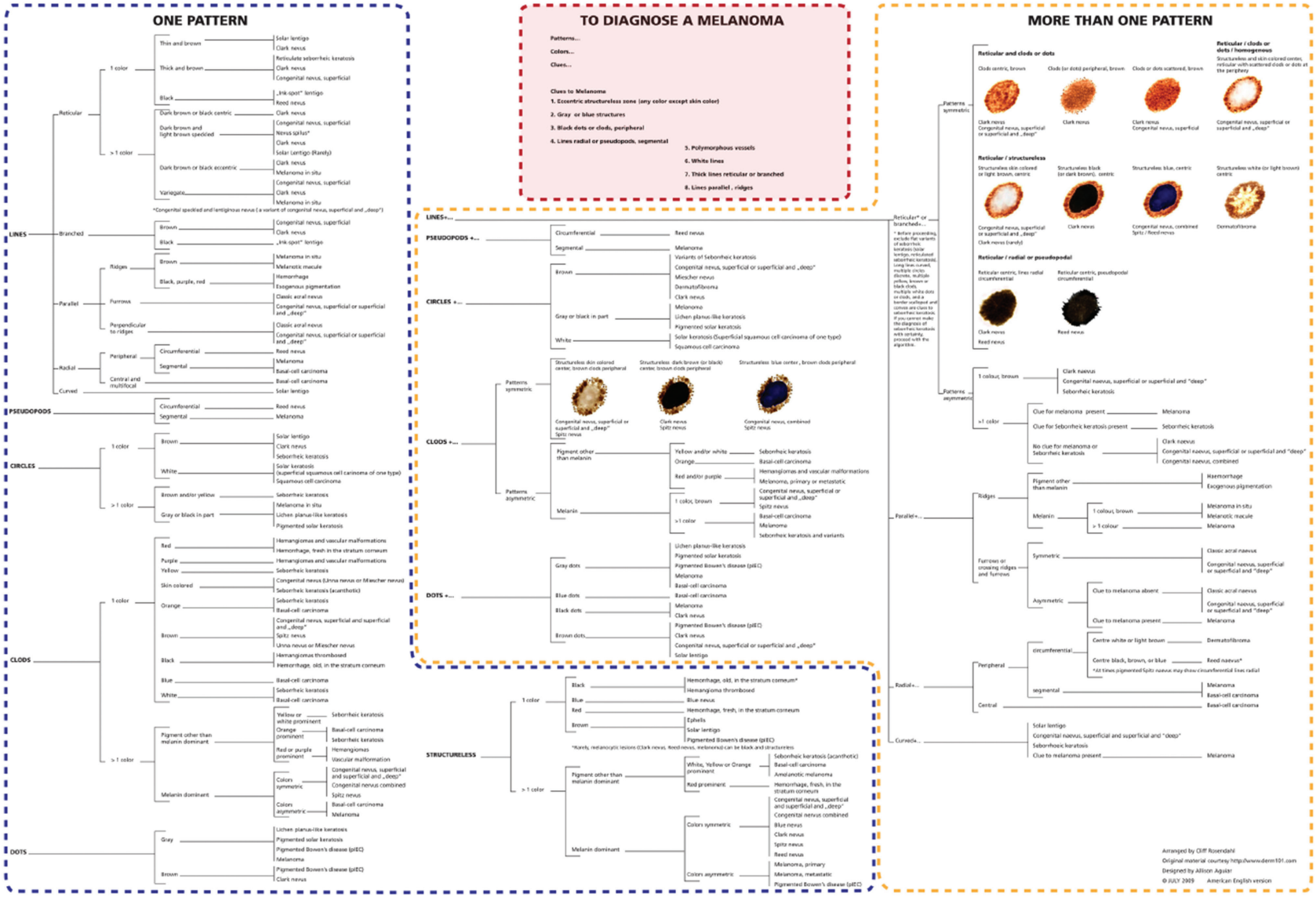

FIGURE 4A.16 Revised pattern analysis can also be applied in the evaluation of nonmelanocytic tumors. This flow diagram provides an overview of the revised pattern analysis approach in the evaluation of both melanocytic and nonmelanocytic tumors. Source: Original material courtesy of www.derm101.com; designed by Allison Aguiar.

face will have central gray color, but symmetry, a uniform gradual border, and historical stability will confirm benign status. Similarly, many solar lentigines will have pigmented circles, but a sharply defined scalloped border will permit pattern recognition diagnosis, thus avoiding biopsy.

Clues

In pattern analysis, a clue is a feature that favors one diagnosis over another, if analysis of patterns and colors has not led to a specific diagnosis. In Chaos and Clues, a clue is simply a feature that, when present, indicates that a lesion requires biopsy. One clue is sufficient. Both Chaos and Clues can be produced by the same feature. Lesion descriptions in Chaos and Clues use the same method and language as revised pattern analysis (Figure 4a.11). There are nine clues to pigmented malignancy (melanoma, pigmented BCC [pBCC], and pigmented Bowen's disease [pBD]):

1. Eccentric structureless area: any color except skin color.
2. Gray or blue structures: Gray dots may be seen in pBCC and pBD as well as melanoma [1, 5, 6]. They are a very common finding even in noninvasive melanomas due to free melanin or melanin in macrophages in the dermis. Gray circles occur in noninvasive facial melanomas (Figure 4a.12). Dense deposition of melanin in the dermis causes blue clods or blue structureless areas in pBCC and invasive melanomas.
3. Black dots or clods, peripheral: Peripheral black dots and clods are generally produced by melanoma cells or nests, respectively, close to or at the level of the stratum corneum due to pagetoid spread. Black structures are rarely seen in pigmented BCC or pBD.
4. Lines, radial or pseudopods, segmental: Lines, radial may be seen at any location in BCC. Pseudopods or lines, radial when circumferential are a feature of Reed nevus, but if segmental, they are highly specific for melanoma [14].
5. Polymorphous vessels: Vessels are called polymorphous when more than one pattern of vessel is seen. Polymorphous vessels reflect disordered malignant growth pattern and possibly increased metabolic demand of actively growing tumor tissue. If vessels as dots are present, melanoma is more likely than BCC.
6. White lines: To qualify as a clue, white lines must be clearly lighter than perilesional skin.
7. Lines reticular or branched, thick: To be called thick, the lines must be thicker than the spaces they surround. This pattern is produced by melanoma cells proliferating in the rete ridges and is not seen in pBCC or pBD.
8. Angulated lines: The lines are straight, do not intersect, and meet at angles larger than 90° in such a way that they form complete or incomplete polygonal shapes [8, 9, 13].
9. Lines, parallel, ridges (acral skin): This is a clue to malignancy even in the absence of chaos. Subcorneal hemorrhage also produces this pattern. Whether pigment lies on ridges or furrows is often easier to assess at the edges of a lesion.

Figures 4a.11–4a.15 show examples of how "Chaos and Clues" is applied in practice. Examining for "chaos" is a screening procedure and with practice, requires minimal cognition and time. If "chaos" is encountered, clues are searched for. This part of the process requires more cognition and a slightly greater investment of time, but as there are no "calculations" required, the process can be done with ease in a busy practice setting. The experienced dermoscopist may then choose to apply revised pattern analysis to resolve the differential diagnosis, but the prior application of "Chaos and Clues" will have reduced this workload. The flow diagram of Figure 4a.16 provides an overview of the revised pattern analysis approach in the evaluation of both melanocytic and nonmelanocytic lesions.

References

1. Altamura D, Menzies SW, Argenziano G, et al. Dermatoscopy of basal cell carcinoma: morphologic variability of global and local features and accuracy of diagnosis. *J Am Acad Dermatol*. 2010;62:67–75.
2. Argenziano G., Soyer H., Chimenti S, et al. Dermoscopy of pigmented skin lesions: results of a consensus meeting via the Internet. *J Am Acad Dermatol*. 2003;48:679–93.
3. Binder M, Kittler H, Steiner A, et al. Reevaluation of the ABCD rule for epiluminescence microscopy. *J Am Acad Dermatol*. 1999;40(2 Pt 1):171–6.
4. Binder M, Schwarz M, Winkler A, et al. Epiluminescence microscopy. A useful tool for the diagnosis of pigmented skin lesions for formally trained dermatologists. *Arch Dermatol*. 1995;131:286–91.
5. Braun RP, Gaide O, Oliviero M, et al. The significance of multiple blue-grey dots (granularity) for the dermoscopic diagnosis of melanoma. *Br J Dermatol*. 2007;157:907–13.
6. Cameron A, Rosendahl C, Tschandl P, Riedl E, Kittler H. Dermatoscopy of pigmented Bowen's disease. *J Am Acad Dermatol*. 2010;62:597–604.
7. Chamberlain AJ, Fritschi L, Kelly JW. Nodular melanoma: patients' perceptions of presenting features and implications for earlier detection. *J Am Acad Dermatol*. 2003;48:694–701.
8. Jaimes N, Marghoob AA, Rabinovitz H, Braun RP, Cameron A, Rosendahl C, Canning G, Keir J. Clinical and dermoscopic characteristics of melanomas on nonfacial chronically sun-damaged skin. *J Am Acad Dermatol*. 2015 Jun;72(6):1027–35.
9. Keir J. Dermatoscopic features of cutaneous non-facial non-acral lentiginous growth pattern melanomas. *Dermatol Pract Concept*. 2014 Jan 31;4(1):77–82.
10. Kittler, H. Dermatoscopy: introduction of a new algorithmic method based on pattern analysis for diagnosis of pigmented skin lesions. *Dermatopathol Pract Conc*. 2007;13:1.
11. Kittler, H., Riedl, E., Rosendahl, C., Cameron, A. Dermatoscopy of unpigmented lesions of the skin: a new classification of vessel morphology based on pattern analysis. *Dermatopathol Pract Conc*. 2010;14:3.
12. Kittler H, Marghoob AA, Argenziano G, Carrera C, Curiel-Lewandrowski C, Hofmann-Wellenhof R, Malvehy J, Menzies S, Puig S, Rabinovitz H, Stolz W, Saida T, Soyer HP, Siegel E, Stoecker WV, Scope A, Tanaka M, Thomas L, Tschandl P, Zalaudek I, Halpern A. Standardization of terminology in dermoscopy/dermatoscopy: results of the third consensus conference of the International Society of Dermoscopy. *J Am Acad Dermatol*. 2016 Jun;74(6):1093–106.
13. Lallas A, Longo C, Manfredini M, Benati E, Babino G, Chinazzo C, Apalla Z, Papageorgiou C, Moscarella E, Kyrgidis A, Argenziano G. Accuracy of dermoscopic criteria for the diagnosis of melanoma in situ. *JAMA Dermatol*. 2018 Apr 1;154(4):414–9.
14. Menzies, S.W., Crotty, K.A., McCarthy, W.H. The morphologic criteria of the pseudopod in surface microscopy. *Arch Dermatol*. 1995;131:436–40.
15. Pehamberger H., Steiner A., Wolff K. In vivo epiluminescence microscopy of pigmented skin lesions. I. Pattern analysis of pigmented skin lesions. *J Am Acad Dermatol*. 1987;17:571–83.
16. Rosendahl C, Tschandl P, Cameron A, Kittler H. Diagnostic accuracy of dermatoscopy for melanocytic and nonmelanocytic pigmented lesions. *J Am Acad Dermatol*. 2011 Jun;64(6):1068–73.

4B PRIMARY DIAGNOSTIC ALGORITHMS: TOP-DOWN 2-STEP PATTERN ANALYSIS ALGORITHM

Ashfaq A. Marghoob, Natalia Jaimes, and Ralph P. Braun

Contents

Introduction 50
Step 1: Benign lesions 50
Level 1: Patterns in acquired and small congenital nevi 50
Level 2: Patterns seen in IDN and dermatofibroma (both raised lesions/papules). 56
Level 3: Seborrheic keratosis and solar lentigo 57
Level 4: Other benign lesions 57
Step 2: Equivocal lesions 58
Step 2a: Disorganized lesions 58
Step 2b: Organized lesions 59
References 59

Introduction

The *top-down 2-step pattern analysis* approach builds upon the previous 2-step approach and combines it with concepts derived from the triage amalgamated dermoscopy algorithm using a top-down strategy of information processing. The top-down reasoning approach starts by hypothesizing the most probable diagnosis or differential diagnosis for the lesion under investigation and then uses dermoscopy to determine what specific features are present or absent to assist the clinician in narrowing the differential to the most likely diagnosis. The new *top-down 2-step pattern analysis* approach eliminates the requirement of subclassifying lesions into melanocytic (i.e., nevus vs melanoma) and nonmelanocytic lesions in step 1.[1–3] In step 1 of the new algorithm, the observer is required to make a specific diagnosis by recognizing the patterns associated with common benign skin lesions (e.g., nevi, lentigines, seborrheic keratoses [SK], angiomas). If an unequivocal diagnosis of one of the benign lesions in step 1 cannot be made with confidence, then the lesion in question will need to be further evaluated in step 2. In step 2, the observer is required to determine whether the overall pattern of the lesion is organized or disorganized (i.e., distribution of colors and structures). Lesions displaying a disorganized pattern (i.e., asymmetric or chaotic) are evaluated in step 2a, and lesions manifesting an organized pattern are evaluated in step 2b. Lesions displaying a disorganized pattern have a high likelihood of being malignant, and based on the presence of specific structures, these lesions can usually be classified as basal cell carcinoma (BCC), squamous cell carcinoma (SCC), or melanoma (Step 2a). Lesions that are organized are likely benign; however, organized lesions displaying any of the following should still raise concern for malignancy: starburst pattern, negative network pattern, vessels, ulceration, or blue-black, gray, or white color (Step 2b) (Figure 4b.1).

Step 1: Benign lesions

In the top-down step 1, the observer is required to make a specific diagnosis by recognizing patterns associated with common benign skin lesions, including nevi, intradermal nevi (IDN), dermatofibromas (DF), lentigines, SK, angiomas, angiokeratomas, sebaceous hyperplasias, and clear cell acanthomas (CCA). This list of benign lesions can be expanded upon as experience is gained (e.g., poromas, xanthogranulomas, etc.). Within each diagnostic category (nevus, DF, SK, etc.), the individual dermoscopic structures present in a lesion need to be placed within the context of the other features present within the lesion. In other words, the global pattern defining a given diagnosis is contingent on the presence of specific structures that carry a high predictive value for the given diagnosis.

Step 1 is based on four-level diagnostic categories of common benign lesions. This ladder guides the observer through the top-down decision-making process as to whether or not a lesion adheres to a specific diagnosis (i.e., nevi, DF, IDN, SK, solar lentigo, other).

Level 1: Patterns in acquired and small congenital nevi (Chapters 7a, 7b, 7d, 7e)

These nevi consist of multiple subtypes, including junctional, compound, Spitz, Reed, and Clark's nevi. It is important to underscore that while these nevi display an organized pattern, each one requires interpretation taking into account contextual features including history, size of lesion, patient age, skin phenotype, anatomical location, and whether the lesion is an outlier or not. Outlier nevi are those that do not adhere to the signature nevus pattern displayed by the other nevi in the patient.

Overall, there are three specific structures that form recognizable patterns (i.e., network, globules, and homogeneous), and their combinations result in 12 benign patterns (Table 4b.1).

a. *Diffuse network/reticular pattern and patchy network/reticular pattern:* The diffuse reticular pattern consists of an organized network with minimal variation in its thickness and color (i.e., regular/typical network). The holes of the network are relatively uniform in their appearance. The patchy network pattern consists of islands of typical network distributed in an organized manner. The network patches all have the same type of network with minimal variability in the thickness and color of the lines. The key contextual feature that needs to be remembered is that that melanoma on sun-damaged

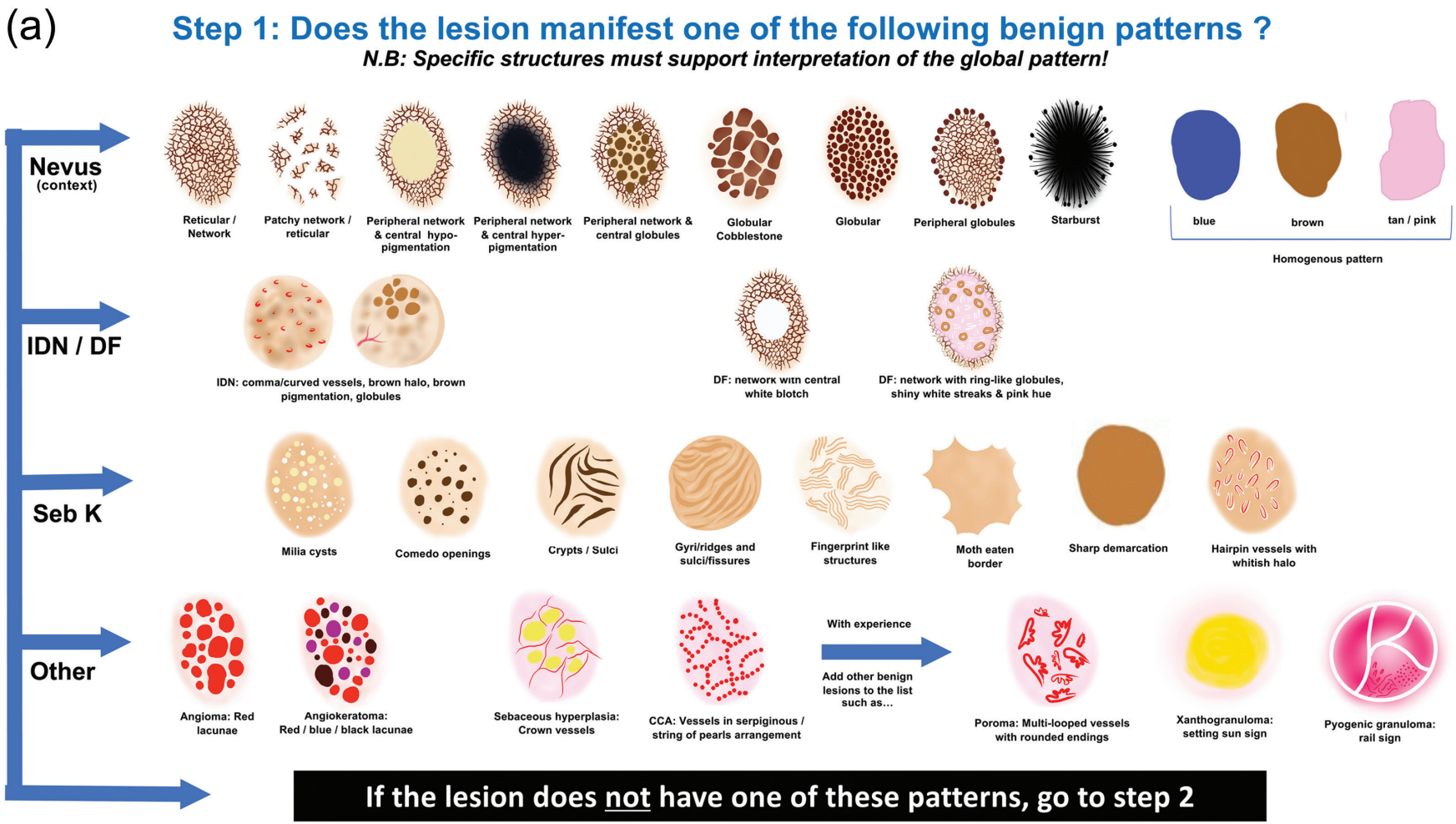

FIGURE 4B.1 The top-down 2-step pattern analysis: (a) step 1; (b) step 2a; (c) step 2b.

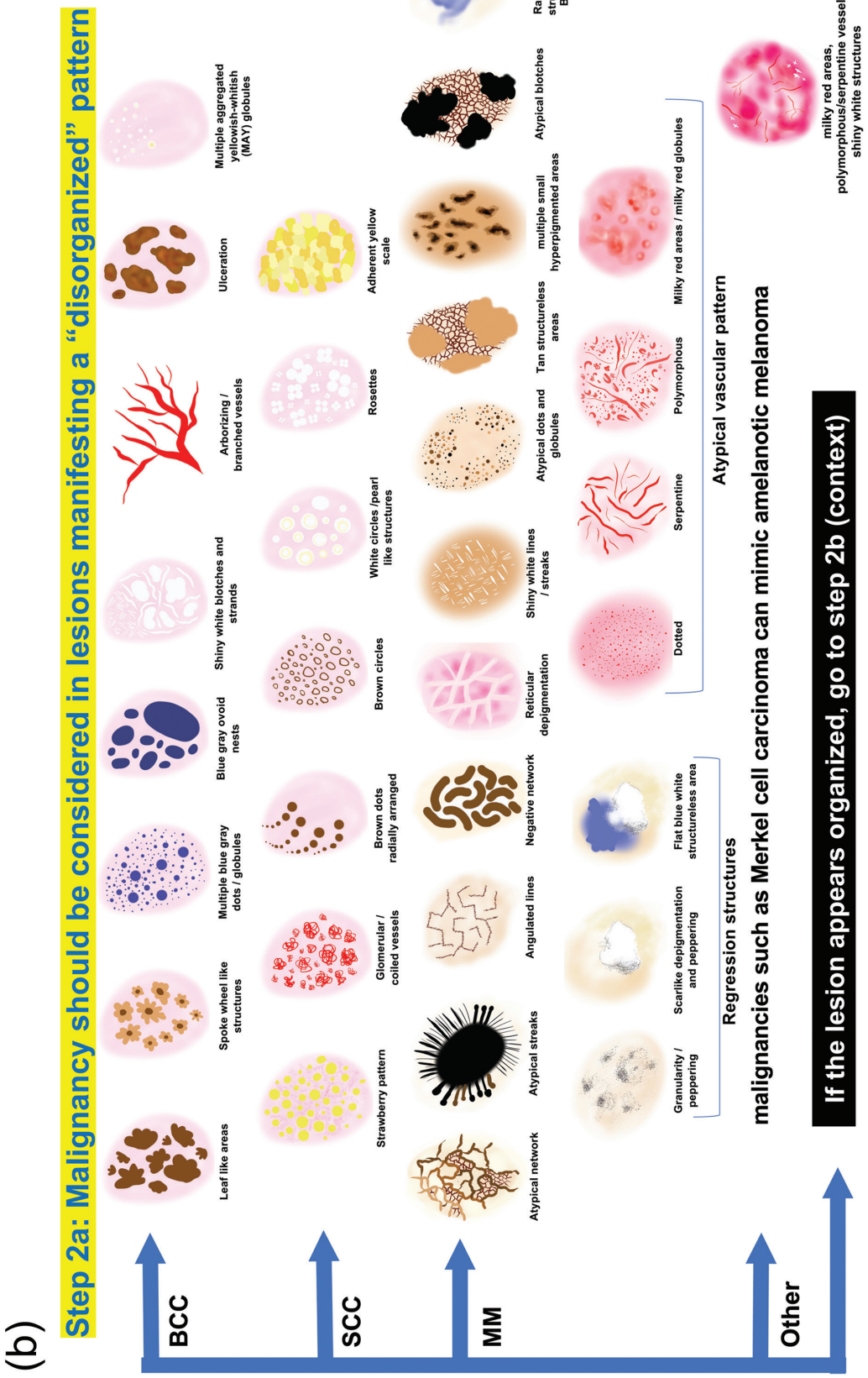

FIGURE 4B.1 (Continued)

(c)

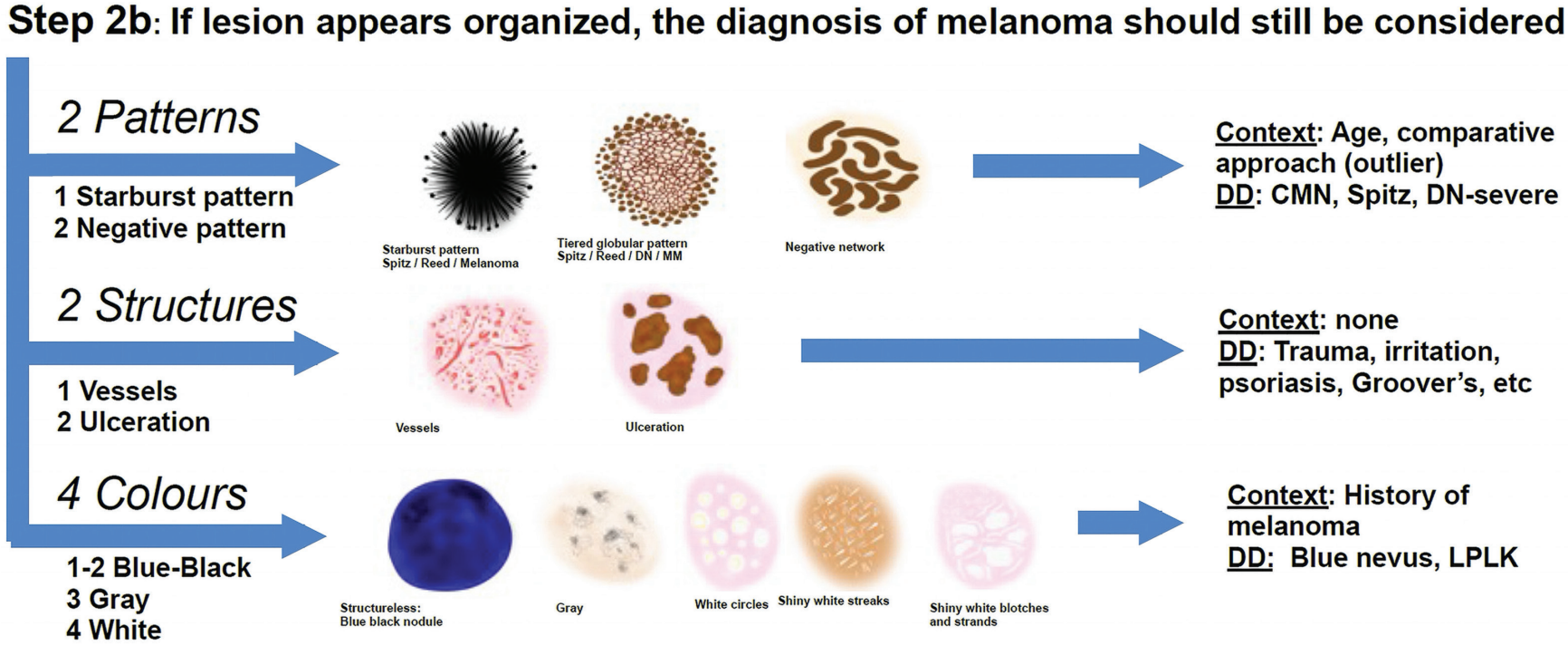

FIGURE 4B.1 (Continued)

TABLE 4B.1: Nevi Patterns in Acquired and Small Congenital Nevi

Main structure/*pattern*	Definition	Key contextual feature	Clues
Network			
Diffuse reticular	An organized network with minimal variation in its thickness and color (i.e., regular/typical network). The holes of the network are relatively uniform in their appearance.	**Sun-damaged skin.** Melanoma on sun-damaged skin can sometimes appear as isolated large lentiginous lesions with a network or patchy network pattern.	The clues to the diagnosis of melanoma include older age, the relatively large size of these lesions, their presence as isolated lesions on sun-damaged skin, and a network that is usually not distributed in an organized fashion.[4]
Patchy reticular	Islands of typical network distributed in an organized manner. The network patches have the same type of network with minimal variability in the thickness and color of the lines.		
Peripheral network with central hypopigmentation	Typical/regular network at the periphery of the lesion with a central portion that is hypopigmented (i.e., area is lighter in color compared with the network but darker than the surrounding skin).	**Phenotype/skin color.** Nevi with central hypopigmentation are usually seen in patients with lighter skin color, and nevi with central hyperpigmentation are seen in patients with darker skin phenotypes.	Lesions displaying central hypopigmentation in dark skin phenotypes and lesions with central hyperpigmentation in light skin phenotypes should raise the possibility of melanoma.[5–7]
Peripheral network with central hyperpigmentation	Typical/regular at the periphery of the lesion with a central portion that is hyperpigmented (i.e., blotch). This blotch is often due to the accumulation of melanin-laden corneocytes in the stratum corneum (i.e., lamella). This lamella can usually be tape-stripped off, revealing an underlying typical network.		
Globules (+/– Network)			
Globular pattern	Round to oval globules with minimal variability in globule size and color (i.e., regular/typical), which are distributed in an organized manner within the lesion.	**Age and location.** These nevi are usually congenital and found on the head/neck or torso.	Newly acquired lesions with a globular morphology occurring in an older individual and specially if the lesion is located on an extremity should raise concern for melanoma.[6, 8, 9]
Cobblestone globular	Large globules that take on the appearance of cobblestones. This is a pattern associated with congenital nevi.		While black and blue globules can on occasion be seen in congenital nevi, their presence should raise suspicion for melanoma.
Central brown globules with peripheral network	Typical/regular network at the periphery of the lesion with central brown globules that are regular with minimal variation in their size and color. On rare occasions, the globules can be white, as seen on balloon cell nevi.		
Reticular pattern with peripheral globules	Typical network with a peripheral rim of regular brown globules. This pattern is associated with the radial growth phase of Clark's/dysplastic nevi. These nevi usually display one rim of globules at the periphery and correspond on histopathology to dysplastic nevi with mild to moderate atypia. Nevi with peripheral globules can also display a multi-tiered peripheral globular pattern at the periphery. This pattern corresponds on histopathology with dysplastic nevi that display at least some degree of spitzoid morphology.	**Age and location**. These nevi are most common on the torso of younger to middle-aged patients, not infrequently with the atypical mole syndrome.	Newly acquired lesions should be viewed with caution if seen in older individuals, especially if the lesion is located on an extremity or reveals a melanoma-specific structure.[6, 10–12]
Streaks			
Starburst pattern	Darkly pigmented nevus with a symmetric distribution of streaks around its perimeter. This pattern is associated with Reed's nevi that are in their radial growth phase.	**Age.** Although streaks can also be encountered in superficial spreading melanoma, such melanomas are extremely rare in pre-adolescent individuals.	Lesions with a starburst pattern seen in children have an extremely high pretest probability for being Reed's nevi. In contrast, lesions with a starburst pattern seen in older individuals have a heightened pretest probability for melanoma.[13]

(*Continued*)

TABLE 4B.1 (CONTINUED): Nevi Patterns in Acquired and Small Congenital Nevi

Main structure/*pattern*	Definition	Key contextual feature	Clues
Homogeneous			
Homogeneous blue	Homogeneous blue color with a whitish veil that encompasses the entire lesion's surface is the hallmark of a blue nevus. The blue color and white veil in blue nevi will display minimal variation in the blue hues.	**History.** Since epidermotropic metastasis can mimic blue nevi, [14] having a previous history of an invasive melanoma becomes the key contextual feature to remember in a lesion with a presumed blue nevus.	If there are multiple hues (i.e., heterogeneous blue color or non-homogeneous veil), then one should consider the diagnosis of melanoma.
Homogeneous brown	Homogeneous brown color with minimal to no variation in its hues. While it is usually devoid of any other structures, on rare occasions, one can see a few regular dots/globules and fragments of network. This pattern is associated with small to medium congenital nevi.	**Age.** These nevi are present at birth or develop within the first few years of life and are stable lesions.	Newly acquired in adults should be viewed with caution. Such lesions, if not palpable, can be digitally monitored and biopsied if they display change.[15]
Homogeneous tan/pink	Featureless tan to pink color, but some can also display vessels.	**Phenotype/skin color.** These nevi are seen predominantly in individuals with skin types I–II.	Newly acquired nevi with a homogeneous tan to pink color in darker skin individuals should raise concern for amelanotic or hypomelanotic melanoma. Yet, amelanotic melanomas are also common in skin types I–II. Therefore, it remains imperative that these lesions be evaluated in context with the other nevi present on the patient's skin. Outlier lesions should always raise the index of suspicion for melanoma. If melanoma is in the differential diagnosis, and the lesion is nonpalpable, then it can be subjected to digital monitoring. Lesions that are raised or manifest change on follow-up should be viewed with extreme suspicion.[15, 16]

skin can sometimes appear as isolated large lentiginous lesions with a network or patchy network pattern. The clues to the diagnosis of melanoma include the older age of these patients, the relatively large size of these lesions, their presence as isolated lesions on sun-damaged skin, and that the network is usually not distributed in an organized fashion.[4]

b. *Peripheral network with central hypopigmentation and peripheral network with central hyperpigmentation:* The peripheral network is typical/regular in both of these nevi. In one, the central portion is hypopigmented (i.e., area is lighter in color compared with the network but darker than the surrounding skin), and in the other, the central portion is hyperpigmented (i.e., blotch). This blotch is often due to the accumulation of melanin-laden corneocytes in the stratum corneum (i.e., lamella). This lamella can usually be tape-stripped off, revealing an underlying typical network. The key contextual feature that needs to be remembered is that nevi with central hypopigmentation are usually seen in patients with lighter skin color, and nevi with central hyperpigmentation are seen in patients with darker skin phenotypes. Thus, lesions displaying central hypopigmentation in dark skin phenotypes and lesions with central hyperpigmentation in light skin phenotypes should raise the possibility of melanoma.[5–7]

c. *Nevi with globules, including lesions with a peripheral network with central brown globules, and globular nevi, including cobblestone globular nevi*. Peripheral network with central brown globules consists of nevi displaying a peripheral typical network with central brown globules that are regular with minimal variation in their size and color. Nevi with a globular pattern display only round to oval globules with minimal variability in globule size and color (i.e., regular/typical) and are distributed in an organized manner within the lesion. On rare occasions, the globules can be white, as seen on balloon cell nevi. While black and blue globules can on occasion be seen in congenital nevi, their presence should raise suspicion for melanoma. When globules are very large, they take on the appearance of cobblestones, creating the cobblestone globular pattern. This is a specific type of globular pattern, which consists of large brown angulated globules that create a pattern reminiscent of cobblestones. This is a pattern associated with congenital nevi. The key contextual feature that needs to be remembered is that nevi with globules in their center or throughout are usually congenital and are usually found on the head/neck or torso. Thus, newly acquired lesions with a globular morphology occurring in an older individual, and specially if the lesion is located on an extremity, should raise concern for melanoma.[6, 8, 9]

d. *Reticular pattern with peripheral globules:* This pattern consists of a typical network nevus that has a peripheral rim of regular brown globules. This pattern is associated with the radial growth phase of Clark's/dysplastic nevi and is commonly encountered in younger patients with the atypical mole syndrome. These nevi usually display one rim of globules at the periphery and correspond on histopathology to dysplastic nevi with mild to moderate atypia. Nevi with peripheral globules can also display a multi-tiered peripheral globular pattern at the periphery. This pattern corresponds on histopathology with dysplastic nevi that display at least some degree of a spitzoid morphology. The key contextual feature to remember regarding nevi with peripheral globules is age and location. These nevi are most common on the torso of younger to middle-aged patients. Newly acquired lesions displaying peripheral globules should be viewed with caution if seen in older individuals, especially if the lesion is located on an extremity or reveals a melanoma-specific structure.[6, 10–12]

e. *Starburst pattern:* The starburst pattern is an extremely easy-to-,recognize pattern consisting of a darkly pigmented nevus with a symmetric distribution of streaks arounds its perimeter. This pattern is associated with Reed's nevi that are in their radial growth phase. The key contextual feature to remember regarding starburst nevi is age, since streaks can also be encountered in superficial spreading melanoma; however, such melanomas are extremely rare in pre-adolescent individuals. Thus, lesions with a starburst pattern seen in children have an extremely high pretest probability for being Reed's nevi; however, lesions with a starburst pattern seen in older individuals have a heightened pretest probability for melanoma.[13]

f. *Homogeneous blue:* A homogeneous blue color with a whitish veil that encompasses the entire lesion's surface is the hallmark of a blue nevus. The blue color and white veil in blue nevi will display minimal variation in the blue hues. If there are multiple hues (i.e., heterogeneous blue color or nonhomogeneous veil), then one should consider the diagnosis of melanoma. The key contextual feature to remember in a lesion with a presumed blue nevus pattern is a previous history of an invasive melanoma, since epidermotropic metastasis can mimic blue nevi.[14]

g. *Homogeneous brown:* This pattern consists of a nevus with homogeneous brown color with minimal to no variation in its hues. While it is usually devoid of any other structures, on rare occasions, one can see a few regular dots/globules and fragments of network. This pattern is associated with small to medium congenital nevi. The main contextual feature is that these nevi are present at birth or develop within the first few years of life and are stable lesions. Thus, newly acquired homogeneous brown lesions in adults should be viewed with caution. Such lesions, if not palpable, can me digitally monitored and biopsied if they display change.[15]

h. *Homogeneous tan/pink:* These nevi display a featureless tan to pink color, but some can also display vessels. The key contextual feature in these nevi is skin phenotype. These nevi are seen predominantly in individuals with skin types I–II. Thus, newly acquired nevi with a homogeneous tan to pink color occurring in darker-skin individuals should raise concern for amelanotic or hypomelanotic melanoma. To complicate matters, amelanotic melanomas are also common in skin types I–II. Therefore, it remains imperative that these lesions be evaluated in context with the other nevi present on the patient's skin. Outlier lesions should always raise the index of suspicion for melanoma. If melanoma is in the differential diagnosis, and the lesion is nonpalpable, then it can be subjected to digital monitoring. Lesions that are raised or manifest change on follow-up should be viewed with extreme suspicion.[15, 16]

Level 2: Patterns seen in IDN and dermatofibroma (both raised lesions/papules)

a. **IDN** (Chapter 7c)

Key contextual features: IDN are first and foremost defined by their clinical morphology as either raised dome-shaped lesions located on the face (Miescher's nevi) or sessile mamillated lesions located on the torso (Unna's nevi). These nevi have preserved skin markings and may have hair emanating from their surface. IDN usually reveal one or more of the following features on dermoscopy:[17–19]

- Predominantly comma-shaped vessels or a polymorphous vascular pattern with at least some comma shaped vessels.
- Brown halo.
- Globules (including cobblestone-type globules).
- Small foci of tan to brown structureless pigment and/or hypopigmented areas.

IDN, especially of the Miescher's type, can sometimes be challenging to differentiate from BCC.[20] One of the main reasons for this is that IDN can at times reveal arborizing vessels, which raises the concern for BCC. *There are, however, multiple* ***clues*** that can assist in differentiating an IDN from a BCC[21]:

Clinical clues

- IDN tend to have been present on the skin for many years, without any history of change, and they do not spontaneously bleed.
- The skin markings in an IDN tend to be preserved, whereas in BCC they are lost, resulting in BCCs having a shiny surface.
- If hair is present within the lesion, then it is highly suggestive of an IDN.

Dermoscopic clues

- IDN wobble on dermoscopy, and BCC tend not to wobble.[22]
- A closer look at the arborizing vessels will also usually reveal that the extent of arborization in IDN tends to be much less than in BCC. In fact, in IDN, there may only be one arborizing point, creating a "Y"-shaped vessel.[18]

- The vessels in BCC tend to be much sharper in focus and have a much brighter red color.
- Unlike BCC, IDN do not reveal any shiny white blotches and strands on polarized dermoscopy.

b. **Dermatofibromas** (Chapter 6a)

Key contextual features and clues: DFs are defined first and foremost by their clinical characteristics of being firm papules that dimple on later pressure. A DF with this clinical morphology will usually reveal the following features when viewed with dermoscopy:

- A symmetric lesion with a peripheral network and a central white scarlike area. In the region between the network and the central scarlike area, one can see ring-like globules and vessels. When viewed with polarized light, the central scarlike area will usually manifest a pink hue and will often also reveal shiny white lines.

Level 3: Seborrheic keratosis and solar lentigo (Chapter 6e)

Key contextual features and clues:

- Borders: Well-demarcated, sharp borders are common to both lentigo and SK. In addition, the borders in a lentigo often display a moth-eaten morphology.
- Gyri/ridges and sulci/fissures. The sulci are often filled with keratin with a brownish color. Short keratin-filled sulci are also known as crypts. The presence of numerous gyri and sulci often creates a cerebriform to coral fan-like pattern.
- Fingerprint-like structures. These structures are seen in lentigines and correspond with early gyri formation. On rare occasions, these lines can be short and slightly curved ("U"-shaped). It is interesting that when present, all the "U"-shaped structures tend to be oriented in the same vectoral direction, resembling jelly that has been spread with a knife across the slice of bread (the jelly sign).
- Multi milia-like cysts.
- Multiple comedo-like openings.
- Hairpin (looped to twisted looped) vessels with a white halo. These hairpin vessels correspond with the capillary loops present in the dermal papilla. The white halo corresponds with the keratinocytes in in the rete ridges that surround the dermal papilla. It is not uncommon for some of these capillaries to become thrombosed and appear as small black dots or loops.
- NB: *heavily pigmented SKs (i.e., melanoacanthoma)* can display a blue-white veil. There are a few **clues** to help differentiate the blue-white veil in an SK from that seen in melanoma.
  - First, an SK will not display any other melanoma-specific structures, including streaks, atypical network, angulated lines, negative network, shiny white lines, atypical dots and globules.[23]
  - Second, within the blue-white veil of an SK, one will almost always see multiple comedo-like openings.
  - Third, and perhaps the most helpful clue, is the wobble test, in which the SK lesion will slide en bloc, whereas a melanoma will not and will wobble instead.[22]
- NB: *Lichen planus–like keratosis* (see Chapter 6e). A solar lentigo or SK can involute, and during this involution phase, they can reveal regression structures consisting of granularity/peppering. The presence of these regression structures may make it difficult to differentiate these lesions from melanoma. There are a few **clues** that may help.
  - First, involution of lentigo/SK usually occurs from the edge, moving centripetally. In presumed lentigo or SK, revealing regression structures in the center with the appearance of the peppering expanding centrifugally should raise concern, since this is a feature often associated with melanoma or a melanoma arising in a SK.
  - Second, in lesions that have not yet fully involuted, classic features of lentigo/SK can usually still be seen at the edge opposite or lateral to the area of peppering.
  - Third, the granularity in involuting lentigo/SK tends to be coarser, and often, the granules appear to be clumped.

Level 4: Other benign lesions

a. **Angioma and hemangiomas** (see Chapter 6g):

- Lacunae with red to maroon to bluish colors that are separated from each other with intervening stroma.

b. **Angiokeratomas** (see Chapter 6g):

- Lacunae with varying shades of red, maroon, and blue. In addition, there may be thrombosed lacunae that have a black color. The center of the lesion often has a blue-whitish veil, and the surrounding skin has an erythematous halo.

c. **Lymphangioma** (see Chapter 6g):

- Lacunae with a clear to slightly yellowish tinge of color. On occasion, there may be some blood present with a lymphangioma. In such cases, the blood tends to settle to the bottom of the lacunae due to gravity, creating lacunae displaying two discrete tones, known as two-toned lacunae with the hypopyon sign.[24]

d. **Sebaceous hyperplasia** (see Chapter 6h):

- Whitish/yellowish polylobular globular structures resembling popcorn.
- Crown vessels are usually seen. These vessels are present at the periphery. They radiate towards the center but do not cross its midline. Molluscum contagiosum will manifest a similar pattern.

e. **Clear cell acanthoma** (see Chapter 6h):

- Dotted or glomerular, arranged in a string of pearls pattern.

As expertise is accumulated, one can easily modify this step by adding other benign lesions, such as poroma and xanthogranuloma, among others.

Step 2: Equivocal lesions

Lesions that cannot be unequivocally diagnosed as one of the benign lesions listed in step 1 will proceed to step 2 for further evaluation. In step 2, the observer will determine whether the overall pattern of the lesion is organized or disorganized. This dichotomization is based on a gestalt impression on the degree of entropy displayed by the lesion based on the distribution of colors and structures. Lesions displaying a disorganized (i.e., asymmetric, chaotic) pattern are evaluated in step 2a, and lesions manifesting an organized pattern are evaluated in step 2b.

Step 2a: Disorganized lesions

This step is reserved for lesions manifesting a disorganized or chaotic appearance. In general, these lesions will prove to be cancer or cancer mimickers. The most common diagnosable cancers are BCC, SCC, and melanoma. Other malignancies, such as Merkel cell carcinoma, sebaceous carcinoma, and porocarcinoma, will also often appear disorganized. While clues such as color, location of tumor, and the presence of certain dermoscopic structures (e.g., polylobular structures in sebaceous carcinoma, or looped vessels with rounded endings in porocarcinoma) may suggest a specific rare cancer diagnosis, no structure or combination of structures can definitively diagnose these rare cancers via dermoscopy. However, since these lesions often display a disorganized pattern with features overlapping with BCC, SCC, or melanoma, they will undoubtedly get biopsied.

In addition, some benign lesions, such as a subset of dysplastic nevi, spitzoid nevi, and BAPomas, among others, can also manifest a disorganized pattern, and these lesions will likely get biopsied or at least closely monitored, since dermoscopy alone will not be able to discriminate them from melanoma. Depending on what technology comes to bear upon these lesions (i.e., short-term digital dermoscopy monitoring, confocal microscopy, electrical impedance spectroscopy, gene expression profiling by analyzing cells acquired via tape-stripping of the stratum corneum), these lesions will influence the total number of benign nevi being biopsied, thus impacting the clinician's benign to malignant biopsy ratio. With all the caveats mentioned, Step 2a focuses on correctly identifying BCC, SCC, and melanoma while not missing other less common skin malignancies.

1. BCC: The features associated with BCC are discussed in Chapter 6b and in brief, consist of the following:

a. Pigmented structures
    a. Leaf-like structures.
    b. Spoke wheel–like structures.
    c. Concentric globules.
    d. Blue-gray dots in a bird-shot scatter distribution.
    e. Blue-gray nonaggregated globules.
    f. Blue-gray ovoid nest.
b. Nonpigmented structures
    a. Arborizing vessels.
    b. Ulceration or multiple erosions.
    c. Shiny white blotches and strands seen with polarized dermoscopy.
    d. Multiple aggregated yellowish-whitish globules (MAY globules).

There is one subtype of BCC that rarely displays any of the BCC-specific features listed here.

*1.1. **Fibroepithelioma of Pinkus*** is a BCC subtype that clinically and dermoscopically appears different from other subtypes of BCC. Clinically, it tends to have a dry-scaly surface (not a shiny surface) and often is slightly sessile. Dermoscopically, it reveals features associated with melanoma, including nonarborizing polymorphous vessels, shiny white lines, and reticular depigmentation (hypopigmented to pink lines intersecting at acute angles, HPLA lines), which is a subtype of negative network.[25]

2. SCC: Features associated with SCC are discussed in Chapter 6d and consist of the following:

a. Adherent scale (rough texture) is present in almost all lesions.
b. Glomerular (coiled) vessels:
    a. Focally distributed towards the periphery.
    b. Diffusely present throughout lesion.
    c. Aligned linearly within lesion.
c. White circles.
d. Brown circles.
e. Rosettes (seen with polarized light).
f. Brown dots aligned in a linear fashion.

There are two lesions composed of atypical squamous cells that require special mention.

*2.1. **Keratoacanthoma.*** While some have questioned whether these are really SCC, most now agree that these lesions represent a form of a well-differentiated SCC with the potential to spontaneously involute. These lesions have a characteristic dome-shaped appearance with central scale/keratin. Dermoscopically, KAs often reveal white circles, shiny white blotches, and looped to twisted looped (hairpin) vessels with a whitish halo at the periphery.

*2.2. **Actinic keratosis (AK).*** AKs contain cells similar to those seen in SCC, but the cells tend not to encompass the entire thickness of the epidermis as they do in unequivocal SCC. AKs reveal a rough texture on palpation, and some consider these lesions to be early SCC but with the caveats that most do not progress to full-thickness atypia and many can spontaneously involute.

The dermoscopy features of **nonpigmented AK** include prominent white follicular openings with or without rosette and perifollicular erythema, creating the so-called strawberry pattern.[26] Some AKs may on

occasion display large areas with adherent scale-crust (hypertrophic AK), dotted or glomerular vessels. In such lesions, it is almost impossible to differentiate them from full-thickness SCC cancers.

Some AKs can collide with a lentigo, creating the so-called **pigmented AK**. These lesions can be difficult to differentiate from lentigo maligna (LM), but some clues are usually present to assist the clinician. First, AK will have a rough texture, and LM will have a smooth surface. Second, the follicular (adnexal/ostial) opening in AK will be large, whitish, and uniformly distributed, whereas in LM, the follicular openings will be of variable size, with asymmetric distribution of pigment (often with grayish hues), follicles surrounded by gray dots, and adnexal openings not uniformly distributed. Third, AKs will often have many rosettes, whereas LM will have few to no rosettes. Fourth, both pigmented AK and LM can reveal structures that look like angulated lines; however, unlike LM, the angulated lines in pigmented AKs are due to keratin and thus will have a brownish color and a rough texture. In LM, the angulated lines will not have a rough texture and often have grayish tones. In fact, anytime you see the color gray on a lesion on facial skin, you should consider the diagnosis of LM. The aforementioned clues can usually help differentiate a pigmented AK from LM, but at times it can be impossible, and a biopsy will be required. Also, it is important to remember that it is not uncommon to find collision lesions between pigmented AK and LM due to both being present in the same actinically damaged field.

3. Melanoma: The melanoma-specific structures are explained in Chapter 8 and consist of the following:

a) Atypical network.

b) Angulated lines.

c) Atypical streaks.

d) Negative network.

Caveat: There are two uniquely different structures that have been classified under the term *negative network*. The first consists of brown elongated to curvilinear globular structures that are located in a background that is lighter in color than the globular structures (this is the pattern in the schematic figure). This pattern is associated with melanomas arising in nevi, Spitz nevi, and some small globular congenital-type nevi seen in children. The second consists of hypopigmented to pink lines meeting at acute angles (reticular depigmentation). This pattern is seen in melanoma, Spitz, and Fibroepithelioma of Pinkus.

e) Shiny white lines. This structure should not be classified as a negative network since it is created by the presence of numerous shiny white lines oriented parallel and orthogonal to each other resulting in a pattern of box shaped polygons.

f) Atypical blotch/es including small hyperpigmented areas.

g) Atypical dots and globules.

h) Blue-white veil over palpable portion of the lesion.

i) Regression structures consisting of peppering/granularity and/or scarlike depigmentation. A few issues should be underscored regarding regression structures found in melanoma. First, granularity in melanoma usually encompasses more than 10% of the surface area of the lesion. Second, the scarlike depigmented area will be flat (nonpalpable) and be devoid of vessels and shiny white lines. Third, the presence of extensive regression can take on the appearance of a blue-white veil; however, in regression, this blue-whitish area will be nonpalpable.

j) Peripheral tan structureless areas.

k) Atypical vessels. Except for the vessels seen in IDN, any vessel seen in a melanocytic lesion should raise suspicion for melanoma. Contextual features including the morphology of other lesions on the patient's skin and the history of the lesion will be required to determine management.

Lastly, there are two other issues to underscore regarding step 2a. First, **some heavily pigmented nodular BCC may be difficult to differentiate from heavily pigmented nodular melanoma.** While there may be some subtle clues, such as the morphology of vessels and the pigment distribution, these clues cannot be relied upon to conclusively differentiate these two malignancies from each other. A biopsy should always be performed in such lesions before instituting definitive management. Second, there are some LPLK lesions that will also be difficult to differentiate from a melanoma, and a skin biopsy will be needed to confirm the diagnosis.

Step 2b: Organized lesions

Step 2b is reserved for lesions that are not unequivocally one of the benign lesions listed in step 1 and manifest an organized architectural morphology on dermoscopy. In such lesions, it is imperative not to miss a cutaneous malignancy displaying an organized pattern. This includes some rare tumors such as Merkel cell carcinoma and leiomyosarcoma, among others. It also includes certain subtypes of melanoma, which are discussed in Chapters 8b, 8e, and 8f and include nodular, nevoid, desmoplastic, spitzoid, amelanotic, epidermatropic metastasis, and featureless/structureless/feature-poor melanomas. A feature set consisting of any one of two patterns, two structures, or four colors has been identified; when any are present, this should prompt a biopsy. The patterns are starburst or negative network, the structures are vessels or ulceration, and the colors are blue-black, gray, or shiny white.[1, 27] Lesions at this stage of the algorithm that lack any of the features mentioned require monitoring to determine whether they are benign or malignant.[28–30] Other technologies such as confocal microscopy, electrical impedance spectroscopy, and gene expression profiling via tape-stripping of cells off the stratum corneum may assist us in managing these lesions.

The rules presented in the 2-step algorithm so far can be applied to any lesion on the skin. However, additional dermoscopic criteria exist for lesions located on special sites. These sites include the skin on the face (Chapter 11a) and the glabrous skin on the volar surfaces of the palms and soles (Chapters 8d and 11b), the nail unit (Chapter 11d), and mucosal surfaces, including the glabrous portion of the lips and genitalia (Chapter 11c). Lesions located on these special sites have separately different algorithms that need to be followed to assist in differentiating benign from malignant lesions. In essence, this would be step 3, reserved only for lesions on special sites.

References

1. Jaimes N, Marghoob AA. Triage amalgamated dermoscopic algorithm. *J Am Acad Dermatol*. 2020 Feb. doi:10.1016/j.jaad.2020.01.079.

2. Marghoob AA, Braun R. Proposal for a revised 2-step algorithm for the classification of lesions of the skin using dermoscopy. *Arch Dermatol.* 2010 Apr;146(4):426–8. doi:10.1001/archdermatol.2010.41. 146/4/426 [pii].
3. Rogers T, Marino M, Dusza SW, Bajaj S, Marchetti MA, Marghoob A. Triage amalgamated dermoscopic algorithm (TADA) for skin cancer screening. *Dermatol Pract Concept*. 2017 Apr;7(2):39–46. doi:10.5826/dpc.0702a09.
4. Jaimes N, Marghoob AA, Rabinovitz H, et al. Clinical and dermoscopic characteristics of melanomas on nonfacial chronically sun-damaged skin. *J Am Acad Dermatol.* 2015 Jun;72(6):1027–35. doi:10.1016/j.jaad.2015.02.1117.
5. Zalaudek I, Docimo G, Argenziano G. Using dermoscopic criteria and patient-related factors for the management of pigmented melanocytic nevi. *Arch Dermatol.* 2009 Jul;145(7):816–26. doi:10.1001/archdermatol.2009.115.
6. Zalaudek I, Schmid K, Marghoob AA, et al. Frequency of dermoscopic nevus subtypes by age and body site: a cross-sectional study. *Arch Dermatol.* 2011 Jun;147(6):663–70. doi:10.1001/archdermatol.2011.149. 147/6/663 [pii].
7. Zalaudek I, Grinschgl S, Argenziano G, et al. Age-related prevalence of dermoscopy patterns in acquired melanocytic naevi. *Br J Dermatol.* 2006 Feb;154(2):299–304. doi:10.1111/j.1365-2133.2005.06973.x.
8. Scope A, Marchetti MA, Marghoob AA, et al. The study of nevi in children: principles learned and implications for melanoma diagnosis. *J Am Acad Dermatol.* 2016 Oct;75(4):813–23. doi:10.1016/j.jaad.2016.03.027.
9. Scope A, Marghoob AA, Dusza SW, et al. Dermoscopic patterns of naevi in fifth grade children of the Framingham school system. *Br J Dermatol.* 2008 May;158(5):1041–9. doi:10.1111/j.1365-2133.2008.08510.x.
10. Reiter O, Chousakos E, Kurtansky N, et al. Association between the dermoscopic morphology of peripheral globules and melanocytic lesion diagnosis. *J Eur Acad Dermatol Venereol.* 2020 Nov. doi:10.1111/jdv.17035.
11. Bajaj S, Dusza SW, Marchetti MA, et al. Growth-curve modeling of nevi with a peripheral globular pattern. *JAMA Dermatol.* 2015 Dec;151(12):1338–45. doi:10.1001/jamadermatol.2015.2231.
12. Williams NM, Navarrete-Dechent C, Marchetti MA, De Bedout V, Jaimes N. Diagnostic utility of circumferential peripheral globules under dermoscopy in adults. *J Am Acad Dermatol.* 2020 Sep. doi:10.1016/j.jaad.2020.08.107.
13. Lallas A, Apalla Z, Ioannides D, et al. Update on dermoscopy of Spitz/Reed naevi and management guidelines by the International Dermoscopy Society. *Br J Dermatol.* 2017 Sep;177(3):645–55. doi:10.1111/bjd.15339.
14. Costa J, Ortiz-Ibañez K, Salerni G, et al. Dermoscopic patterns of melanoma metastases: interobserver consistency and accuracy for metastasis recognition. *Br J Dermatol.* 2013 Jul;169(1):91–9. doi:10.1111/bjd.12314.
15. Kittler H, Guitera P, Riedl E, et al. Identification of clinically featureless incipient melanoma using sequential dermoscopy imaging. *Arch Dermatol.* 2006 Sep;142(9):1113–9. doi: 10.1001/archderm.142.9.1113. 142/9/1113 [pii].
16. Argenziano G, Catricala C, Ardigo M, et al. Dermoscopy of patients with multiple nevi: improved management recommendations using a comparative diagnostic approach. *Arch Dermatol.* 2011 Jan;147(1):46–9. doi:10.1001/archdermatol.2010.389. 147/1/46 [pii].
17. Grazzini M, Marghoob AA. The "golden brown halo" of the Miescher nevus. *Arch Dermatol.* 2012 Jul;148(7):870. doi:10.1001/archdermatol.2011.2304. 1216921 [pii].
18. Greco V, Cappello M, Megna M, et al. Dermoscopic patterns of intradermal naevi. *Australas J Dermatol.* 2020 Nov;61(4):337–41. doi:10.1111/ajd.13366.
19. Niederkorn A, Ahlgrimm-Siess V, Fink-Puches R, et al. Frequency, clinical and dermoscopic features of benign papillomatous melanocytic naevi (Unna type). *Br J Dermatol.* 2009 Sep;161(3):510–4. doi:10.1111/j.1365-2133.2009.09239.x. BJD9 239 [pii]
20. Chen LL, Dusza SW, Jaimes N, Marghoob AA. Performance of the first step of the 2-step dermoscopy algorithm. *JAMA Dermatol.* 2015 Jul;151(7):715–21. doi:10.1001/jamadermatol.2014.4642.
21. Williams NM, Navarrete-Dechent C, Marghoob AA, Abarzua-Araya Á, Salerni G, Jaimes N. Differentiating basal cell carcinoma from intradermal nevi along the eyelid margin with dermoscopy: a case series. *J Am Acad Dermatol.* 2021 Jan;84(1):173–5. doi:10.1016/j.jaad.2020.04.059.
22. Braun RP, Krischer J, Saurat JH. The "wobble sign" in epiluminescence microscopy as a novel clue to the differential diagnosis of pigmented skin lesions. *Arch Dermatol.* 2000 Jul;136(7):940–2. doi:10.1001/archderm.136.7.940-a.
23. Carrera C, Segura S, Aguilera P, et al. Dermoscopic clues for diagnosing melanomas that resemble seborrheic keratosis. *JAMA Dermatol.* 201706;153(6):544–51. doi:10.1001/jamadermatol.2017.0129.
24. Zaballos P, Del Pozo LJ, Argenziano G, et al. Dermoscopy of lymphangioma circumscriptum: a morphological study of 45 cases. *Australas J Dermatol.* 2018 Aug;59(3):e189–93. doi:10.1111/ajd.12668.
25. Nanda JK, Marghoob N, Forero Cuevas DM, et al. Clinical and dermoscopic features of Fibroepithelioma of Pinkus: case series with an emphasis on hypopigmented to pink lines intersecting at acute angles. *Arch Dermatol Res.* 2020 Sep. doi:10.1007/s00403-020-02142-6.
26. Zalaudek I, Giacomel J, Argenziano G, et al. Dermoscopy of facial nonpigmented actinic keratosis. *Br J Dermatol.* 2006 Nov;155(5):951–6. doi:10.1111/j.1365-2133.2006.07426.x.
27. Rogers T, Marino ML, Dusza SW, et al. A clinical aid for detecting skin cancer: the triage amalgamated dermoscopic algorithm (TADA). *J Am Board Fam Med*. 2016 11;29(6):694–701. doi:10.3122/jabfm.2016.06.160079.
28. Menzies SW, Gutenev A, Avramidis M, Batrac A, McCarthy WH. Short-term digital surface microscopic monitoring of atypical or changing melanocytic lesions. *Arch Dermatol.* 2001 Dec;137(12):1583–9. doi:dst10171 [pii].
29. Adler NR, Kelly JW, Guitera P, et al. Methods of melanoma detection and of skin monitoring for individuals at high risk of melanoma: new Australian clinical practice. *Med J Aust.* 2019 Jan;210(1):41–7. doi:10.5694/mja2.12033.
30. Altamura D, Avramidis M, Menzies SW. Assessment of the optimal interval for and sensitivity of short-term sequential digital dermoscopy monitoring for the diagnosis of melanoma. *Arch Dermatol.* 2008 Apr;144(4):502–6. doi:10.1001/archderm.144.4.502. 144/4/502 [pii].

4C PRIMARY DIAGNOSTIC ALGORITHMS: A DECISION ALGORITHM FOR NONPIGMENTED SKIN LESIONS

Cliff Rosendahl and Aksana Marozava

Contents

Prediction without Pigment: A decision algorithm for nonpigmented skin lesions 61
Applying Prediction without Pigment in routine practice: Red flags and Prediction without Pigment 61
Red flags 61
Prediction without Pigment: The algorithm 62
Step 1: Is there ulceration? 62
Step 2: White clues 62
Step 3: Is the vessel pattern consistent with malignancy? 64
Conclusion 69
References 69

Prediction without Pigment: A decision algorithm for nonpigmented skin lesions

For the purpose of this algorithm, nonpigmented lesions are defined as lesions without clinical or dermatoscopic evidence of pigmentation due to ***melanin***. Therefore, brown or gray color must be absent. If black, purple, or blue colors are present, they must be due to blood rather than melanin, which is usually the case if they are associated with red color only [1].

Although the dermatoscopic evaluation is more challenging when pigmented structures are absent, the understanding of certain clues, in addition to vessels in nonpigmented skin lesions, allowed the development of the Prediction without Pigment algorithm, a method analogous to Chaos and Clues, which is used for the evaluation of pigmented lesions [2].

In contrast to the revised pattern analysis, which leads to a *provisional diagnosis* in a logical stepwise process [3], the methods Chaos and Clues for pigmented lesions and Prediction without Pigment for nonpigmented lesions are algorithmic methods that use pattern analysis to guide the clinician in a stepwise process to the *decision* as to whether or not a skin biopsy is indicated [1] (Figure 4c.1).

Applying Prediction without Pigment in routine practice: Red flags and Prediction without Pigment

Similarly to the Chaos and Clues algorithm (Chapter 5a), the Prediction without Pigment algorithm includes the same five groups of common benign lesions with the addition of cysts, namely: nonpigmented varieties of nevus; benign keratinocytic lesions (including viral warts and actinic keratoses); hemangioma; dermatofibroma; sebaceous gland hyperplasia; and cyst. These benign lesions should be identified by pattern recognition based on their characteristic morphology. As is the case for their pigmented counterparts, these lesions are ubiquitous, and the clinician can become an expert at their recognition by deliberately looking at thousands of them. On the other hand, malignant lesions such as basal cell carcinoma (BCC) may also be identified by pattern recognition, and this is expected to happen more frequently with increasing experience. However, expertise in pattern recognition can be achieved much earlier with benign lesions because the dermatoscopist will have the opportunity to examine many of them in a short time.

Just as pigmented lesions are selected in routine practice for dermatoscopic analysis by recognizing "red flags," the same principle is applicable to nonpigmented lesions.

In cases where clinical or dermatoscopic pattern recognition is not possible, or where additional concerns are present (see "Red flags" later), we recommend initial evaluation using the Prediction without Pigment decision algorithm.

Red flags

Red flags represent additional ***features that classify a lesion as suspicious and warrant formal algorithmic assessment.*** These features may be of concern or known by the patient; they may be clinically obvious (i.e., clinical pattern-breaker, ulceration, surface keratin on a raised lesion) or recognized during the dermatoscopic evaluation (e.g., shiny white lines using polarized light).

1. **Patient concern or clinical evidence of change**

   Lesions that are of concern to the patient should never be dismissed without a close examination, including dermatoscopy [3]**.** Patient concern should automatically **flag a lesion as suspicious** and lead to a dermatoscopic assessment. Similarly, documented evidence of change at mature age **flags a lesion as suspicious** and therefore requiring focused dermatoscopic assessment. In particular, any elevated, firm, and continuously growing (EFG) lesion should be subjected to excision biopsy [4].

2. **Clinical pattern-breaker**

   The disorganized and uncontrolled behavior of pigmented malignant neoplasms causes dermatoscopic chaos and also often causes nonpigmented malignant lesions to break the pattern of the surrounding skin lesions. Malignant neoplasms can have an irregular unexpected shape or larger size as compared with the surrounding lesions due to their unrestrained growth. Any lesion that clinically breaks the pattern should be **flagged as suspicious** and be analyzed with dermatoscopy [1].

DOI: 10.1201/9780429487873-6

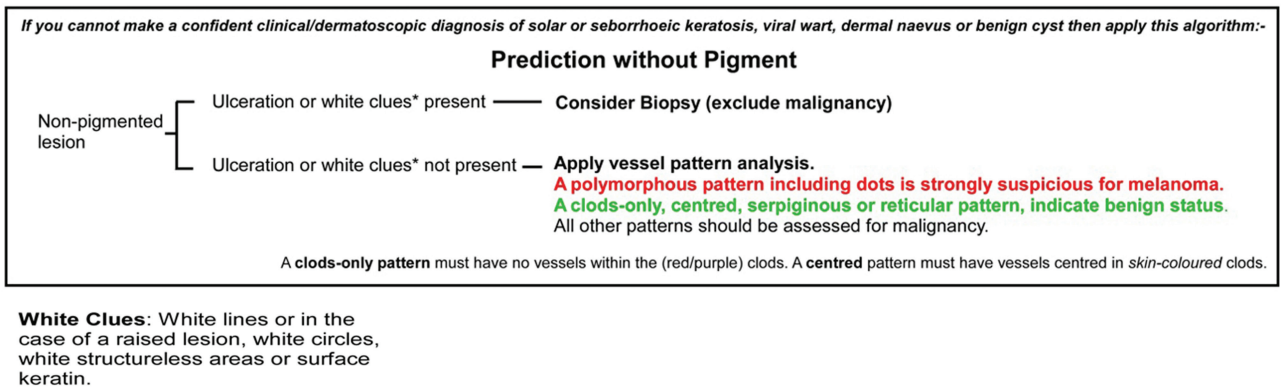

FIGURE 4C.1 Flowchart for the Prediction without Pigment decision algorithm.

Prediction without Pigment: The algorithm

Structures pigmented by melanin provide valuable patterns and clues for the assessment of pigmented lesions, and when such structures are present, even focally, the lesion is generally best assessed as a pigmented lesion. As mentioned earlier, when such structures are absent, the assessment is more challenging, and because of this, it is useful to use all available information, both clinical and dermatoscopic, when assessing such lesions.

Ulceration is commonly present in BCC and often best assessed clinically. Therefore, it is given first priority in the decision algorithm Prediction without Pigment [1].

W**hite lines** seen with either polarized or nonpolarized dermatoscopy, a clue to malignancy in the assessment of pigmented lesions, is also a useful clue in the nonpigmented variants of those same lesions, and for this reason, it has been given priority after the assessment of ulceration [1].

A study has shown that with respect to the assessment of raised nonpigmented lesions, the keratin clues of **surface keratin, white structureless areas, and white circles** are more robust than vessel clues [5], and therefore, these clues are given priority over vessel clues. Because one of the purposes of dermatoscopy is to render keratin invisible, surface keratin is often best displayed clinically, but in raised lesions, it is generally also seen dermatoscopically. The clues of white structureless areas and white circles are dermatoscopic clues. The Prediction without Pigment algorithm, displayed in Figure 4c.1, is a decision algorithm, although revised pattern analysis can be applied to carry the process further to attempt to predict the specific diagnosis.

Step 1: Is there ulceration?

Because BCC is the most common nonpigmented skin malignancy, and ulceration is frequently present on its surface, this is the first step in the Prediction without Pigment algorithm. Considering that the dermatoscope is generally applied to nonpigmented lesions of concern, ulceration caused by significant trauma should not be a confounding factor. Furthermore, if ulceration of a lesion of concern is observed with the naked eye, that only increases the appropriateness of dermatoscopic examination, because if the lesion is malignant, additional dermatoscopic clues can be expected to add weight to the suspicion of malignancy as well as providing evidence for the precise diagnosis. Of course, dermatoscopy may actually make ulceration more difficult to appreciate because the application of immersion fluid or even the use of polarized light with noncontact dermatoscopy may render the optical features of ulceration invisible. There is, however, a dermatoscopic clue to ulceration, which may be observed even in cases of micro-ulceration, which is not apparent clinically, and that is the presence of adherent fiber (see Figure 4c.2) [1, 3]. Ulceration results in a serum exudate, which may trap clothing fiber or other environmental or intrinsic matter, including hair, and the observation of such material may be a clue to occult ulceration, which might not have been otherwise apparent.

Ulceration can have secondary effects, including the promotion of neoangiogenesis and in some cases, keratinization; therefore, different vessel morphologies, including a polymorphous vessel pattern (Figure 4c.3), as well as surface keratin or white circles (Figure 4c.4), which are normally expected in squamous cell carcinoma (SCC) but not in BCC, may be evident.

Step 2: White clues

"White clues" are defined as:

1. White lines in *any* nonpigmented lesion
2. Keratin clues of surface keratin (clinical or dermatoscopic), white structureless areas (dermatoscopic), or white circles (dermatoscopic) in any *raised* nonpigmented lesion

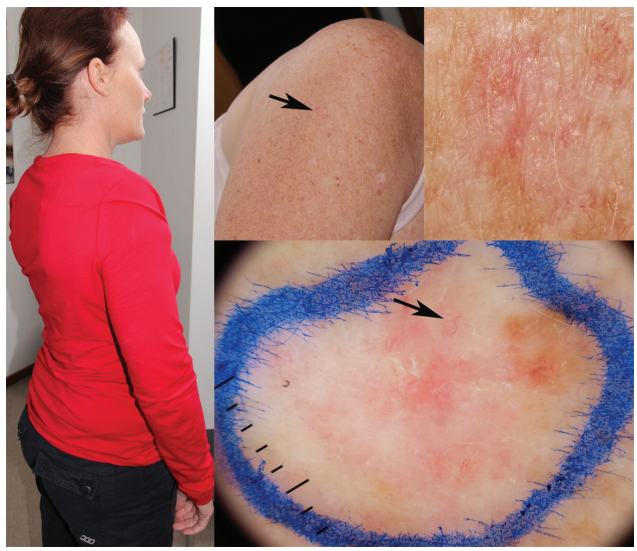

FIGURE 4C.2 Adherent fiber as a clue to micro-ulceration of a BCC.

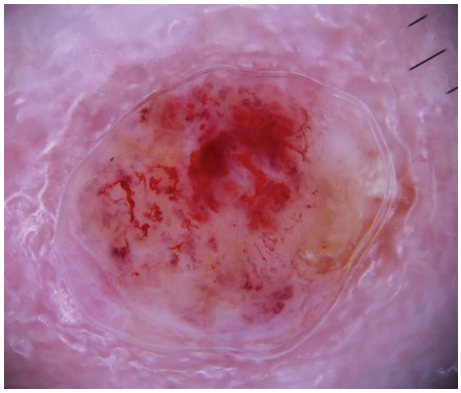

FIGURE 4C.3 Polymorphous vessels including dots, clods, linear straight, linear curved, linear looped, and linear serpentine vessels in an ulcerated BCC.

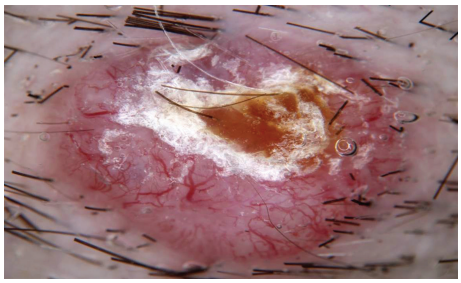

FIGURE 4C.4 Secondary keratinization in an ulcerated BCC.

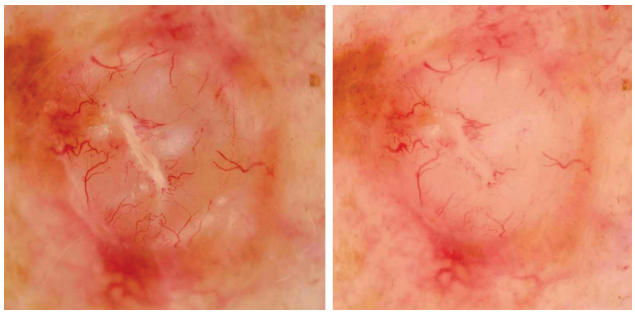

FIGURE 4C.5 Polarizing-specific white lines; straight, whiter than surrounding skin, and perpendicularly orientated, only seen with polarized (a) and not with nonpolarized dermatoscopy (b). A monomorphous pattern of branched serpentine vessels as well as the characteristic translucent stroma, which casts the vessels into sharp focus, is supporting evidence that this is a BCC.

As for pigmented lesions, the clue of white lines may be seen with nonpolarized and/or polarized dermatoscopy, and to be classified as white lines, they must be at least as white as the perilesional skin.

Polarizing-specific white lines, straight, orientated perpendicularly to each other, not crossing, and frequently shifting as the dermatoscope is rotated, are the white lines most frequently seen in nonpigmented lesions, being a valuable clue particularly to BCC (Figure 4c.5). They can also be seen (uncommonly) in SCC in situ and lichen planus–like keratosis (LPLK), and correlation with vessel morphology may be necessary when

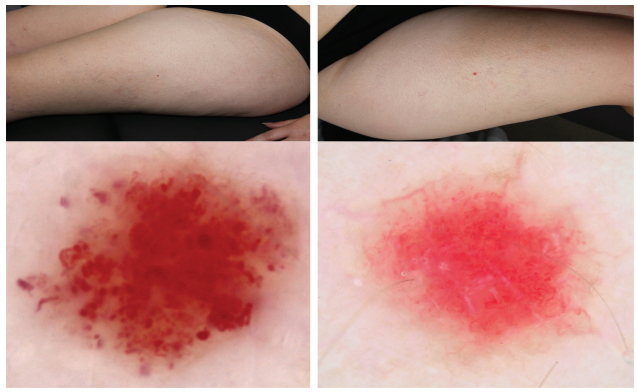

FIGURE 4C.6 Two lesions on the same 30-year-old woman. On the left thigh (a) is a lesion with the pattern recognition features of a hemangioma (clods-only pattern with few linear variants, as commonly seen with very small hemangiomas). The lesion on the right thigh (b) does not have the pattern recognition morphology of any of the six common benign groups so is analyzed carefully. Polarizing-specific white lines are clearly visible and take priority over vessels (there are none of the four benign vessel patterns anyway), leading to excision biopsy. Histopathologic findings revealed an amelanotic melanoma, Breslow thickness 0.8 mm.

attempting to predict a specific diagnosis. Differentiation from the other benign lesions where this clue may be seen, dermatofibroma (DF) and Spitz nevus, is less often a concern when pigment is absent, and of course, apart from DF, the distinction is not critical, because Spitz nevi should be excised regardless of the age of the patient due to the fact that differentiation from Spitzoid melanoma cannot be made with confidence without histological confirmation—and even that may be equivocal. Similarly, polarizing-specific white lines may be seen in amelanotic melanoma (Figure 4c.6), where vessel clues can often, but not always, be used to distinguish BCC from melanoma, a polymorphous pattern including patterns of dotted vessels being a frequent feature of melanoma but not of BCC.

The keratin clues of surface keratin, white structureless areas, and white circles are only applicable to *raised* nonpigmented lesions. A raised lesion is defined as a lesion that is visibly or palpably raised, *other than due to surface keratin*, or a lesion that has the *dermatoscopic clue to a raised lesion of looped vessels* (Figures 4c.7 and 4c.8).

Actinic keratoses may have surface keratin and/or white circles, but such lesions, not being raised and therefore not being predicted to harbor invasive malignancy, may be suitable for nonsurgical treatment without biopsy. Similarly, the keratin clue of a white structureless area is not expected in a flat keratinizing lesion, as white structureless areas in SCC/keratoacanthoma (KA) correspond to significant acanthosis of highly keratinized squamous cells, and if this is present, the lesion will not be flat.

While the presence of any of the three keratin clues in a raised nonpigmented lesion should lead to consideration of biopsy on suspicion of SCC/KA (see Figures 4c.9,4c.10,4c.11), the clue of white circles is regarded as the most useful clue, being 87% specific for SCC/KA in a consecutive test series examined, while 44% of SCC/KA in that series displayed dermatoscopic white circles (Figures 4c.10, 4c.11) [5]. In the experience of the



FIGURE 4C.7 Schematic of blood vessels within the dermal papilla (a) and the different dermatoscopic morphologies (b). On the right side of the diagram, a vessel within the dermal papilla, coming from below, which ascends to the top and curves across before descending, will appear a curved vessel. If it is convoluted, it will appear as a coiled vessel, and if it turns on itself sharply, it will appear as a dot. Once a lesion becomes raised, the dermal papilla distorts laterally, so whatever the dermatoscopic appearance was will now project as a looped vessel.

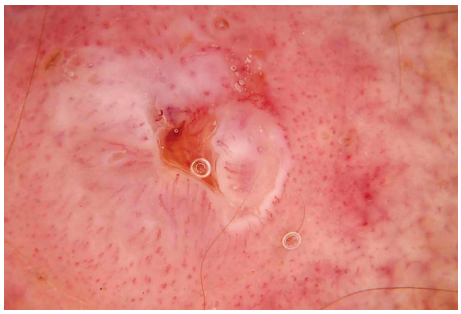

FIGURE 4C.8 A pattern of coiled vessels at the periphery of the lesion, is consistent with SCC in situ. In the center, the SCC has become invasive, and the dermal papillae vessels, being displaced sideways, appear as looped vessels. It can also be noticed that white structureless areas due to highly keratinized aggregated tumor tissue are evident centrally in association with the looped vessels.

authors, dermatoscopic white circles have frequently enabled the confident prediction of the diagnosis of very small SCC where such a diagnosis would not have been possible for such small lesions prior to that clue being described (Figure 4c.12).

Step 3: Is the vessel pattern consistent with malignancy?

It is only when the nonpigmented lesion of concern has neither ulceration nor white clues that analysis of vessel patterns is necessary. In fact, if either of those priority clues is present, then as a general rule, vessels should be considered as additional clues to a specific diagnosis rather than being relied on to avoid a biopsy. However, if a nonpigmented lesion is not

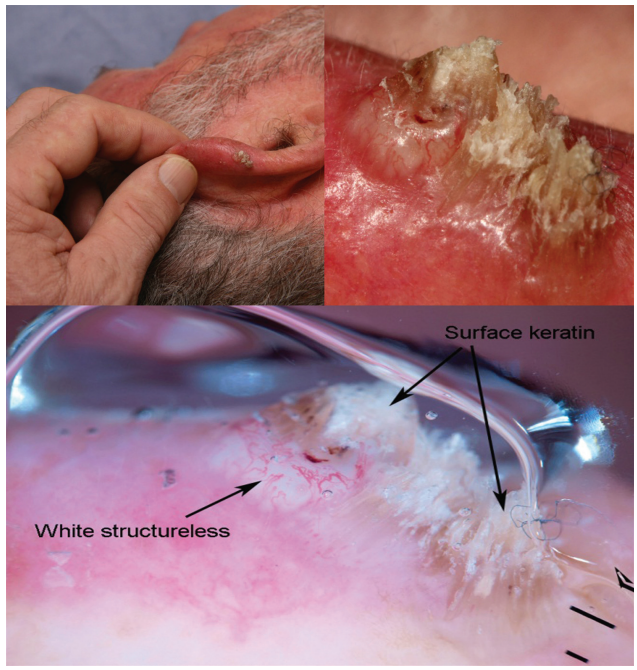

FIGURE 4C.9 Surface keratin and a white structureless area as clues to malignancy on a raised nonpigmented SCC.

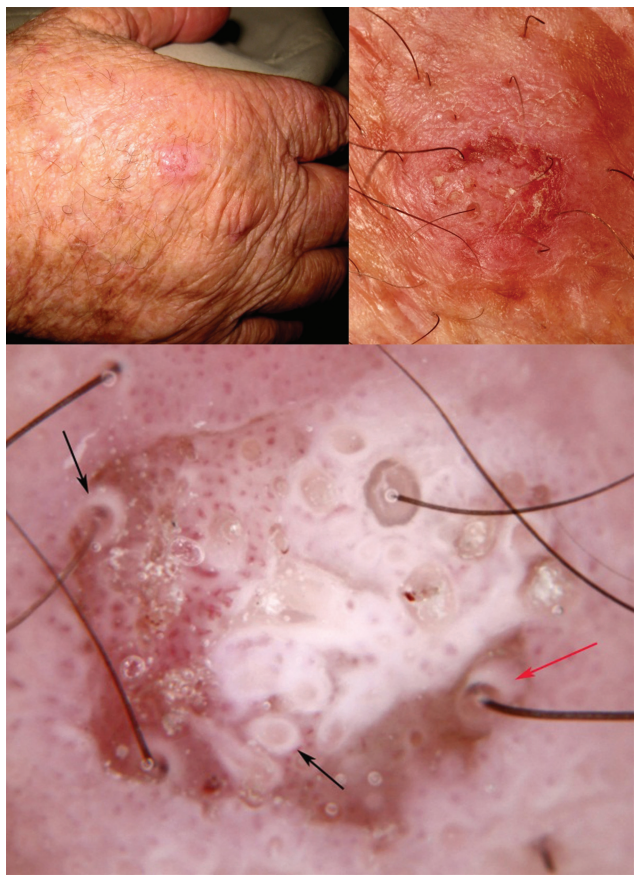

FIGURE 4C.10 Dermatoscopic white circles on a raised nonpigmented SCC on the hand of a 75-year-old man. An arrow points to an obliquely orientated structure with a white cylinder surrounding a hair shaft, illustrating the white circle correlation of SCC invading a hair follicle.



FIGURE 4C.11 A dermatoscopic pattern of white circles in a SCC on the scalp of a 48-year-old man.

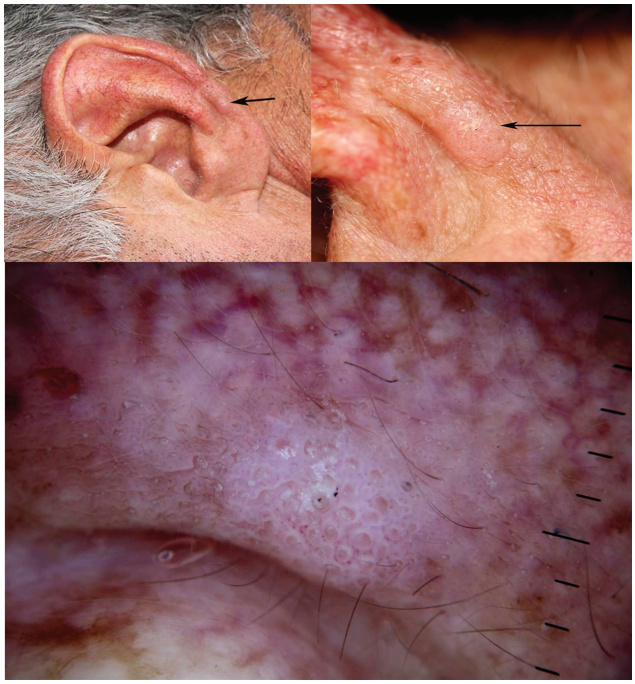

FIGURE 4C.12 A small nodule on the helix of the ear is confidently diagnosed as a SCC due to the compelling dermatoscopic clue of white circles.

ulcerated and has no white lines, nor in the case of a raised lesion any keratin clues, vessel pattern analysis is the only remaining assessment possible.

Revised pattern analysis precisely defines eight types of vessel structures (Figure 4c.13) and eight vessel arrangements (Figure 4c.14) [1]. The eight types of vessel structures include dots, clods, linear straight, linear looped, linear curved, linear serpentine, linear helical, and linear coiled. (Figure 13)

Vessel types are defined as follows:

Dot: A vessel structure, red in color, too small to have a discernible shape (at 10× magnification)

Clod: A well-circumscribed solid vessel structure, red or purple in color, larger than a dot, any shape

Linear: A vessel structure with length usually greatly exceeding width

Linear vessels may be:

a) Linear straight: Linear vessels without a bend

b) Linear looped: Linear vessels with one sharp bend (180 degrees) resulting in a reversal of direction (U-turn)

c) Linear curved: Linear vessels with one gentle bend

d) Linear serpentine: Linear vessels with more than one bend and shaped in a snakelike fashion

e) Linear helical: Linear vessels with multiple bends twisted along a central axis

f) Linear coiled: Linear vessels with multiple bends and convoluted compactly

The eight types of vessel arrangement are: random, clustered, serpiginous, linear, centered, radial, reticular, and branched. (Figure 14)

Multiple vessels of one type may form a pattern, and that pattern may be monomorphic if one vessel type predominates, or polymorphic either if *more than one vessel type is present in significant numbers within a pattern* or alternatively, if there are *separate patterns of more than one vessel type*. If there is, for example, a pattern of linear serpentine vessels with a couple of dot vessels, that is not a polymorphous pattern. There would need to be enough dotted vessels either to clearly interfere with the pattern of serpentine vessels or alternatively, to form a separate cluster making a pattern of their own.

Vessel *arrangements* that form patterns are defined as follows:

a) Random: Vessels not arranged in any of the following specific ways (b–h)

b) Clustered: Vessels that are concentrated in certain areas of a lesion

c) Serpiginous: Dotted or coiled vessels arranged in a linear snakelike pattern (this is different from the linear serpentine vessel *type*)

d) Linear: Dotted or coiled vessels arranged in straight lines

e) Centered: Vessels located at the center in *skin-colored* clods

f) Radial: Linear vessels in a group orientated from the periphery towards the center of a lesion but not crossing it

g) Reticular: Linear vessels crossing at right angles to form a net-like pattern

h) Branched: Linear serpentine vessels that divide into consecutively thinner serpentine vessels from a central main stem

In Prediction without Pigment, vessel analysis should proceed in the following manner:

There are four monomorphous vessel patterns that are consistent with a benign diagnosis when seen in a non-pigmented skin lesion.

***A pattern of (red, purple, and/or blue) clods*-only** is consistent with the diagnosis of hemangioma in an

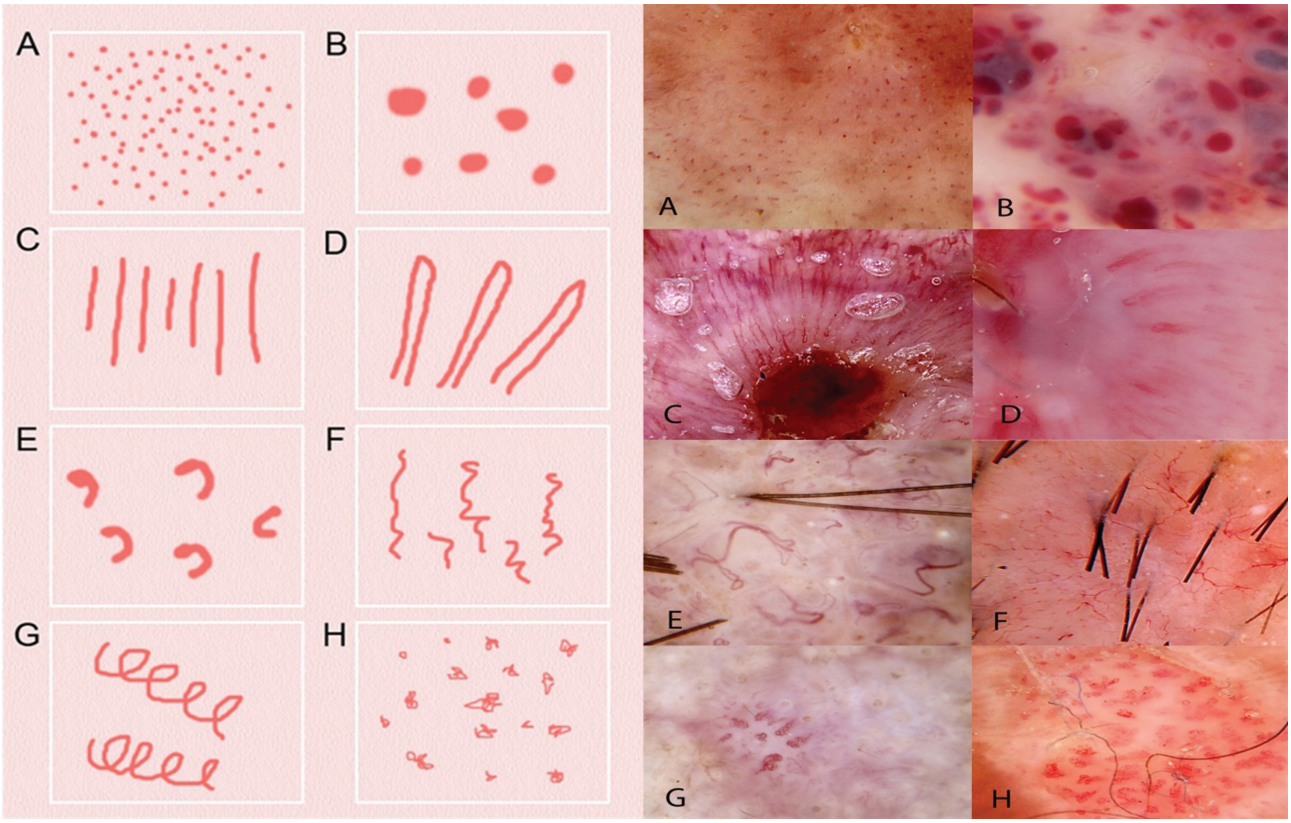

FIGURE 4C.13 Vessel structures: (a) Dots, (b) clods, (c) linear straight, (d) linear looped, (e) linear curved, (f) linear serpentine, (g) linear helical, and (h) linear coiled.

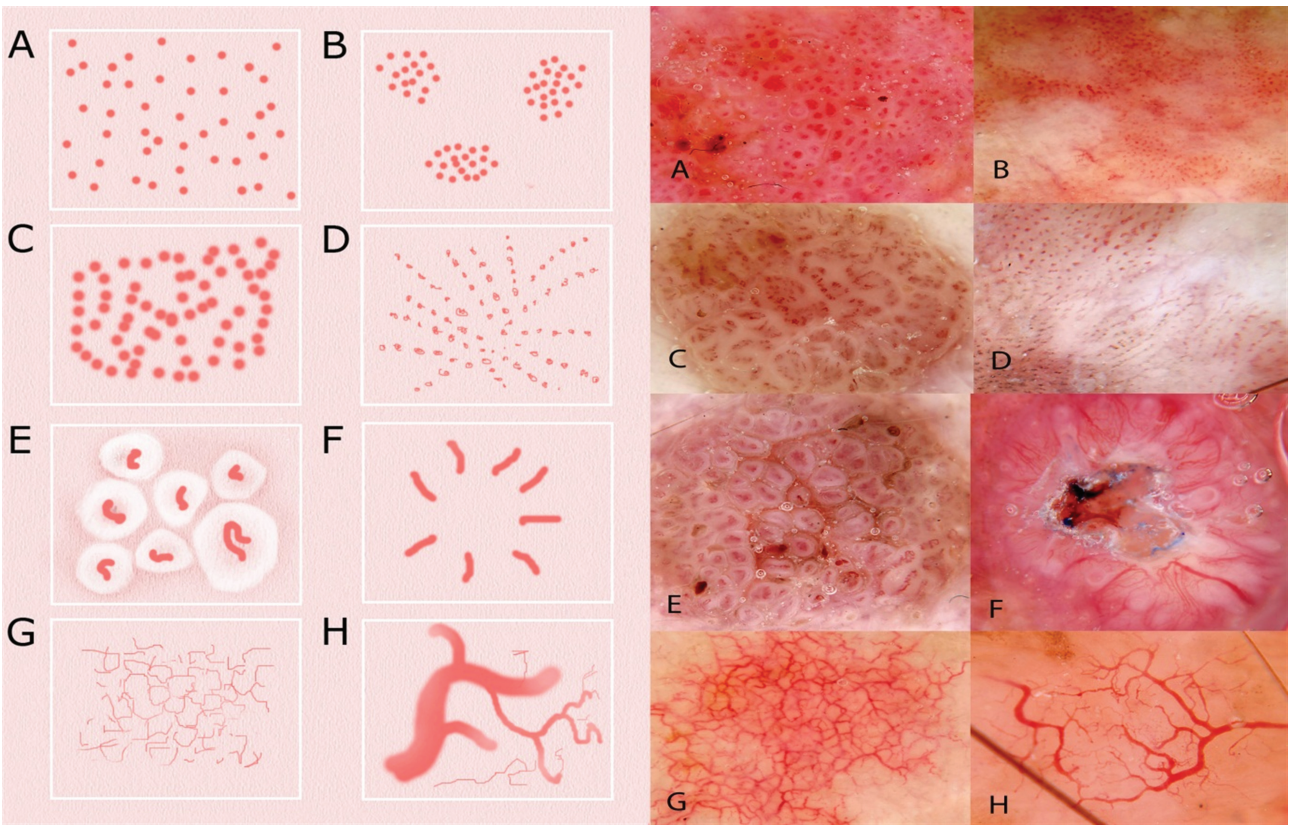

FIGURE 4C.14 Vessel arrangements: (a) random, (b) clustered, (c) serpiginous, (d) linear, (e) centered, (f) radial, (g) reticular, and (h) branched.

apparently stable lesion (Figure 4c.15). Normally, hemangiomas are diagnosed with confidence clinically, and the dermatoscopist is encouraged to look at thousands of such lesions to become familiar with their distinctive but protean morphology. While it has been regarded as a rule that a clods-only pattern excludes lesions with any linear vessels, it is not at all uncommon to see hemangioma with linear vessels as well as clods (Figure 4c.6 lower left image). This is almost universal with very small embryonic hemangiomas. Clinical correlation is required in the evaluation of such lesions. If there is some additional cause for concern, such as reported recent change, then biopsy may be indicated regardless of dermatoscopic findings, and in such a situation, the presence of any linear vessels would increase the index of suspicion. Certainly, any apparent hemangioma with any vessels seen *within* the red or purple clods should be excised.

A pattern of centered vessels only is consistent with a benign diagnosis of verruca, congenital nevus, or seborrheic keratosis in an apparently stable lesion (Figure 4c.16). A centered vessel pattern is defined as the presence of vessels (any type) centered in *skin-colored clods* and cannot be applied if the clods are dark pink or red, as such a background color can be seen in some nodular melanomas with vessels centered in pink clods. Note that the presence of any white lines, also seen in some nodular melanomas, takes priority over vessel analysis and should lead to excision even if there is a monomorphous pattern of centered vessels. A background pink color can be falsely rendered as skin-colored if undue pressure is exerted on the dermatoscope foot-plate. In such a situation, observation of pink color on clinical examination should override observation of skin-color on dermatoscopy, and the diagnosis of a centered pattern should not be made.

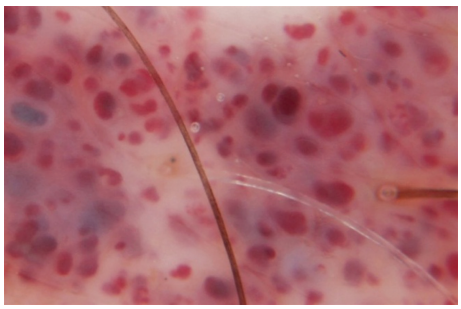

FIGURE 4C.15 A clods-only pattern in a hemangioma.

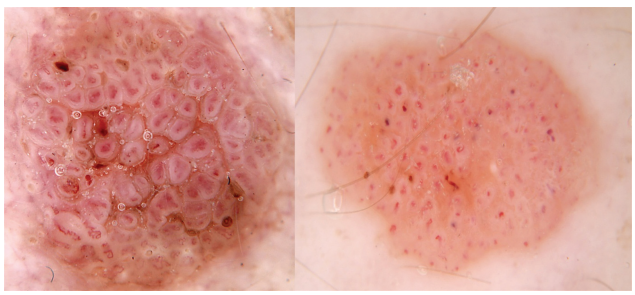

FIGURE 4C.16 A centered vascular pattern in two examples of seborrheic keratosis.



FIGURE 4C.17 A serpiginous vascular pattern in a clear cell acanthoma.

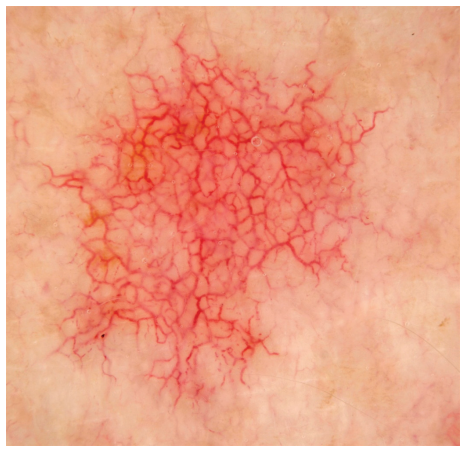

FIGURE 4C.18 A reticular vessel pattern on sun-damaged skin (not excised). What is seen here are the vessels of the superficial horizontal vascular plexus made visible by solar-induced atrophy of the overlying dermis.

A pattern of serpiginous vessels only is consistent with the diagnosis of clear cell acanthoma with no differential diagnosis (Figure 4c.17).

A pattern of reticular vessels only predictably corresponds to a benign diagnosis, with this pattern commonly seen in isolated patches on sun-damaged skin (Figure 4c.18) as well as in the form of mastocytosis known as telangiectasia macularis perstans.

All other vessel patterns in lesions of concern should be assessed for biopsy (Figures 4c.19,4c.20,4c.21,4c.22).

While any polymorphous pattern of vessels can be a clue to malignancy, it should be remembered that benign lesions such as seborrheic keratoses and most dermal nevi can also have polymorphous (linear) vessels. The dermatoscopist is encouraged to look at thousands of obviously benign examples of these lesions to become familiar with their distinctive but protean vessel morphology.

Any polymorphous vessel pattern that includes a pattern of dots in addition to any pattern of linear vessels

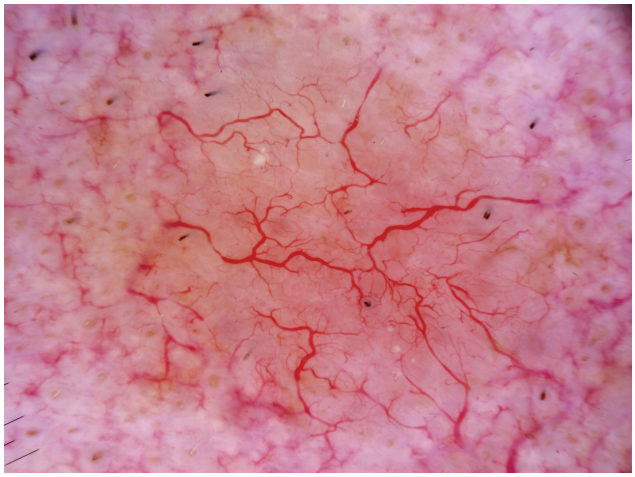

FIGURE 4C.19 This nonpigmented lesion on the cheek of a 62-year-old man shows no evidence of ulceration or white clues (white clods/dots are not regarded as white clues in Prediction without Pigment because they are commonly encountered in benign lesions, and additionally, this lesion is not raised). None of the four benign vessel patterns are present, and in the context of a discrete lesion, a pattern of branched serpentine vessels, thrown into sharp relief by translucent stroma, is most consistent with a diagnosis of BCC. Note that the serpentine-branched vessels are not unique to the lesion, blending seamlessly with the perilesional superficial dermal vascular plexus. What is unique to the lesion is the translucent stroma, which casts the vessels in sharp relief.

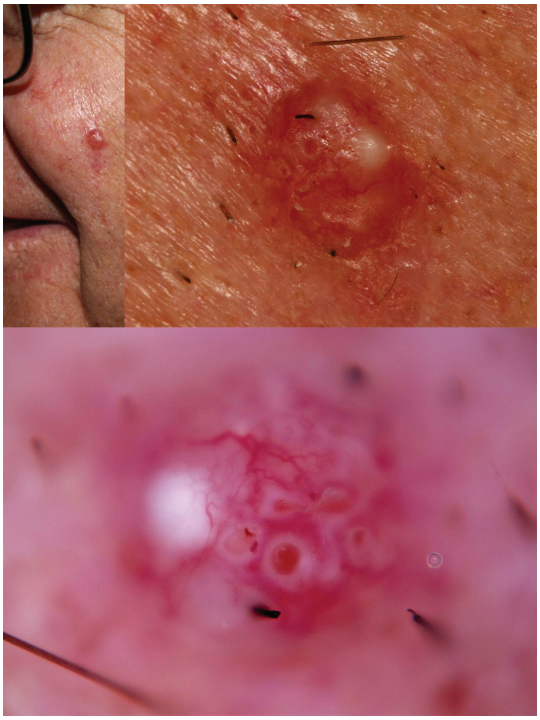

FIGURE 4C.20 A nodular lesion on the cheek of a 68-year-old man has serpentine-branched vessels, which might be considered consistent with a diagnosis of BCC. Applying Prediction without Pigment, there is neither ulceration nor white lines, but there are white circles and a white structureless area. These clues have priority over vessel clues, leading to the correct diagnosis of SCC.

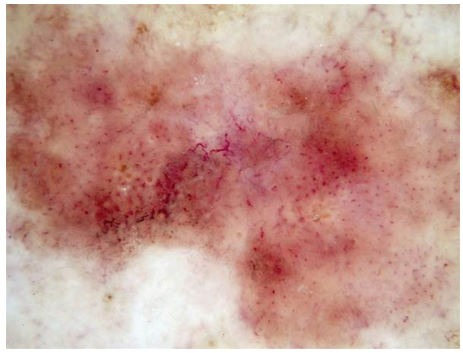

FIGURE 4C.21 Dermatoscopic image of a hypopigmented melanoma with a polymorphous vascular pattern including a vast pattern of dot vessels.

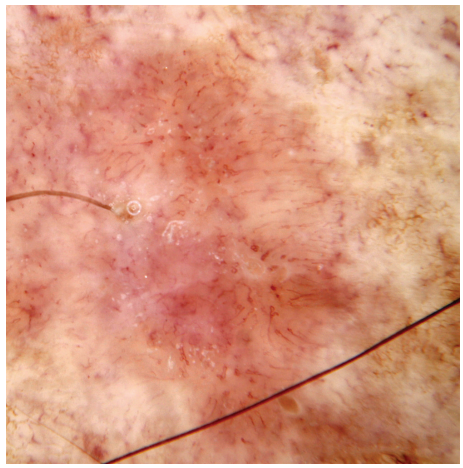

FIGURE 4C.22 A nonpigmented lesion treated by curettage and cautery on suspicion of BCC. Fortunately, because the diagnosis of BCC was not made with absolute certainty, a shave biopsy 1 mm thick was performed first, and histological diagnosis of invasive melanoma Breslow 0.3 mm was made [1]. In retrospect, as well as a pattern of linear serpentine vessels, there is a cluster of dot vessels at the upper extremity of the image.

raises suspicion for melanoma (Figures 21 and 22). This assumes again that the lesion is not an unequivocal seborrheic keratosis or dermal nevus, because scattered linear and dot vessels are not uncommon in such lesions. It is assumed that vessel analysis is being applied to a discrete lesion that does not have compelling criteria of any common benign entity. Also, a few dotted vessels in a lesion with predominantly linear vessels does not constitute a pattern of dotted vessels. The pattern of dotted vessels in a melanoma will usually, but not always, appear as a separate pattern of vessels rather than speckled in between linear vessels. Dotted vessels are only expected in the macular part of a melanoma because they actually represent prominent dermal papillae vessels projecting vertically from the superficial vascular plexus towards the epidermis; once a melanoma becomes invasive, the normal organized morphology of the dermal papillae becomes distorted with lateral displacement, meaning that dermal papillae vessels will project as linear vessels of various types. Linear vessels, either laterally

displaced dermal papillae vessels, dilated dermal plexus vessels (usually serpentine), or polymorphic linear vessels (looped, curved, serpentine, helical, or coiled), can be seen in both macular and raised portions of a melanoma. A melanoma may also have a polymorphous pattern of linear vessels without a pattern of dots, in which case the different vessel types are likely to be combined in a random arrangement.

Conclusion

As with Chaos and Clues, Prediction without Pigment should not be regarded as an ultimate method, set in stone. It has also been designed as a useful tool, and it is suitable for seamless integration into routine practice. We encourage our colleagues to use it as a framework on which to organize their accumulated experience and to adapt and individualize the method for their own style and practice.

References

1. Rosendahl C, Cameron A, Tschandl P, Bulinska A, Zalaudek I, Kittler H. Prediction without Pigment: a decision algorithm for non-pigmented skin malignancy. *Dermatol Pract Concept*. 2014;4(1):9. doi:10.5826/dpc.0401a09
2. Rosendahl C, Cameron A, McColl I, Wilkinson D. Dermatoscopy in routine practice: "Chaos and Clues". *Aust Fam Physician*. 2012 Jul;41(7):482–7.
3. Kittler H, Rosendahl C, Cameron A, Tschandl P. *Dermatoscopy*. 2nd ed. Austria: Facultas; 2016.
4. Chamberlain AJ, Fritschi L, Kelly JW. Nodular melanoma: patients' perceptions of presenting features and implications for earlier detection. *J Am Acad Dermatol*. 2003;48:694–701.
5. Rosendahl C, Cameron A, Argenziano G, Zalaudek I, Tschandl P, Kittler H. Dermoscopy of squamous cell carcinoma and keratoacanthoma. *Arch Dermatol*. 2012 Sep 17:1–7.

5A TRIAGE ALGORITHMS: A DECISION ALGORITHM FOR PIGMENTED LESIONS BASED ON REVISED PATTERN ANALYSIS ("CHAOS AND CLUES")

Cliff Rosendahl and Aksana Marozava

Contents

A decision algorithm for pigmented lesions based on revised pattern analysis . . . 70
Applying Chaos and Clues in routine practice: Red flags, Chaos and Clues . . . 70
What chaos really means . . . 70
Red flags . . . 70
Chaos and Clues: A dermatoscopic decision algorithm . . . 72
Chaos . . . 72
Clues . . . 73
Exceptions . . . 78
Conclusion . . . 80
References . . . 80

A decision algorithm for pigmented lesions based on revised pattern analysis

Revised pattern analysis is designed to lead to a *provisional diagnosis* in a logical stepwise process [1]. Chaos and Clues is an algorithmic method that uses pattern analysis to guide the clinician in a stepwise process to the *decision* about whether (excision) biopsy is indicated [2].

Applying Chaos and Clues in routine practice: Red flags, Chaos and Clues

Before considering the dermatoscopic decision algorithm Chaos and Clues, it is relevant to consider what is done in the daily routine of ***clinical*** practice.

Although the clinician is ideally encouraged to apply the dermatoscope to all lesions, a detailed algorithmic analysis of every lesion is neither realistic nor necessary. The vast majority of skin lesions are benign and can be diagnosed dermatoscopically by pattern recognition. **The main benign lesions, pigmented and nonpigmented, that can be encountered every working day can be divided into five groups: nevus, benign keratinocytic, hemangioma, dermatofibroma, and sebaceous gland hyperplasia.**

Because these lesions are ubiquitous, the clinician can very rapidly become an expert at recognizing them by deliberately looking at thousands of them to understand their characteristic protean variations.

What chaos really means

There are two steps used in the decision-making process to triage skin lesions. The first step is to decide if a lesion is suspicious and the second whether it is likely to be malignant. Dermatoscopic chaos is the most compelling factor in deciding whether a pigmented lesion is suspicious, and this, along with some other "red flags," should determine the first part of the triage process.

Benign lesions tend to have biological symmetry, which occurs in the form of recognizable patterns, just as faces of different species of animals have recognizable patterns. We will recognize any dog's face by pattern recognition even though there are many different morphological varieties of dog faces. In Figure 5a.1, there are six different images of animal faces. The first five are recognizable as "normal" faces because even though they are not necessarily perfectly symmetrical, they are biologically symmetrical and therefore recognizable. *They do not exhibit chaos*. The sixth image, on the other hand, is not biologically symmetrical. *It is chaotic* and therefore unrecognizable, which means that pattern analysis must be used to weigh clues to identify what it represents.

The common benign skin lesions we may see every day are also recognizable because of biologically symmetrical characteristic patterns (Figure 5a.2). Just as there are many different morphological varieties of dogs and fish, there are many different morphological types of nevus and of seborrheic keratosis, but the experienced clinician will recognize them instantly through the dermatoscope as nevi or seborrheic keratoses and move to the next lesion. Becoming an expert at pattern recognition of common benign lesions requires only one thing—the deliberate examination of thousands of them with a dermatoscope.

Red flags

Red Flags represent the ***features that flag a lesion as suspicious and therefore warranting formal algorithmic assessment.*** These features are such that they will either be known (patient concern), be obvious (clinical pattern-breaker), or be recognized during *scanning* dermatoscopic evaluation (chaos of pattern, color, or border abruptness, dermatoscopic clues to change, and dermatoscopic uniqueness).

Red flags in addition to dermatoscopic chaos

Patient concern or clinical evidence of change

No lesion of patient concern should ever be dismissed without targeted examination including dermatoscopy [3, 4]. Patients may be concerned because a seborrheic keratosis is large and black, because a hemangioma has suddenly appeared, or because a mole is perceived to have changed. Patient concern should automatically **flag a lesion as suspicious** and lead to an analytical assessment. Similarly, documented evidence of change at mature age, including deliberately monitored change, **flags a lesion as suspicious** and therefore requiring focused dermatoscopic assessment.



FIGURE 5A.1 In this collage of faces, the first five are recognizable by pattern recognition because they are biologically symmetrical. The sixth exhibits biological asymmetry (chaos) and therefore may require further analysis of the patterns to achieve recognition.

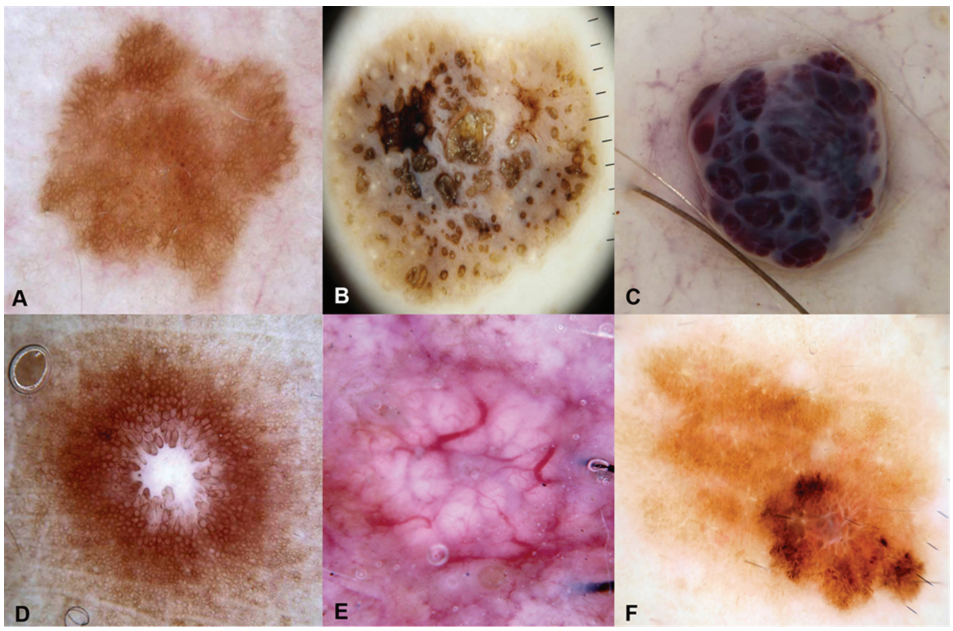

FIGURE 5A.2 To an experienced dermatoscopist, the first five lesions in this collage are biologically symmetrical (no chaos) and will be diagnosed by pattern recognition as (a) nevus, (b) seborrheic keratosis, (c) hemangioma, (d) dermatofibroma, and (e) sebaceous hyperplasia. The last lesion (f) is asymmetrical and cannot be *recognized* as any of the common benign lesions; thus, pattern analysis is applied. It is disorganized (chaotic) with clues to malignancy; melanoma invasive.

Clinical pattern-breaker

The same disorganized and uncontrolled behavior of malignant tissue that causes dermatoscopic chaos often causes malignant lesions to clinically break the pattern of the surrounding skin. Malignant lesions may arise randomly, have an irregular, unexpected shape or color, and eventually, their unrestrained growth may make them larger than surrounding benign lesions. A lesion that breaks the pattern clinically should be **flagged as suspicious** and dermatoscopically analyzed [2].

Dermatoscopic clues to change

Peripheral clods, radial lines, and pseudopods are all dermatoscopic clues to change. ***Circumferential*** peripheral clods may not cause concern in adolescence, but **any clues to change should flag a lesion as suspicious at mature age**. At

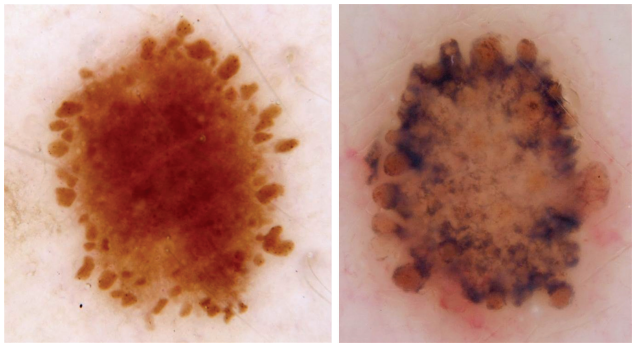

FIGURE 5A.3 Two lesions with the dermatoscopic clue to change of peripheral clods. Lesion (a) was a growing nevus on the back of an adolescent (not excised). Lesion (b) was on the back of a 60-year-old woman, and it was excised; nodular melanoma 3 mm in diameter with a Breslow thickness of 0.9 mm. Note that the melanoma, although arguably symmetrical, has a disorganized structure compared with the nevus, consistent with the chaotic behavior of malignant tissue. (From Rosendahl, C., et al., *Dermatol Pract Concept*, 4(2), 15, 2014.)

intermediate age, this feature should be assessed in the context of other lesions on the patient. ***Segmental*** radial lines or pseudopods should be recognized as a red flag at any age (Figure 5a.3).

Dermatoscopic uniqueness

Any lesion that has a dermatoscopic pattern different from all other lesions on the patient should be **flagged as suspicious**. This feature has been previously described as the dermatoscopic ugly duckling sign [5], and it is particularly relevant with respect to a clod pattern nevus at mature age, which is usually not expected at this stage of life (Figure 5a.4).

Chaos and Clues: A dermatoscopic decision algorithm

When clinical and dermatoscopic examination identifies a **red flag** as defined previously, the lesion is **flagged as suspicious** and is subjected to a careful, methodical examination by the method of choice.

While we prefer to use Chaos and Clues, we do not believe that the performance of an expert using an alternative method will be in any way inferior. We prefer Chaos and Clues because we have found that it is easy to teach and relatively easy to employ in a busy routine practice. It also uses clearly defined geometric terminology, facilitating unambiguous communication between professionals, this being particularly relevant with teledermatoscopy. Expert diagnosis has more to do with experience and expertise than choice of method. However, a method that cannot be taught is barely a method at all.

The flowchart for the Chaos and Clues algorithm is shown in Figure 5a.5.

Chaos

While natural laws (gravity, electrical and magnetic fields, surface tension, and feedback mechanisms) favor symmetry, malignant tissue defies natural laws, and this is the basis for both dermatopathological and dermatoscopic chaos in malignant tissue (see Figure 5a.6). This chaotic behavior of malignant tissue also produces all the other red flag characteristics

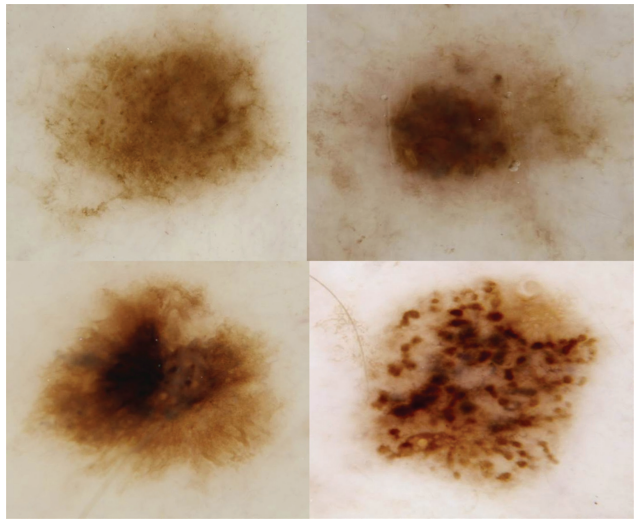

FIGURE 5A.4 Four lesions on the anterior thigh of a 50-year-old woman. Lesions (a–c) were all consistent with the patient's signature nevi, being structureless and with reasonable biological symmetry. The fourth lesion (d) was also reasonably symmetrical but being the only clod pattern lesion, making it dermatoscopically unique, it was excised; melanoma in situ.

described earlier, as well as the clues to malignancy described later. If a dermatoscopist is equivocating about the presence of chaos, the situation is usually resolved by considering whether the dermatoscopic pattern is consistent with the chaotic behavior of malignant tissue.

Chaos is defined as the presence of dermatoscopic asymmetry of any or all of pattern, color, and border abruptness. *This differs from asymmetry as assessed by the revised pattern analysis method in that chaos of border abruptness is not included in that method* [1]. Any irregularity of the shape of a lesion is not relevant.

Chaos of pattern requires the presence of more than one pattern (a pattern covering a significant area of the lesion, arbitrarily defined as at least 20%), with the patterns being asymmetrically combined. If any of the highly specific defined clues (i.e., peripheral black clods/dots, lines radial segmental/pseudopods) is asymmetrically present in a lesion, even if the structure does not cover sufficient area to produce a pattern, it is considered chaotic.

Chaos of color requires the presence of more than one color (light and dark brown being regarded as different colors if the transition between them is abrupt), with those colors being asymmetrically combined. If the variation is obvious and abruptly demarcated, there is no lower limit of the area required to be covered by a color to create asymmetry.

Chaos of border abruptness is defined as definite and asymmetric variability in the abruptness of demarcation of the border of a lesion.* While border abruptness is also assessed in the ABCD method of dermatoscopy, it is given most significance when the total border is abrupt (Figure 5a.7). The ABCD method would therefore allocate the highest score for border abruptness to an ink spot lentigo (Figure 5a.8) or solar lentigo and a lower score for a lesion that has abruptness of only a portion of the border (Figure 5a.9). In fact, abruptness of the



FIGURE 5A.5 Flowchart for the Chaos and Clues algorithm. Pigmented lesions are first assessed for the presence of chaos (chaos is defined as the presence of dermatoscopic asymmetry of any or all of pattern, color, and border abruptness). If chaos is present, the lesion is examined for any one or more of nine clues to malignancy. If a clue is present, an excisional biopsy is considered unless an unequivocal diagnosis of seborrheic keratosis can be made by pattern analysis. There are four exceptions in which an excisional biopsy is *considered* even for nonchaotic lesions: any changing lesion on an adult, a nodular or small (<6 mm) lesion (lacking the morphology of a known benign lesion) with any clue to malignancy, any lesion on the head or neck (lacking the morphology of a known benign lesion) with either pigmented circles or dermatoscopic gray color, and any acral lesion with a parallel ridge pattern pigmented by melanin. (From Kittler, H., et al., *Dermatoscopy*, 2nd ed., Facultas, Austria, 2016.)

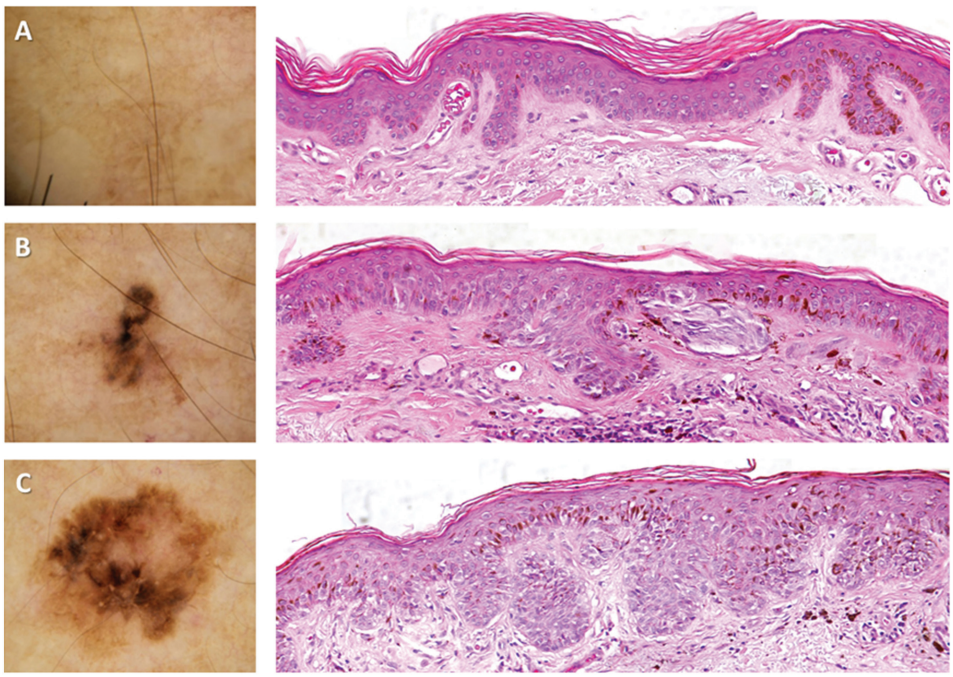

FIGURE 5A.6 Dermatoscopic chaos can be seen to increase along with histological disorganization moving from perilesional skin (a) to melanoma in situ (b) and to invasive melanoma (c), all being encountered on the same patient on the same day.

total border is a feature of benignancy, while chaos of border abruptness is more likely to be observed in a malignant lesion (Figure 5a.7).*

Clues

1. **Gray or blue structures** (including gray or blue structureless). This clue, in a chaotic lesion, applies to both melanocytic and nonmelanocytic malignancies. Gray color correlates with melanin in the superficial dermis, either in melanocytes, in keratinocytes or as melanin incontinence in melanophages, which is frequently the result of an immune attack even on lesions that remain confined to the epidermis. Gray color is the most sensitive clue to malignancy and is seen in most in situ melanomas (Figure 5a.10) and in many pigmented basal cell carcinomas (pBCC) and pigmented squamous cell carcinomas (pSCC). In a study on flat pigmented facial lesions, the presence of gray color was found to have a

* Chaos of border abruptness was first recognized and described to us by Francis Drugge, the 12-year-old son of dermatologist Rhett Drugge (Stanford, Connecticut, USA)

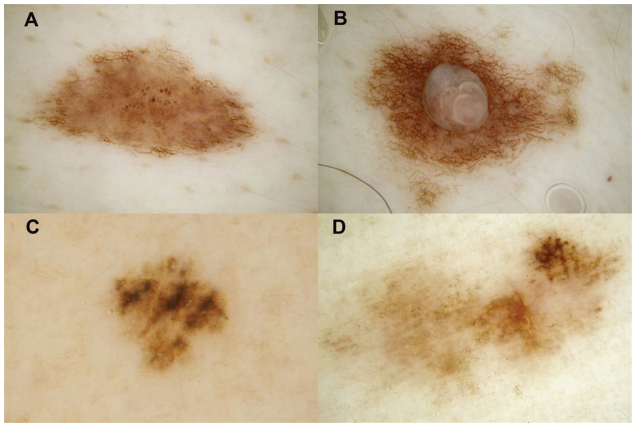

FIGURE 5A.7 This composite of four lesions from the same patient shows only one (d) with dermatoscopic chaos. It was excised and confirmed as a melanoma in situ. The other three lesions have been confirmed as benign by stability over time. Their morphology is consistent with the diagnosis of compound congenital-type nevus. (a) Central clod pattern surrounded by a structureless pattern with a pattern of lines at the periphery—concentric symmetry. (b) Central skin-colored clods and peripheral pattern of lines—concentric symmetry. (c) Structureless pattern with central gray and brown above and below—symmetry. Shape is irrelevant, and none of the lesions (a–c) has a pattern consistent with the chaotic behavior of malignant tissue. (d) Unequivocal asymmetry of both pattern and color consistent with the chaotic behavior of malignant tissue. It is also the only one with chaos of border abruptness. (From Kittler, H., et al., *Dermatoscopy*, 2nd ed., Facultas, Austria, 2016.)

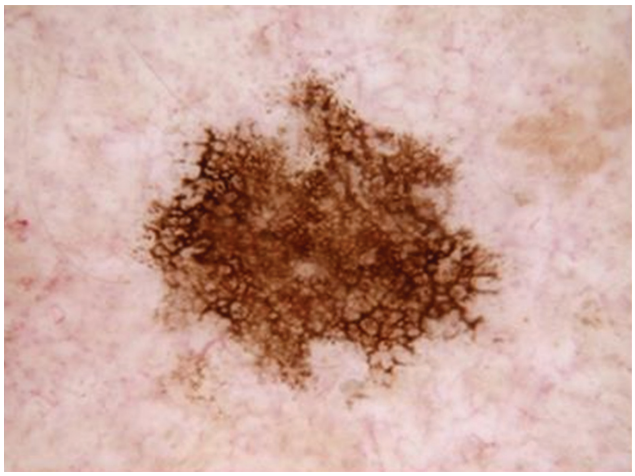

FIGURE 5A.8 An ink-spot lentigo demonstrating an abrupt border over the total perimeter, which would give the lesion a high score in the ABCD method of dermatoscopy. However, the lack of chaos of border abruptness is a feature of benignancy, which is consistent with the diagnosis of ink-spot lentigo.

sensitivity and specificity for the diagnosis of melanoma of 95.8% and 30.6%, respectively [6, 7].

Blue color correlates with pigment in the deep dermis, most commonly in nested melanocytes or nests of BCC (Figure 5a.11).

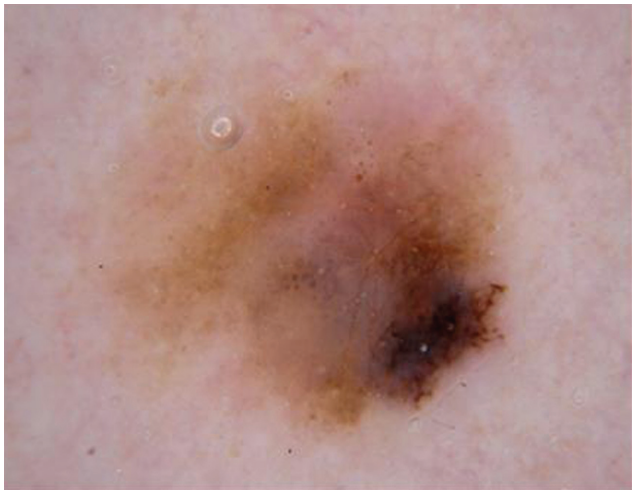

FIGURE 5A.9 Invasive melanoma demonstrating chaos of pattern, color, and border abruptness with an abrupt border at the lower right extremity and a gradual border elsewhere.

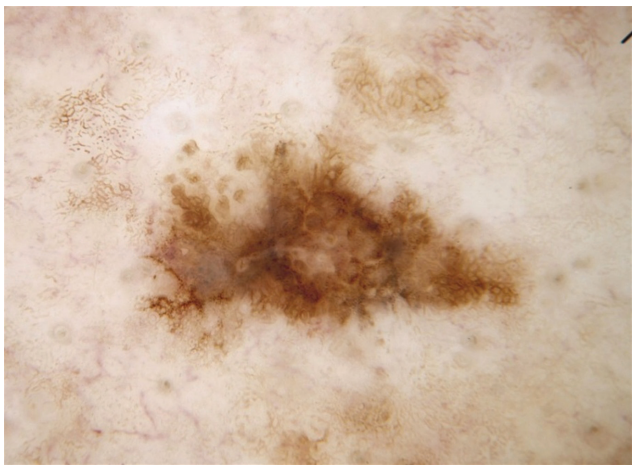

FIGURE 5A.10 Gray color in this in situ melanoma is seen as contrasting with the brown background—a color invariably present in a pigmented (melanotic) melanocytic lesion.

2. **An eccentric structureless area** *must cover a sufficient area of the lesion to form a pattern; it must be eccentrically located, contrasted to a structured pattern present within the lesion or to a structureless pattern of significantly different color, and have a color other than skin-colored.* Different colors of melanin may be produced by the chaotic behavior of malignant melanocytes; if pink is present, it may be caused by increased blood flow from the high metabolic demand of tumor tissue, and if white is present, it may correlate with fibrosis after regression. This clue applies to both melanocytic and nonmelanocytic malignancies (Figure 5a.12).
3. **Thick lines reticular** are defined when the lines are at least as thick as the holes that they surround, and in melanocytic lesions they may correlate with rete ridges, which are widened by pigment-laden malignant melanocytes. In a chaotic lesion, they are a clue to malignancy and will be focally distributed rather than evenly widespread over the lesion (Figure 5a.13). This clue is

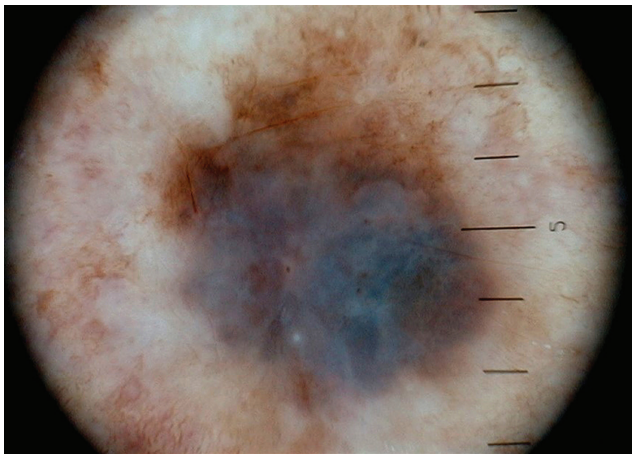

FIGURE 5A.11 The blue color in this invasive melanoma contrasts with the brown color.

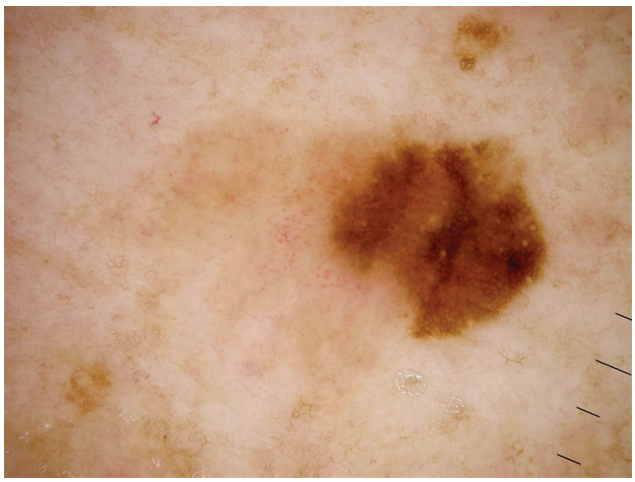

FIGURE 5A.12 An eccentric light brown structureless area extending to the left of a structured (lines reticular) area in this in situ melanoma.

specific to melanoma, as the presence of reticular lines effectively rules out the diagnosis of BCC or SCC. Thick reticular lines frequently occur in seborrheic keratoses due to acanthotic rete ridges (due to a proliferation of pigmented keratinocytes), but they will be widespread, and other clues to seborrheic keratosis are expected to be present.

4. **Black dots and clods, peripheral**, correlate with pigmented pagetoid melanocytes and nests of melanocytes in melanomas, and therefore, this clue is specific to melanoma. In reality, because dots are common in both pBCC and pSCC in situ, and because gray may be perceived as black, this clue can also be seen in those tumors. The reason for the designation that they be peripherally located is because black dots can be seen centrally in nevi that have been traumatized, correlating with pigment in ascending keratinocytes. Pagetoid spread can occur anywhere in a melanoma, so when black dots or clods are seen peripherally, they are regarded as a clue to malignancy (Figure 5a.14).

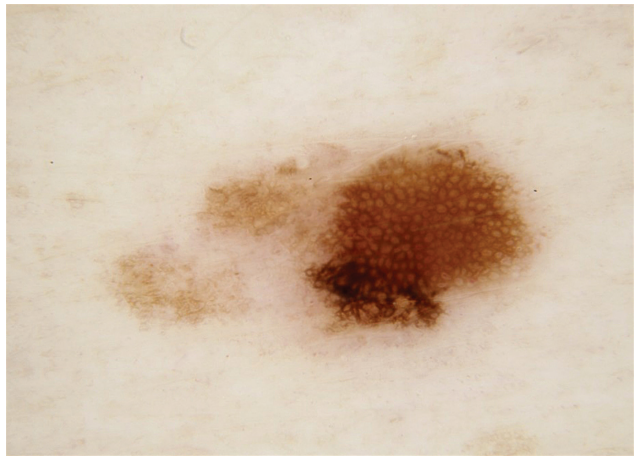

FIGURE 5A.13 This in situ melanoma has more than one pattern: lines reticular on the right and an eccentric structureless area on the left. Inferiorly, the reticular lines are focally thicker than the holes they surround. The fact that this clue to malignancy is unequivocal but focal is consistent with the chaotic behavior of malignant tissue.

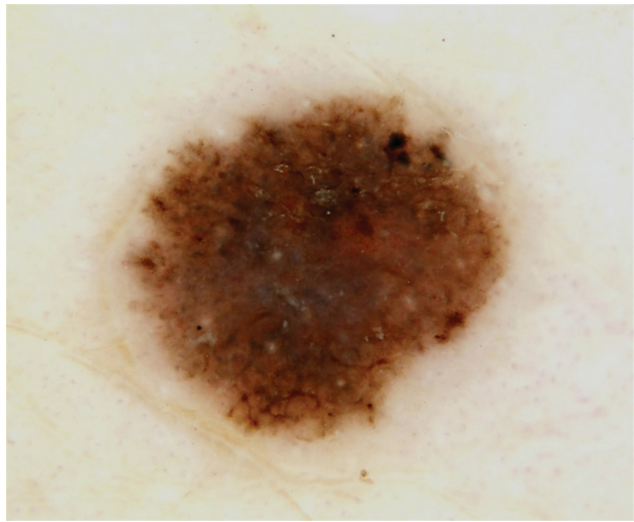

FIGURE 5A.14 In this small (4 mm diameter) young melanoma in situ, the feature of peripheral black clods at the upper right border of the lesion gives the lesion both chaos and a clue.

5. **Lines radial or pseudopods, segmental** are clues to malignancy, segmental pseudopods being specific to melanoma and lines radial segmental being found in all three pigmented malignancies. In melanocytic lesions, these structures correlate with fascicles of pigmented melanocytes extending from the periphery of a lesion, and they signify growth. In melanomas, they should be distributed asymmetrically and should extend from reticular lines, clods, or structureless areas of equivalently dense pigmentation to the radial lines or pseudopods (Figure 5a.15). This can sometimes distinguish them from the radial lines seen in BCCs, which invariably converge and may (but not always) project from hypopigmented structureless areas (Figure 5a.16). Lines radial segmental are also seen in pSCC in situ, which are usually created by dots in a linear arrangement (Figure 5a.17).

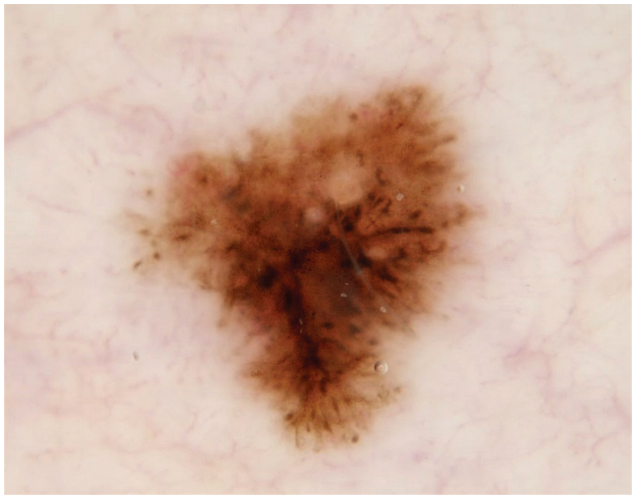

FIGURE 5A.15 Lines radial/pseudopods segmental in a melanoma in situ extending from pigmented structures as dark as, or darker than, the radial lines/pseudopods.

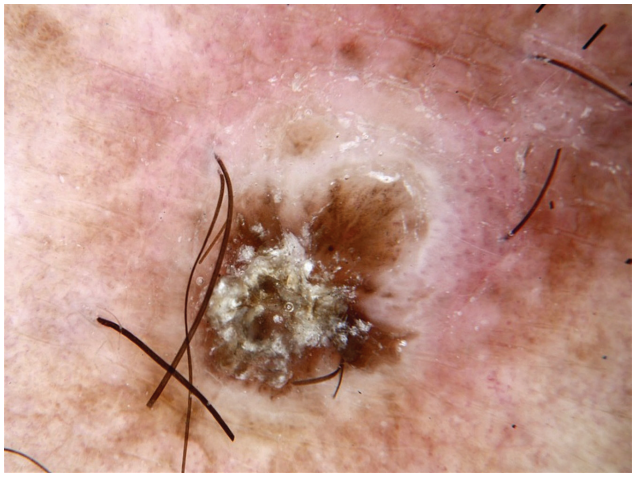

FIGURE 5A.17 Lines radial segmental are composed of dots in linear arrangement in this pSCC in situ. Surface keratin is an additional clue to the diagnosis.

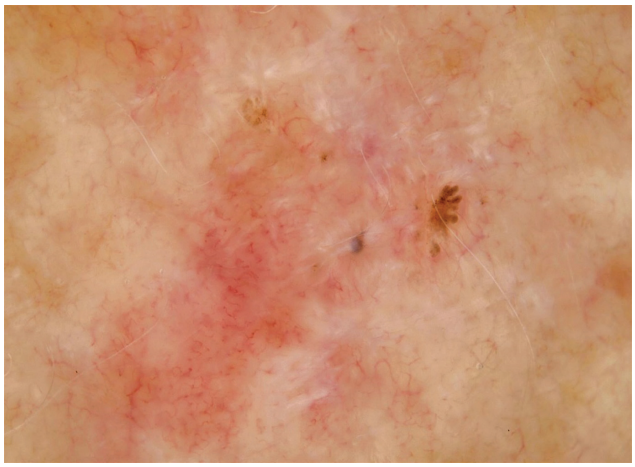

FIGURE 5A.16 In this pBCC, the radial lines have a morphology that is very specific to pBCC in that they converge and also extend from a nonpigmented area of the lesion.

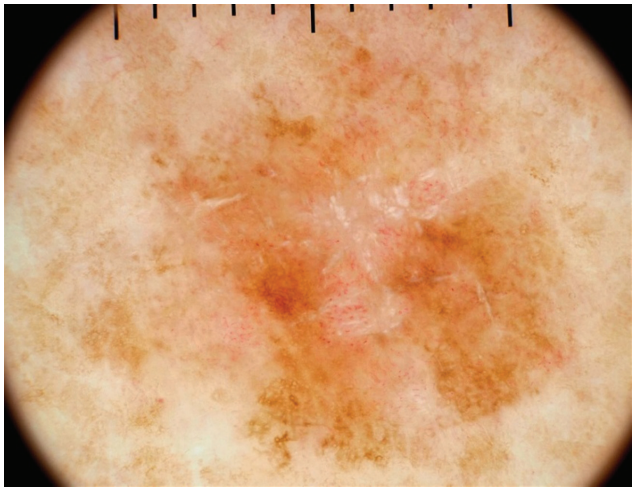

FIGURE 5A.18 Polarized dermatoscopy of this melanoma in situ displays white lines in a perpendicularly orientated arrangement.

6. **White lines** must be whiter than normal surrounding skin, and they may be polarizing specific (polarizing-specific blue lines have the same significance) or alternatively, white lines that are seen with both modalities. Polarizing-specific white lines are straight shiny white lines orientated perpendicularly to each other but not crossing. They are only seen with polarized dermatoscopy (Figure 5a.18); however, they may sometimes correlate with reticular white lines seen with nonpolarized dermatoscopy (Figure 5a.19). Polarizing-specific white lines are commonly seen in BCC (pigmented or nonpigmented), and they are not unusual in melanoma (pigmented or nonpigmented). They are rarely seen in pSCC in situ. They are also commonly seen in both dermatofibroma (DF) and Spitz nevus, but their presence is not expected in any other type of nevus (unless traumatized) or in seborrheic keratosis.
7. **Lines parallel on the ridges (acral) or lines parallel chaotic on the nails** are a clue to melanoma, specifically on acral skin (Figure 5a.20) or in nail matrix (Figure 5a.21), respectively. This is the only one of the listed clues to malignancy that is specific to a particular anatomical site. It is important to remember that the longer an acral or nail matrix melanoma remains untreated, the more likely it is to develop any of the other clues to melanoma.

   Melanoma may also arise in an acral nevus, in which case any of the other eight clues will override a benign parallel furrow pattern, which may be present (Figure 5a.22).
8. **Polymorphous vessels** are a clue to both melanoma and pBCC but not pSCC in situ, which is expected to have a monomorphous pattern of coiled vessels. Pigmented BCC often has a monomorphous pattern of serpentine or serpentine branched vessels, but it may have a pattern of polymorphous linear vessels (Figure 5a.23), especially on the lower limb.

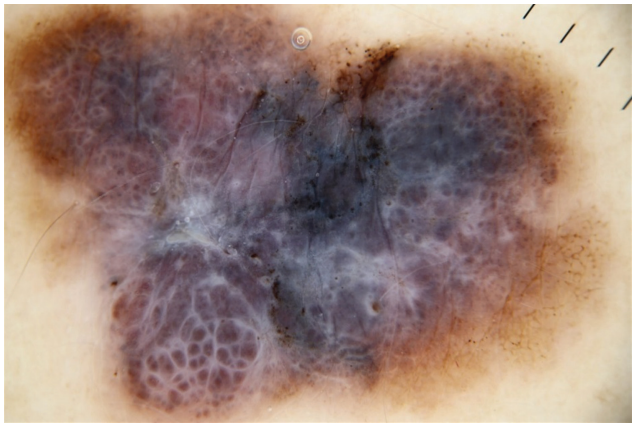

FIGURE 5A.19 Nonpolarized dermatoscopy of an invasive melanoma demonstrated white lines in a reticular arrangement.

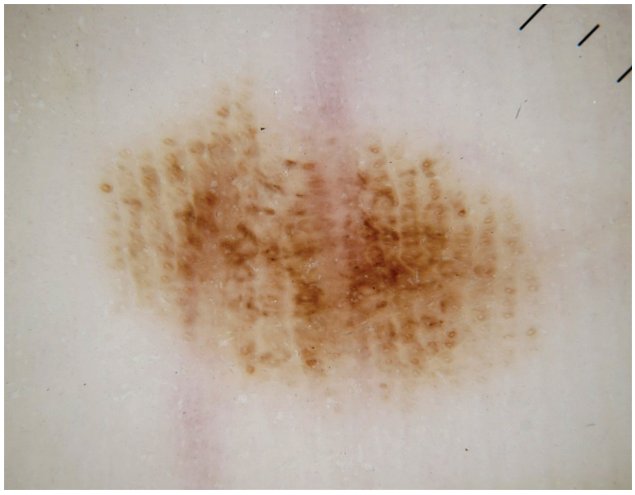

FIGURE 5A.20 Dermatoscopy image of a melanoma in situ on the sole of a 55-year-old woman's foot with a pattern of lines parallel. Although pigment is present on both dermatoglyphic ridges and furrows, the pattern of lines, best assessed at the edges of the lesion, is a parallel ridge pattern. Pigmented circles, marking the center of the ridges, correlate with pigmented malignant melanocytes in the eccrine ducts. This acral melanoma is arguably symmetrical but would qualify for excision as an "exception."



FIGURE 5A.21 Lines parallel chaotic (varying in width, interval, and color) in a nail matrix melanoma. (From Rosendahl, C., et al., *Dermatol Pract Concept*, 2(2), 13, 2012.)

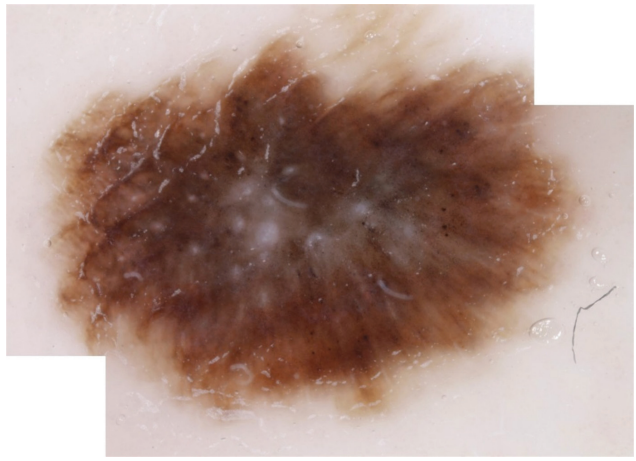

FIGURE 5A.22 In this image, the clue of radial lines segmental (right and inferior portions) overrides the clue of lines parallel in a furrow pattern (upper left). This is a melanoma arising in an acral nevus. Note that in the benign furrow pattern, there is pigment over the ridges, but the lines (as assessed at the edges) lie in the furrows. (Image courtesy Agata Bulinska.)

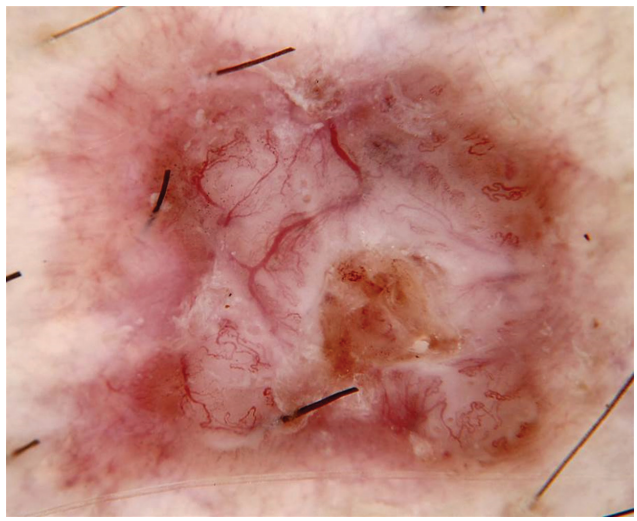

FIGURE 5A.23 This basal cell carcinoma displays linear polymorphic vessels. Branched serpentine (centrally) and looped (peripherally—upper right).

A pattern of dot vessels is not expected in pBCC, but ulceration, which is commonly present in BCC, and associated keratinization may produce polymorphous vessels, including looped vessels in radial arrangement and even dotted vessels (Figure 5a.24).

In melanomas, polymorphous vessels may include various types of linear vessels in raised portions and a pattern of dot vessel, as well as any pattern of linear vessel, over macular areas. Generally, other clues in addition to polymorphous vessels (pigment clues and/or white lines) are expected in a melanoma, and the vessel clues are then useful in differentiating melanoma from pBCC and pSCC in situ (Figure 5a.25). Dot vessels correlate with vessels ascending in dermal papillae and are not therefore expected in the raised portion of a melanoma, in which the regular morphology of dermal papillae is not expected.

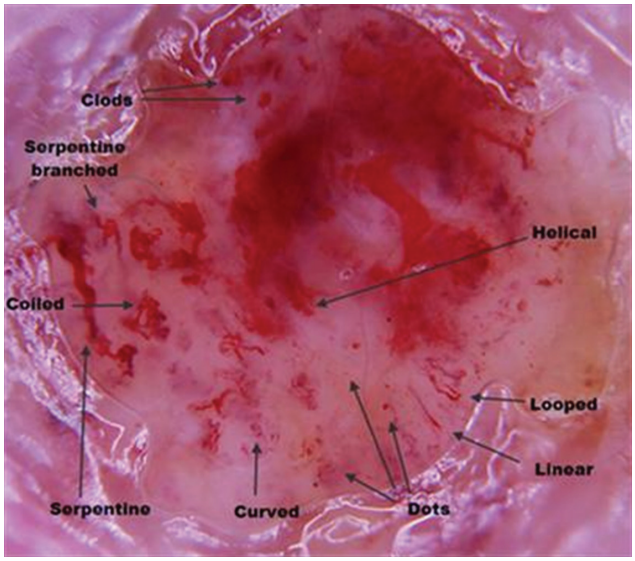

FIGURE 5A.24 Ulceration over the total surface of this basal cell carcinoma resulted in a polymorphous pattern of vessels including almost every vessel type.

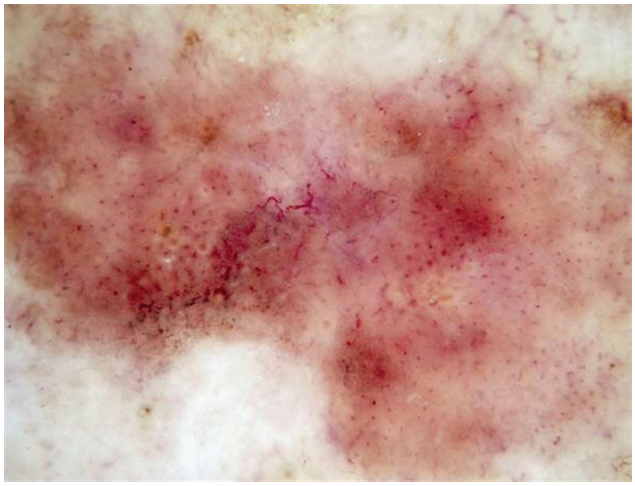

FIGURE 5A.25 Chaos and the clue of gray color point to malignancy. A pattern of serpentine vessels centrally combined with a vast pattern of dot vessels is consistent with melanoma; Melanoma, only focally invasive.

Pigmented SCC in situ is expected to have a monomorphous pattern of coiled vessels, which may be seen as dots depending on visual acuity and magnification (Figure 5a.26).

9. **Angulated lines** are straight lines, not reticular or branched, meeting at angles 90° or more, but not crossing. These lines may join to enclose a **polygon**. Straight pigment interfaces have the same significance as straight lines. This clue, in a chaotic lesion, is a valuable clue to melanoma (Figure 5a.27) but may also rarely be seen in pBCC (Figure 5a.28) as well as on pSCC in situ and pigmented actinic keratosis.

Exceptions

Chaos and Clues was tested on a consecutive series of pigmented lesions, the majority of melanomas in the series being in situ. It was found to have a sensitivity of 90.6% (BCC 98.5%, SCC 86.5%, melanoma 79.3%) and a specificity of 62.7% for the diagnosis of malignancy, any type [8]. In an attempt to move the sensitivity closer to 100%, the following exceptions are included to *consider* lesions for biopsy, even if not chaotic:

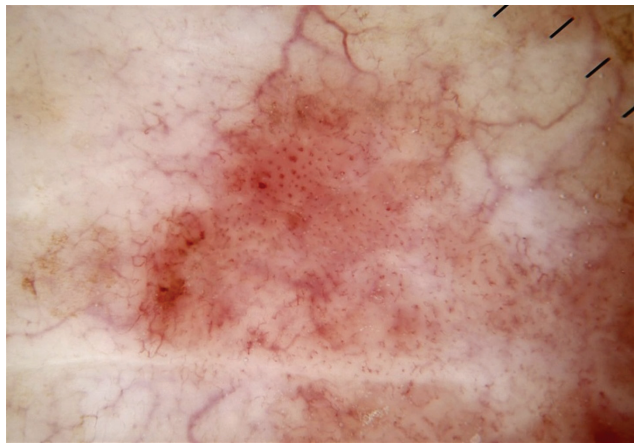

FIGURE 5A.26 A lightly pigmented SCC in situ displays a monomorphic pattern of coiled vessels, which on the right-hand side of the lesion present as dots. A few linear serpentine dermal plexus vessels, seen at the edge of the lesion, do not make this a polymorphous pattern.

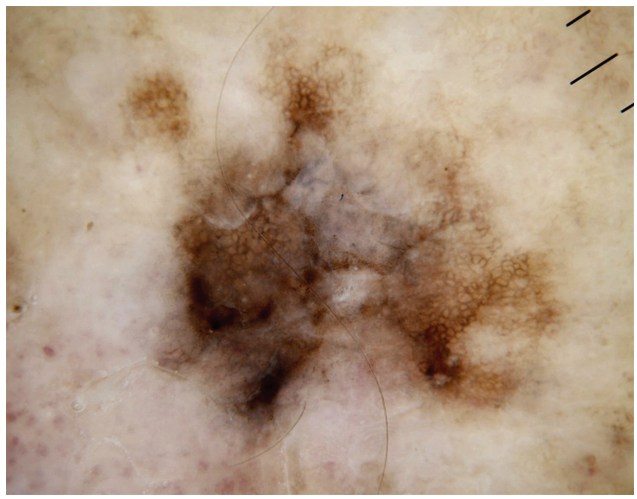

FIGURE 5A.27 Angulated lines form both complete and incomplete polygons in this melanoma in situ.

1. **Any changing lesion on an adult**. This includes a lesion with a history of change, lesions with monitored change (Figure 5a.29), and lesions with dermatoscopic clues to change, such as the presence of peripheral clods (Figure 5a.30) or radial lines/pseudopods. The presence of peripheral clods must be considered in the context of the age of the patient. Peripheral clods in an otherwise unremarkable lesion with the morphology of a nevus are consistent with the diagnosis of a growing nevus under the age of 30 but not over the age of 50 (Figure 5a.31). In between these ages, the clues must be weighed, discretion exercised, and if doubt remains, then excision biopsy is prudent.

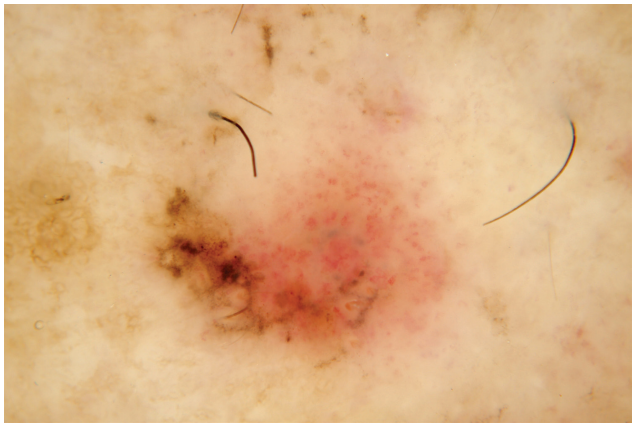

FIGURE 5A.28 Angulated lines in a pigmented BCC.

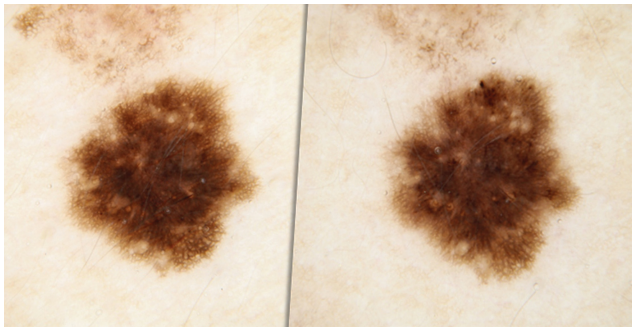

FIGURE 5A.29 A pigmented skin lesion (a) has been dermatoscopically monitored over 6 months (b). A structural change, with the appearance of a small cluster of peripheral black dots (upper extremity), led to excisional biopsy; melanoma in situ.

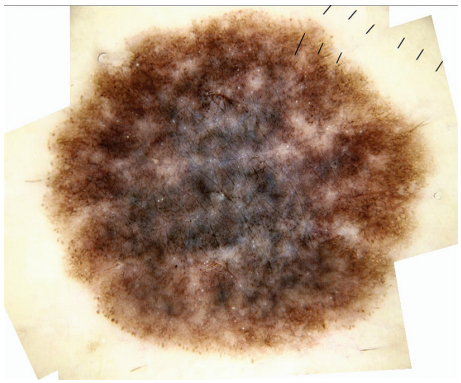

FIGURE 5A.30 A large symmetrical pigmented skin lesion on the abdomen of a 70-year-old man has the dermatoscopic clue to change of peripheral clods/dots. Excisional biopsy revealed an invasive melanoma.

2. **A nodular or small lesion that has any of the clues to malignancy**. We defined small, arbitrarily, as less than 6 mm in diameter, this being the size cited in the clinical ABCD method of dermatoscopy. This 3 mm diameter nodular melanoma shown in Figure 5a.31 was arguably symmetrical, but in addition to peripheral clods as a dermatoscopic clue to change, it had the clue of gray color.

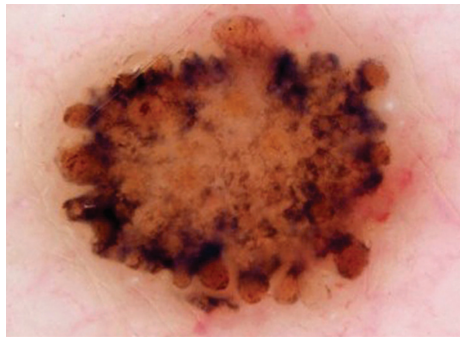

FIGURE 5A.31 This pigmented skin lesion on the flank of a 60-year-old lady was only 3 mm in diameter, but it was raised. Although it had structural symmetry, there were two relevant exceptions. First, there was the dermatoscopic clue to change of peripheral clods, and second, it was both small and nodular with the clue of gray structures; nodular melanoma (Breslow thickness 0.8 mm). (From Rosendahl, C., et al., *Dermatol Pract Concept*, 4(2), 15, 2014.)



FIGURE 5A.32 A 4 mm diameter pigmented skin lesion on the ear of an adult male is both a small lesion with a clue (dermatoscopic gray) and also a lesion on the head and neck with dermatoscopic gray. However, a lesion that has the unequivocal morphology of a nevus (symmetry and a gradual border over the total periphery), as well as historical stability, does not need to be excised.

*This particular exception should only be applied with respect to **small** lesions if there is an additional significant cause for concern*. Many nevi have gray color or even patterns that could be interpreted as angulated lines, but if they are nonchaotic, and a gradual border supports the diagnosis of nevus, there being no historical information to cause concern, a biopsy is *not* indicated (Figure 5a.32).

Also, the common lesion DF is a small nodular lesion that frequently has central polarizing-specific white lines, and if DF can be diagnosed confidently by clinical (including historical stability) and dermatoscopic criteria, excision biopsy is not necessary (Figure 5a.33).

3. **Any lesion on the head or neck with pigmented circles and/or any dermatoscopic gray**. This clue acknowledges the fact that young melanomas on the head and neck, possibly related to a physical barrier effect of numerous follicles, may be symmetrical (Figure 5a.34). A study on flat pigmented facial lesions found that the presence

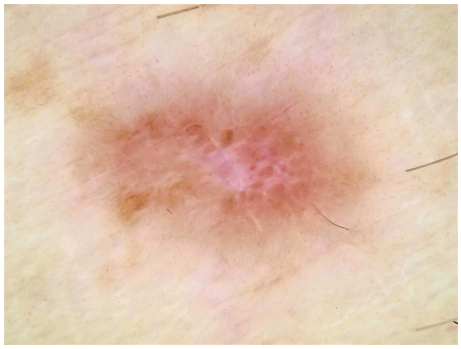

FIGURE 5A.33 This lesion is a small nodular lesion with the clue to malignancy of polarizing-specific white lines. However, it has a history of stability, the morphology of a dermatofibroma with biological symmetry of pattern and color with a central white area; therefore, it does not require excision.

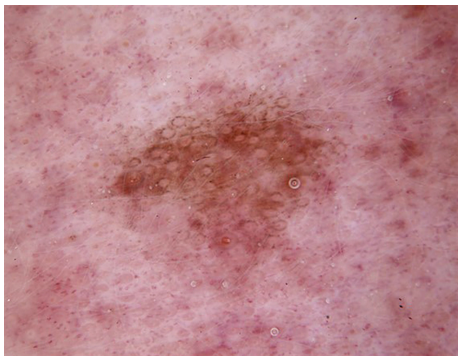

FIGURE 5A.34 This pigmented skin lesion on the ear lobe of a 42-year-old man is arguably symmetrical, but it does not have a uniform border, so a specific benign diagnosis could not be rendered. In this context, pigmented circles related to adnexal openings were a compelling clue to melanoma; melanoma in situ.

of any gray structures had sensitivity and specificity for melanoma of 95.8% and 30.5%, respectively, while gray circles had a sensitivity of 54.2% and a specificity of 83.3% [6]. Pigmented circles (any color) were similar to grey circles, with a sensitivity and specificity for melanoma of 70.83% and 76.9%, respectively [7—unpublished data from the same study].

4. **Any lesion on acral skin with a parallel ridge pattern**. This clue acknowledges the fact that young melanomas on acral skin, possibly related to a physical barrier effect of numerous eccrine ducts, may be symmetrical (Figure 5a.20).

Conclusion

Chaos and Clues is not a method designed for robots, and it should not be regarded as an ultimate method set in stone. It has been designed as a useful tool, avoiding tedious mathematical calculations, unburdened by a language of innumerable poorly defined metaphorical terms carrying preconceived diagnostic implications, and it is suitable for seamless integration into routine practice. Individuals are encouraged to use it as a framework on which to organize their accumulated experience as they individualize the method for their own style and practice.

References

1. Kittler H, Rosendahl C, Cameron A, Tschandl P. *Dermatoscopy*. 2nd ed. Austria: Facultas; 2016.
2. Rosendahl C, Cameron A, McColl I, Wilkinson D. Dermatoscopy in routine practice: "Chaos and Clues". *Aust Fam Physician*. 2012 Jul; 41(7):482–7.
3. Bourne P, Rosendahl C, Keir J, Cameron A. BLINCK: a diagnostic algorithm for skin cancer diagnosis combining clinical features with dermatoscopy findings. *Dermatol Pract Conc.* 2012;2(2):12. doi:10.5826/dpc.0202a12
4. Rosendahl C, Hishon M, Cameron A, Barksdale S, Weedon D, Kittler H. Nodular melanoma: five consecutive cases in a general practice with polarized and non-polarized dermatoscopy and dermatopathology. *Dermatol Pract Concept*. 2014;4(2):15.
5. Scope A, Marghoob AA. The "ugly duckling" sign: an early melanoma recognition tool for clinicians and the public. *Melanoma Lett.* 2007;25:1–2.
6. Tschandl P, Rosendahl C, Kittler H. Dermatoscopy of flat pigmented facial lesions. *J Eur Acad Dermatol Venereol.* 2014 Mar 24.
7. Rosendahl C, Cameron A, Wilkinson D, Belt P, Williamson R, Weedon D. Nail matrix melanoma: consecutive cases in a general practice. *Dermatol Pract Conc.* 2012;2(2):13. doi:10.5826/dpc.0202a13
8. Rosendahl C, Tschandl P, Cameron A, Kittler H. Diagnostic accuracy of dermatoscopy for melanocytic and nonmelanocytic pigmented lesions. *J. Am. Acad. Dermatol.* 2011 Jun; 64(6):1068–73.

5B TRIAGE ALGORITHMS: TRIAGE AMALGAMATED DERMOSCOPY ALGORITHM (TADA)

Natalia Jaimes and Ashfaq Marghoob

Contents

TADA Step 1: *Is the lesion an unequivocal seborrheic keratosis, angioma, or dermatofibroma?* 81
TADA Step 2: *Does the lesion manifest a disorganized pattern?* 81
TADA Step 3: *Does the organized-appearing lesion manifest one of two patterns, two structures, or four colors?* 81
References 85

The Triage Amalgamated Dermoscopic Algorithm (TADA) is a three-step algorithm created to provide a simple method to guide management decisions as to whether the lesion under investigation should undergo a biopsy or referral to an expert clinician. The TADA is a triage algorithm that incorporates key criteria for malignancy derived from existing algorithms.[1–5] TADA has been tested in a reader study with clinicians and nurse practitioners with a resulting sensitivity of between 88.1% and 94.8%, and specificity between 72.3% to 87.8%.[6, 7] (Figure 5b.1). TADA was designed and tested on lesions on non-glabrous skin. It cannot be used on lesions located on volar surfaces, nails, and mucosae.

TADA Step 1: *Is the lesion an unequivocal seborrheic keratosis, angioma, or dermatofibroma?*

In the first step of the TADA, the observer determines whether the lesion fulfills the clinical and dermoscopic criteria for an *unequivocal* seborrheic keratosis, angioma, or dermatofibroma, which are some of the most common benign lesions encountered in the clinical daily practice (Figure 5b.2–5b.4). Less common benign lesions such as clear cell acanthoma, molluscum, and xanthogranuloma, among others, are not included in the TADA, but if the clinician has gained experience and expertise and can confidently diagnose other lesions as benign, then they can add them to the list of benign lesions in step 1 of the TADA.

If the lesion is unequivocally considered, based on clinical experience and dermoscopy, to be a benign lesion, then the patient can be reassured, and no further evaluation is required. If the lesion does not manifest an unequivocal benign pattern, the lesion will proceed to the second step of TADA.

TADA Step 2: *Does the lesion manifest a disorganized pattern?*

Only those lesions that are not unequivocally benign will proceed to step 2, which requires the use of *polarized light*. In this step, the observer determines whether the lesion demonstrates an organized or a disorganized pattern. Dermoscopic patterns take into account the distribution of colors and structures within the lesion. Lesions displaying a chaotic or disorganized distribution of colors and structures are considered suspicious (Figure 5b.5 and 5b.6).

Asymmetry (chaos or disorganized pattern) in dermoscopy is the most important characteristic to help differentiate benign and malignant tumors. [1, 2, 8] It is reproducible and demonstrates the highest inter-observer agreement. [3, 9] Thus, if the lesion displays a disorganized pattern, a skin biopsy should be performed. If the lesion reveals an organized pattern, the lesion will proceed to be evaluated in the third and final step of TADA.

TADA Step 3: *Does the organized-appearing lesion manifest one of two patterns, two structures, or four colors?*

Only those equivocal lesions demonstrating a dermoscopic organized pattern will proceed to step 3, which also requires the use of *polarized light*. In the third step, the observer determines whether **any** of the following features are present (Figure 5b.7–11):

1. Any one of **two patterns**:
   a. *Streaks or globules forming a starburst pattern:* A starburst pattern can be seen in Spitz/Reed's nevi but also in melanoma. Thus, this pattern should be considered suspicious, especially if found in individuals over the age of 12 years, and a biopsy should be performed (Figures 5b.7a-5b.8).
   b. *Negative network pattern:* Both Spitz nevi and melanomas can display a negative network throughout the lesion. Thus, this pattern should be considered suspicious, and a biopsy should be performed (Figure 5b.9).
2. Any of **two structures**:
   a. *Vessels:* Lesions revealing any vascular structure, including vessels of any morphology, should be considered concerning and biopsied (Figures 5b.7e, 5b.9).
   b. *Ulceration:* A lesion with ulceration or erosions should be considered suspect and biopsied.
3. Any one of **four colors** (5b.7b–c, 5b.10–5b.11):
   a. *Blue*
   b. *Black*

DOI: 10.1201/9780429487873-8

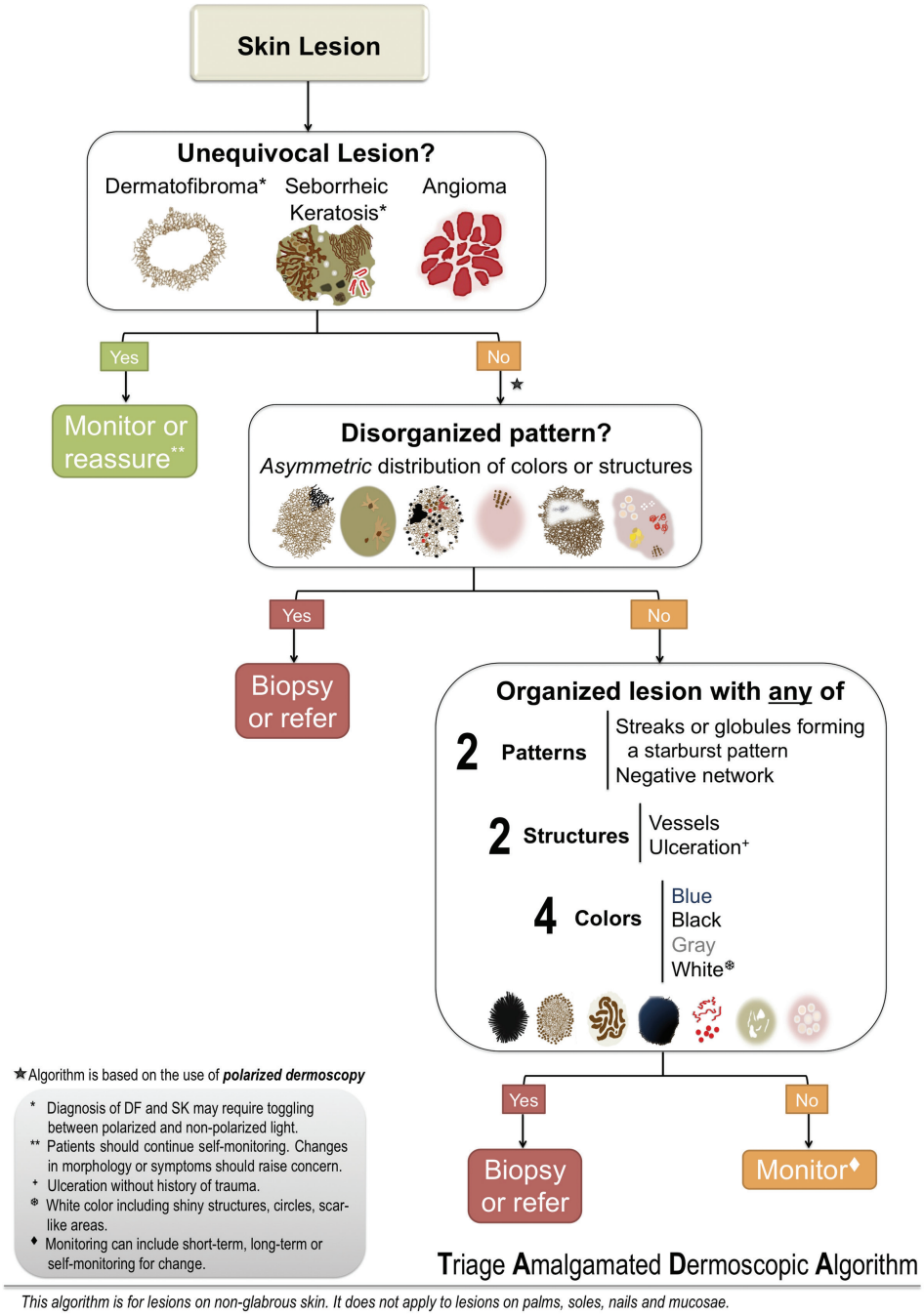

FIGURE 5B.1 Triage Amalgamated Algorithm.

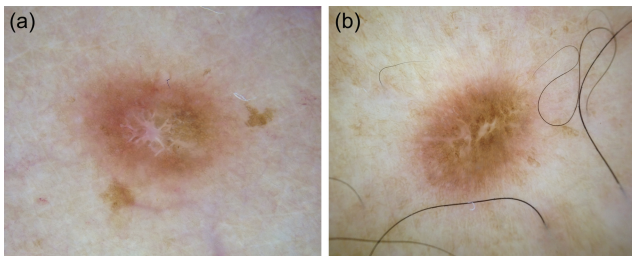

FIGURE 5B.2 Dermoscopic images of unequivocal dermatofibromas. Dermoscopy demonstrates a peripheral network with a central scarlike area, and ring-like structures.

c. *Gray:* The presence of blue-black color has been shown to have high sensitivity for nodular melanoma.[4] Similarly, gray color is an important clue for skin cancer, in particular for melanomas on sun-damaged skin.[5] Therefore, any organized lesion revealing blue-black or gray color should be considered suspicious and subjected to biopsy.[10, 11]

d. *White:* White structures include shiny white structures and white circles. Shiny white structures are most conspicuous when viewed with polarized dermoscopy and include the melanoma-specific structures known as shiny white lines or streaks and the

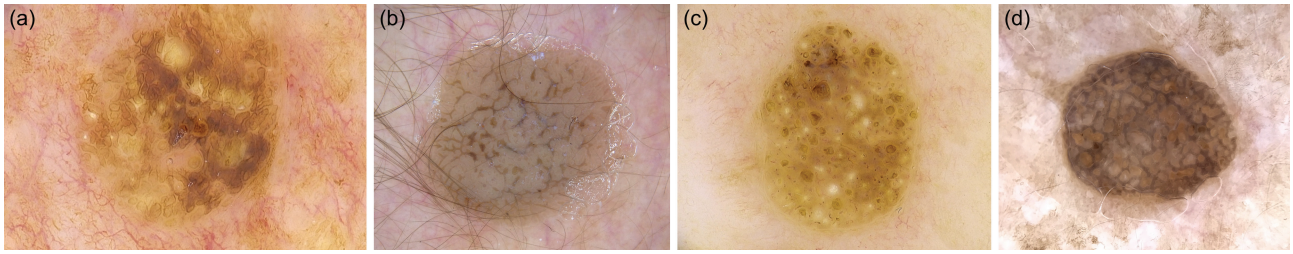

FIGURE 5B.3 Dermoscopic images of unequivocal seborrheic keratosis. (a) Dermoscopy reveals gyri and sulci (ridges and fissures) and milia cysts, (b) seborrheic keratosis with a cerebriform pattern, (c) seborrheic keratosis with multiple comedo-like openings, milia cysts, and well demarcated borders.

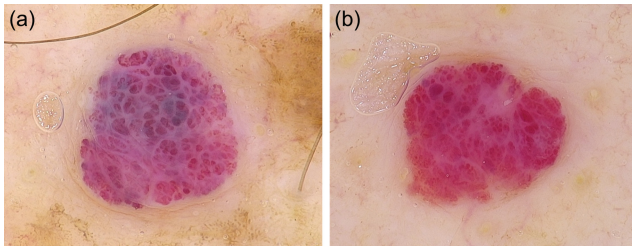

FIGURE 5B.4 Dermoscopic images of unequivocal angiomas. Dermoscopy reveals lacunae separated by septae.

basal cell carcinoma–specific structures known as shiny white blotches and strands. White circles can be seen with both polarized and nonpolarized dermoscopy and are a feature associated with well-differentiated squamous cell carcinomas. Although all these white structures have a strong association with malignancy,[12–14] there are benign lesions, such as dermatofibromas, lichen planus–like keratoses, and Spitz nevi, that may also reveal these structures. However, for the purpose of a triage algorithm, which TADA is intended to be, it would be advisable that any lesion displaying white color be viewed with suspicion.

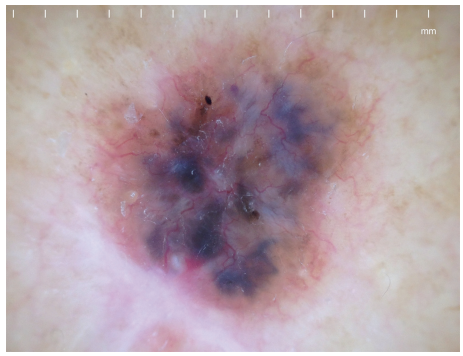

FIGURE 5B.5 Dermoscopic image of basal cell carcinoma revealing a disorganized pattern of colors and structures.

Malignancy should be considered in any organized lesion located on nonglabrous skin that displays **any** of the aforementioned features. In addition, *lesions located on volar skin of the palms or soles displaying a parallel ridge pattern* and any *changing lesion in an adult patient* should also be considered suspicious for malignancy.

If **none** of the above features are present, and the lesion is *nonpalpable*, it can be monitored (see Chapter 13).

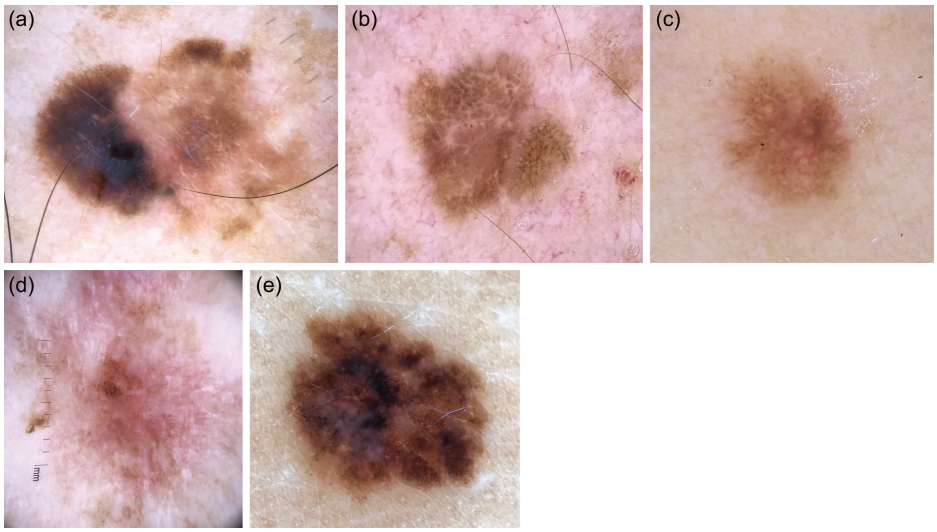

FIGURE 5B.6 Dermoscopic images of melanomas demonstrating a disorganized pattern, all of them revealing at least one melanoma-specific structure.

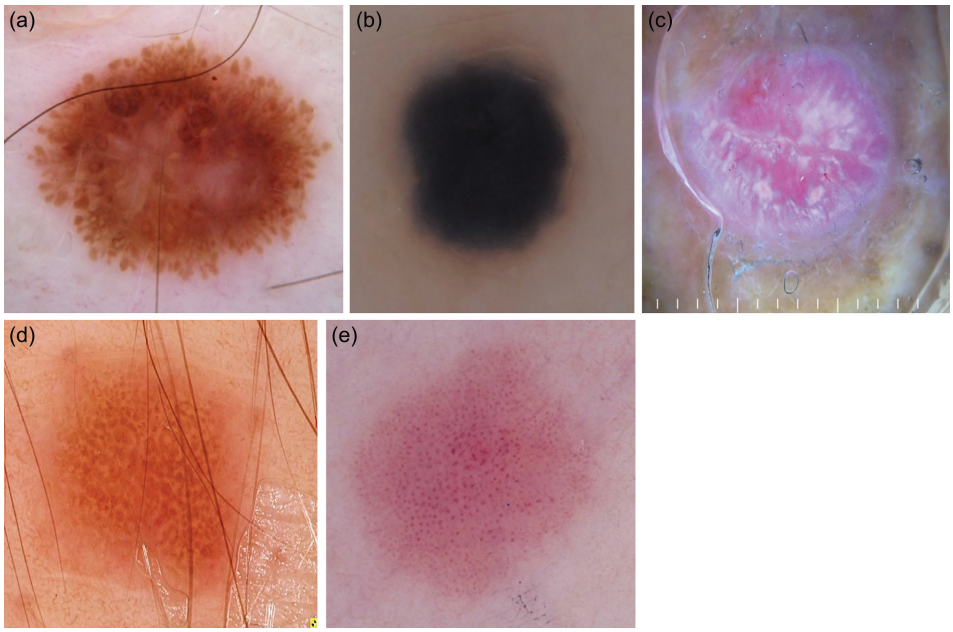

FIGURE 5B.7 Symmetric lesions revealing a starburst pattern (a), blue-black–gray color (b), shiny white structures seen with polarized dermoscopy (c), negative network (d), and vascular structures (e).



FIGURE 5B.8 Melanoma in situ. Dermoscopy reveals an irregular starburst pattern.

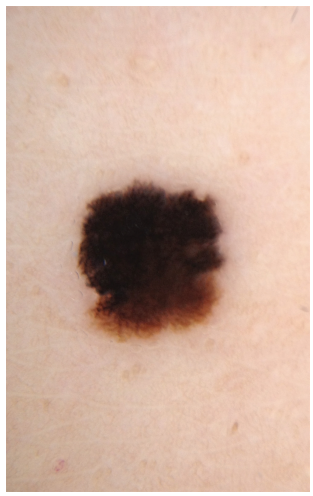

FIGURE 5B.10 This is a relatively symmetric melanoma, demonstrating dark brown and black color.

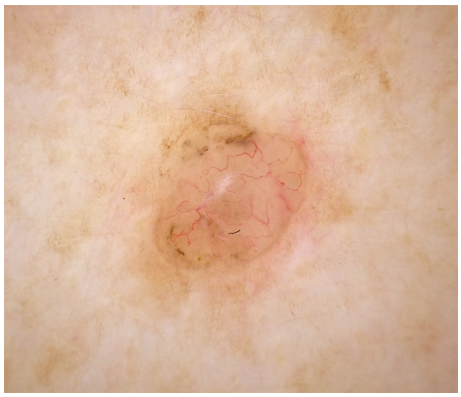

FIGURE 5B.9 This is a relatively symmetric basal cell carcinoma, demonstrating arborizing vessels.

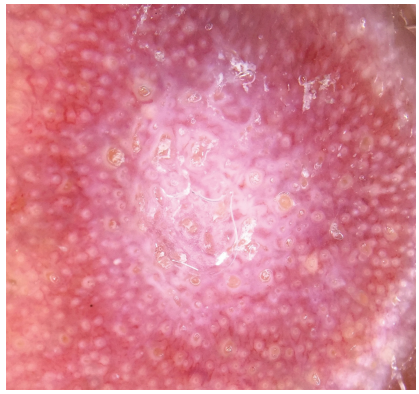

FIGURE 5B.11 Dermoscopy image of a symmetric squamous cell carcinoma, revealing white circles and scale.

References

1. Luttrell MJ, Hofmann-Wellenhof R, Fink-Puches R, Soyer HP. The AC Rule for melanoma: a simpler tool for the wider community. *J Am Acad Dermatol.* 2011;65(6):1233–4.
2. Stolz WRA, Cognetta A, Pillet L, Abmayr W, Holzel D, et al,. ABCD rule of dermoscopy: a new practical method for early recognition of maligant melanoma. *Eur J Dermatol.* 1994;4:521–17.
3. Zalaudek I, Argenziano G, Soyer HP, et al. Three-point checklist of dermoscopy: an open internet study. *Br J Dermatol.* 2006;154(3):431–7.
4. Argenziano G, Longo C, Cameron A, et al. Blue-black rule: a simple dermoscopic clue to recognize pigmented nodular melanoma. *Br J Dermatol.* 2011;165(6):1251–5.
5. Rosendahl C, Cameron A, McColl I, Wilkinson D. Dermatoscopy in routine practice - 'chaos and clues'. *Aust Fam Physician.* 2012;41(7):482–7.
6. Rogers T, Marino ML, Dusza SW, et al. A Clinical Aid for Detecting Skin Cancer: The Triage Amalgamated Dermoscopic Algorithm (TADA). *J Am Board Fam Med.* 2016;29(6):694–701.
7. Seiverling EV, Ahrns HT, Greene A, et al. Teaching Benign Skin Lesions as a Strategy to Improve the Triage Amalgamated Dermoscopic Algorithm (TADA). *J Am Board Fam Med.* 2019;32(1):96–102.
8. Seidenari S, Pellacani G, Martella A. Acquired melanocytic lesions and the decision to excise: role of color variegation and distribution as assessed by dermoscopy. *Dermatol Surg.* 2005;31(2):184–9.
9. Unified Dermoscopy Algorithm Study. in progress. Preliminary results.
10. Braun RP, Gaide O, Oliviero M, et al. The significance of multiple blue-grey dots (granularity) for the dermoscopic diagnosis of melanoma. *Br J Dermatol.* 2007;157(5):907–13.
11. Jaimes N, Marghoob AA, Rabinovitz H, et al. Clinical and dermoscopic characteristics of melanomas on nonfacial chronically sun-damaged skin. *J Am Acad Dermatol.* 2015;72(6):1027–35.
12. Balagula Y, Braun RP, Rabinovitz HS, et al. The significance of crystalline/chrysalis structures in the diagnosis of melanocytic and nonmelanocytic lesions. *J Am Acad Dermatol.* 2012;67(2):194.e191–8.
13. Liebman TN, Rabinovitz HS, Balagula Y, Jaimes-Lopez N, Marghoob AA. White shiny structures in melanoma and BCC. *Arch Dermatol.* 2012;148(1):146.
14. Pizzichetta MA, Talamini R, Marghoob AA, et al. Negative pigment network: an additional dermoscopic feature for the diagnosis of melanoma. *J Am Acad Dermatol.* 2013;68(4):552–9.

5C TRIAGE ALGORITHMS: OTHER DERMOSCOPIC ALGORITHMS IN SKIN CANCER TRIAGE

Natalia Jaimes

Contents

Algorithms for pigmented lesions . . . 86
The three-point checklist . . . 86
The AC rule . . . 86
The blue-black rule . . . 86
Chaos and Clues . . . 87
Algorithms for nonpigmented lesions . . . 89
Prediction without Pigment algorithm . . . 89
Algorithm for pigmented and nonpigmented lesions . . . 89
References . . . 89

Triage refers to the sorting out and classification of patients and lesions to determine priority of need and proper place of treatment. Triage can be performed during skin cancer screenings using dermoscopy. Dermoscopy enables identifying lesions that are suspicious for skin cancer and aiding in the correct management decision. Deciding whether or not to biopsy a skin lesion is paramount during screening, whereas making a specific diagnosis, such as differentiating between basal cell carcinoma (BCC), squamous cell carcinoma (SCC), and melanoma, is less important. For triage purposes, to decide which lesion(s) should be biopsied, several simplified dermoscopic algorithms have been proposed, most of which include asymmetry and color variation in their criteria[1–4] (Table 5c.1).

Algorithms for pigmented lesions

Algorithms for pigmented lesions include the three-point checklist, the AC rule, the blue-black rule, and Chaos and Clues. Overall, these algorithms have a sensitivity of between 78.2% and 92.9% and a specificity ranging from 64% to 92.3% for the diagnosis of *pigmented* skin cancers, including melanoma or BCC.[2, 5–7]

The three-point checklist

The three-point checklist was initially developed for nonexperts as a skin cancer screening tool. The three-point checklist has a high sensitivity for pigmented skin cancers, including pigmented BCC and melanoma (Table 5c.1). [1, 5] This checklist includes three dermoscopic features:

- Asymmetry of pattern and structures, defined as asymmetry in the distribution of dermoscopic color and/or structures in one or two perpendicular axes. The contour or silhouette of the lesion does not factor into whether the lesion is symmetric or not (Figures 5c.1 – 5c.6)
- Blue-white structures, defined as blue-white veil and/or white scarlike depigmentation and/or blue pepper-like granules (Figures 5c.2–5c.4)
- Atypical network, defined as pigment network with thick lines and irregular-sized holes (Figure 5c.5)

Asymmetry in the distribution of colors and structures within a lesion is considered the best predictor of malignancy, followed by blue-white structures and atypical network.[6] One point is assigned to each criterion present in the lesion. Lesions with a total score of two or three points are considered positive, and a skin biopsy or referral is recommended. The three-point checklist has a sensitivity of 79% to 91% and a specificity of 71–72% for the diagnosis of melanoma and BCC.[5, 6] Since the three-point checklist was not developed to identify pigmented SCC, it is recommended that any pigmented lesion with focal adherent keratin or a rough texture that reveals an asymmetric dermoscopic pattern be considered suspicious so as to avoid missing the diagnosis of a pigmented SCC (Figure 5c.7).

The AC rule

The AC rule was developed as a simple rule to identify lesions that may be suspicious for melanoma.[2] The AC rule uses two dermoscopic criteria:

- Asymmetry in the distribution of structures and colors (Figures 5c.1 – 5c.6)
- Color variation. Multiple colors within the lesion, with black or blue-gray color being most suggestive of melanoma (Figures 5c.2, 5c.3, 5c.6)

The AC rule has been tested in laypersons, demonstrating a sensitivity of 94% and a specificity of 62% for melanoma.[7]

The blue-black rule

The blue-black rule was proposed to identify pigmented nodular melanomas, which often appear as symmetric papules or nodules.[4] This rule is based on the presence of a *blue-black feature*, which is defined as the presence of a combination of blue and black areas involving at least 10% of the lesion surface area (Figures 5c.6, 5c.8, 5c.9) It is not counted or considered as a significant feature when unequivocal comedo-like openings, as found in seborrheic keratosis, or dark lacunae, as seen in angiokeratomas, occur with the blue-black background.

The blue-black rule demonstrated a sensitivity of 78.2% and a specificity of 80.5% for melanoma. This sensitivity for melanoma improved from 78.2% to 84.6% when the observer also sought to look for other melanoma-specific structures. Melanoma-specific structures are listed in Table 5c.1. In their study, Argenziano and colleagues evaluated the lesions for the presence of specific melanoma structures, including atypical

TABLE 5C.1: Dermoscopy Triage Algorithms

	Pigmented				Nonpigmented	Pigmented and nonpigmented
	3-point	AC rule	Blue-black rule	Chaos and Clues	Prediction without Pigment	TADA
Asymmetry	x	x		x		x
Color variation	x	x	x	x		x
Atypical network	x					x
Blue-white structures	x					x
Asymmetry	x	x		x		x
Blue-black colors (more than 10% of the lesion)			x			x
Ulceration					x	x
Shiny white structures					x	x
Keratin clues					x	x
Vascular pattern					x	x

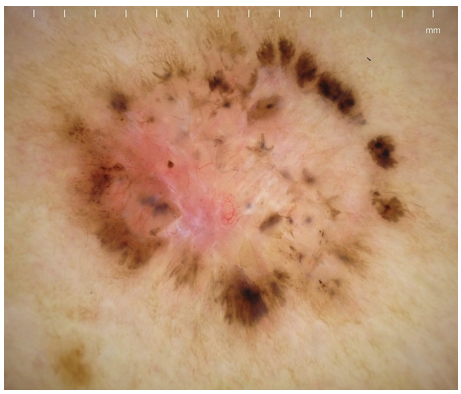

FIGURE 5C.1 Dermoscopy image of a pigmented basal cell carcinoma, revealing asymmetry in the distribution of structures and colors.

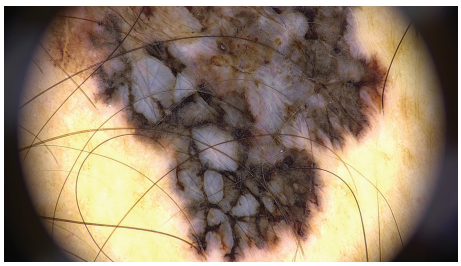

FIGURE 5C.2 Invasive melanoma: Dermoscopy demonstrates a blue-white veil and asymmetry in the distribution of structures and colors.

network, negative network, irregular streaks, regression structures, and irregular brown structureless areas.[4] Specificity for melanoma was 80.5% when using the blue-black rule only, 97.6% when using the classic melanoma-specific structures only, and 80.5% using both criteria (i.e., blue-black rule and classic melanoma structures). In addition to detecting nodular melanoma, the presence of blue-black color can also aid in the detection of other heavily pigmented skin malignancies, including pigmented nodular BCCs [4] (Figure 5c.9)

Chaos and Clues

This algorithm was also developed for the evaluation of pigmented skin lesions and is discussed in Chapter 5a.[3]

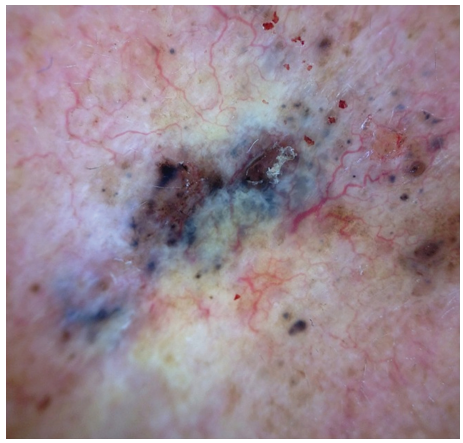

FIGURE 5C.3 Basal cell carcinoma on the L cheek of female patient. Dermoscopy reveals blue-white structures, including blue-gray globules, and a white scarlike depigmentation. There is also asymmetry in the distribution of structures and colors.



FIGURE 5C.4 Basal cell carcinoma with blue-gray globules, shiny white structures, and asymmetry in the distribution of colors and structures.

Altogether, these four algorithms were developed to aid in the diagnosis of pigmented skin cancer, including melanoma and pigmented BCC; however, they will not help in

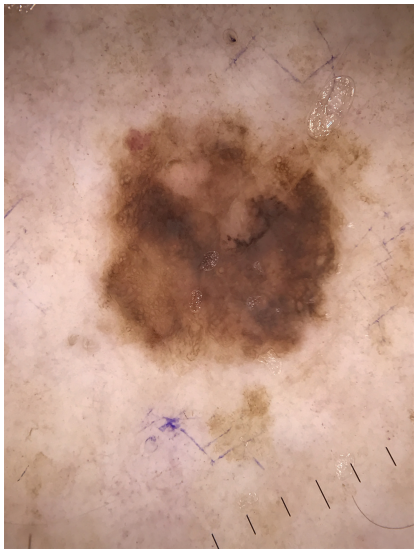

FIGURE 5C.5 Melanoma in situ demonstrating an atypical network under dermoscopy, with thickened lines and irregular holes.

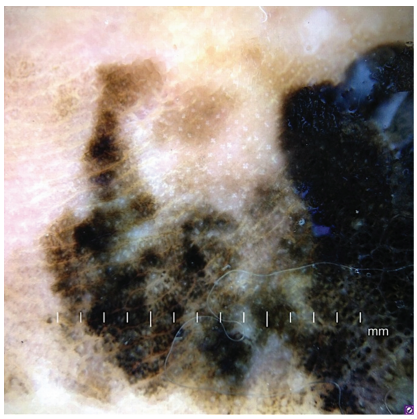

FIGURE 5C.6 Acral melanoma. Dermoscopy reveals asymmetry in structures and colors, with multiple colors, but black and blue-gray color being predominant.



FIGURE 5C.7 Pigmented squamous cell carcinoma in situ. Dermoscopy reveals a focal adherent keratin, with asymmetry in colors and structures.



FIGURE 5C.8 Dermoscopy image of a melanoma. A black color is observed in almost 90% of the surface area, and an atypical network towards the lower portion of the lesion.

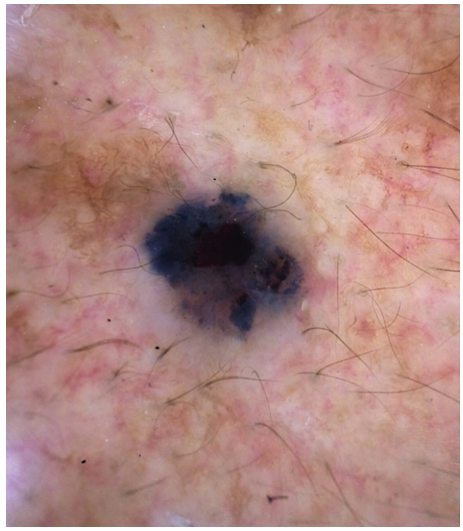

FIGURE 5C.9 Pigmented basal cell carcinoma. Dermoscopy reveals blue-black color in more than 10% of the lesion, corresponding to a blue-gray ovoid nest, blue-gray globules, and ulceration.



FIGURE 5C.10 Thrombosed hemangiomas, with red lacunae and a hemorrhagic crust.

the detection of any skin cancer devoid of pigment, and thus, amelanotic or hypomelanotic skin cancers may be missed. In addition, since the main purpose of these algorithms is not to miss a pigmented skin cancer, it is possible that some benign

pigmented lesions, such as thrombosed hemangiomas, angiokeratomas, or pigmented seborrheic keratosis, may be misclassified as suspicious and subjected to biopsy (Figure 5c.10).

Algorithms for nonpigmented lesions

Prediction without Pigment algorithm

This algorithm was created for the evaluation of amelanotic lesions and is discussed in Chapter 4c. [8]

Algorithm for pigmented and nonpigmented lesions

The Triage Amalgamated Dermoscopic Algorithm (TADA) was created as a relatively simple, easy-to-use and learn algorithm that can guide management decision in a skin cancer triage setting. TADA is discussed in Chapter 5b.

References

1. Soyer HP, Argenziano G, Zalaudek I, et al. Three-point checklist of dermoscopy. A new screening method for early detection of melanoma. *Dermatology*. 2004;208(1):27–31.
2. Luttrell MJ, Hofmann-Wellenhof R, Fink-Puches R, Soyer HP. The AC Rule for melanoma: a simpler tool for the wider community. *J Am Acad Dermatol.* 2011;65(6):1233–4.
3. Rosendahl C, Cameron A, McColl I, Wilkinson D. Dermatoscopy in routine practice: 'chaos and clues'. *Aust Fam Physician*. 2012;41(7):482–7.
4. Argenziano G, Longo C, Cameron A, et al. Blue-black rule: a simple dermoscopic clue to recognize pigmented nodular melanoma. *Br J Dermatol.* 2011;165(6):1251–5.
5. Zalaudek I, Argenziano G, Soyer HP, et al. Three-point checklist of dermoscopy: an open internet study. *Br J Dermatol.* 2006;154(3):431–7.
6. Argenziano G, Puig S, Zalaudek I, et al. Dermoscopy improves accuracy of primary care physicians to triage lesions suggestive of skin cancer. *J Clin Oncol.* 2006;24(12):1877–82.
7. Luttrell MJ, McClenahan P, Hofmann-Wellenhof R, Fink-Puches R, Soyer HP. Laypersons' sensitivity for melanoma identification is higher with dermoscopy images than clinical photographs. *Br J Dermatol.* 2012;167(5):1037–41.
8. Rosendahl C, Cameron A, Tschandl P, Bulinska A, Zalaudek I, Kittler H. Prediction without Pigment: a decision algorithm for non-pigmented skin malignancy. *Dermatol Pract Concept*. 2014;4(1):59–66.

6A NONMELANOCYTIC LESIONS: DERMATOFIBROMA

Silvia E. Mancebo and Michael A. Marchetti

Contents

Introduction 90
Dermoscopy light source and technique 90
Dermoscopic patterns 90
Dermatofibroma variants 91
Conclusion 95
References 96

A cutaneous dermatofibroma is a benign fibrohistiocytic tumor that may present with varied dermoscopic features based on the histologic subtype. Ten dermoscopic patterns of dermatofibromas have been reported. The most prevalent appearance is that of a delicate peripheral network surrounding a central white structureless patch that, when examined with polarized light, variably displays vessels and shiny white structures. Skin type/color, anatomic location, and secondary epidermal changes may influence the pattern visualized on dermoscopy. Variants such as the aneurysmal/hemosiderotic type are challenging to identify and mimic malignancy. Although most dermatofibromas can be reliably identified as benign tumors after clinical and dermoscopic examination, some lesions cannot be distinguished from melanoma and therefore warrant histological evaluation for diagnostic confirmation.

Introduction

Dermatofibroma is a benign proliferation of fibrohistiocytic cells, which may occur anywhere on the skin surface but has a predilection for the extremities of adults(1). Clinically, these tumors may present as single or multiple, round to ovoid, firm papules, plaques, or nodules, usually measuring <1 cm in diameter with variation in color from light to dark brown to purple and red. Characteristically, dimpling of these tumors occurs with lateral compression (i.e., dimple or Fitzpatrick sign) (1). Multiple clinical and histologic variants of dermatofibromas exist, and as such, the dermoscopic features of dermatofibromas vary (see Figures 6a.1–6a.26). It is most important to differentiate this benign neoplasm from melanoma and other cutaneous proliferations, including basal cell carcinoma, squamous cell carcinoma, and melanocytic nevi.

Dermoscopy light source and technique

Dermatofibromas appear different depending on the light source (polarized vs. nonpolarized) and dermoscopic technique (contact vs. noncontact) employed (see Figures 6a.2–6a.3, and 6a.19) (2). With contact dermoscopy, vasculature findings are less apparent, or not visualized at all, relative to noncontact dermoscopy. With polarized dermoscopy, shiny white structures are visualized, and the appearance of blood vessels is accentuated. Nonpolarized dermoscopy will accentuate superficial cutaneous features, such as ridges, fissures, comedo-like openings, milia-like cysts, or a mammillated surface. The reason for these differences is explained by the physical and optical properties of polarized and nonpolarized dermoscopy (see Chapter 2).

Dermoscopic patterns

Multiple dermoscopic features and patterns have been reported in dermatofibromas. The classically described presentation using nonpolarized dermoscopy is that of a central structureless white patch (previously termed scarlike area) surrounded by a delicate pigment network (see Figure 6a.5) (2–5). The pigment network histopathologically correlates to hyperpigmentation of basal layer keratinocytes situated along elongated rete ridges. The central structureless white patch corresponds to an attenuated epidermis overlying a fibrous histiocytic stroma in the papillary dermis (3, 6). The pigment network in a dermatofibroma is typically composed of thin, light to dark brown lines with a characteristic fine or lacey quality, which fades into the surrounding skin. Toward the center of the lesion, the pigment network may cease to look reticulated and instead may resemble "ring-like" globular or clod-like structures, which correspond to widely spaced, flattened and broad hyperpigmented rete ridges (7) surrounded by an attenuated epidermis (see Figure 6a.8) (5). These "ring-like" globules are characteristically round or oval, and their periphery is relatively darker than the center. Early descriptions of dermatofibromas reported the presence of a "white network"; this phenomenon is created when "ring-like" globules or small islands of pigmented rete ridges are surrounded by collagen (i.e., white structureless scarlike patch, shiny white structures). This so-called "white network appearance" can sometimes be difficult to differentiate from a negative network found in melanocytic tumors.

In a study of 412 dermatofibromas by Zaballos et al., pigment network was present in 72% of lesions (3). The majority of these cases displayed a typical delicate pigment network, but 3% of cases had an atypical or broadened pigment network. The pigment network was most often located in the periphery of the lesion (71%) and less often throughout the lesion (27%) or irregularly distributed (3%). In cases where the pigment network was atypical or irregularly distributed, the lesion was excised and histopathologically confirmed. In addition, 25% of dermatofibromas were found to have structureless pigmentation either at the periphery (55%), throughout the entire lesion (24%), in the center of the lesion (24%), or irregularly and multi-focally distributed (3%). Most often, the structureless pigmentation was brown in color, but occasionally, bluish or reddish-bluish colors were observed (3).

A central structureless white patch is the second most common feature found in dermatofibromas. The aforementioned study by Zaballos et al. reported that 57% of 412

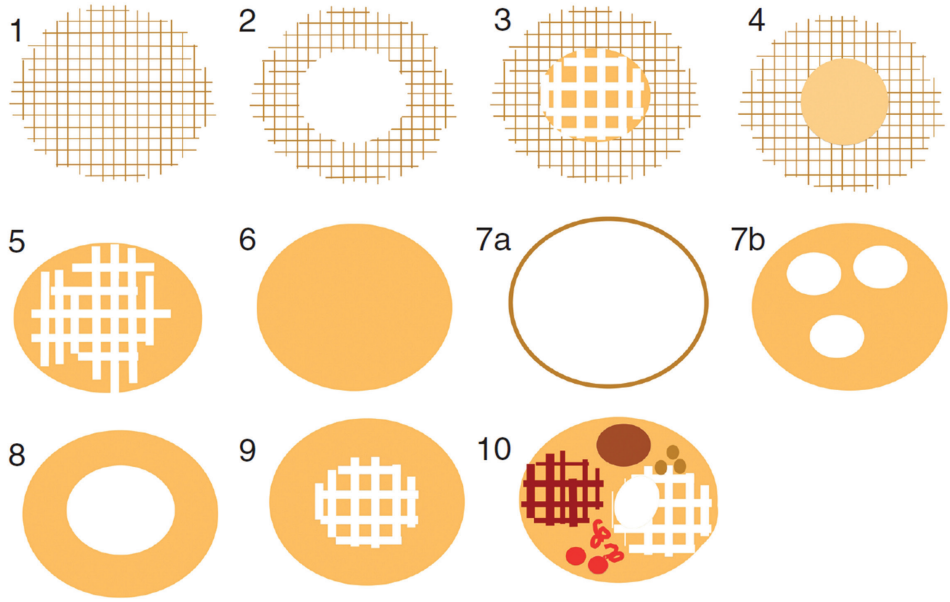

FIGURE 6A.1 Schematics of the different dermoscopic patterns in dermatofibromas.

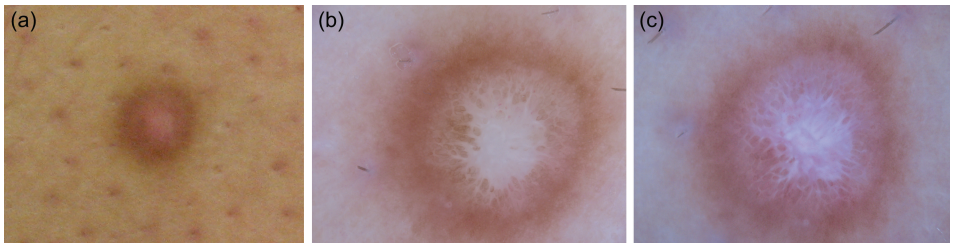

FIGURE 6A.2 (a) Clinical image of dermatofibroma. (b) Nonpolarized dermoscopy. The lesion displays central structureless white patch surrounded by delicate pigment network. The network located toward the center appears as "ring-like" globules. (c) Polarized dermoscopy. The central white patch appears brighter, has a pink hue, and reveals shiny white blotches and streaks.

dermatofibromas had a white scarlike area, and the most common presentation was that of a single, well-demarcated patch located in the lesional center (3). The authors less frequently observed multiple white scarlike patches (12%) or scarlike areas distributed throughout the lesion (10%) or irregularly distributed (3%) (3).

In addition to pigment network and structureless white areas, dermatofibromas can display a variety of vascular patterns, none of which are specific to the diagnosis of dermatofibroma. Described blood vessel morphologies include dotted, comma, hairpin, glomerular, and linear vessels. Multiple vessel morphologies may be present in the same lesion (i.e., polymorphous vessels), and at times, only structureless erythema (i.e., vascular blush) may be present (2–5). Vascular structures are most conspicuous with noncontact polarized dermoscopy. Less prevalent features include scale, ulceration/erosion, fissures, ridges, and a mammillated surface (see Figure 6a.16) (2).

Dermatofibromas have been classified into 10 global patterns, which can be grouped into those with and without a peripheral delicate pigment network (see Table 6a.1 and Figure 6a.1) (3). The most common pattern on the chest, back, arms, and legs is a delicate peripheral network with central structureless white patch (8). On the face and hands, however, a delicate network throughout the lesion is most often observed. Brancaccio et al. compared dermatofibromas on the trunk with those on the extremities and found that dermatofibromas on the trunk appear different from those situated on the extremities. The most common pattern on the trunk in their series was structureless pigmentation, whereas the most common pattern on the extremities was the central white structureless patch surrounded by delicate network (9). An individual's skin color/type can also influence the dermoscopic features present in dermatofibromas. A prospective study of 100 dermatofibromas in Fitzpatrick skin type IV–V found that the classic dermatofibroma pattern consisting of a peripheral network with central white structureless area was the most common subtype but was significantly less prevalent compared with previous studies examining individuals with lighter skin colors (10).

Dermatofibroma variants

Aneurysmal dermatofibroma is an uncommon but distinct histologic variant characterized by blood-filled spaces occupying up to one-half of the lesion and abundant hemosiderin in the surrounding stroma (1). This variant is often grouped with hemosiderotic dermatofibroma, which is considered to be an earlier stage in the development of the aneurysmal dermatofibroma. Dermoscopically, the most common appearance includes a central bluish or reddish structureless area with

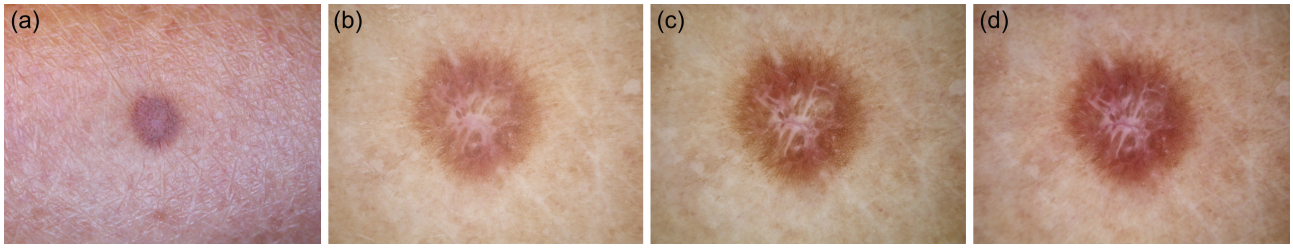

FIGURE 6A.3 (a) Clinical image of dermatofibroma. (b) Nonpolarized dermoscopy. The lesion displays central structureless white patch and "ring-like" globules surrounded by delicate pigment network. (c) Polarized contact dermoscopy. The central white patch appears brighter, and shiny white streaks are evident. (d) Polarized non-contact dermoscopy. The central white patch has a pink hue.

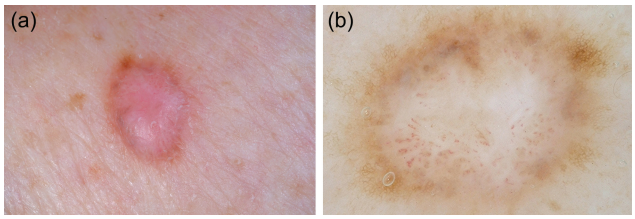

FIGURE 6A.4 (a) Clinical image of dermatofibroma. (b) Dermoscopy reveals central structureless white patch surrounded by delicate pigment network. Numerous blood vessels are present in the white patch.

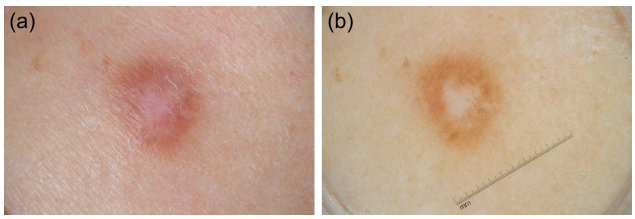

FIGURE 6A.5 (a) Clinical image of dermatofibroma. (b) Dermoscopy of classic dermatofibroma with peripheral delicate network and central structureless white patch.

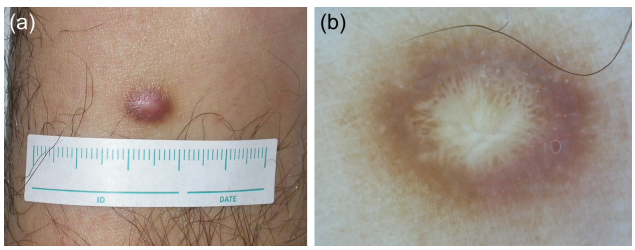

FIGURE 6A.6 (a) Clinical image of dermatofibroma. (b) Dermoscopy of classic dermatofibroma with peripheral delicate network and central structureless white patch. "Ring-like" globules are present at the perimeter of the white patch.

shiny white streaks and a delicate peripheral network with variable degrees of vascular structures (see Figures 6a.8-9, 6a.13, 6a.21, 6a.25) (11). Other features described in aneurysmal/hemosiderotic dermatofibromas include bluish to yellowish and red-brownish hues in the center of the tumor, a scaly surface, which may correlate to acanthosis or hyperkeratosis, and yellowish structureless areas at the periphery that likely correlate to hemosiderin or foamy histiocytes (11). In patients with Fitzpatrick skin type IV–V, a different dermoscopic feature

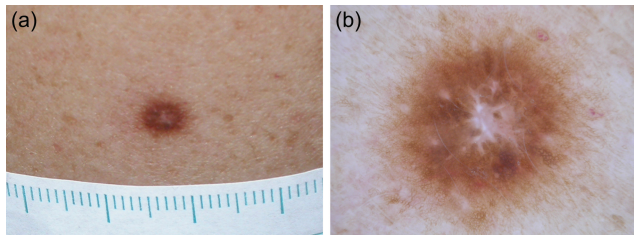

FIGURE 6A.7 (a) Clinical image of dermatofibroma. (b) Polarized dermoscopy of dermatofibroma with peripheral delicate network and central structureless white patch. Shiny white streaks are evident in the white patch.

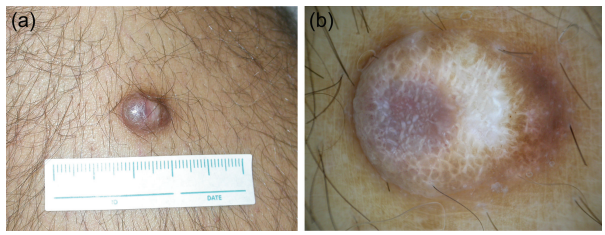

FIGURE 6A.8 (a) Clinical image of aneurysmal dermatofibroma. (b) Polarized dermoscopy reveals an atypical pattern composed of brown-red structureless area (*right*), central white patch, red-blue structureless area (*left*), and numerous shiny white streaks and blotches. Red-bluish structureless areas are typical of aneurysmal dermatofibromas. This lesion is unusual enough that a biopsy should be considered.

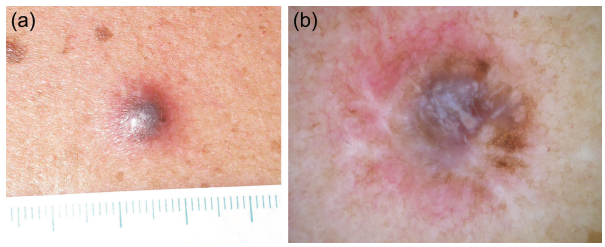

FIGURE 6A.9 (a) Clinical image of aneurysmal dermatofibroma. (b) Polarized dermoscopy reveals an atypical pattern composed atypical pigment network, central red-bluish structureless area, shiny white blotches and streaks, and a prominent peripheral vascular blush.

has been reported, namely, a white ring around a central ulceration (10). The authors hypothesized that the white ring may

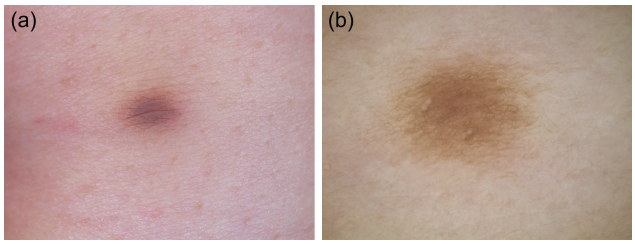

FIGURE 6A.10 (a) Clinical image of dermatofibroma. (b) Dermoscopy shows delicate pigment network throughout the lesion.

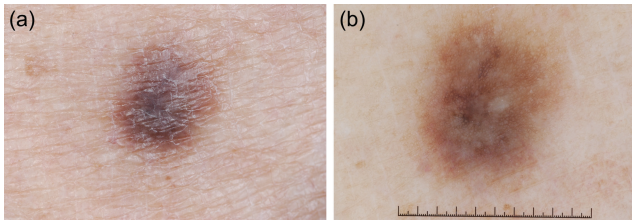

FIGURE 6A.11 (a) Clinical image of dermatofibroma. (b) Dermoscopy shows pigment network with variability in color throughout the lesion.

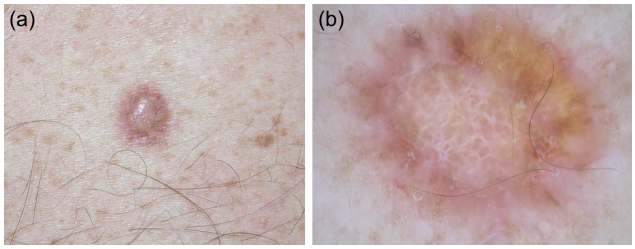

FIGURE 6A.12 (a) Clinical image of lipidized dermatofibroma.(b) Dermoscopy shows peripheral pigment network, shiny white streaks, and "ring-like" globules. A yellowish color is focally present at the periphery (*right*), which corresponds histopathologically to areas of lipidization with lipophages and Touton giant cells.

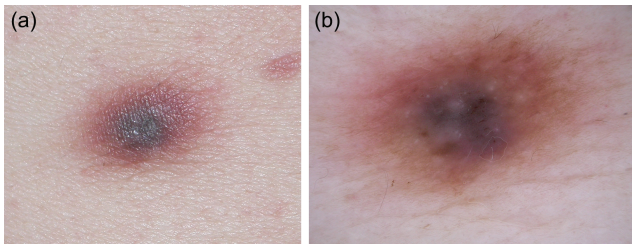

FIGURE 6A.13 (a) Clinical image of aneurysmal dermatofibroma. (b) Dermoscopy reveals peripheral network and central blue-violet structureless pigmentation, which can be mistaken for melanoma.

be explained by dermal fibrosis surrounding large blood-filled spaces and that at times, these hemorrhagic spaces may cause epidermal ulceration (10). Given that none of these dermoscopic features are specific, the authors of the aforementioned studies recommended histopathologic evaluation of suspicious tumors, as melanoma cannot be confidently ruled out (10, 11).

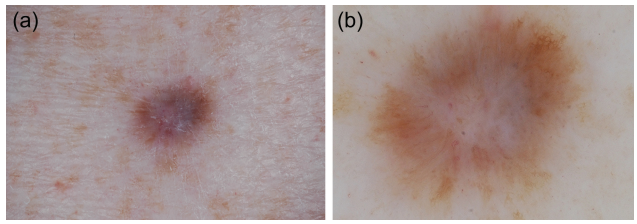

FIGURE 6A.14 (a) Clinical image of dermatofibroma. (b) Dermoscopy shows focal areas of thickened pigment network and multiple blood vessels. These features can also be seen in melanoma.

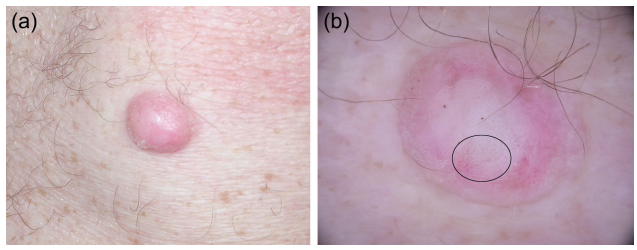

FIGURE 6A.15 (a) Clinical image of dermatofibroma. (b) Dermoscopy shows nonpigmented lesion with vascular blush and dotted vessels (black circle).

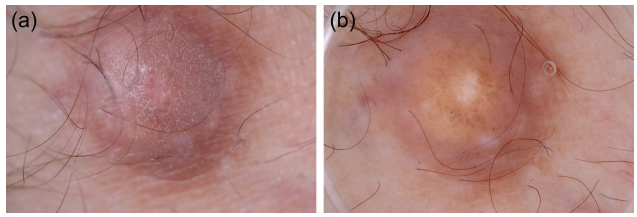

FIGURE 6A.16 (a) Clinical image of a dermatofibroma with mammillated surface. (b) Dermoscopy shows that the region of the lesion that clinically appears mammillated is composed of "ring-like" globules.

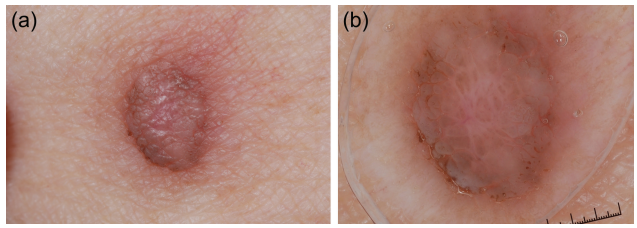

FIGURE 6A.17 (a) Clinical image of a dermatofibroma with mammillated surface. (b) Dermoscopy shows fissures (sulci) and ridges, which are more commonly associated with seborrheic keratosis.

Atrophic dermatofibromas are clinically flat, atrophic, or indented papules or plaques. Histopathologically, these tumors show a reduction in the thickness of the dermis as well as a reduction in the number of elastic fibers (12). Dermoscopically, these lesions are characterized by a patchy delicate network with multiple white structureless areas (10).

Dermatofibromas can present with superimposed epidermal changes, which may include acanthosis, hyperkeratosis,

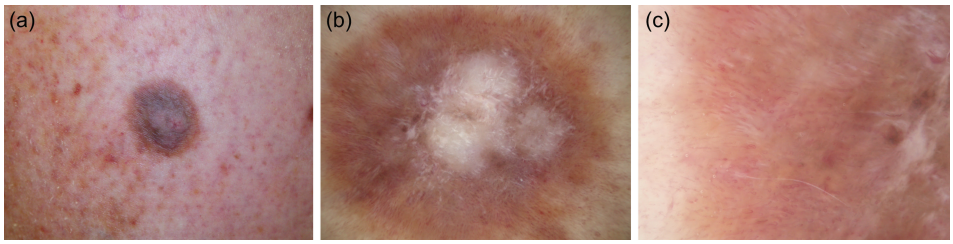

FIGURE 6A.18 (a) Clinical image of a 2-centimeter dermatofibroma. (b) Dermoscopy reveals peripheral brown structureless areas, central white patch with shiny white blotches and streaks, pink hue, and atypical vessels. (c) The dermoscopy features described in image (b) are highlighted in this magnified image of the left aspect of the same lesion.

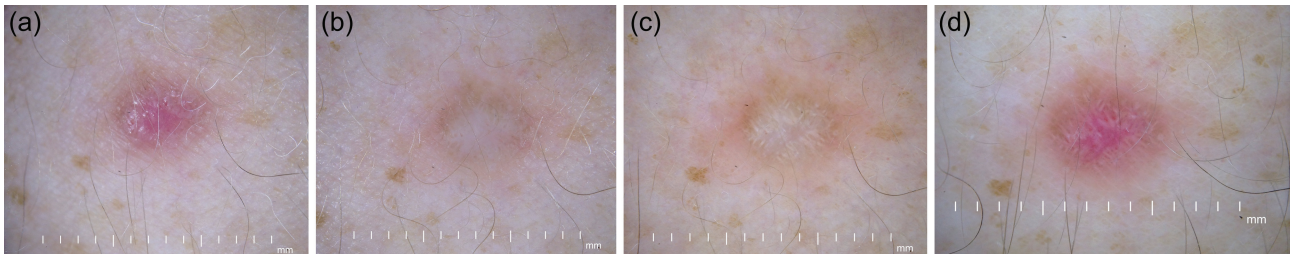

FIGURE 6A.19 (a) Clinical image of dermatofibroma. (b) Nonpolarized dermoscopy. The lesion displays peripheral tan structureless color and central white structureless patch with "ring-like" globules. (c) Polarized contact dermoscopy. The lesion now shows prominent shiny white streaks. (d) Polarized noncontact dermoscopy. Elimination of contact of the dermatoscope reveals prominent vascular blush and dotted vessels.

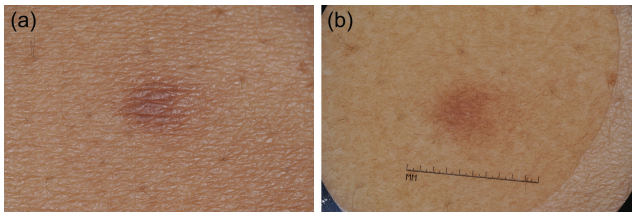

FIGURE 6A.20 (a) Clinical image of dermatofibroma in dark-skinned individual. (b) Dermoscopy reveals network diffusely throughout the lesion and a pink hue.

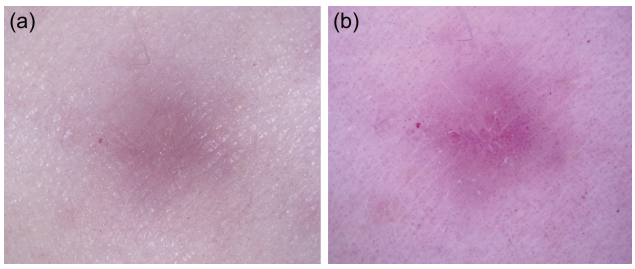

FIGURE 6A.22 (a) Clinical image of dermatofibroma in a skin type I individual with red hair. (b) Dermoscopy reveals a nonpigmented lesion with dotted vessels and shiny white streaks. The differential diagnosis of this lesion includes Spitz nevus and amelanotic melanoma. The presence of a dimple sign with lateral pressure and additional dermatofibromas with the same morphology in this patient aid the clinical diagnosis.

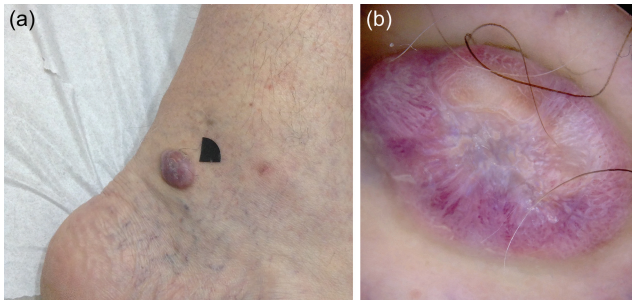

FIGURE 6A.21 (a) Clinical image of hemosiderotic dermatofibroma. (b) Dermoscopy reveals an atypical pattern with blue-red hue with numerous shiny white structures and polymorphous vessels.

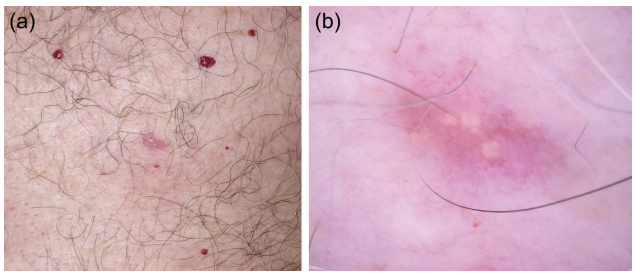

FIGURE 6A.23 (a) Clinical image of lipidized dermatofibroma. (b) Dermoscopy reveals a nonpigmented lesion with yellow clods.

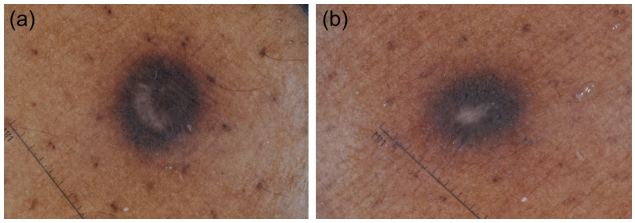

FIGURE 6A.24 (a) Dermoscopy image of dermatofibroma in skin type VI individual. The lesion shows peripheral delicate network, a gray central structureless patch, and numerous darkly pigmented "ring-like" globules. (b) Dermoscopy image of dermatofibroma in skin type VI individual (same individual as image a). The lesion shows peripheral delicate network, a gray central structureless patch, and numerous darkly pigmented "ring-like" globules.

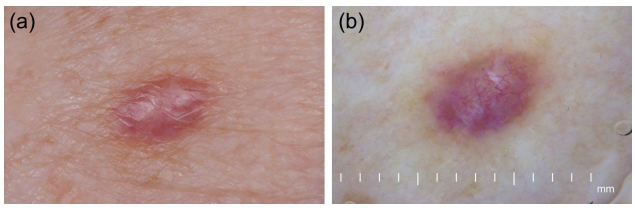

FIGURE 6A.25 (a) Clinical image of hemosiderotic dermatofibroma. (b) Dermoscopy reveals an atypical pattern with violaceous-blue structureless areas, peripheral brown pigment, shiny white blotches, and prominent branched vessels.

papillomatosis, and keratin-filled invaginations. Altogether, these features give rise to a ***dermatofibroma with seborrheic keratosis–like features*** (see Figure 6a.17). Dermoscopically, these tumors may present with ridges and fissures, comedo-like openings, and milia-like cysts (13, 14). In addition to seborrheic keratosis–like features, these lesions may feature variable degrees of peripheral network, white structureless areas, and "ring-like" globules (14).

Lipidized dermatofibromas histopathologically contain scattered cells with foamy cytoplasm; dermoscopically, these tumors have been reported to have yellowish structureless pigmentation in all cases (15). Of 13 cases, 5 had a total yellowish structureless pattern, 5 had an atypical pattern, and 3 had a central white patch with peripheral delicate network pattern (15). Dermatofibroma with sebaceous induction or overlying sebaceous hyperplasia has been reported to display whitish or white-yellow lobules (16, 17).

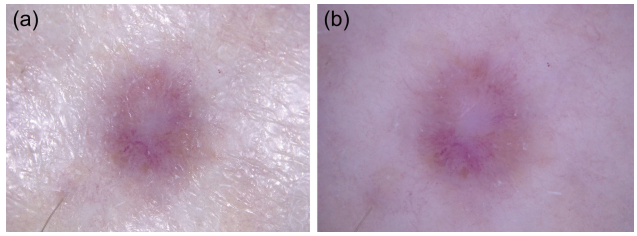

FIGURE 6A.26 (a) Clinical image of dermatofibroma in a skin type I individual with red hair. (b) Dermoscopy reveals a nonpigmented lesion with central white patch and shiny white streaks surrounded by polymorphous vessels and focal areas of brown pigmentation. The differential diagnosis of this lesion includes hypomelanotic melanoma, but the overall pattern is typical of dermatofibroma in fair-skinned individuals. The presence of a dimple sign with lateral pressure or additional dermatofibromas with the same morphology would aid the clinical diagnosis.

Conclusion

In conclusion, a cutaneous dermatofibroma is a benign fibrohistiocytic tumor that may present with varied dermoscopic features. The most prevalent pattern is that of a delicate peripheral network surrounding a central white structureless patch that variably displays vessels and shiny white structures with polarized light. Skin type/color, anatomic location, and secondary epidermal changes may affect the pattern visualized on dermoscopy. Less common presentations of dermatofibromas include hemosiderotic/aneurysmal, atrophic, and seborrheic keratosis–like types. Although most dermatofibromas can be reliably identified as benign tumors after clinical and dermoscopic examination, there are some dermatofibromas that cannot be distinguished from melanoma and therefore warrant histological evaluation for diagnostic confirmation.

TABLE 6A.1: Dermoscopic Patterns of Dermatofibromas

Pattern	Description of Structures	Prevalence[a] (%)
1	Delicate pigment network throughout	15
2	Peripheral delicate pigment network and central white structureless patch	35
3	Peripheral delicate pigment network and central white structureless patch with "ring-like" globules	9
4	Peripheral delicate pigment network and central homogeneous pigmentation	5
5	Central white structureless patch with "ring-like" globules	2
6	Structureless pigmentation throughout	5
7a	White structureless patch throughout	6
7b	Multiple focal white structureless patches	6
8	Peripheral structureless pigmentation and central white structureless patch	7
9	Peripheral structureless pigmentation and central white structureless patch with "ring-like" globules	5
10	Atypical	6

Source: Adapted from Zaballos, P., et al., *Arch Dermatol*, 144(1), 75–83, 2008.
[a] Numbers do not add to 100% due to rounding.

References

1. Weedon D, Strutton G, Rubin AI, Weedon D. *Weedon's Skin Pathology*. Edinburgh: Churchill Livingstone/Elsevier; 2010.
2. Agero AL, Taliercio S, Dusza SW, Salaro C, Chu P, Marghoob AA. Conventional and polarized dermoscopy features of dermatofibroma. *Arch Dermatol*. 2006;142(11):1431–7.
3. Zaballos P, Puig S, Llambrich A, Malvehy J. Dermoscopy of dermatofibromas: a prospective morphological study of 412 cases. *Arch Dermatol*. 2008;144(1):75–83.
4. Arpaia N, Cassano N, Vena GA. Dermoscopic patterns of dermatofibroma. *Dermatol. Surg*. 2005;31(10):1336–9.
5. Ferrari A, Argenziano G, Buccini P, et al. Typical and atypical dermoscopic presentations of dermatofibroma. *J Eur Acad Dermatol Venereol*. 2013;27(11):1375–80.
6. Puig S, Romero D, Zaballos P, Malvehy J. Dermoscopy of dermatofibroma. *Arch Dermatol*. 2005;141(1):122.
7. Scope A, Ardigo M, Marghoob AA. Correlation of dermoscopic globule-like structures of dermatofibroma using reflectance confocal microscopy. *Dermatology*. 2008;216(1):81–2.
8. Senel E, Yuyucu Karabulut Y, Dogruer Senel S. Clinical, histopathological, dermatoscopic and digital microscopic features of dermatofibroma: a retrospective analysis of 200 lesions. *J Eur Acad Dermatol Venereol*. 2015;29(10):1958–66.
9. Brancaccio G, Nuzzo T, DIMR, et al. Dermatofibroma looks dermoscopically different on trunk versus extremities. *G Ital Dermatol Venereol*. 2017;152(4):333–7.
10. Kelati A, Aqil N, Baybay H, Gallouj S, Mernissi FZ. Beyond classic dermoscopic patterns of dermatofibromas: a prospective research study. *J Med Case Rep*. 2017;11(1):266.
11. Zaballos P, Llambrich A, Ara M, Olazaran Z, Malvehy J, Puig S. Dermoscopic findings of haemosiderotic and aneurysmal dermatofibroma: report of six patients. *Br J Dermatol*. 2006;154(2):244–50.
12. Mota AN, Tortelly VD, Obadia DL, Silva RS. Atrophic dermatofibroma. *An Bras Dermatol*. 2013;88(5):793–5.
13. Barroso DH, Leite CP, Araujo GD, Teixeira MA, Alencar ER, Cavalcanti SM. Dermatofibroma simulating seborrheic keratosis dermoscopically. *An Bras Dermatol*. 2016;91(3):354–6.
14. Piccolo V, Mascolo M, Russo T, Russo D, Baroni A. Dermatofibroma with seborrheic keratosis-like changes: a dermoscopic challenge. Diagnosis: dermatofibroma with seborrheic keratosis-like changes. *J Am Acad Dermatol*. 2014;71(4):e123–4.
15. Zaballos P, Mir-Bonafe JF, Aviles JA, Banuls J. Dermoscopy of lipidised dermatofibroma: a morphological study of 13 cases. *Australas J Dermatol*. 2018.
16. Toyoshima A, Osada SI, Umebayashi Y, Manabe M. Dermoscopic features of dermatofibroma with overlying sebaceous hyperplasia. *J Dermatol*. 2017;44(5):548–9.
17. Monteagudo B, Figueroa-Silva O, Suarez-Amor O, Alvarez JC. Clinical, dermoscopic, and histopathologic features of a dermatofibroma with sebaceous induction. *Actas Dermo-Sifiliogr*. 2017;108(9):874–6.

6B NONMELANOCYTIC LESIONS: BASAL CELL CARCINOMA

Cristian Navarrete-Dechent, Konstantinos Liopyris, and Ashfaq A. Marghoob

Contents

Introduction . . . 97
Diagnostic accuracy of dermoscopy . . . 97
Dermoscopic structures associated with BCC . . . 97
Dermoscopic structures seen in pigmented BCCs . . . 97
Dermoscopic structures seen in pigmented or nonpigmented BCC . . . 99
Histologic subtype prediction using dermoscopy . . . 101
Treatment selection and monitoring . . . 101
References . . . 101

Introduction

Basal cell carcinoma (BCC) is the most common cutaneous malignancy of humankind [9], and its incidence is on the rise. Over 2 million cases of BCC are diagnosed annually in the United States alone [3, 14, 16, 18]. While the mortality rate associated with BCC is negligible, they can be associated with significant morbidity, especially if the tumors are located in cosmetically or functionally sensitive areas such as the eyelids or if the tumors are allowed to grow to a large size. The goal of screening individuals at risk for developing BCC is to find these tumors while their diameter is as small as possible. The routine use of dermoscopy has greatly improved our ability to detect small-diameter BCCs, since the criteria used in rendering a diagnosis of BCC are the same in large as well as tiny tumors. The "classic" dermoscopic structures associated with BCC were first described by Menzies et al. in 2000 [10]. Since then, the list of structures associated with BCC has expanded, and this in turn has enhanced our ability to detect BCC, including those lacking the "classic" features described by Menzies in 2000. Furthermore, the presence or absence of specific structures can also be used to help predict BCC subtype, which in turn can help in management decisions.

Diagnostic accuracy of dermoscopy

Clinically, BCC can present with a variety of morphologies ranging from erythematous macules to ulcerated nodules. While most BCCs are pink lesions, some BCCs can display pigment within the lesion and based on the degree of pigmentation, can mimic melanomas or other pigmented lesions when examined with the naked eye alone. Fortunately, the use of dermoscopy has improved the diagnostic accuracy and confidence of clinicians for both pigmented and nonpigmented BCCs. Studies comparing naked eye and dermoscopy sensitivity and specificity for diagnosing BCC found that dermoscopy had a higher sensitivity (85.0% vs 66.9%) and specificity (97.2% vs 98.2%) [15]. The sensitivity was higher for pigmented BCC compared with nonpigmented BCC (91.3% vs 84.3%). In addition, the specificity was also found to be higher for pigmented compared with nonpigmented BCC (99% vs 73.2%). This difference between pigmented and nonpigmented BCC is mainly due to the higher specificity associated with pigmented structures seen with the dermatoscope (see later) [15].

Dermoscopic structures associated with BCC (Table 6b.1)

The first formal study investigating the dermoscopic features associated with pigmented BCC was performed by Menzies et al. [10]. They found that pigmented BCCs lacked features found in melanocytic tumors, such as a network, and instead revealed at least one of the following structures: (1) multiple blue-gray (nonaggregated) globules; (2) large blue-gray ovoid nests; (3) leaf-like structures; (4) spoke-wheel structures, (5) arborizing telangiectasia; and (6) ulceration. A subsequent study described variants of the "classic" criteria, including "short-fine telangiectasia" (variant of arborizing vessels), "multiple small erosions" (variant of ulceration), "concentric structures" (variant of spoke-wheel structures), and "in-focus dots" (variant of blue-gray globules) [1]. In addition to the "classic" features of BCC and their variants, two other structures have proven helpful in diagnosing BCC, including "shiny white blotches and strands" seen only with polarized light dermoscopy, and "multiple aggregated yellow-white globules" (MAY globules) [11, 13].

Dermoscopic structures seen in pigmented BCCs

The first group of structures we will describe are the blue-gray dots, blue-gray globules, and ovoid nests. These structures correspond to variants of BCC tumor islands containing melanin pigment [19]. The distinction between these structures is dependent on their size relative to each other and relative to the surface area of the tumor. Whereas blue-gray ovoid nests encompass >10% of the surface area of the tumor, blue-gray globules encompass less than 10% of the tumor's surface area.

1. *Multiple blue-gray dots:* Blue-gray dots consist of well-defined, in-focus, pinpoint-sized structures that are smaller than globules. They usually appear in a random "bird-shot" scatter distribution. These dots correspond to tiny superficial pigmented BCC tumor islands. In the absence of blue-gray globules, ovoid nests, arborizing vessels, and ulceration, their presence is highly suggestive of superficial BCC (Figure 6b.1).
2. *Multiple blue-gray nonaggregated globules:* Unlike globules seen in melanocytic lesions, which are usually found in aggregates of three or more, the globules in BCC tend not to aggregate. In addition, while globules in melanocytic lesions are usually brown to black in color,

DOI: 10.1201/9780429487873-11

TABLE 6b.1: Sensitivity and Specificity of Dermoscopic Structures for Pigmented Basal Cell Carcinomas[a]

Features	Sensitivity (%)	Specificity (%)[b]
Large blue-gray ovoid nests	55	97/99
Arborizing telangiectasia	52	77/92
Multiple blue-gray globules	27	87/97
Ulceration	27	87/97
Leaf-like structures	17	100/100
Spoke wheel–like structures	10	100/100
Shiny white blotches and strands	30%	91%[c]
Multiple aggregated yellow-white (MAY) globules	21%	99%[c]

[a] The diagnosis of a pigmented BCC is made when a lesion lacks a pigment network and has one or more of the specific features tabled. This method gives a sensitivity of 93% and specificity of 89–92% for the diagnosis of pigmented BCC.
[b] The specificity represents the percentage of melanomas (left number) or benign pigmented skin lesions (right number) lacking that feature.
[c] No specific analysis between melanomas/benign pigmented lesions.
Abbreviation: BCC, basal cell carcinoma.

the globules in BCC tend to have a blue-gray color. The blue-gray globules in BCC are well-defined round to oval structures, larger than dots but smaller than large ovoid nests. They correlate with pigmented tumor islands on histopathology. These blue-gray globules are associated with early nodular BCC (Figure 6b.1).

3. *Large blue-gray ovoid nests:* These are nonaggregated round to oval structures that are usually situated in a background that is relatively hypopigmented. Despite initially being described as 'blue-gray' in color, they can be brown or even pink in color. There exists a size continuum from large ovoid nests to smaller globules, but no clear cut-off points have been defined to separate nests from globules. We use >10% of the lesion surface area size as a reference to dichotomize these structures into nests or globules. In other words, if the structure encompasses >10% of the lesion's surface area, it is classified as an ovoid nest, and if it is smaller, then it is classified as a nonaggregated globule. Since the separation of nests from nonaggregated globules is based on a relative size scale based on the size of the lesion, and since the histopathology correlation for both structures is the same, perhaps it would make sense to consider ovoid nests and nonaggregated globules as one and the same entity [12]. This condensation of terminology can be justified based on dermoscopy–histopathology correlations; both ovoid nests and nonaggregated bluish globules correlate with nodular BCC tumor islands on histopathology (Figure 6b.1).

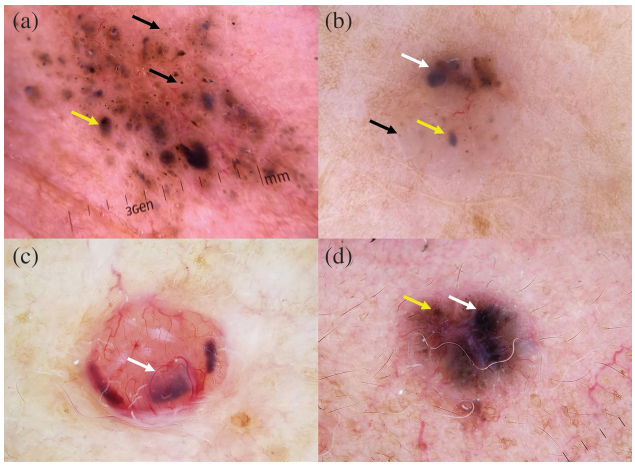

FIGURE 6B.1 Basal cell carcinomas showing in-focus dots, blue-gray globules, and ovoid nests. (a) In-focus dots (black arrows) and blue-gray globules (yellow arrow). (b) In-focus dots (black arrow), blue-gray globules (yellow arrow), and ovoid nest (white arrow). (c) Ovoid nest (white arrow). (d) Blue-gray globules (yellow arrow) and ovoid nest (white arrow). (Original magnification 10×, polarized light.)

The next group of pigmented structures we will describe are leaf-life structures, spoke-wheel structures, and concentric globules. It is not surprising to see significant morphologic overlap between these structures, since they all correspond to pigmented superficial BCC. Thus, in the absence of ovoid nests, arborizing vessels, and ulceration, the presence of leaf-like structures, spoke-wheel structures, and/or concentric globules is highly suggestive, if not diagnostic, of pigmented superficial BCC with a specificity of 100%.

4. *Leaf-like structures.* These structures consist of linear to bulbous projections that converge towards an off-center base. They are usually brown to gray-blue in color. Leaf-like areas created by linear extensions can sometimes be mistaken for streaks seen in melanocytic lesions. However, streaks in melanocytic lesions tend to be sharply focused extensions located at the lesion's perimeter, and they radiate outwards towards normal skin in a direction pointing away from the main tumor mass. In addition, streaks in a melanocytic lesion appear to converge towards the geometric center of the lesion, which is often hyperpigmented with a blue-white veil. In contrast, the extensions seen in leaf-like and spoke-wheel structures tend to be broader and less sharply in focus. They do not necessarily have to be located at the lesion's perimeter, and they do not always radiate away from the main tumor mass toward normal skin. In other words, the individual lines or bulbous projections in leaf-like structures can point towards the lesion's center. In addition, the extensions seen in BCC converge at an off-center base, which is usually not the geometric center of the lesion. Also, the geometric centers of BCCs

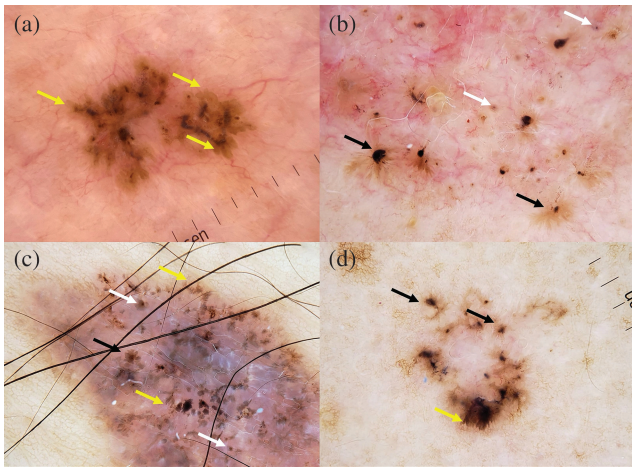

FIGURE 6B.2 Basal cell carcinomas showing leaf-like structures, spoke-wheel areas, and concentric structures. (a) Leaf-like structures (yellow arrows). (b) Spoke-wheel areas (black arrows) and concentric structures (white arrows). (c) Leaf-like structures (yellow arrows), spoke-wheel areas (black arrows), and concentric structures (white arrows). (d) Leaf-like structures (yellow arrows) and spoke-wheel areas (black arrows). (Original magnification 10×, polarized light.)

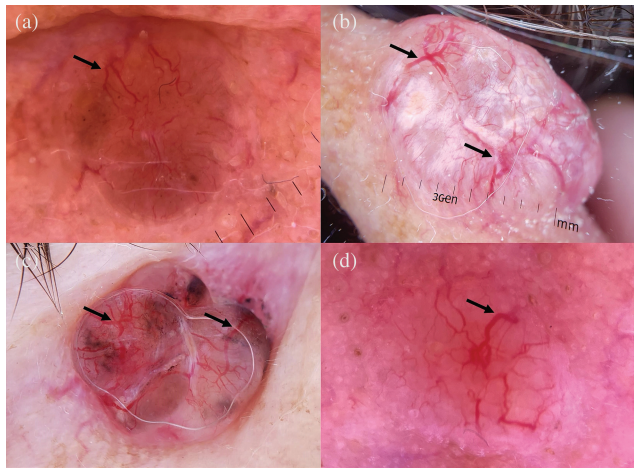

FIGURE 6B.3 Basal cell carcinomas showing arborizing vessels. (a–d) Arborizing vessels (black arrows). Note that vessels are sharply in focus. (Original magnification 10×, polarized light.)

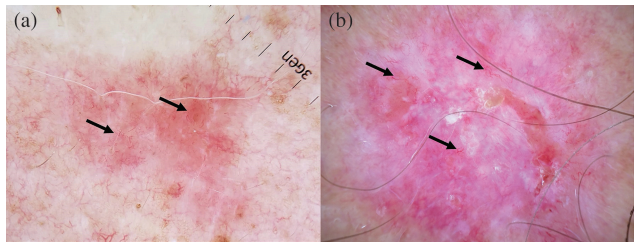

FIGURE 6B.4 Basal cell carcinomas showing short-fine telangiectasia. (a, b) Short-fine telangiectasia (black arrows). These fine vessels are also seen in focus. (Original magnification 10×, polarized light.)

displaying leaf-like areas are often hypopigmented and relatively structureless. Leaf-like structures correlate with pigmented BCC tumor budding from the epidermis [19] (Figure 6b.2).

5. *Spoke wheel–like structures/concentric globule.* Spoke-wheel structures consist of radial projections that converge at a central base. The central hub/base is often darker in color compared with the radial projections. The radial projections have a brown, blue, or gray color, and the central point or hub is usually darker brown, blue, or black in color. At times, the radial projections are not well defined, and the spoke wheel–like structure manifest as brownish globules with a central darker hub; this particular variant of spoke-wheel structures is termed "concentric structures." Similarly to the leaf-like structures, the spoke wheel–like structures have been associated with a 100% specificity for the diagnosis of BCC. On histopathology, the spoke wheel–like/concentric globule structure corresponds to pigmented BCC tumor islands budding off the epidermis (Figure 6b.2).

Dermoscopic structures seen in pigmented or nonpigmented BCC

6. *Arborizing telangiectasia/short-fine telangiectasia:* BCC can display a myriad of vessel morphologies, ranging from large-caliber branching vessels called arborizing vessels, to thin linear vessels called short-fine telangiectasia, to coiled to looped vessels. However, the most specific of all vessel morphologies in nodular BCC is the arborizing vessel, and the most common vessels seen in superficial BCC are short-fine telangiectasias. Arborizing vessels consist of large-caliber vessels that branch into smaller-caliber vessels in a "tree-like" or "arborizing" pattern. They are typically sharply in focus, bright red in color, and appear to traverse the skin superficially. Arborizing vessels likely represent the neoangiogenic vessels that surround dermal BCC tumor islands, and thus, their presence suggests that the BCC is of the nodular subtype (Figure 6b.3). In contrast, superficial BCC usually reveal very thin-caliber vessels with a linear undulating to branching morphology (Figure 6b.4). While thin linear vessels can also be seen in amelanotic superficial spreading melanoma, almost all superficial BCCs displaying such vessels will also reveal shiny white blotches or stands when viewed with polarized light dermoscopy (see later), whereas amelanotic superficial melanoma will usually reveal no shiny white structures or will reveal short shiny white lines. It is important to underscore that the vessel morphologies manifest by lesions should always be viewed in the context of the clinical morphology, history, and associated dermoscopic structures. This is exemplified by two benign lesions that are often confused with BCC. The first one is dome-shaped intradermal nevi (IDN) of the Miescher's type, which similarly to nodular BCC, can also display arborizing vessels. The second is pinkish macular lichen planus–like keratosis (LPLK) lesions that can be confused with superficial BCC by displaying fine-caliber telangiectasias. While history and accompanying dermoscopic structures such as globules or granularity (peppering) can assist in correctly identifying IDN and LPLK, respectively, it is not uncommon to biopsy these

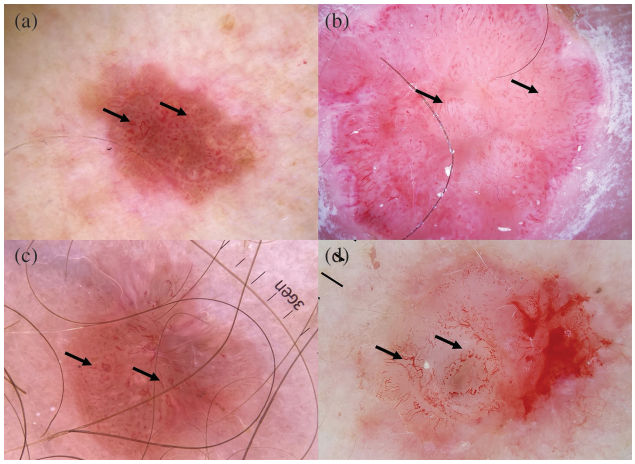

FIGURE 6B.5 Basal cell carcinomas on the legs showing polymorphous vessels. (a–d) Polymorphous vessels made of hairpin, serpentine, glomerular vessels (black arrows). (Original magnification 10×, polarized light.)

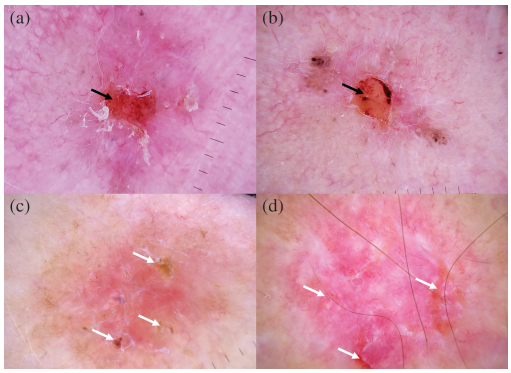

FIGURE 6B.6 Basal cell carcinomas showing ulcerations and multiple small erosions. (a, b) Ulcerations (black arrows). (c, d) Multiple small erosions (white arrows). (Original magnification 10×, polarized light.)

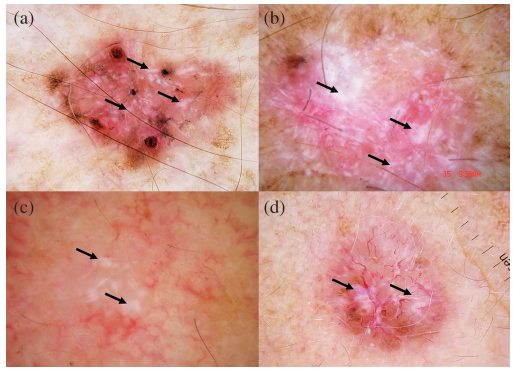

FIGURE 6B.7 Basal cell carcinomas showing blotches and strands. (a–d) Blotches and strands (black arrows). These structures are seen only with polarized light dermoscopy. (Original magnification 10×, polarized light.)

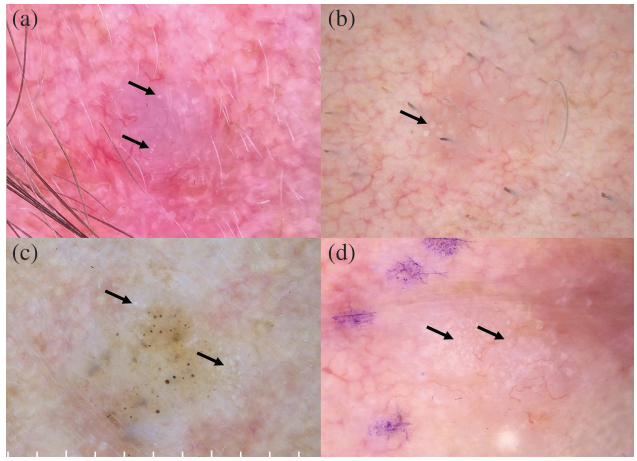

FIGURE 6B.8 Basal cell carcinomas showing multiple aggregated yellow-white (MAY) globules. (a–d) MAY globules (black arrows). (Original magnification 10×, polarized light.)

benign lesions with the aim of ruling out BCC [8]. One last point that requires emphasis regarding vessels seen in BCC is that the vessel morphology seen in BCCs on the lower extremity cannot be relied upon to make a diagnosis, since they usually reveal a nondescript polymorphous vascular pattern [17] (Figure 6b.5).

7. *Ulceration/erosions:* Both ulceration and erosions are associated with BCC. Ulceration, which corresponds to full-thickness loss of the epidermis, is associated with nodular BCC. They present as red to orange moist to sero-crusted areas (Figure 6b.6). In contrast, erosions are due to partial-thickness loss of the epidermis, and the presence of multiple small (1 mm or less in diameter) erosions is a feature associated with superficial BCC (Figure 6b.6). These erosions appear as well-demarcated sero-crusted areas within the BCC.

8. *Shiny white blotches and strands:* All structures in BCC can be visualized with either polarized or nonpolarized light dermoscopy, with the exception of shiny white blotches and strands (Figure 6b.7), which can only be seen with polarized light dermoscopy. The precise histopathology correlation of these structures remains to be elucidated, but preliminary work done by our group suggests that the shiny white blotches correspond to "pools" of mucin, and the strands correspond to an altered stroma in BCC. It is important to underscore that sometimes, the presence of shiny white blotches and strands can be the only structure visible within a BCC. One study showed that approximately 65% of nonpigmented BCCs lacked all diagnostic structures except for the presence of shiny white blotches and strands [11].

9. *Multiple aggregated yellow-white (MAY) globules:* MAY globules consist of multiple, aggregated, yellowish to whitish globules (Figure 6b.8). MAY globules are visible in both polarized and nonpolarized light, differentiating them from milia-like cysts, which are more conspicuous when viewed with nonpolarized light dermoscopy. The presence of MAY globules is associated with a sensitivity of 21% and specificity of 99% for BCC, and their presence indicates that the BCC is of either the nodular or the aggressive subtype. While MAY globules are not found in superficial BCC, they can be seen in over 50% of

infiltrative and morpheaform BCC and in approximately 20% of nodular BCC. MAY globules correlate with calcifications on histopathology [13].

Histologic subtype prediction using dermoscopy

The in vivo ability to predict the BCC subtype may assist in management decisions. The presence of leaf-like areas, spoke wheel–like structures, concentric globules, short-fine telangiectasia, and multiple small erosions are predictors of superficial BCC. In contrast, the presence of arborizing vessels, blue-gray ovoid nests, and ulceration are predictors of nodular BCC [7]. As was already mentioned, the presence of MAY globules suggests a higher-risk BCC subtype [13].

Treatment selection and monitoring

Dermoscopy can aid in the selection of BCCs amenable to treatment via noninvasive modalities. For example, the ability to diagnose superficial BCCs with dermoscopy permits one to consider empiric therapy with topical medications such as imiquimod. Also, it has been shown that the presence of pigmentation in a BCC portends a poor response of the tumor to photodynamic therapy (PDT) [4]. Since dermoscopy can aid in the detection of pigmented structures that are not visible to the naked eye, it can help select for PDT only those BCCs that lack any pigment on dermoscopy [2]. One study showed that dermoscopy was able to reveal clinically undetectable pigmentation in approximately 30% of nonpigmented BCCs, enabling physicians to better select patients for PDT [5, 6]. Finally, dermoscopy can help detect residual/recurrent BCC after noninvasive treatments. Specifically, the disappearance of all pre-treatment dermoscopic criteria predicts BCC clearance. The persistence or re-appearance of BCC criteria suggests persistence or recurrence of BCC [5].

References

1. Altamura D, Menzies SW, Argenziano G, et al. Dermatoscopy of basal cell carcinoma: morphologic variability of global and local features and accuracy of diagnosis. *J Am Acad Dermatol*. 2010;62(1):67–75.
2. Apalla Z, Lallas A, Sotiriou E, Ioannides D. Effect of pigmentation on photodynamic therapy. *Lancet Oncol*. 2013;14(9):e339–40.
3. Asgari MM, Moffet HH, Ray GT, Quesenberry CP. Trends in basal cell carcinoma incidence and identification of high-risk subgroups, 1998–2012. *JAMA Dermatol*. 2015;151(9):976–81.
4. Kaviani A, Ataie-Fashtami L, Fateh M, et al. Photodynamic therapy of head and neck basal cell carcinoma according to different clinicopathologic features. *Lasers Surg Med*. 2005;36(5):377–82.
5. Lallas A, Apalla Z, Argenziano G, et al. The dermatoscopic universe of basal cell carcinoma. *Dermatol Pract Concept*. 2014a;4(3):11–24.
6. Lallas A, Argenziano G, Kyrgidis A, et al. Dermoscopy uncovers clinically undetectable pigmentation in basal cell carcinoma. *Br J Dermatol*. 2014b;170(1):192–5.
7. Lallas A, Tzellos T, Kyrgidis A, et al. Accuracy of dermoscopic criteria for discriminating superficial from other subtypes of basal cell carcinoma. *J Am Acad Dermatol*. 2014c;70(2):303–11.
8. Liopyris K, Navarrete-Dechent C, Dusza SW, et al. Clinical and dermoscopic features associated with lichen planus-like keratoses that undergo skin biopsy: a single-center, observational study. *Australas J Dermatol*. 2019;60(2):e119–e26.
9. Lomas A, Leonardi-Bee J, Bath-Hextall F. A systematic review of worldwide incidence of nonmelanoma skin cancer. *Br J Dermatol*. 2012;166(5):1069–80.
10. Menzies SW, Westerhoff K, Rabinovitz H, Kopf AW, McCarthy WH, Katz B. Surface microscopy of pigmented basal cell carcinoma. *Arch Dermatol*. 2000;136(8):1012–6.
11. Navarrete-Dechent C, Bajaj S, Marchetti MA, Rabinovitz H, Dusza SW, Marghoob AA. Association of shiny white blotches and strands with nonpigmented basal cell carcinoma: Evaluation of an additional dermoscopic diagnostic criterion. *JAMA Dermatol*. 2016;152(5):546–52.
12. Navarrete-Dechent C, Cordova M, Sahu A, et al. Optical imaging guided- 'precision' biopsy of skin tumors: a novel approach for targeted sampling and histopathologic correlation. *Arch Dermatol Res*. 2020a.
13. Navarrete-Dechent C, Liopyris K, Rishpon A, et al. Association of multiple aggregated yellow-white globules with nonpigmented basal cell carcinoma. *JAMA Dermatol*. 2020b.
14. Nehal KS, Bichakjian CK. Update on keratinocyte carcinomas. *N Engl J Med*. 2018;379(4):363–74.
15. Reiter O, Mimouni I, Gdalevich M, et al. The diagnostic accuracy of dermoscopy for basal cell carcinoma: a systematic review and meta-analysis. *J Am Acad Dermatol*. 2018.
16. Rogers HW, Weinstock MA, Feldman SR, Coldiron BM. Incidence estimate of nonmelanoma skin cancer (keratinocyte carcinomas) in the U.S. population, 2012. *JAMA Dermatol*. 2015;151(10):1081–6.
17. Wolner ZJ, Bajaj S, Flores E, et al. Variation in dermoscopic features of basal cell carcinoma as a function of anatomical location and pigmentation status. *Br J Dermatol*. 2018;178(2):e136–e7.
18. Wu S, Han J, Li WQ, Li T, Qureshi AA. Basal-cell carcinoma incidence and associated risk factors in U.S. women and men. *Am J Epidemiol*. 2013;178(6):890–7.
19. Yelamos O, Braun RP, Liopyris K, et al. Dermoscopy and dermatopathology correlates of cutaneous neoplasms. *J Am Acad Dermatol*. 2019;80(2):341–63.

6C NONMELANOCYTIC LESIONS: ACTINIC KERATOSIS

Olivier Gaide, Adèle Rakosi, and François Kuonen

Contents

Introduction 102
Dermoscopic features of actinic keratosis 102
Nonvascular features 102
Vascular features 102
Pigmented features 105
Conclusion and key points 106
References 106

Introduction

Actinic keratoses (AK) are cutaneous lesions that contain some degree of keratinocytic atypia. The extent of histologic atypia can range from minimal keratinocytic atypia confined to the lower part of the epidermis (grade I) to full-thickness atypia (grade III). Lesions displaying full-thickness atypia are classified further by the amount of atypia, with minimal atypia representing grade III AK and marked atypia representing squamous cell carcinoma in situ (Bowen's disease). Consequently, dermoscopic features of AK grade III and SCC in situ overlap to some degree, and it may not be clinically and dermoscopically possible to differentiate them from each other.

Dermoscopic features of actinic keratosis

The classic features of AK include pink-red pseudonetwork, follicular plugs surrounded with white halo, linear wavy vessels, dotted vessels, and conspicuous scales [9]. The first three signs are frequent in AK I and II, whereas dotted vessels and scales are more prominent features of AK III and SCC in situ [1].

Nonvascular features

Follicular plugs with halo (FPWH), also known as targetoid hair follicles (HF) or HF with an inner gray halo: Multiple follicular plugs containing keratin are usually readily visible (Figure 6c.1). As the keratin within the ostial opening builds up, it causes the orifice of the follicle to widen. The follicular epithelium surrounding the central keratin plug is what corresponds to the follicular plug with halo seen with dermoscopy [6, 9]. The constellation of findings of FPWH surrounded by erythema resulting in the appearance of a pink-red pseudonetwork creates the so-called strawberry pattern seen with dermoscopy (Figure 6c.1 and 6c.4). While other skin conditions also exhibit follicular plugs (e.g., discoid lupus erythematosus, keratosis pilaris, viral-associated trichodysplasia), the clinical context, including the presence of background actinic-damaged skin, can usually differentiate AKs from other disease entities [3]. However, one disease entity that can prove challenging to differentiate from AK is lentigo maligna (LM). The collision between an AK and a lentigo results in a pigmented AK, and these lesions can mimic LM. One key difference between LM and AK is found on touch/palpation. The LM will have a smooth surface, while AK will have a rough surface. On dermoscopy, the presence of numerous FPWH is the cardinal sign that helps identify AKs and differentiate them from LM [7, 8] (Figure 6c.1.

Rosettes: Rosettes are only seen with polarized light and appear as four points of light arranged in a pattern creating the shape of a diamond or four-leaf clover. This feature corresponds to the keratin-filled follicular opening and results from the interaction of polarized light with the keratin within the ostial opening (FPWH). While rosettes can be seen in background actinic -damaged skin and other skin tumors, including melanoma, their presence in a rough macule located on actinic-damaged skin is highly suggestive of AK, especially if multiple such structures are located within the lesion (Figure 6c.2).

Scales, crusts, and structureless areas: The presence of scale, which contributes to the rough texture of an AK, is a common feature observable in almost all AKs. In pigmented AK, the scale can take on the appearance of angulated lines (Figure 6c.3), which is a feature associated with LM. However, the lack of other LM-specific features and the presence of a rough texture with FPWH can help in diagnosing AK. The continued accumulation of adherent scale eventually results in the formation of crusts. The presence of crusts is a frequent feature of grade III AKs (hypertrophic AK) and SCCs. Large areas covered by scale-crust obscuring the ability to see any follicular openings or any structures within the epidermis are called structureless areas Figure 6c.4.

Vascular features

Pink-red pseudonetwork: Dilatation of capillaries increases blood flow in AK and results in their pink-to-red color. The erythematous skin of an AK is interrupted by dilated follicular openings, and this creates the so-called red pseudonetwork pattern. When this red pseudonetwork is combined with FPWH, it yields a strawberry pattern [7] (Figure 6c.5).

Linear wavy vessels: Thin linear wavy vessels may be observed in all grades of AK. They are not specific and can be observed in many other lesions, both benign (essential telangiectasia, cutaneous sarcoidosis) and malignant (including BCC and melanoma) [2, 4] (Figure 6c.6).

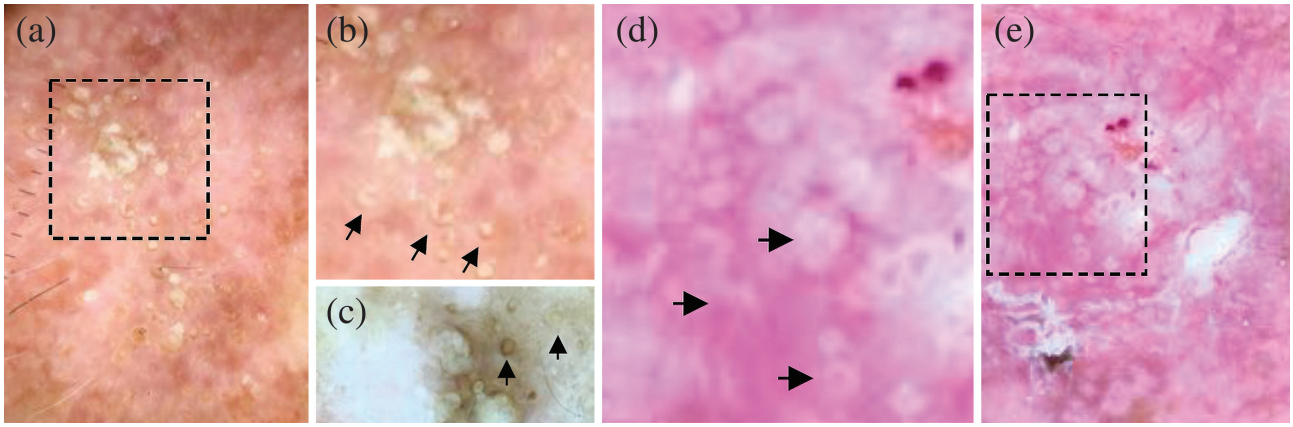

FIGURE 6C.1 Follicular plugs with halo. (a) Nonpolarized image of an AK revealing FPWH. The boxed area is enlarged in (b). (b) FPWH are highlighted by arrows. (c) FPWH can be hyperpigmented in darker skin and thus appear as delineated by a dark rim. (d) Close-up of the boxed area in (e), revealing FWPH highlighted by arrows. (e) Nonpolarized image of an AK revealing FPWH. The boxed area is enlarged in (d).

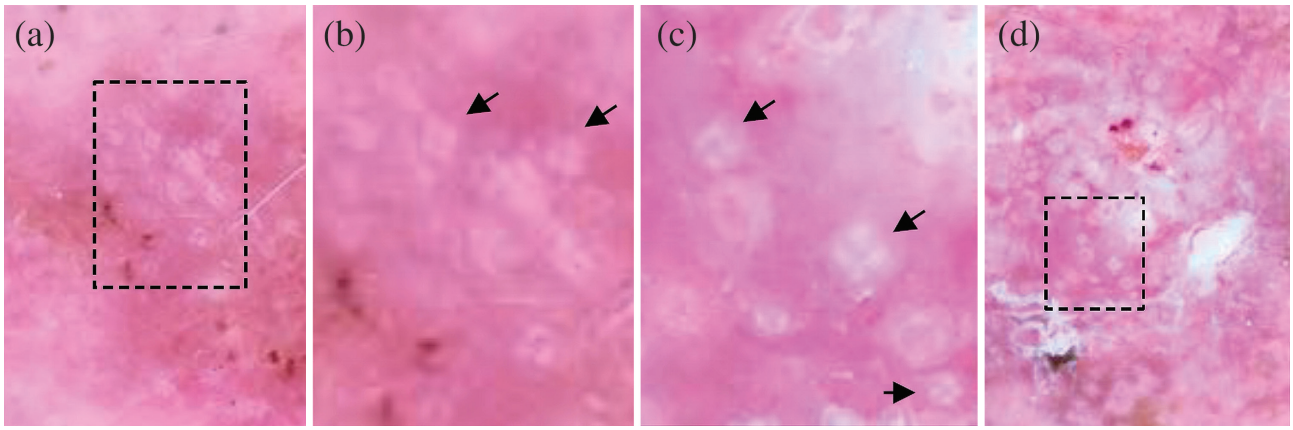

FIGURE 6C.2 Rosettes. (a) Nonpolarized image of an AK revealing rosettes. The boxed area is enlarged in (b). (b) Typical rosettes, resembling four diamonds arranged perpendicular to one another, highlighted by arrows. (d) Close-up of the boxed area in (d), revealing rosettes highlighted by arrows. (d) Nonpolarized image of an AK revealing typical rosettes. The boxed area is enlarged in (c).

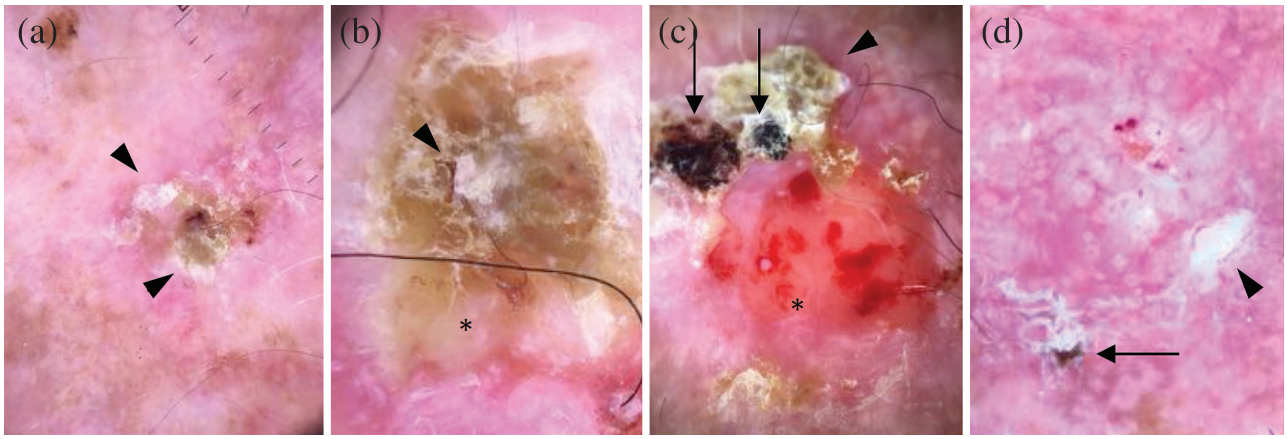

FIGURE 6C.3 Hyperkeratosis in AK. (a) Nonpolarized image of an AK revealing whitish and yellowish scales (arrowheads). (b) Nonpolarized image of an AK revealing whitish and yellowish scales (arrowheads) as well as a structureless area (asterisks). (c) Nonpolarized image of an AK revealing whitish and yellowish scales (arrowheads), structureless area (asterisks), and brown crust (arrows). (d) Nonpolarized image of an AK revealing whitish scales (arrowheads) as well as a brown crust (arrows).

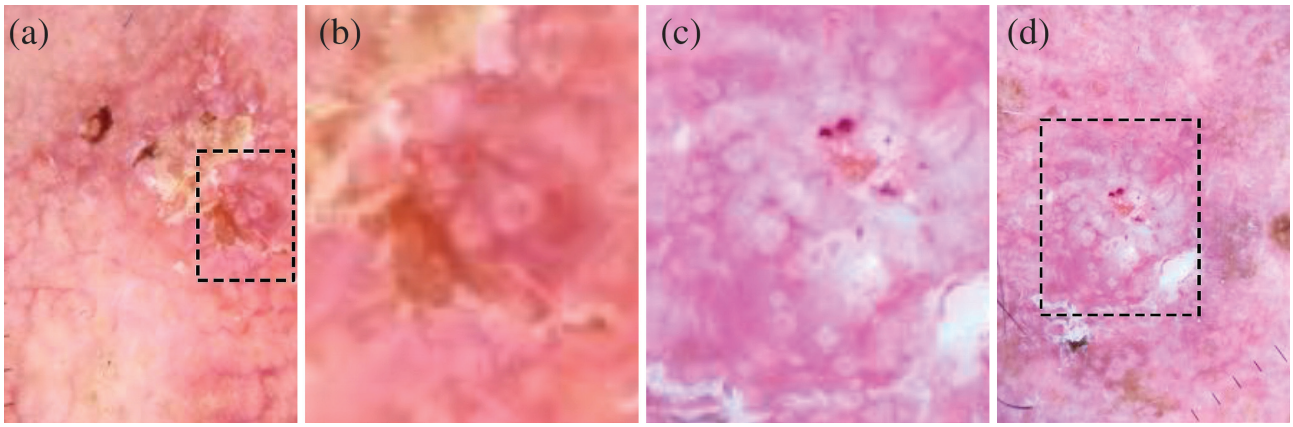

FIGURE 6C.4 Pink-red pseudonetwork and the strawberry pattern. (a) Nonpolarized image of an AK revealing pink-red pseudonetwork. The boxed area is enlarged in (b). (f) Pink-red pseudonetwork and FPWH forming, together, the strawberry pattern. (c) Close-up of the boxed area in (d), revealing pink-red pseudonetwork and FPWH forming, together, the strawberry pattern. (d) Nonpolarized image of the same AK. The boxed area is enlarged in (c).

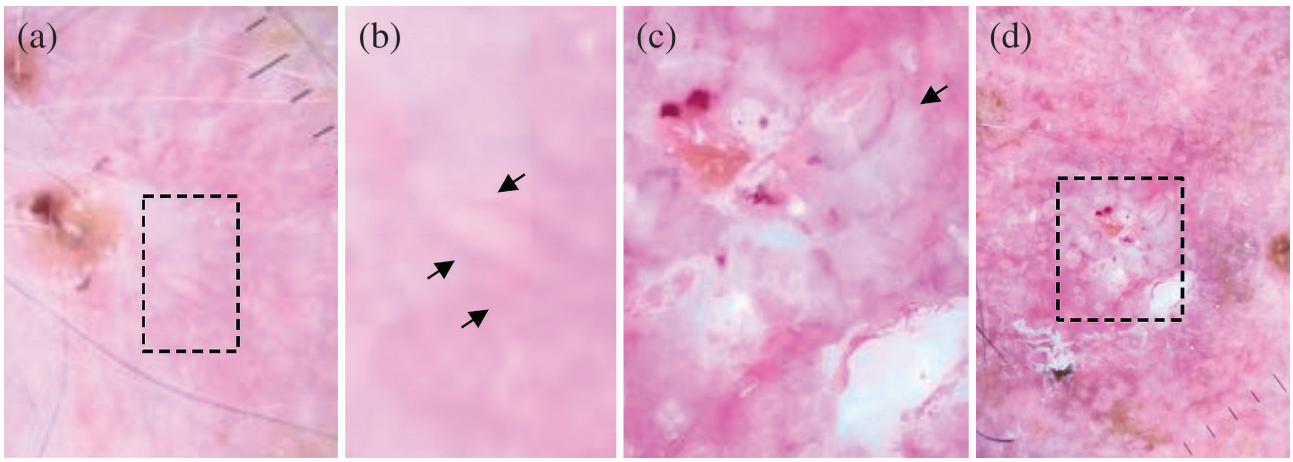

FIGURE 6C.5 Linear wavy vessels. (a) Nonpolarized image of an AK revealing linear wavy vessels. The boxed area is enlarged in (b). (b) Linear wavy vessels highlighted by arrows. (c) Close-up of the boxed area in d, revealing linear wavy vessels highlighted by arrows. (d) Nonpolarized image of the same AK. The boxed area is enlarged in (c).

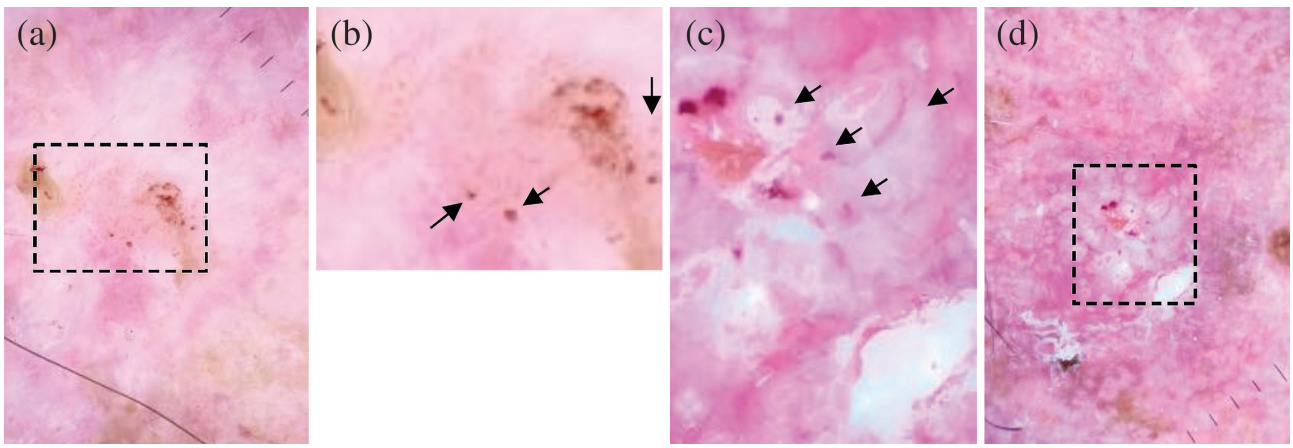

FIGURE 6C.6 Dotted vessels. (a) Nonpolarized image of an AK revealing dotted vessels. The boxed area is enlarged in (b). (b) Dotted vessels highlighted by arrows. (c) close-up of the boxed area in (d), revealing dotted vessels highlighted by arrows. (d) Nonpolarized image of the same AK. The boxed area is enlarged in (c).

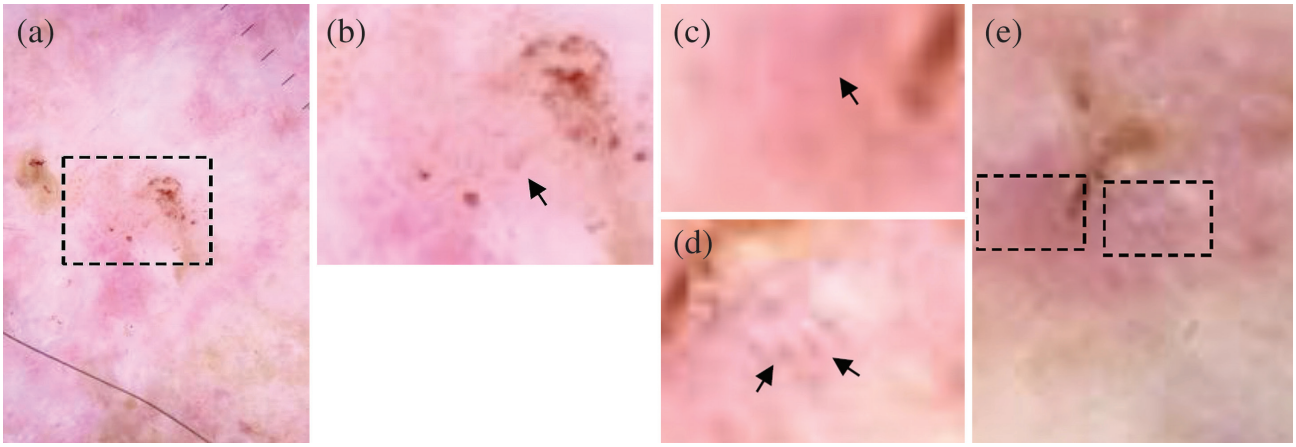

FIGURE 6C.7 Hairpin vessels. (a) Nonpolarized image of an AK revealing hairpin vessels. The boxed area is enlarged in (b). (b) Hairpin vessels, highlighted by arrows, are surrounded by a halo, a feature of all keratinizing tumors, be they benign or malignant. (c) and (d) close-up of the boxed areas in (e), revealing typical hairpin vessels and their surrounding halo, highlighted by arrows. (e) Non-polarized image of the same AK. The boxed areas are enlarged in (c) and (d).

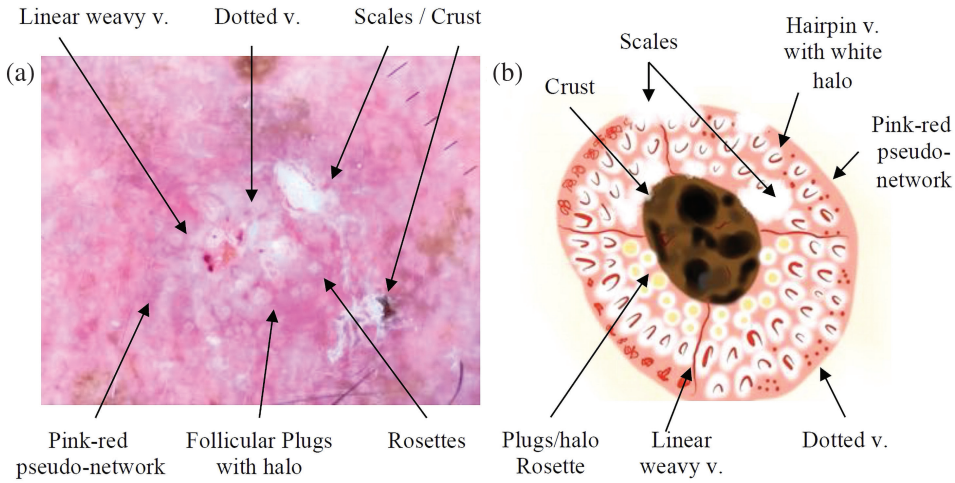

FIGURE 6C.8 Simultaneous occurrence of multiple AK features helps in the diagnosis. (a) Nonpolarized dermoscopic image of an AK, featuring nearly all the nonvascular (FPWH, rosettes, scales crust, and structureless areas) and vascular (pink-red pseudonetwork, linear wavy, dotted, and hairpin vessels with a halo) features described. (b) Schematic drawing of the nonvascular and vascular features of AK. (Panel (b) from dermoscopedia.org.)

Dotted vessels: They appear as small red dots that are more readily visible under polarized light dermoscopy. Dotted vessels are frequently observed in AKs and Bowen's disease. They are not specific and are commonly seen in inflammatory diseases, stasis dermatitis, and traumatized skin; they can also be present in neoplastic lesions such as melanoma [4] (Figure 6c.7).

Hairpin vessels with white halo: While characteristic of keratinized tumors, they are rarely observed in hypertrophic AKs. They are more commonly seen in well-differentiated SCCs and seborrheic keratosis (Figure 6c.8).

Combinations of features: The right panels in Figures 6c.1 – 6c.8 are all images captured from a single lesion monitored over time showing an AK transitioning to a well-differentiated SCC in situ. This case illustrates the overlapping features observed in AKs and SCCs, which are summarized in Figure 6c.9.

Pigmented features

Pigmented AKs (pAK) arise from a collision of an AK with a solar lentigo. These pigmented AK can sometimes be mistaken for LM. Dermoscopy can, however, help discriminate between pAK and LM [5, 7].

Constellation of features (global pattern) of AK: While LM may reveal any of the aforementioned AK features, these features will only be present focally within the melanoma, and the rest of the lesion will almost always reveal LMM-specific features. In contrast, AK, unlike LM, will have a rough texture across the entire surface, and the entire surface area of the lesion will reveal the aforementioned AK features such as FPWH and rosettes. Hence, the constellation of features of AKs, including its pattern and texture, combined with the absence of clear signs of melanoma, is the key to differentiating AK from LM [8]. Figure 6c.9.

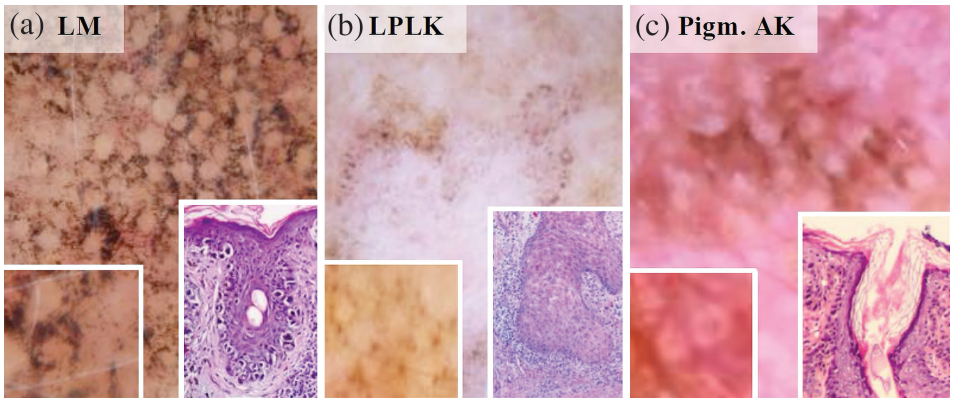

FIGURE 6C.9 Importance of the size of follicular openings for the diagnosis of lentigo maligna, LPLK, and pigmented AK. (a) In lentigo maligna, follicular openings appear smaller as melanocytes migrate along them. The lower inserts show a close-up and the corresponding HE histology to the left and right, respectively. (b) In LPLK, melanin deposits occur in between follicular openings that are normal in size. The lower inserts show a close-up and the corresponding HE histology to the left and right, respectively. (c) In pigmented AK, the follicular plugs and halo correspond to an enlargement of the follicular size over the interfollicular epidermis, which thus appears largest in dermoscopy. The lower inserts show a close-up and the corresponding HE histology to the left and right, respectively.

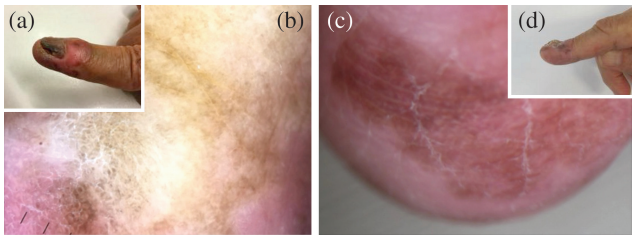

FIGURE 6C.10 Grayish pigmentation associated with clear epidermal changes in AK/SCC compared with melanoma. (a) Clinical image showing a pigmented SCC of the finger, with typical dirty gray appearance. (b) Dermoscopy image of the same finger, showing a grayish appearance as well as architectural atypia of the epidermis, which are always present in SCC. (c) Dermoscopic image of melanoma, showing a brown pigmentation largely covering the ridges, a typical sign of melanoma. There is no epidermal disruption here, but it should be noted that this will occur with more aggressive forms of melanoma. (d) Clinical image of the finger in (c), showing that in melanoma, coloration may vary from brown to a similar grayish coloration.

Presence of red pseudonetwork / strawberry pattern: Melanoma can manifest pink-red color mimicking pink-red pseudonetwork, but this will not be associated with the characteristic changes of the hair follicle (FPWH). Hence, the strawberry pattern is a strong indicator of AK/SCC. In addition, melanomas may occasionally have focal scale and crust, but this will not encompass the entire surface area of the melanoma. In addition, the scale-crust in melanoma will not become as hyperkeratotic as can occur in AK.

Larger than normal size of follicular opening and contrasting pigmentation around the ostial opening: In AK, the FPWH creates dilation of the hair follicle diameter. The pigmentation around these dilated hair follicles will appear as a pigmentation ring that has a much larger diameter than the diameter observed in solar lentigo, LPLK, or LM (Figure 6c.10).

Inner gray halo: In pigmented AKs, a subtle homogeneous gray or beige halo that surrounds follicular openings (or follicular plugs), forming a sort of "internal ring" to the brown meshes of the pseudonetwork, can be frequently observed [6].

Conclusion and key points

1. The hallmark pattern of an AK is a lesion with a red pseudonetwork and FPWH, resulting in the so-called strawberry pattern.
2. Keratin-filled ostial openings in an AK will manifest as rosettes when viewed with polarized light.
3. The angulated lines seen in AK are due to scales.
4. Attempts have been made to grade AK. Grade I AK are lesions with a rough texture revealing a red pseudonetwork. Grade II AK lesions will have prominent FHWH, creating the strawberry pattern. They can also have scale. Grade III AK are also known as hypertrophic AK and display prominent adherent scale-crust leading to structureless areas.
5. Wavy vessels can be seen in all grades of AK. Dotted vessels are associated with higher grades of AK.
6. Simultaneous occurrence of the above described AK features is frequent and helps in the diagnosis.

References

1. Cayirli, M, et al. Dermatoscopy of facial non-pigmented actinic keratosis regarding to grades of the lesions. *J Eur Acad Dermatol Venereol*. 2013;27(9):1185–7.
2. Conforti, C, et al. Dermoscopy of a single plaque on the face: an uncommon presentation of cutaneous sarcoidosis. *Dermatol Pract Concept*. 2018;8(3):174–6.
3. Cook, LC, et al. Dermoscopy in the diagnosis of inflammatory dermatoses: systematic review findings reported for psoriasis, lupus, and lichen planus. *J Clin Aesthet Dermatol*. 2018;11(4):41–2.
4. Dermoscopedia. from www.dermoscopedia.org.

5. Lallas, A, et al. Dermoscopic clues to differentiate facial lentigo maligna from pigmented actinic keratosis. *Br J Dermatol*. 2016;174(5):1079–85.
6. Nascimento, MM, et al. Inner gray halo, a novel dermoscopic feature for the diagnosis of pigmented actinic keratosis: clues for the differential diagnosis with lentigo maligna. *J Am Acad Dermatol*. 2014;71(4):708–15.
7. Peris K, Micantonio T, Piccolo D, Concetta M. Dermoscopic features of actinic keratosis. *JDDG: J Dtsch Dermatol Ges*. 2007;5(11):970–75. doi:10.1111/j.1610-0387.2007.06318.x.
8. Tschandl et al. Seven non-melanoma features to rule out facial melanoma. *ActaDV*. 2017;97:1219–24.
9. Zalaudek, I, Giacomel J, Argenziano G, Hofmann-Wellenhof R, Micantonio T, Di Stefani A, Oliviero M, Rabinovitz H, Soyer HP, Peris K. Dermoscopy of facial nonpigmented actinic keratosis. *Br J Dermatol*. 2006;155(5):951–56. doi:10.1111/j.1365-2133.2006.07426.x.

6D NONMELANOCYTIC LESIONS: ACTINIC KERATOSIS, BOWEN'S DISEASE, KERATOACANTHOMA, AND SQUAMOUS CELL CARCINOMA

Iris Zalaudek, Alan Cameron, Cliff Rosendahl, Shushanik Karapetyan, and Pawel Pietkiewicz

Contents

Introduction . . . 108
Nonpigmented actinic keratosis . . . 109
Pigmented actinic keratosis . . . 109
Nonpigmented Bowen's disease . . . 110
Pigmented Bowen's disease . . . 111
Bowenoid actinic keratosis . . . 112
Erythroplasia of Queyrat . . . 112
Keratoacanthoma . . . 112
Invasive squamous cell carcinoma . . . 112
Pigmented invasive squamous cell carcinoma . . . 114
Key points . . . 114
References . . . 115

Introduction

The spectrum of premalignant and malignant keratinizing tumors comprises actinic (solar) keratosis (AK), Bowen's disease (BD), keratoacanthoma (KA), and squamous cell carcinoma (SCC). Although pigmented variants do exist, the great majority of these tumors are nonpigmented, meaning that their dermatoscopic diagnosis is based mainly on the assessment of either keratin structures or vascular patterns. Other associated, but nonspecific, features, such as erythema, ulceration, or erosion, may provide further clues to the diagnosis [1, 8, 12, 13].

In contrast to the well-defined dermatoscopic criteria of pigmented tumors, dermatoscopic features of nonpigmented keratinizing tumors are less well established [17]. Although the utility of vascular patterns in the diagnosis of nonpigmented tumors has been recognized for some time [13], their assessment has gained more importance in recent years. This may in part reflect technical improvements in the ability to visualize blood vessels under dermatoscopy. With respect to raised nonpigmented lesions, the significance of the keratin clues of surface keratin, white circles, and white structureless areas was defined in 2012 [22].

When using contact dermatoscopy, pressure applied to the contact plate may compress blood vessels, thereby rendering them invisible. Using a viscous immersion medium such as ultrasound gel permits examination of lesions without excessive pressure being applied to the contact plate, enhancing our ability to visualize vascular structures. More recently, the development of polarized light dermatoscopy instruments that do not require any direct contact with the skin has eliminated pressure-induced compression of blood vessels, improving their visualization.

Before discussing the dermatoscopic features of specific keratinizing tumors, it is important to acknowledge the following points.

- While there has been a quantitative analysis of clues to nonpigmented SCC and KA [21], many of the described dermatoscopic patterns of AK, BD, KA, and SCC are based on case series, meaning these patterns have not yet been formally evaluated for their diagnostic specificity and sensitivity.
- These tumors may be viewed as lying on a spectrum of keratinocyte dysplasia. Therefore, the clinical and dermatoscopic features of the various keratinizing tumors do show some overlap.
- There are many competing (and sometimes contradictory) terms used to describe vascular structures, which were often introduced in an ad hoc fashion. This may cause confusion, particularly for beginners in dermatoscopy. We will use the terms defined by Argenziano et al. in 2004, as well as the geometric classification system of revised pattern analysis [11]. These definitions are summarized in Table 6d.1. For patterns not included in either of these systems, we will use the terms as originally described.
- Diagnosis based on vessel morphology is considerably less specific than diagnosis based on assessment of other dermatoscopic structures, because the same vessel morphology may be found in different tumor types and even in inflammatory lesions. This problem is particularly acute on the lower limbs, where dot and coiled vessels may be seen in lesions (such as basal cell carcinoma [BCC]) that elsewhere only rarely show these patterns [19].
- The arrangement and distribution of vessels within the lesion may provide improved specificity over and above simply assessing vessel patterns. For example, BD, stasis dermatitis, and psoriasis may all contain glomerular (coiled) vessels. However, in BD, the vessels are typically seen in a clustered or linear arrangement, whereas in dermatoses, the vessels are regularly distributed throughout the lesion (arranged randomly). Therefore, the diagnosis of nonpigmented skin lesions is based on the following: (i) clinical assessment (e.g., texture, firmness, rate of growth), (ii) assessment of keratin clues (e.g., surface keratin, white circles, white structureless areas, and four-dot-clods/rosettes), (iii) assessment of vascular morphology, and (iv) assessment of architectural arrangement and distribution of vessels.

TABLE 6D.1: Definitions of the Different Morphologic Types of Vessels Associated with Keratinizing Tumors, Including Actinic Keratosis, Bowen's Disease, Keratoacanthoma, and Squamous Cell Carcinoma

[1]	Definition	[11]	Definition
Dotted	Tiny red dots densely aligned next to each other	Dots	Vessels appear as tiny round spots not extending in any direction (no length and no breadth)
Glomerular	Variation on the theme of dotted vessels. They are tortuous capillaries often distributed in clusters mimicking the glomerular apparatus of the kidney	Coiled	Vessels appear as lines compactly convoluted
Hairpin	Vascular loops sometimes twisted and bending, usually surrounded by a whitish halo when seen in keratinizing tumors	Looped	Vessels appear as lines with one major bend, which is sharp (180°) and results in a reversal of direction (U-turn)
Linear irregular	Linear, irregularly shaped, sized, and distributed red structures	Straight	Vessels appear as lines without a bend
		Serpentine	Vessels appear as lines with more than one bend (in a snakelike fashion)
Strawberry	Erythema resembling a marked pink-to-red "pseudonetwork" around the hair follicles intermingled with fine, linear wavy vessels surrounding the hair follicles. Often hair follicle openings filled with yellowish keratotic plugs surrounded by a white halo are additionally presented	White circles on a red background	A circle is a curved line equidistant from a central point
Polymorphous	Any combination of two or more different types of vascular structures. The most frequent is that occurring between linear irregular and dotted vessels	Monomorphous	One vascular pattern dominates by far
		Polymorphous	Two or more vascular patterns are present

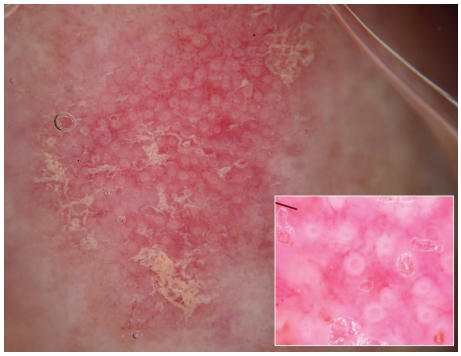

FIGURE 6D.1 Nonpigmented facial actinic keratosis showing background erythema interrupted by white circles with a central yellow clod. In addition, surface scale is visible. At higher magnification, coiled vessels around the hair follicle ostia can be seen (inset on right).

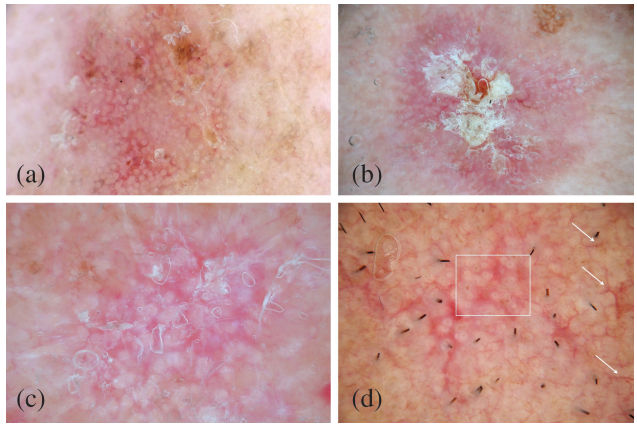

FIGURE 6D.2 Dermatoscopy of nonpigmented facial actinic keratosis typically reveals white clods or circles on a pink or red background (a, b, d) and surface scale (c). The elongated telangiectasiae (d, arrows) are the normal vessels of the dermal plexus visible through the thinned, actinically damaged skin.

Nonpigmented actinic keratosis

Nonpigmented AK on the face shows four dermatoscopic features: (i) A background erythema sparing the hair follicles (white circles on a red background—the so-called strawberry pattern) (Figure 6d.1), (ii) white-to-yellow surface scale, (iii) fine, wavy vessels (straight or coiled) surrounding the hair follicles, and (iv) hair follicle openings surrounded by a white circle with a central yellow keratotic plug (white circle surrounding a yellow clod) (Figure 6d.2) [20, 31].

On nonfacial skin, AK usually exhibits [32] nonspecific patterns, with features such as surface scale and keratin (Figure 6d.3), and sometimes dotted vessels.

An additional clue to the diagnosis of AK is the rosette sign, which can only be seen with polarized light [6]. The rosette sign consists of four bright white clods arranged in a square (four-dot clod) (Figure 6d.4). The phenomenon is caused by light interaction with concentric horn material in follicular openings, eccrine ducts at the infundibular level (small rosettes, dia. 0.1–0.2 mm), and perifollicular concentric fibrosis (large rosettes, dia. 0.3–0.5 mm) [10]. Although this clue is most commonly seen in AK and superficial SCC, it can also be seen in other tumors such as BCC, melanoma, scars, inflammatory conditions, and even on actinically damaged skin without any specific lesion.[6, 10].

Pigmented actinic keratosis

Pigmented variants of AK (pAK) are less common than nonpigmented AK and in our experience, occur more often in darker skin phototypes. Both clinically and dermatoscopically, the structures seen in facial pAK may overlap with those visualized in lentigo maligna (LM) and include asymmetric pigmented follicular openings, annular-granular pattern, and polygons in the form of either rhomboidal structures or angulated lines [24, 26]. Differentiating some pAK from LM may

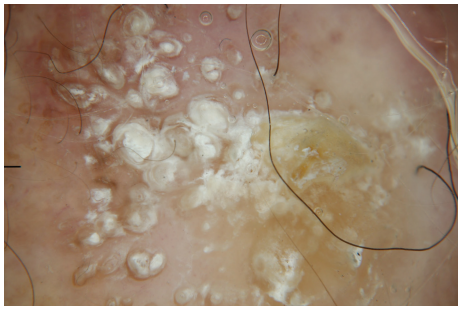

FIGURE 6D.3 Dermatoscopy of actinic keratosis that is not located on the face often reveals only nonspecific features, such as hyperkeratosis.

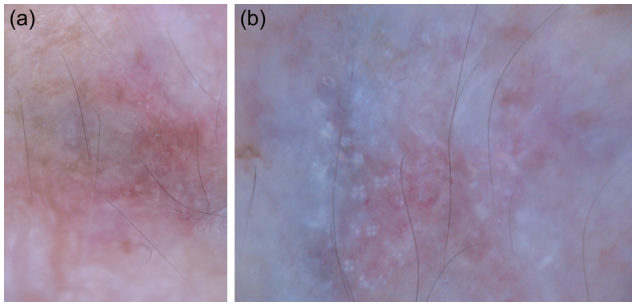

FIGURE 6D.4 (a) Clinical image of an actinic keratosis with focal transition to squamous cell carcinoma in situ. (b) Under dermatoscopy multiple rosettes/four-dot clods, consisting of four shiny white dots arranged in a square, can be seen. This feature can only be seen with polarized light dermatoscopy.

only be possible via palpation; pAK have a rough texture as compared with a smooth texture in LM. Dermatoscopically, a diagnosis of pAK is supported by the presence of prominent, pale follicular openings (Figure 6d.5) [16]; a finding less commonly seen in LM [21, 31]. In addition, dermatoscopy of LM may reveal a darker dot located within ostial openings (some call this the isobar sign); a finding rarely seen in pAK (Figure 6d.6b).

Although dermatoscopy cannot always reliably differentiate pAK from LM, it may help guide the best location to biopsy. Biopsying areas revealing the most suspicious features, such as annular-granular structures, asymmetric follicular openings, dots within the ostial openings, or rhomboidal structures, may provide the pathologist with the most diagnostically relevant tissue to examine (Figure 6d.7) [2], although caution should be exercised when not performing a complete biopsy of any lesion to exclude or confirm melanoma.

Nonpigmented Bowen's disease

BD and intraepidermal carcinoma (IEC) represent SCC in situ of the skin. Although many consider BD and IEC to be separated entities based on epidemiologic, clinical, and histopathologic features, dermatoscopic differences are not well defined.

The archetypal dermatoscopic pattern of BD is one of white-to-yellow surface scale on an erythematous to yellow background and glomerular (coiled) vessels in clustered or linear arrangement (Figure 6d.8) [3, 4, 7, 23, 25, 27–30]. The simultaneous finding of surface scale and focal clusters of glomerular

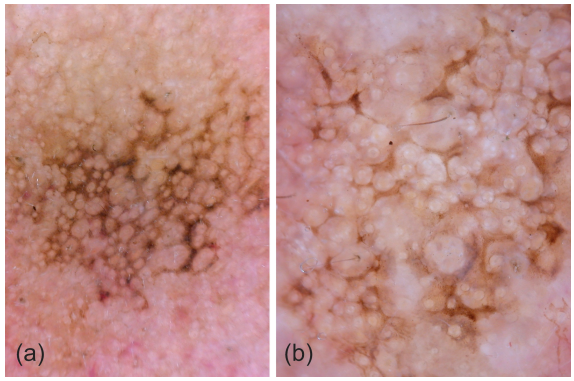

FIGURE 6D.5 Typical dermatoscopic appearance of pigmented facial actinic keratosis showing angulated lines between pale follicular structures forming polygons (a) and angulated brown short lines between keratin-filled hair follicles of irregular size (b).

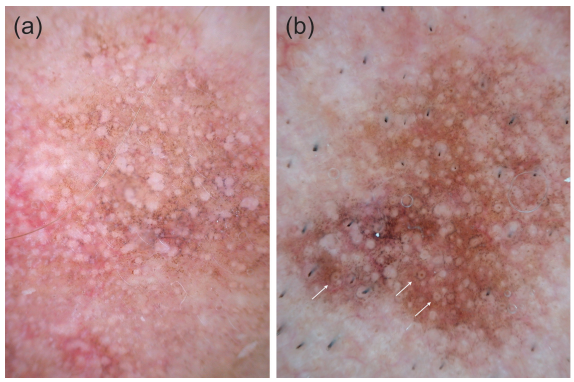

FIGURE 6D.6 Side-by-side comparison between (a) pigmented actinic keratosis and (b) lentigo maligna. Both tumors show multiple small gray dots (annular-granular pattern). Note that the hair follicle openings of the actinic keratosis lack the central black dot (also known as the isobar sign) as seen in this case of lentigo maligna (arrows).

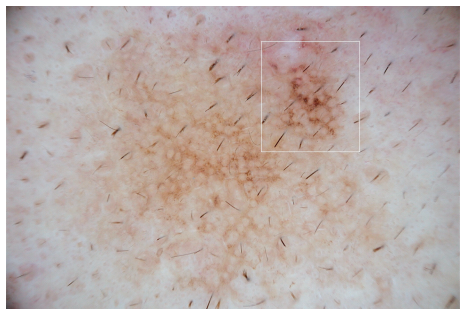

FIGURE 6D.7 Dermatoscopy may help guide biopsy of equivocal cases. The most suspicious area under dermatoscopy is the one showing enhanced gray-brown angulated lines (square). The biopsy was therefore taken from this area. The histopathologic diagnosis was pigmented actinic keratosis.

vessels has been reported to give a 98% diagnostic probability that the lesion in question is BD [18] (Figure 6d.9).

Although it is usually easy to see glomerular/coiled vessels through a dermatoscope, it is often difficult to capture

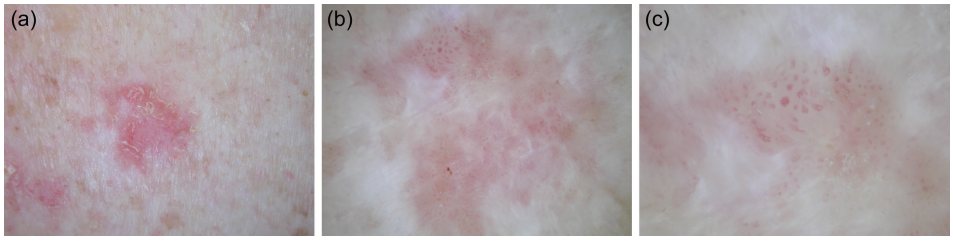

FIGURE 6D.8 (a) Clinical image of Bowen's disease. Notice the adherent surface scale. (b) Dermatoscopy reveals numerous different blood vessel morphologies; however, the archetypal vessel morphology is the glomerular (coiled) type, as highlighted in the magnification in (c).

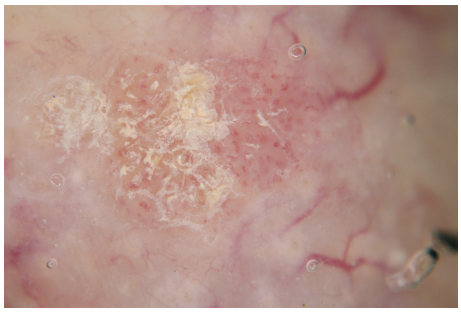

FIGURE 6D.9 Glomerular (coiled) vessels and surface scale are frequently seen in squamous cell carcinoma in situ.

their coiled morphology on images. Due to their small size, lack of contrast, and camera resolution issues, these vessels often appear in images as red dots (Figure 6d.10). Thus, when analyzing images, these coiled vessels can be confused with dotted vessels as seen in melanocytic skin tumors, such as Spitz nevi. The clustered distribution of the vessels in BD versus the symmetric random distribution of vessels in spitzoid neoplasms may help differentiate these entities (Figure 6d.11) [1, 30, 31].

Dermoscopic features of BD occasionally overlap with BCC, amelanotic melanoma, seborrheic keratosis, lichen planus–like keratosis, and AK [27].

Pigmented Bowen's disease

Pigmented Bowen's disease (pBD) is encountered less frequently than its nonpigmented counterpart, and it is more common in darker skin phenotypes. In our analysis of more than 50 consecutive cases [5], the following dermatoscopic patterns were found in pBD: (i) brown or gray dots (these dots are a strong clue when arranged as linear radial lines at the periphery of the lesion (Figure 6d.12); (ii) pink or skin-colored eccentric structureless areas (Figure 6d.13); and (iii) glomerular

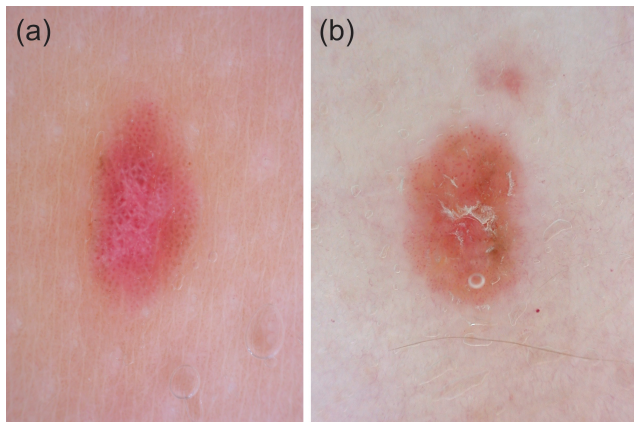

FIGURE 6D.11 Comparison of (a) nonpigmented Spitz nevus and (b) Bowen's disease. Although at 10-fold magnification the vessels in both tumors appear as dots, they are homogeneously distributed in the Spitz nevus, whereas they appear a little larger and clustered in Bowen's disease. Additional clues to the correct diagnosis include the reticular depigmentation (negative network) in the Spitz nevus and the surface scale in Bowen's disease.

(coiled) vessels, arranged randomly, as clusters, or in radial lines (Figures 6d.12, 6d.13).

In a case report, Fraga-Braghiroli et al. described dermatoscopic pigmented circles in pBD, which on confocal microscopy correlated with pigmented basal keratinocytes, rimming the dermal papillae. The circular morphology was only revealed by higher magnification of the dermatoscopic image, so it is likely that this morphology is generally observed as pigmented dots, although we have also observed pigmented circles (in linear arrangement) in pBD (Figure 6d.14).

Occasionally, pBD may mimic melanoma (Figure 6d.13). Features that support a diagnosis of pBD are the presence of

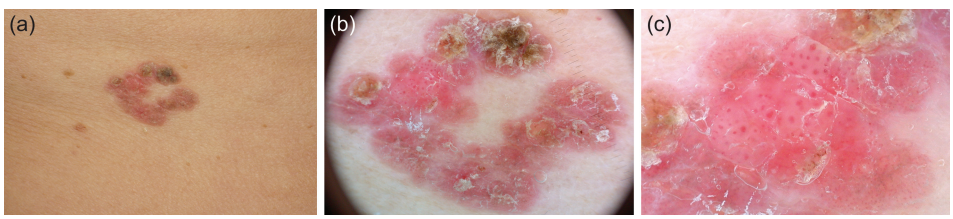

FIGURE 6D.10 (a) Clinical image of Bowen's disease. (b) Dermatoscopy of Bowen's disease shows surface scale and glomerular vessels (coiled vessels) in a clustered arrangement. (c) Higher magnification of glomerular (coiled) vessels.

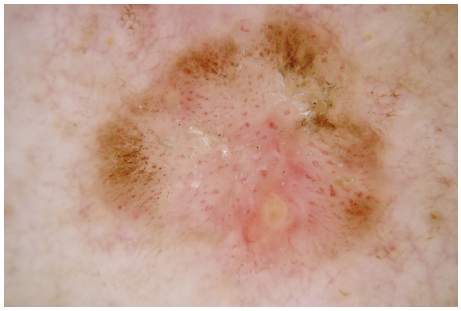

FIGURE 6D.12 Partially pigmented Bowen's disease showing clustered glomerular (coiled) vessels and brown dots at the periphery arranged in a radial (linear) configuration.

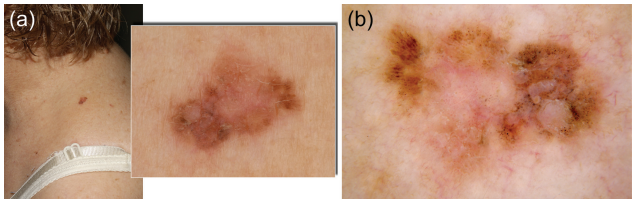

FIGURE 6D.13 (a) Pigmented lesion suggestive for melanoma. Note, however, that the lesion has surface scale. (b) Dermatoscopy reveals brown dots arranged in radial lines, an eccentric pink structureless zone, and monomorphic glomerular (coiled) vessels. Histopathology confirmed the diagnosis of pigmented Bowen's disease.

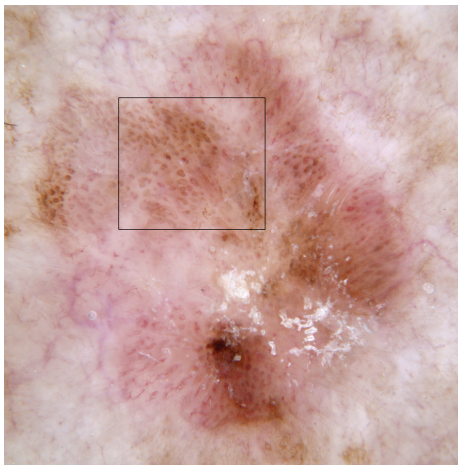

FIGURE 6D.14 Dermatoscopy image of pigmented Bowen's disease showing brown circles in linear arrangement (boxed area).

an adherently scaly surface, the presence of dermatoscopically brown or gray dots arranged in linear radial lines at the periphery, and focal glomerular (coiled) vessels. In contrast, the brown/gray dots in melanoma do not follow any pattern, and the blood vessel morphology usually consists of dotted (red dots) or polymorphous vessels.

Bowenoid actinic keratosis

The Bowenoid actinic keratosis is one that reveals nearly full-thickness dysplasia of keratinocytes histologically. Not surprisingly, its dermatoscopic appearance is similar to that

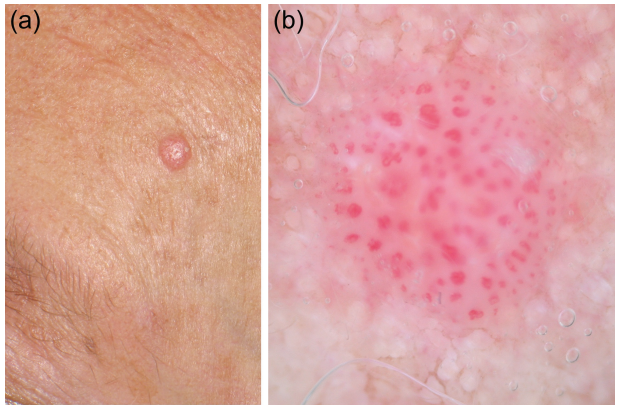

FIGURE 6D.15 (a) Clinical image of a Bowenoid actinic keratosis. (b) Dermatoscopic features of Bowenoid actinic keratosis showing glomerular (coiled) vessels of irregular size that are uniformly distributed.

of BD (Figure 6d.15). However, in our experience, the glomerular vessels in Bowenoid actinic keratosis tend to be regularly distributed and not arranged in focal clusters as seen in classic BD.

Erythroplasia of Queyrat

The dermatoscopy of Erythroplasia of Queyrat (EQ), which is Bowen's disease of the glans penis, was evaluated by Errichetti et al. [8]. They studied 14 cases and compared them with cases of psoriasis, Zoon plasma cell balanitis, and candida balanitis. They found that glomerular (coiled) vessels, both clustered and randomly distributed, were highly predictive of EQ (Figure 6d.16).

Keratoacanthoma

KA is considered by many to be a well-differentiated variant of SCC, with a typical clinical course of initial rapid growth followed by spontaneous involution over a period of a few months. Others consider it a distinct benign tumor, but of course, this controversy has no effect on dermatoscopy findings.

KA exhibits the same keratin clues and vessel patterns as invasive SCC, with one or more of the keratin clues of surface keratin, white circles, and white structureless areas usually being present. These clues have been shown to be more robust than vessel clues and take priority over any vessel clues present [22]. Dermatoscopically, KA is characterized by a central yellowish to brownish structureless mass of keratin, which is typically surrounded by elongated and sometimes thick telangiectasias. The vessel morphology may be hairpin (looped) or linear irregular (serpentine or branched serpentine). A white-to-yellow background halo (Figures 6d.17 and 6d.18) usually surrounds these blood vessels. Glomerular (coiled) vessels may also be seen [1, 12, 14].

KA cannot reliably be distinguished from SCC dermatoscopically [21].

Invasive squamous cell carcinoma

Invasive SCC is usually straightforward to recognize clinically as a firm, tender, growing nodule. Pigmented variants

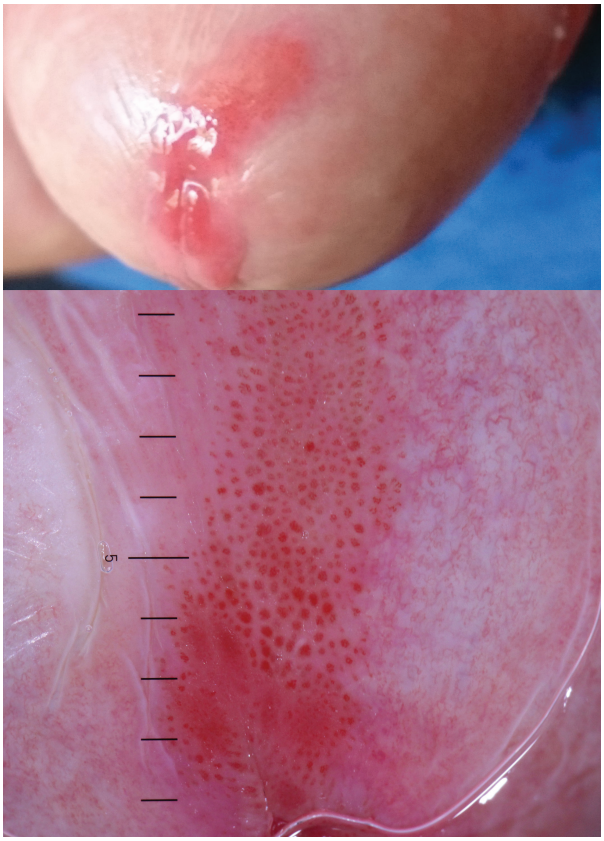

FIGURE 6D.16 Clinical and dermatoscopic images of Erythroplasia of Queyrat. Dermatoscopically, there is a random distribution of coiled glomerular (coiled) vessels, some of which are in a linear arrangement.

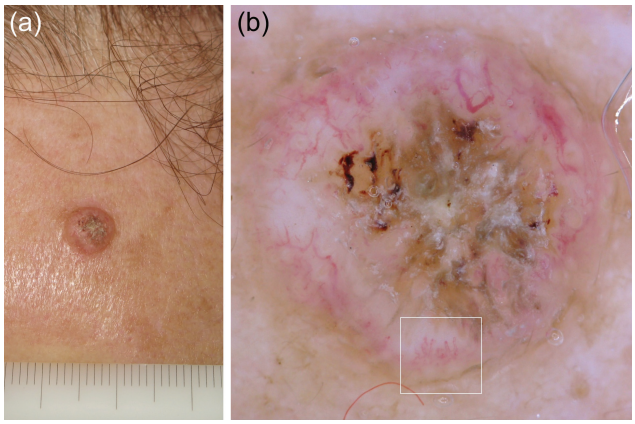

FIGURE 6D.17 (a) Clinical image of a keratoacanthoma. (b) Dermatoscopic features of keratoacanthoma. While clinically the central crust is easy to identify, only dermatoscopy allows the visualization of large linear irregular vessels (also known as serpentine branched) and hairpin (also known as looped) vessels (square) on a white background (structureless white area, which correlates with a mass of highly keratinized keratinocytes).

are exceedingly rare. The differential diagnosis of SCC is wide, comprising the full range of pink and skin-colored nodules.

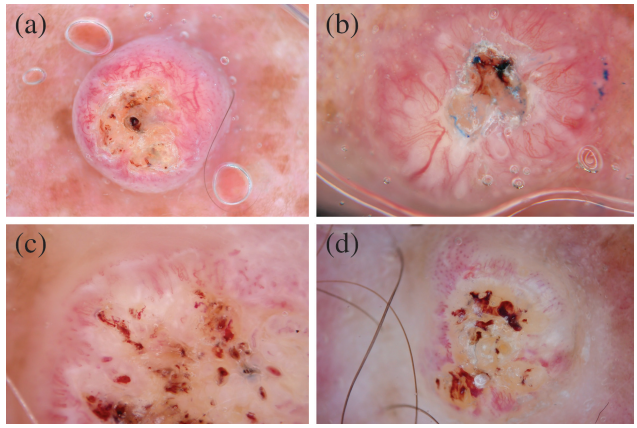

FIGURE 6D.18 Dermatoscopy of keratoacanthoma is characterized by surface keratin surrounded by linear vessels of different caliber. Although looped and serpentine vessels are most common in KA, dotted (red dots) or glomerular (coiled) vessels can also be seen on occasion (d). White structureless areas and white circles are compelling clues to SCC/KA in this lesion and take priority over vessel clues; KA (b).

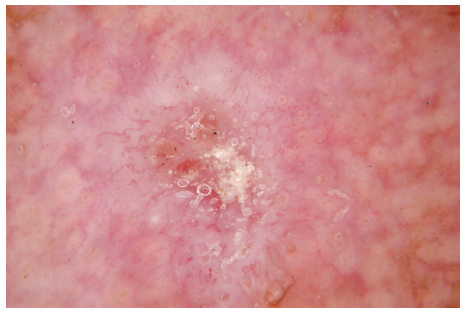

FIGURE 6D.19 Invasive squamous cell carcinoma showing surface keratin and polymorphous vascular morphologies, including linear irregular (serpentine), hairpin (looped), and dotted vessels. The individual blood vessels appear on a structureless white background.

On dermatoscopy, hairpin (looped), dotted, glomerular (coiled), and linear irregular vessels (serpentine) are seen, often surrounded by a whitish background halo (Figures 6d.19–6d.21). Combinations of two or more vascular morphologies result in the so-called polymorphous pattern. Ulceration and blood crusts, if present, appear as irregularly distributed reddish-orange to brownish to black blotches on the surface of the tumor [9, 18].

A 2012 study on raised nonpigmented lesions found that the keratin clues of surface keratin, white circles, and white structureless areas were more robust than these previously noted vessel clues. These keratin clues pointed to SCC/KA with a high specificity [22], with the specificity of white circles in the study-lesions being 87%.

Well- and poorly differentiated variants of SCCs (KA-type and desmoplastic-type, respectively) have different clinical and dermatoscopic features. Poor differentiation in SCC is frequently associated with endophytic growth, no keratin clues, predominant red color of the lesion, and nonspecific vascular features (more than 50% of the tumor's surface covered by vessels, diffuse vessel distribution, higher vessel caliber, and



FIGURE 6D.20 Minimal invasive squamous cell carcinoma at a higher magnification, showing polymorphism of vascular structures. In addition, white circles are apparent.

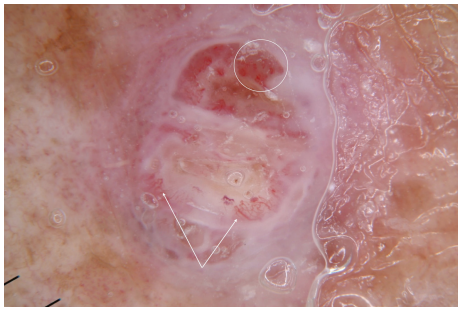

FIGURE 6D.21 Poorly differentiated invasive squamous cell carcinoma showing irregularly distributed and irregularly shaped hairpin (looped) vessels (arrows) and glomerular (coiled) vessels (circle) on a mainly white structureless background. The structureless white component, being due to keratin in squamous cells, is evidence of a degree of differentiation.

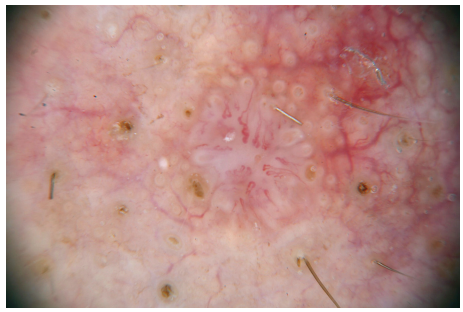

FIGURE 6D.22 Minimally invasive squamous cell carcinoma arising in association with an actinic keratosis. Elongated hairpin (looped) vessels are seen in the SCC; the adjacent skin to the right showing white circles is the actinic keratosis component.

presence of hemorrhages/bleeding). In contrast, frequent features of moderately and well-differentiated tumors include exophytic growth, the presence of scales/keratin clues, and predominant white and white-yellow color [15]. As invasive SCC often arises in association with AK, it is not surprising that the pattern of white circles on a pink/red background described for AK can be seen adjacent to and contiguous with some SCCs (Figure 6d.22).

Pigmented invasive squamous cell carcinoma

Pigmented invasive SCC is rare and reveals dermatoscopically a diffuse, homogeneous blue pigmentation with distinct, irregularly distributed, blue-gray interfollicular pigment. If ulcerated, dark brown to black crusts are visible. Due to the pigmentation, vessels are usually not seen [28, 29]. The differential diagnosis includes pigmented BCC and melanoma (Figure 6d.23).

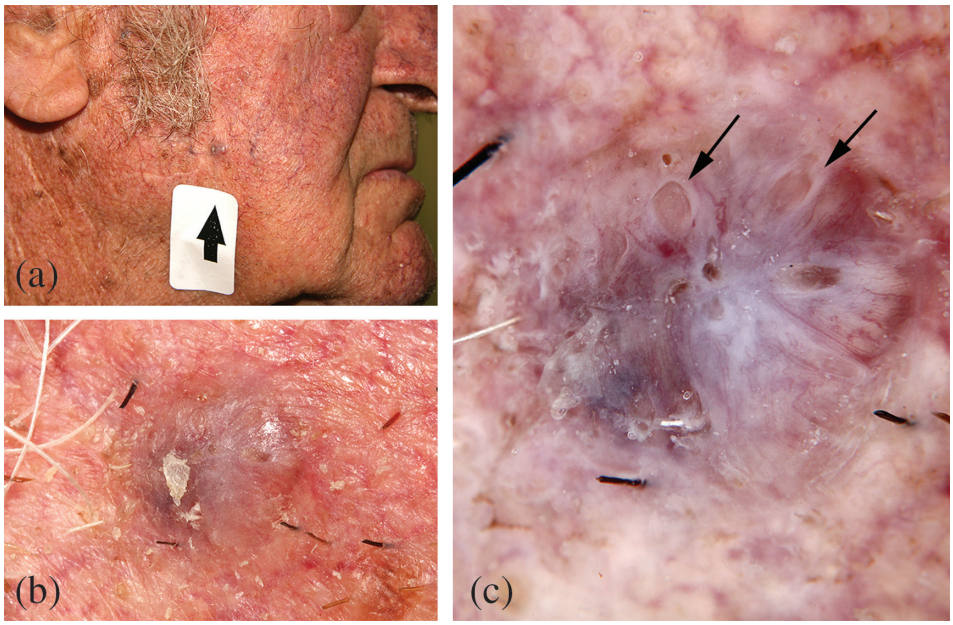

FIGURE 6D.23 Clinical (a), close-up (b), and dermatoscopic (c) images of an invasive pigmented squamous cell carcinoma with surface scale (b) and a dermatoscopic blue and white structureless area as well as white circles (arrows). (From Rosendahl, C., et al., *Dermatol Pract Concept*, 1(1), 14, 2011.)

Invasive SCC arising in pBD may show dermatoscopic features of the latter.

Key points

1. Five factors to evaluate when attempting to diagnose nonpigmented tumors:
   (i) Clinical features, such as rate of growth, the presence of ulceration, and surface keratin
   (ii) Dermatoscopic keratin clues including surface keratin, white circles, and white structureless areas
   (iii) Dermatoscopic morphology of vascular structures
   (iv) Architectural arrangement and distribution of vessels seen under dermatoscopy
   (v) Additional dermatoscopic criteria, such as the rosette sign or strawberry pattern
2. Common vascular structures and patterns encountered in keratinizing tumors
   (i) Hairpin (looped) vessels with a whitish halo
   (ii) Glomerular (coiled) vessels
   (iii) Linear irregular (serpentine)
   (iv) Dotted
   (v) Polymorphous
3. Nonpigmented actinic keratosis on the face typically reveals a "strawberry" pattern composed of white circles on a red background. In addition, white-to-yellow surface scale, blood vessels (straight or coiled) surrounding the hair follicles, and hair follicle openings surrounded by a white circle and filled with a yellowish keratotic plug (targetoid appearance) all contribute to the "strawberry appearance" of these AKs.
4. Nonpigmented Bowen's disease is characterized by glomerular (coiled) vessels, which are typically in a clustered or linear arrangement.
5. KA typically shows surface keratin and often white circles and white structureless areas surrounded by elongated hairpin (linear looped) or linear irregular (linear straight or serpentine) vessels.
6. SCC shows similar features to those seen in KA. Common features include the keratin clues of surface keratin, white circles, and white structureless areas as well as polymorphous vessels, including linear irregular or serpentine, hairpin or looped, glomerular or coiled, and dotted morphologies. Poorly differentiated SCC often lacks keratin clues.
7. Pigmented variants of keratinizing tumors can be difficult to differentiate from melanoma.

References

1. Argenziano, G, Zalaudek, I, Corona, R, et al. Vascular structures in skin tumors: a dermoscopy study. *Arch Dermatol*. 2004;140:1485–9.
2. Bauer, J, Leinweber, B, Metzler, G, et al. Correlation with digital dermoscopic images can help dermatopathologists to diagnose equivocal skin tumours. *Br J Dermatol*. 2006;155:546–51.
3. Bugatti, L, Filosa, G, De Angelis, R. Dermoscopic observation of Bowen's disease. *J Eur Acad Dermatol Venereol*. 2004;18:572–4.
4. Bugatti, L, Filosa, G, De Angelis, R. The specific dermoscopical criteria of Bowen's disease. *J Eur Acad Dermatol Venereol*. 2007;21:700–1.
5. Cameron A, Rosendahl C, Tschandl P, Riedl E, Kittler H. Dermatoscopy of pigmented Bowen's disease. *J Am Acad Dermatol*. 2010;62:597–604.
6. Cuellar, F, Vilalta, A, Puig, S, et al. New dermoscopic pattern in actinic keratosis and related conditions. *Arch Dermatol*. 2009;145:732.
7. Deinlein, T, Richtig, G, Schwab, C, Scarfi, F, Arzberger, E, Wolf, I, Hofmann-Wellenhof, R, Zalaudek, I. The use of dermatoscopy in diagnosis and therapy of nonmelanocytic skin cancer. *J Dtsch Dermatol Ges*. 2016;14:144–51.
8. Errichetti E, Lallas A, Di Stefani A, et al. Accuracy of dermoscopy in distinguishing erythroplasia of Queyrat from common forms of chronic balanitis: results from a multicentric observational study. *J Eur Acad Dermatol Venereol*. 2018 Nov 23.
9. Felder S, Rabinovitz H, Oliviero M, Kopf A. Dermoscopic differentiation of a superficial basal cell carcinoma and squamous cell carcinoma in situ. *Dermatol Surg*. 2006;32:423–5.
10. Haspeslagh, M, Noë, M, De Wispelaere, I, Degryse, N, Vossaert, K, Lanssens, S, Facchetti, F, Van Den Bossche, K, Brochez, L. Rosettes and other white shiny structures in polarized dermoscopy: histological correlate and optical explanation. *J Eur Acad Dermatol Venereol*. 2015;30:311–3.
11. Kittler, H, Riedl, E, Rosendahl, C, Cameron, A. Dermatoscopy of unpigmented lesions of the skin: a new classification of vessel morphology based on pattern analysis. *Dermatopathol Pract Conc*. 2008;14:4.
12. Kreusch, J, Koch, F. Auflichtmikroskopische Charakterisierung von Gefassmustern in Hauttumoren. *Hautarzt*. 1996;47: 264–72.
13. Kreusch, J, Rassner, G. Structural analysis of melanocytic pigment nevi using epiluminescence microscopy. Review and personal experiences. *Hautarzt*. 1990;41:27–33.
14. Kreusch, JF.Vascular patterns in skin tumors. *Clin Dermatol*. 2002;20:248–54.
15. Lallas, A, Pyne, J, Kyrgidis, A, Andreani, S, Argenziano, G, Cavaller, A, Giacomel, J, Longo, C, Malvestiti, A, Moscarella, E, Piana, S, Specchio, F, Hofmann-Wellenhof, R, Zalaudek, I. The clinical and dermoscopic features of invasive cutaneous squamous cell carcinoma depend on the histopathological grade of differentiation. *Br J Dermatol*. 2015;172:1308–15.
16. Lallas A, Tschandl P, Kyrgidis A, et al. Dermoscopic clues to differentiate facial lentigo maligna from pigmented actinic keratosis. *Br J Dermatol.* 2016 May;174(5):1079–85.
17. Mogensen, M, Jemec, GB, 2007, Diagnosis of nonmelanoma skin cancer/keratinocyte carcinoma: a review of diagnostic accuracy of nonmelanoma skin cancer diagnostic tests and technologies. *Dermatol Surg*. 2007;33:1158–74.
18. Pan Y, Chamberlain AJ, Bailey M, et al. Dermatoscopy aids in the diagnosis of the solitary red scaly patch or plaque-features distinguishing superficial basal cell carcinoma, intraepidermal carcinoma, and psoriasis. *J Am Acad Dermatol*. 2008;59:268–74.
19. Papageorgiou C, Apalla Z, Variaah G, Matiaki FC, Sotiriou E, Vakirlis E, Lazaridou E, Ioannides D, Lallas A. Accuracy of dermoscopic criteria for the differentiation between superficial basal cell carcinoma and Bowen's disease. *J Eur Acad Dermatol Venereol*. 2018.
20. Peris, K, Micantonio, T, Piccolo, D, Concetta, M. Dermoscopic features of actinic keratosis. *J Dtsch Dermatol Ges*. 2007;5: 970–6.
21. Pock, L, Drlik, L, Hercogova, J. Dermatoscopy of pigmented actinic keratosis: a striking similarity to lentigo maligna. *Int J Dermatol*. 2007;46:414–16.
22. Rosendahl, C, Cameron, A, Argenziano, G, Zalaudek, I, Tschandl, P, Kittler, H. Dermoscopy of squamous cell carcinoma and keratoacanthoma. *Arch Dermatol*. 2012;148: 1386–92.
23. Russo T, Piccolo V, Lallas A, Argenziano G. Recent advances in dermoscopy. *F1000 Res*. 2016;5:F1000 Faculty Rev-184.
24. Schiffner, R, Schiffner-Rohe, J, Vogt, T, et al., 2000, Improvement of early recognition of lentigo maligna using dermatoscopy. *J Am Acad Dermatol*. 2000;42:25–32.
25. Stante, M, De Giorgi, V, Massi, D, Chiarugi, A, Carli, P. Pigmented Bowen's disease mimicking cutaneous melanoma: clinical and dermoscopic aspects. *Dermatol Surg*. 2004;30:541–4.
26. Stolz, W, Schiffner, R, Burgdorf, WH. Dermatoscopy for facial pigmented skin lesions. *Clin Dermatol*. 2002;20:276–8.
27. Yang, Y, Lin, J, Fang, S, Han, S, Song, Z. What's new in dermoscopy of Bowen's disease: two new dermoscopic signs and its differential diagnosis. *Int J Dermatol*. 2017;56:1022–5.
28. Zalaudek, I, Argenziano, G. Glomerular vessels in Bowen's disease. *Br J Dermatol*. 2004;151:720.
29. Zalaudek, I, Argenziano, G, Leinweber, B, et al. Dermoscopy of Bowen's disease. *Br J Dermatol*. 2004;150:1112–6.
30. Zalaudek, I, Di Stefani, A, Argenziano, G. The specific dermoscopic criteria of Bowen's disease. *J Eur Acad Dermatol Venereol*. 2006a;20:361–2.
31. Zalaudek, I, Giacomel, J, Argenziano, G, et al. Dermoscopy of facial nonpigmented actinic keratosis. *Br J Dermatol*. 2006b;155:951–6.
32. Zalaudek, I, Giacomel, J, Schmid, K, et al. Dermatoscopy of facial actinic keratosis, intraepidermal carcinoma, and invasive squamous cell carcinoma: a progression model. *J Am Acad Dermatol*. 2012;66:589–97.

6E NONMELANOCYTIC LESIONS: SOLAR LENTIGINES, SEBORRHEIC KERATOSES, AND LICHEN PLANUS–LIKE KERATOSIS

Sarah N. Hocker, Harold S. Rabinovitz, Margaret C. Oliviero, and Ashfaq A. Marghoob

Contents

Solar lentigo . . . 116
Seborrheic keratoses . . . 116
Lichen planus–like keratosis . . . 121
Key points . . . 123
References . . . 123

Solar lentigo

Solar lentigines are sharply circumscribed, uniformly pigmented macules that are located predominantly on the sun-exposed areas of the skin, such as the dorsal aspects of the hands, the shoulders, and the scalp. These lentigines are a result of hyperplasia of keratinocytes and melanocytes, with increased accumulation of melanin in the keratinocytes. They are induced by ultraviolet light exposure. Unlike freckles, solar lentigines persist indefinitely. Nearly 90% of Caucasians over the age of 60 years have these lesions. Due to the increased prevalence of lentigines in the elderly, these lesions are sometimes referred to as lentigo senilis. However, younger individuals who have a tendency to burn after ultraviolet exposure can also develop lentigines after acute or prolonged ultraviolet light exposure [3, 16].

Clinically, solar lentigines may be oval, round, or irregular in shape and can vary from a few millimeters to a few centimeters in diameter. Most lesions have a uniform light brown color (Figure 6e.1); however, there are instances when they vary from dark brown to black. One variant of solar lentigo is the "ink spot" lentigo, which has a jet-black color (Figure 6e.2) [1, 9]. Actinic purpura or other signs of solar damage can frequently be found in the skin surrounding solar lentigines.

A solar lentigo is a benign lesion that can evolve to form a pigmented seborrheic keratosis (Figure 6e.3) [7, 23]. Histologically, it is characterized by club-shaped rete ridges with small nub-like extensions. In addition, there is an increased number of melanocytes and increased pigmentation in the basal keratinocytes.

Although most solar lentigines are easily recognized on clinical examination, some lesions pose diagnostic challenges because their clinical appearance resembles that of melanoma (Figure 6e.4). Dermoscopy can be helpful in correctly differentiating a solar lentigo from melanoma.

The key dermoscopic features of solar lentigines are as follows (Figure 6e.5):

1. *Moth-eaten border:* The presence of a sharply demarcated and irregularly curved border is characteristic of solar lentigines. Often, portions of the border are scalloped, giving a moth-eaten appearance (Figures 6e.1 and 6e.3) [12, 1, 17].
2. *Homogeneous light brown pigmentation:* Many lesions have no structures or networks, only containing light brown and structureless areas (Figure 6e.6). The term "jelly sign" has been proposed to describe the pigment quality of these lesions (Figure 6e.7); the pigment appears as if jelly had been smeared on the skin surface [11, 13] (Figure 6e.8).
3. *Pigment network:* There may be an area of faint reticulation (Figures 6e.1 and 6e.3). This correlates with the presence of melanocytes and melanin-filled keratinocytes in the rete ridges [21].
4. *Fingerprint-like areas:* They are areas consisting of fine parallel running lines of light brown to dark brown colors. They resemble the dermatoglyphics of a human fingerprint (Figures 6e.1 and 6e.9) [10, 17].
5. *Pseudonetwork:* Lentigines located on the scalp and face share features of pigmented melanocytic lesions in this special location (see Chapter 11a for further information) revealing a pseudonetwork pattern. This is created when a diffusely pigmented area is interrupted by non-pigmented adnexal openings (Figure 6e.10) [8, 17].
6. *Symmetric follicular pigmentation:* In a solar lentigo, the pigment around hair follicles is distributed in a symmetric fashion, creating small brown circles (Figure 6e.11). The pigment is usually light brown in color and similar to the color of the rest of the lesion. While the pigment is usually distributed symmetrically around the follicle, some follicles may appear asymmetrically pigmented. These asymmetrically pigmented follicles appear as brown crescent-shaped structures. However, these asymmetric follicles will also have a brown color similar to the rest of the lesion. If the color of the pigment around the follicle, whether symmetric or asymmetric, is of a grayish hue or differs from the rest of the lesion, then melanoma needs to enter the differential diagnosis.

Ink spot lentigines have their own distinct dermoscopic pattern (Figures 6e.2, and 6e.12). These lesions have a very prominent black-pigmented network, which has an almost three-dimensional quality under dermoscopy. The network lines can be either thin or thick in width, and the network ends abruptly at the edge of the lesion [1, 9].

Seborrheic keratoses

Seborrheic keratoses are benign epithelial lesions that can appear on any part of the body except for the mucous membranes, palms, and soles. The lesions are quite prevalent in people older than 30 years. The etiology of seborrheic keratoses

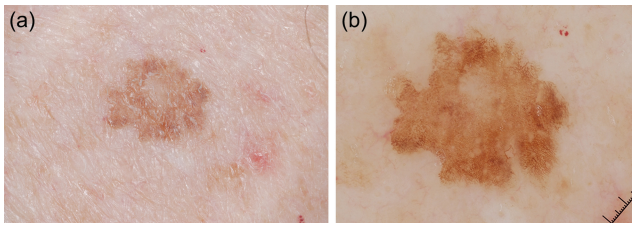

FIGURE 6E.1 (a) This light brown macule with irregular borders is a solar lentigo. (b) Dermoscopy reveals a uniformly light brown lesion with a border that resembles a garment that has been eaten by moths. Fingerprint-like structures are also evident. In addition, in some areas. faint network-like structures are visible.

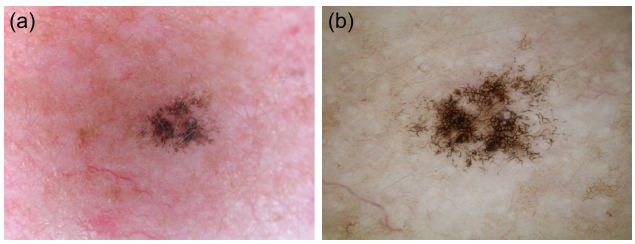

FIGURE 6E.2 (a) Clinical image of an ink spot lentigo. (b) Dermoscopic image revealing a prominent black network that has an almost three-dimensional quality. Some clinicians use the metaphor of a chicken-wire fence to describe the quality of the network in ink spot lentigines.

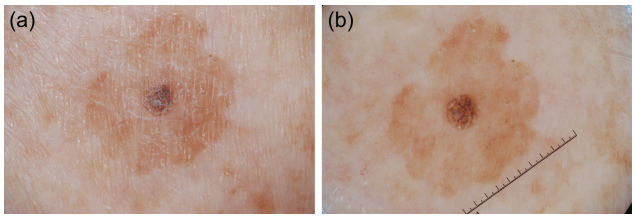

FIGURE 6E.3 (a) Clinical image of solar lentigo transitioning into a seborrheic keratosis. (b) Dermoscopy reveals features of a lentigo consisting of a tan lesion with a moth-eaten border and fingerprint-like structures. In some areas, faint network-like structures are visible. In the center of the lesion is a raised papule with ridges and multiple milia-like cysts; both of these structures are commonly seen in seborrheic keratosis.

remains unclear. Ultraviolet light exposure may be responsible for the development of some seborrheic keratoses, because they appear to evolve from solar lentigines (Figure 6e.3); however, many develop in areas of the skin naturally protected from ultraviolet light exposure, such as the inframammary (intertriginous) areas.

Clinically, early seborrheic keratoses are light to dark brown oval macules with sharply demarcated borders (solar lentigo). As the lesions progress, they transform into plaques with a waxy or stuck-on appearance. The surfaces of these lesions have a warty and keratotic appearance [15]. Often, the lesions have follicular plugs scattered over their surfaces. The size of the lesions varies from a few millimeters to a few centimeters. Histologically, there are several distinct forms of seborrheic

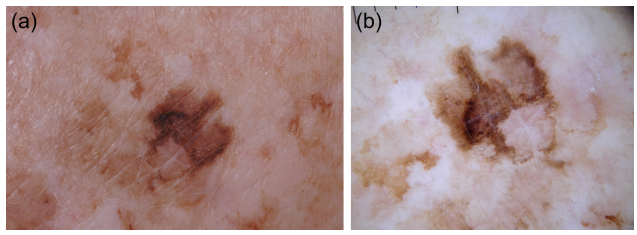

FIGURE 6E.4 (a) This irregularly pigmented lentigo has clinical features that resemble melanoma. (b) Dermoscopy: Although this lesion has a moth-eaten border, its overall pattern is atypical and resembles a melanoma.

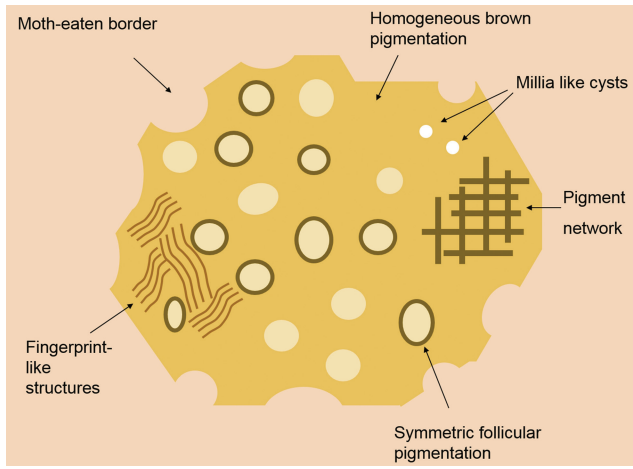

FIGURE 6E.5 Schematic drawing of the criteria of solar lentigines/early seborrheic keratosis.

keratoses; in general [18], the lesions are characterized by papillomatous epidermal hyperplasia of uniform and monotonous keratinocytes and the presence of pseudocysts [5, 21]. The diagnosis of most seborrheic keratoses is straightforward. However, some seborrheic keratoses, especially the deeply pigmented variant, can simulate melanomas. Thin, early lesions have moth-eaten borders and fingerprint-like structures as described previously for solar lentigines. Thicker pigmented seborrheic keratoses have the following typical dermoscopy features (Figure 6e.13) [5, 18]:

1. *Milia-like cysts:* They are white-to-yellow, round structures that appear very bright when contrasted with their dark brown or black surroundings (Figures 6e.14, 6e.15) [5]. The presence of multiple milia-like cysts in pigmented seborrheic keratoses conjures up an image of "stars in the sky." Milia-like cysts can also be seen in nonpigmented seborrheic keratosis (Figure 6e.16) and other lesions such as basal cell carcinoma (BCC), congenital nevi, and melanoma. However, if the lesion is nonmelanocytic and is not a BCC, then the presence of milia-like cysts is diagnostic of seborrheic keratosis, especially if more than three are seen. It is interesting to note that the quality of milia-like cysts appears somewhat different in seborrheic keratosis and melanocytic lesions. In melanoma and congenital nevi, the cysts appear "starry," which is defined as small, bright, and sharp. In seborrheic keratosis, they appear "cloudy," defined as larger and hazier in appearance [19]. Histologically, the cysts

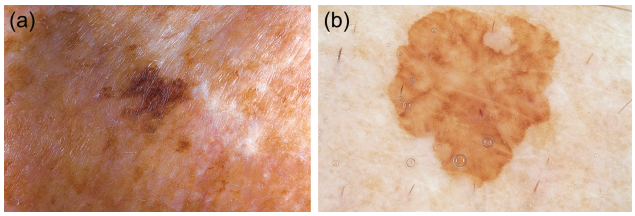

FIGURE 6E.6 (a) Clinical photograph of a light brown solar lentigo. (b) Dermoscopic photograph of a lentigo. The lesion is a characteristic light brown to tan color, with a sharply demarcated border. The superior portion of the border has a scalloped and moth-eaten appearance. The pigment appears as if it has been smeared onto the skin. This is known as the jelly sign.

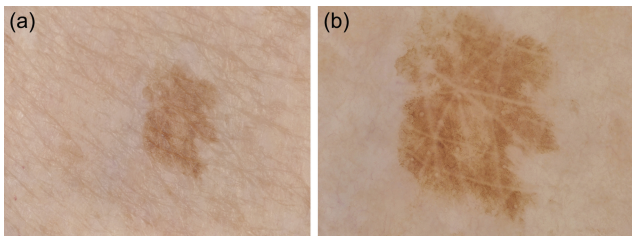

FIGURE 6E.7 (a) Clinical image of a lentigo. (b) Dermoscopy reveals smudging of pigment at approximately 9 o'clock. This smudging is known as the jelly sign.



FIGURE 6E.8 The jelly sign is the unique appearance of pigment that can be observed in some lentigines. In the figure, notice how the pigment creates an almost fish scale–like appearance. The "U"-shaped fish scale–like pigment structures are all oriented in the same direction, resembling jelly that was spread across a slice of toast.

correspond to intraepidermal, keratin-filled cysts [5, 18, 21]. It is important to be aware that milia-like cysts are more conspicuous with nonpolarized dermoscopy and are often difficult to visualize with polarized dermoscopy (Figure 6e.17).

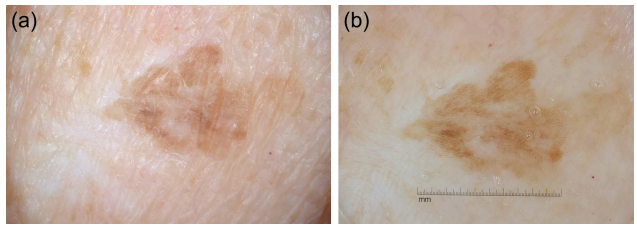

FIGURE 6E.9 (a) Clinical image of a solar lentigo. (b) Dermoscopic image: This lesion is an excellent illustration of the fingerprint pattern. There are many linear and striated network lines arranged parallel to each other. These lines do not interconnect to form a clear reticulated network.

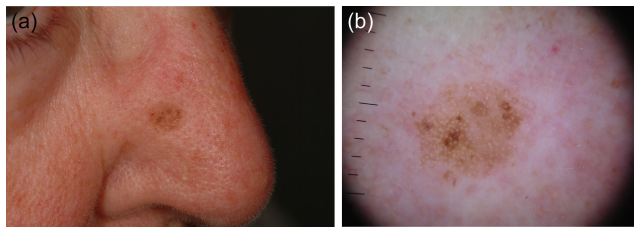

FIGURE 6E.10 (a) Clinical image of a light brown macule. This lesion is a lentigo. (b) Dermoscopy reveals a pseudonetwork pattern.

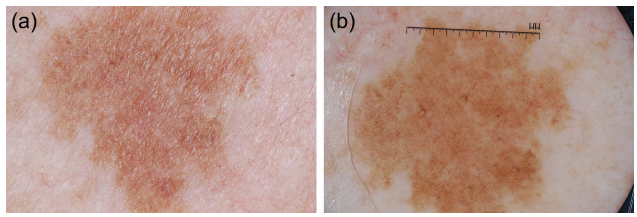

FIGURE 6E.11 (a) Clinical image of a lentigo, which consists of a homogenous tan macule with irregular borders. (b) Dermoscopy reveals fingerprint-like structures and symmetrically pigmented follicular openings. Note that the follicular pigmentation has the same color as the rest of the lesion. This is characteristic of a lentigo.

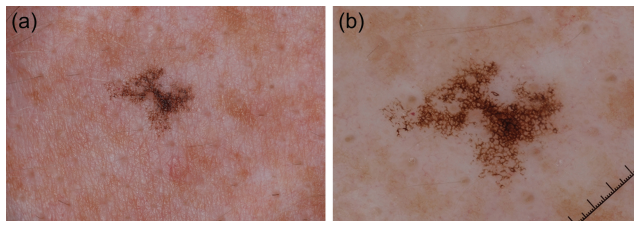

FIGURE 6E.12 (a) This darkly pigmented macule has an irregular border. (b) Dermoscopy: Prominent dark and thick network of an ink spot lentigo.

2. *Comedo-like openings:* They are round to ovoid craters that have black or brown comedo-like plugs. Histologically, they correlate with keratin-filled invaginations of the skin surface (Figures 6e.18 and 6e.19) [5, 18, 21].
3. *Fissures (sulci) and ridges (gyri):* Fissures are comedo-like openings, which are not round but rather, linear

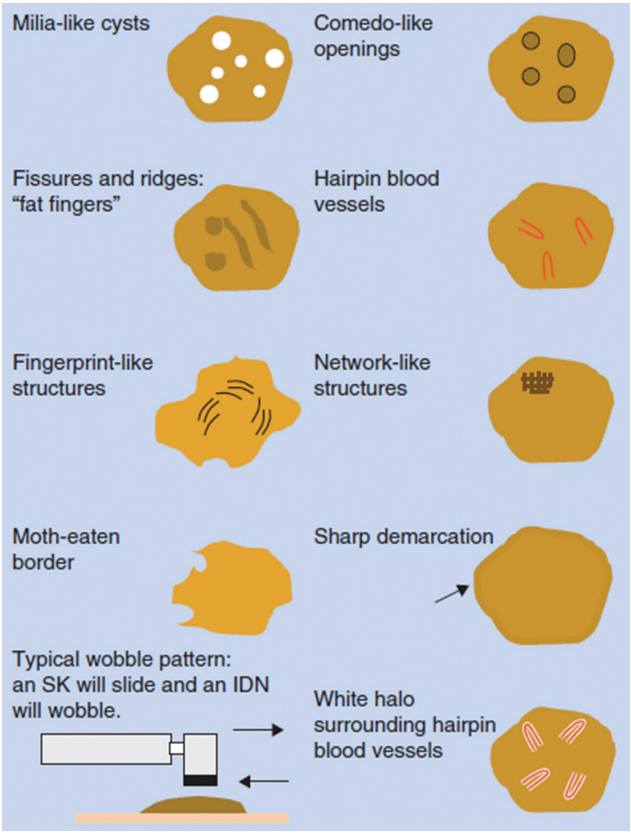

FIGURE 6E.13 Dermoscopy criteria of pigmented seborrheic keratoses.

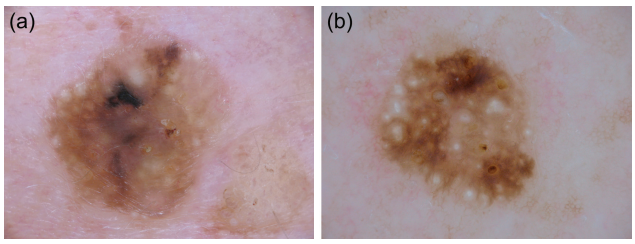

FIGURE 6E.14 (a) Clinical image of a seborrheic keratosis. (b) Dermoscopy reveals multiple milia-like cysts and a few comedo-like openings.

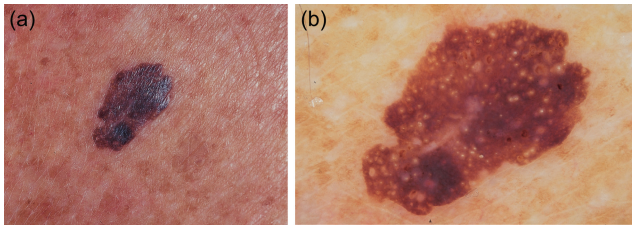

FIGURE 6E.15 (a) Clinical image. (b) A darkly pigmented and raised seborrheic keratosis. Differential diagnoses include atypical nevus and melanoma. Dermoscopic examination shows a lack of network within the lesion, suggesting this is not a melanocytic lesion. The sharp border, presence of comedo-like openings, and milia-like cysts confirm this is a seborrheic keratosis.

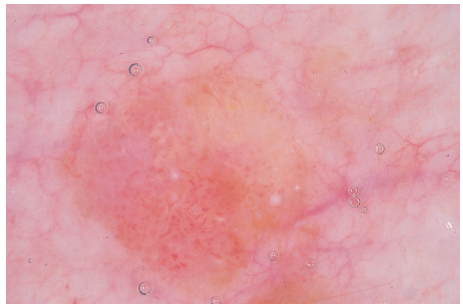

FIGURE 6E.16 Seborrheic keratosis with many hairpin blood vessels and a few milia-like cysts.

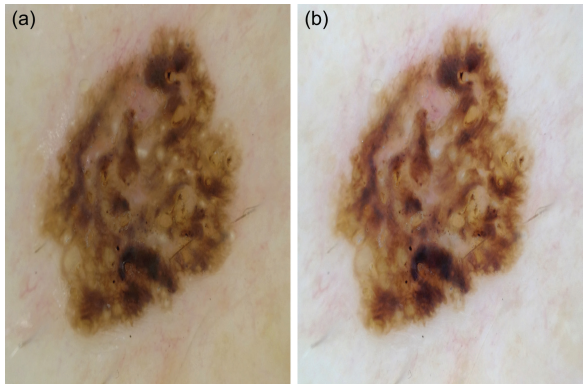

FIGURE 6E.17 (a) This is a seborrheic keratosis viewed with a nonpolarized dermoscope. Notice that the lesion reveals multiple milia-like cysts. (b) When the lesion is viewed with polarized dermoscopy, the milia cysts become less conspicuous.

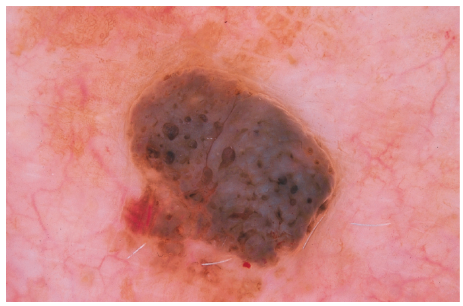

FIGURE 6E.18 Dermoscopic photograph of a seborrheic keratosis. The lesion has sharp borders and numerous comedo-like openings.

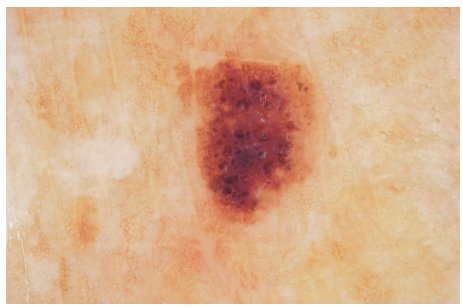

FIGURE 6E.19 Dermoscopic image of a seborrheic keratosis. Dermoscopy reveals numerous comedo-like openings and a few milia-like cysts.

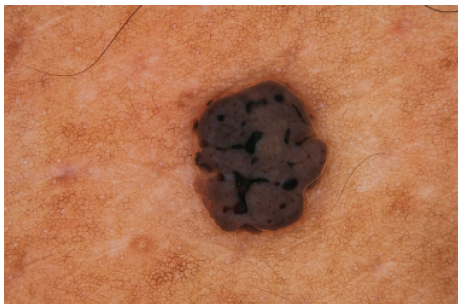

FIGURE 6E.20 Seborrheic keratosis with a characteristic white-blue pigmentation. Large comedo-like openings and fissures (sulci) are present.

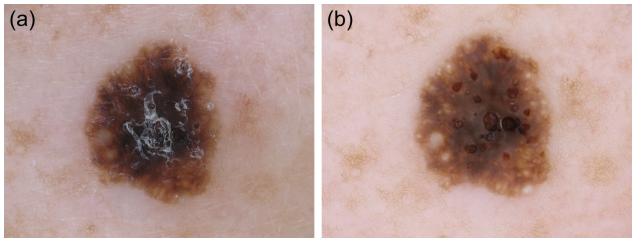

FIGURE 6E.21 (a) Clinical image of a seborrheic keratosis. (b) Dermoscopy reveals interlacing ridges and sulci, resulting in the formation of what appears like a network. Note that the lines of the network-like areas are broader and the holes are larger as compared with the network grid seen in nevi. In network-like areas, the lines are created by ridges, and the holes are due to sulci.

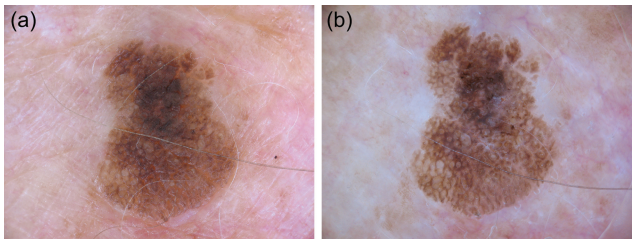

FIGURE 6E.22 (a) Clinical image of seborrheic keratosis. (b) Dermoscopy reveals network-like structures, which are larger than one would expect from a pigment network. This appearance is caused by ridges and multiple comedo-like openings. Examining the lesion clinically via side lighting will help confirm that the network-like areas are due to ridges.

and appear as dark brown to black linear to curvilinear structures within the lesion (Figure 6e.20). The presence of numerous fissures and ridges can result in the formation of network-like structures or result in a cerebriform pattern. Histologically, they represent deep invaginations of the epidermis, filled with keratin [5, 18, 21].

4. *Network-like structures:* Interlacing gyri and sulci can create an appearance of network-like or negative network–like structures (Figure 6e.21). The quality of the grid in a seborrheic keratosis differs from the network grid seen in melanocytic nevi by being significantly larger. However, at times, the network-like structure in a seborrheic keratosis can look very similar to that of a nevus (Figures 6e.22, 6e.23 and 6e.24) [5]. Examining the lesion clinically via side lighting can make the ridges more evident, thereby making it easier to differentiate network-like ridges in seborrheic keratosis from pigment network seen in melanocytic lesions (Figure 6e.25).

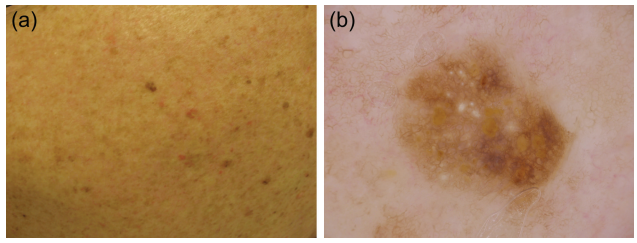

FIGURE 6E.23 (a) Clinical image of a seborrheic keratosis. (b) Dermoscopy reveals network-like structures that can at times resemble the network seen in nevi. However, this seborrheic keratosis can be identified due to the presence of multiple milia-like cysts and yellowish comedo-like openings.

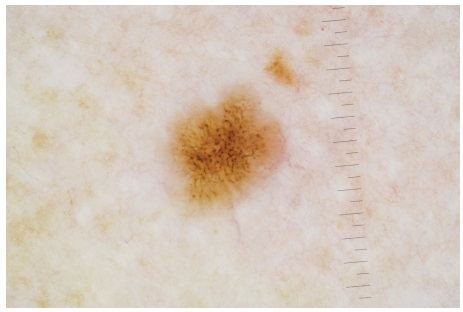

FIGURE 6E.24 This clonal SK reveals features that can be confused with a negative network. In fact, the lesion was biopsied because of this concern, and the pathology revealed a clonal SK.

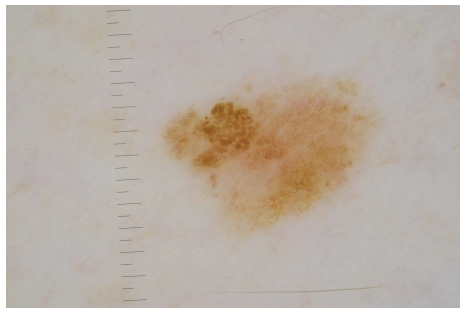

FIGURE 6E.25 This image reveals a reticular nevus with a focal area with a structure that resembles a negative network. This raised concern for a melanoma arising in association with a nevus. Side lighting, however, revealed that this focus actually represented gyri and sulci. A biopsy revealed a SK in association with a nevus.

5. *Cerebriform pattern:* Multiple fissures (sulci) and ridges (gyri) may produce a cerebriform pattern (Figures 6e.26 and 6e.27), where the structures resemble sulci and gyri of the brain (brain-like appearance). These features are generally associated with an acanthotic seborrheic keratosis [5].

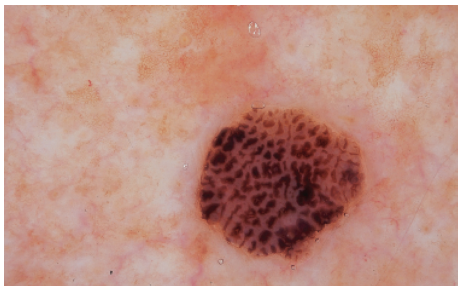

FIGURE 6E.26 Dermoscopic example of seborrheic keratosis with a cerebriform pattern, which is created by the ridges and sulci.

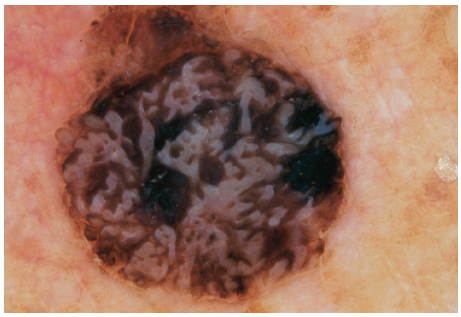

FIGURE 6E.27 Dermoscopic photograph of a seborrheic keratosis showing the cerebriform pattern.

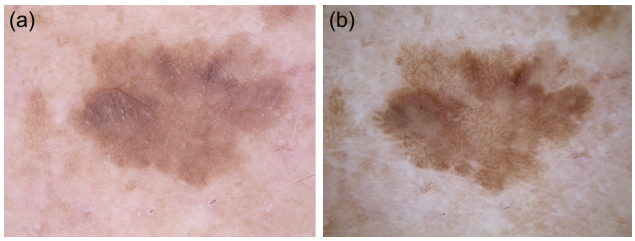

FIGURE 6E.28 (a) Clinical image of a seborrheic keratosis. (b) Dermoscopy reveals numerous curvilinear pigmented ridges, which are also called fat-finger-like structures.

6. *Fat-fingers:* They are linear and wide dermoscopic structures corresponding to ridges. They often appear as short sausage-shaped structures (Figure 6e.28) [10]. The colors of these structures vary from tan/brown to blue, and they can be hypopigmented (Figure 6e.29). The name has been given to these structures because their shapes can resemble a straight finger (linear), bent finger (curvilinear), or fingertip (oval–circular) [10].
7. *Sharply demarcated borders:* As known from clinical examination, seborrheic keratoses often have sharply demarcated borders [5].
8. *Typical hairpin blood vessels:* Some seborrheic keratoses are associated with hairpin vessels (Figures 6e.16, 6e.30, and 6e.31). These hairpin vessels can appear as perfect "U"-shaped vessels or as "U"-shaped vessels that are twisted upon themselves. Typical hairpin blood vessels have a whitish halo around the blood vessel corresponding to the surrounding keratin. It is important to note that some melanomas can have hairpin vessels, but these vessels generally do not have the surrounding white halo but rather, have a pink halo. Similar hairpin vessels on a pink background can be seen in irritated seborrheic keratosis [2, 5, 26].
9. *Wobble test:* This is a dynamic test that can only be performed with a contact dermoscopy device. The test is performed as follows: Once the contact plate of the dermoscope is firmly pressed down (pressure in vertical direction) against the lesion, it is then moved slightly back and forth in the horizontal plane (parallel to the skin surface). Seborrheic keratoses will appear to stick to the glass plate and move en bloc with the movement of the dermoscopic face plate. In other words, they will slide back and forth. In contrast, nevi will not move en bloc but rather, roll back and forth. In other words, intradermal nevi will wobble [4].

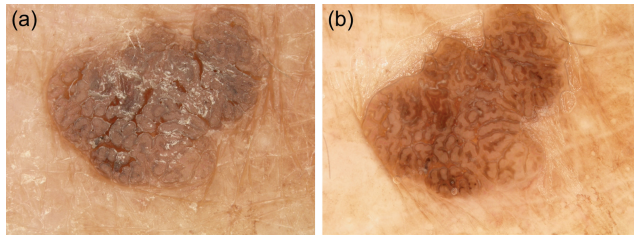

FIGURE 6E.29 (a) Clinical image of a seborrheic keratosis. (b) Dermoscopy reveals numerous curvilinear hypopigmented ridges, which are called fat-finger-like structures.

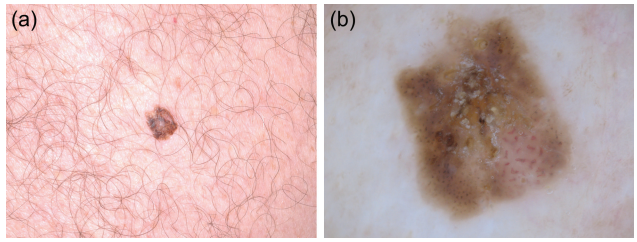

FIGURE 6E.30 (a) This seborrheic keratosis appears as an "ugly duckling" lesion on the back of this patient. (b) Dermoscopy reveals multiple dark thrombosed capillaries. Hairpin vessels with a white halo can be seen in the right lower corner of this seborrheic keratosis.

Knowledge of the above-described dermoscopic features and patterns seen in seborrheic keratosis will often prove valuable in differentiating seborrheic keratoses from other lesions, including melanoma. However, irritated or traumatized seborrheic keratoses can mimic melanoma or squamous cell carcinoma (Figure 6e.32). In these cases, the history of trauma or the presence of typical criteria for seborrheic keratoses in another part of the lesion might be comforting (Figures 6e.33 and 6e.34). However, it is important to remember that skin cancer can develop within a seborrheic keratosis, and thus, a biopsy is justified for atypical-appearing seborrheic keratosis (Figure 6e.35).

Lichen planus–like keratosis

Lichen planus–like keratosis (LPLK) is a relatively common skin lesion found on actinically damaged skin [20, 22].

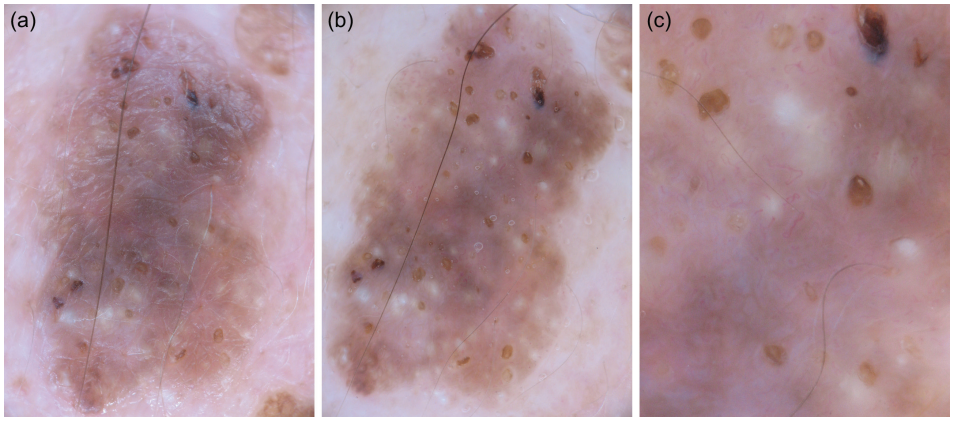

FIGURE 6E.31 (a) Clinical image of an irritated seborrheic keratosis. (b) Dermoscopy reveals numerous milia-like cysts, comedo-like openings, and hairpin vessels with a white halo. (c) Dermoscopy magnified image: Note multiple hairpin vessels, some of which are twisted upon themselves.

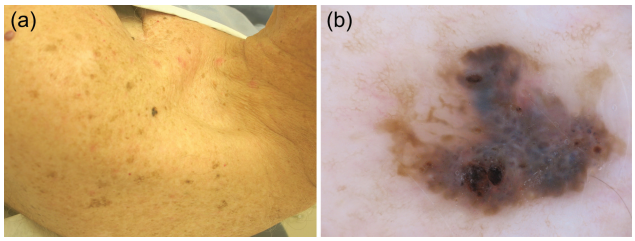

FIGURE 6E.32 (a) Clinical image of an atypical-appearing seborrheic keratosis. This lesion appears as an "ugly duckling" lesion on the shoulder of this patient. (b) Dermoscopy reveals a few comedo-like openings; however, the overall dermoscopic pattern remains difficult to differentiate from melanoma.

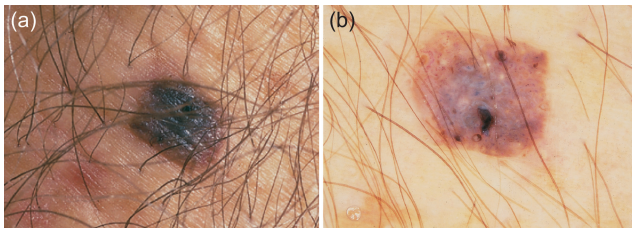

FIGURE 6E.33 (a) Clinical image of a seborrheic keratosis. (b) A pigmented seborrheic keratosis. Dermoscopic examination shows a lesion with a sharp border and multiple milia-like cysts. Numerous hairpin vessels can also be seen.

Clinically, LPLK usually occurs as a solitary lesion with sharply demarcated borders. It may be macular or slightly raised and has brown, tan-brown, violaceous, or red-brown color. There is also a pink variant of LPLK that resembles a BCC. Clinical diagnosis of LPLK lesions is often difficult, since they can mimic cutaneous malignancies. Histologically, LPLK shares some of the features seen in lichen planus. Although the etiology of LPLK remains unknown, it is believed to be mediated by an immunologic or inflammatory response to a pre-existing lesion, such as a seborrheic keratosis, solar lentigo, or actinic keratosis.

Dermoscopy can sometimes help differentiate LPLK from other lesions [6, 25]; however, it does not help differentiate most pink or skin-colored LPLK lesions from BCC and melanoma,

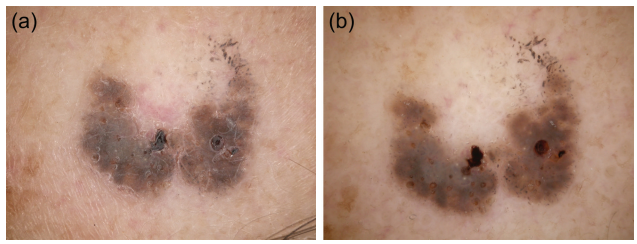

FIGURE 6E.34 (a) Clinical image of a traumatized seborrheic keratosis. (b) Dermoscopy reveals regression structures; however, the presence of multiple milia-like cysts and comedo-like openings is reassuring that the lesion is a seborrheic keratosis. The lesion was biopsied and was consistent with an irritated seborrheic keratosis.

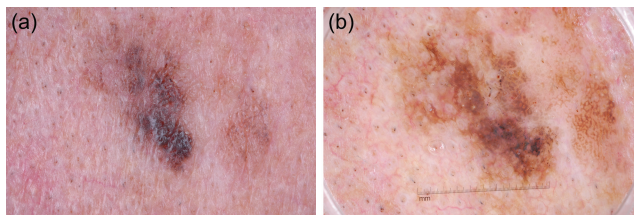

FIGURE 6E.35 (a) Clinical image of an irregular pigmented lesion. (b) Dermoscopy: dermoscopy reveals fingerprint-like areas, fat-finger-like structures, and milia-like cyst. In addition, regression structures consisting of granularity and a blue-white veil are also seen focally within the lesion. This lesion was biopsied and disclosed the presence of a 1.5-mm melanoma arising within a seborrheic keratosis.

because these pink lesions tend to be devoid of any dermoscopic structures (structureless or featureless lesions). To complicate matters, LPLK often reveals crystalline structures, which can also be seen in BCC and melanoma. With that being said, the key dermoscopic features of LPLK are as follows [22, 24]:

1. *Diffuse granular pattern:* This is characterized by the presence of diffuse granularity (peppering) of brown, gray, bluish-gray, or white-gray colors. These granules tend to be coarse and scattered throughout the lesion in a homogeneous fashion (Figures 6e.36 and 6e.37).

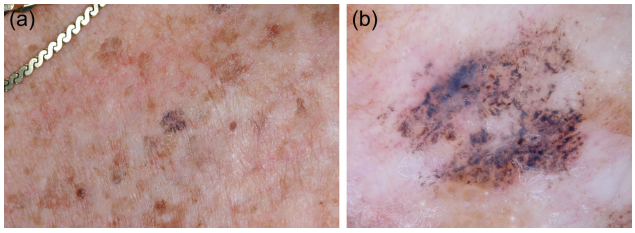

FIGURE 6E.36 (a) Clinical image of a lichen planus–like keratosis. (b) Dermoscopic image showing diffuse clumped bluish-gray granules.

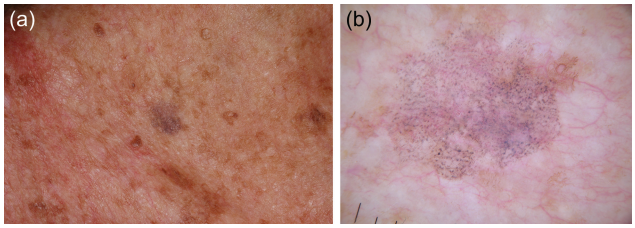

FIGURE 6E.37 (a) Clinical image of a lichen planus–like keratosis. (b) Dermoscopic image showing diffuse fine and coarse granules.

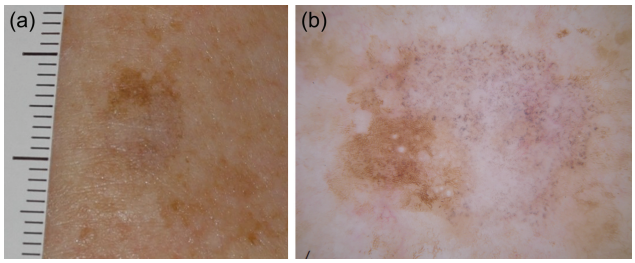

FIGURE 6E.38 (a) Clinical image of a lichen planus–like keratosis. (b) Dermoscopic image: On the right half of the lesion, there are localized fine and coarse granules. On the left half of the lesion, there are two milia-like cysts, fingerprint-like areas, and a moth-eaten border; all features consistent with a diagnosis of a regressing solar lentigo/seborrheic keratosis.

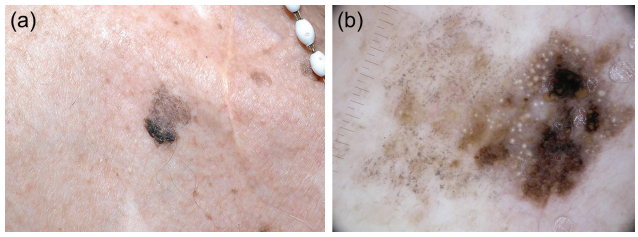

FIGURE 6E.39 (a) Clinical image of a lichen planus–like keratosis. (b) Dermoscopic image: On the left half of the lesion, there is coarse granularity. On the right half of the lesion, there are milia-like cysts and comedo-like openings. The biopsy was consistent with a seborrheic keratosis undergoing regression.

2. *Localized granular pattern:* The presence of grayish-brown granularity (peppering) localized to one focal area within the lesion. Since the regression is only occurring in a part of the lesion, the typical dermoscopy features of the original lesion (seborrheic keratosis, solar lentigo, actinic keratosis) can still be found [14] (Figures 6e.38 and 6e.39).
3. *Pink to orange macule with shiny white lines:* This pattern is fairly structureless but can reveal focal granularity, vessels, and shiny white structures including blotches, lines, and rosettes. This pattern is impossible to differentiate from superficial BCC and amelanotic melanoma based on dermoscopy morphology alone. (Figure 6e.40).

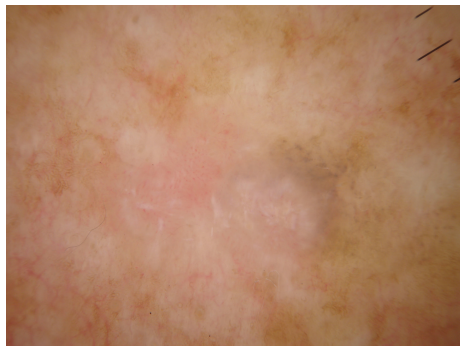

FIGURE 6E.40 This pink lesion has focal gray color, focal polymorphous vessels, and shiny white lines. The differential diagnosis for this pattern of lesions includes LPLK, superficial BCC, and amelanotic melanoma. Biopsy of this lesion revealed LPLK.

The coarse granules in LPLK can be confused with the multiple blue-gray dots (also known as regression structures) seen in melanomas. One differentiating feature, however, is the size of the granules. In LPLK, the granules tend to be larger, coarser, and often appear clumped. In contrast, in melanoma, the blue-gray dots are much smaller and finer in size.

Key points

Solar lentigines can sometimes clinically resemble melanoma. However, most can be distinguished from melanoma by the presence of the following key dermoscopic features of solar lentigines:

- *Moth-eaten border*
- *Homogeneous light brown pigmentation and the jelly sign*
- *Faint pigment network*
- *Fingerprint-like area*
- *Pseudonetwork*
- *Symmetrically pigmented follicular openings*

Dermoscopic features of seborrheic keratoses include the presence of:

- *Milia-like cysts*
- *Comedo-like openings*
- *Fissures and ridges (gyri and sulci)*
- *Network-like structures*
- *Cerebriform pattern*
- *Fat-fingers*
- *Sharply demarcated borders*
- *Typical hairpin blood vessels with a white halo*

Dermoscopic features of LPLK:

- *Diffuse granular pattern*
- *Localized granular pattern*
- *Crystalline structures*

References

1. Argenziano G. Dermoscopy of melanocytic hyperplasias: subpatterns of lentigines (ink spot). *Arch Dermatol*. 2004;140:776.

2. Argenziano G, Zalaudek I, Corona R, et al. Vascular structures in skin tumors: a dermoscopy study. *Arch Dermatol*. 2004;140:1485–9.
3. Bastiaens M, Hoefnagel J, Westendorp R, Vermeer B-J, Bouwes Bavinck JN. Solar lentigines are strongly related to sun exposure in contrast to ephelides. *Pigment Cell Res*. 2004;17:225–9.
4. Braun RP, Krischer J, Saurat J. The "wobble sign" in epiluminescence microscopy as a novel clue to the differential diagnosis of pigmented skin lesions. *Arch Dermatol*. 2000;136:940–2.
5. Braun RP, Rabinovitz HS, Krischer J, et al. Dermoscopy of pigmented seborrheic keratosis: a morphological study. *Arch Dermatol*. 2002;138:1556–60.
6. Bugatti L, Filosa G. Dermoscopy of lichen planus-like keratosis: a model of inflammatory regression. *J Eur Acad Dermatol Venereol*. 2007;21:1392–7.
7. Chamberlain A, NG J. Cutaneous melanoma-atypical variants and presentations. *Aust Fam Physician*. 2009;38:476–82.
8. Cognetta A, Stolz W, Katz B, Tullos J, Gossain S. Dermatoscopy of lentigo maligna. *Dermatol Clin*. 2001;19:307–18.
9. Kaddu S, Soyer H, Wolf I, Rieger E, Kerl H. Reticular lentigo. *Hautarzt*. 1997;48:181–5.
10. Kopf A, Rabinovitz HS, Marghoob M, et al. "Fat fingers:" a clue in the dermoscopic diagnosis of seborrheic keratoses. *J Am Acad Dermatol*. 2006;55:1089–91.
26. Marghoob M, Braun RP, Kopf A. Re: Differentiating vessels from globules on dermoscopy. *Dermatol Surg*. 2005;31:120; author reply 120.
11. Menzies SW. *Dermoscopy: An Atlas*. Sydney: McGraw-Hill; 2009.
12. Menzies SW, Ingvar C, Crotty K, Mccarthy W. Frequency and morphologic characteristics of invasive melanomas lacking specific surface microscopic features. *Arch Dermatol*. 1996a;132:1178–82.
13. Menzies SW, Ingvar C, McCarthy W. A sensitivity and specificity analysis of the surface microscopy features of invasive melanoma. *Melanoma Res*. 1996b;6:55–62.
14. Nagrani N, Jaimes N, Oliviero M, Rabinovitz H. Lichen planus-like keratosis: clinical applicability of in vivo reflectance confocal microscopy for an indeterminate cutaneous lesion. *Dermatology Practical & Conceptual*. 2018;8(3):180–183. doi:10.5826/dpc.0803a06.
15. Pehamberger H, Binder M, Steiner A, Wolff K. In vivo epiluminescence microscopy: improvement of early diagnosis of melanoma. *J Invest Dermatol*. 1993;100:356S–62S.
16. Reguiaï Z, Jovenin N, Bernard P, Derancourt C. Melanoma, past severe sunburns and multiple solar lentigines of the upper back and shoulders. *Dermatology*. 2008;216, 330–6.
17. Schiffner R, Schiffner-Rohe J, Vogt T, et al. Improvement of early recognition of lentigo maligna using dermatoscopy. *J Am Acad Dermatol*. 2000;42, 25–32.
18. Soyer H, Kenet R, Wolf I, Kenet B, Cerroni L. Clinicopathological correlation of pigmented skin lesions using dermoscopy. *Eur J Dermatol*. 2000;10:22–8.
19. Stricklin SM, Stoecker WV, Oliviero MC, Rabinovitz HS, Mahajan SK. Cloudy and starry milia-like cysts: how well do they distinguish seborrheic keratoses from malignant melanomas? *J Eur Acad Dermatol Venereol*. 2011;25:1222–4.
20. Vazquez-Lopez F, Maldonado-Seral C, Lopez-Escobar M, Perez-Oliva N. Dermoscopy of pigmented lichen planus lesions. *Clin Exp Dermatol*. 2003;28:554–5.
21. Yadav S, Vossaert K, Kopf A, Silverman M, Grin-Jorgensen C. Histopathologic correlates of structures seen on dermoscopy (epiluminescence microscopy). *Am J Dermatopathol*. 1993;15:297–305.
22. Zaballos P, Ara M, Puig-Butille S, Malvehy J. Clinical and dermoscopic image of an intermediate stage of regressing seborrheic keratosis in a lichenoid keratosis. *Dermatol Surg*. 2005;31:102–3.
23. Zaballos P, Blazquez S, Puig-Butille S, et al. Dermoscopic pattern of intermediate stage in seborrhoeic keratosis regressing to lichenoid keratosis: report of 24 cases. *Br J Dermatol*. 2007;157:266–72.
24. Zaballos P, Puig-Butille S, Malvehy J. Dermoscopy of pigmented purpuric dermatoses (lichen aureus): a useful tool for clinical diagnosis. *Arch Dermatol*. 2004;140:1290–1.
25. Zalaudek I, Argenziano G. Dermoscopy subpatterns of inflammatory skin disorders. *Arch Dermatol*. 2006;142:808.

6F NONMELANOCYTIC LESIONS: VASCULAR LESIONS

Nicole Nagrani, Natalie M. Williams, and Natalia Jaimes

Contents

Hemangiomas . . . 125
Dermoscopic characteristics. . . . 125
Vascular malformations. . . . 127
Dermoscopic characteristics. . . . 127
Angiokeratoma . . . 127
Dermoscopic characteristics. . . . 127
Lymphangioma circumscriptum . . . 128
Dermoscopic characteristics. . . . 128
Pyogenic granuloma. . . . 128
Dermoscopic characteristics. . . . 129
Kaposi's sarcoma. . . . 129
Dermoscopic characteristics. . . . 129
Cutaneous angiosarcoma . . . 129
Dermoscopic characteristics. . . . 129
Targetoid hemosiderotic hemangioma. . . . 129
Dermoscopic characteristics. . . . 130
Key points . . . 130
References . . . 131

Vascular lesions can be broadly categorized into congenital and acquired. Congenital lesions include two major categories: hemangiomas and vascular malformations. Acquired vascular lesions comprise benign and malignant tumors, including cherry angiomas, angiokeratomas, lymphangioma circumscriptum, pyogenic granuloma, angiosarcoma, and Kaposi sarcoma.

The dermoscopic evaluation of vascular lesions relies on the recognition of vascular patterns, including color, morphology, and arrangement of vascular structures, and other clues, such as scale. The identification and correct interpretation of these structures and patterns will prevent unnecessary skin biopsies of benign lesions while detecting those that deviate from benign patterns and require a skin biopsy to rule out an amelanotic or hypomelanotic malignant tumor, such as melanoma, or Merkel cell carcinoma, among others.

In this chapter, we describe the dermoscopic features of vascular lesions commonly encountered in clinical practice.

Hemangiomas

Hemangiomas are benign vascular proliferations characterized by hyperplasia of different types of blood vessels. Infantile hemangiomas and cherry angiomas are the most common vascular proliferations in children and adults, respectively.[1]

Infantile hemangiomas usually become clinically apparent within the first few days to months of life, yet some newborns may show a telangiectatic patch at the hemangioma site as a premonitory sign. These tumors are characterized by rapid growth or proliferation followed by a slow involution stage. Clinically, they appear as bright red to violaceous papules, plaques, or tumors of different sizes. On the other hand, *cherry hemangiomas*, also known as cherry angiomas or Campbell de Morgan spots, are common cutaneous capillary proliferations that present as small red to violaceous papules in adults. They are commonly found on the trunk and tend to increase in number with age.

Dermoscopic characteristics

Both types of hemangiomas demonstrate similar dermoscopic features. The archetypal dermoscopic structures in hemangiomas are lacunae or lagoons, which are round to oval or angulated, well-defined areas that may vary in size and color. Lacunae may be tightly clustered or scattered throughout the lesion and are often separated by fibrous septae. Based on their location and depth within the skin, their color can range from red, red-white, or red-blue to maroon, blue, blue-black, or even black if thrombosis is present (Figures 6f.1–6f.7).

In more superficial hemangiomas involving the papillary dermis, lacunae demonstrate a bright red color (Figure 6f.2), while deeper hemangiomas reveal a darker color with a bluish-purple hue[2] (Figures 6f.3, 6f.5). Hemangiomas that develop a partial thrombosis can acquire a focal blue-black color and clinically resemble melanoma (Figures 6f.5, 6f.6). If the entire lesion develops thrombosis, then it will present with a jet-black color (Figure 6f.7). Histologically, lacunae correlate to dilated blood-filled vessels in the papillary dermis.

Additional vascular structures that can be seen include isolated dilated vessels (Figure 6f.8).[3] In small early lesions, one or more dilated interconnecting thin-walled vascular channels can be present in the dermal papillae (Figure 6f.9). In older lesions, there is loss of rete ridges and atrophy of the superficial epidermis, with the formation of polypoid lesions composed of dilated communicating channels with scant intervening connective tissue.

DOI: 10.1201/9780429487873-15



FIGURE 6F.1 The classic dermoscopic structure observed in hemangiomas are lacunae, which are often separated by fibrous septae.

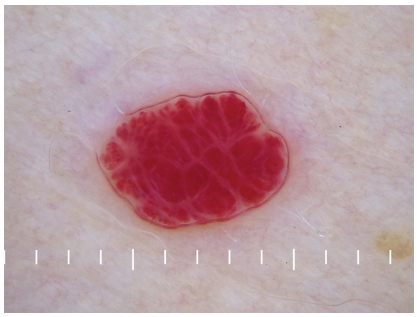

FIGURE 6F.2 Dermoscopy image reveals bright red lacunae in a more superficial hemangioma involving the papillary dermis.

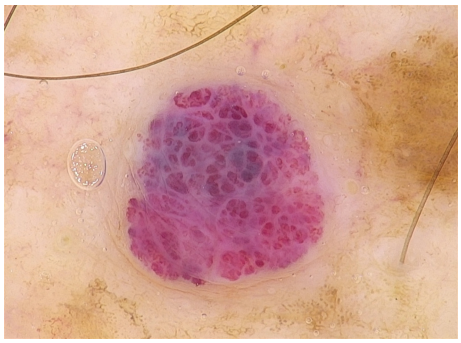

FIGURE 6F.3 Deeper hemangiomas reveal lacunae with a purple-to-bluish hue.



FIGURE 6F.4 Dermoscopic image of a cherry angioma with lacunae separated by septae.

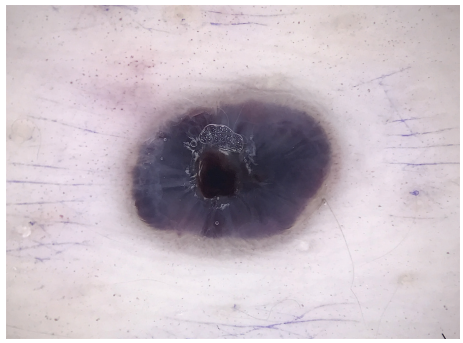

FIGURE 6F.5 Dermoscopic image of a thrombosed cherry angioma with a central crust and violaceous lacunae.



FIGURE 6F.6 Partially thrombosed angioma. Dermoscopy reveals a focal black color.

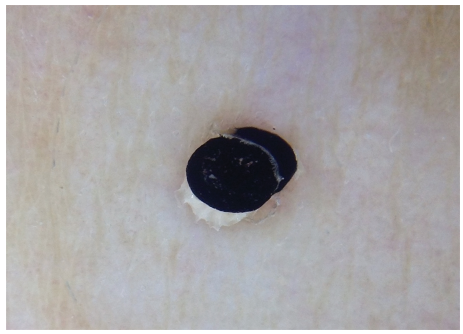

FIGURE 6F.7 Thrombosed angioma showing a jet-black color comprising the entire lesion.

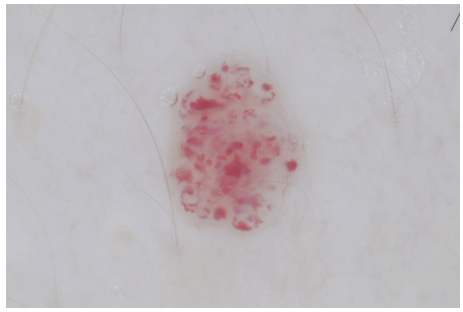

FIGURE 6F.8 Isolated dilated vessels in an angioma.

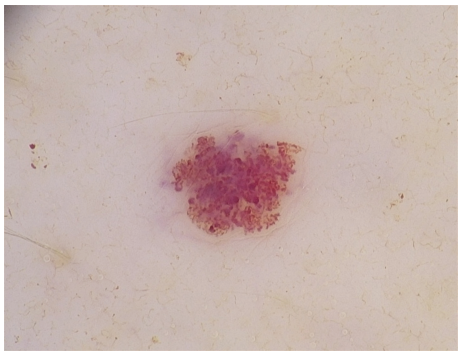

FIGURE 6F.9 Early angioma with dilated interconnecting vessels.

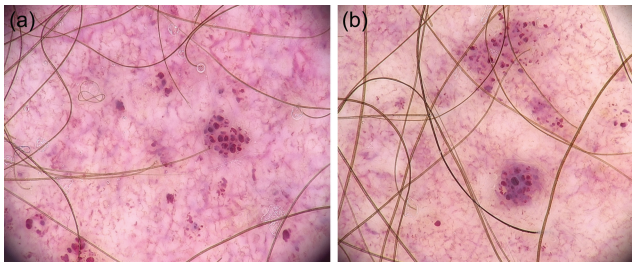

FIGURE 6F.10 Vascular malformation on the thigh of an adult male. Dermoscopy demonstrates linear vessels and red globules.

Vascular malformations

Vascular malformations are congenital lesions characterized by vascular ectasia secondary to the progressive vascular dilatation of pre-existing blood vessels. The most common vascular malformation of the skin is the port-wine stain (PWS), also known as nevus flammeus. PWS is a capillary malformation resulting from a malformation of the post-capillary venules and dermal capillaries within the papillary and reticular dermis. They appear as blanchable pink to red patches anywhere on the body, but usually in a unilateral or segmental distribution with respect to the midline. PWS are persistent lesions, and although their size may remain relatively stable during life, they can become darker, thicker, and eventually, nodular.[4]

The clinical appearance of capillary malformations depends on the depth and size of the vessels; bright red lesions are primarily composed of superficial ectatic vessels, fainter pink lesions consist of smaller and deeper ectatic vessels, and purplish lesions are comprised of larger and deeper vessels.[5]

Dermoscopic characteristics

Two main dermoscopic structures are observed: Red linear vessels and red globules.[6] The more superficial, vertically oriented capillaries within the papillary dermis are represented by red, rounded globular vessels. The deeper, ectatic horizontal capillaries within the reticular dermis are seen as linear vessels[6] (Figure 6f.10). This distinction using dermoscopy has prognostic significance, with superficial PWS being more responsive and amenable to laser treatment.[5]

Angiokeratoma

Angiokeratomas are acquired benign vascular proliferations that result from the dilation of pre-existing blood vessels.

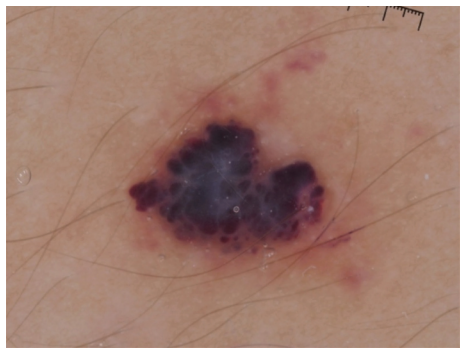

FIGURE 6F.11 Angiokeratoma. Dermoscopy reveals dark lacunae and a whitish veil.

Angiokeratomas present as solitary or clustered, red to violaceous, nonkeratotic papules, ranging from 2 to 10 mm in diameter. As they grow, they become dark red to blue colored and more firm, with a scaly surface or verrucous appearance.[7] The most common variants include the solitary, multiple, and vulva or scrotum variants. The solitary and multiple variants are primarily found on the lower extremities but may present anywhere on the body; those located on the vulva or scrotum, also known as Fordyce spots, are usually multiple, red-to-purple, small papules of less than 5 mm. Other clinical variants include the angiokeratoma of Mibelli, which typically presents on the dorsal and lateral aspects of the fingers and toes of children and teenagers; the angiokeratoma corporis diffusum, characterized by multiple papules in a bathing trunk distribution (i.e., trunk and buttocks); and the angiokeratoma circumscriptum that appears in childhood as grouped or confluent papules on the trunk, arms, or legs.[8] Clinically, angiokeratomas may appear similar to other vascular or nonvascular tumors such as melanocytic nevi, Spitz nevi, melanoma, pigmented basal cell carcinoma, seborrheic keratoses, and dermatofibromas. Histologically, angiokeratomas are characterized by dilated blood vessels in the papillary dermis and epidermal changes, including acanthosis and varying degrees of overlying hyperkeratosis.

Dermoscopic characteristics

Clinical variants of angiokeratoma demonstrate similar histopathological features. As a result, all variants reveal similar dermoscopic findings. The two most common dermoscopic structures observed in angiokeratomas include dark lacunae and whitish veil. According to the location of the ectatic blood vessels, dark colors may vary from red and purple to maroon and black. The whitish veil describes an ill-defined structureless area that gives the appearance of a whitish "ground glass" film overlying the area. Histologically, the whitish veil correlates to the hyperkeratotic and acanthotic epidermis (Figure 6f.11).

Both melanoma and angiokeratoma can share the blue-black sign, defined as the combination of blue and black-pigmented areas involving at least 10% of the lesion surface; however, the ability to clearly identify lacunae separated by septae without vessels within the lacunae is less suggestive of melanoma.[9] Nonetheless, melanoma should always be considered in the differential of lesions demonstrating lacunae-like structures that are irregular, not clearly separated by septae, and containing atypical vessels, especially if a multicomponent pattern with other melanoma-specific structures (i.e., shiny white structures, ulceration) is present (Figure 6f.12). In addition, the



FIGURE 6F.12 Dermoscopic image of a nodular melanoma. Lacunae-like structures that are irregular and not clearly separated by septae, containing atypical vessels, are observed. In addition, other melanoma-specific structures are observed, including shiny white structures and ulceration. (Courtesy of Lina Gómez, MD.)

presence of dark lacunae in combination with a whitish veil has shown a sensitivity of 84% and a specificity of 99% for angiokeratomas. Additional dermoscopic structures that can be seen in angiokeratomas include peripheral erythema and hemorrhagic crusts, which are suggestive of inflammation and bleeding, respectively.[10]

Lymphangioma circumscriptum

Lymphangioma circumscriptum (LC) is a benign hamartomatous malformation characterized by slow-flow vascular lesions comprised of dilated lymphatic channels or cysts lined by lymphatic endothelial cells.[11] LC may be present at birth or develop during the first few years of life. Clinically, they present as clusters of small translucent vesicle-like lesions filled with lymphatic fluid, reminiscent of frogspawn; lesions may also reveal sero-hematic or hemorrhagic papules due to the inclusion of blood.

Dermoscopic characteristics

The most common dermoscopic structures found in LC are lacunae, vascular structures, white lines, scales, and the hypopyon sign.[12] Lacunae are defined as multiple, clustered, well-defined, round to oval structures ranging in color from yellow to red or dark red, depending on the content. The white to yellow-colored lacunae are due to the presence of lymphatic fluid. When blood cells are present in the dilated lymphatic channels, the lacunae appear pink to red. The dark red to violaceous lacunae appear when the lacunae become partially or completely thrombosed.[12]

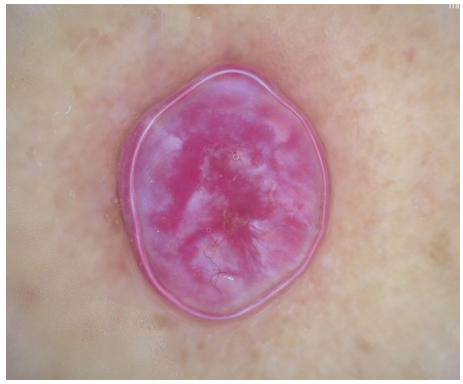

FIGURE 6F.14 Pyogenic granuloma. Dermoscopy demonstrated a red homogeneous area and white rail lines.

The hypopyon sign, or two-tone lacunae, displays the transition from dark to light color and is representative of blood sedimentation, where the cellular components settle at the bottom of the lacunae, and serum rises to the top.[12, 13] In lesions that are clinically indistinguishable from hemangiomas, dermoscopy can be used to identify the hypopyon sign seen in LC[14] (Figure 6f.13).

LC demonstrates two dermoscopic patterns: yellow lacunae separated by pale septae, or yellow to pink lacunae with alternating reddish-blue lacunae representative of hematic content.[15] The latter pattern is the most common pattern associated with LC.[12]

Pyogenic granuloma

Pyogenic granuloma (PG), also known as telangiectatic granuloma or lobular capillary hemangioma, is a benign vascular tumor of the skin and mucous membranes. Although its cause and pathogenesis are poorly understood, it has been suggested that PG is the result of a hyperplastic, neovascular response, secondary to an angiogenic stimulus such as trauma, infection, a drug, or pregnancy.[16] PG may occur at any age and any anatomical site; however, it commonly affects the hands, face, and oral mucosa of children and young adults. PG appears as a solitary, smooth or lobulated, red papule, often surrounded by a collarette of scale. PGs usually undergo rapid growth before

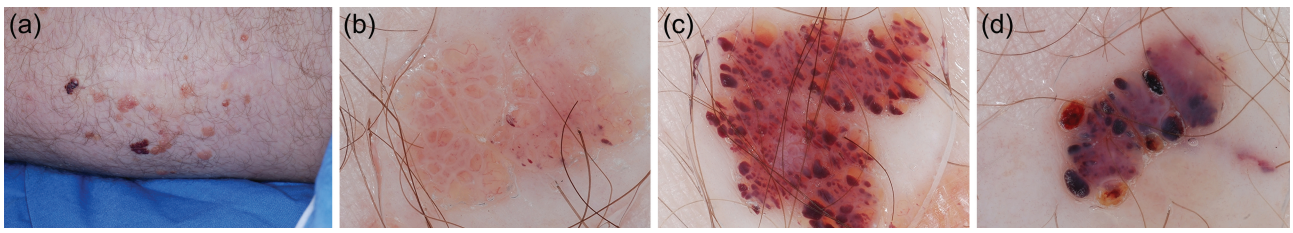

FIGURE 6F.13 (a) Clinical image of a lymphangioma circumscriptum. This lymphangioma recurred after a wide excision. (b) Dermoscopy reveals multiple different lacunar morphologies with clustered clear to yellowish lacunae. (c) Clustered maroon and yellowish lacunae. (d) Thrombosed lacunae as seen in angiokeratomas. (From Zaballos, P., et al., in *Atlas of Dermoscopy*, second edition, Informa, London, 2012. With permission.)

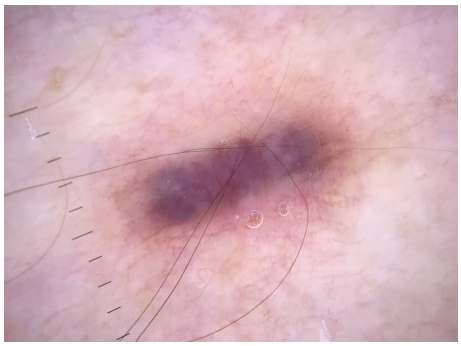

FIGURE 6F.15 Kaposi's sarcoma. The dermoscopic image reveals blue-red pigmentation as the only finding. The clinical context together with the dermoscopic findings suggested the diagnosis.

stabilizing in size but rarely exceed 1 cm. They are characterized by a friable surface and are prone to profuse bleeding and potentially, ulceration.[17]

Dermoscopic characteristics

The dermoscopic structures seen in PG include red homogeneous areas (sensitivity 96.7%, specificity 37.1%), white collarette (sensitivity 73.8%, specificity 90.7%), white rail lines (sensitivity 45.1%, specificity 81.4%), and ulceration.[18] Notably, vascular structures have been appreciated in 45% of PGs, with 31% being in the form of serpentine vessels. Although none of the individual structures is considered an isolated criterion, the presence of a homogeneous red area separated by white rail lines surrounded by a white collarette is highly characteristic for PG[18] (Figure 6f.14).

The red homogeneous area is the most common and sensitive dermoscopic finding; histologically, it correlates to numerous proliferating vessels in a myxoid stroma. The white collarette is the most specific dermoscopic finding, appearing as a ring-shaped squamous structure located at the periphery of the PG, which corresponds to the hyperplastic adnexal epithelium. White rail lines are white streaks that intersect the lesion and correspond to fibrous septae that surround the capillary tufts on histology.[18] Although dermoscopy is a useful tool in evaluating PGs, histopathological confirmation is always recommended, because these lesions may mimic amelanotic melanomas.[19]

Kaposi's sarcoma

Kaposi's sarcoma (KS) is a malignant angioproliferative neoplasm of lymphatic endothelial cell origin. There are four clinical variants: classic, endemic (African), epidemic (HIV-AIDS associated), and iatrogenic (in immunosuppressed patients). KS is linked to co-infection with human herpes virus 8 (HHV-8) in all cases and is characterized by angiogenesis, inflammation, and spindle cell proliferation.

Dermoscopic characteristics

Although there are no specific dermoscopic patterns described for KS, the most common and suggestive structures include the blue-red pigmentation, the rainbow-like pattern, and the scaly surface.[20] The rainbow-like pattern has been described as circumscribed structureless areas demonstrating multiple colors similar to a rainbow. Histologically, it has been correlated to spindle-like cells formed into bundles interweaving through vascular spaces of various sizes and shapes.[20, 21] Only papular or nodular KS lesions show evidence of the rainbow-like pattern, and it may not be visualized in macular or bullae-like KS lesions.[21] It should be underscored that the rainbow pattern is not specific for KS and can also be seen in several non-KS lesions, such as dermatofibromas, PG, melanoma, stasis dermatitis, scars, angiomas, and lichen planus, among others[22] (Figure 6f.15).

Cutaneous angiosarcoma

Cutaneous angiosarcoma is a rare, aggressive neoplasm of endothelial origin with poor prognosis. Three clinical variants of cutaneous angiosarcoma exist: classic angiosarcoma (AS) of the face, neck, and scalp, lymphedema-associated angiosarcoma (LAS), and radiation-induced angiosarcoma (RAS). Clinically, early angiosarcoma lesions appear as ill-defined violaceous to blue-colored spots (Figure 6f.16a,b). As the lesions are deceptively benign-appearing at this stage, the initial diagnosis is often delayed. At advanced stages, the tumor forms violaceous nodules that can ulcerate and bleed easily[23] (Figure 6f.16c).

Dermoscopic characteristics

As it is a rare cancer, the dermoscopic features of cutaneous angiosarcoma are not completely understood. One characteristic feature of classic AS is the presence of various color gradations within the tumor.[24] This can help differentiate AS from other lesions, such as purpura and ecchymosis.[25] AS lesions typically demonstrate any *combination of colors seen in vascular tumors, especially red, purple, and blue*. Pink areas are histopathologically correlated with pleomorphic cells with minimal luminal differentiation, while dark red to purple areas represent an organizing thrombus, hemorrhage, and/or secondary dilated vascular structures.[24] AS lesions often display *"steam-like areas"* with a white central region and increased intensity in color around the lesion periphery.[26] They might also exhibit *white lines*, which correspond to fibrous septae between enlarged neoplastic vascular spaces on histopathology. Notably, AS tends to *lack vascular structures under dermoscopy*, including vessels and lacunae/lagoons, unlike many of the previously discussed vascular lesions.[27] The absence of vascular structures under dermoscopy may be attributed to the indiscriminate proliferation of cancerous cells, precluding the formation of standard vessels. Other dermoscopic features that have been described include regions of linear or ring-shaped erythema, skin-colored perifollicular areas, and whitish veils.[28] In contrast to classic AS, RAS lesions tend to contain colors of lower intensity and present with a more homogeneous pink-white pattern under dermoscopy.[29] Like AS, they may also show color gradations, white lines, and strengthening of color at the lesion margin.[30, 31] To date, the dermoscopic features of LAS in particular have not been described (Figure 6f.16d,e).

Targetoid hemosiderotic hemangioma

Targetoid hemosiderotic hemangioma (THH), also known as hobnail hemangioma, is a benign vascular malformation of lymphatic origin confined to the dermis.[32] The classic description is that of a single, small, violaceous, targetoid papule surrounded by a thin pale area and ecchymotic rim.[33] Over time, the surrounding halo may expand into the periphery until

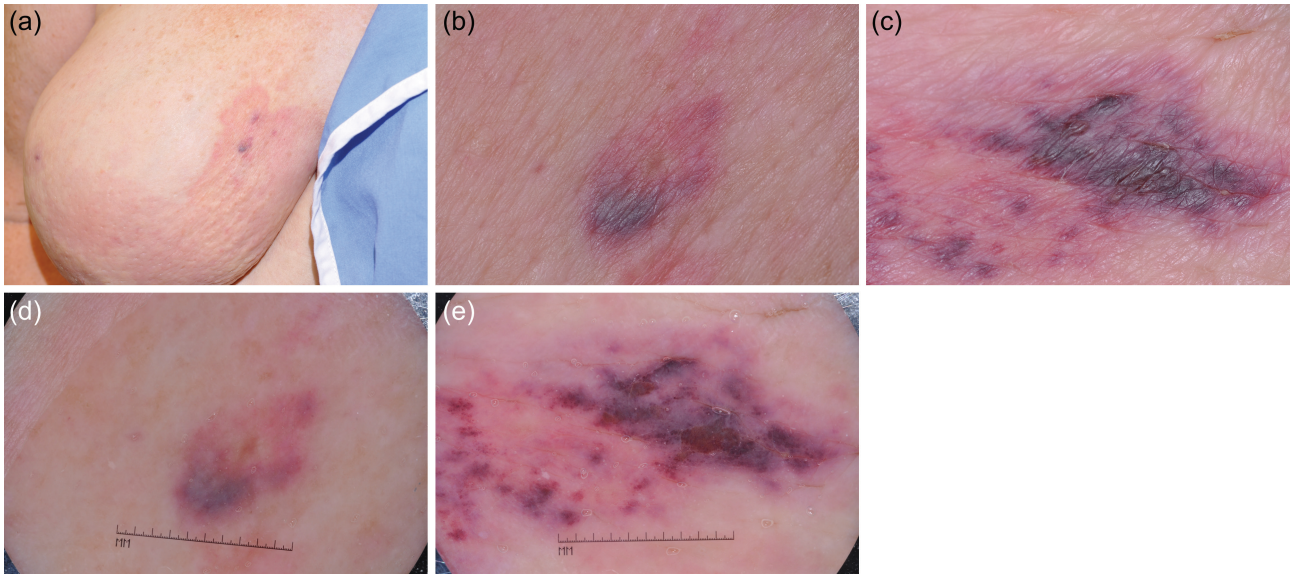

FIGURE 6F.16 Clinical (a) and close-up (b, c) images of an angiosarcoma on the left breast. Although clinically, it simulates a hemangioma, dermoscopy demonstrates lack of lacunae; instead, it reveals a homogeneous pattern with different colors including whitish, pink, red, bluish, and purple (d, e).

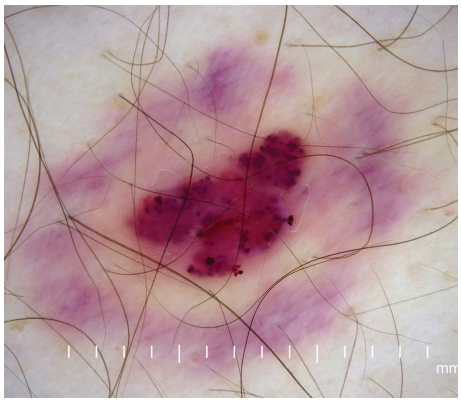

FIGURE 6F.17 Targetoid hemosiderotic hemangioma. Dermoscopy reveals central red and purple small lacunae-like structures, surrounded by a peripheral red-to-purple homogeneous rim.



FIGURE 6F.18 Targetoid hemosiderotic hemangioma. Dermoscopy reveals central red, purple, and black lacunae with a peripheral red homogeneous peripheral rim. (Image courtesy of Alejandra Avila, MD.)

it disappears spontaneously, leaving only a central papule. However, the clinical appearance of THH is often variable and depends upon the stage of its cyclical changes. Histologically, THH exhibits a biphasic growth pattern, with dilated vessels lined by prominent hobnail endothelial cells in the superficial dermis and narrow neoplastic vessels dissecting collagen in deeper parts of the lesion.[34]

Dermoscopic characteristics

The most common dermoscopic pattern consists of central red and/or dark lacunae and a peripheral red-brownish homogeneous area.[35] This pattern may also be seen in other vascular lesions such as angiokeratomas and thrombosed hemangiomas[10, 36] (Figures 6f.17, 6f.18).

Due to the potential for indistinct, nontargetoid, and atypical clinical and dermoscopic presentations of THH, diagnosis should be confirmed by histology to rule out similarly appearing lesions such as amelanotic/hypomelanotic melanoma.[35]

Key points

1. The quintessential dermoscopic structures in hemangiomas and angiokeratomas are lacunae, which can range from red to purple or even black and are separated by white septae.
2. Angiokeratomas often reveals dark lacunae and a whitish veil.
3. Vascular malformations, including PWS, reveal red linear vessels and red globules.
4. Pyogenic granuloma often demonstrates homogeneous red areas, white rail lines, and a collarette of scale.
5. Lymphangiomas also have lacunae; however, they have a clear to yellowish color.
6. While angiosarcomas clinically appear vascular, they lack vascular structures such as lacunae under dermoscopy.

7. The most common dermoscopic pattern in targetoid hemosiderotic hemangioma is central red and/or dark lacunae and a peripheral rim of a red to brownish homogeneous area.

References

1. Léauté-Labrèze C, Harper JI, Hoeger PH. Infantile haemangioma. *Lancet* 2017;390:85.
2. Haliasos EC, Kerner M, Jaimes N, et al. Dermoscopy for the pediatric dermatologist, part ii: dermoscopy of genetic syndromes with cutaneous manifestations and pediatric vascular lesions. *Pediatric Dermatol*. 2013;30(2):172–181.
3. Grazzini M, Stanganelli I, Rossari S, et al. Dermoscopy, confocal laser microscopy, and hi-tech evaluation of vascular skin lesions: diagnostic and therapeutic perspectives. *Dermatol Ther*. 2012;25(4):297–303.
4. Klapman MH, Yao JF. Thickening and nodules in port-wine stains. *J Am Acad Dermatol*. 2001;44(2):300–302.
5. Sevila A, Nagore E, Botella-Estrada R, et al. Videomicroscopy of venular malformations (port-wine stain type): prediction of response to pulsed dye laser. *Pediatric Dermatol*. 2004;21(5):589–596.
6. Vazquez-Lopez F, Manjon-Haces JA, Vazquez-Lopez AC, Perez-Oliva N. The hand-held dermatoscope improves the clinical evaluation of port-wine stains. *J Am Acad Dermatol*. 2003;48(6):984–985.
7. Kim JH, Kim MR, Lee SH, Lee SE, Lee SH. Dermoscopy: a useful tool for the diagnosis of angiokeratoma. *Ann Dermatol*. 2012;24(4):468–471.
8. Bolognia JL, Jorizzo J, Schaffer JV. *Dermatology*. Vol 1. 3rd ed. Philadelphia: Elsevier Saunders; 2012.
9. Argenziano G, Longo C, Cameron A, et al. Blue-black rule: a simple dermoscopic clue to recognize pigmented nodular melanoma. *Br J Dermatol*. 2011;165(6):1251–1255.
10. Zaballos P, Daufi C, Puig S, et al. Dermoscopy of solitary angiokeratomas: a morphological study. *Arch Dermatol*. 2007;143(3):318–325.
11. Wassef M, Blei F, Adams D, et al. Vascular anomalies classification: recommendations from the international society for the study of vascular anomalies. *Pediatrics*. 2015;136(1): e203–214.
12. Zaballos P, Del Pozo LJ, Argenziano G, et al. Dermoscopy of lymphangioma circumscriptum: A morphological study of 45 cases. *Australas J Dermatol*. 2018;59(3):e189–e193.
13. Gencoglan G, Inanir I, Ermertcan AT. Hypopyon-like features: new dermoscopic criteria in the differential diagnosis of cutaneous lymphangioma circumscriptum and haemangiomas? *J Eur Acad Dermatol Venereol*. 2012;26(8):1023–1025.
14. Amini S, Kim NH, Zell DS, Oliviero MC, Rabinovitz HS. Dermoscopic-histopathologic correlation of cutaneous lymphangioma circumscriptum. *Arch Dermatol*. 2008;144(12):1671–1672.
15. Arpaia N, Cassano N, Vena GA. Dermoscopic features of cutaneous lymphangioma circumscriptum. *Dermatol Surg*. 2006;32(6):852–854.
16. Giblin AV, Clover AJ, Athanassopoulos A, Budny PG. Pyogenic granuloma: the quest for optimum treatment: audit of treatment of 408 cases. *J Plast Reconstr Aesth Surg*. 2007;60(9):1030–1035.
17. Zaballos P, Llambrich A, Cuellar F, Puig S, Malvehy J. Dermoscopic findings in pyogenic granuloma. *Br J Dermatol*. 2006;154(6):1108–1111.
18. Zaballos P, Carulla M, Ozdemir F, et al. Dermoscopy of pyogenic granuloma: a morphological study. *Br J Dermatol*. 2010;163(6):1229–1237.
19. Puig S, Argenziano G, Zalaudek I, et al. Melanomas that failed dermoscopic detection: a combined clinicodermoscopic approach for not missing melanoma. *Dermatol. Surg*. 2007;33(10):1262–1273.
20. Hu SC, Ke CL, Lee CH, Wu CS, Chen GS, Cheng ST. Dermoscopy of Kaposi's sarcoma: areas exhibiting the multicoloured 'rainbow pattern'. *J Eur Acad Dermatol Venereol*. 2009;23(10):1128–1132.
21. Satta R, Fresi L, Cottoni F. Dermoscopic rainbow pattern in Kaposi's sarcoma lesions: our experience. *Arch Dermatol*. 2012;148(10):1207–1208.
22. Vazquez-Lopez F, Garcia-Garcia B, Rajadhyaksha M, Marghoob AA. Dermoscopic rainbow pattern in non-Kaposi sarcoma lesions. *Br J Dermatol*. 2009;161(2):474–475.
23. North PE. Vascular neoplasms and neoplastic-like proliferations. In *Dermatology*, J.L. Bolognia, Editor. Amsterdam: Elsevier Limited. p. 2020–2049; 2018.
24. Oiso N, Matsuda H, Kawada A. Various colour gradations as a dermatoscopic feature of cutaneous angiosarcoma of the scalp. *Australas J Dermatol*. 2013;54(1):36–8.
25. Vazquez-Lopez F, et al. Dermoscopic patterns of purpuric lesions. *Arch Dermatol*. 2010;146(8):938.
26. De Giorgi V, et al., Dermoscopy pattern of cutaneous angiosarcoma. *Eur J Dermatol*. 2011;21(1):113–4.
27. Cozzani E, et al. Cutaneous angiosarcoma: the role of dermoscopy to reduce the risk of a delayed diagnosis. *Int J Dermatol*. 2018;57(8):996–7.
28. Minagawa A, Koga H, Okuyama R. Vascular structure absence under dermoscopy in two cases of angiosarcoma on the scalp. *Int J Dermatol*. 2014;53(7):e350–2.
29. Lallas A, et al. Dermoscopy of uncommon skin tumours. *Australas J Dermatol*. 2014;55(1):53–62.
30. Figueroa-Silva O, et al. Dermoscopic pattern of radiation-induced angiosarcoma (RIA). *J Am Acad Dermatol*. 2015;73(2):e51–5.
31. Zalaudek I, et al. Clinical, dermoscopic and histopathological features of spontaneous scalp or face and radiotherapy-induced angiosarcoma. *Australas J Dermatol*. 2013;54(3):201–7.
32. Trindade F, Kutzner H, Tellechea O, Requena L, Colmenero I. Hobnail hemangioma reclassified as superficial lymphatic malformation: a study of 52 cases. *J Am Acad Dermatol*. 2012;66(1):112–115.
33. Santa Cruz DJ, Aronberg J. Targetoid hemosiderotic hemangioma. *J Am Acad Dermatol*. 1988;19(3):550–558.
34. Mentzel T, Partanen TA, Kutzner H. Hobnail hemangioma ("targetoid hemosiderotic hemangioma"): clinicopathologic and immunohistochemical analysis of 62 cases. *J Cutan Pathol*. 1999;26(6):279–286.
35. Zaballos P, Llambrich A, Del Pozo LJ, et al. Dermoscopy of Targetoid Hemosiderotic Hemangioma: A Morphological Study of 35 Cases. *Dermatology*. 2015;231(4):339–344.
36. Moscarella E, Zalaudek I, Buccini P, Cota C, Catricala C, Argenziano G. Dermoscopy and confocal microscopy of thrombosed hemangiomas. *Archives of Dermatol*. 2012;148(3):410.

6G NONMELANOCYTIC LESIONS: CLEAR CELL ACANTHOMA, POROMA, SEBACEOUS HYPERPLASIA, AND OTHER ADNEXAL NEOPLASMS

Constanza Riquelme-Mc Loughlin, Daniel Morgado-Carrasco, Susana Puig, and Cristina Carrera

Contents

Clear cell acanthoma . . . 132
Clinical presentation . . . 132
Histopathology . . . 132
Dermoscopic features . . . 133
Treatment and management . . . 133
Differential diagnosis . . . 133
Adnexal neoplasms . . . 133
Eccrine poroma . . . 133
Clinical presentation . . . 133
Histopathology . . . 133
Dermoscopic features . . . 133
Treatment and management . . . 134
Differential diagnosis . . . 134
Sebaceous neoplasms . . . 134
Sebaceous hyperplasia . . . 134
Clinical presentation . . . 134
Histopathology . . . 135
Dermoscopic features . . . 135
Treatment and management . . . 135
Differential diagnosis . . . 135
Sebaceous adenoma . . . 135
Clinical presentation . . . 135
Histopathology . . . 135
Dermoscopic features . . . 135
Treatment and management . . . 136
Differential diagnosis . . . 136
Tumors of the hair follicle . . . 136
Pilomatricomas . . . 136
Clinical presentation . . . 136
Histopathology . . . 137
Dermoscopic features . . . 137
Treatment and management . . . 137
Differential diagnosis . . . 137
Trichoepithelioma . . . 137
Clinical presentation . . . 137
Histopathology . . . 138
Dermoscopic features . . . 138
Treatment and management . . . 138
Differential diagnosis . . . 138
References . . . 138

The clinical and dermoscopic features of common and rare benign epithelial tumors, including clear cell acanthoma and a few of the most frequently encountered adnexal neoplasms, are discussed in this chapter. While dermoscopy can provide morphological information to help in their diagnosis, it is not uncommon to discover that the dermoscopic findings in many of these neoplasms are nonspecific, requiring a biopsy to rule out a malignancy.

Clear cell acanthoma

Clear cell acanthoma (CCA) is a rare, benign, epithelial tumor. It has no gender predilection and usually develops in middle-aged adults, with a peak incidence between 50 and 60 years of age [13].

Clinical presentation

CCA manifests as an asymptomatic, erythematous, rounded papulo-nodular lesion. It is usually located on the lower limbs and may reveal a peripheral epidermal collarette of scale or superimposed serous exudate [3].

Histopathology

CCA is characterized by a well-demarcated area of psoriasiform epidermal hyperplasia in which the keratinocytes have pale-staining cytoplasm. Mild spongiosis, exocytosis of

neutrophils, and thinning of the suprapapillary plates may also be seen [17].

Dermoscopic features

The presence of glomerular or dotted vessels aligned and arranged in serpiginous lines, resembling a string of pearls in a pearl-necklace, is rarely seen in lesions other than CCA [4, 24]. CCA may reveal a peripheral collarette of scale, and this feature may correlate with the active growth phase of the lesion [3] (Figure 6g.1).

Treatment and management

CCA is a benign lesion; however, if the history or the dermoscopic features are not typical, then a biopsy to confirm the diagnosis is the safest management strategy (Figure 6g.2).

Differential diagnosis

The clinical differential diagnosis includes amelanotic melanoma, inflamed seborrheic keratosis, squamous cell carcinoma, and basal cell carcinoma (BCC); however, the vessel type and the arrangement of the vessels can usually guide the dermoscopist to the correct diagnosis. Nontumoral lesions such as a patch of psoriasis can also manifest features on clinical and dermoscopy that resemble CCA, but the clinical context will assist the clinician in correctly diagnosing such conditions [11].

Adnexal neoplasms

Adnexal neoplasms can be classified according to their adnexal differentiation as eccrine, apocrine, sebaceous, and follicular [2, 16].

Eccrine poroma

Eccrine poroma is a benign adnexal neoplasm composed of glandular ductal cells of eccrine origin [5].

Clinical presentation

Eccrine poromas usually present as asymptomatic, skin-colored to erythematous lesions. Their clinical presentation can vary widely from a sessile or pedunculated papule to large plaques and exophytic tumors. They often occur on the palms and soles; however, a recent study conducted by the International Dermoscopy Society demonstrated that the most frequent location is actually the trunk, followed by the limbs, including acral sites [12]. Pigmented variants of poromas have been described and account for 10–15% of poromas [9].

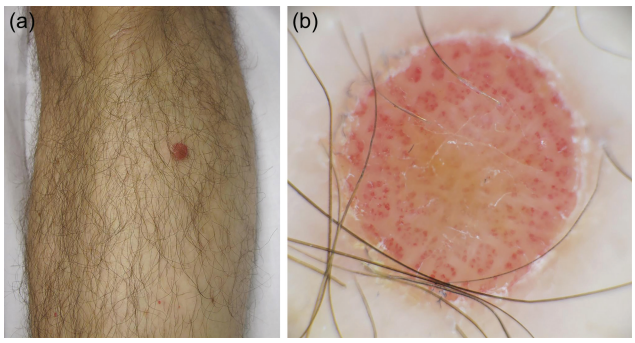

FIGURE 6G.1 Clear cell acanthoma. (a) Papular lesion of unknown evolution located on the left leg of a 45-year-old man. (b) Dermoscopy shows glomerular vessels linearly arranged, resembling a pearl necklace.

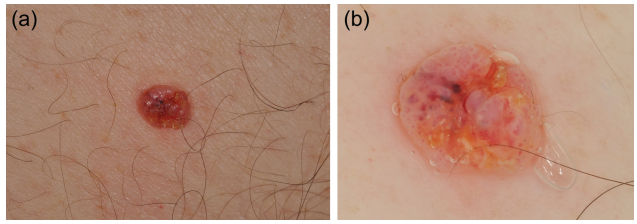

FIGURE 6G.2 Porocarcinoma. (a) Clinically, a pink outlier irregular papule was observed on the back of a male patient. (b) Dermoscopy revealed atypical vessels and yellowish scale. (Image courtesy of Harry Goldin, MD.)

Ulceration may be present, especially if they are located on sites of pressure. Clinically, poromas can simulate benign and malignant tumors.

Histopathology

On histology, proliferation of small round cuboidal cells ("poroid cells") and sweat ducts can be observed. Superficial and deep vascular proliferation combined with the basaloid proliferation can also be identified in some poromas [19].

Dermoscopic features

Dermoscopically, poromas can be highly heterogeneous and can mimic benign and malignant tumors. The most specific dermoscopic features, despite their low prevalence, include branched vessels with rounded endings (formerly known as chalice or cherry blossom–like vessels) and milky-red globules in addition to the white interlacing areas around vessels and yellow structureless areas [12]. None of these features are exclusive to poroma, since malignant tumors, including melanoma and squamous cell carcinoma, can also display similar structures.

Other nonspecific dermoscopic features frequently found in poroma include collarette of keratin/scale, milky-red areas, blood spots, hairpin/looped vessels, and polymorphous vessels, among others [12]. Four main patterns of presentation of poromas have been described by Marchetti et al.

Pattern 1: This is the most frequently encountered pattern and is commonly associated with poromas located on the palms/soles. This pattern reveals a typical hyperkeratotic well-demarcated border (also known as a collarette), blood spots, yellow structureless areas, milky-red globules, milky-red areas, and branched vessels with rounded endings.

Pattern 2: This pattern is usually associated with poromas located on the trunk or nonvolar sites on the extremities. This pattern reveals polymorphous vessels, white interlacing areas around vessels, and branched vessels with rounded endings.

Pattern 3: This pattern is characterized by its small size. These lesions can be located anywhere on the body. While branched vessels with rounded endings can be seen, most often, this pattern does not display any vessels. Lesions with this pattern have clinically simulated nodular BCC.

Pattern 4: This pattern can be found in poromas located anywhere on the body. These lesions are large in size and sometimes pigmented. They frequently reveal blood

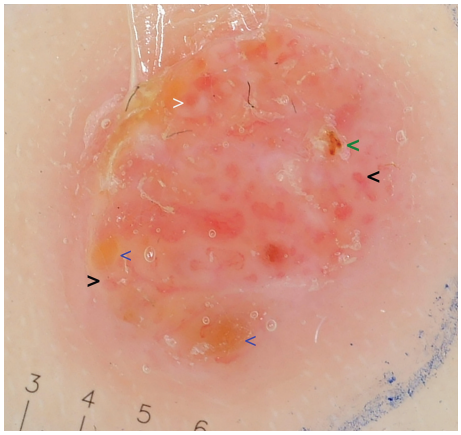

FIGURE 6G.3 Eccrine poroma. Dermoscopic pattern type 1 typical on volar skin with collarette, yellow structureless areas (blue arrows), erosions and crusts (green arrows), milky-red globules and areas (white arrow), and ill-defined vessels with rounded endings (black arrows). (Courtesy of Michael A. Marchetti, MD.)



FIGURE 6G.4 Eccrine poroma. Dermoscopic pattern type 2: Typical small papule on nonacral skin, showing white interlacing areas around multiple polymorphous vessels and branched vessels with rounded endings (black arrows). (Courtesy of Michael A. Marchetti, MD.)

spots, keratin/scale, and looped/hairpin vessels, as can be seen in keratinizing/pseudoepitheliomatous tumors such as seborrheic keratosis [12] (Figures 6g.3 –6g.5).

The dermoscopic characteristics of other apocrine and eccrine neoplasms are documented in Table 6g.1.

Treatment and management

Poromas are benign tumors, but the structures and patterns they manifest are not reliable in differentiating them from malignant tumors such as porocarcinoma (Figure 6g.6). Thus, it is recommended that lesions suspicious for poroma undergo histopathology confirmation [7]. In addition, several cases of malignant transformation [10] and/or coexistence of poroma with porocarcinoma have been reported [1].

Differential diagnosis

As mentioned earlier, poromas can clinically and dermoscopically simulate other tumors, including pyogenic granulomas, angiomas, inflamed seborrheic keratosis, squamous cell



FIGURE 6G.5 Eccrine poroma. Dermoscopic pattern type 3: Plaque characteristically on the trunk, with multiple and polymorphic vessels: Branched with rounded endings (black arrows), glomerular (blue arrow), and lineal vessels (white arrow). (Courtesy of Michael A. Marchetti, MD.)

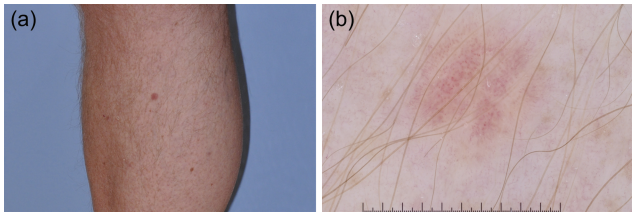

FIGURE 6G.6 Amelanotic melanoma on the leg. Although dermoscopy revealed features like clear cell acanthoma, clinically, there was no collarette of scale. (Image courtesy of Steve Wang, MD.)

carcinomas, BCCs, and melanomas [7]. As a result, lesions suggestive of poroma should be biopsied to confirm the diagnosis and rule out malignancy.

Sebaceous neoplasms

Sebaceous neoplasms are adnexal tumors with sebaceous differentiation that comprise a broad spectrum of histopathologic subtypes [14]. Consistent criteria for the diagnosis and nomenclature of sebaceous tumors are lacking. However, these tumors have conventionally been classified from the benign to malignant spectrum as benign sebaceous hyperplasia, sebaceous adenoma, sebaceoma, and sebaceous carcinoma [8]. Dermoscopic characteristics of these tumors are described in Table 6g.2.

Sebaceous hyperplasia

Sebaceous hyperplasia is a benign neoplasm that represents localized hypertrophy of the sebaceous glands.

Clinical presentation

Sebaceous hyperplasia usually presents as single or multiple white to yellowish soft papules of varying size on the face of middle-aged adults. They may also be found, although less frequently, on the chest, areolae, mouth, and genitals. The center of the lesion often has a slight indentation.

TABLE 6G.1: Dermoscopic Features of Sweat Gland–Derived Neoplasms)

Tumor	Dermoscopic criteria
Hidradenoma (Figure 6g.11)	Homogeneous blue pattern Structureless white areas Hairpin or serpentine vessels
Cylindroma	Unfocused arborizing vessels on a white-pink background Blue-gray dots or globules Ulceration
Syringomas	Yellowish or brownish background Fine linear vessels Areas of hypopigmentation
Syringocystadenoma papilliferum	Polymorphous vessels (linear irregular, glomerular vessels) White halo around vessels Pink/white background
Hidrocystoma	Structureless skin-colored/yellowish to bluish areas Linear vessels
Eccrine poroma	Milky-red globules Yellow structureless areas Blue/gray globules or nests Branched vessels with rounded endings (cherry blossom–like vessels) White interlacing areas around vessels
Porocarcinoma	Polymorphous and atypical vessels (dotted, linear irregular vessels) Ulceration

Source: Adapted from Lallas, A., et al., *Australas J Dermatol*, 55(1), 55–62, 2014.

Histopathology

Grouped white-yellowish nodules can be identified at the center of the lesion, which correspond to hyperplastic sebaceous glands. Within each gland, mature sebaceous lobules or acini surround and connect a dilated central sebaceous duct.

Dermoscopic features

Sebaceous hyperplasia presents with white to yellowish polylobular round structures (also known as "popcorn"-like structures) with a central umbilication (known as the bonbon toffee sign) [8], which are surrounded by groups of nonarborizing, branching vessels that extend toward the center but do not cross the midline. This vascular pattern has been described as "crown vessels" and is characteristic of, although not specific to, hyperplastic sebaceous glands [22] (Figure 6g.7)

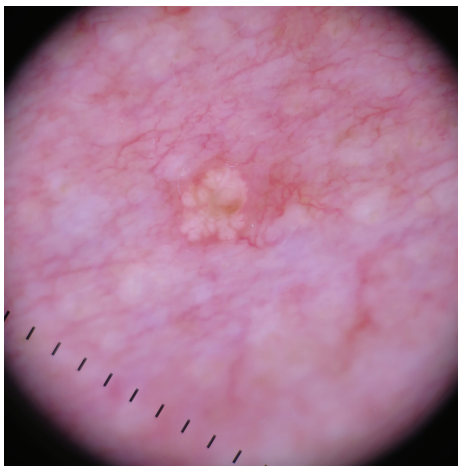

FIGURE 6G.7 Sebaceous hyperplasia. A tiny papule located on the left cheek of a woman. Dermoscopy shows a polylobular whitish structure with crown vessels at the periphery and a small ostium in the center.

Treatment and management

Sebaceous hyperplasia does not require treatment unless for cosmetic purposes. Some sebaceous hyperplasia papules can resemble BCC on both clinical and dermoscopy, and in such lesions, a biopsy would be justified.

Differential diagnosis

Dermoscopy is highly useful to rule out BCC on the face. Differential diagnosis includes other sebaceous neoplasms, dermal nevus, fibrous papule, molluscum contagiosum, and syringomas, among others (Table 6g.2).

Sebaceous adenoma

Sebaceous adenoma, sebaceoma, and sebaceous carcinoma are uncommon in the general population but are commonly encountered in patients with Muir-Torre syndrome (MTS). Sebaceous adenomas are rare, benign neoplasms that originate from sebaceous glands. They are the most common histopathologic tumor found in patients with MTS (reported frequency around 70% [18]), and therefore, with their detection, it is advisable to rule out MTS.

Clinical presentation

Sebaceous adenomas usually appear in midlife as white to pink nodules on the head and neck region. However, in MTS, they can develop at a younger age and are often found on the torso.

Histopathology

Sebaceous adenomas are well-circumscribed nodular dermal proliferations consisting of lobular aggregations of fully differentiated sebocytes with basaloid germinative cells at the periphery [14]. Immunohistochemical study for proteins MSH2, MLH1, and MSH6 should be performed to rule out MTS [21].

Dermoscopic features

Central indentation associated with a structureless ovoid white-yellow center, radial telangiectasia, known as crown vessels (similar to sebaceous hyperplasia), and red blood crusts (Figure 6g.8).

TABLE 6G.2: Dermoscopic Features of Sebaceous Gland–Derived Neoplasms

Tumor	Dermoscopic criteria
Sebaceous hyperplasia	Yellow/white polylobular or structureless central area Central umbilication Crown vessels (vessels do not cross through the center of the lesion)
Sebaceoma	Homogeneous yellowish central structure Crown vessels
Sebaceous adenoma	Structureless ovoid white-yellow center Yellowish background Central indentation Yellow comedo-like globules (without central indentation) Red blood crusts Crown vessels
Sebaceous carcinoma	Polymorphous and atypical vessels Yellowish background Ulceration
Sebaceous cyst	White/yellow central structure Yellowish background Crown vessels

Source: Adapted from Lallas, A., et al., *Australas J Dermatol*, 55(1), 55–62, 2014.

TABLE 6G.3: Dermoscopic Features of Hair Follicle–Derived Tumors ()

Tumor	Dermoscopic criteria
Trichodiscoma	White globules Blue/gray nests Linear vessels
Trichoblastoma (Figure 6g.12)	Blue-gray dots or globules Arborizing vessels
Trichilemmal cyst	White/yellow central structure Linear branched vessels at periphery Structureless blue pigmentation
Trichilemmoma	Keratin Red iris-like structures White halos surrounding vessels
Trichilemmal carcinoma	Polymorphous and atypical vessels White/yellow structureless areas Ulceration
Trichoepithelioma	Pearly white background Multiple milia-like cysts and rosettes In-focus arborizing vessels Ivory/white background (in desmoplastic subtype)
Pilomatricoma	Irregular white and/or yellow structures White streaks Structureless gray-blue areas Reddish areas Linear and hairpin vessels Ulceration

Source: Adapted from Lallas, A., et al., *Australas J Dermatol*, 55(1), 55–62, 2014.

Treatment and management

Surgical removal of the tumor is the mainstay of management. In the presence of sebaceous adenomas and loss of MSH2/6/1 expression, it is incumbent to rule out mismatched repair genes, germline defects, and familial colorectal Lynch syndrome. If confirmed, referral for genetic counseling is recommended.

Differential diagnosis

Sebaceous hyperplasia, sebaceous carcinoma, sebaceous epitheliomas, BCC, sebaceoma, and nevus sebaceous, among others.

Tumors of the hair follicle

In general, the dermoscopic pattern of benign follicular tumors shows structures overlapping with BCC, such as linear branching vessels and blue-gray dots or globules [20]. The presence of "white structures" has been suggested as a dermoscopic clue suggesting a follicular tumor [8]. The dermoscopic features of tumors of the hair follicles are summarized in Table 6g.3.

Pilomatricomas

Pilomatricoma is a dermal or subcutaneous tumor derived from immature hair matrix cells.

Clinical presentation

Pilomatricomas are usually located on the head, neck, and upper extremities of children and adolescents [8]. Clinically, they are firm, solitary, and sometimes partially pigmented with a gray to bluish color.

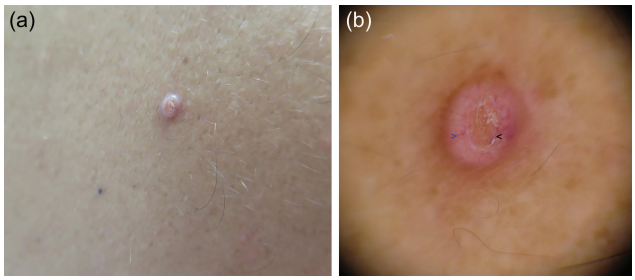

FIGURE 6G.8 Sebaceous adenoma. (a) A skin-colored well-circumscribed nodular lesion on the left cheek of a patient with Muir Torre syndrome. (b) Dermoscopy shows a central crater with a structureless ovoid yellow center and lineal (black arrow), out-of-focus telangiectasia at the periphery (blue arrow). Immunohistochemical staining was performed and revealed lack of expression of MSH-2 and MSH-6.

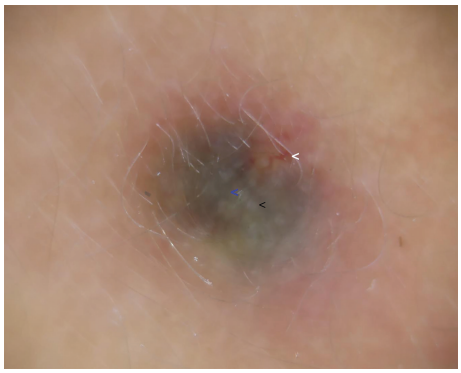

FIGURE 6G.9 Pilomatricoma. A solitary lesion on the face of a 9-year-old girl. Dermoscopy shows the presence of blue-gray structureless areas (blue arrow) and yellow/whitish round structures (black arrow). Some linear vessels are seen at the periphery of the lesion (white arrow).

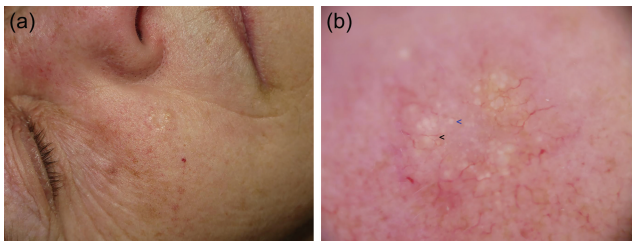

FIGURE 6G.10 Trichoepithelioma. (a) A skin lesion located on a sun-exposed area. (b) Dermoscopy shows multiple white milia-like cysts (blue arrow) in a pink-whitish or ivory background. The image also shows the presence of in-focus fine arborizing vessels (black arrow), resembling BCC (infundibulecystic type).

Histopathology

Early lesions can be cystic, consisting of mitotically active, uniform, basaloid cells covering the cystic cavity, and transformed into pale eosinophilic anucleated shadow/ghost cells admixed with keratin. Older pilomatricomas become solid and present a prominent shadow cell component, keratin debris, secondary multinucleated giant cells, and dystrophic calcification [2].

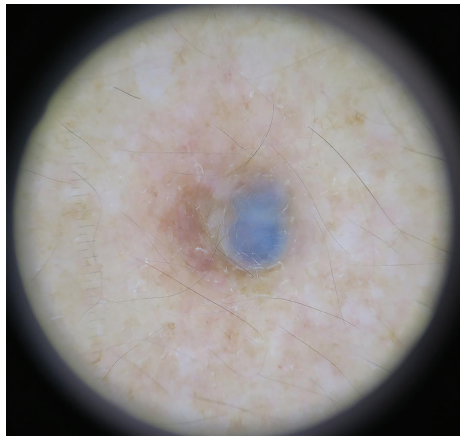

FIGURE 6G.11 Hidradenoma. A nodular lesion located on the back of a middle-aged woman. Dermoscopy shows a blue homogeneous nodular area with white structureless areas.

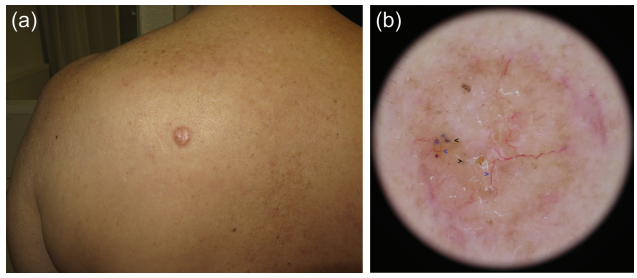

FIGURE 6G.12 Trichoblastoma. Dermoscopy shows the presence of blue-gray dots (black arrows), white structureless areas, and arborizing vessels (blue arrows). Note the striking similarity with a BCC; diagnosis should always be histopathologically confirmed.

Dermoscopic features

Dermoscopic structures found in pilomatricomas include irregular yellow and/or whitish structures and streaks that correspond histologically to the presence of calcification. In addition, ulceration and small structureless gray-blue areas can also be seen [23]. Vascular structures including reddish homogeneous areas, hairpin vessels, and serpentine vessels have also been noted in pilomatricomas [22]. (Figure 6g.9). Unfortunately, there are no dermoscopic structures that are diagnostic of these tumors.

Treatment and management

Simple excision for the purpose of diagnosis and to prevent local persistence and growth is the management of choice.

Differential diagnosis

Epidermoid or pilar cyst, calcinosis cutis, and glomus tumor enter the differential diagnosis.

Trichoepithelioma

Trichoepithelioma is another benign follicle tumor.

Clinical presentation

Trichoepitheliomas, including desmoplastic trichoepitheliomas, can present as: (1) an isolated pink papule (5 mm in diameter) on hair-bearing skin, especially on sun-exposed areas of

the face in young to middle-aged adults, or (2) as multiple small (1–5 mm) lesions in children and adolescents, usually involving the upper lip, cheeks, and paranasal region. In patients with multiple trichoepitheliomas, one needs to consider an autosomal dominant familial disorder such as Rombo syndrome [2]. Trichoepitheliomas tend to remain stable over years to decades.

Histopathology

Histologically, trichoepitheliomas are characterized by basaloid cells arranged in small cords and infundibulocystic structures containing keratin surrounded by fibrotic collagen [6].

Dermoscopic features

Dermoscopy of these lesions reveals features that can also be seen in BCC, including in-focus arborizing vessels, multiple milia-like cysts, and rosettes amidst a porcelain white background [15]. (Figure 6g.10).

Treatment and management

A biopsy can be performed to confirm the diagnosis.

Differential diagnosis

Clinically, trichoepithelioma may simulate trichoblastoma, trichilemmomas, molluscum contagiosum, syringomas, milia, or sebaceous hyperplasia, and especially, BCC. Often, the only clinical clue to distinguish a desmoplastic trichoepithelioma from a BCC is the history of stability in the former over a period of many years.

References

1. Abarzúa Á, Álvarez-Véliz S, Moll-Manzur C. Concomitant Poroma and Porocarcinoma. *An Bras Dermatol.* 2017;92(4):550–52. doi:10.1590/abd1806-4841.20175719.
2. Alsaad KO, Obaidat NA, Ghazarian D. Skin adnexal neoplasms: part 1: an approach to tumours of the pilosebaceous unit. *J Clin Pathol.* 2007;60(2):129–44. doi:10.1136/jcp.2006.040337.
3. Cunha DG, Kassuga-Roisman LEBP, Silveira LKCDB, Macedo FCD. Dermoscopic features of clear cell acanthoma. *An Bras Dermatol.* 2018;93(3):449–50.
4. Espinosa AED, Akay BN, González-Ramírez RA. 'String of pearls pattern': report of three cases of non clear-cell acanthoma. *An Bras Dermatol.* 2017;92(5) Supplement 1:142–44.
5. Goldman P, Pinkus H, Rogin JR. Eccrine poroma; tumors exhibiting features of the epidermal sweat duct unit. *A.M.A. Arch Dermatol.* 1956;74(5):511–21.
6. Kunz, M, Kerl K, Braun RP. Basal cell carcinoma mimicking desmoplastic trichoepithelioma: a case with correlation of dermoscopy and histology. *Case Rep Dermatol.* 2018;10(2):133–37. doi:10.1159/000489164.
7. Lallas A, Chellini PR, Guimaraes MG, Cordeiro N, Apalla Z, Longo C, Moscarella E, Alfano R, Argenziano G. Eccrine poroma: the great dermoscopic imitator. *J Eur Acad Dermatol Venereol.* 2016;30(10):e62–63. doi:10.1111/jdv.13300.
8. Lallas A, Moscarella E, Argenziano G, Longo C, Apalla Z, Ferrara G, Piana S, Rosato S, Zalaudek I. Dermoscopy of uncommon skin tumours. *Australas J Dermatol.* 2014;55(1):55–62. https://doi.org/10.1111/ajd.12074.
9. Lan CC, Yu HS, Wu CS, Tsai KB, Wen CH, Chen GS. Pigmented Eccrine Poroma with Enhanced Endothelin-1 Expression: Implications for Mechanism of Hyperpigmentation. *Br J Dermatol.* 2005;152(5):1070–72. https://doi.org/10.1111/j.1365-2133.2005.06560.x.
10. Landa NG, Winkelmann RK 1991. "Epidermotropic Eccrine Porocarcinoma." *Journal of the American Academy of Dermatology* 24 (1): 27–31.
11. Lyons G, Chamberlain AJ, Kelly JW. Dermoscopic features of clear cell acanthoma: five new cases and a review of existing published cases. *Australas J Dermatol.* 2015;56(3):206–11. doi:10.1111/ajd.12206.
12. Marchetti MA, Marino ML, Virmani P, Dusza SW, Marghoob AA, Nazzaro G, Lallas A et al. Dermoscopic features and patterns of poromas: a multicentre observational case–control study conducted by the international dermoscopy society. *J Eur Acad Dermatol Venereol.* 2018;32(8):1263–71.doi:10.1111/jdv.14729.
13. Morrison L Katie MD, Janik M, Nicholas Shamma H. Clear Cell Acanthoma: A Rare Clinical Diagnosis Prior to Biopsy. *Int J Dermatol.* 2010;49(9):1008–11.
14. Moscarella E., Argenziano G, Longo C, Cota C, Ardigò M, Stigliano V, Mete LS et al. "Clinical, dermoscopic and reflectance confocal microscopy features of sebaceous neoplasms in muir-torre syndrome." *J Eur Acad Dermatol Venereol.* 2013;27(6):699–705. doi:10.1111/j.1468-3083.2012.04539.x.
15. Navarrete-Dechent C, Bajaj S, Marghoob AA, González S, Muñoz D. Multiple familial trichoepithelioma: confirmation via dermoscop. *Dermatol Pract Concept.* 2016;6(3):51–54. doi:10.5826/dpc.0603a10.
16. Obaidat NA, Alsaad KO, Ghazarian D. Skin adnexal neoplasms - part 2: an approach to tumours of cutaneous sweat glands. *J Clin Pathol.* 2007;60(2):145–59. doi:10.1136/jcp.2006.041608.
17. Patterson JW. *Weedon´s Skin Pathology.* 4th ed. Churchill Livingston Elsevier;2016.
18. Peltomäki P, Vasen HFA. Mutations predisposing to hereditary nonpolyposis colorectal cancer: database and results of a collaborative study. The international collaborative group on hereditary nonpolyposis colorectal cancer. *Gastroenterology* 1997;113(4):1146–58.
19. Sawaya JL., Khachemoune A. Poroma: a review of eccrine, apocrine, and malignant forms. *In* J Dermatol. 2014;53(9):1053–61. doi:10.1111/ijd.12448.
20. Sgambato A, Zalaudek I, Ferrara G, Giorgio CM, Moscarella E, Nicolino R, Argenziano G. Adnexal tumors. *Arch Dermatol.* 2008;144(3):2018. doi:10.1001/archderm.144.3.426.
21. Shalin SC, Lyle S, Calonje E, Lazar AJF. Sebaceous neoplasia and the Muir-Torre syndrome: important connections with clinical implications. *Histopathology* 2010;56(1):133–47. doi:10.1111/j.1365-2559.2009.03454.x.
22. Zaballos P, Ara M, Puig S, Malvehy J. Dermoscopy of sebaceous hyperplasia. *Arch Dermatol.* 2005;141(6):808. doi:10.1001/archderm.141.6.808.
23. Zaballos P, Llambrich Á, Puig S, Malvehy J. Dermoscopic findings of pilomatricomas. *Dermatology.* 2008;217(3):225–30. doi:10.1159/000148248.
24. Zalaudek I, Hofmann-Wellenhof R, Argenziano G, Blum A, Bauer J. Dermoscopy of clear-cell acanthoma differs from dermoscopy of psoriasis. *Dermatology.* 2003;207(4):428–29. doi:10.1159/000074137.

7A BENIGN MELANOCYTIC LESIONS: CONGENITAL MELANOCYTIC NEVI

Natalia Jaimes and Ashfaq A. Marghoob

Contents

Introduction . . . 139
Clinical characteristics . . . 139
Dermoscopy of CMN . . . 139
Other dermoscopic features seen in CMN . . . 142
Variants . . . 144
Nevus spilus . . . 144
CMN and risk of melanoma . . . 144
Management of CMN . . . 144
Conclusion . . . 145
Key points . . . 145
References . . . 145

Introduction

Congenital melanocytic nevi (CMN) develop as a result of mutations acquired during embryogenesis (8), and these nevi are clinically visible on the skin of 1% to 2% of newborns (1). However, at least 6% of the population harbor melanocytic nevi displaying the characteristic morphologic features associated with CMN. While some of these so-called congenital nevus–like nevi (CNLN) may result from postnatally acquired mutations, some may be tardive CMN (4, 6). These tardive CMN are presumed to be due to mutations that are determined in utero, but for unknown reasons, the nevi do not become clinically manifest until months to years after birth. It is possible that some of these tardive CMN may initially be present as small incipient nevus nests in the skin, and these nevus clusters may proliferate at some point in life and grow large enough to become clinically apparent (14). Another hypothesis is that some tardive CMN may initially lack the ability to form melanin, and only after the induction of melanogenesis do they become visible on the skin.

The term CMN as used in this chapter will encompass all the aforementioned scenarios. In general, for a lesion to be categorized as a CMN, it should meet the following criteria:

1. Any melanocytic nevus documented to have been present at birth, or
2. Any CNLN in which the history is reliable that it was present since early life and the clinical examination or histology is consistent with a CMN (7)

Clinical characteristics

CMN are much more variable in terms of size, color, shape, and topography compared with acquired melanocytic nevi. Their size can vary from a few millimeters to sizable lesions that encompass large segments of the integument. They can have a smooth to mamillated surface, but the larger lesions can have a rugose to nodular surface. The colors range from light to dark brown to blue-black. CMN often contain terminal hairs, a feature that is not seen in acquired nevi.

Dermoscopy of CMN

Most small and medium CMN are fairly uniform, both clinically and dermoscopically. Large CMN, on the other hand, are often heterogeneous, displaying multiple islands of color and irregular topography. There are three main dermoscopic structures associated with CMN: network, globules, and diffuse homogeneous pigmentation. The specific characteristics of these three dermoscopic features are described in Table 7a.**1** (3, 6, 15, 16, 18–20). Other features associated with CMN include terminal hairs with perifollicular hypo- or hyperpigmentation and milia-like cysts.

a. ***Network.*** Network is composed of interconnecting dark lines with intervening lighter -colored holes. There tends to be minimal variability in the color and size/thickness of the lines and holes. The network is usually distributed in a symmetric and organized manner and can demonstrate two patterns:

   - ***Diffuse reticular pattern.*** The network is distributed throughout the lesion.
   - ***Patchy reticular pattern***. The network is distributed in small foci with intervening hypopigmented structureless areas or follicular openings throughout the lesion.

   The reticular pattern is seen in superficial CMN and in CMN located on the lower extremities**.** At times, the network can appear fragmented, and the fragments have a morphology that is reminiscent of fungal hyphae.

b. ***Globules.*** Globules consist of sharply circumscribed, round-to-oval aggregates that are usually brown in color; however, they can also appear with black or blue colors. Globules correspond to nests of melanin-containing nevomelanocytes within the dermis. The following globular patterns are associated with CMN:

   - ***Cobblestone pattern.*** Confluent globules that are large and angulated.

DOI: 10.1201/9780429487873-17

TABLE 7A.1: Dermoscopic Structures and Features Observed in Congenital Melanocytic Nevi

Dermoscopic structures in CMN	Quality	Distribution	Variations
Reticular network	Fine (Figure 7a.1) Thick (Fig. 7a.2)	Homogeneous (Figure 7a.3) Focal (patchy) (Figure 7a.4) At the periphery (Figure 7a.5)	Thick linear resembling hyphae (Figures 7a.6 and 7a.7)
Globules	Small (Figure 7a.8) Large (Figures 7a.9 and 7a.10)	DiffuseSparse or dense (Figures 7a.11 and 7a.12) Clustered in the center (Figure 7a.13)	Cobblestone-like (Figure 7a.14) Target-like (Figures 7a.15 and 7a.16) Figs. 7a.15 and 7a.16

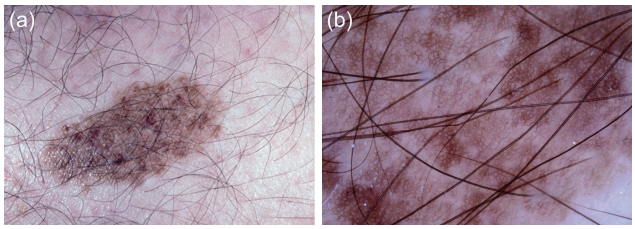

FIGURE 7A.1 (a) Clinical image of a medium-sized CMN. (b) CMN with a fine reticular network throughout. Note the hypertrichosis, which is frequently seen in CMN.



FIGURE 7A.2 (a) Clinical image of a small CMN. (b) CMN with a thick reticular network throughout. Note the presence of a few small bluish globules within this CMN.

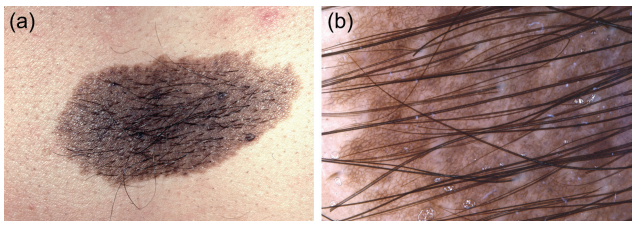

FIGURE 7A.3 (a) Clinical image of a medium-sized CMN. (b) CMN with homogeneous reticulation throughout the lesion. Other features that are often seen in CMN include hypertrichosis, as can be seen in this nevus.

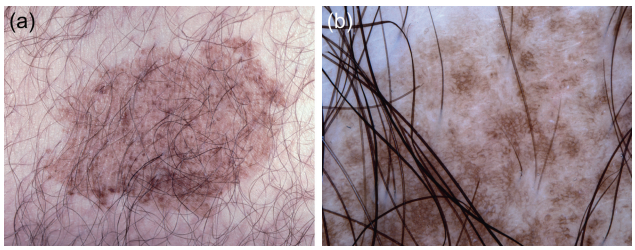

FIGURE 7A.4 (a) Clinical image of a medium-sized CMN. (b) CMN with patchy reticulation throughout the lesion. Other features that are common to CMN include hypertrichosis and perifollicular hypopigmentation, as seen in this CMN.

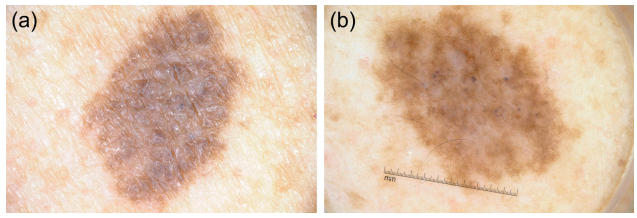

FIGURE 7A.5 (a) Clinical image of a small CMN. (b) This CMN has a reticular pattern with hypopigmented structureless areas in the center. It also has hypertrichosis. Although globules in CMN tend to be aggregated and brown in color, on rare occasions, one can find nonaggregated globules with a blue color, as is evident in this CMN.

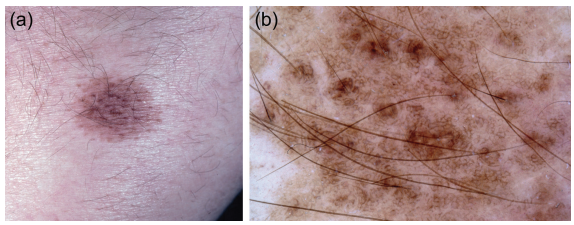

FIGURE 7A.6 (a) Clinical image of a medium-sized CMN. (b) CMN can have network fragments that resemble hyphal-like structures. Other features seen in this nevus that are common to CMN include hypertrichosis and perifollicular hyperpigmentation.

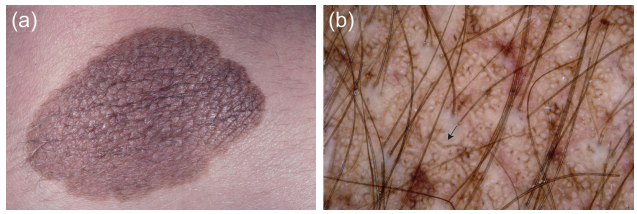

FIGURE 7A.7 (a) Clinical image of a medium-sized CMN. (b) CMN can have network fragments that resemble hyphal-like structures (arrow).

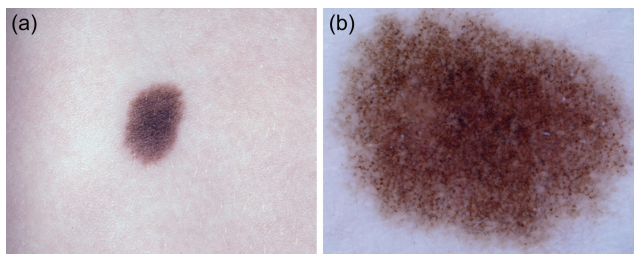

FIGURE 7A.8 (a) Clinical image of a small CMN. (b) CMN with small globules. The homogeneous brown background color as seen in this nevus is a feature commonly seen in CMN.

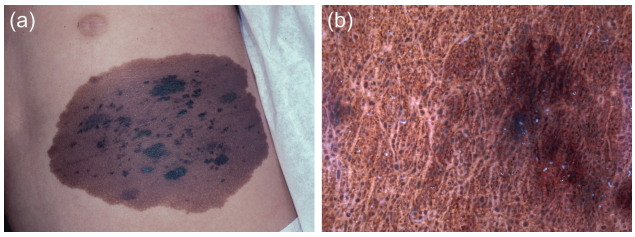

FIGURE 7A.9 (a) Clinical image of a large CMN. (b) CMN with large globules. Note the homogenous brown background pigment, which is often seen in CMN.

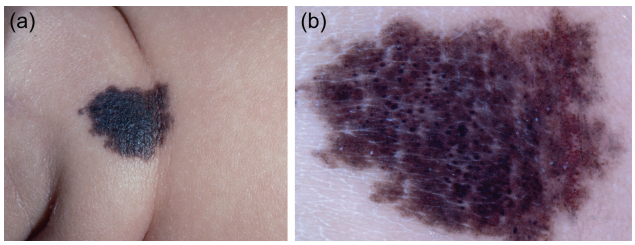

FIGURE 7A.10 (a) Clinical image of a small CMN. (b) CMN with large and small globules. Note the diffuse brown background color, which is a common occurrence in CMN.

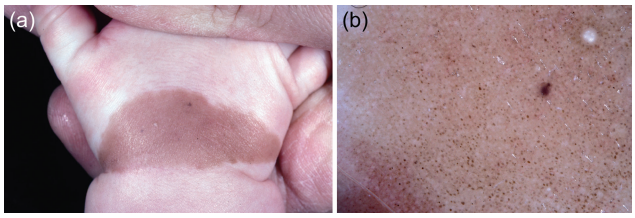

FIGURE 7A.11 (a) Clinical image of a medium-sized CMN. (b) CMN with globules present throughout the lesion and distributed in a sparse concentration. Other features seen in this nevus, common to CMN, include diffuse background pigment and the presence of a milia-like cyst.

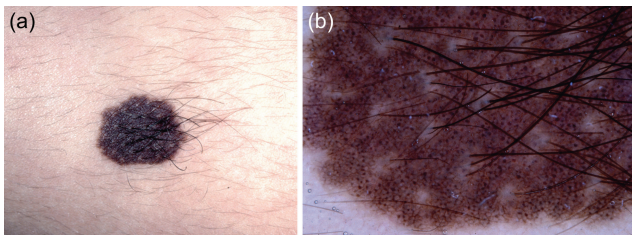

FIGURE 7A.12 (a) Clinical image of a medium-sized CMN. (b) CMN with globules throughout the lesion and distributed in dense concentration. Other features seen in this nevus are hypertrichosis, perifollicular hypopigmentation, and diffuse brown background color, all of which are commonly found in CMN.

- ***Globular pattern.*** Multiple globules of similar shape, size, and color distributed throughout the lesion. Nevi with a globular pattern are more common in CMN located on the head, neck, and torso.

c. **Presence of both network and globules**. CMN can also contain both network and globules. The most common reticuloglobular patterns are:

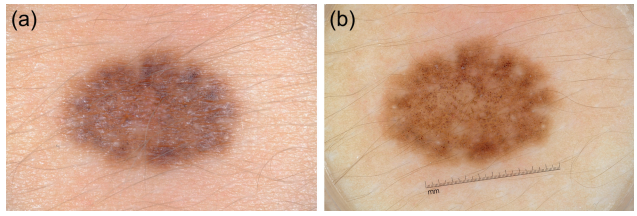

FIGURE 7A.13 (a) Clinical image of a CMN. (b) CMN with globules present centrally and surrounded by a reticular network. Note the presence of milia-like cyst, which can often be seen in CMN.

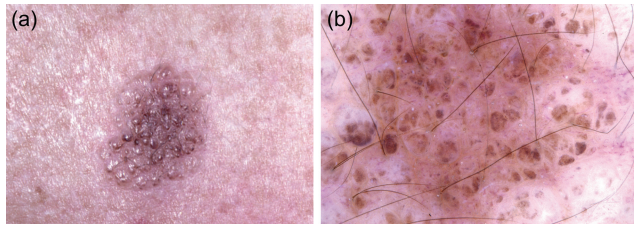

FIGURE 7A.14 (a) Clinical image of a small CMN. (b) CMN with cobblestone-like globules. Note the hypertrichosis, which is frequently seen in CMN.

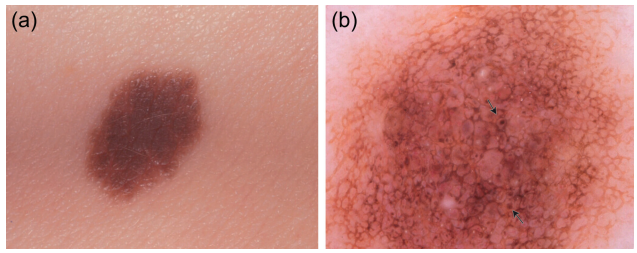

FIGURE 7A.15 (a) Clinical image of a medium-sized CMN. (b) CMN with target network with globules (arrows).

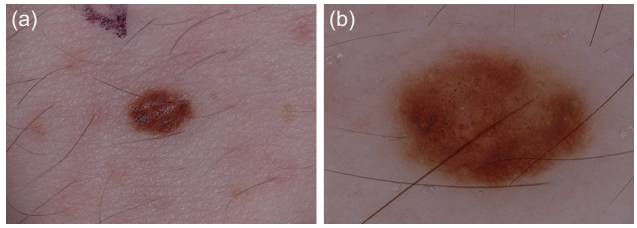

FIGURE 7A.16 (a) Clinical image of a small CMN. (b) CMN with target globules.

- ***Central globules with peripheral network***. Uniform network at the periphery of the lesion with central globules. This pattern is commonly seen in superficial compound congenital nevi.
- ***Target network pattern with globules in the holes.*** This pattern consists of a network within the hole of which one finds a small globule. Target network with globules corresponds to the presence of nevomelanocytic nests in the dermal papillae (6).

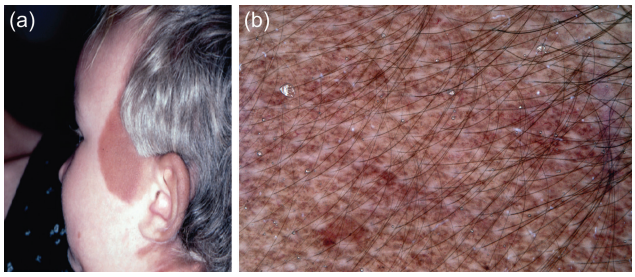

FIGURE 7A.17 (a) Clinical image of a medium-sized CMN. (b) CMN with a diffuse brown background pigment without any discernible structures.

d. ***Structureless or homogeneous pattern.*** Diffuse brown pigmentation (with or without network fragments and few sparse globules) is due to the diffuse distribution of melanin in the epidermis and dermis (7). Often, these CMN appear structureless (i.e., network or globules) (Figure 7a.17), but on occasion, a few scattered reticular network fragments and/or globules (Figure 7a.18) may be visible focally within the lesion.

e. ***Multiple structures.*** The presence of three or more dermoscopic structures in the same lesion creates a ***multicomponent pattern***. The melanocytic structures can include network, streaks, negative network, globules, shiny white lines, blotch, and blue-white veil. When structures in a multicomponent CMN are distributed asymmetrically, differentiating them from melanoma may prove challenging.

Other dermoscopic features seen in CMN

Other structures frequently observed in CMN viewed with dermoscopy include the following (Table 7a.2):

1. Milia-like cysts
2. Hypertrichosis
3. Blood vessels
4. Perifollicular pigment changes

Milia-like cysts (Figures 7a.19 and 7a.20) are white to yellow, rounded, often hazy structures that correlate histologically with intraepidermal keratin cysts/pseudocysts (17). They derive their name from their resemblance to the small seeds or millets of various grain grasses. They may be observed scattered throughout a CMN (6). It is important to stress that although the presence of milia-like cysts is one of the dermoscopic hallmarks of seborrheic keratosis, they can also be seen in melanocytic neoplasms, including CMN, papillomatous dermal nevi, and rarely, melanomas (2, 3). Thus, if the lesion is deemed to be a nonmelanocytic growth, then the presence of multiple milia-like cysts favors the diagnosis of seborrheic keratosis; however, if the lesion is a melanocytic tumor, then the presence of multiple milia-like cysts favors a diagnosis of CMN. With that being said, it is important to remember that in a melanocytic tumor, the presence of milia-like cysts, in and of themselves, is not diagnostic of a CMN, since they can also be seen in melanoma.

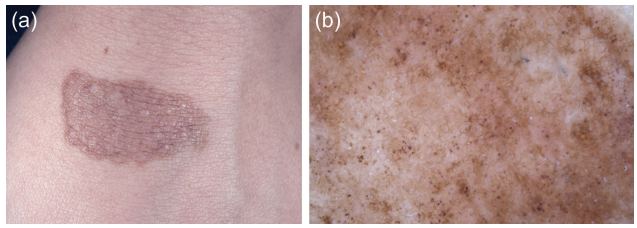

FIGURE 7A.18 (a) Clinical image of a medium-sized CMN. (b) CMN with a diffuse brown background and with a few globules and network fragments.

Hypertrichosis is characteristic of CMN and is often accompanied by perifollicular hyperpigmentation (Figures 7a.6 and 7a.21) or hypopigmentation (Figure 7a.22).

The presence of ***blood vessels*** of varying morphologies is commonly observed in CMN. Occasionally, the blood vessels can be seen within the hole of the network and correspond to vessels in the dermal papillae. When a network surrounds these vessels, they create a target structure called "target network with blood vessels."

In summary, CMNs are either primarily reticular (Figures 7a.23 and 7a.24) or primarily globular (Figures 7a.25 and 7a.26). Some exhibit peripheral reticulation in conjunction with central globules and are designated reticuloglobular (Figures 7a.13 and 7a.27). CMN that primarily have diffuse brown pigmentation are often structureless, but some may contain fragments of reticulation and/or globules (Figures 7a.28 and 7a.29). Approximately 7% of CMN will manifest a multicomponent pattern. If the structures in a multicomponent nevus are distributed asymmetrically, then differentiating these CMN from melanoma may be challenging (Figures 7a.30 and 7a.31). In addition, thick mammillated CMN are often difficult to evaluate using dermoscopy (Figure 7a.32). These lesions often have ridges, comedo-like openings, and

TABLE 7A.2: Other Dermoscopic Features Seen in Congenital Melanocytic Nevi

Feature (Frequency)	Definition
Milia-like cysts (52%)	White to yellow, rounded, often hazy structures resembling the small seeds or millets of various grain grasses
Target network with vessels (33%)	Blood vessels situated within the holes of the network
Target network with globules (target globules) (27%)	Globules present within the holes of the network
Blood vessels of varying morphologies (68%)	Blood vessel morphology can include any or all of the morphologies described for nevi (i.e., comma vessels) and melanoma (i.e., dotted, linear serpentine, coiled, and hairpin)
Hypertrichosis (79%)	Increased number of terminal hairs
Perifollicular pigment changes (42%)	Hypopigmentation or hyperpigmentation occurring around the hair follicles

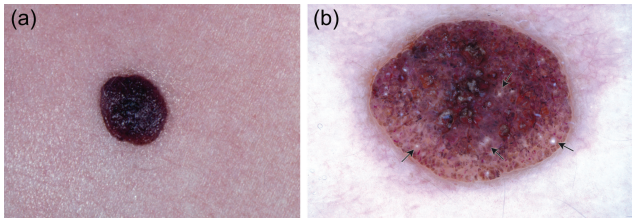

FIGURE 7A.19 (a) Clinical image of a small CMN. (b) CMN with milia-like cysts (arrows). This lesion also has globules and vessels.

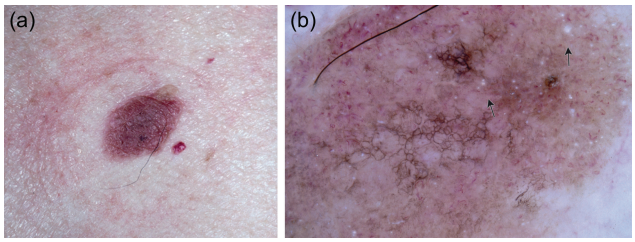

FIGURE 7A.20 (a) Clinical image of a medium-sized CMN. (b) CMN with milia-like cysts (arrows). This lesion also has a patchy network, vessels, and diffuse background pigmentation.

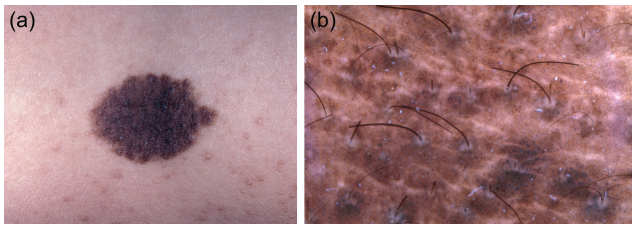

FIGURE 7A.21 (a) Clinical image of a medium-sized CMN. (b) CMN with perifollicular hyperpigmentation. Note the target globules in the right upper corner of the image and the diffuse brown background pigment—both features commonly seen in CMN.

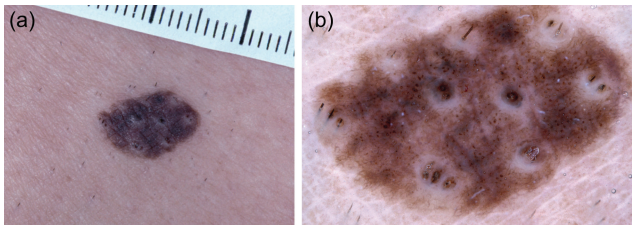

FIGURE 7A.22 (a) Clinical image of a small CMN. (b) CMN with perifollicular hypopigmentation. This lesion also has a few target globules and peripherally placed network, both of which are common features seen in CMN.

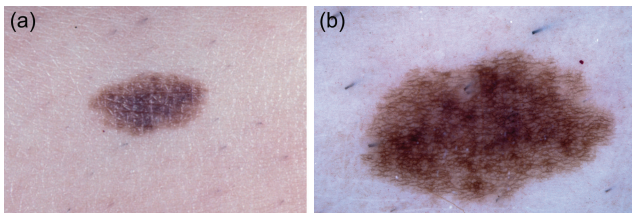

FIGURE 7A.23 (a) Clinical image of a small CMN. (b) CMN with a reticular network pattern.

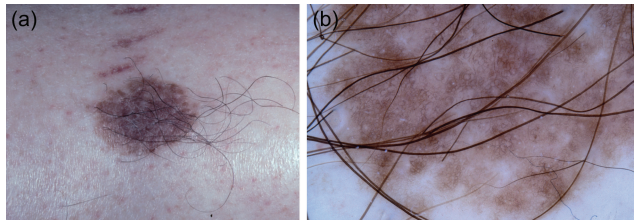

FIGURE 7A.24 (a) Clinical image of a medium-sized CMN. (b) CMN with a patchy reticular network pattern.

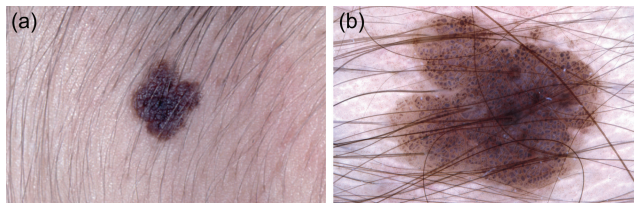

FIGURE 7A.25 (a) Clinical image of a small CMN. (b) CMN with a globular pattern.

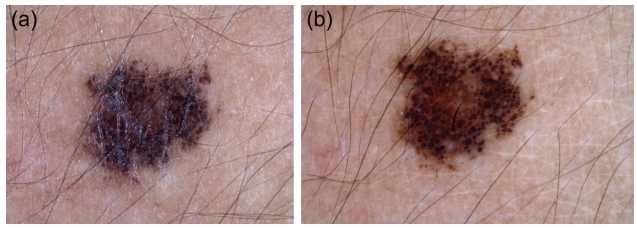

FIGURE 7A.26 (a) Clinical image of a small CMN. (b) CMN with a globular pattern.

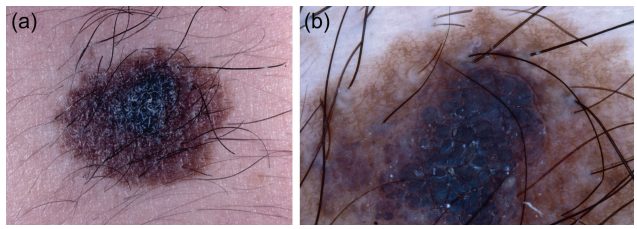

FIGURE 7A.27 (a) Clinical image of a medium-sized CMN. (b) CMN with a reticuloglobular pattern. Notice the fine network around the periphery of the lesion and the large globules clustered in the center. This same pattern can be seen in Figure 7a.13.

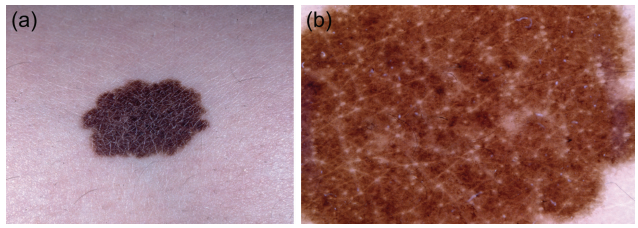

FIGURE 7A.28 (a) Clinical image of a medium-sized CMN. (b) CMN with a diffuse brown background pigment pattern. There are no discernible structures.

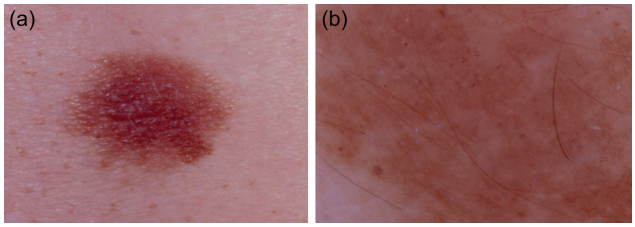

FIGURE 7A.29 (a) Clinical image of a medium-sized CMN. (b) CMN with a diffuse brown background pigment pattern. There are a few globules and network fragments discernible.

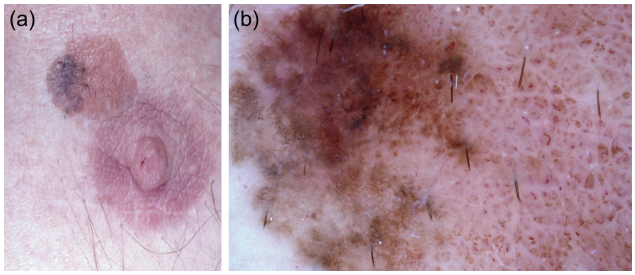

FIGURE 7A.30 (a) Clinical image of a CMN in which a melanoma has developed. (b) This CMN developed a focal pigment change. Under dermoscopy, one can see the classic CMN cobblestone pattern on the right. This area also reveals hypertrichosis, milia-like cysts, and comma-shaped blood vessels, which are all features common to CMN. The left side of the lesion reveals irregular dots, atypical network, and blue-gray areas, which are features commonly associated with melanoma. This lesion manifests an asymmetric multicomponent pattern. This lesion was excised and revealed a melanoma arising in association with a CMN.

many blood vessels, as can be seen in Figure 7a.32. This pattern can sometimes mimic a seborrheic keratosis.

Although any of the above-mentioned dermoscopic patterns could be present in CMN at any anatomical location, CMN on the torso are more frequently globular, and CMN on the lower extremities are more frequently reticular (6).

Variants

Nevus spilus

Nevus spilus or speckled lentiginous nevus is a CMN with a lentiginous background that is studded with discrete nevi. There are two variants:

Nevus spilus maculosus is characterized by dark macular speckles over a light brown background (10). The speckles, all of approximately the same size, have a reticular or homogeneous appearance under dermoscopy.

Nevus spilus papulosis consists of variously sized dark macules and papules distributed over a light brown background (10). With dermoscopy, these macules and papules can be reticular, homogeneous, or globular, can manifest a combined pattern, and on occasion, can even have a spitzoid morphology.

CMN and risk of melanoma

While most CMN remain benign throughout the life of the individual, on rare occasions, a melanoma can develop in association with a CMN. While melanoma may develop in association with any CMN, the risk of developing melanoma appears proportional to the size of the CMN. The location and age at onset of melanoma differ between the different sizes of the CMN.

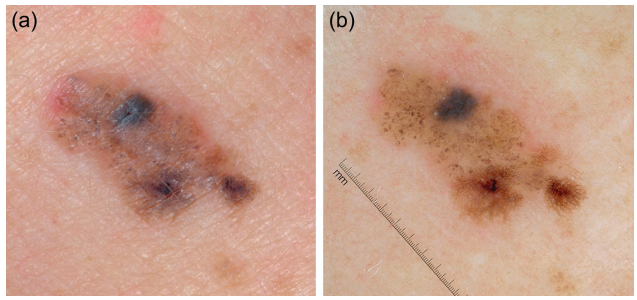

FIGURE 7A.31 (a) Clinical image of a small CMN. (b) This CMN has a multicomponent pattern with network, blotch, dots, and globules. The lesion also has milia-like cysts. Due to the asymmetric pattern, this lesion was excised and step-sectioned. The pathology confirmed the diagnosis of a CMN.

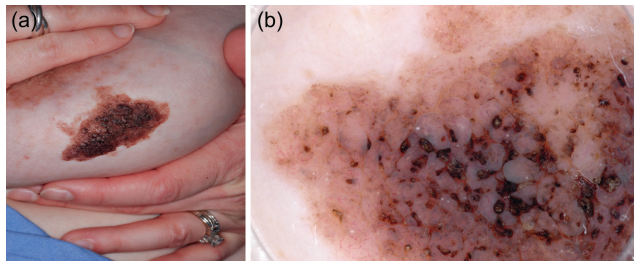

FIGURE 7A.32 (a) Clinical image of a mammillated medium-sized CMN. (b) The undulating surface of this CMN creates invaginations that resemble crypts and comedo-like openings commonly seen in seborrheic keratosis. This CMN also reveals numerous blood vessels of varying morphologies.

Melanomas developing in small-to-medium CMN tend to appear after puberty and are more likely to originate at the dermo-epidermal junction (DEJ) and at the peripheral edge of the CMN. Thus, dermoscopy is an ideal instrument to evaluate for the development of melanoma in smaller CMN, since dermoscopy allows the clinician to observe morphologic changes at the DEJ that may herald the onset of melanoma.

Melanomas developing in large CMN tend to develop earlier in life and frequently have their origin below the DEJ. Thus, palpation becomes an important component in the evaluation of large CMN, while dermoscopy demonstrates a limited role in evaluating large CMN, especially those that are thick and rugous, since it cannot adequately visualize morphologic changes that may be indicative of melanoma developing below the papillary dermis.

Melanomas developing in nevus spilus. Although rare, melanoma can develop in any nevus spilus, yet the risk is highest in larger speckled lentiginous nevi of the maculosa variant.

Management of CMN

The current management options for CMN include close clinical follow-up with or without baseline photographs and/or prophylactic surgical excision, if feasible (11). Most physicians, however,

are electing to follow CMN, especially those that have a homogeneous clinical appearance and are small to medium in size, by periodic follow-up examinations. Dermoscopy has improved our ability to clinically monitor CMN, especially the smaller ones. Knowledge of the dermoscopic features and patterns common to CMN can aid physicians in following these lesions and recognizing aberrancy that may be suggestive of melanoma. Needless to say, many physicians find baseline photographs and dermoscopy to be very helpful in monitoring CMN (12, 13). Ideally, the photographs of CMN should include overview clinical images and dermoscopic images (13). The dermoscopic images should capture the representative architecture and border of the CMN (3). In addition, supplemental dermoscopic images should be obtained of any areas within the CMN that are of "special interest" (3).

Conclusion

Dermoscopy is a valuable tool in the diagnosis and follow-up of CMN (5, 9). This noninvasive in vivo technique allows the clinician to examine morphologic structures within the epidermis, DEJ, and superficial dermis. Since most melanomas arising in association with smaller CMN develop along the DEJ, dermoscopy is an ideal instrument to help in the evaluation, screening, and monitoring of these nevi. Dermoscopy may also assist in evaluating, screening, and monitoring of flat large CMN. However, due to the limitation of how deeply into the skin dermoscopy allows the observer to see, this tool is not ideal for evaluating large rugose CMN, because melanomas developing in such lesions are often located below the papillary dermis. Although dermoscopy can assist in evaluating the superficial component of these thicker CMN, other techniques, such as palpation, ultrasound, or other imaging modalities, may need to be used to evaluate the deeper nevus component. The classification system proposed in this chapter should provide the foundation for the recognition of CMN. Those CMN that do not conform to the known patterns described earlier should be viewed with caution. One such example is provided in Figure 7a.30. Within one section of this asymmetric melanocytic lesion, one can see the classic cobblestone globular pattern of a CMN. This part of the lesion also reveals milia-like cysts, hypertrichosis, and multiple blood vessels—all structures commonly seen in CMN. However, another portion of the same lesion has features that are not seen in CMN and are, in fact, features commonly seen in melanoma. This lesion was excised and revealed a melanoma arising in association with a CMN.

Key points

1. Structures commonly seen in CMN include network, globules, diffuse brown structureless areas, milia cysts, target network, vessels, hypertrichosis, and perifollicular pigment changes.
2. The most common dermoscopic patterns seen in CMN include reticular, globular, peripheral reticular with central globules, homogeneous brown, and multicomponent pattern.
3. CMN on the lower extremity predominantly have a reticular pattern. CMN on the torso and head and neck predominantly have a globular pattern.
4. Knowledge of the structures and patterns commonly seen in CMN can help in their evaluation. Lesions that deviate from the known patterns or reveal structures not commonly associated with CMN should be monitored closely or biopsied.

References

1. Alper JC, Holmes LB. The incidence and significance of birthmarks in a cohort of 4,641 newborns. *Pediatr Dermatol*. 1983;1(1):58–68. https://doi.org/10.1111/j.1525-1470.1983.tb01093.x. https://www.ncbi.nlm.nih.gov/pubmed/6679890.
2. Argenziano G, Rossiello L, Scalvenzi M, et al. Melanoma simulating seborrheic keratosis: a major dermoscopy pitfall. *Arch Dermatol*. 2003;139:389–91.
3. Braun RP, Calza AM, Krischer J, Saurat JH. The use of digital dermoscopy for the follow-up of congenital nevi: a pilot study. *Pediatr Dermatol*. 2001;18:277–81.
4. Braun RP, Rabinovitz HS, Krischer J, et al. Dermoscopy of pigmented seborrheic keratosis: a morphological study. *Arch Dermatol*. 2002;138:1556–60.
5. Braun RP, Rabinovitz HS, Oliviero M, Kopf AW, Saurat JH. Dermoscopy of pigmented skin lesions. *J Am Acad Dermatol*. 2005;52:109–21.
6. Changchien L, Dusza SW, Agero AL, et al. Age- and site-specific variation in the dermoscopic patterns of congenital melanocytic nevi: an aid to accurate classification and assessment of melanocytic nevi. *Arch Dermatol*. 2007;143:1007–14.
7. Kenet R, Kang S, Kenet B, et al. Clinical diagnosis of pigmented lesions using digital epiluminescence microscopy. Grading protocol and atlas. *Arch Dermatol*. 1993;129:157–74.
8. Kinsler VA, O'Hare P, Bulstrode N, Calonje JE, Chong WK, Hargrave D, Jacques T, Lomas D, Sebire NJ, Slater O. Melanoma in congenital melanocytic naevi. *Br J Dermatol*. 2017;176(5):1131–43. https://doi.org/10.1111/bjd.15301.
9. Lodha R, McDonald WS, Elgart GW, Thaller S. Dermoscopy for congenital melanocytic nevi. *J Craniofac Surg*. 2003;14:661–5.
10. Marghoob AA. Congenital melanocytic nevi. Evaluation and management. *Dermatol Clin*. 2002;20:607–16, viii.
11. Marghoob AA, Borrego JP, Halpern AC. Congenital melanocytic nevi: treatment modalities and management options. *Semin Cutan Med Surg*. 2007;26:231–40.
12. Nehal KS, Oliveria SA, Marghoob AA, et al. Use of and beliefs about baseline photography in the management of patients with pigmented lesions: a survey of dermatology residency programmes in the United States. *Melanoma Res*. 2002a;12:161–7.
13. Nehal KS, Oliveria SA, Marghoob AA, et al. Use of and beliefs about dermoscopy in the management of patients with pigmented lesions: a survey of dermatology residency programmes in the United States. *Melanoma Res*. 2002b;12:601–5.
14. ScopeA,MarghoobAA,ChenCS,LiebJA,WeinstockMA,Halpern AC, SONIC Study Group. Dermoscopic patterns and subclinical melanocytic nests in normal-appearing skin. *Br J Dermatol*. 2009;160(6):1318–21. https://doi.org/10.1111/j.1365-2133.2009.09073.x. https://www.ncbi.nlm.nih.gov/pubmed/19416274.
15. Seidenari S, Pellacani G. Surface microscopy features of congenital nevi. *Clin Dermatol*. 2002;20:263–7.
16. Seidenari S, Martella A, Pellacani G. Polarized light-surface microscopy for description and classification of small and medium-sized congenital melanocytic naevi. *Acta Dermato-Venereologica*. 2003;83:271–6.
17. Soyer H, Smolle J, H"dl S, Pachernegg H, Kerl H. Surface microscopy: a new approach to the diagnosis of cutaneous pigmented tumors. *Am J Dermatopathol*. 1989;11:1–10.
18. Soyer HP, Argenziano G, Ruocco V, Chimenti S. Dermoscopy of pigmented skin lesions (Part II). *Eur J Dermatol*. 2001b;11:483–98.
19. Wang S, Katz B, Rabinovitz HS, Kopf A, Oliviero M. Lessons on dermoscopy. Compound congenital melanocytic nevus. *Dermatol Surg*. 2000a;26:397–8.
20. Wang S, Katz B, Rabinovitz HS, Kopf A, Oliviero M. Lessons on dermoscopy: case #9. Congenital melanocytic nevus. *Dermatol Surg*. 2000b;26:977–8. https://www.ncbi.nlm.nih.gov/pubmed/28078671.

7B BENIGN MELANOCYTIC LESIONS: MELANOCYTIC NEVI

Konstantinos Liopyris, Cristian Navarrete-Dechent, Silvia E. Mancebo and Michael A. Marchetti

Contents

Introduction . . . 146
Dermatoscopic patterns of nevi . . . 146
Reticular/patchy reticular pattern . . . 146
Globular pattern . . . 149
Peripheral reticular with central globules pattern . . . 150
Homogeneous pattern . . . 150
Starburst pattern . . . 151
Peripheral globular patterns/starburst pattern . . . 151
Two-component pattern . . . 152
Multicomponent pattern . . . 152
Melanocytic nevi subtypes . . . 153
Acquired nevi, including banal and atypical/dysplastic nevi . . . 153
Growing nevi . . . 153
Congenital melanocytic nevi . . . 154
Special situations . . . 154
Halo nevi . . . 154
Ultraviolet radiation–related changes . . . 155
Balloon cell nevus . . . 155
Traumatized nevus . . . 155
Combined nevus . . . 155
References . . . 156

Melanocytic nevi are common skin lesions and the primary differential diagnosis of early presentations of cutaneous melanoma. Their accurate recognition is critical for efficient skin cancer detection. Fortunately, the majority of melanocytic nevi can be correctly identified after careful clinical and dermatoscopic inspection as well as integration of patient- and lesion-related factors such as age, anatomic location, skin color, and clinical history. In this chapter, we review the common dermatoscopic patterns of melanocytic nevi, including reticular, globular, homogeneous, starburst, peripheral globules, multicomponent patterns, and their variants. We also discuss banal/common nevi, atypical/dysplastic nevi, growing nevi, and congenital nevi. Finally, we point out dermatoscopic features relevant to less common nevus subtypes, including halo nevi, balloon cell nevi, traumatized nevi, combined nevi, and nevi subjected to ultraviolet irradiation.

Introduction

Melanocytic nevi are the primary differential diagnosis of early presentations of cutaneous melanoma. As the majority of skin lesions evaluated during total body skin examinations are nevi, their accurate recognition is of great importance. Fortunately, most nevi can be correctly identified after careful clinical and dermatoscopic evaluation. Since dermatoscopic patterns of banal (common) nevi, atypical/dysplastic nevi, growing nevi, and congenital nevi can overlap considerably, these clinical terms are not always relevant to the dermatoscopist. For example, a banal and an atypical nevus may appear dissimilar to the naked eye but may have the identical dermatoscopic pattern. Given the commonalities in the dermatoscopic patterns of various clinically defined nevus subgroups, in this chapter, we first outline the most frequent structures and patterns seen in nevi and later, comment on key features relevant to specific nevi subtypes. Of note, this chapter focuses on the dermatoscopic appearance of nevi on the trunk and nonvolar extremities; for nevi on facial, nail, volar, or mucosal sites, the reader is referred to the chapters dedicated to these special sites.

Dermatoscopic patterns of nevi

The majority of melanocytic nevi reveal symmetry of colors and structures across two axes and can be categorized into easily recognizable, reproducible patterns based on the color and distribution of structures (Figure 7b.1, Table 7b.1) (1–3). Of note, symmetry in dermatoscopy refers to the regular distribution of colors and structures within the lesion; as such, the border, shape, silhouette, and size do not factor into this determination (Figure 7b.2). Therefore, a lesion with an irregular silhouette but regular distribution of uniformly brown pigment network is clinically asymmetric but considered to be symmetric with dermatoscopic examination.

Reticular/patchy reticular pattern

Nevi with a reticular pattern present with pigment network. The lines of the network represent pigmented melanocytes/nevus cells and melanized keratinocytes in or along the epidermal rete ridges. The holes of the network are created by relative paucity of pigment in the suprapapillary epidermal plate overlying the dermal papillae. Histopathologically, reticular nevi have prominent junctional or lentiginous components (4). Variants of the reticular pattern include network diffusely

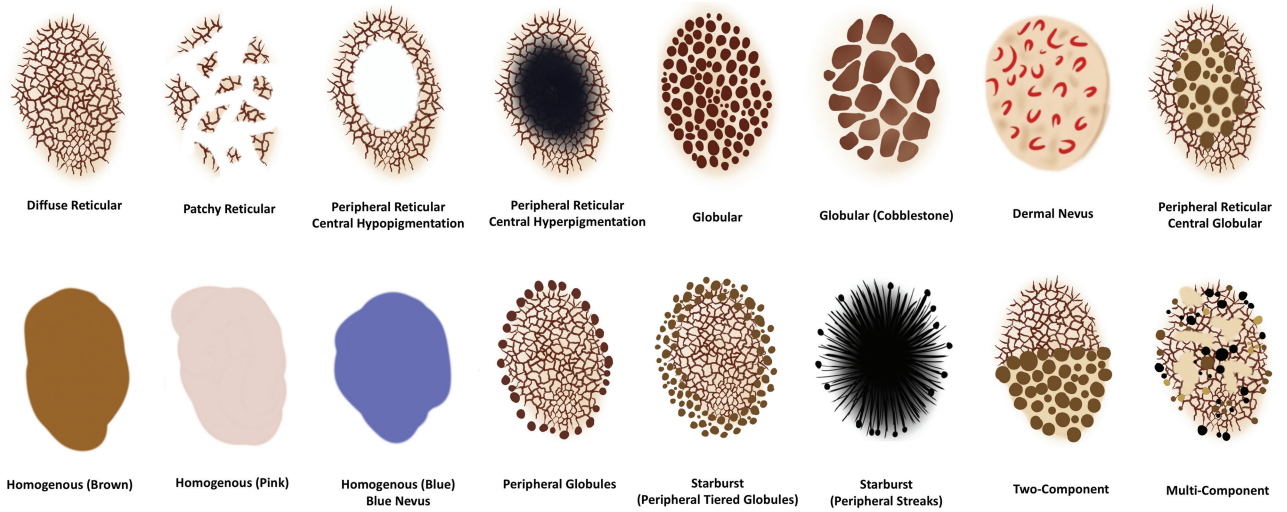

FIGURE 7B.1 Common dermatoscopic patterns of melanocytic nevi. (Images courtesy of Dr. Ralph Braun and www.dermoscopedia.org, via CC BY-NC-SA 4.0.)

TABLE 7B.1: Dermatoscopic Structures Present in Nevi

Descriptive terminology	Metaphoric terminology	Definition	Significance
Lines, reticular	Pigment network	Grid-like pattern consisting of interconnecting pigmented lines surrounding hypopigmented holes	
Lines, reticular, hypopigmented, around brown clods	Negative pigment network	Serpiginous interconnecting broadened hypopigmented lines that surround elongated and curvilinear globules	Spitz or "spitzoid" nevi, melanoma
Lines, branched	Branched streaks	Broadened or widened network with broken lines and incomplete connections	
Lines, radial at periphery, circumferential	Streaks (starburst pattern)	Radial linear extensions at the lesion edge	Spitz/Reed nevus
Pseudopods, radial at periphery, circumferential	Streaks (starburst pattern)	Bulbous and often kinked projections seen at the lesion edge, directly associated with either a network or a solid tumor border	Spitz/Reed nevus
Clods, brown, small, round, or oval	Globules, regular	Globules with minimal variability in their color, size, and shape	
Clods, brown, circumferential	Rim of brown globules	Globules distributed at the periphery of the lesion	Growing nevus
Clods, brown or skin-colored, large and polygonal	Cobblestone globules	Polygonal globules symmetrically distributed throughout the lesion	Dermal or congenital nevus
Clods, white	White globules	Globules with white color	Balloon cell features
Dots	Dots, regular	Dots clustered at the center of the lesion, or located on the network lines, or located in the center of the hypopigmented spaces between reticular lines (also called target network)	
Dots, central (in the center of hypopigmented spaces between reticular lines)	Targetoid dots (also called target network)	Dots located in the center of the hypopigmented spaces between reticular lines (also called target network)	Congenital nevus
Structureless zone, brown or black, central	Regular blotch	One blotch within the center of the lesion and surrounded by typical pigment network (if removed after tape-stripping the stratum corneum, referred to as a "lamella").	
Structureless zone, brown, pink, or blue	Homogeneous brown, pink or blue	Homogeneous brown, pink or blue pattern without any definable structures	Brown or pink homogeneous patterns seen more frequently in lighter skin types Blue homogeneous pattern = blue nevus
Vessels, curved or linear, short	Comma vessels	Linear, curved short vessels	Dermal nevus
Vessels, dotted, central (in the center of hypopigmented spaces between reticular lines)	Targetoid vessels	Red dots (vessels) in the center of hypopigmented spaces between reticular lines (also called target network with vessels)	Congenital nevus

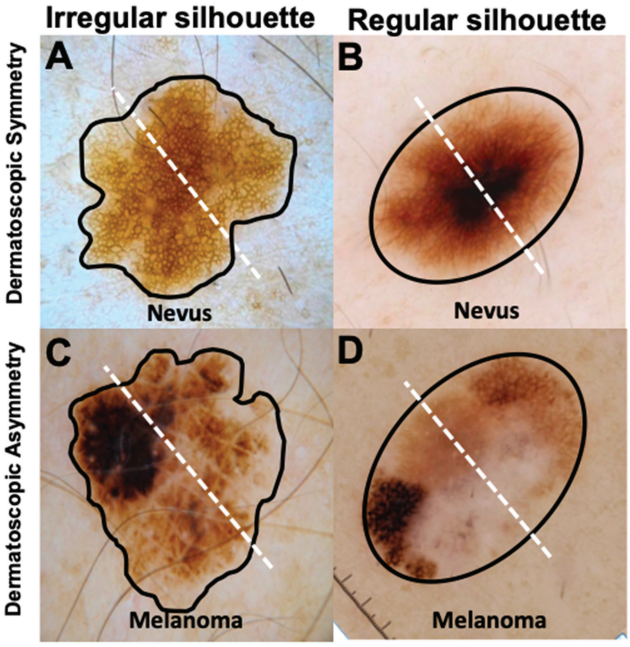

FIGURE 7B.2 Dermatoscopic symmetry refers to a regular distribution of colors and structures within the contours of a lesion; the shape, silhouette, and size do not factor into this determination. Dermatoscopic symmetry is a more helpful diagnostic feature than clinical border regularity/irregularity. (a) Nevus with irregular silhouette and dermatoscopic symmetry characterized by diffuse reticular pattern with regular distribution of light brown network lines. (b) Nevus with regular silhouette and dermatoscopic symmetry—peripheral reticular with central hyperpigmentation pattern. (c) Melanoma with irregular silhouette and dermatoscopic asymmetry—note eccentric pigment blotch. (d) Melanoma with regular silhouette and dermatoscopic asymmetry—note atypical network, scarlike depigmentation, peripheral tan structureless area, and peppering/granularity.

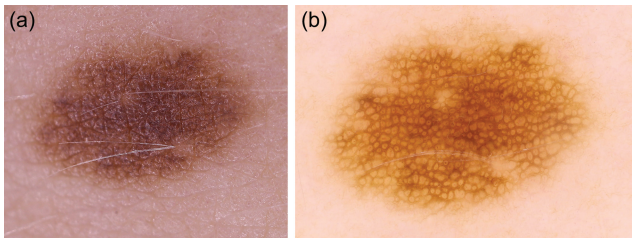

FIGURE 7B.3 (a) Clinical image of melanocytic nevus. (b) Dermoscopy shows diffuse reticular pattern. Note the minimal variability in the width and color of the light brown network lines and in the sizes of the hypopigmented holes. Characteristically, the network fades into the surrounding skin at the periphery.

distributed throughout the lesion (i.e., *diffuse reticular pattern*) (Figures 7b.3-7b.5) or network scattered in patches throughout the lesion (i.e., *patchy reticular pattern*) (Figures 7b.6-7b.7). Some refer to network with broken lines and incomplete connections, which is often present in a patchy reticular patterned nevus, as *branched streaks*.

Pigmentation will also vary depending on the patient's phenotype; in fair skin, the network lines are tan to light brown,

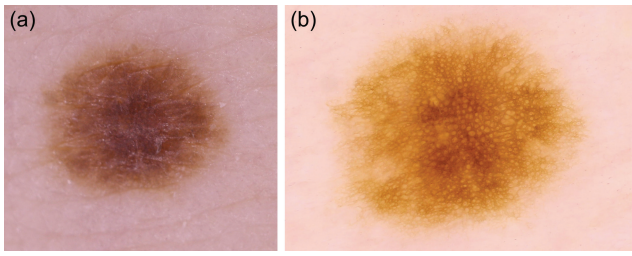

FIGURE 7B.4 (a) Clinical image of melanocytic nevus. (b) Dermoscopy shows diffuse reticular pattern. In this example, the network lines are relatively thicker and darker in the center compared with the periphery, and there is mild variability in the size of the hypopigmented holes, but the lesion retains symmetry. This appearance is still considered a "typical" presentation of network pattern.

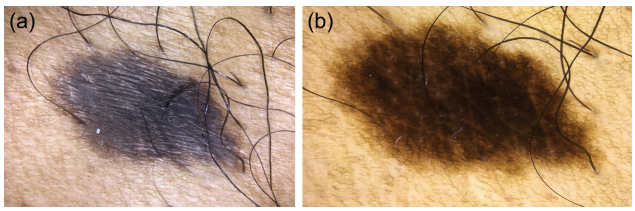

FIGURE 7B.5 (a) Clinical image of melanocytic nevus. (b) Dermoscopy shows diffuse reticular network composed of dark brown lines in a dark-skinned individual.

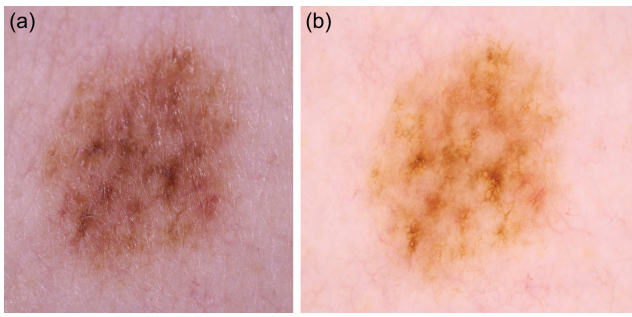

FIGURE 7B.6 (a) Clinical image of melanocytic nevus. (b) Dermoscopy shows symmetrical distribution of patchy reticular network with areas of structureless hypopigmentation.

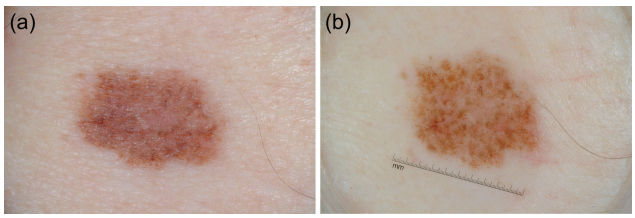

FIGURE 7B.7 (a) Clinical image of melanocytic nevus. (b) Dermatoscopy shows patchy network pattern.

and there will often be a central hypopigmented structureless area (i.e., *peripheral reticular with central hypopigmentation pattern*) (Figures 7b.8-7b.9). In darker skin, the network lines are dark brown to black, and there may be a central hyperpigmented structureless area (i.e., *peripheral reticular with central hyperpigmentation*) (Figures 7b.10-7b.11). This area of

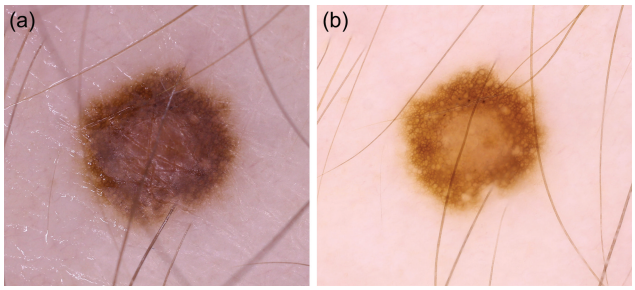

FIGURE 7B.8 (a) Clinical image of melanocytic nevus. (b) Dermatoscopy shows peripheral network with central hypopigmentation pattern.

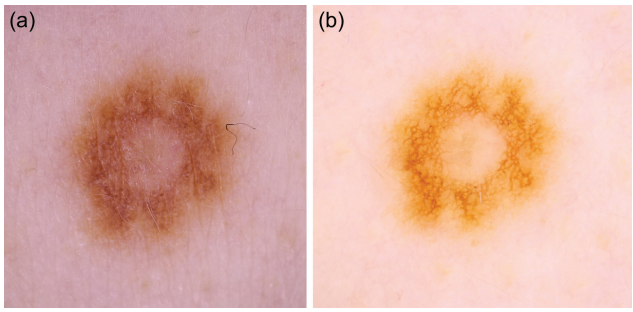

FIGURE 7B.9 (a) Clinical image of melanocytic nevus. (b) Dermatoscopy shows peripheral network with central hypopigmentation pattern.

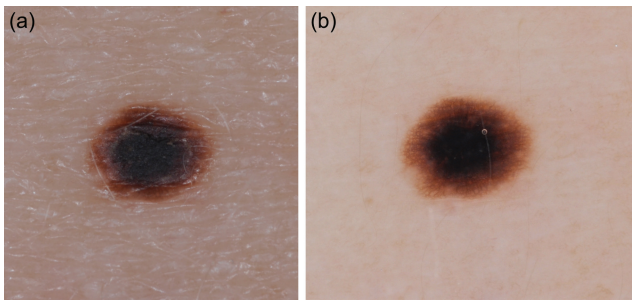

FIGURE 7B.10 (a) Clinical image of melanocytic nevus. (b) Dermatoscopy shows peripheral network with central hyperpigmentation pattern.

structureless hyperpigmentation is also referred to as a "regular pigment blotch." Occasionally, this area of hyperpigmentation can be completely removed by tape-stripping off the stratum corneum; in these cases, the structure is best referred to as a "*black lamella*" (Figure 7b.12). After removal of the lamella, the

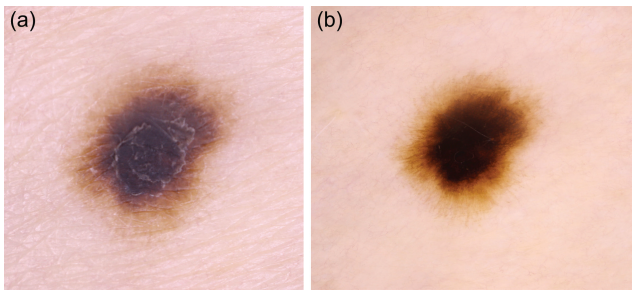

FIGURE 7B.11 (a) Clinical image of melanocytic nevus. (b) Dermatoscopy shows peripheral network with central hyperpigmentation pattern.

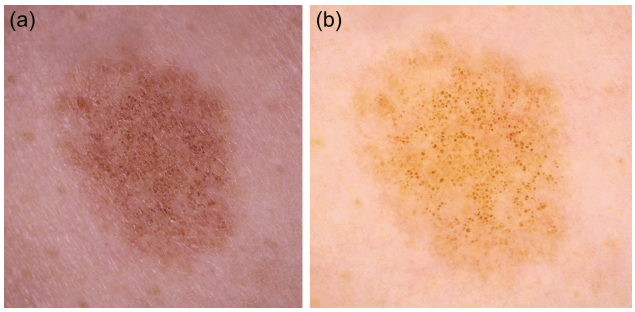

FIGURE 7B.13 (a) Clinical image of melanocytic nevus. (b) Dermatoscopy shows diffuse small brown globules with minimal variability in size, shape, and color of the globules.

underlying structure, which is most often a regular network, can be clearly visualized.

Reticular patterned nevi can be found anywhere on the trunk and extremities, and there appears to be no anatomic site predilection (5). Reticular patterned nevi are the most prevalent nevi in adults (6).

Globular pattern

The globular pattern of nevi presents with round to oval, brown globules, which represent dermal nests of melanocytes. The most common presentation is globules diffusely and evenly present throughout the lesion, with minimal variability in their color, size, and shape (i.e., *diffuse globular pattern*) (Figure 7b.13). Nevi with cobblestone globules are a variant (i.e., *cobblestone globular pattern*) and characterized by larger, closely aggregated, and somewhat angulated brown-gray structures reminiscent of cobblestones (Figure 7b.14). Histopathologically, these large globules correspond to large nests of nevomelanocytes in the upper and deeper parts of the

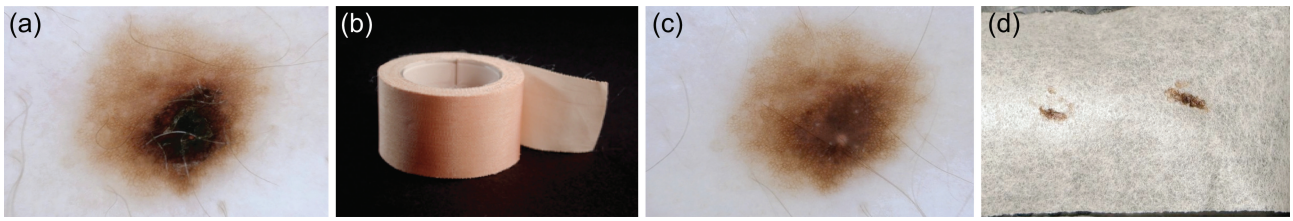

FIGURE 7B.12 (a) Example of a reticular patterned nevus with black lamella. After removing the black lamella with tape (b), the regular network of the nevus is visible (c). Note the black lamella, which is melanized stratum corneum, attached to tape (d).

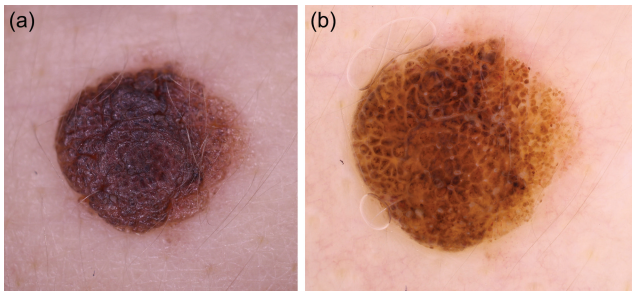

FIGURE 7B.14 (a) Clinical image of melanocytic nevus. (b) Dermatoscopy shows cobblestone globules.

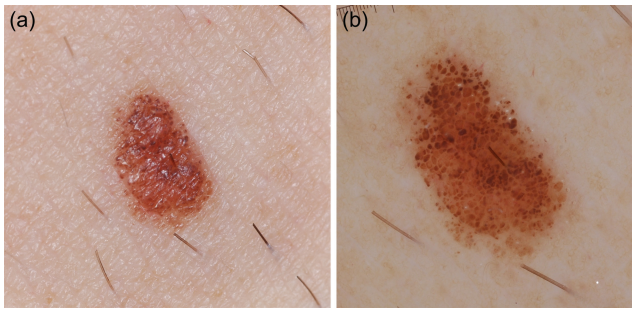

FIGURE 7B.15 (a) Clinical image of melanocytic nevus. (b) Dermatoscopy shows cobblestone globules and smaller rounded globules.

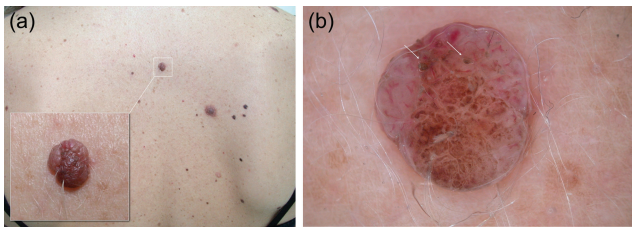

FIGURE 7B.16 (a) Clinical view of dermal nevus—Unna type. (b) Dermoscopy exhibits asymmetry of colors and structures. The nonpigmented area reveals comma vessels, and the pigmented area reveals a mixture of structureless brown areas and globules. Comedo-like openings filled with keratin (arrows) can often be found in these nevi.

dermis (i.e., dermal nevi or small congenital nevi) (4). It is not uncommon to see nevi with both regular globules and cobblestone globules in the same lesion (Figure 7b.15). Globular patterned nevi are most commonly found on the trunk, particularly the upper trunk (5, 6). Globular nevi are one of the most common nevi patterns in children but can be seen in individuals of any age (5, 6).

Variants of globular and cobblestone nevi are clinically recognized as dermal nevi, Unna or Miescher types (Figures 7b.16 and 7b.17). These nevi can be diagnostically challenging, as they often reveal asymmetry of colors and structures with irregularly distributed globules or brown-gray structureless areas. The typical background brown to flesh-colored appearance of these lesions and the presence of comma-like vessels can aid in their recognition (Figures 7b.18-7b.19) (7). On occasion, the vessels in dermal nevi appear arborizing but tend to be out of focus and dull red in color; this contrasts with the

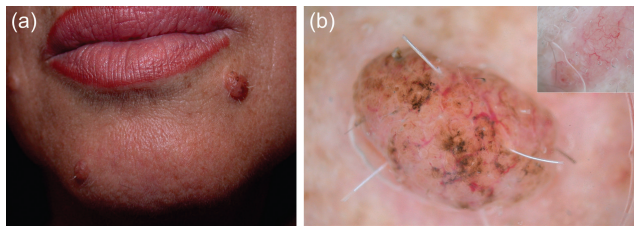

FIGURE 7B.17 (a) Clinical view of dermal nevus—Miescher type. (b) Dermoscopy reveals irregularly distributed brown-to-gray structureless areas and blurred comma and branched vessels.

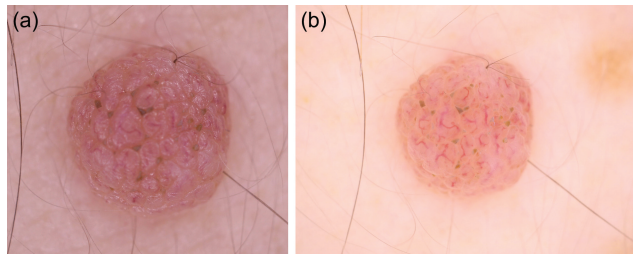

FIGURE 7B.18 (a) Clinical image of dermal nevus. (b) Dermoscopy image shows comma vessels and keratin invaginations.

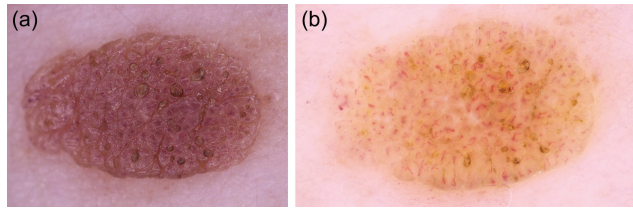

FIGURE 7B.19 (a) Clinical image of dermal nevus. (b) dermoscopy image shows comma vessels and keratin invaginations.

arborizing vessels of basal cell carcinoma, which tend to be bright red and sharply focused. Dermal nevi can also present comedo-like openings, milia-like cysts, and terminal hairs.

Peripheral reticular with central globules pattern

This nevus type consists of a central portion showing a globular pattern, which may be elevated (dermal component), and a peripheral flat portion composed of reticular pigment network (Figures 7b.20-7b.21). Clinically, some of these lesions correspond to the so-called "fried egg" nevus type. These nevi are often large and more frequently encountered on the trunk or scalp than in the extremities.

Homogeneous pattern

The homogeneous pattern of nevi can be tan to light brown, pink, or blue in color (Figures 7b.22-7b.24). It is characterized by a paucity or total lack of discernible structures. A homogeneous blue pattern corresponds to a blue nevus. A homogeneous tan, light brown, or pink pattern is most frequently encountered in fair-skinned individuals. These nevi can be a diagnostic challenge because they may simulate Spitz nevi or

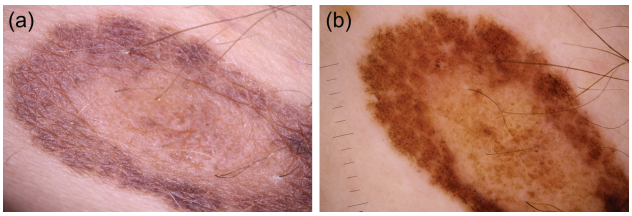

FIGURE 7B.20 (a) Clinical image of atypical/dysplastic melanocytic nevus. (b) Dermatoscopy shows peripheral network and central cobblestone globules. Numerous dots are situated along the network lines, which is a normal finding. Note that this lesion has an identical dermatoscopic pattern to the banal nevus in Figure 21.

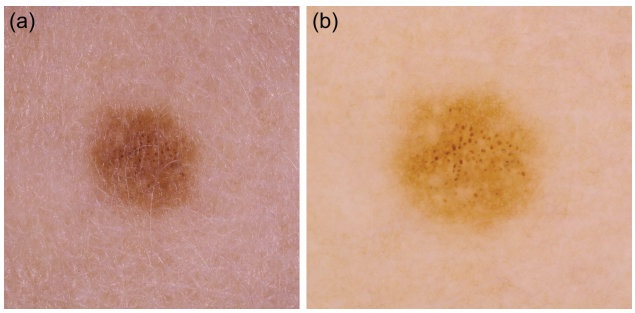

FIGURE 7B.21 (a) Clinical image of banal melanocytic nevus. (b) Dermatoscopy shows peripheral network and central small brown globules. Note that this lesion has an identical dermatoscopic pattern to the atypical/dysplastic nevus in Figure 7b.20.

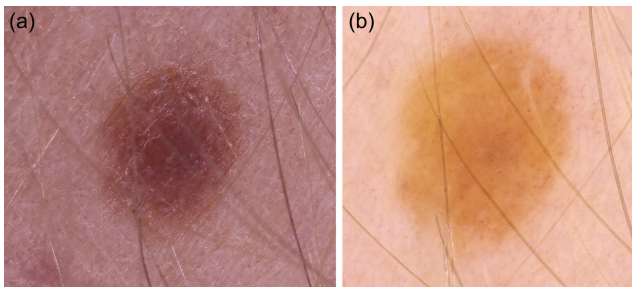

FIGURE 7B.22 (a) Clinical image of melanocytic nevus. (b) Dermoscopy shows a light brown homogeneous pattern.

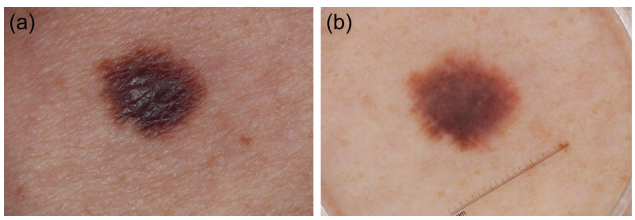

FIGURE 7B.23 (a) Clinical image of melanocytic nevus. (b) Dermatoscopy shows a dark brown homogeneous pattern.

hypomelanocytic/amelanotic melanoma by revealing vascular blush/erythema, dotted vessels either alone or in combination with comma, linear, or serpentine vessels, or nonspecific shades of structureless brown pigmentation. Evaluation of these lesions must always be performed in the context of the

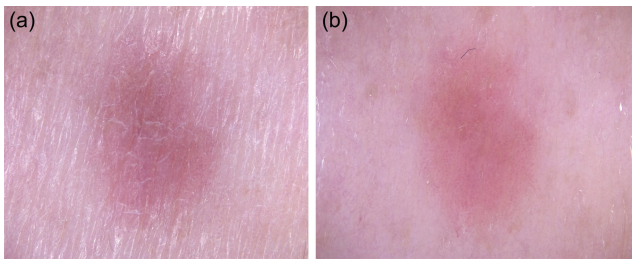

FIGURE 7B.24 (a) Clinical image of melanocytic nevus in red-haired individual. (b) Dermoscopy image shows a pink homogeneous pattern. Without knowledge of the clinical context (fair-skinned individual with red hair; multiple similar lesions; stable over time), the diagnosis of amelanotic melanoma must be considered for lesions with this appearance.

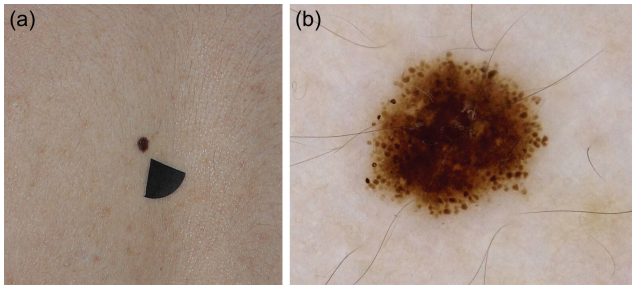

FIGURE 7B.25 (a) Clinical image of melanocytic nevus. (b) Dermatoscopy shows starburst pattern composed of tiered rows of dark brown globules.

individual. For example, a solitary homogeneous pink lesion in a darker-skinned individual should be viewed with caution, whereas the presence of numerous homogeneous pink lesions with polymorphous vessels in a red-haired patient may be a normal finding. This concept is based on the observation that most individuals have nevi that resemble each other (i.e., *moles breed true* or *signature nevus*) (5) and allows the identification of morphologically outlier lesions (i.e., *ugly duckling sign*) (8).

Starburst pattern

The Starburst pattern is specific to Spitz and Reed nevi. The starburst pattern can manifest with peripheral globules tiered one on top of the other (Figures 7b.25-7b.26) or with streaks around the entire perimeter (Figures 7b.27-7b.28). Although the starburst pattern composed of peripheral tiered globules is commonly seen in Spitz nevi, it can also be seen in atypical/dysplastic nevi with spitzoid features. Lesions having a starburst pattern presenting in adolescents or adults, even when completely symmetric, should be viewed cautiously, as melanoma can present with this pattern (9).

Peripheral globular patterns/starburst pattern

A single rim of small, brown peripheral globules surrounding a reticular, homogeneous, or globular center is characteristic of growing nevi (Figure 7b.29). These peripheral globules histopathologically correspond to small junctional nests of melanocytes at the tips of rete ridges and are present at the edge of junctional or compound nevi (see later section on growing nevi for more detail) (10).

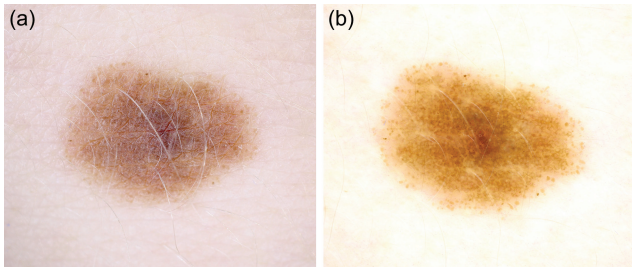

FIGURE 7B.26 (a) Clinical image of melanocytic nevus. (b) Dermatoscopy shows starburst pattern composed of tiered rows of brown globules.

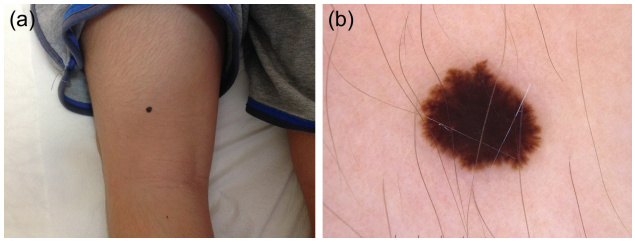

FIGURE 7B.27 (a) Clinical image of melanocytic nevus in a child. (b) Dermatoscopy shows starburst pattern composed of circumferential streaks (radial streaming) at the periphery. The streaks at the periphery can consist of radial streaming or pseudopods.

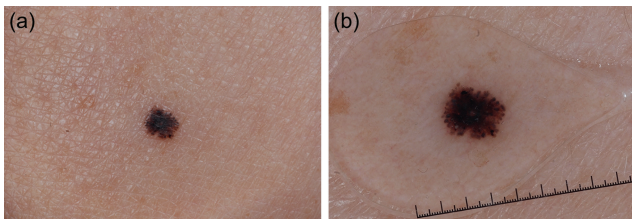

FIGURE 7B.28 (a) Clinical image of melanocytic nevus. (b) Dermatoscopy shows starburst pattern composed of circumferential streaks (pseudopods) at the periphery. The streaks at the periphery can consistent of radial streaming or pseudopods.

Two-component pattern

Two-component nevi reveal two different structures (reticular-globular, reticular-homogeneous, or globular-homogeneous) (Figure 7b.30-7b.31). One half of the lesion manifests one pattern, and the other half of the lesion shows a different pattern. This can be seen as a collision of two different nevi, usually in individuals with many lesions. The possibility of a malignant transformation of a nevus (melanoma) should also be considered when confronted with lesions manifesting two different structures.

Multicomponent pattern

Multicomponent nevi have three or more structures present, including network, globules, and structureless areas (Figures 7b.32–**7b.36**). These structureless areas may include hypopigmented areas (but not white scarlike areas) or hyperpigmented areas (such as blotches). If these structures are distributed symmetrically at least in one axis and in an organized manner (symmetric multicomponent pattern), the lesion will usually prove to be a dysplastic nevus upon histopathological examination. However, if distributed asymmetrically in a disorganized manner, or if melanoma-specific structures are present, the diagnosis of melanoma must be considered.

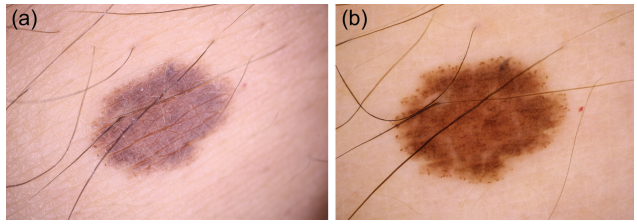

FIGURE 7B.29 (a) Clinical image of melanocytic nevus. (b) Dermatoscopy shows single row of small brown globules at the periphery of a lesion with central network pattern.

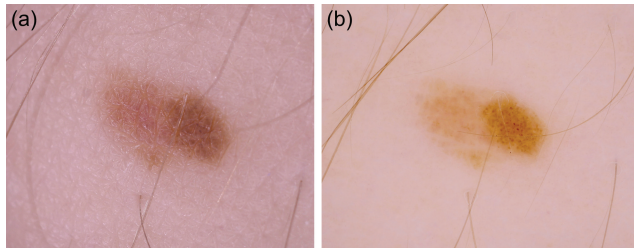

FIGURE 7B.30 (a) Clinical image of melanocytic nevus. (b) Dermatoscopy shows two-component pattern with globular and homogeneous brown patterns.

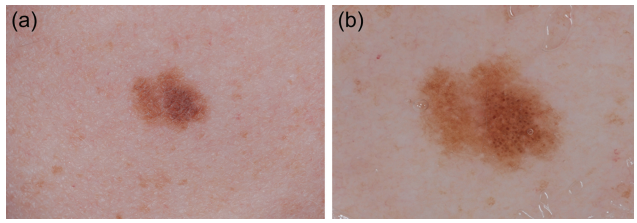

FIGURE 7B.31 (a) Clinical image of melanocytic nevus. (b) Dermatoscopy shows two-component pattern with globular and homogeneous brown patterns.

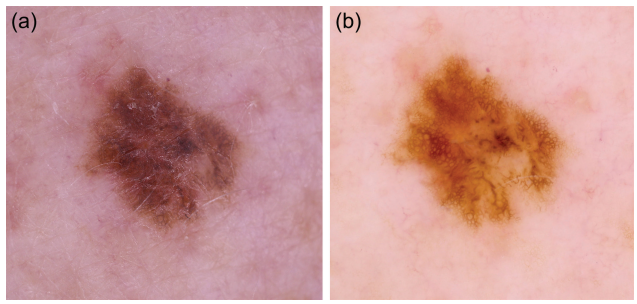

FIGURE 7B.32 (a) Clinical image of atypical/dysplastic nevus. (b) Dermatoscopy shows symmetric multicomponent pattern with atypical network, branched streaks, globules, and hypopigmented structureless areas. Histopathological examination of an excisional biopsy of this lesion was interpreted as dysplastic nevus with moderate atypia.

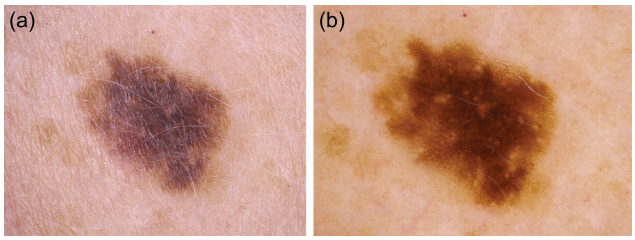

FIGURE 7B.33 (a) Clinical image of atypical/dysplastic nevus. (b) Dermatoscopy shows asymmetric multicomponent pattern with negative network, atypical network, globules, and structureless areas. Histopathological examination of an excisional biopsy of this lesion was interpreted as dysplastic nevus with moderate to severe atypia.

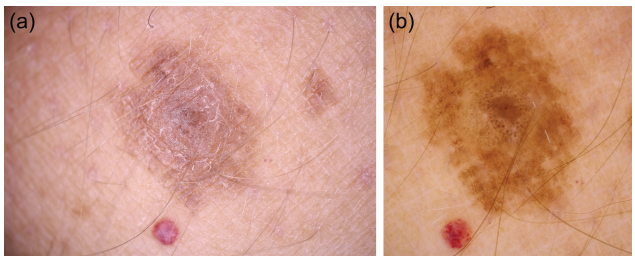

FIGURE 7B.34 (a) Clinical image of atypical/dysplastic nevus. (b) Dermatoscopy shows symmetric multicomponent pattern with central structureless area surrounded by globules and peripheral network.

Melanocytic nevi subtypes

Acquired nevi, including banal and atypical/dysplastic nevi

Clinically, a banal nevus is a symmetric, uniformly pigmented (usually brown), flat, slightly elevated, or raised lesion with regular borders and a round or oval shape. On the other hand, atypical/dysplastic nevi are acquired nevi that have a diameter >5 mm, have a prominent macular component, and variably display asymmetry, notched/irregular/ill-defined borders, and variegated colors. Some authors have proposed replacing the term *atypical/dysplastic nevus* with *large acquired melanocytic nevus* to more accurately reflect the etiology, morphology, and biology of this lesion (11).

The clinical significance of atypical/dysplastic nevi includes: (i) Their presence is associated with melanoma risk (12) in a dose–response manner and is greatest in individuals who have a family history of cutaneous melanoma, and (ii) Their morphology can resemble early presentations of melanoma with naked-eye examination, which can lead to unnecessary biopsies. Despite their name, the risk of melanoma arising in association with atypical/dysplastic nevi is exceedingly low, and prophylactic removal of these lesions to prevent melanoma development is not effective, warranted, or recommended (13). Furthermore, although up to 30% of melanomas are histopathologically associated with a nevus, the associated nevus can be banal, atypical/dysplastic, or congenital (11, 14).

Banal and atypical/dysplastic nevi can display any of the dermatoscopic patterns depicted in Figure 7b.1. To date, no study has documented a dermatoscopic structure or pattern specific to atypical/dysplastic nevi. As a result, the dermatoscopist

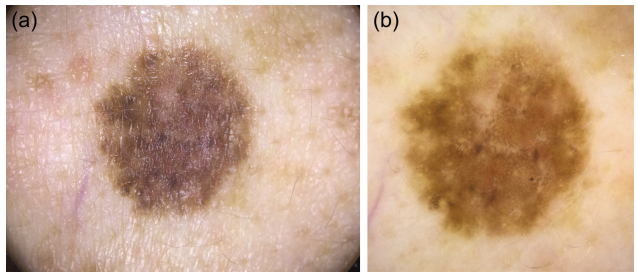

FIGURE 7B.35 (a) Clinical image of atypical/dysplastic nevus. (b) Dermatoscopy shows asymmetric multicomponent pattern with network, structureless zones, and negative network. Histopathological examination of an excisional biopsy of this lesion was interpreted as dysplastic nevus with severe atypia.

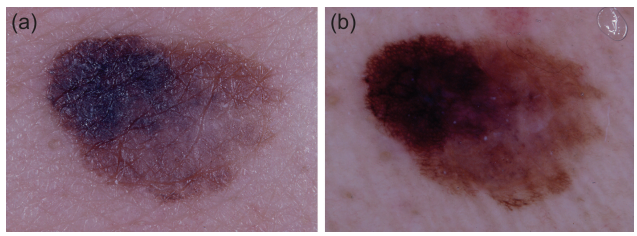

FIGURE 7B.36 (a) Clinical image of atypical/dysplastic nevus. (b) Dermatoscopy reveals a multicomponent pattern with atypical network, dots, eccentric blotch, blue-white to pink veil, and peppering. Histopathological examination of an excisional biopsy of this lesion was interpreted as dysplastic nevus.

recognizes the vast majority of atypical/dysplastic nevi as benign lesions that do not require biopsy. Even the dermoscopy expert, however, will be challenged by a subset of indeterminate atypical/dysplastic nevi that are difficult, if not impossible, to differentiate from melanoma. These indeterminate lesions often have a multicomponent pattern and/or display melanoma-specific structures. Any of the melanoma-specific structures can be seen in nevi, and their presence should always be viewed with caution, prompting consideration of monitoring, biopsy, or another diagnostic procedure (e.g., reflectance confocal microscopy). In particular, atypical streaks, shiny white structures, blue-white veil over raised areas, scarlike depigmentation, and polymorphous vessels (specifically the combination of dotted and serpentine vessels) are unusual in nevi, and a biopsy should generally be considered for lesions with these features.

Growing nevi

Clinically, a growing nevus is defined as a lesion that is increasing in surface area over time. Digital dermatoscopic imaging of nevi led to the observation that nevi with a peripheral rim of small brown globules frequently increase in size; however, not all growing nevi display this dermatoscopic pattern. The central component of nevi with a peripheral rim of globules may be reticular, homogeneous, or globular. Histopathologically, peripheral globules correspond to small junctional nests of melanocytes at the tips of the rete ridges and are present at the edge of junctional or compound nevi. Recognition of this dermatoscopic pattern is of clinical importance, as these nevi are common in adolescence and young adulthood, particularly among individuals with increased total body nevus counts, but

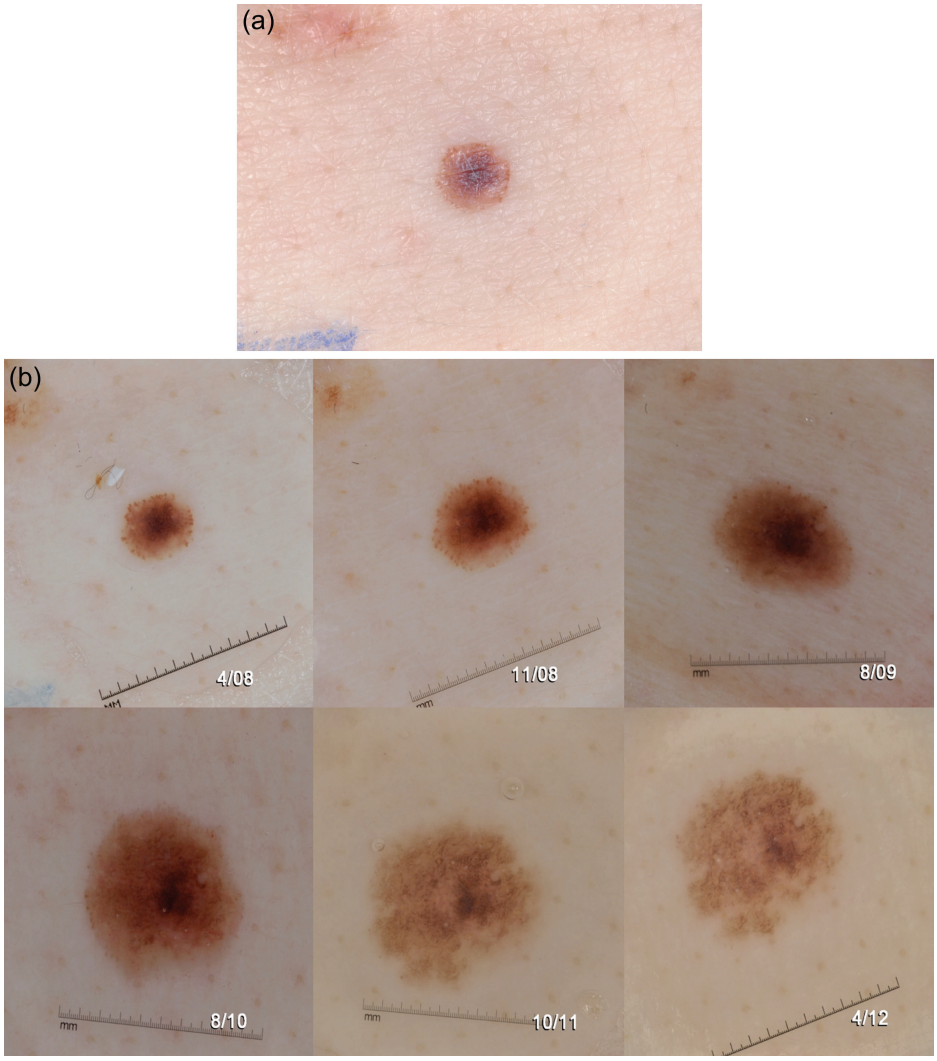

FIGURE 7B.37 (a) Clinical image of melanocytic nevus. (b) Dermatoscopy of this nevus revealed a peripheral globular pattern. This pattern is often seen in nevi that are enlarging, as is evident in the sequence of images of this nevus taken over time.

are rare in adults (6). Accordingly, a lesion with a peripheral globular pattern in an adult, especially if solitary, should be examined with caution, and a biopsy must be considered to rule out melanoma. The likelihood of lesions with a peripheral globular pattern being melanoma increases with age. Furthermore, one must always carefully examine the central component of a lesion with a peripheral rim of globules for melanoma-specific structures; if present, a biopsy should be strongly considered, no matter the age of the patient. Longitudinal studies of growing nevi with a peripheral rim of small brown globules have revealed that these lesions will reveal symmetric enlargement over years until senescence, at which point the peripheral rim of globules will no longer be visible (Figures 7b.37-7b.38) (10).

Congenital melanocytic nevi

Congenital melanocytic nevi (CMN) are determined in utero. Although most CMN are present at birth, some are not apparent until the first 2 years of life (i.e., tardive CMN). The principal dermatoscopic patterns of CMN are reticular, globular, peripheral reticular with central globular, structureless/homogeneous brown with or without remnants of globules or network, and multicomponent. Dermatoscopic clues that suggest the congenital origin of a nevus include:

(a) Reticular network composed of thick linear network fragments that resemble hyphal elements.

(b) Cobblestone globules.

(c) Target dots or target globules, which are dots or globules present within the hypopigmented holes of the pigment network. These correspond histopathologically to nevomelanocytic nests in the dermal papillae.

(d) Milia-like cysts.

(e) Hypertrichosis, often accompanied by perifollicular hyperpigmentation or hypopigmentation.

(f) Dotted vessels present in the hole of a pigment network, which correspond to vessels in dermal papillae (referred to as "targetoid vessels" or "target network with vessels").

Special situations

Halo nevi

Halo nevi are nevi surrounded by a rim of depigmentation, undergoing progressive involution with eventual total disappearance (Figure 7b.39). Halo nevi are rare and most

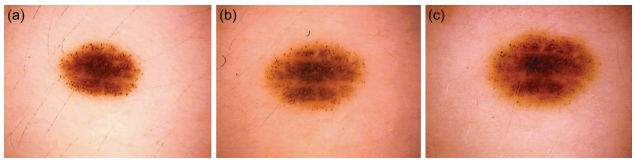

FIGURE 7B.38 Baseline digital dermoscopic image of a nevus with reticular pattern and peripheral rim of globules (a). During 1-year follow-up, the nevus shows symmetric enlargement (b) until the disappearance of the peripheral globules after 2 years, which indicates that the nevus has entered senescence (c). (Images courtesy of Dr. Harald Kittler.)

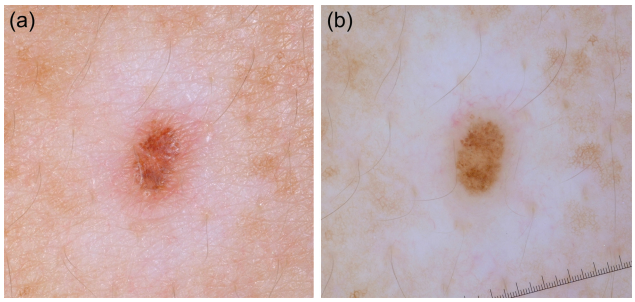

FIGURE 7B.39 (a) Clinical image of halo nevus. (b) Dermoscopy image shows central globules and structureless brown areas surrounded by peripheral depigmentation.

commonly encountered on the trunk, particularly the back, of younger individuals. The most common dermatoscopic pattern found in halo nevi is homogeneous-globular (42%), followed by homogeneous (23%) and globular (17%) patterns. Reticular patterns are uncommon in halo nevi (7%), and therefore, melanoma should be ruled out in these cases (15). The presence of a white halo surrounding a melanocytic lesion is not necessarily reassuring, as halo melanomas can occur.

Ultraviolet radiation–related changes

Melanocytic nevi can undergo morphological changes after exposure to ultraviolet radiation (natural or artificial sources). These changes include increase in surface area, pigmentation, and quantity and size of dots/globules, as well as the appearance of blurring of pigment network lines, thicker pigment lines, scaling, erythema, dotted vessels, and bluish-gray regression structures (16–18).

Balloon cell nevus

Balloon cell nevus is a rare variant of a melanocytic nevus in which a part of the cell population is composed of "balloon" cells, which are formed by vacuolization of melanocytes due to enlargement and disintegration of melanosomes. They typically appear on the head and neck area in the first three decades of life (19). Dermoscopically, balloon cell nevi display white globules (Figures 7b.40-7b.41), which histopathologically correspond to balloon cell clusters.

Traumatized nevus

Trauma most frequently occurs in papular or sessile melanocytic nevus, and intradermal nevus. Trauma may be due to various mechanisms including scratching, shaving, or clothing. After trauma, these nevi may display clinical and dermoscopic features worrisome for melanoma, including a dermoscopic

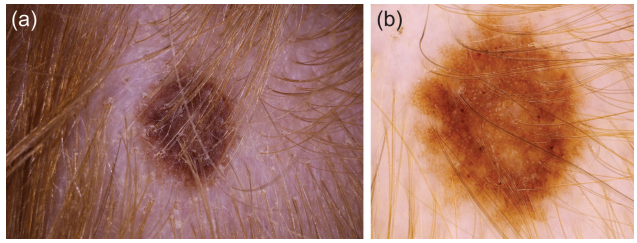

FIGURE 7B.40 (a) Clinical image of balloon cell nevus on scalp in red-haired individual. (b) Dermoscopy shows a reticular patterned nevus with central white globules, which are characteristic of balloon cell changes histopathologically.

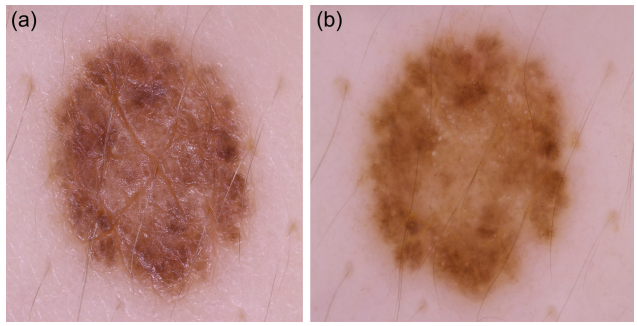

FIGURE 7B.41 (a) Clinical image of a balloon cell nevus on the upper back. (b) Dermoscopy shows peripheral structureless brown areas and central hypopigmentation with white globules.

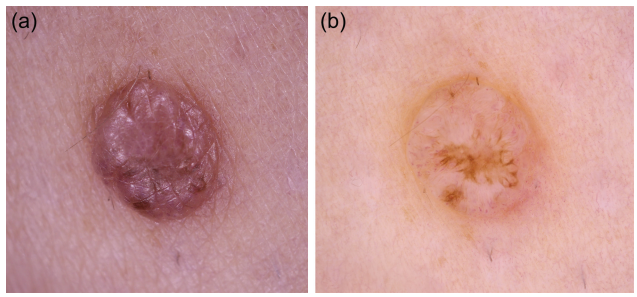

FIGURE 7B.42 (a) Clinical image of dermal nevus on the lower extremity of a female that often gets traumatized during shaving. (b) Dermoscopy shows predominantly structureless lesion with central brown streaks confined to the lesion. This feature is typical of recurrent/persistent nevi or traumatized nevi.

appearance similar to that seen in recurrent nevi (Figure 7b.42) (20).

Combined nevus

Combined nevus refers to a melanocytic nevus showing histological characteristics of two or more nevus subtypes. The most common "combined nevus" is a common blue nevus in association with a dermal and/or compound nevus. The combination of different histological nevus patterns results in a clinical lesion showing asymmetry in shape and/or color, mimicking melanoma. Dermoscopy shows both patterns intermingled, most frequently a structureless blue central area and a peripheral pigmented network. However, any combination of patterns can occur (21).

Acknowledgement: The authors sincerely thank the authors of the previous edition of this chapter, including Iris Zalaudek, Ashfaq A. Marghoob, and Alfred W. Kopf.

References

1. Blum A, Soyer HP, Garbe C, Kerl H, Rassner G, Hofmann-Wellenhof R. The dermoscopic classification of atypical melanocytic naevi (Clark naevi) is useful to discriminate benign from malignant melanocytic lesions. *Br J Dermatol.* 2003;149(6):1159–64.
2. Hofmann-Wellenhof R, Blum A, Wolf IH, et al. Dermoscopic classification of Clark's nevi (atypical melanocytic nevi). *Clin Dermatol.* 2002;20(3):255–8.
3. Hofmann-Wellenhof R, Blum A, Wolf IH, et al. Dermoscopic classification of atypical melanocytic nevi (Clark nevi). *Arch Dermatol.* 2001;137(12):1575–80.
4. Marchetti MA, Kiuru MH, Busam KJ, et al. Melanocytic naevi with globular and reticular dermoscopic patterns display distinct BRAF V600E expression profiles and histopathological patterns. *Br J Dermatol.* 2014;171(5):1060–5.
5. Scope A, Marchetti MA, Marghoob AA, et al. The study of nevi in children: principles learned and implications for melanoma diagnosis. *J Am Acad Dermatol.* 2016;75(4):813–23.
6. Zalaudek I, Schmid K, Marghoob AA, et al. Frequency of dermoscopic nevus subtypes by age and body site: a cross-sectional study. *Arch Dermatol.* 2011;147(6):663–70.
7. Argenziano G, Zalaudek I, Corona R, et al. Vascular structures in skin tumors: a dermoscopy study. *Arch Dermatol.* 2004;140(12):1485–9.
8. Gaudy-Marqueste C, Wazaefi Y, Bruneu Y, et al. Ugly duckling sign as a major factor of efficiency in melanoma detection. *JAMA Dermatol.* 2017;153(4):279–84.
9. Lallas A, Moscarella E, Longo C, et al. Likelihood of finding melanoma when removing a Spitzoid-looking lesion in patients aged 12 years or older. *J Am Acad Dermatol.* 2015;72(1):47–53.
10. Bajaj S, Dusza SW, Marchetti MA, et al. Growth-curve modeling of nevi with a peripheral globular pattern. *JAMA Dermatol.* 2015;151(12):1338–45.
11. Hofmann-Wellenhof R, Marghoob AA, Zalaudek I. Large acquired nevus or dysplastic nevus: what's in the name of a nevus? *JAMA Dermatol.* 2016;152(6):623–4.
12. Gandini S, Sera F, Cattaruzza MS, et al. Meta-analysis of risk factors for cutaneous melanoma: I. Common and atypical naevi. *Eur J Cancer.* 2005;41(1):28–44.
13. Tsao H, Bevona C, Goggins W, Quinn T. The transformation rate of moles (melanocytic nevi) into cutaneous melanoma: a population-based estimate. *Arch Dermatol.* 2003;139(3):282–8.
14. Duffy K, Grossman D. The dysplastic nevus: from historical perspective to management in the modern era: part II. Molecular aspects and clinical management. *J Am Acad Dermatol.* 2012;67(1):19 e1–2; quiz 31–2.
15. Kolm I, Di Stefani A, Hofmann-Wellenhof R, et al. Dermoscopy patterns of halo nevi. *Arch Dermatol.* 2006;142(12):1627–32.
16. Carrera C, Puig-Butille JA, Aguilera P, et al. Impact of sunscreens on preventing UVR-induced effects in nevi: in vivo study comparing protection using a physical barrier vs sunscreen. *JAMA Dermatol.* 2013;149(7):803–13.
17. Ghani-Nejad H, Hallaji Z, Damavandi MR, et al. Dermoscopic changes of melanocytic nevi after psoralen-ultraviolet A and narrow-band ultraviolet B phototherapy. *Indian J Dermatol.* 2016;61(1):118.
18. Zaher H, Bassiouny D, Abdel Hay R, Samir N, Ragab N, Sayed S. Dermoscopic and immunohistochemical changes in acquired melanocytic nevi following narrow-band ultraviolet B therapy. *Dermatology.* 2016;232(3):273–8.
19. Martinez-Casimiro L, Sanchez Carazo JL, Alegre V. Balloon cell naevus. *J Eur Acad Dermatol Venereol.* 2009;23(2):236–7.
20. Yoshida Y, Yamada N, Adachi K, Tanaka M, Yamamoto O. Traumatized recurrent melanocytic naevus with typical starburst pattern on dermoscopy. *Acta Derm Venereol.* 2008;88(4):408–9.
21. de Giorgi V, Massi D, Salvini C, Trez E, Mannone F, Carli P. Dermoscopic features of combined melanocytic nevi. *J Cutan Pathol.* 2004;31(9):600–4.

7C BENIGN MELANOCYTIC LESIONS: INTRADERMAL NEVUS

Rainer Hofmann-Wellenhof

Contents

Introduction . . . 157
Eclipse nevus . . . 157
Dermoscopic characteristics . . . 157
Miescher nevus . . . 157
Dermoscopic characteristics . . . 157
Unna nevus . . . 158
Dermoscopic characteristics . . . 159
Summary . . . 163
References . . . 163

Introduction

Intradermal nevi (IDN) are benign melanocytic neoplasms composed of nests of nevomelanocytes that are located predominantly in the dermis. There are multiple variants of IDN, and they all have one unifying clinical criterion; they are elevated and form a papule or a nodule.

Intradermal nevi can be classified into three variants based on their clinical morphology, dermoscopic morphology, and anatomical location. In this chapter, we will outline the typical features of the eclipse nevus, the Miescher nevus, and the Unna nevus.

Eclipse nevus

The eclipse nevus is a compound nevus with a central portion resembling an intradermal nevus, which is surrounded by a junctional component (1). Clinically, the tan elevated center and brown peripheral rim create the characteristic pattern displayed by eclipse nevi. In some cases, the brown peripheral rim can be disrupted or can have a stellate appearance (Figure 7c.1). The preferred anatomic location for eclipse nevi, especially in children, is the scalp (2, 3). There is some evidence that the eclipse nevus transforms into a pure intradermal nevus (1).

Dermoscopic characteristics

Dermoscopy of the eclipse nevus reveals two components. The elevated central part is usually light brown to skin colored. This papule often has a papillomatous surface forming a cobblestone pattern. Within this papillomatous region, one can often see short, curved vessels (comma vessels). The pigmented periphery displays brown shades with a reticular or homogeneous pattern. On rare occasions, the pigmentation at the periphery is disrupted or can reveal streaks, creating a stellate appearance (Figures 7c.2 to 7c.5) (3).

The typical eclipse nevus is a benign melanocytic nevus that does not need to be excised. Some eclipse nevi may appear somewhat irregular, and these lesions can be monitored via digital dermoscopy (4).

Miescher nevus

This IDN is named after Alfred Guido Miescher, professor and director of the University Dermatology Clinic in Zürich, Switzerland. In his original landmark work, *Histologie de 100 cas de naevi pigmentaires d'après les methods de Masson*, published in 1935, Miescher studied 100 hemispherical-shaped nevi found mostly on women's faces. These nevi are dome-shaped papules in which melanocytes are distributed mostly endophytically, often in a wedge pattern. In contrast to the intradermal nevus of Unna's type, the nevus cells in a Miescher's nevus often extend to the deep reticular dermis (5, 6).

Miescher nevi are mainly found on the face. Studying 751 nevi, Sanchez Yus et al. found that 91% of Miescher nevi were located on the face and that 94% of the IDN on the face were Miescher nevi. The reason for this distribution has not been elucidated (7). Sanchez Yus et al. postulated that the embryogenetic origin of the dermis of the face may hold the answer as to why Miescher's nevi are located on the face. The dermis of the frontal, temporal, maxillary, and mandibulary regions derives from the neural crest, whereas the dermis of the parietal/occipital regions originates from the paraxial mesoderm (somites and somitomeres) (8). In their study of 137 nevi, they divided the head and neck area into two regions: Area A (parietal + occipital + low neck) and area B (face + temporal + frontal + high neck). In region A, only 2% of nevi were of the Miescher's type, whereas 89% of the nevi in region B were Miescher nevi. Moreover, 99% of Miescher nevi were found in region B.

Clinically, the Miescher nevus is a dome-shaped papule with a smooth surface. It is not uncommon for terminal hairs to emanate from Miescher nevi. The color of the Miescher nevus is brown to nearly skin colored, and their diameter typically ranges between 4 and 6 millimeters (Figures 7c.6, 7c.7). Miescher's nevi usually remain stable over the lifetime of the individual. It is postulated by some that some IDN can become fibrous papules. Rarely, one can observe a secondary ossification in an IDN (osteo-nevus of Nanta) (9).

Dermoscopic characteristics

The dermoscopic appearance of Miescher nevi is relatively nonspecific. Most Miescher nevi show a homogeneous pattern. The color in the center can be a bit darker than at the periphery of the lesion. Vessels can be seen quite frequently. Linear curved vessels, also called comma vessels, serpentine vessels, and arborizing vessels, can be seen most often (Figures 7c.8 to 7c.10). The presence of a golden brown halo may assist in differentiating a Miescher nevus from basal cell carcinomas

DOI: 10.1201/9780429487873-19



FIGURE 7C.1 Clinical image of an eclipse nevus on the scalp. Note the hypopigmented papillomatous central part surrounded by a darker pigmented rim.



FIGURE 7C.2 Different dermoscopic examples of eclipse nevi. The central dermal part is surrounded by a hyperpigmented rim with different colors and shapes. In Figure 7c.1, one can see the typical comma-like vessels, whereas in Figure 7c.5, a polymorphous pattern of vessels is visible.



FIGURE 7C.3 Different dermoscopic examples of eclipse nevi. The central dermal part is surrounded by a hyperpigmented rim with different colors and shapes. In Figure 7c.1, one can see the typical comma-like vessels, whereas in Figure 7c.5, a polymorphous pattern of vessels is visible.

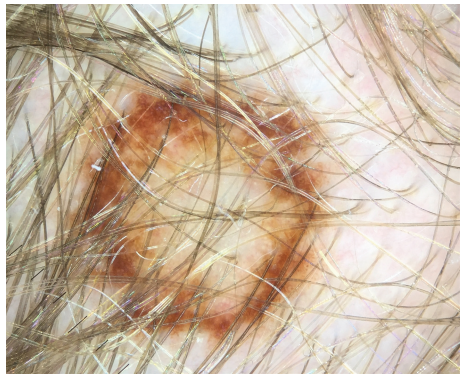

FIGURE 7C.4 Different dermoscopic examples of eclipse nevi. The central dermal part is surrounded by a hyperpigmented rim with different colors and shapes. In Figure 7c.1, one can see the typical comma-like vessels, whereas in Figure 7c.5, a polymorphous pattern of vessels is visible.



FIGURE 7C.5 Different dermoscopic examples of eclipse nevi. The central dermal part is surrounded by a hyperpigmented rim with different colors and shapes. In Figure 7c.1, one can see the typical comma-like vessels, whereas in Figure 7c.5, a polymorphous pattern of vessels is visible.



FIGURE 7C.6 Examples of typical Miescher nevi, clinical view.

(Figure 7c.11) (10). Besides basal cell carcinomas, fibrous papules and adnexal tumors are in the differential diagnosis of these nevi.

There are no reports in literature of a melanoma arising in a Miescher nevus.

Unna nevus

This IDN is named after Paul Gerson Unna, who named it "soft nevus" in his landmark work, *Histopathology of Diseases of*



FIGURE 7C.7 Examples of typical Miescher nevi, clinical view.



FIGURE 7C.8 Examples of typical Miescher nevi, clinical view.

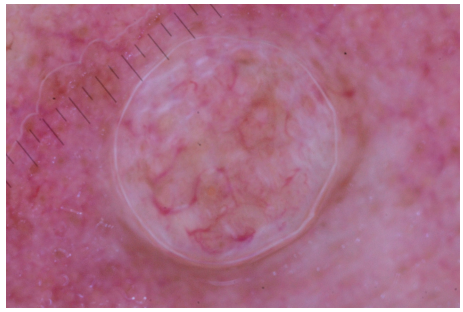

FIGURE 7C.9 Dermoscopic images of the Miescher nevi shown in Figures 7c.6–7c.8. All nevi show a homogeneous pattern displaying different shades of brown and comma-like vessels.

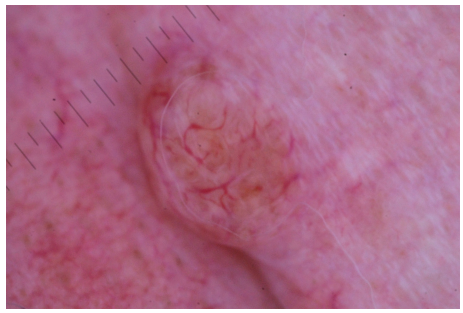

FIGURE 7C.10 Dermoscopic images of the Miescher nevi shown in Figures 7c.6–7c.8. All nevi show a homogeneous pattern displaying different shades of brown and comma-like vessels.

the Skin, published in 1896 (11). Unna defined this nevus as "sessile, button-shaped, raspberry-like, molluscoid or fibromatous soft nevus usually seen in adults." Ackerman and Milde described this nevus as a strikingly exophytic melanocytic nevus in the shape of a fibroepithelial polyp/papilloma (5). We use the term *papillomatous nevus* synonymously with *Unna nevus*. In contrast to the Miescher nevus, the nevus cell nests in an Unna nevus do not reach the reticular dermis. In a screening population of 700 persons, almost one-third of Caucasians had at least one Unna nevus (12).

Clinically, Unna nevi are predominantly located on the trunk with a median diameter of 5.0 millimeters. They are sessile to pedunculated papules with a papillomatous surface. The most common colors are light brown, dark brown, and skin colored. Most of the time, the pigment is distributed uniformly throughout the lesion, but sometimes, there is pigmentation in the center of the lesion with a skin-colored periphery (Figures 7c.12 to 7c.17) (12).

Dermoscopic characteristics

Dermoscopy often reveals light brown or dark brown colors. However, white and red regions can also be seen. Uniform pigmentation, multifocal hypo/hyperpigmentation, and central hyperpigmentation are the most common distribution of colors in Unna nevi. The dermoscopic patterns of Unna nevi include the homogeneous pattern, the globular pattern, and the cobblestone pattern (Figures 7c.18 to 7c.23). Unna nevi frequently reveal vessels. The curved vessels or comma vessels are stereotypic for Unna nevi. Sometimes, dotted or atypical vessels can also be seen (Figures 7c.24-7c.28) (12). Vessels can be more prominent in irritated Unna nevi (Figure 7c.29). Additionally, Unna nevi frequently have a papillomatous surface with deep invaginations filled with keratin. The keratin -filled sulci can resemble comedo-like openings associated with seborrheic keratosis (Figures 7c.29-7c.32). Braun et al. described the wobble sign in IDN. Placing a dermatoscope on the lesion and then applying horizontal pressure in a back and forth motion will show that an IDN wobbles, whereas lesions without a dermal component will slide and not wobble (13).

There are just a few reports in the literature of melanoma arising in association with a papillomatous nevus (Figure 7c.33).

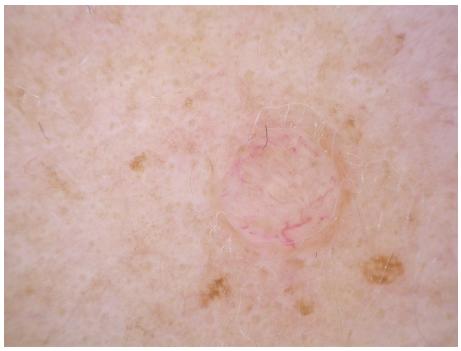

FIGURE 7C.11 Dermoscopic images of the Miescher nevi shown in Figures 7c.6–7c.8. All nevi show a homogeneous pattern displaying different shades of brown and comma-like vessels.



FIGURE 7C.12 Clinical examples of Unna nevi demonstrating the most common colors.



FIGURE 7C.13 Clinical examples of Unna nevi demonstrating the most common colors.



FIGURE 7C.14 Clinical examples of Unna nevi demonstrating the most common colors.



FIGURE 7C.15 Clinical examples of Unna nevi demonstrating the most common colors.



FIGURE 7C.16 Clinical examples of Unna nevi demonstrating the most common colors.



FIGURE 7C.17 Clinical examples of Unna nevi demonstrating the most common colors.

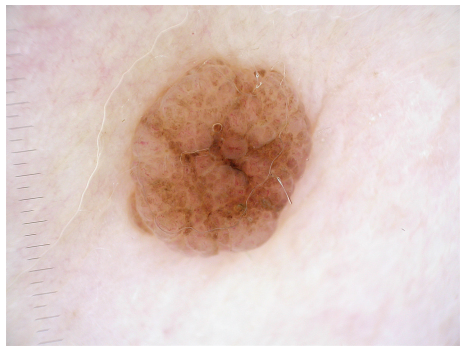

FIGURE 7C.18 Typical cobblestone pattern in Unna nevi with different shades of brown.

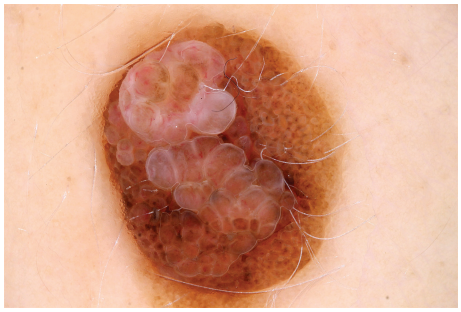

FIGURE 7C.19 Typical cobblestone pattern in Unna nevi with different shades of brown.



FIGURE 7C.20 Examples of Unna nevi with a smooth surface. The color is faint brown and skin colored.

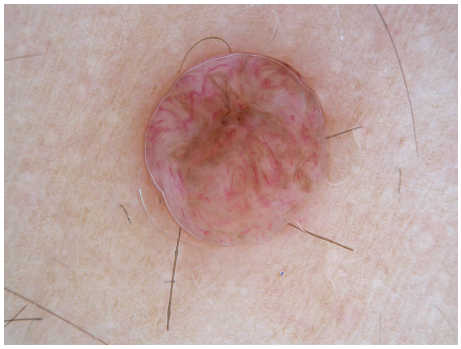

FIGURE 7C.21 Examples of Unna nevi with a smooth surface. The color is faint brown and skin colored.

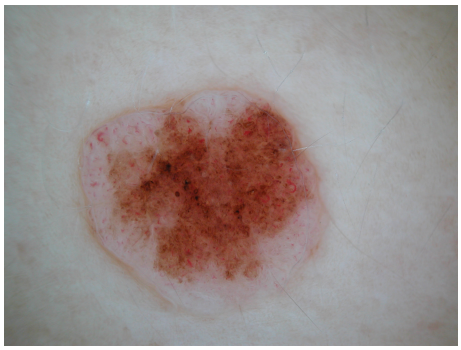

FIGURE 7C.22 Unna nevi with central hyperpigmentation; this pattern of pigmentation is more frequent in older age.

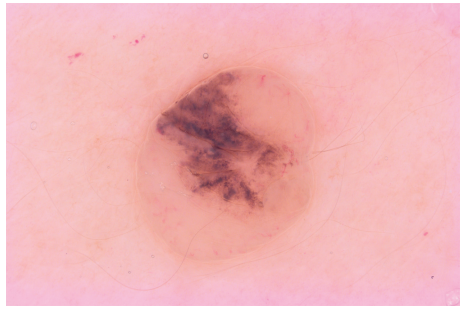

FIGURE 7C.23 Unna nevi with central hyperpigmentation; this pattern of pigmentation is more frequent in older age.

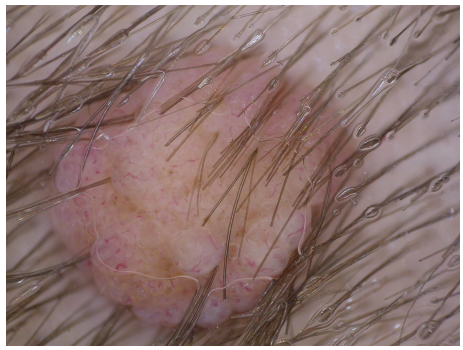

FIGURE 7C.24 Different pattern of vessels in Unna nevi. Stereotypic comma vessels are frequently visible, but Unna nevi can show a wide range of vessel morphologies.

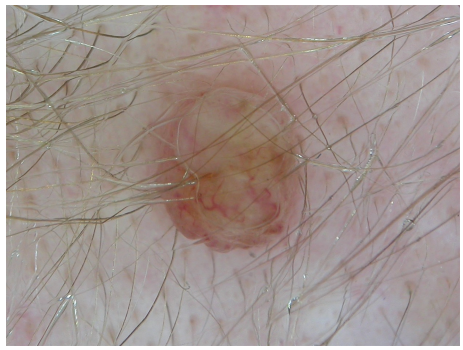

FIGURE 7C.25 Different pattern of vessels in Unna nevi. Stereotypic comma vessels are frequently visible, but Unna nevi can show a wide range of vessel morphologies.



FIGURE 7C.26 Different pattern of vessels in Unna nevi. Stereotypic comma vessels are frequently visible, but Unna nevi can show a wide range of vessel morphologies.

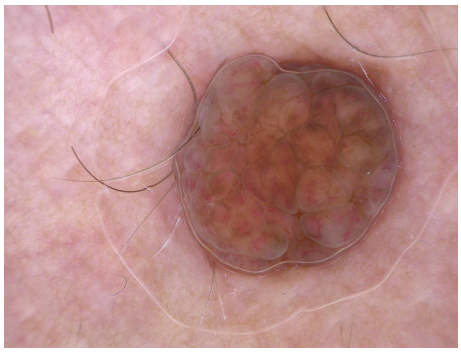

FIGURE 7C.27 Different pattern of vessels in Unna nevi. Stereotypic comma vessels are frequently visible, but Unna nevi can show a wide range of vessel morphologies.

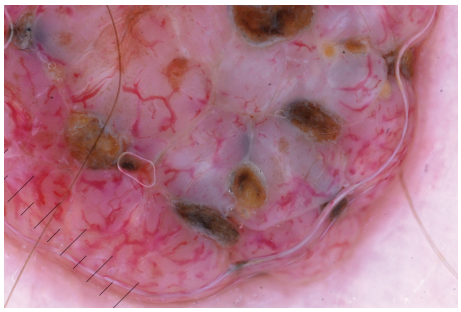

FIGURE 7C.28 Different pattern of vessels in Unna nevi. Stereotypic comma vessels are frequently visible, but Unna nevi can show a wide range of vessel morphologies.

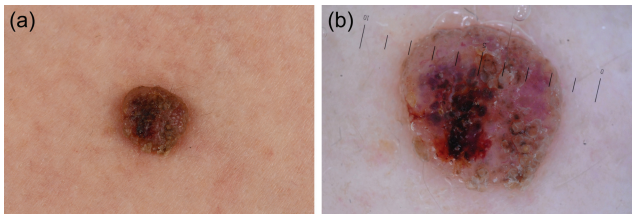

FIGURE 7C.29 Clinical (a) and dermoscopic (b) image of a traumatized Unna nevus. In the dermoscopic image, irregular vessel and a red background are evident (b).

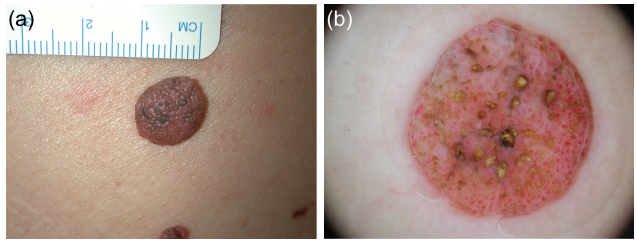

FIGURE 7C.30 Clinical (a) and dermoscopic (b) image of an Unna nevus with keratin plugs and stereotypic comma vessels.

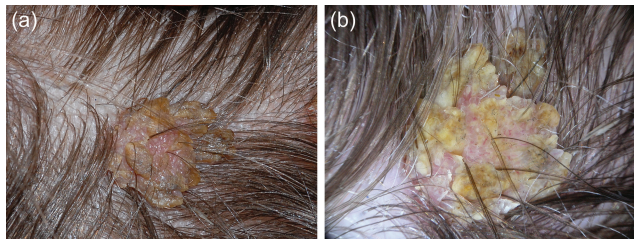

FIGURE 7C.31 Clinical (a) and dermoscopic (b) image of an Unna nevus with a surface covered by keratin.

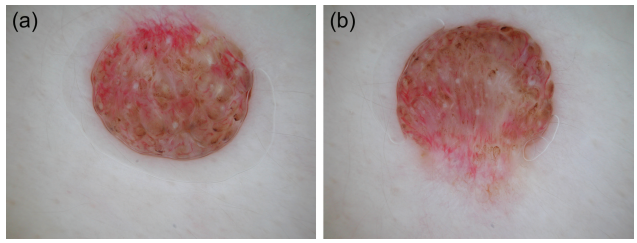

FIGURE 7C.33 (a, b) Another example of the wobble sign in an typical Unna nevus.



FIGURE 7C.34 Stereotypic dermoscopic image of an intradermal nevus beside a small junctional nevus.

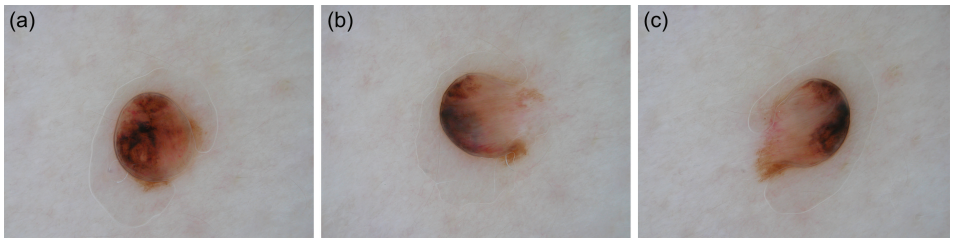

FIGURE 7C.32 (a–c) Wobble sign: Moving the dermatoscope horizontally enables one to see the "hidden" under surface of a sessile IDN.

The differential diagnoses include skin tags, fibromas, neurofibromas, and adnexal tumors.

Summary

Intradermal nevi are very common. One can divide them into the eclipse nevus, the Miescher nevus located mainly on the face, and the Unna nevus located predominantly on the trunk (Figure 7c.34). Clinically, they are dome-shaped to sessile to pedunculated papules. IDN often reveal comma vessels and are light brown to skin colored with a homogeneous or globular pattern.

References

1. Schaffer JV, Glusac, EJ, Bolognia JL. The eclipse naevus: tan centre with stellate rim. *Br J Dermatol.* 2001;145:1023–6.
2. Tcheung WJ, Bellet JS, Prose NS, Cyr DD, Nelson KC. Clinical and dermoscopic features of 88 scalp naevi in 39 children. *Br J Dermatol.* 2011;165:137–43.
3. Zalaudek I, Schmid K, Niederkorn A, Fink-Puches R, Richtig E, Wolf I, Hofmann-Wellenhof R. Proposal for a clinical-dermoscopic classification of scalp naevi. *Br J Dermatol.* 2014;170:1065–72.
4. Kessides MC, Puttgen KB, Cohen BA. No biopsy needed for eclipse and cockade nevi found on the scalps of children. *Arch Dermatol.* 2009;145:1334–6.
5. Ackerman AB, Magana-Garcia M. Naming acquired melanocytic nevi: Unna's, Miescher's, Spitz's, Clark's. *Am J Dermatopathol.* 1990;12:193–209.
6. Vaira F, Nazzaro G, Crosti C, Veraldi S. The men or women behind Nevi: Alfred Guido Miescher. *JAMA Dermatol.* 2014;150:411.
7. Yus ES, del Cerro M, Simón RS, Herrera M, Rueda M. Unna's and Miescher's nevi: two different types of intradermal nevus: hypothesis concerning their histogenesis. *Am J Dermatopathol.* 2007;29:141–51.
8. Fernandez-Flores A, Sanchez-Velicia L, Manjon JA, Alija A, Soto F. A hypothesis on the morphologic differences between Unna and Miescher nevi on the head and neck, based on embryologic bases. *Am J Dermatopathol.* 2012;34:602–6.
9. Murtas D, Rongioletti F, Ferreli C, Atzori L, Pilloni L. Ossification into the osteo-nevus of Nanta: an interpretative insight. *Int J Dermatol.* 2019;58:e10–2.
10. Grazzini M, Marghoob AA. The "Golden Brown Halo" of the Miescher Nevus. *Arch Dermatol.* 2012;148:870.
11. Vaira F, Nazzaro G, Veraldi S. The men or women behind Nevi: Paul Gerson Unna. *JAMA Dermatol.* 2014;150:176.
12. Niederkorn A, Ahlgrimm-Siess V, Fink-Puches R, Wolf IH, Richtig E, Lackner HK, Hofmann-Wellenhof R. Frequency, clinical and dermoscopic features of benign papillomatous melanocytic naevi (Unna type). *Br J Dermatol.* 2009;161:510–4.
13. Braun RP, Krischer J, Saurat JH. The "wobble sign" in epiluminescence microscopy as a novel clue to the differential diagnosis of pigmented skin lesions. *Arch Dermatol.* 2000;136:940–2.

7D BENIGN MELANOCYTIC LESIONS: BLUE NEVI AND VARIANTS

Josep Riera-Monroig, Alicia Barreiro, Josep Malvehy, and Cristina Carrera

Contents

Introduction 164
Blue nevi 164
Dermoscopy 164
Special locations 164
Blue nevi variants 164
Other diagnostic techniques 166
Differential diagnosis of blue nevi 166
References 167

Introduction

The blue nevus (BN) is a distinct benign melanocytic nevus subtype with characteristic clinical, dermoscopic, and histopathologic features. The features seen in BN can sometimes overlap with features seen in nodular/dermal melanoma and melanoma metastasis. In addition, variants of BN such as cellular blue nevi, deep penetrating blue nevi, and sclerosing blue nevi can be confused with melanoma.

Blue nevi

BN is a benign dermal melanocytic proliferation arising from neural-crest melanocytes. These melanocytes likely became arrested in the dermis in the course of migration from the neural crest to the skin during embryogenesis. Their prevalence is 1–2% in Caucasians and 3–5% in Asians. Typically, BN first appear in adolescence and young adulthood, but they can also arise in older individuals (2). Somatic mutations in *GNAQ* and *GNA11* have been identified in BN (24).

Clinically, a common BN presents as a solitary, small, well-defined, round- to oval-shaped, flat to slightly elevated papule with a predominant steel-blue color (spectrum gray-blue-black). They are most often located on the distal extensor aspects of limbs, followed by the face and scalp, and the sacral region. Other less common locations include genitalia, oral cavity, and lymph nodes (28). The histopathologic features seen in common BN consist of heavily pigmented bipolar spindle-shaped melanocytes oriented parallel to the epidermis and intermingled with bundles of collagen in the mid- to deep dermis with occasional extensions into the hypodermis (Figure 7d.1). Typically, there is a grenz zone devoid of nevomelanocytes at the dermo-epidermal junction.

When evaluating blue-colored lesions, clinical history remains of great importance. Blue lesions arising in childhood and with no history of change are highly suggestive of common BN. In contrast, a new and fast-growing blue lesion in adulthood, or in the context of a previous melanoma, should raise concern for the possibility of melanoma.

Dermoscopy

The most characteristic pattern of BN is the presence of homogeneous and structureless blue pigmentation. The pigment in BN is confluent throughout the lesion and fades toward the periphery (Figures 7d.2, 7d.3). Subtypes of BN may reveal a combination of two colors, including white-blue, steel-blue-gray, blue-brown, or blue-black. While multichromatic pigmentation can be seen in BN, they always include blue in the spectrum of colors being displayed (Figure 7d.4) (9). With the use of polarized light dermatoscopes, additional structures may be seen, including bluish globules/dots, shiny white lines, network-like structures, or peripheral out-of-focus streaks corresponding to pigmented projections of nevomelanocyte clusters or melanophages within the dermis. Lesions showing more criteria than the homogeneous structureless blue pigmentation should raise suspicion for melanoma, and in such lesions, the context and history will play a critical role in management decisions.

Special locations

- Face/scalp BN frequently display whitish scarlike areas, follicular white openings, and multichromatic pigmentation (Figure 7d.4) (9).
- Congenital BN located on palms/soles displaying a homogeneous blue pattern can be difficult to distinguish from acral melanoma (12).
- BN located in the nail matrix are rare and present as blue melanonychia (8, 15). There are no known morphologic criteria to distinguish subungual BN from subungual melanoma.

Blue nevi variants

The histopathologic variants of BN are defined primarily based on their cellularity and stromal fibrotic reaction. Clinically, BN variants may be difficult to differentiate from each other.

- **Agminated or plaque-type BN** present as clustered blue macules or papules arising in an anatomic area measuring less than 10 cm^2. Dermoscopically, multiple structureless confluent blue to gray-black-brown macules or papules are seen (Figure 7d.5). The skin surrounding BN may display a bluish-grayish discoloration or appear completely normal (4, 18).
- **Sclerotic BN** display whitish areas or even whitish scarlike structures corresponding to dermal fibrosis. When

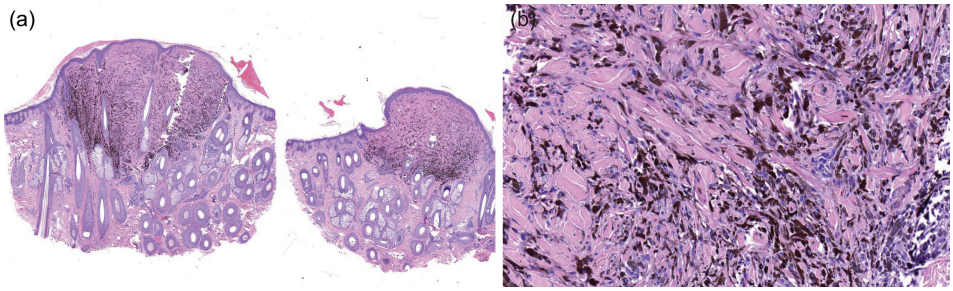

FIGURE 7D.1 Histopathological features of a common blue nevus: Dermal proliferation of heavily pigmented spindled cells with enriched fibroblast and collagen background.

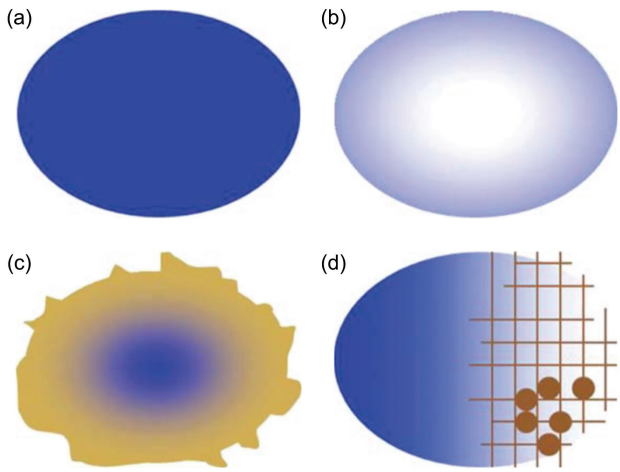

FIGURE 7D.2 Schematic representation of dermoscopic features usually seen in blue nevi (BN). (a) Homogeneous blue pattern, typically seen in BN. (b) Blue and white homogeneous pattern, usually found in the sclerotic-type BN. (c) Homogeneous blue pattern with homogeneous brown pigmentation at the periphery. (d) Combined nevus with homogeneous blue pattern (BN component) and pigment network and aggregated globules (compound nevus component).

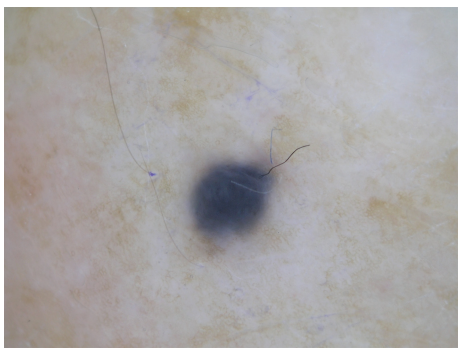

FIGURE 7D.3 Small papule on the forearm. Dermoscopy shows a structureless steel-bluish pigmentation with faded border (homogeneous blue pattern of common BN).

the scarlike area is located in the center, then BN can resemble dermatofibromas (9, 26). Histologically, the bipolar dendritic melanocytes are surrounded by prominent sclerotic stroma. In the rare cases of **hypomelanotic or amelanotic BN**, a whitish or gray-whitish structureless pattern with or without thin vessels is observed (17).

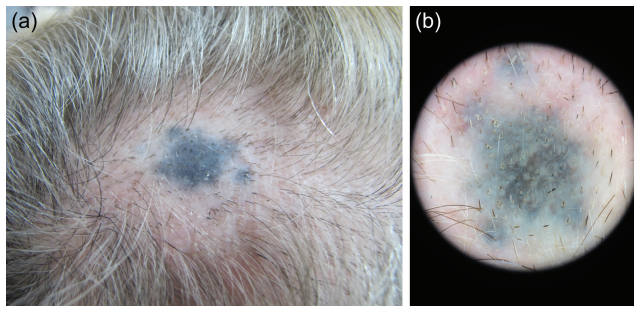

FIGURE 7D.4 Blue patch present since infancy on the scalp of a woman. On dermoscopy, a polychromatic structureless lesion with white-gray and blue-grey areas, follicular openings, and undefined borders was observed. Sclerotic BN.

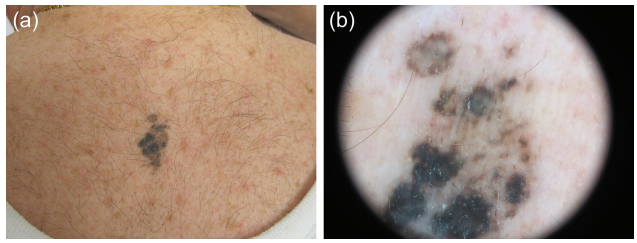

FIGURE 7D.5 Heterogeneous blue-black and brown agminated plaque on the back of a middle-aged male. Dermoscopy revealed a heterogeneous lesion with multifocal blue-black, brown, and whitish homogeneous structureless pigmentations. Histology confirmed a combined nevus (blue and compound melanocytic nevi).

- **Cellular BN** lesions can be larger than common BN, measuring between 1 and 3 cm, and are usually located on the trunk or buttocks (Figure 7d.6). Histologically, less elongated and slightly pigmented melanocytes with pale cytoplasm form nevomelanocytic nests in the deep dermis, and extension into subcutaneous tissue can also be observed (28).
- **Combined BN** consists of at least two different populations of nevomelanocytes. The most frequent combination is BN (dermal component) with a junctional nevus (at the dermo-epidermal junction) (1). Dermoscopically, a central blue-black blotch surrounded by a brown pigment network is frequently seen (Figures 7d.7, 7d.8). When BN is combined with a dermal or compound nevus, a hypopigmented pattern with brown and blue areas is evident (13). BN can also be found in association

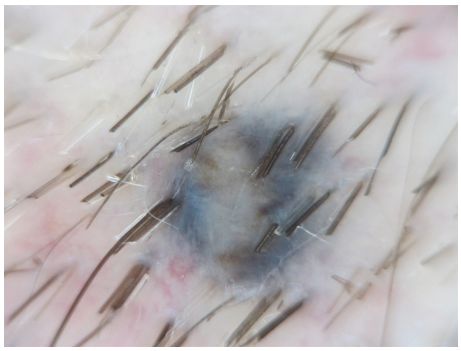

FIGURE 7D.6 Dermoscopy of a blue-white papule on the scalp of a 60-year-old male: Structureless blue pigmentation with white homogeneous center in a cellular BN.

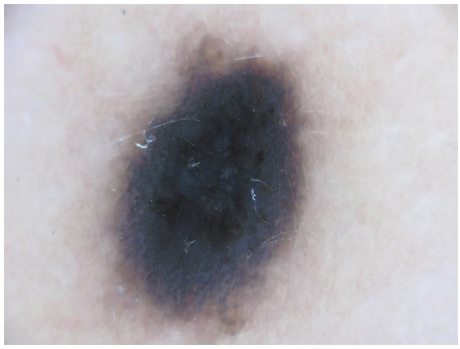

FIGURE 7D.7 Dermoscopy of a combined nevus; a Spitz/Reed nevus and BN on the arm of a young male: Blue-black pigmentation with peripheral faded projections and bluish globules.

with other proliferations such as smooth-muscle hamartomas or trichoepithelioma (23).

- **Epithelioid BN** is a term that describes both pigmented epithelioid melanocytic proliferations occurring in patients with Carney's complex, and BN with a high proportion of polygonal pigmented melanocytes in otherwise healthy individuals (14, 25). No specific dermoscopic patterns have been reported in this variant.
- **Compound BN** presents as a small solitary papule with symmetric black lamella with a bluish background at dermoscopy. Other less common features include dots, globules, or even a pigment network at the periphery (3, 10). This variant has heavily pigmented dendritic melanocytes located both at the dermo-epidermal junction and in the dermis.
- **Deep penetrating nevi** are considered by some to be a variant of BN. They represent a challenging clinical diagnosis due to their resemblance to melanoma. On dermoscopy, a polychromatic and heterogeneous pattern can be seen (Figure 7d.9) (5, 11, 22).
- **Malignant BN** is a term that includes both melanomas that histologically resemble BN and melanomas arising in pre-existing BN. They are most frequently located on the scalp and tend to grow rapidly and penetrate deeply. Malignant BN can display *GNA11* mutations and *BAP1* expression loss (7, 16).

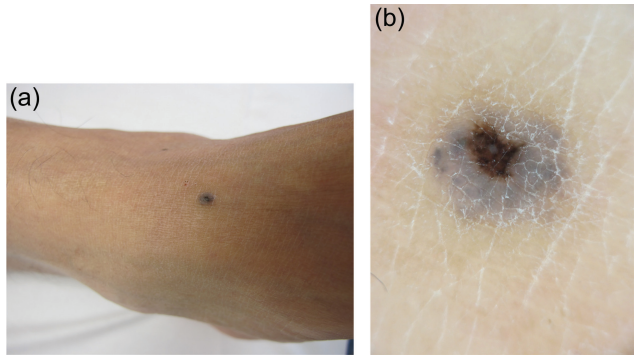

FIGURE 7D.8 Combined nevus; compound nevus with BN in a middle-aged woman. A gray-blue homogeneous pigmentation presented at the periphery and brown-black blotch with projections in the center.

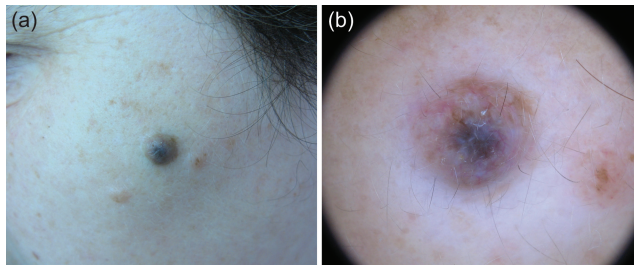

FIGURE 7D.9 Dermoscopy of a raised pigmented tumor on the cheek of a woman: Heterogeneous polychromic blue-brown and whitish pigmentation with some lineal vessels. Histopathological examination corresponded to a combined nevus (deep penetrating nevus with intradermal nevus).

Other diagnostic techniques

- In vivo reflectance confocal microscopy (RCM) improves the diagnostic accuracy of melanocytic tumors. However, since the maximum depth visualized with RCM is around 150 microns, it is not the best instrument to evaluate BN, given that the nevus cells in a BN are mainly located in the reticular dermis. In cases of BN where the melanocytic proliferation is located in the superficial dermis, nests of hyperrefractile dendritic cells surrounded by collagen fibers can be seen (20).
- High-resolution skin ultrasonography (US) has been shown to have a higher specificity and similar sensitivity to dermoscopy in differentiating BN from cutaneous metastasis of melanoma (21). BN are more frequently dish-shaped, homogeneous, hypoechoic lesions, located in the upper dermis.

Differential diagnosis of blue nevi

Congenital melanocytic nevi, malignant BN, nodular melanoma, melanoma metastasis, exogenous tattoos (i.e., radiotherapy tattoos), or pigmented spindle-cell nevi (Reed's nevi) can be indistinguishable from BN. However, a meticulous history and dermoscopic examination can usually identify additional features, providing clues to the diagnosis (Table 7d.1). The evolution or new appearance of a homogeneous blue lesion in a patient with a history of a previous invasive melanoma should

TABLE 7D.1: Differential Diagnosis of BN

Nodular melanoma	Usually displays other melanoma features: several colors (blue, black, white, brown), atypical vessels, milky-red areas, shiny white streaks.
Melanoma metastasis	Clinical history of previous invasive melanoma.
Pigmented Spitz/Reed nevi	Blue and black colors, starburst pattern, radial streaming, and/or black globules or network.
Nodular pigmented basal cell carcinoma	Blue color located only in ovoid nests/globules/dots, arborizing vessels, ulceration.
Kaposi sarcoma	Clinical presentation, blue-reddish coloration, the so-called "rainbow pattern."
Hemosiderotic dermatofibroma	Structureless bluish pigmentation, fine peripheral pigmented network, shiny white streaks in the center, peripheral vessels can be seen.
Pilomatrixoma	Irregular white areas, shiny white streaks, reddish homogeneous area, hairpin and irregular vessels.
Radiotherapy tattoo	Clinical history, typical morphology, and multiple locations on the field of irradiation.
Angiokeratoma	Displaying black lagoons with a lighter blue color or white interlacing areas separating them.

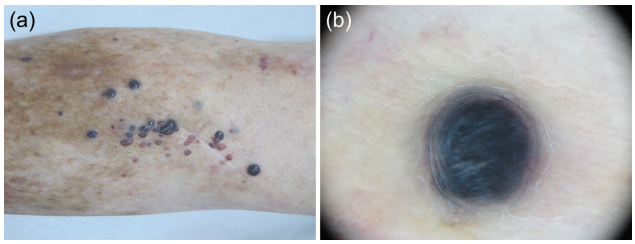

FIGURE 7D.10 Multiple blue-black and red papules on the site of a previously excised melanoma. Dermoscopically, a blue-black pigmentation with white areas can be seen, as well as small irregular vessels at the periphery.

raise concern for a melanoma metastasis (BN-like melanoma metastasis, Figure 7d.10) (6). In melanoma, a multichromatic pattern is more frequent; blue pigmentation is commonly patchy and is not homogeneously located throughout the lesion (19). In addition, the combination of dots/globules and pigment networks or dots/globules and whitish areas, even if there is a steel-blue background, is suggestive of melanoma (9).

Other nonmelanocytic tumors, such as basal cell carcinomas, hemangiomas, angiokeratomas, and up to 20% of pilomatrixomas, may present with confluent bluish pigmentation, but other clinical and dermoscopic clues are often evident to assist in making the correct diagnosis (26, 27).

References

1. Baran JL, Duncan LM. Combined melanocytic nevi: histologic variants and melanoma mimics." *Am J Surg Pathol.* 2011;35(10):1540–48.
2. Cabral ES, Chen FW, Egbert BM, Swetter SM. Acquired blue nevi in older individuals: retrospective case series from a veterans affairs population, 1991 to 2013. *JAMA Dermatol.* 2014;150(8):873.
3. Carrera C, Ferrer B, Mascaro JM, Palou J. Compound blue naevus: a potential simulator of melanoma. *Br J Dermatol.* 2006;155(1):207–8.
4. Collgros H, Vicente A, Díaz AM, Rodríguez-Carunchio L, Malvehy J, Puig S. Agminated cellular blue naevi of the penis: dermoscopic, confocal and histopathological correlation of two cases. *Clin Exp Dermatol.* 2016;41(5):490–94.
5. Cooper PH. Deep penetrating (plexiform spindle cell) nevus. A frequent participant in combined nevus." *J Cutan Pathol.* 1992;19(3):172–80.
6. Costa J, Ortiz-Ibañez K, Salerni G, Borges V, Carrera C, Puig S, Malvehy J. Dermoscopic patterns of melanoma metastases: interobserver consistency and accuracy for metastasis recognition. *Br J Dermatol.* 2013;169(1):91–9.
7. Costa S, Byrne M, Pissaloux D, et al. Melanomas associated with blue nevi or mimicking cellular blue nevi: clinical, pathologic, and molecular study of 11 cases displaying a high frequency of GNA11 mutations, BAP1 expression loss, and a predilection for the scalp. *Am J Surg Pathol.* 2016;40(3):368–77.
8. Dalle S, Ronger-Savle S, Cicale L, Balme B, Thomas L. A blue-gray subungual discoloration: quiz case. *Arch Dermatol.* 2007;143(7):937–42.
9. Di Cesare A, Sera F, Gulia A, Coletti G, Micantonio T, Fargnoli MC, Peris K. The spectrum of dermatoscopic patterns in Blue Nevi. *J Am Acad Dermatol.* 2012;67(2):199–205.
10. Ferrara G, Argenziano G, Zgavec B, Bartenjev I, Staibano S, De Rosa G, Peter Soyer H. 'Compound blue nevus': a reappraisal of 'superficial blue naevus with prominent intraepidermal dendritic melanocytes' with emphasis on dermoscopic and histopathologic features. *J Am Acad Dermatol.* 2002;46(1):85–89.
11. Ferrara G, Peter Soyer H, Malvehy J, Piccolo D, Puig S, Sopena J, Zalaudek I, Argenziano G. The many faces of blue nevus: a clinicopathologic study. *J Cutan Pathol.* 2007;34(7):543–51.
12. Garrido-Ríos AA, Carrera C, Puig S, Aguilera P, Salerni G, Malvehy J. Homogeneous blue pattern in an acral congenital melanocytic nevus. *Dermatology.* 2008;217(4):315–17.
13. Giorgi V de, Massi D, Salvini C, Trez E, Mannone F, Carli P. Dermoscopic features of combined melanocytic nevi. *J Cutan Pathol.* 2004; 31(9):600–604.
14. Groben PA, Harvell JD, White WL. Epithelioid blue nevus: neoplasm Sui Generis or variation on a theme? *Am J Dermatopathol.* 2000;22(6):473–88.
15. Lee Mh, Lee EJ, Shin MK. A subungual blue naevus showing expansile growth. *Acta Dermato Venereol.* 2012;92(2):162–63.
16. Loghavi S, Curry JL, Torres-Cabala CA, Ivan D, Patel KP, Mehrotra M, Bassett R, Prieto VG, Tetzlaff MT. Melanoma arising in association with blue nevus: a clinical and pathologic study of 24 cases and comprehensive review of the literature. *Modern Pathol.* 2014;27(11):1468–78.
17. Ma C, Chambers CJ, Kiuru M, Marsee DK, Silverstein M. Amelanotic blue nevus. *JAAD Case Rep.* 2017;3(2):93–4.
18. Pizzichetta MA. Clinical and dermoscopic features of agminated blue nevus. *Arch Dermatol.* 2007;143(9):1209.
19. Popadić M, Sinz C, Kittler H. The significance of blue color in dermatoscopy: blue color in dermatoscopy. *J Dtsch Dermatol Ges.* 2017;15(3): 302–7.
20. Puig S, Di Giacomo TB, Serra D, Cabrini F, Alos L, Palou J, Malvehy J. Reflectance confocal microscopy of blue nevus. *Eur J Dermatol.* 2012;22(4):552–53.
21. Samimi M, Perrinaud A, Naouri M, Maruani A, Perrodeau E, Vaillant L, Machet L. High-resolution ultrasonography assists the differential diagnosis of blue naevi and cutaneous metastases of melanoma: ultrasonography for differential diagnosis of naevi and melanoma metastases. *Br J Dermatol.* 2010;163(3):550–56.
22. Strazzula L, Senna MM, Yasuda M, Belazarian L. The deep penetrating nevus. *J Am Acad Dermatol.* 2014;71(6):1234–40.

23. Tzu J, Goldman C, Perry AE, and Meehan SA. Combined blue nevus-smooth muscle hamartoma: a series of 12 cases. *J Cutan Pathol*. 2013;40(10):879–83.
24. Van Raamsdonk CD, Griewank KG, Crosby MB, Garrido MC, Vemula S, Wiesner T, Obenauf AC, et al. Mutations in *GNA11* in uveal melanoma. *N Engl J Med*. 2010;363(23):2191–99.
25. Yazdan P, Haghighat Z, Guitart J, Gerami P. Epithelioid and fusiform blue nevus of chronically sun-damaged skin, an entity distinct from the epithelioid blue nevus of the carney complex. *Am J Surg Pathol*. 2013;37(1):81–8.
26. Zaballos P, Llambrich Á, Ara M, Olazarán Z, Malvehy J, Puig S. 2006. Dermoscopic findings of haemosiderotic and aneurysmal dermatofibroma: report of six patients. *Br J Dermatol*. 154(2):244–50.
27. Zaballos P, Llambrich Á, Puig S, Malvehy J. Dermoscopic findings of pilomatricomas. *Dermatology*. 2008;217(3):225–30.
28. Zembowicz A. Blue nevi and related tumors. *Clin Lab Med*. 2017;37(3):401–15.

7E BENIGN MELANOCYTIC LESIONS: SPITZ AND REED NEVI

Chryssoula Papageorgiou and Aimilios Lallas

Contents

Dermoscopy of Spitz/Reed nevi . . . 169
Nonpigmented Spitz nevus . . . 169
Pigmented Spitz nevus . . . 169
Reed nevus . . . 170
Evolution of Spitz nevi . . . 171
Dermoscopy of spitzoid melanoma . . . 171
Atypical Spitz tumors (ASTs) . . . 171
Dermoscopy of AST . . . 173
Management of spitzoid-looking lesions . . . 173
References . . . 174

In 1948, Sophie Spitz described the features of a distinct type of melanocytic tumor that now bears her name—Spitz nevus. She noted that this neoplasm displays epithelioid and spindle cells and is most often found in childhood.[1] A few years later, Richard Reed described a pigmented variant of Spitz nevus, namely, the pigmented spindle cell nevus (spindle cell and/or epithelioid cell nevus).[2] Decades after being described, Spitz and Reed nevi remain controversial in terms of their classification and biologic potential. Although Reed nevus was described as a pigmented variant of Spitz nevus, many researchers are of the opinion that Spitz and Reed nevi are distinct entities.[3–7] In fact, certain differences in age and anatomic site predilection do exist between Spitz and Reed nevi. However, based on cellular morphology, these two nevi appear to belong to the same spectrum.

To date, the biological behavior, natural evolution, and malignant potential of Spitz/Reed nevi have not been fully elucidated. To complicate matters, melanomas, at times, can resemble Spitz/Reed nevi clinically, dermoscopically, and even histopathologically. The scenario becomes even more complicated by the fact that some spitzoid tumors cannot be confidently classified as benign (nevi) or malignant (melanomas) based on histopathology findings. While differences in immunohistochemistry and molecular markers have been observed between Spitz/Reed nevi and melanoma, to date, no single test or combination of tests can reliably differentiate Spitz/Reed nevi from melanoma. The ambiguous "Spitzoid" tumors are currently classified under several terms, including "atypical Spitz tumors" and "melanocytic tumors of unknown malignant potential."

Dermoscopy of Spitz and Reed nevi reveals a few unique and reproducible findings. These dermoscopic findings allowed the clinical recognition of Spitz and Reed nevi, many of which would not have been diagnosed otherwise. While the existing controversies regarding the biologic nature of spitzoid tumors have not been solved, dermoscopy has provided insights that have influenced the management of these nevi.

Dermoscopy of Spitz/Reed nevi

Nonpigmented Spitz nevus

"Classic" nonpigmented Spitz nevi are dermoscopically typified by a pattern of multiple, regularly distributed, dotted vessels. In lesions that are more raised or nodular, the vessels tend to be larger than dots and can appear as globular or glomerular vessels. In addition, comma, hairpin, serpentine, and corkscrew vessels can also be seen in nodular Spitz nevi. Besides vessels, other features commonly found in many Spitz nevi include the so-called negative network (also known as inverse network) and shiny white lines seen with polarized light. These shiny white lines can crisscross, forming a white network (also known as reticular depigmentation) (Figure 7e.1). In nonpigmented Spitz nevi, the shiny white lines of the network appear to surround vessels.

The aforementioned description of the typical dermoscopic pattern of nonpigmented Spitz nevi includes the symmetric distribution of the vascular structures as well as the symmetric arrangement of the shiny white lines. Nonpigmented Spitz nevi lacking a symmetric distribution of structures also exist, including some peculiar varieties such as angiomatous or desmoplastic Spitz nevi. However, it is important to underscore that a Spitz nevus lacking dermoscopic symmetry cannot be differentiated from melanoma. Therefore, it is strongly advised that any spitzoid-looking lesion that displays an asymmetric distribution of structures be biopsied and examined histopathologically.[8]

Pigmented Spitz nevus

Pigmented Spitz nevi are dermoscopically typified by the presence of globules. These globules often vary in their size and color, ranging from different shades of brown to gray and black color. These globules can appear elongated and curvilinear and when aggregated together, create the so-called negative network. In addition, some of these pigmented Spitz nevi can also manifest shiny white lines (Figure 7e.2). The co-existence of negative network and shiny white lines is very helpful in the recognition of pigmented Spitz nevi. The presence of these two dermoscopic features is not seen in globular pattern nevi of the classic dermal subtype. In addition, classic dermal globular nevi, unlike Spitz nevi, tend not to display globules of varying size and color. In fact, and in contrast to Spitz nevi, the globules in classic dermal nevi tend to be brown and quite monomorphous.

It has been suggested by some that the globular pattern might represent the initial stage of evolution of a pigmented Spitz nevus. As the nevus evolves, it transforms from a globular to a starburst pattern, and when it eventually enters senescence, it manifests

DOI: 10.1201/9780429487873-21

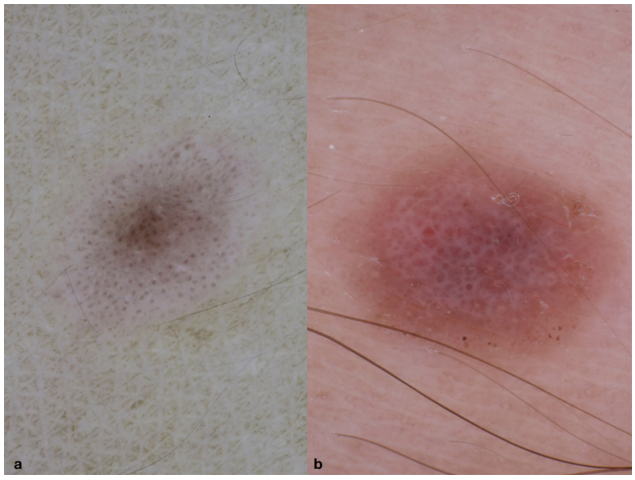

FIGURE 7E.1 Dermoscopic images of classic nonpigmented Spitz nevi exhibiting (a) multiple dotted vessels in a symmetric distribution and (b) multiple dotted, glomerular, and a few comma vessels surrounded by white network symmetrically arranged.

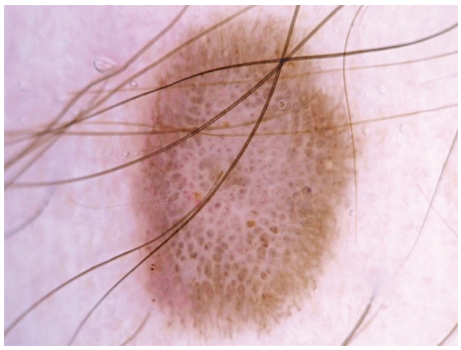

FIGURE 7E.2 Dermoscopic image of a pigmented Spitz nevus typified by the globular pattern and reticular depigmentation.

a more homogeneous pattern with a central blue-white veil. However, others suggest that pigmented Spitz nevi are typified by a globular pattern and Reed nevi by a starburst pattern. [9–11]

Reed nevus

Reed nevus is dermoscopically typified by the so-called "starburst" pattern. The term derives from the fact that the dermoscopic structures are arranged in a way that resembles an exploding star. Typically, it consists of a central area of dark brown/black/blue pigmentation, often homogeneous, combined with multiple pigmented streaks (streaks include both radial streaming and pseudopods) that arise from the center and radially expand towards the periphery of the lesion (Figures 7e.3 and 7e.4). A starburst pattern always presupposes symmetry in terms of distribution of colors and structures. Histopathologically, the streaks/pseudopods correspond to confluent, elongated nests of melanocytes located at the dermoepidermal junction. Reed nevi might also display other dermoscopic patterns, such as a reticular and a homogeneous pattern. Homogeneous is defined as a structureless pattern of diffuse, brown, grey-blue to grey-black pigmentation in the absence of other discernable structures. The reticular pattern (also known as superficial black network) consists of a prominent



FIGURE 7E.3 Dermoscopic image of a Reed nevus displaying the starburst pattern consisting of a central area of dark brown/black/blue pigmentation combined with multiple pigmented streaks.



FIGURE 7E.4 Dermoscopic image of a Reed nevus displaying the starburst pattern consisting of a central area of dark brown/black/blue pigmentation combined with pseudopods in a radial arrangement at the periphery.

dark pigment network with an underlying bluish haze covering most parts of the lesion (Figure 7e.5).[7] Longitudinal follow-up of a few isolated cases of Reed nevi has demonstrated that the starburst pattern corresponds to its radial growth phase. Once a Reed's nevus enters senescence, it usually manifests a homogeneous pattern but at times, can also display a reticular pattern as described earlier. At this stage, their recognition is not easy, as several other types of nevi may exhibit similar patterns.

Some Spitz/Reed nevi present with a multicomponent pattern, which is composed of more than one of the aforementioned patterns (Figure 7e.6). However, a pigmented lesion displaying a multicomponent pattern should always be considered suspicious for melanoma, and a biopsy should be performed on all such lesions.

Summarizing the three main dermoscopic patterns displayed by Spitz/Reed nevi:

1. The starburst pattern, exemplified by the Reed's nevus
2. The globular pattern with reticular depigmentation (negative network with shiny white lines), exemplified by the pigmented Spitz nevus
3. The pattern consisting of regularly distributed dotted vessels combined with shiny white lines (white network), exemplified by the classic nonpigmented Spitz nevus



FIGURE 7E.5 (a) Homogeneous and (b) reticular pattern in Reed nevi.

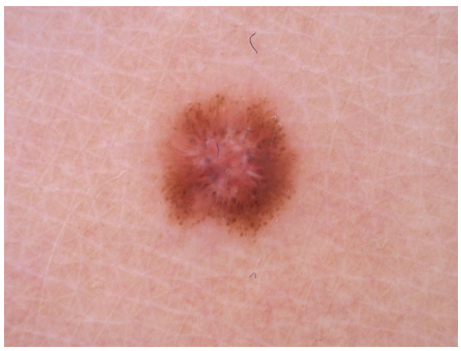

FIGURE 7E.6 Dermoscopic image of a Spitz nevus displaying a multicomponent pattern consisting of irregularly distributed pigmented dots and globules, central white shiny structures, and pseudopods at the periphery.

The International Dermoscopy Society published a systematic review that sought to examine the frequency of different dermoscopic morphologies encountered in Spitz nevi.[12] The systematic analysis included 15 studies of dermoscopic findings of Spitz nevi and analyzed 896 lesions. It was found that the starburst pattern was the commonest dermoscopic pattern in Spitz nevi, being present in 51% of the cases. Dotted vessels, the globular and the multicomponent/atypical patterns were noted in 19%, 17%, and 9% of nevi, respectively. In another study by de Mastier et al.,[13] the authors aimed to evaluate the clinical and dermoscopic differences of Spitz nevi according to age and anatomical site. They found that in younger patients (≤12 years), Spitz nevi were more likely to exhibit a globular and nonpigmented homogeneous pattern. In addition, starburst and reticular patterns were more commonly observed on the anterior trunk and acral sites.

Evolution of Spitz nevi

The ease of image acquisition and the acceptance of sequential digital monitoring of nevi have allowed us to appreciate the natural evolution of a few Spitz/Reed nevi. Some case reports and small case series have longitudinally followed Spitz/Reed nevi. As already stated, it appears that the dermoscopic pattern manifest by a Spitz/Reed nevus is dependent upon the evolutionary stage it is in. Although the starburst pattern is considered the exemplar dermoscopic pattern of Spitz/Reed nevi, it probably simply reflects an easy-to-identify stage in the evolution of this nevus. A few reports provide insights to suggest that during early nevogenesis, Spitz/Reed nevi are dermoscopically exemplified by the presence of a dense globular pattern. As the nevus evolves, it gradually transforms from a globular to a starburst pattern. Then, when it enters senescence, the starburst pattern is replaced by a homogeneous or reticular pattern (Figure 7e.7). Finally, Spitz/Reed nevi will either retain the reticular or homogeneous pattern or undergo spontaneous involution (partial or complete) over a variable period of months to years.[9]

Dermoscopy of spitzoid melanoma

Due to morphological overlap, "spitzoid" is a term that has been adopted to describe melanomas with similar clinical and dermoscopic characteristics to those associated with Spitz nevi. Spitzoid melanomas often exhibit dermoscopic features that are also seen in Spitz nevi, including streaks, globules, dotted vessels, negative network, and shiny white lines (Figure 7e.8). However, spitzoid melanomas tend to display multiple colors and structures, usually distributed in a disorganized manner within the lesion. In contrast, Spitz nevi tend to maintain morphologic symmetry. But, it needs to be underscored that exceptions do exist. There are cases of melanomas that perfectly mimic symmetric Spitz/Reed nevi, rendering their differentiation from Spitz/Reed nevi impossible (Figures 7e.9-7e.11). In fact, it has been shown that approximately 13% of dermoscopically symmetric spitzoid lesions in patients over 12 years of age are in fact melanomas.[14] While some melanomas can look like exemplar Spitz nevi, there are also some Spitz nevi that look like exemplar melanomas. These cases of Spitz nevi are dermoscopically characterized by an atypical/multicomponent pattern, which is most often associated with melanoma (Figure 7e.12). It needs to be highlighted here that dermoscopic atypia of Spitz nevi does not necessarily correspond with histologic atypia.[6]

Atypical Spitz tumors (ASTs)

Despite the morphologic overlap, most spitzoid melanocytic lesions can reliably be diagnosed as nevus or melanoma histopathologically. However, the true biologic potential of a subset of lesions remains impossible to discern. Several terms have been adopted to describe these equivocal cases, including Spitz nevus with atypia and metastasis, atypical Spitz nevus, ASTs, metastasizing Spitz tumor, melanocytic tumor of unknown malignant potential, and melanocytoma.[15–20] It remains unknown whether these lesions are only morphologically "intermediate" or if they are also biologically "intermediate" in terms of their behavior or malignant potential. Three theories prevail regarding the biology of these lesions. One theory is that these tumors are in fact either benign or malignant (nevus or melanoma, respectively), and the inability of classification is only a matter of human diagnostic uncertainty.[21] The second theory is that there exists a wide biologic spectrum, ranging from benign to malignant, with lesions of intermediate biologic potential present in between. According to this theory, one could envision a classification such as the following: Typical Spitz nevus (benign), atypical Spitz nevus

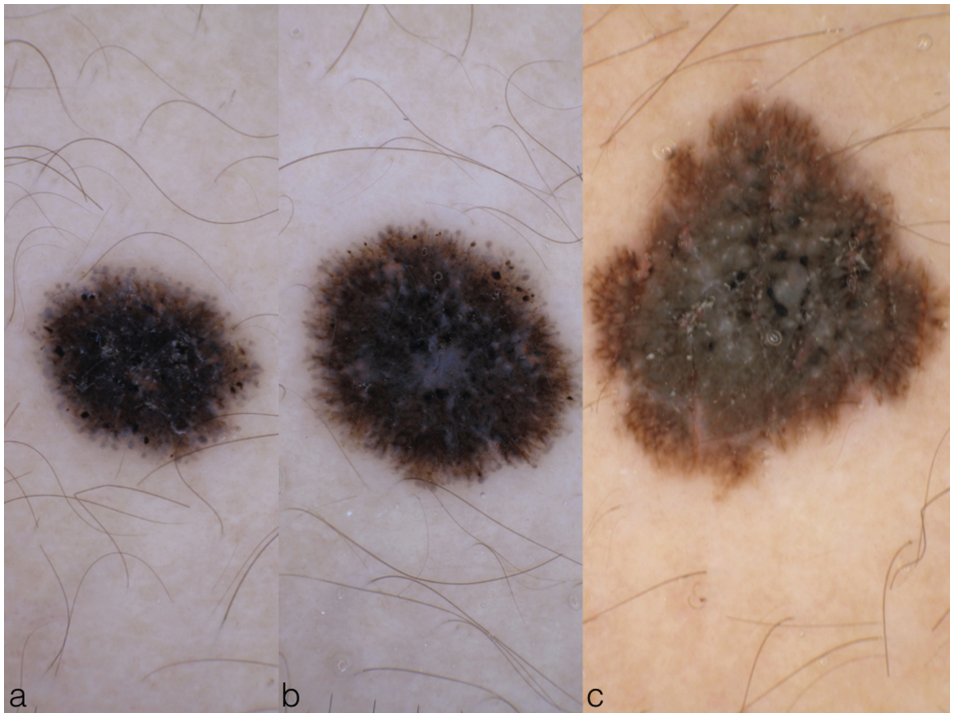

FIGURE 7E.7 Sequential dermoscopic images of a Reed nevus demonstrating its evolution. At the initial phase, it exhibits a starburst pattern (a) and (b), which is gradually turned into a homogeneous-reticular (c) pattern, indicating that the lesion has been stabilized.

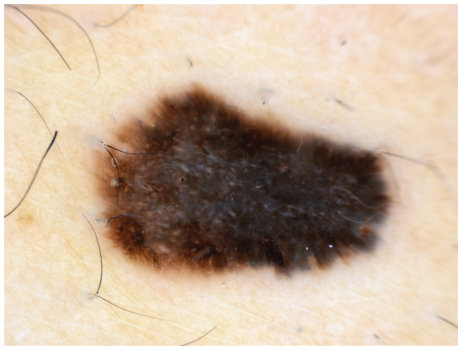

FIGURE 7E.8 Spitzoid melanoma dermoscopically displaying a central area of dark brown/blue pigmentation, atypical network, white shiny streaks, and peripheral streaks.



FIGURE 7E.9 Dermoscopic image of a spitzoid melanoma in a 34-year-old woman. The lesion exhibits a dark brown-black central area combined with peripheral streaks, perfectly mimicking the starburst pattern of a Reed nevus.



FIGURE 7E.10 Dermoscopic image of a spitzoid melanoma with a perfectly symmetric starburst pattern.

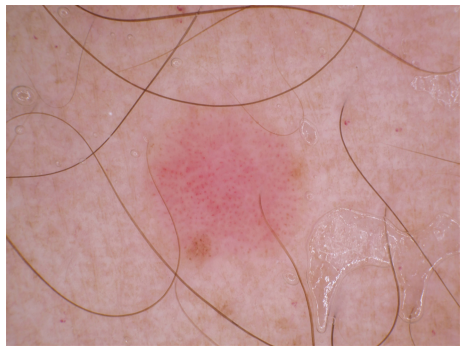

FIGURE 7E.11 Dermoscopic image of a spitzoid melanoma with a perfectly symmetric pattern of dotted vessels.

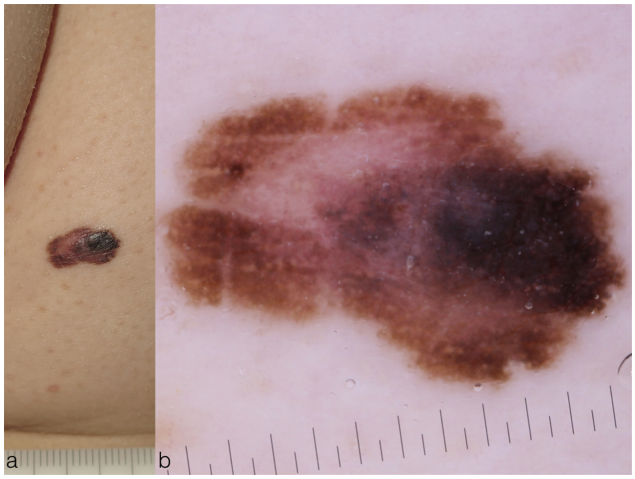

FIGURE 7E.12 (a) Clinical image of a Spitz nevus in a 4-year-old girl. (b) Dermoscopy reveals a multicomponent pattern and asymmetric distribution of structures and colors, typically suggestive of melanoma.

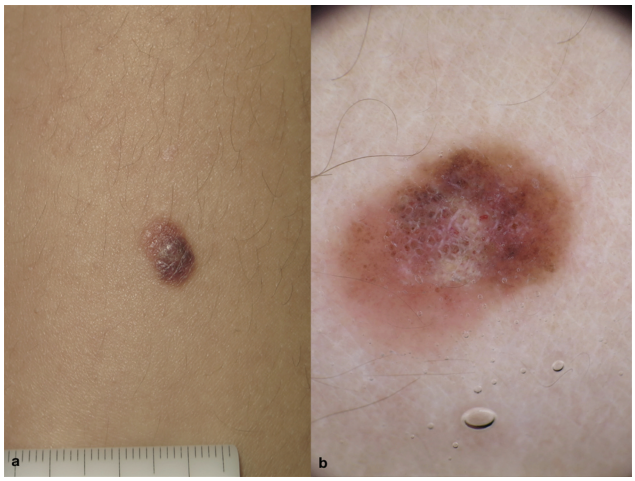

FIGURE 7E.13 (a) Clinical and (b) dermoscopic image of an atypical Spitz tumor. Dermoscopy reveals a multicomponent pattern consisting of brown globules, reticular depigmentation, a few hairpin vessels (in the more elevated part of the lesion). and white shiny streaks.

(benign, with atypical histologic features), AST (potential low-grade melanoma), spitzoid melanoma (malignant, with spitzoid features).[22–24] Finally, a third theory is that ASTs are a heterogeneous group of melanocytic tumors, some of low and others of high risk for malignant degeneration.[25–29]

Collectively, ASTs are melanocytic proliferations with intermediate histopathologic features between Spitz nevi and spitzoid melanoma, and their malignant potential is uncertain.[15–17, 21, 30–34]

Dermoscopy of AST

In a multicentric study that examined the clinical and dermoscopic features of ASTs and included 55 ASTs and 110 Spitz nevi,[35] the authors found that the commonest pattern of AST was the multicomponent, being present in 44% of cases,

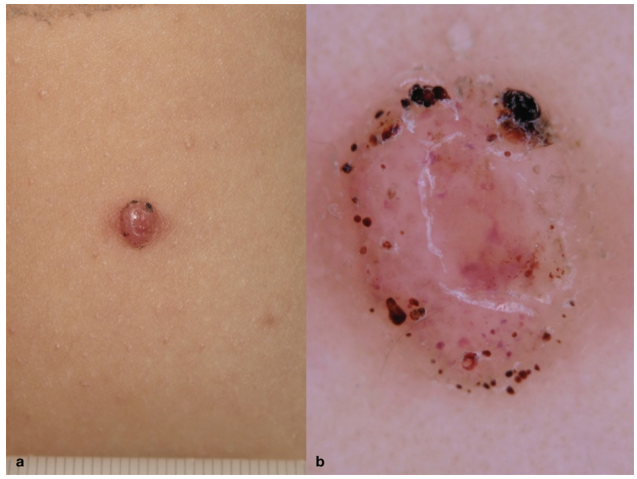

FIGURE 7E.14 A clinically (a) and dermoscopically (b) amelanotic nodule that proved to be AST after histologic examination. Dermoscopy reveals a nonpigmented typical spitzoid pattern mimicking a classic Spitz nevus.

followed by a nonspecific pattern (20%). It should be underscored that both of these patterns are generally suggestive of melanoma (Figure 7e.13). Interestingly, 20% of ASTs mimic classic Spitz nevi by displaying a nonpigmented typical spitzoid pattern, namely, regularly distributed dotted vessels with or without reticular depigmentation (Figure 7e.14). Based on these results, a nonpigmented lesion manifesting a typical spitzoid pattern might be a Spitz nevus or AST, and dermoscopy seems insufficient to discriminate between the two entities.

Management of spitzoid-looking lesions

In everyday clinical practice, management decisions aim at eliminating the risk of missing a melanoma while at the same time, minimizing the removal of benign lesions. With these goals in mind, the selection of the optimal management approach for spitzoid-appearing lesions still remains challenging. However, two important parameters should be taken into account in this decision-making process. First, benign and malignant spitzoid tumors share common clinical and dermoscopic morphological characteristics. Although Spitz nevi more commonly display a symmetric/organized pattern, and spitzoid melanomas display an asymmetric/disorganized pattern, some Spitz nevi can present with an asymmetric pattern, mimicking the morphology of spitzoid melanoma, and inversely, spitzoid melanomas can present with morphological characteristics of Spitz nevi (Figures 7e.8 and 7e.9). This means that the clinical and dermoscopic morphology is not sufficient to differentiate reliably between Spitz/Reed nevi and spitzoid melanoma. Second, there is a significant difference in the age predilection of nevi and melanoma. Most Spitz nevi develop in children, and they develop extremely rarely after the fourth decade of life. In contrast, melanoma is exceedingly rare before puberty.[36–39] Therefore, the age at which a spitzoid-looking lesion appears provides information regarding the pretest probability of its being benign or malignant, and this does ultimately factor into the diagnostic thoughts and the management decisions.[14, 40]

Based on these considerations, the current accepted recommendations propose that the management of spitzoid-looking

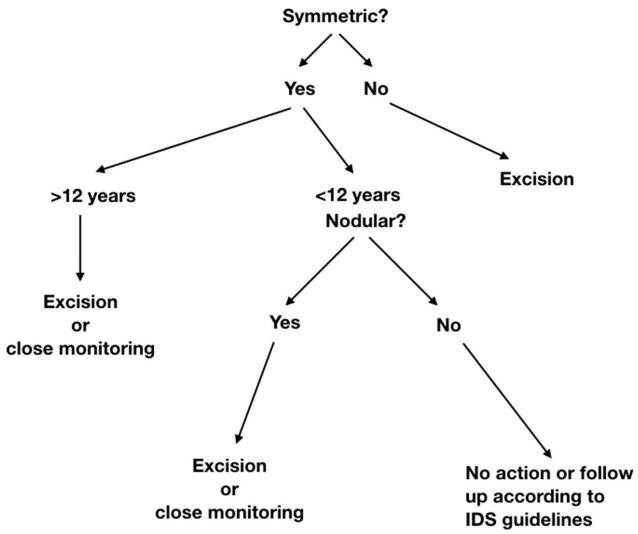

FIGURE 7E.15 Algorithm for management of spitzoid-looking lesions.

lesions should take into consideration three key factors: Assessment of the overall dermoscopic symmetry, consideration of the age of the patient, and evaluation of the clinical morphology (flat/elevated or nodular) (Figure 7e.15).

1. Assessment of dermoscopic symmetry: The general recommendation is that any dermoscopically asymmetric or disorganized lesion with spitzoid features, such as streaks, dotted vessels, or negative network, be excised to rule out melanoma. Dermoscopically symmetric/organized spitzoid-looking lesions should enter the second step of the evaluation process.

2. Consideration of the age of the patient: Based on data showing that a considerable proportion of symmetric spitzoid-appearing lesions developing after the age of 12 years prove to be melanomas, the recommendation is that this age should be considered as a threshold in terms of management. Any symmetric/organized spitzoid-looking lesion developing in individuals older than 12 years should be either excised or closely monitored. Symmetric spitzoid-looking lesions developing in children younger than 12 years can enter the third and last step.

3. Evaluation of the clinical morphology (flat/elevated vs. nodular): Symmetric nodular lesions with spitzoid characteristics in children require excision or close monitoring (every 15 days) in order to rule out nodular melanoma. If follow-up is selected, asymmetric growth of the lesion should warrant excision. If the lesion remains symmetric, the intervals of the visits could be prolonged to 1 and later, to 2 months. Monitoring termination is indicated when stabilization (no change for at least 6 months) or involution until complete disappearance of the lesion is observed. In contrast, flat symmetric spitzoid-looking lesions in children can be monitored until stabilization. The follow-up intervals for flat lesions are longer (usually 3 months) and can be further prolonged if the lesion remains symmetric. Monitoring can be terminated after stabilization, defined by the absence of dermoscopically detectable changes between two sequential visits with a 6-month interval. However, clinicians should keep in mind that monitoring Spitz/Reed nevi in children has its limitations. A proportion of Spitz/Reed nevi will not follow a symmetric growth pattern, and monitoring their evolution will ultimately lead to excisions. A recent study found that approximately 20% of symmetric Spitz/Reed nevi in children were ultimately excised because of asymmetric changes noted during follow-up. It is interesting to note that none of these excised lesions proved to be AST or melanoma.[41] Based on this data, some have made the argument that if the clinical and dermoscopic diagnosis of a flat, pigmented, dermoscopically symmetric Spitz/Reed nevus is made, it may be better to ignore the lesion than to subject it to monitoring in prepubertal patients (Figure 7e.15). Others have made the argument, based on the observed growth dynamics of some Spitz/Reed nevi, that if you detect a Spitz/Reed nevus while the nevus is small enough to permit its complete removal via simple excision, then it would be best to remove it at that time. This is based on the premise that the resultant small scar would be preferable to waiting until the lesion becomes larger before being excised. Naturally, this logic holds true only for those lesions that would ultimately become significantly larger and change in an asymmetric manner. However, currently, there is no way to predict which Spitz/Reed nevi will grow significantly larger or grow in an asymmetric manner. Thus, despite all we have learnt about Spitz/Reed nevi, the best management approach for these lesions still needs to be elucidated.

References

1. Spitz S. Melanomas of childhood. *Am J Pathol.* 1948;24(3):591–609.
2. Reed RJ, Ichinose H, Clark WH Jr, Mihm MC Jr. Common and uncommon melanocytic nevi and borderline melanomas. *Semin Oncol.* 1975;2(2):119–47.
3. Choi JH, Sung KJ, Koh JK. Pigmented epithelioid cell nevus: a variant of Spitz nevus? *J Am Acad Dermatol.* 1993;28(3):497–8.
4. Paniago-Pereira C, Maize JC, Ackerman AB. Nevus of large spindle and/or epithelioid cells (Spitz's nevus). *Arch Dermatol.* 1978;114(12):1811–23.
5. Requena C, Requena L, Kutzner H, Sánchez Yus E. Spitz nevus: a clinicopathological study of 349 cases. *Am J Dermatopathol.* 2009;31(2):107–16.
6. Ferrara G, Argenziano G, Soyer HP, et al. The spectrum of Spitz nevi: a clinicopathologic study of 83 cases. *Arch Dermatol.* 2005;141(11):1381–7.
7. Argenziano G, Soyer HP, Ferrara G, et al. Superficial black network: an additional dermoscopic clue for the diagnosis of pigmented spindle and/or epithelioid cell nevus. *Dermatology.* 2001;203(4):333–5.
8. Pizzichetta MA, Talamini R, Marghoob AA, et al. Negative pigment network: an additional dermoscopic feature for the diagnosis of melanoma. *J Am Acad Dermatol.* 2013;68(4):552–9.
9. Nino M, Brunetti B, Delfino S, Brunetti B, Panariello L, Russo D. Spitz nevus: follow-up study of 8 cases of childhood starburst type and proposal for management. *Dermatology.* 2009;218(1):48–51.
10. Piccolo D, Ferrari A, Peris K. Sequential dermoscopic evolution of pigmented Spitz nevus in childhood. *J Am Acad Dermatol.* 2003;49(3):556–8.
11. Pizzichetta MA, Argenziano G, Grandi G, de Giacomi C, Trevisan G, Soyer HP. Morphologic changes of a pigmented Spitz nevus assessed by dermoscopy. *J Am Acad Dermatol.* 2002;47(1):137–9.

12. Lallas A, Apalla Z, Ioannides D, et al. Update on dermoscopy of Spitz/Reed naevi and management guidelines by the international dermoscopy society. *Br J Dermatol.* 2017;177(3):645–55.
13. de Mestier Y, Moscarella E, Marchetti Cautela J, et al. Clinicodermoscopic features of Spitz naevi by age and anatomical site: a study of 378 Spitz naevi. *Br J Dermatol.* 2017;177(4): e152–e153.
14. Lallas A, Moscarella E, Longo C, et al. Likelihood of finding melanoma when removing a Spitzoid-looking lesion in patients aged 12 years or older. *J Am Acad Dermatol.* 2015;72(1):47–53.
15. Smith KJ, Barrett TL, Skelton HG 3rd, Lupton GP, Graham JH. Spindle cell and epithelioid cell nevi with atypia and metastasis (malignant Spitz nevus). *Am J Surg Pathol.* 1989;13(11):931–9.
16. Barnhill RL, Flotte TJ, Fleischli M, Perez-Atayde A. Cutaneous melanoma and atypical Spitz tumors in childhood. *Cancer* 1995; 76:1833–45.
17. Barnhill RL, Argenyi ZB, From L, et al. Atypical Spitz nevi/tumors: lack of consensus for diagnosis, discrimination from melanoma, and prediction of outcome. *Hum Pathol* 1999; 30:513–20.
18. Elder DE, Xu X. The approach to the patient with a difficult melanocytic lesion. *Pathology* 2004; 36:428–34.
19. Cerroni L, Barnhill R, Elder D, et al. Melanocytic tumors of uncertain malignant potential: results of a tutorial held at the XXIX symposium of the international society of dermatopathology in Graz, October 2008. *Am J Surg Pathol* 2010; 34:314–26.
20. Zembowicz A, Scolyer RA. Nevus/melanocytoma/melanoma: an emerging paradigm for classification of melanocytic neoplasms? *Arch Pathol Lab Med.* 2011;135(3):300–6.
21. Mones JM, Ackerman AB. "Atypical" Spitz's nevus, "malignant" Spitz's nevus, and "metastasizing" Spitz's nevus: a critique in historical perspective of three concepts flawed fatally. *Am J Dermatopathol.* 2004;26(4):310–33.
22. Ferrara G, Gianotti R, Cavicchini S, Salviato T, Zalaudek I, Argenziano G. Spitz nevus, Spitz tumor, and Spitzoid melanoma: a comprehensive clinicopathologic overview. *Dermatol Clin.* 2013;31(4):589–98, viii.
23. Da Forno PD, Fletcher A, Pringle JH, Saldanha GS. Understanding Spitzoid tumours: new insights from molecular pathology. *Br J Dermatol.* 2008;158(1):4–14.
24. Ferrara G, Cavicchini S, Corradin MT. Hypopigmented atypical Spitzoid neoplasms (atypical Spitz nevi, atypical Spitz tumors, Spitzoid melanoma): a clinicopathological update. *Dermatol Pract Concept.* 2015;5(1):45–52.
25. Urso C. On the nature of atypical Spitz tumors. *Arch Pathol Lab Med.* 2016;140(12):1316–1317.
26. Harms KL, Lowe L, Fullen DR, Harms PW. In reply. *Arch Pathol Lab Med.* 2016;140(12):1317.
27. Gerami P, Scolyer RA, Xu X, et al. Risk assessment for atypical Spitzoid melanocytic neoplasms using FISH to identify chromosomal copy number aberrations. *Am J Surg Pathol.* 2013;37(5):676–84.
28. Zedek DC, McCalmont TH. Spitz nevi, atypical Spitzoid neoplasms, and Spitzoid melanoma. *Clin Lab Med.* 2011;31(2):311–20.
29. Luo S, Sepehr A, Tsao H. Spitz nevi and other Spitzoid lesions part II. Natural history and management. *J Am Acad Dermatol.* 2011;65(6):1087–92.
30. Kernen JA, Ackerman LV. Spindle cell nevi and epithelioid cell nevi (so-called juvenile melanomas) in children and adults: a clinicopathologic study of 27 cases. *Cancer.* 1960;13:612–625.
31. Casso EM, Grin-Jorgensen CM, Grant-Kels JM. Spitz nevi. *J Am Acad Dermatol.* 1992;27:901–913.
32. Wiesner T, He J, Yelensky R, et al. Kinase fusions are frequent in Spitz tumours and spitzoid melanomas. *Nat Commun.* 2014;5:3116.
33. Ferrara G, Zalaudek I, Savarese I, Scalvenzi M, Argenziano G. Pediatric atypical Spitzoid neoplasms: a review with emphasis on 'red' ('Spitz') tumors and 'blue' ('blitz') tumors. *Dermatology.* 2010;220(4):306–10.
34. Ludgate MW, Fullen DR, Lee J, et al. The atypical Spitz tumor of uncertain biologic potential: a series of 67 patients from a single institution. *Cancer.* 2009;115(3):631–41.
35. Moscarella E, Lallas A, Kyrgidis A, et al. Clinical and dermoscopic features of atypical Spitz tumors: a multicenter, retrospective, case-control study. *J Am Acad Dermatol.* 2015;73(5):777–84.
36. Luo S, Sepehr A, Tsao H. Spitz nevi and other Spitzoid lesions part I. Background and diagnoses. *J Am Acad Dermatol.* 2011;65(6):1073–84.
37. Herreid PA, Shapiro PE. Age distribution of Spitz nevus vs malignant melanoma. *Arch Dermatol.* 1996;132(3):352–3.
38. Schaffer JV. Update on melanocytic nevi in children. *Clin Dermatol.* 2015;33(3):368–86.
39. Vollmer RT. Patient age in Spitz nevus and malignant melanoma: implication of Bayes rule for differential diagnosis. *Am J Clin Pathol.* 2004;121(6):872–7.
40. Bär M, Tschandl P, Kittler H. Differentiation of pigmented Spitz nevi and Reed nevi by integration of dermatopathologic and dermatoscopic findings. *Dermatol Pract Concept.* 2012;2(1):13–24.
41. Lallas A, Apalla Z, Papageorgiou C, Evangelou G, Ioannides D, Argenziano G. Management of flat pigmented Spitz and Reed Nevi in children. *JAMA Dermatol.* 2018;154(11):1353–4.

7F BENIGN MELANOCYTIC LESIONS: OTHER NEVI

Valeria De Bedout and Natalia Jaimes

Contents

Introduction . . . 176
Targetoid nevi . . . 176
Halo nevi . . . 176
Dermoscopic characteristics of halo nevi . . . 176
Meyerson's nevi . . . 176
Dermoscopic characteristics of Meyerson's nevi . . . 176
Cockade nevi . . . 176
Dermoscopic characteristics of cockade nevi . . . 177
Melanoma simulators . . . 177
Recurrent nevi . . . 177
Dermoscopic characteristics of recurrent nevi . . . 177
Lichen sclerosus nevi . . . 177
Dermoscopic characteristics of LS nevi . . . 177
Other uncommon variants . . . 177
Balloon cell nevi . . . 177
Dermoscopic characteristics of BCN . . . 177
Epidermolysis bullosa nevi . . . 177
Dermoscopic characteristics of EB nevi . . . 178
References . . . 179

Introduction

Dermoscopy has proven useful in diagnosing less frequent variants of melanocytic nevi, including "targetoid" nevi (i.e., halo nevi, cockade nevi, Meyerson nevi); "melanoma simulators," in particular recurrent nevi and lichen sclerosus nevi; and other uncommon variants (i.e., balloon cell nevi, epidermolysis bullosa nevi).

Targetoid nevi

Halo nevi

Halo nevi, also known as Sutton's nevi or leukoderma acquisitum centrifugum, were first described by Sutton in 1916 (1). They are frequently seen on the trunk of children and young adults with or without a history of atopic dermatitis or autoimmune disorders, such as vitiligo (1, 2). Halo nevi are characterized by a rim or halo of depigmentation surrounding a melanocytic nevus, most frequently a globular or homogeneous compound or intradermal nevus (2). This phenomenon of depigmentation represents one pathway to the involution of nevi, specifically a T-cell immune-mediated process (3). Halo nevi persist for an average of 8 years before re-pigmentation occurs (2, 4).

Dermoscopic characteristics of halo nevi

- Halo nevi usually occur in nevi with a globular or homogeneous pattern.
- A symmetric white structureless area is seen surrounding central dots/globules, homogeneous tan pigmentation, and/or gray dots/granules.
- After complete involution of the nevus, a pink central area can be observed.

Rarely, melanomas display peripheral depigmentation, but in these cases, dermoscopy reveals a lesion with a multicomponent pattern with one or more melanoma-specific structures (see Chapters 8a–8f). In addition, the halo in melanoma tends to be irregular with asymmetry and unevenness in its distribution (2).

Meyerson's nevi

Meyerson's nevi, also known as eczematous nevi, were first described by Meyerson in 1971 (5). They are usually found on the trunk and upper extremities of young adults. Meyerson's nevi are characterized by an eczematous reaction surrounding and overlying a pre-existing nevus. The eczematous reaction is characterized by erythema, scale, and pruritus. It usually resolves after a few weeks or months without affecting the dermoscopic architecture of the associated nevus (6). Histopathology demonstrates a nevus, frequently compound, without atypia, associated spongiosis, and a perivascular infiltrate composed of CD4+ lymphocytes with occasional eosinophils (6, 7). Meyerson's nevi can be treated with topical corticosteroids.

Dermoscopic characteristics of Meyerson's nevi

Overall, the eczematous reaction does not significantly distort the dermoscopic pattern of the nevus. However, the structures and pattern may appear less focused due to the overlying fine superficial scale or serocrusts (8).

Cockade nevi

Clinically, Cockade nevi reveal a targetoid pattern characterized by a central pink to brown papule or macule that is surrounded by an inner hypopigmented rim and an outer pigmented rim. Cockade nevi are often found on the scalp of children and adolescents (9). Histologically, the central portion corresponds to a compound nevus, while the peripheral portion shows a nonpigmented junctional nevus pattern (10).

Dermoscopic characteristics of cockade nevi

- Targetoid appearance, with a darker, central globular or homogeneous pattern, surrounded by a hypopigmented homogeneous structureless inner rim and a peripheral darker reticular outer rim (9)

Melanoma simulators

Recurrent nevi

Recurrent nevi are defined as proliferations of nevomelanocytes occurring after the partial surgical or traumatic removal of a melanocytic nevus (11). They most commonly occur on the back of young adults and often develop within the first 3 to 8 months after incomplete removal of the nevus (11–13). Although clinically recurrent nevi may simulate a melanoma (i.e., pseudomelanoma), dermoscopy has proven useful in differentiating them from melanoma (13).

Dermoscopic characteristics of recurrent nevi

- Pigmentation is usually confined to the scar and follows a centrifugal growth pattern with radial lines that are symmetric, and the pigment does not traverse from the scar into the surrounding normal skin.
- Pigmented structures are usually arranged contiguously and centrifugally.

In addition, there are other characteristics that can aid the clinician in differentiating recurrent nevi from recurrent melanoma, including age, characteristics of the pigmentation, time to recurrence, and location (13) (Table 7f.1).

Lichen sclerosus nevi

Lichen sclerosus (LS) is a chronic inflammatory skin disease of unknown etiology. It has a predilection for the anogenital area of female patients and manifests as white, ivory-colored macules or patches. These patches can also reveal focal ecchymotic areas. Rarely, a melanocytic nevus can develop within LS. It is hypothesized that the altered stroma in LS may lead to melanocyte activation, resulting in their proliferation (14). This occurs most commonly in children and young adults. The morphology created when nevi and LS collide mimics melanoma.

Dermoscopic characteristics of LS nevi

- Nevi developing in LS usually reveal a parallel, globular, or homogeneous pattern, but a multicomponent pattern is not uncommon.
- Dermoscopy of the LS reveals porcelain white structureless areas and may also reveal comedo-like openings. Lesions may or may not display vessels or shiny white lines.

In the presence of a pigmented lesion in genitalia, it is important to always evaluate the surrounding skin and the entire anogenital area to rule out the presence of LS. It is suggested that some of the atypical findings observed in nevi arising on LS are due to the inflammation and altered stroma (14). In fact, some authors suggest that providing treatment to the LS (i.e., topical steroids) may improve some of the atypical features observed in these nevi (15).

Other uncommon variants

Balloon cell nevi

Balloon cell nevi (BCN) are a rare variant of melanocytic nevi, often found on the head and trunk of children and young adults. BCN present as a relatively symmetric, pink or light brown macule or papule with a flat, raised, or mammillated surface (16). Histologically, BCN are characterized by dermal lobules of large multinucleated cells with small round central nuclei (17). Balloon cells are melanocytes with extensive pale staining and vacuolated cytoplasm, which often have a defect in the melanosome formation (17–19).

Dermoscopic characteristics of BCN

- Three or more aggregated white-to-yellow globules. These globules correspond to balloon cell nests. In contrast to milia-like cysts, which are more conspicuous with nonpolarized light, white globules seen in BCN can be visualized equally well with polarized and nonpolarized light (18, 19).

Epidermolysis bullosa nevi

Epidermolysis bullosa (EB) refers to a group of mechanobullous diseases arising from various mutations in keratin proteins at the dermo-epidermal junction. Patients with EB develop blisters and erosions after minor trauma to the skin and mucosae. Depending on the level at which the cleavage occurs, EB has been classified into epidermolytic or simplex, junctional, and dermolytic or dystrophic (20).

Up to 14% of patients with all forms of inherited EB can develop new nevi;, with large atypical nevi commonly seen in patients with the recessive inherited forms of EB (21–23). These nevi, known as EB nevi, usually arise during the first two decades of life and are frequently found on sites of prior blisters, in particular on the extremities overlying bony prominences (21). They are relatively large, asymmetric and irregularly pigmented

TABLE 7F.1: Differences Between Recurrent Nevi and Recurrent Melanoma

	Recurrent Nevi	Recurrent Melanoma
Age	Younger patients	Older patients
Location	Torso	Head and neck
Average time to recurrence	8 months	25 months
Pigment	• Confined to scar • Contiguous	• Pigment traverses the scar's edge • Noncontiguous
Growth pattern	Centrifugal	Chaotic

Source: Blum, A., et al., *JAMA Dermatol*, 150(2), 138–145, 2014.

neoplasms (21). Not infrequently, small satellite nevi can develop around the primary EB nevus (22). Different theories for their pathogenesis have been posited, including that they form due to a reactive process resulting in the increased proliferation of melanocytes, which is thought to be triggered by the repetitive disruption of the basement membrane. Another theory postulates that they form when free-floating melanocytes within the cytokine milieu of an EB blister settle onto the epidermis and begin to proliferate (21, 22).

Although melanoma is not common in any form of EB, only patients with the recessive dystrophic form of EB have a slightly increased lifetime risk for melanoma (cumulative risk of 2.5% by age 12) (23). In 2001, Bauer and colleagues published a 20-year prospective study of 86 EB nevi, which showed that none of the pigmented lesions progressed to melanoma (24). To our knowledge, two cases of melanoma arising on EB-affected skin have been reported in the literature. Both cases have been female adults (ages 26 and 30) with new and changing lesions on EB simplex–affected skin (25, 26). The first case reported was a 30-year-old female with a long history of EB simplex, with persistent blisters and erosions on the sole, who developed a melanoma of at least 1.10 mm thickness on EB simplex–affected skin (25). The other case was a 26-year-old female with EB simplex who developed a new enlarging and changing lesion on her back; a biopsy was performed, demonstrating a superficial spreading melanoma, 0.25 mm (26).

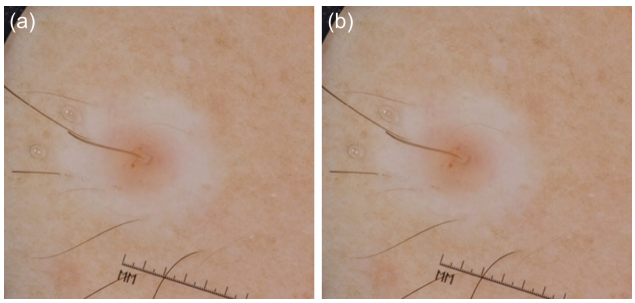

FIGURE 7F.1 (a, b) Dermoscopy images of a halo nevus.



FIGURE 7F.2 Meyerson nevus on the nasolabial skin of a young female. Clinically, an eczematous reaction, with erythema and scale, was observed surrounding the pre-existing nevus. The eczematous reaction did not significantly distort the dermoscopic pattern of the nevus. However, the structures and pattern appeared less focused with an adjacent overlying fine superficial serocrust.

Dermoscopic characteristics of EB nevi

Not infrequently, EB nevi can demonstrate dermoscopic features that overlap with those seen in melanoma, including a multicomponent pattern with atypical pigment network, irregular dots and globules, and milky-red areas (21, 27). Therefore, patients with EB nevi should be closely followed with clinical images, digital dermoscopy, and total body photography. Although the risk for melanoma is extremely low, a skin biopsy should be considered in cases of new and/or changing lesions, especially on EB-affected skin, and older age of onset (Figures 7f.1 to 7f.6).

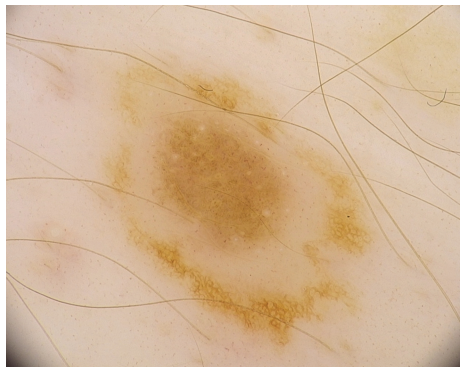

FIGURE 7F.3 Dermoscopy image of a Cockade nevus. Dermoscopy demonstrates the targetoid pattern with a central brown flat papule surrounded by an inner hypopigmented rim and an outer pigmented network rim.



FIGURE 7F.4 Recurrent nevus on the abdomen of a young male. Dermoscopy demonstrates brown pigmentation confined to the scar with a centrifugal growth pattern: symmetric radial lines that do not traverse from the scar into the surrounding normal skin.

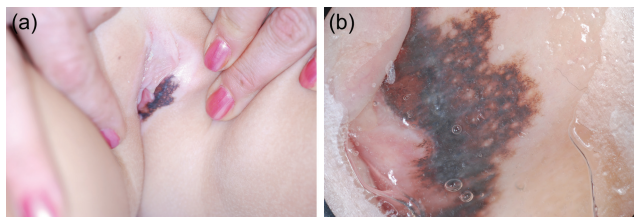

FIGURE 7F.5 Young girl with history of lichen sclerosis. She developed an irregular dark brown lesion within the sclerotic skin. A biopsy of this lesion revealed features that are commonly associated with recurrent nevi.

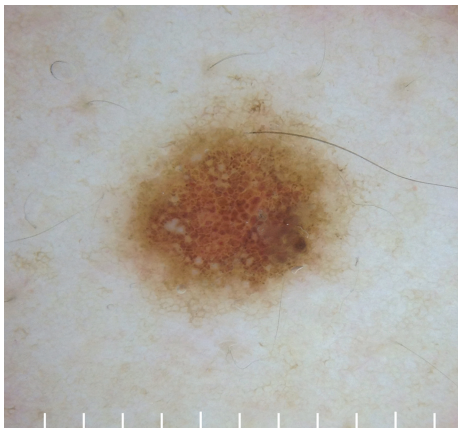

FIGURE 7F.6 Dermoscopy image of a balloon cell nevus revealing aggregated white globules (i.e., three or more globules). These white globules can be seen with polarized and nonpolarized light, and correspond to balloon cell nests.

References

1. Becker MD, Marcks KM, Trevaskis AE, Heffernan AG, Puchner G. Halo nevus of Sutton. *Plast Reconstr Surg.* 1966;37(5):413–5.
2. Kolm I, Di Stefani A, Hofmann-Wellenhof R, et al. Dermoscopy patterns of halo nevi. *Arch Dermatol.* 2006;142(12):1627–32.
3. Terushkin V, Scope A, Halpern AC, Marghoob AA. Pathways to involution of nevi: insights from dermoscopic follow-up. *Arch Dermatol.* 2010;146(4):459–60.
4. Aouthmany M, Weinstein M, Zirwas MJ, Brodell RT. The natural history of halo nevi: a retrospective case series. *J Am Acad Dermatol.* 2012;67(4):582–6.
5. Meyerson LB. A peculiar papulosquamous eruption involving pigmented nevi. *Arch Dermatol.* 1971;103(5):510–2.
6. Cook-Norris RH, Zic JA, Boyd AS. Meyerson's naevus: a clinical and histopathological study of 11 cases. *Australas J Dermatol.* 2008;49(4):191–5.
7. Pizem J, Stojanovic L, Luzar B. Melanocytic lesions with eczematous reaction (Meyerson's phenomenon): a histopathologic analysis of 64 cases. *J Cutan Pathol.* 2012;39(10):901–10.
8. Gabbi TV, Omar ED, Criado PR, Valente NY, Martins JE. Clinical, dermoscopic and histopathological evaluation of the Meyerson nevus: case report. *An Bras Dermatol.* 2010;85(5):681–3.
9. Tcheung WJ, Bellet JS, Prose NS, Cyr DD, Nelson KC. Clinical and dermoscopic features of 88 scalp naevi in 39 children. *Br J Dermatol.* 2011;165(1):137–43.
10. Kessides MC, Puttgen KB, Cohen BA. No biopsy needed for eclipse and cockade nevi found on the scalps of children. *Arch Dermatol.* 2009;145(11):1334–6.
11. Castagna RD, Stramari JM, Chemello RML. The recurrent nevus phenomenon. *An Bras Dermatol.* 2017;92(4):531–3.
12. Heck R, Ferrari T, Cartell A, Bakos RM. Clinical and dermoscopic (in vivo and ex vivo) predictors of recurrent nevi. *Eur J Dermatol.* 2019;29(2):179–84.
13. Blum A, Hofmann-Wellenhof R, Marghoob AA, et al. Recurrent melanocytic nevi and melanomas in dermoscopy: results of a multicenter study of the International Dermoscopy Society. *JAMA Dermatol.* 2014;150(2):138–45.
14. Carlson JA, Mu XC, Slominski A, et al. Melanocytic proliferations associated with lichen sclerosus. *Arch Dermatol.* 2002;138(1):77–87.
15. Neri I, Dika E, Fanti PA, Misciali C, Patrizi A. Genital melanocytic naevus on lichen sclerosus: an uncommon occurrence and a management proposal. *J Eur Acad Dermatol Venereol.* 2016;30(5):794–7.
16. Martinez-Casimiro L, Sanchez Carazo JL, Alegre V. Balloon cell naevus. *J Eur Acad Dermatol Venereol.* 2009;23(2):236–7.
17. Oliveira A, Zalaudek I. Balloon cell naevus: new perspectives using high-definition optical coherence tomography with dermoscopic and reflectance confocal microscopic correlation. *J Eur Acad Dermatol Venereol.* 2016;30(9):1624–5.
18. Jaimes N, Scope A, Welzel J, et al. White globules in melanocytic neoplasms: in vivo and ex vivo characteristics. *Dermatol Surg.* 2012;38(1):128–32.
19. Jaimes N, Braun RP, Stolz W, Busam KJ, Marghoob AA. White globules correlate with balloon cell nevi nests. *J Am Acad Dermatol.* 2011;65(4):e119–e20.
20. Uitto J, Richard G. Progress in epidermolysis bullosa: from eponyms to molecular genetic classification. *Clin Dermatol.* 2005;23(1):33–40.
21. Koga M, Koga K, Imafuku S. Spontaneous regression of an epidermolysis bullosa nevus on the sole. *J Dermatol.* 2015;42(1):37–9.
22. Lanschuetzer CM, Laimer M, Nischler E, Hintner H. Epidermolysis bullosa nevi. *Dermatol Clin.* 2010;28(1):179–83.
23. Fine JD, Johnson LB, Weiner M, Li KP, Suchindran C. Epidermolysis bullosa and the risk of life-threatening cancers: the National EB Registry experience, 1986–2006. *J Am Acad Dermatol.* 2009;60(2):203–11.
24. Bauer JW, Schaeppi H, Kaserer C, Hantich B, Hintner H. Large melanocytic nevi in hereditary epidermolysis bullosa. *J Am Acad Dermatol.* 2001;44(4):577–84.
25. Hocker TL, Fox MC, Kozlow JH, et al. Malignant melanoma arising in the setting of epidermolysis bullosa simplex: an important distinction from epidermolysis bullosa nevus. *JAMA Dermatol.* 2013;149(10):1195–8.
26. Kantarjiev V, Yordanov T, Broshtilova V. Epidermolysis bullosa nevi: a concept of awareness. *Int J Clin Pathol Diagn.* 2019;IJCP-127.
27. Lanschuetzer CM, Emberger M, Laimer M, et al. Epidermolysis bullosa naevi reveal a distinctive dermoscopic pattern. *Br J Dermatol.* 2005;153(1):97–102.

8A MELANOCYTIC LESIONS: SUPERFICIAL SPREADING MELANOMAS

Natalia Jaimes and Scott W. Menzies

Contents

Variants. 181
Key points 183
References 185

Superficial spreading melanoma (SSM) is the most common histological subtype, accounting for up to 66% of all cutaneous melanomas (6, 12, 20). A SSM is defined as an invasive melanoma that has an in situ component beyond three rete ridges of its invasive component. It is characterized by invasion of malignant melanocytes both singly and in nests upward within the epidermis (pagetoid spread) and radially at the dermoepidermal junction (DEJ). These histologic features correlate with the dermoscopic features found at the edge of a SSM (Figures 8a.1–8a.24, Table 8a.1).

1. *Atypical network* correlates with the expansion of malignant melanocytes at the rete ridges and can often be found focally at or near the edge of a SSM (13, 14). It appears as a web of lines of varying colors and thicknesses with holes of varying diameters. The color of the atypical network ranges from brown to black or gray, and it can appear smudged or seemingly out of focus. The atypical network is often associated with the in situ component and may be the only specific feature of an early thin SSM (13, 14) (Figures 8a.1, 8a.2, 8a.4–8a.6, 8a.9, 8a.12, 8a.13, 8a.20, 8a.23).

2. *Streaks, including pseudopods and radial streaming.* Their presence represents confluent radial nests of melanoma at the DEJ. Streaks appear as radial projections at the periphery of the lesion emanating from the tumor and radiating towards the surrounding normal skin (Figures 8a.1, 8a.5, 8a.7, 8a.8, 8a.9, 8a.14, 8a.15, 8a.21, 8a.24). They correspond to the radial growth phase of either a pigmented Spitz nevus or a SSM.

3. *Atypical dots* are black or brown round structures measuring less than 0.1 mm in diameter. Black dots represent malignant melanocytes found at or near the stratum corneum (Figures 8a.15, 8a.19, 8a.20). Multiple brown dots correlate with suprabasal epidermal malignant melanocytes and represent the pagetoid spread of a SSM (Figures 8a.8 and 8a.9). Under dermoscopy, atypical dots tend to be distributed randomly and are often found towards the periphery of the melanoma; they may or may not need to be associated with a network, but if a network is present, it is often atypical.

4. *Atypical globules* are round to oval pigmented structures larger than 0.1 mm in diameter. Histopathologically, globules correspond to nests of melanocytes in the DEJ or dermis. According to their location and/or cell type, globules can be brown (nests of melanocytes present at the DEJ or superficial dermis), blue (nests of melanocytes located deeper in the dermis), or white (balloon cell changes in melanocytes (9)). Atypical globules present with varying size, shape, and/or colors, and may be distributed in a disorganized fashion within the lesion (Figure 8a.22).

5. *Regression structures* include scarlike areas and peppering or granularity. *Scarlike areas* appear as porcelain white structureless areas that are lighter than the surrounding normal skin. *Peppering or granularity* appears as blue-gray fine dots and represents the common occurrence of regression in SSM. Histologically, the peppering corresponds to melanophages or free melanin in the papillary dermis, and the scarlike depigmentation corresponds to dermal fibrosis. Regression areas displaying peppering in association with scarlike depigmentation can manifest a blue-whitish color. This blue-white pattern is usually seen in macular lesions, as opposed to the blue-white veil, which is seen in raised or palpable lesions (Figures 8a.3, 8a.6–8a.8, 8a.10, 8a.14 and 8a.17).

6. *Blue-white veil*, which is due to melanin in the middermis with overlying epidermal compact orthokeratosis, is also frequently observed in invasive melanomas (Figures 8a.6, 8a.7, 8a.9, 8a.10, 8a.12, 8a.13, 8a.15, 8a.24).

7. *Multiple colors*, due to melanin at various levels within the dermis and epidermis, are commonly seen in SSM (Figures 8a.9, 8a.11, 8a.15, 8a.17, 8a.19, 8a.20).

8. *Negative network* is seen as hypopigmented serpiginous interconnecting lines that surround irregularly shaped pigmented structures resembling elongated curvilinear globules (14, 17). Histology reveals bridging or elongation of rete ridges in association with large melanocytic nests in papillary dermis (17). It can be seen in melanoma, Spitz nevi, dysplastic nevi, or melanomas arising in association with nevi (Figure 8a.23).

9. *Peripheral light brown structureless areas* are seen as homogeneous light brown areas of variable size and shape, located at the periphery of the lesion and occupying more than 10% of its surface (1). Histologically, the areas are due to relative flattening of the rete ridges in combination with a preponderance of single-cell pagetoid melanoma cells and pigmented keratinocytes rather than the formation of nests in the epidermis (Figures 8a.1, 8a.6, 8a.10, 8a.11, 8a.17, 8a.19, 8a.20, 8a.22).

10. *Shiny white lines:* Shiny white lines or streaks can only be seen with polarized light. They consist of short, bright, white lines that are usually oriented parallel or orthogonal to each other. Histologically, shiny white lines correspond to stromal alteration and dermal fibrosis (Figure 8a.20).

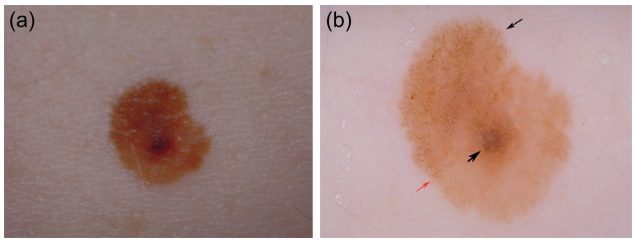

FIGURE 8A.1 (a) Clinical image. (b) This asymmetrically patterned multicolored lesion (i.e., lacks symmetry of pattern over every axis through the center of the lesion [see Chapter 7b] and has more than one color; scored from tan, dark brown, gray, black, blue, and red) has the positive melanoma features of a broadened atypical network (thick arrow), and the pseudopod (thin arrow) and radial streaming (red arrow) are very subtle. Note the peripheral light brown structureless area occupying more than 10% of the lesion surface from 3 to 7 o'clock in position. Diagnosis: in situ superficial spreading melanoma.

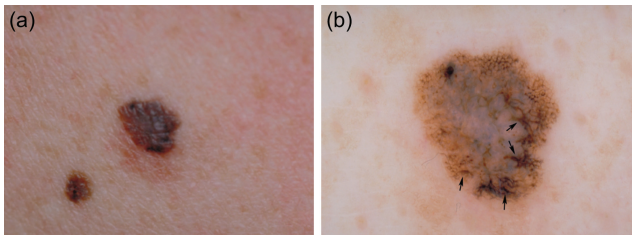

FIGURE 8A.2 (a) Clinical image. (b) This asymmetrically patterned multicolored lesion has the positive melanoma feature of broadened atypical network (arrows). Broadened network is usually seen focally rather than in a uniform distribution. It is probably the most important (sensitive) feature of early nonregressing superficial spreading melanoma. Note the blue pigmentation formed by confluent melanophages in the mid-dermis. Diagnosis: In situ superficial spreading melanoma.

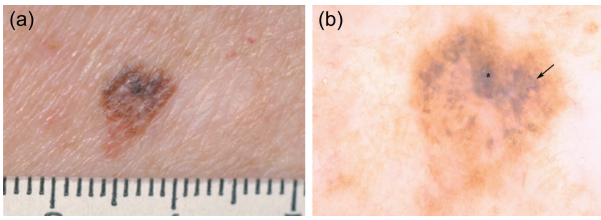

FIGURE 8A.3 (a) Clinical image. (b) This asymmetrically patterned multicolored lesion has both the positive melanoma features of regression (scarlike depigmentation and multiple blue-gray dots; the latter indicated by the arrow). Confluence of melanophages is seen in this lesion as blue-white color (asterisk). Diagnosis: Regressing superficial spreading melanoma, Breslow thickness 0.3 mm.

Table 8a.1 shows the specificity and sensitivity of the important dermoscopic features of invasive SSM. The morphologic definitions of the features described here have been described in detail in Chapter 7.

Variants

Amelanotic melanomas. SSMs have a number of specific dermoscopic features that are less commonly found in nodular melanoma. Indeed, the vast majority of pigmented SSMs are easily identified using dermoscopic criteria. In contrast to pigmented SSMs, fewer descriptions of the dermoscopy of hypomelanotic or amelanotic SSMs are published (4, 10, 15, 18). These latter lesions can be due to *widespread regression*, in which case their diagnosis is less difficult because of the positive specific features of scarlike depigmentation with or without multiple blue-gray fine dots (melanophages) (Figures 8a.3, 8a.6, 8a.7). More difficult are the true amelanotic or hypomelanotic SSMs. In the largest series published where more than 80% were SSMs, the most significant positive predictive *nonregressing features* were (in order) blue-white veil, irregularly shaped depigmentation, irregularly distributed and shaped brown dots/globules, five to six colors (in partially pigmented

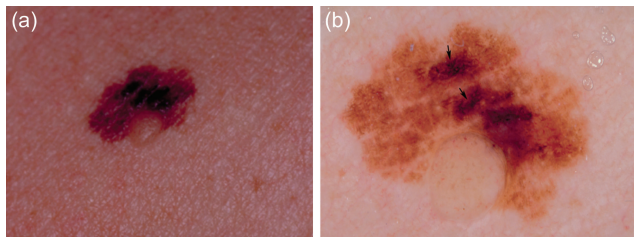

FIGURE 8A.4 (a) Clinical image. (b) This asymmetrically patterned multicolored lesion has the one positive melanoma feature of focal broadened network (arrows). Note the amelanotic contiguous nevus. Diagnosis: Superficial spreading melanoma, Breslow thickness 0.35 mm with a contiguous compound nevus.

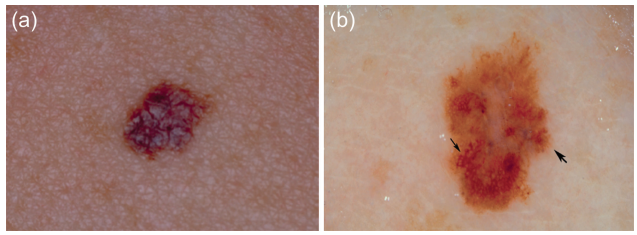

FIGURE 8A.5 (a) Clinical image. (b) This asymmetrically patterned multicolored lesion (dark brown, tan, and gray) has the positive features of focal broadened network (thin arrow) and subtle radial streaming (large arrow). Diagnosis: Superficial spreading melanoma, Breslow thickness 0.35 mm.

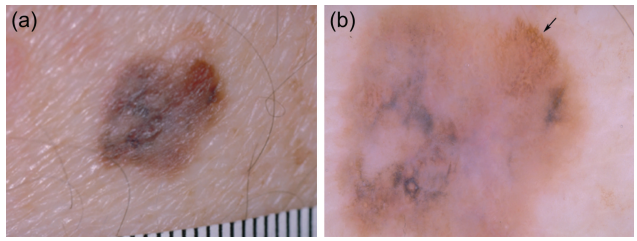

FIGURE 8A.6 (a) Clinical image. (b) This asymmetrically patterned multicolored lesion has the positive features of scarlike depigmentation, granularity, and focal broadened network (arrow). In addition, note the widespread peripheral light brown structureless areas occupying more than 10% of the lesion surface. Diagnosis: Regressing superficial spreading melanoma, Breslow thickness 0.4 mm.

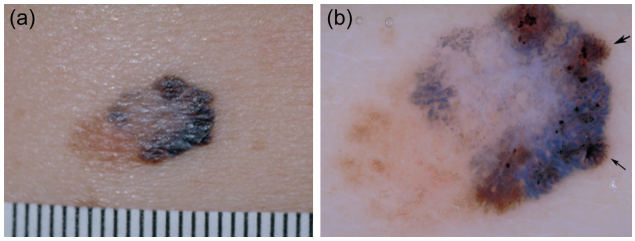

FIGURE 8A.7 (a) Clinical image. (b) This asymmetrically patterned multicolored lesion has the positive melanoma features of blue-white veil, radial streaming (thin arrow), pseudopods (thick arrow), scarlike depigmentation, multiple blue-gray dots and multiple (five–six) colors (scored from tan, dark brown, gray, blue, black, and red). Note the contiguous nevus at the left pole. Diagnosis: Superficial spreading melanoma, Breslow thickness 0.42 mm.

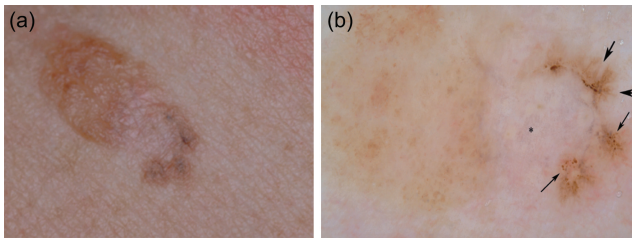

FIGURE 8A.8 (a) Clinical image. (b) This asymmetrically patterned multicolored lesion has the positive melanoma features of multiple brown dots, found in the classical focal distribution (thin arrows), radial streaming (thick arrows), and multiple blue-gray dots (asterisk). Note the contiguous banal nevus at the left half of the lesion. Diagnosis: Regressing superficial spreading melanoma, Breslow thickness 0.45 mm with a contiguous compound nevus.

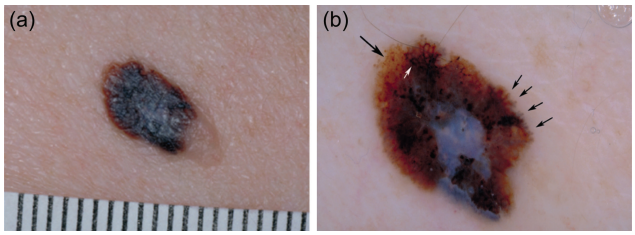

FIGURE 8A.9 (a) Clinical image. (b) This asymmetrically patterned multicolored lesion has the positive melanoma features of blue-white veil, radial streaming, and pseudopods (thin arrows), multiple brown dots (thick arrow), focal broadened network (white arrow), and multiple (five–six) colors. Diagnosis: Superficial spreading melanoma, Breslow thickness 0.5 mm with a contiguous dermal nevus.

lesions), predominant central vessels, peripheral light brown structureless areas, asymmetrical pigmentation pattern, milky red pink areas, greater than one shade of pink, asymmetrical shape, dotted and linear irregular vessels in combination, and linear irregular vessels as the predominant vessel type (15). Features that were uncommon in amelanotic/hypomelanotic melanomas were multiple (>3) milia-like cysts (1%), regularly distributed comma vessels (1%) or comma vessels as the predominant vessel type (2.9%), blue-gray globules of irregular size or distribution (1.9%), arborizing small-diameter vessels (6.7%),

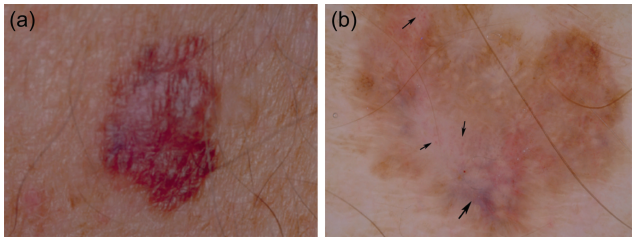

FIGURE 8A.10 (a) Clinical image. (b) This lesion is identified as melanocytic because of the areas of network and brown globules. It is multicolored, has an asymmetric pattern, and has the positive features of scarlike depigmentation and granularity (thick arrow). Note the pin-point (dotted) vessels in the hypomelanotic areas (thin arrows). While dotted vessels are commonly found in thin SSM; they indicate the lesion is melanocytic in origin rather than melanoma. Also seen are widespread peripheral light brown structureless areas. Diagnosis: Regressing superficial spreading melanoma, Breslow thickness 0.5 mm.

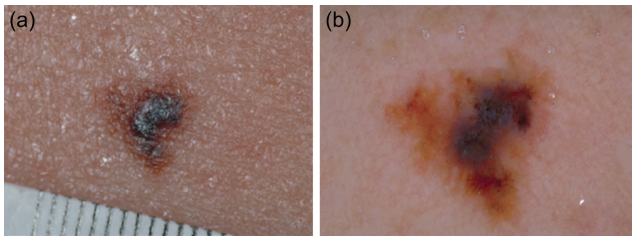

FIGURE 8A.11 (a) Clinical image. (b) As also seen in Figure 8a.9, the positive melanoma feature of multiple (five–six) colors can be found in relatively thin melanoma. Diagnosis: Superficial spreading melanoma, Breslow thickness 0.55 mm.

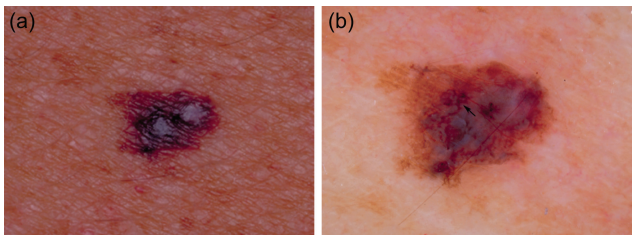

FIGURE 8A.12 (a) Clinical image. (b) This asymmetrically patterned multicolored lesion has the positive features of blue-white veil and broadened network (arrow). Diagnosis: Superficial spreading melanoma, Breslow thickness 0.6 mm.

arborizing vessels as the predominant vessel type (8.6%), and symmetrical pigmentation pattern (7.6%) (15). More details on the dermoscopy of hypomelanotic melanoma can be found in Chapter 8e.

Nevus-associated melanomas have been described in one-third to half of patients with melanoma, in particular those with multiple nevi (8, 21). Up to 42% of these cases are associated with a SSM, and the most frequent dermoscopic findings include the presence of a negative network (OR 9.9), globules (OR 2.4), and streaks (OR 2.4) (16, 21).

Nested melanoma is a histopathologic variant of SSM, characterized by large intraepidermal nests, sharp lateral

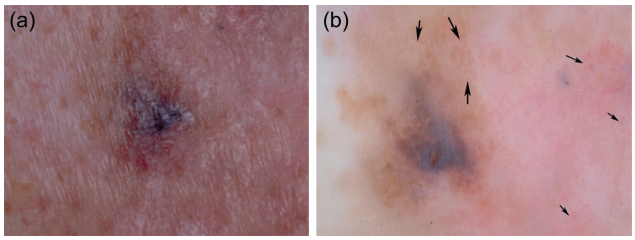

FIGURE 8A.13 (a) Clinical image. (b) This hypomelanotic asymmetrically patterned multicolored lesion has the positive features of extensive scarlike depigmentation and blue-white veil. Note the pin-point (dotted) vessels within the amelanotic component (small arrows). Also note the negative pigment network (large arrows), which is a significant finding in both Spitz nevi and invasive melanoma (13). Diagnosis: Superficial spreading melanoma, Breslow thickness 0.7 mm.

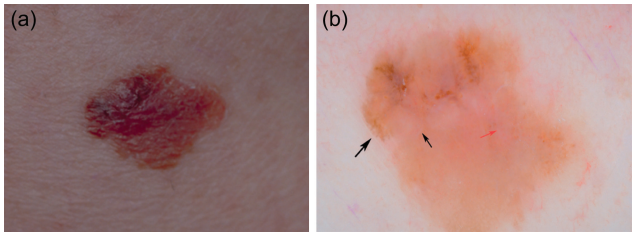

FIGURE 8A.14 (a) Clinical image. (b) This asymmetric multicolored lesion (tan and dark brown) has the positive features of scarlike depigmentation (fine arrow) and subtle radial streaming (thick arrow). Note the combination of pin-point vessels (red arrow) with linear irregular vessels (within the more vascular top right area) predictive of melanoma. Diagnosis: Superficial spreading melanoma, Breslow thickness 0.7 mm.

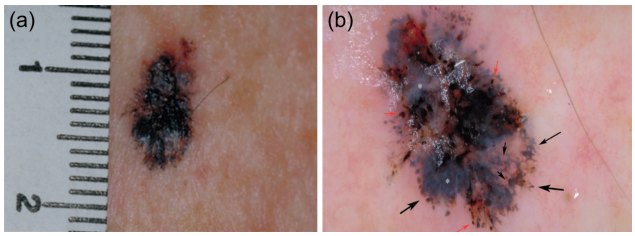

FIGURE 8A.15 (a) Clinical image. (b) This asymmetrically patterned multicolored lesion has the positive melanoma features of broadened network (thin arrows), blue-white veil (asterisk), peripheral black dots/globules (red arrow), pseudopods (thick arrows), and multiple (five–six) colors. Diagnosis: Superficial spreading melanoma, Breslow thickness 0.8 mm.

circumscription, and focal areas of lentiginous proliferation of melanocytes at the DEJ. Nested melanomas usually present as pigmented flat lesions with irregular borders on the trunk and extremities of patients older than 60 years. Less frequently, nested melanomas can also present as exophytic papillomatous nodules with little junctional component (5). The most common dermoscopic finding is atypical globules of different size, shape, and color that are irregularly distributed (11).

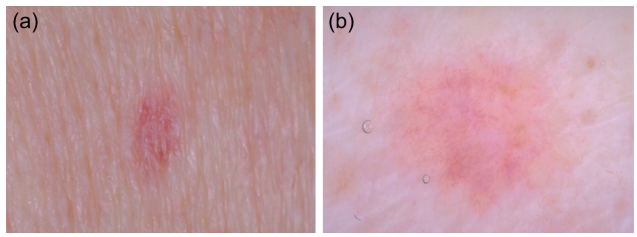

FIGURE 8A.16 (a) Clinical image. (b) This amelanotic lesion has some linear irregular and arborizing (tree-like) vessels scattered throughout its surface. Because of some overlap between amelanotic melanoma and other malignant amelanotic lesions as seen here, it has been shown to be relatively easier to distinguish all malignant amelanotic/hypomelanotic lesions from all benign lesions (rather than to attempt to discriminate melanoma from other malignant lesions such as basal cell carcinoma). This illustrates the importance of biopsy prior to any nonsurgical treatment of amelanotic lesions. Diagnosis: Amelanotic superficial spreading melanoma, Breslow thickness 0.8 mm.

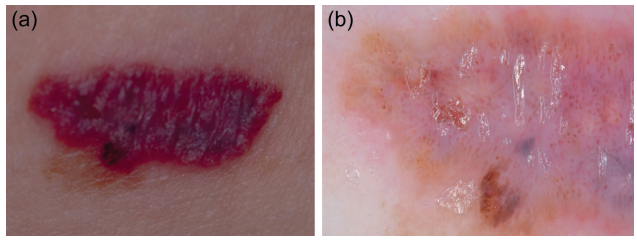

FIGURE 8A.17 (a) Clinical image. (b) This hypomelanotic lesion is asymmetric in pattern and multicolored. It has foci of brown dots and globules, indicating its melanocytic origin. In addition, it has the positive features of scarlike depigmentation and blue-white veil. Note the extensive pin-point (dotted) vessels in the amelanotic component. Also seen are widespread peripheral light brown structureless areas (especially at the superior lesion border). Diagnosis: Superficial spreading melanoma, Breslow thickness 1.1 mm.

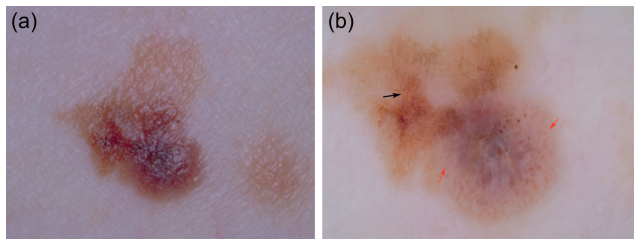

FIGURE 8A.18 (a) Clinical image. (b) This asymmetrically patterned multicolored superficial spreading melanoma (SSM) has the positive melanoma features of focal multiple brown dots (arrows) and small areas of blue-white veil. Note also the extensive negative pigment network (red arrows). Diagnosis: SSM, Breslow thickness 1.2 mm with associated compound nevus.

Key points

1. SSM manifests an asymmetric pattern that may be multicolored.
2. Atypical network is one of the earliest features seen in SSM.

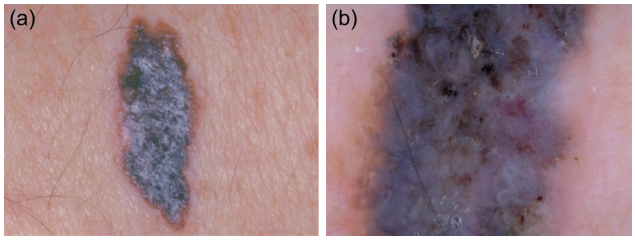

FIGURE 8A.19 (a) Clinical image. (b) This asymmetrically patterned multicolored lesion has the positive melanoma features of blue-white veil, peripheral black dots/globules, and multiple (five–six) colors. Also seen are peripheral light brown structureless areas at the left border of the lesion. Diagnosis: Superficial spreading melanoma, Breslow thickness 1.4 mm.

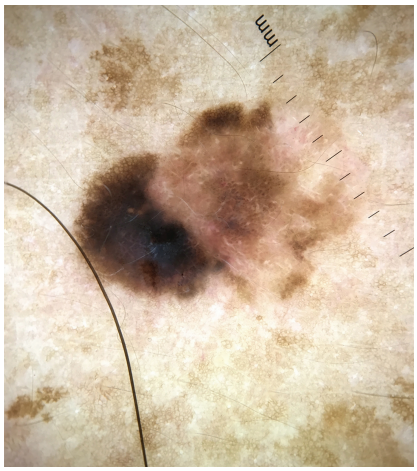

FIGURE 8A.20 Dermoscopic image of a superficial spreading melanoma revealing an asymmetric, multicolored pattern. More than one melanoma-specific structure is observed, including shiny white structures, peripheral light brown structureless areas, multiple (five–six) colors, and atypical dots. Breslow thickness 0.45 mm,



FIGURE 8A.21 Atypical streaks (i.e., radial streaming) as the predominant feature in a melanoma in situ. Note the structural asymmetry, particularly at the long edge of the lesion.



FIGURE 8A.22 Dermoscopic image of a 0.4 mm melanoma with atypical brown globules, peripheral light brown structureless areas, and atypical vessels (i.e., linear irregular and dotted vessels).



FIGURE 8A.23 Dermoscopic image of a melanoma in situ with an asymmetrically distributed negative network and atypical network. This was a collision tumor between a seborrheic keratosis and a melanoma in situ.

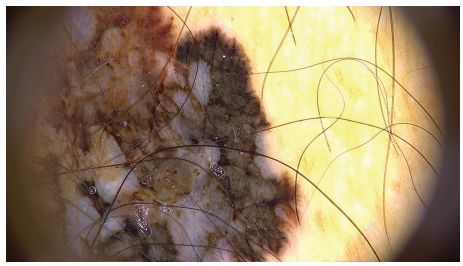

FIGURE 8A.24 Dermoscopic image of a portion of a melanoma demonstrating multiple (five–six) colors, radial streaming/pseudopods, multiple brown dots, and blue-white veil.

TABLE 8A.1: Major Dermoscopic Features of Superficial Spreading Melanoma

Melanoma-specific structure commonly observed in SSMs	Sensitivity (%)[a]	Specificity (%)[a]	PPV (%)[a]	NPV (%)[a]	OR[a]
1. Atypical network	77.1(1)	88.5 (15)	67 (1)	88 (7)	9 (2)
2. Streaks (i.e., pseudopods and/or radial streaming)	32 (19)	98.7(15)	76.5 (1)	86 (7)	5.8 (2)
3. Atypical dots and/or globules	39.6 (1)	91.1 (15)	79 (1)	86 (7)	4.8(2)
4. Regression structures					
• Granularity	21.9 (15)	92.6 (15)	78 (1)	62 (1)	3.5 (15)
• Scarlike areas	22.9 (15)	93.6 (15)			4.4 (15)
• Either of the two	41.7 (1)	89.2 (1)			7.8 (1)
5. Blue-white veil	11.4 (15)	99 (15)			13 (15)
6. Negative network	34.6 (17)	95 (14)			1.8 (17)
7. Brown peripheral structureless areas	62.5 (1)	96.1 (1)	93.8 (1)	73.1 (1)	27.9 (1)
8. White shiny streaks (crystalline structures)					9.7 (3)

Source: adapted from Menzies et al. with additions.
[a] Highest reported.
Abbreviation: OR, odds ratio.
Data were derived from both in situ and thin invasive melanoma (1).

3. Streaks in a SSM are indicative of radial growth.
4. Dotted and serpentine/linear vessels within the same lesion are highly suggestive of melanoma.
5. Other structures commonly seen in SSM include negative network, shiny white lines, atypical dots and globules, irregular blotch, blue-white veil, regression structures, and peripheral brown structureless areas.
6. Shiny white lines correlate with an altered stromal matrix and are suggestive of invasion. This structure can only be seen with polarized light.
7. Negative network is a common structure observed in nevus-associated melanomas.
8. An atypical globular pattern is the hallmark pattern seen in nested melanomas.

References

1. Annessi G, et al. Sensitivity, specificity, and diagnostic accuracy of three dermoscopic algorithmic methods in the diagnosis of doubtful melanocytic lesions: the importance of light brown structureless areas in differentiating atypical melanocytic nevi from thin melanomas. *J Am Acad Dermatol*. May 2007;56(5):759–67. ISSN 1097-6787 (Electronic). 0190-9622 (Linking). Disponível em: http://www.ncbi.nlm.nih.gov/pubmed/17316894.
2. Argenziano G, et al. Dermoscopy of pigmented skin lesions: results of a consensus meeting via the Internet. *J Am Acad Dermatol*. May 2003;48(5):679–93. ISSN 0190-9622 (Print). 0190-9622 (Linking). Disponível em: http://www.ncbi.nlm.nih.gov/entrez/query.fcgi?cmd=Retrieve&db=PubMed&dopt=Citation&list_uids=12734496.
3. Balagula Y, et al. The significance of crystalline/chrysalis structures in the diagnosis of melanocytic and nonmelanocytic lesions. *J Am Acad Dermatol*. Aug 2012;67(2):194.e1–8. ISSN 1097-6787. Disponível em: http://www.ncbi.nlm.nih.gov/pubmed/22030020.
4. Bono A, et al. Clinical and dermatoscopic diagnosis of early amelanotic melanoma. *Melanoma Res*. Oct 2001;11(5):491–4. ISSN 0960-8931 (Print). 0960-8931 (Linking). Disponível em: http://www.ncbi.nlm.nih.gov/pubmed/11595886.
5. Cook MG, et al. New insights into naevoid melanomas: a clinicopathological reassessment. *Histopathology*. Dec 2017;71(6):943–950. ISSN 1365-2559. Disponível em: https://www.ncbi.nlm.nih.gov/pubmed/28741688.
6. Crocetti E, et al. Survival of patients with skin melanoma in Europe increases further: Results of the EUROCARE-5 study. *Eur J Cancer*. Oct 2015;51(15):2179–90. ISSN 1879-0852. Disponível em: https://www.ncbi.nlm.nih.gov/pubmed/26421821.
7. Haenssle HA, et al. Seven-point checklist for dermatoscopy: performance during 10 years of prospective surveillance of patients at increased melanoma risk. *J Am Acad Dermatol*. May 2010;62(5):785–93. ISSN 1097-6787 (Electronic). 0190-9622 (Linking). Disponível em: http://www.ncbi.nlm.nih.gov/pubmed/20226567.
8. _____. Association of patient risk factors and frequency of nevus-associated cutaneous melanomas. *JAMA Dermatol*. Mar 2016;152(3):291–8. ISSN 2168-6084. Disponível em: https://www.ncbi.nlm.nih.gov/pubmed/26536613.
9. Jaimes N, et al. White globules correlate with balloon cell nevi nests. *J Am Acad Dermatol*. Oct 2011;65(4):e119–20. ISSN 1097-6787 (Electronic). 0190-9622 (Linking). Disponível em: http://www.ncbi.nlm.nih.gov/pubmed/21920229.
10. _____. Clinical and dermoscopic characteristics of amelanotic melanomas that are not of the nodular subtype. *J Eur Acad Dermatol Venereol*. May 2012;26(5):591–6. ISSN 1468-3083 (Electronic). 0926-9959 (Linking). Disponível em: http://www.ncbi.nlm.nih.gov/pubmed/21585561.
11. Longo C, et al. Dermoscopy and confocal microscopy of nested melanoma of the elderly: recognizing a newly defined entity. *JAMA Dermatol*. Aug 2013;149(8):941–5. ISSN 2168-6084. Disponível em: https://www.ncbi.nlm.nih.gov/pubmed/23740161.
12. Mar V, et al. Nodular melanoma: a distinct clinical entity and the largest contributor to melanoma deaths in Victoria, Australia. *J Am Acad Dermatol*. Apr 2013;68(4):568–575. ISSN 1097-6787. Disponível em: https://www.ncbi.nlm.nih.gov/pubmed/23182058.
13. Menzies SW, et al. Frequency and morphologic characteristics of invasive melanomas lacking specific surface microscopic features. *Arch Dermatol*. Oct 1996;132(10):1178–82. ISSN 0003-987X (Print) 0003-987X (Linking). Disponível em: http://www.ncbi.nlm.nih.gov/pubmed/8859028.
14. Menzies SW, Ingvar C, Mccarthy WH. A sensitivity and specificity analysis of the surface microscopy features of invasive melanoma. *Melanoma Res*. Feb 1996;6(1):55–62. ISSN 0960-8931 (Print) 0960-8931 (Linking). Disponível em: http://www.ncbi.nlm.nih.gov/pubmed/8640071.
15. Menzies SW, et al. Dermoscopic evaluation of amelanotic and hypomelanotic melanoma. *Arch Dermatol*. Sep 2008;144(9):1120–7. ISSN 1538-3652 (Electronic) 0003-987X (Linking). Disponível em: http://www.ncbi.nlm.nih.gov/pubmed/18794455.

16. Pan Y, et al. Nodular melanoma is less likely than superficial spreading melanoma to be histologically associated with a naevus. *Med J Aust*. Oct 2017;207(8):333–338. ISSN 1326-5377. Disponível em: https://www.ncbi.nlm.nih.gov/pubmed/29020904.
17. Pizzichetta MA, et al. Negative pigment network: an additional dermoscopic feature for the diagnosis of melanoma. *J Am Acad Dermatol*. Apr 2013;68(4):552–9. ISSN 1097-6787. Disponível em: http://www.ncbi.nlm.nih.gov/pubmed/23062610.
18. _____. Amelanotic/hypomelanotic melanoma: clinical and dermoscopic features. *Br J Dermatol*. Jun 2004;150(6):1117–24. ISSN 0007-0963 (Print) 0007-0963 (Linking). Disponível em: http://www.ncbi.nlm.nih.gov/pubmed/15214897.
19. Salopek TG, et al. Differentiation of atypical moles (dysplastic nevi) from early melanomas by dermoscopy. *Dermatol Clin*. Apr 2001;19(2):337–45. ISSN 0733-8635 (Print) 0733-8635 (Linking). Disponível em: http://www.ncbi.nlm.nih.gov/pubmed/11556242.
20. Shaikh WR, Xiong M, Weinstock MA. The contribution of nodular subtype to melanoma mortality in the United States, 1978 to 2007. *Arch Dermatol*. Jan 2012;148(1):30–6. ISSN 1538-3652. Disponível em: https://www.ncbi.nlm.nih.gov/pubmed/21931016.
21. Shitara D, et al. Dermoscopy of Naevus-associated Melanomas. *Acta Derm Venereol*. Jul 2015;95(6):671–5. ISSN 1651-2057. Disponível em: https://www.ncbi.nlm.nih.gov/pubmed/25394499.

8B MELANOCYTIC LESIONS: NODULAR MELANOMA

Natalia Jaimes and Scott W. Menzies

Contents

Key points 187
References 189

Nodular melanomas (NMs) are defined as invasive melanomas without a radial growth phase. Specifically, they lack an in situ component beyond three rete ridges of the invasive vertical growth phase. Thick melanomas (>3 mm Breslow thickness) are predominantly NMs (56%), and while they represent only 14% of invasive melanomas, they are the predominant contributor to melanoma-related deaths.[1, 2]

Clinically, NMs may lack the "ABCD" features more typical of superficial spreading melanomas (SSMs). Similarly, many of the classic dermoscopy features of SSMs (see Chapter 8a) are less common in NMs. In particular, features correlating with radial growth and pagetoid spread (streaks/pseudopods/radial streaming) and those features found in thin melanomas (atypical network and regression features, including multiple blue-gray fine dots or peppering, and scarlike areas) are often lacking in NMs.[3]

NMs can present as pigmented or nonpigmented tumors. Pigmented NMs more frequently reveal features associated with thick melanomas, including blue-white veil, multiple (five–six) colors, shiny white streaks also known as crystalline structures (seen only with polarized light), ulceration, and atypical vascular patterns.[3] In addition, NMs can display a clinically symmetric shape with an asymmetric pigmentation pattern under dermoscopy. However, the asymmetry of pattern may be less marked compared with SSM, and a small percentage of pigmented NMs (5.8%) can show symmetry of pigmentation pattern across all axes.[3] Nevertheless, the majority of pigmented NMs can be diagnosed using standard dermoscopy criteria. Dermoscopic structures that positively correlate with NMs include:[3, 4]

- Areas of homogeneous blue pigmentation
- Asymmetrical pigmentation pattern
- Atypical peripheral black dots/globules with irregular size and distribution
- Blue-white veil
- Pink, blue, or black color
- Atypical vascular structures, including polymorphous vessels, milky-red globules/areas, and homogeneous red areas
- Blue-black structures, defined as the presence of a combination of blue and black pigmented areas involving at least 10% of the lesion surface (sensitivity 78.2%, specificity 80.5%) for the diagnosis of melanoma[5]
- Shiny white structures (shiny white streaks or lines) seen with polarized light[6]

What is diagnostically problematic is the fact that a significant number of NMs are hypomelanotic or amelanotic when compared with invasive non-NM (37.3% vs. 7.5%).[3] In these cases, atypical vascular structures may be the only clues for the diagnosis of such lesions and are indicative of angiogenesis (see Chapter 8e, "Amelanotic Melanoma"). Atypical vessels that are commonly seen in amelanotic/hypomelanotic NMs include linear irregular vessels and hairpin vessels. Milky-red/pink areas are also an important feature of amelanotic/hypomelanotic NM.[3] In addition, thicker melanomas tend to show more peripheral vessels than thin melanomas[3, 7] (Figures 8b.1–8b.7).

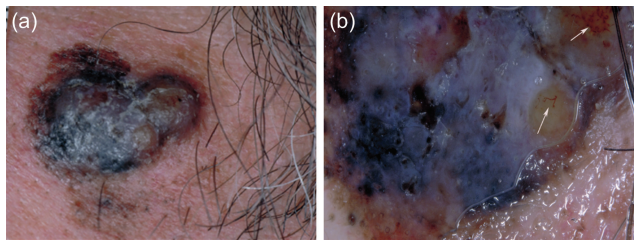

FIGURE 8B.1 (a) Clinical image. (b) This asymmetrically patterned multicolored lesion has the major positive nodular melanoma (NM) features of blue-white veil, multiple (five–six) colors (scored from tan, dark brown, black, blue, gray, and red), ulceration (top arrow), and a hairpin (looped) vessel (lower arrow). Diagnosis: NM within a contiguous nevus, Breslow thickness 3.3 mm.

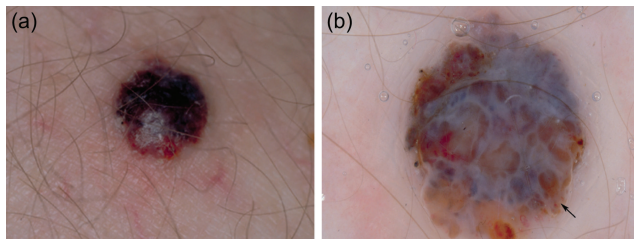

FIGURE 8B.2 (a) Clinical image. (b) Again, this asymmetrically patterned multicolored lesion has extensive blue-white veil and multiple (five–six) colors. The dotted vessels (arrow) indicate its melanocytic origin. Diagnosis: NM, 2.5 mm Breslow thickness.

Key points

1. Nodular melanomas (NMs) lack network, streaks, and regression structures.

DOI: 10.1201/9780429487873-24

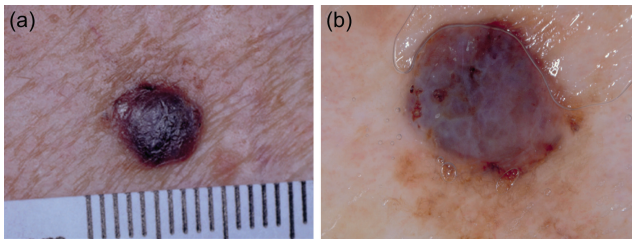

FIGURE 8B.3 (a) Clinical image. (b) The nodule in this lesion is asymmetrically patterned and multicolored with the positive melanoma feature of extensive blue-white veil. Here, asymmetry of pattern is definitely seen (see Chapter 6b) but is less marked than in many superficial spreading melanomas. Diagnosis: Nodular melanoma, 1.6 mm Breslow thickness with a contiguous area of atypical lentiginous proliferation of melanocytes.

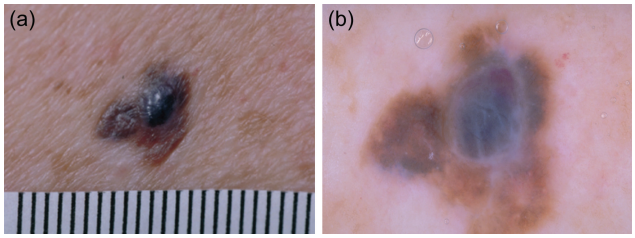

FIGURE 8B.4 (a) Clinical image. (b) This superficial spreading melanoma (SSM) has a distinct nodular component (1.7 mm Breslow thickness) within the center of the lesion. When only the nodular component is considered, asymmetry of the pigmentation pattern is present but again, less marked than in most SSMs. The presence of blue-white veil remains the defining feature of this nodular component.

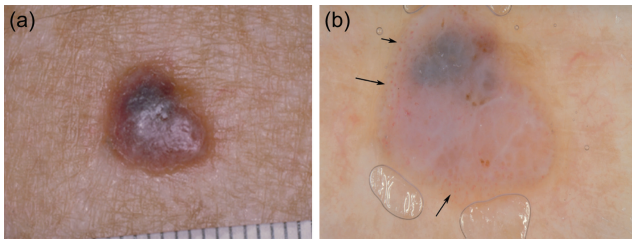

FIGURE 8B.5 (a) Clinical image. (b) This hypomelanotic nodule is multicolored (tan, blue, and red) and has an asymmetric pattern. Note the few but obvious brown globules and widespread dotted (pin-point) vessels (arrows), both indicative of its melanocytic origin. It also has the positive melanoma features of blue-white veil and scarlike depigmentation. Diagnosis: NM, 2.2 mm Breslow thickness.

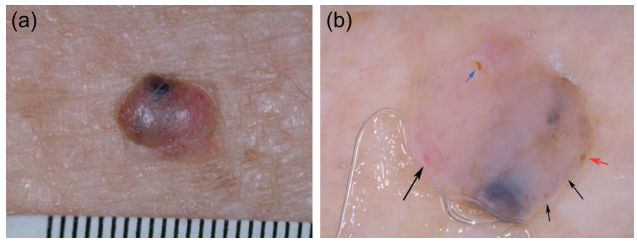

FIGURE 8B.6 (a) Clinical image. (b) This hypomelanotic nodule is asymmetric in pattern and is multicolored (tan, red, blue). While it has features of a pigmented basal cell carcinoma (BCC) with large blue-gray ovoid nests and ulceration (blue arrow), it lacks arborizing vessels typical of BCC. Instead, it has a solitary brown globule (red arrow) and dotted vessels (thin black arrows) indicative of a melanocytic lesion. Furthermore, it has a milky-red globule (thick black arrow), which is a specific feature of melanoma. Diagnosis: Hypomelanotic NM, Breslow thickness 1.9 mm.

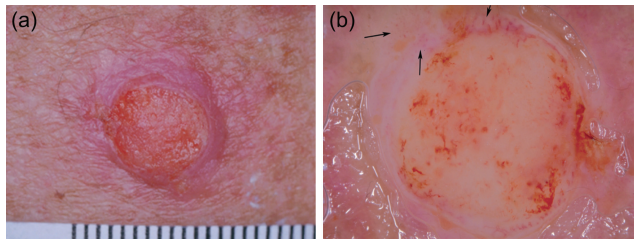

FIGURE 8B.7 (a) Clinical image. (b) This ulcerated amelanotic nodule has dotted (pin-point) vessels suggestive of a melanocytic lesion. Diagnosis: NM, Breslow thickness 2.8 mm.

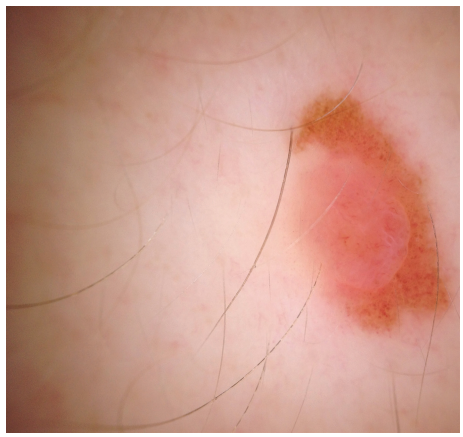

FIGURE 8B.8 Nodular melanoma arising on a nevus. Dermoscopy reveals atypical vessels over a pink background within a small papule.

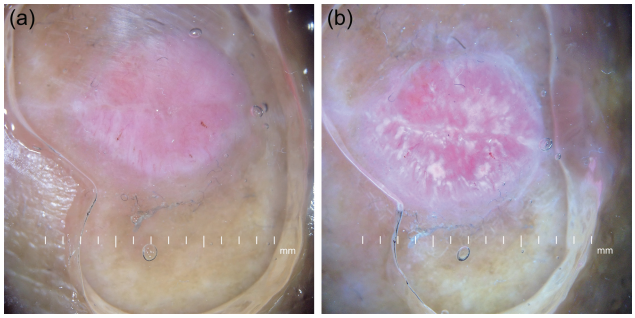

FIGURE 8B.9 Non-polarized (a) and polarized dermoscopy (b) of a nodular amelanotic melanoma demonstrating atypical vessels over a pink background, including hairpin vessels; and shiny white structures observed with polarized light only.

2. Pigmented NMs often manifest blue-white veil, multiple colors, shiny white structures, and atypical vessels.
3. Amelanotic NMs reveal atypical vessels and/or shiny white streaks.
4. The dermoscopic pattern of NM is often homogeneous disorganized (dermoscopically asymmetric) or featureless with atypical vessels (Figures 8b.8 and 8b.9).

References

1. Mar V, Roberts H, Wolfe R, English DR, Kelly JW. Nodular melanoma: a distinct clinical entity and the largest contributor to melanoma deaths in Victoria, Australia. *J Am Acad Dermatol*. 2013;68(4):568–75.
2. Chamberlain AJ, Fritschi L, Giles GG, Dowling JP, Kelly JW. Nodular type and older age as the most significant associations of thick melanoma in Victoria, Australia. *Arch Dermatol*. 2002;138(5):609–14.
3. Menzies SW, Moloney FJ, Byth K, et al. Dermoscopic evaluation of nodular melanoma. *JAMA Dermatol*. 2013;149(6):699–709.
4. Pizzichetta MA, Kittler H, Stanganelli I, et al. Pigmented nodular melanoma: the predictive value of dermoscopic features using multivariate analysis. *Br J Dermatol*. 2015;173(1):106–14.
5. Argenziano G, Longo C, Cameron A, et al. Blue-black rule: a simple dermoscopic clue to recognize pigmented nodular melanoma. *Br J Dermatol*. 2011;165(6):1251–5.
6. Kalkhoran S, Milne O, Zalaudek I, et al. Historical, clinical, and dermoscopic characteristics of thin nodular melanoma. *Arch Dermatol*. 2010;146(3):311–8.
7. Menzies SW, Kreusch J, Byth K, et al. Dermoscopic evaluation of amelanotic and hypomelanotic melanoma. *Arch Dermatol*. 2008;144(9):1120–7.

8C MELANOCYTIC LESIONS: LENTIGO MALIGNA OR LENTIGINOUS MELANOMA ON SUN-DAMAGED SKIN

Rachel Fayne and Natalia Jaimes

Contents

Introduction 190
Chronically sun-damaged skin 190
Melanomas on sun-damaged skin 190
Dermoscopic findings of melanomas on CSDS 190
Dermoscopic structures of melanomas on facial skin with CSDS 191
Dermoscopic structures of melanoma on nonfacial CSDS 192
Differential diagnoses 192
Conclusion 194
Key points 194
References 195

Introduction

Exposure to ultraviolet radiation, from artificial and natural sources (i.e., tanning beds, sun), results in a wide array of skin changes, including hyper- and hypopigmentation, mottled pigmentation, and poikiloderma (defined as hypopigmentation, hyperpigmentation, telangiectasias, and atrophy).[1] For this chapter, all these changes will be grouped under the name of chronically sun-damaged skin (CSDS). Patients with CSDS present with varied skin lesions, ranging from lentigines, seborrheic keratoses (SK), and actinic keratoses (AK) to malignant neoplasms such as melanoma and nonmelanoma skin cancers. Differentiation between benign and malignant lesions on CSDS is often a challenge based on clinical features alone, given that many of them share features that significantly overlap and often co-exist.[2–4] Dermoscopy has proven useful in distinguishing between benign and malignant lesions on CSDS. However, given the histological characteristics and anatomic sites, dermoscopic features can appear different on a background of CSDS compared with skin without sun damage.[2] Therefore, it is essential to be aware of these differences in order to accurately detect and diagnose skin tumors on CSDS.[5] In this chapter, we describe the clinical and dermoscopic features of melanomas on CSDS, including lentigo maligna (LM).

Chronically sun-damaged skin

Histologic changes due to ultraviolet radiation are evident in the epidermis and dermis. Epidermal changes include a compacted stratum corneum that may contain vesicles of proteinaceous material, flattening of the rete ridges, cell heterogeneity, vacuolization, reduced number of Langerhans cells, dysplasia, and zonal necrosis.[6] The dermis of CSDS demonstrates changes consistent with solar elastosis, including amorphous material and evidence of fiber breakdown, with scattered macrophages and coarse granules.[6] These histologic changes can be apparent clinically and correlate with the findings observed under dermoscopy. For example, on facial skin with chronic sun exposure, effacement of the epidermis allows easier visualization of vascular structures and melanophages; the flattening of the rete ridges results in the absence of a pigment network and visualization of a pseudonetwork due to the high density of pilosebaceous units and adnexal openings.

Melanomas on sun-damaged skin

Melanomas appearing on a background of CSDS can be of any histologic subtype, including LM, superficial spreading melanoma (SSM), nodular melanoma, or desmoplastic melanoma (DM), among others.[5] However, in patients with CSDS, lentigo maligna or lentiginous melanoma on sun-damaged skin (in this chapter, both will be referred to as LM) is the most common subtype of melanoma, followed by SSM.[2 5]. LM is a slow-growing melanoma that can arise on facial and nonfacial skin.[5] LM refers to the in situ form, also referred to as Hutchinson melanotic freckle. Approximately 5% of LM cases may progress to an invasive melanoma, also called LM melanoma (LMM).[7,8,9] Melanomas arising on a background of CSDS are genetically different from those arising on intermittently sun-exposed skin.[10] Patients with CSDS are more likely to harbor KIT mutations (25–28%) and infrequent BRAF mutations (11–20%); in contrast, patients without CSDS frequently demonstrate BRAF mutations (50–80%) and rarely KIT mutations (0–2%). [10–12]

Melanomas on CSDS are often found on the face, back, and upper extremities as brown outlier macules.[5] Usually, these melanomas display two to four colors, most often light brown, dark brown, and pink. Borders are frequently poorly defined, and size is variable, with an average of 9 mm.[2] Although the background skin may contain multiple lentigines and SKs, melanomas on CSDS often appear as isolated, relatively large lentiginous macules that are outlier lesions on visual inspection.[2] This is a useful clinical aid, because the identification of an outlier lesion typically triggers further examination with dermoscopy, which ultimately leads to the identification of features indicative of melanoma.

Dermoscopic findings of melanomas on CSDS

Any pigmented lesion on facial or nonfacial CSDS should first be examined for the presence of any of the melanoma-specific structures discussed in Chapters 8a–8f,[13] including atypical network (Figures 8c.1 - 8c.3), negative network (Figure 8c.4),

atypical dots or globules (Figures 8c.2, 8c.5, 8c.6), blue-white veil (Figure 8c.7), off-centered blotch (Figure 8c.7), shiny white structures (Figure 8c.3), peripheral streaks, and atypical vascular structures (Figures 8c.3, 8c.5). If the lesion does not demonstrate any of these melanoma-specific structures, there is a different set of features that should raise concern for melanomas on CSDS.[13, 14]

Dermoscopic structures of melanomas on facial skin with CSDS (Table 8c.1) (See Chapter 11a)

Although the following dermoscopic features are more commonly seen in melanomas on facial CSDS (Chapter 11a), it is not uncommon to also observe them in melanomas on nonfacial CSDS (Figures 8c.3, 8c.8).

- Annular-granular pattern, formed by slate-gray dots and granules surrounding the adnexal openings (Figures 8c.3, 8c.7)
- Asymmetric follicular openings, consisting of an asymmetric distribution of color (tan-brown to gray) surrounding follicular openings (Figures 8c.7, 8c.8)
- Concentric isobar pattern, also known as circle within a circle
- Angulated lines (i.e., zig-zag pattern, polygons, and rhomboidal structures), defined as multiple, confluent grayish to brown lines forming polygonal shapes around and in between follicular openings (Figures 8c.3, 8c.7, 8c.8)

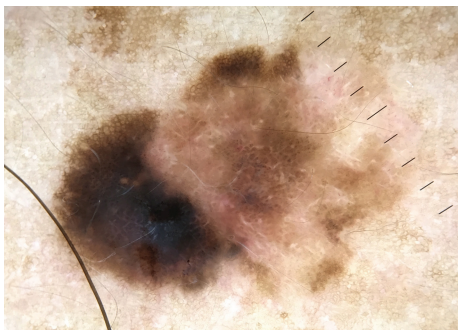

FIGURE 8C.1 Superficial spreading melanoma 0.45 mm on upper back. Dermoscopy demonstrates atypical network, peripheral tan structureless areas, off-centered blotch, and shiny white structures.

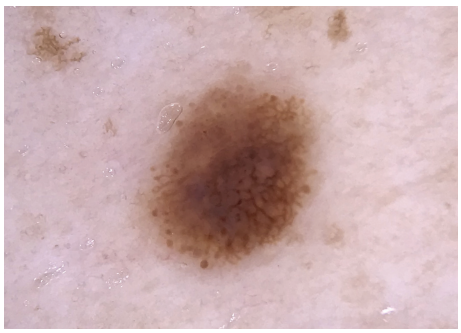

FIGURE 8C.2 Melanoma in situ on the back of a female patient with chronically sun-damaged skin. Dermoscopy image reveals atypical globules, peripheral tan structureless areas, and atypical network.

- Homogeneous darkly pigmented areas with preservation of the adnexal openings, defined as dark brown, gray, or black pigmentation around adnexal openings (Figures 8c.7, 8c.8)
- Homogeneous darkly pigmented areas with follicular or adnexal obliteration, defined as dark brown, gray, or black pigmentation or blotch with loss of the adnexal openings

Angulated lines, defined as brown to grayish (rarely black) lines meeting at angles (i.e., zig-zag pattern, rhomboidal structures, polygonal lines) and coalescing to form polygonal structures such as rhomboids. The lines can be formed by confluent granules or dots, and this may at times be the only criteria present to indicate malignancy.[15, 16, 19] Early signs of angulated lines in association with asymmetric follicular openings, granularity, or dots aggregated around the hair follicles comprise the earliest stage in the progression model for LM. As the lesion progresses, the associated dermoscopic features of asymmetric follicular openings and angulated lines are replaced by homogeneous dark areas or blotches with obliteration of adnexal openings.[15]

While the presence of multiple features such as granularity, angulated lines, and asymmetric follicular openings increases specificity for the diagnosis of LM, the most sensitive feature is the presence of dermoscopic gray color.[15, 20]

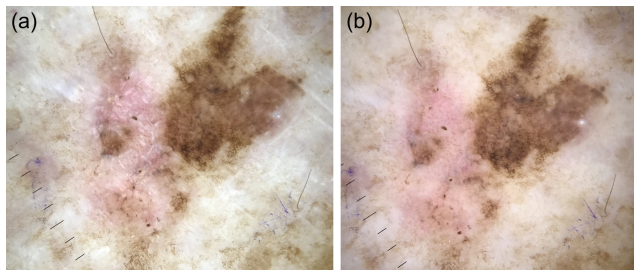

FIGURE 8C.3 Melanoma in situ on the left thigh of a female patient with chronically sun-damaged skin. Polarized (a) and non-polarized (b) dermoscopy reveals atypical network, focal areas with angulated lines, dotted vessels, and shiny white lines only seen with polarized light (a).

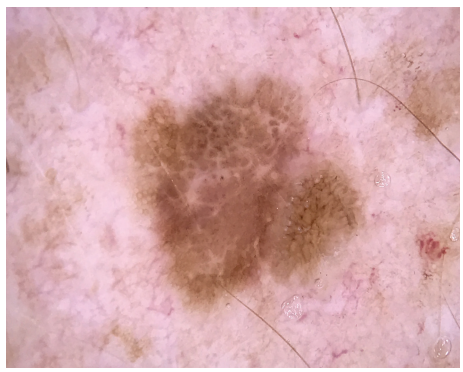

FIGURE 8C.4 Melanoma in situ on the back of a male patient with chronically sun-damaged skin. Dermoscopy reveals negative network and peripheral structureless areas. This was a collision tumor between a melanoma in situ and a seborrheic keratosis.

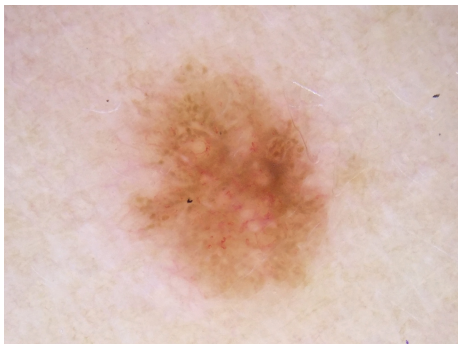

FIGURE 8C.5 Melanoma 0.4 mm on the back of a female patient with chronically sun-damaged skin. This was a dermoscopically outlier lesion, revealing atypical globules, peripheral tan structureless areas, and atypical vessels (i.e., dotted and lineal irregular vessels).

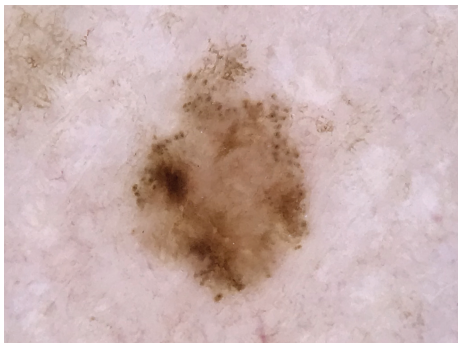

FIGURE 8C.6 Melanoma in situ on the back of a female patient with chronically sun-damaged skin. This was a dermoscopically outlier lesion, revealing atypical globules and peripheral tan structureless areas.

Dermoscopic structures of melanoma on nonfacial CSDS (Table 8c.1)

In addition to the structures mentioned seen on facial skin, three dermoscopic patterns can be seen in up to 78% of melanomas on nonfacial CSDS[2]:

- Patchy peripheral pigmented island pattern. This pattern consists of peripheral islands of pigment or structureless areas, which are usually distributed at the periphery in a disorganized manner (Figure 8c.9).
- Areas with regression consisting primarily of gray dots (granularity pattern) (Figure 8c.10).
- Angulated lines pattern. This pattern is formed by coalescing angulated lines, creating zig-zag lines and polygons (Figure 8c.11).

It is always advisable to palpate any skin lesion on CSDS with suspicious features for melanoma, including LM, in order to detect any firm subcutaneous component that may suggest the presence of a DM. DMs (see Chapter 8e) also have a predilection for sun-exposed skin, particularly the head and neck, and are often associated with an overlying LM.[21] Data suggest that in approximately 83% of cases of DM, the DM is associated with another melanoma subtype involving epidermis, most frequently LM, followed by SSM[21, 22] (Chapter 8e).

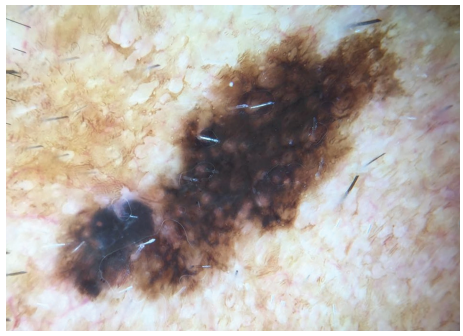

FIGURE 8C.7 Melanoma on facial skin. Dermoscopy shows angulated lines as the predominant dermoscopic structures, and also blue-white-veil and an off-centered blotch.

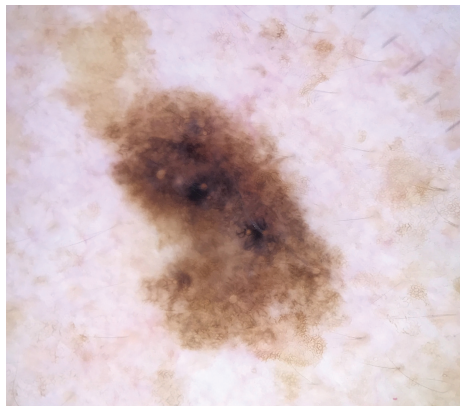

FIGURE 8C.8 Melanoma in situ on the upper back of a male patient. Dermoscopy reveals asymmetric follicular openings with an asymmetric distribution of color surrounding follicular openings; homogeneous darkly pigmented areas with preservation of the adnexal openings; and structureless tan peripheral areas.

Differential diagnoses

Considering all lesions that are part of the differential diagnosis of LM is important, since lesions on CSDS that do not display diagnostic features of LM and also do manifest any of the diagnostic features of AK, lentigo, SK, or lichen planus–like keratosis (LPLK) should still be viewed as potential LM.

- *Pigmented actinic keratosis*

Pigmented actinic keratosis (PAK) can also reveal an annular-granular pattern and structures resembling angulated lines. However, unlike LM, the follicular openings in AK tend to be prominent, large, and white in color, often revealing multiple rosettes when viewed with polarized dermoscopy. The lines tend to have a brownish color and correspond with adherent scale, and thus, these lesions have a rough texture on palpation, in contrast to LM, which tends to have a smooth surface. The borders of an AK tend to be scalloped, and the intrafollicular space is often erythematous, resulting in the so-called strawberry pattern. Additionally, the presence of an inner gray halo is associated with PAK, and this may be another useful clue[23] (Chapter 6c).

TABLE 8C.1: Dermoscopic structures seen in melanomas on facial and nonfacial sun-damaged skin. [2, 4, 15–17]

Dermoscopic structure	Definition
Follicular/peri-adnexal granularity 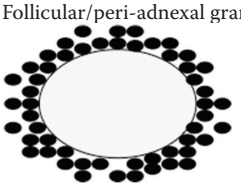	Dots, gray to brown in color, aggregated around hair follicles or adnexal openings.
Asymmetric perifollicular openings 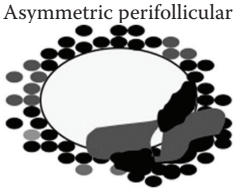	Dots, usually gray in color, aggregated around hair follicles in an asymmetric fashion.[15]
Angulated lines 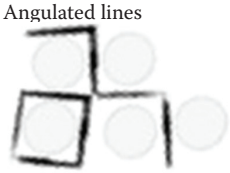	Confluent gray to brown fine dots forming straight lines that meet at angles. Includes rhomboidal structures,[15] zig-zag lines, and large polygonal structures.
Follicle/adnexal openings obliteration 	Rhomboidal structures become broader, obliterating hair follicles or adnexal openings.
Circle within a circle (isobar pattern) 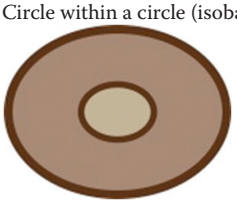	Concentric pigmented rings encircling each other.
Dermoscopic Patterns seen in CSDS[18]	
Patchy peripheral pigmented islands 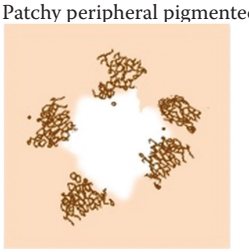	Focal islands of pigmentation located towards the periphery of the lesion. Towards the center, scarlike areas or hypopigmented areas are seen with or without the presence of shiny white structures and/or vascular blush. "Islands of pigment" can consist of reticular or structureless areas.
Angulated line pattern 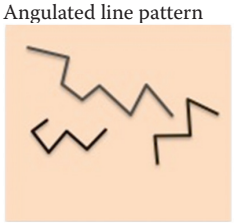	Lesions with angulated lines, with or without the presence of other structures (i.e., granularity or circle within a circle).
Tan structureless and granularity pattern 	Lesions with tan structureless areas and granularity.

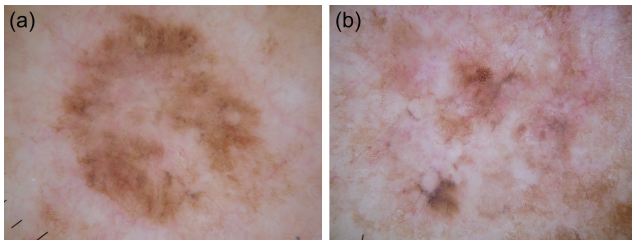

FIGURE 8C.9 (a, b) Melanomas on CSDS demonstrating a patchy peripheral pigmented islands pattern. (Images courtesy of Harold Rabinovitz, MD.)

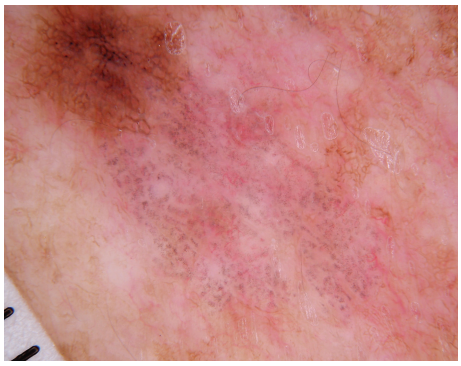

FIGURE 8C.10 Melanoma on the chest demonstrating a tan structureless area with granularity pattern. (Image courtesy of Harold Rabinovitz, MD.)

- *Solar lentigo and flat seborrheic keratosis*

Solar lentigines and flat SKs rarely manifest any of the features associated with LM. Dermoscopic features commonly found in these lesions include fingerprint-like structures, moth-eaten borders, well-demarcated borders, gyri and sulci, and symmetric brown perifollicular/adnexal openings. The brown color surrounding the adnexal openings tends to have the same hue as the surrounding fingerprint-like lines. The presence of the aforementioned features and lack of any of the melanoma-specific structures associated with LM imply a very low likelihood of LM[20] (Chapter 6e).

- *LPLK*

LPLK represents regressing epidermal lesions such as SKs and solar lentigines. These lesions usually contain abundant dermal melanophages and free melanin, which are seen on dermoscopy as gray dots/granules (peppering)[24]. These granules often differ from regression structures seen in LM in that they seem clumped, forming coarse-appearing granules, in LPLK, whereas in LM, they appear as fine gray dots. However, despite some subtle morphologic differences in the granules, the presence of these gray dots/granules may make it difficult to differentiate these lesions from melanoma. There are a few clues that may help. First, involution of lentigo/SK usually occurs from the edge, moving centripetally. In presumed lentigo or SK that reveals regression structures in its center, the appearance of peppering expanding centrifugally should raise concern, since this is a feature more often associated with melanoma or with melanoma arising in an SK. Second, in lesions that have not yet fully involuted, classic features of lentigo/SK can usually still be seen at the edge opposite or lateral to the area of granularity. Third, besides peppering, no other melanoma-specific structures should be visible in an LPLK. Lastly, LPLK often will have an overall orange hue as opposed to brown hues seen in LM.[25] It should be underscored that while the aforementioned clues may assist in differentiating some LPLKs from LM, more often than not, it will remain challenging to discriminate LPLK from LM with confidence, and in such lesions, a biopsy is recommended (Chapter 6e).

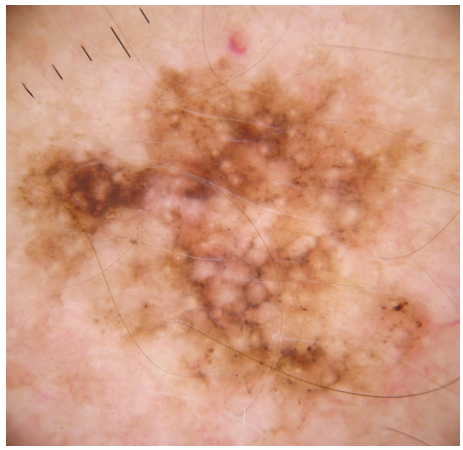

FIGURE 8C.11 Melanoma on the chest demonstrating an angulated pattern. (Image courtesy of Harold Rabinovitz, MD.)

Conclusion

Although the clinical morphology of benign and malignant lesions on CSDS overlaps, dermoscopy has proven useful in their differentiation. Lesions on facial and nonfacial CSDS that present with fine gray granularity, asymmetric perifollicular openings, angulated lines, concentric isobars, also known as a circle within a circle, and homogeneous darkly pigmented areas, with and without preservation of the adnexal openings, should always raise suspicion for LM. Lesions on CSDS revealing a patchy peripheral pigmented islands pattern, a regression structure pattern, or a pattern composed of angulated lines should also raise suspicion for melanoma.

Key points

- Angulated lines are a significant finding for the diagnosis of melanomas on CSDS, including LM, and may be the only criteria present to indicate malignancy.
- The presence of gray color is a clue that should raise suspicion for LM, although it may also be present in LPLK and PAK.
- Findings of asymmetric pigmented follicular openings, fine granularity, and peripheral islands of pigmentation should raise suspicion for melanomas on CSDS.
- Always palpate skin lesions on CSDS with suspicious features for melanoma, including LM, in order to detect any firm subcutaneous component that may suggest the presence of desmoplastic melanoma.

References

1. Zalaudek I, Cota C, Ferrara G, et al. Flat pigmented macules on sun-damaged skin of the head/neck: junctional nevus, atypical lentiginous nevus, or melanoma in situ? *Clin Dermatol*. 2014;32(1):88–93.
2. Jaimes N, Marghoob AA, Rabinovitz H, et al. Clinical and dermoscopic characteristics of melanomas on nonfacial chronically sun-damaged skin. *J Am Acad Dermatol*. 2015;72(6):1027–35.
3. Lau YN, Affleck AG, Fleming CJ. Dermatoscopic features of extrafacial lentigo maligna. *Clin Exp Dermatol*. 2013;38(6):612–6.
4. Keir J. Dermatoscopic features of cutaneous nonfacial nonacral lentiginous growth pattern melanomas. *Dermatol Pract Concept*. 2014;4(1):77–82.
5. Higgins HW, 2nd, Lee KC, Galan A, Leffell DJ. Melanoma in situ: part I. Epidemiology, screening, and clinical features. *J Am Acad Dermatol*. 2015;73(2):181–190, quiz 191–182.
6. Montagna W, Kirchner S, Carlisle K. Histology of sun-damaged human skin. *J Am Acade Dermatol*. 1989;21(5 Pt 1):907–918.
7. McGovern VJ, Mihm MC, Jr., Bailly C, et al. The classification of malignant melanoma and its histologic reporting. *Cancer*. 1973;32(6):1446–57.
8. Weinstock MA, Sober AJ. The risk of progression of lentigo maligna to lentigo maligna melanoma. *Br J Dermatol*. 1987;116(3):303–10.
9. Greveling K, Wakkee M, Nijsten T, van den Bos RR, Hollestein LM. Epidemiology of Lentigo Maligna and Lentigo Maligna Melanoma in the Netherlands, 1989–2013. *J Invest Dermatol*. 2016;136(10):1955–60.
10. Curtin JA, Fridlyand J, Kageshita T, et al. Distinct sets of genetic alterations in melanoma. *N Engl J Med*. 2005;353(20):2135–47.
11. Curtin JA, Busam K, Pinkel D, Bastian BC. Somatic activation of KIT in distinct subtypes of melanoma. *J Clin Oncol*. 2006;24(26):4340–6.
12. Stadelmeyer E, Heitzer E, Resel M, Cerroni L, Wolf P, Dandachi N. The BRAF V600K mutation is more frequent than the BRAF V600E mutation in melanoma in situ of lentigo maligna type. *J Invest Dermatol*. 2014;134(2):548–50.
13. Jaimes N, Marghoob AA. The morphologic universe of melanoma. *Dermatol Clin*. 2013;31(4):599–613, viii–ix.
14. Mataca E, Migaldi M, Cesinaro AM. Impact of dermoscopy and reflectance confocal microscopy on the histopathologic diagnosis of lentigo maligna/lentigo maligna melanoma. *Am J Dermatopathol*. 2018;40(12):884–9.
15. Schiffner R, Schiffner-Rohe J, Vogt T, et al. Improvement of early recognition of lentigo maligna using dermatoscopy. *J Am Acad Dermatol*. 2000;42(1 Pt 1):25–32.
16. Slutsky JB, Marghoob AA. The zig-zag pattern of lentigo maligna. *Arch Dermatol*. 2010;146(12):1444.
17. Cognetta AB, Jr., Stolz W, Katz B, Tullos J, Gossain S. Dermatoscopy of lentigo maligna. *Dermatol Clin*. 2001;19(2):307–18.
18. Jaimes N, Marghoob AA, Rabinovitz H, et al. Clinical and dermoscopic characteristics of melanomas on nonfacial chronically sun-damaged skin. *J Am Acad Dermatol*. 2015;72(6):1027–35.
19. Vanden Daelen A, Ferreira I, Marot L, Tromme I. A digital dermoscopy follow-up illustration and a histopathologic correlation for angulated lines in extrafacial Lentigo Maligna. *JAMA Dermatol*. 2016;152(2):200–3.
20. Carbone A, Ferrari A, Paolino G, et al. Lentigo maligna of the face: a quantitative simple method to identify individual patient risk probability on dermoscopy. *Australas J Dermatol*. 2017;58(4):286–91.
21. Nicolson NG, Han D. Desmoplastic melanoma. *J Surg Oncol*. 2019;119(2):208–15.
22. Jaimes N, Chen L, Dusza SW, et al. Clinical and dermoscopic characteristics of desmoplastic melanomas. *JAMA Dermatol*. 2013;149(4):413–21.
23. Nascimento MM, Shitara D, Enokihara MM, Yamada S, Pellacani G, Rezze GG. Inner gray halo, a novel dermoscopic feature for the diagnosis of pigmented actinic keratosis: clues for the differential diagnosis with lentigo maligna. *J Am Acade Dermatol*. 2014;71(4):708–15.
24. Lallas A, Argenziano G, Moscarella E, Longo C, Simonetti V, Zalaudek I. Diagnosis and management of facial pigmented macules. *Clin Dermatol*. 2014;32(1):94–100.
25. Liopyris K, Navarrete-Dechent C, Dusza SW, et al. Clinical and dermoscopic features associated with lichen planus-like keratoses that undergo skin biopsy: a single-center, observational study. *Australas J Dermatol*. May 2019;60(2):e119–26. doi:10.1111/ajd.12955

8D MELANOCYTIC LESIONS: ACROLENTIGINOUS MELANOMA

Ralph P. Braun, Susana Puig, and Josep Malvehy

Contents

Introduction . . . 196
Anatomy of palms and soles . . . 196
Malignant dermoscopy patterns on glabrous skin . . . 196
Parallel ridge pattern . . . 196
Diffuse pigmentation with variable shades of brown color and serrated pattern . . . 196
Atypical fibrillar pattern . . . 197
Milky-red pattern . . . 197
Multicomponent pattern . . . 197
ALM with focal benign patterns . . . 197
Size matters . . . 197
Algorithms . . . 197
Key points . . . 201
References . . . 201

Introduction

The skin on palms and soles has a unique anatomy due to the presence of alternating furrows and ridges, which creates the individualized dermatoglyphic patterns or fingerprints (Figure 8d.1). The knowledge of the particular histologic anatomy of palms and soles facilitates the comprehension of the significance of dermoscopic colors, structures, and patterns associated with benign and malignant lesions in these locations. In this chapter, we will cover the dermoscopy criteria of melanomas located on the volar aspect of the palms and soles.

Anatomy of palms and soles

The unique microanatomy of the skin of the palms and soles is described in detail in Chapter 11b. The key observation that has helped clinicians differentiate nevi from melanoma with dermoscopy is that pigment is more prominently distributed in the furrows (sulcus superficialis) of nevi and on the ridges (crista superficialis) in melanoma (Figure 8d.2). Analyzing vertical histology sections oriented perpendicular to the dermatoglyphic lines sheds light on why the pigment is distributed in parallel lines and why nevi favor the furrows and melanoma the ridges. In melanocytic nevi, the location of the pigment tends to favor the crista limitans, which corresponds to the furrows of the skin (1, 2). Interestingly, while nevomelanocytic nests in nevi on volar skin may be located at the tips of the rete ridges associated with the crista intermedia and limitans, the ones located along the crista limitans preferentially transfer melanin to the keratinocytes, resulting in the observed parallel furrow pattern seen in nevi (2–4). In contrast, in early melanoma, the malignant melanocytes tend to favor growth in the environment surrounding the crista intermedia, perhaps due to the fact that melanocytic stem cells reside in the same environment. The end result is that melanomas will often reveal pigmentation on the ridges (Figures 8d.1 and 8d.2) (5–7). The dermoscopic patterns observed in benign lesions located on volar skin are described in Chapter 11b.

Malignant dermoscopy patterns on glabrous skin (8, 9) (Figure 8d.3)

Parallel ridge pattern

The most common and specific dermoscopic finding in early (including in situ) acrolentiginous melanoma (ALM) is the presence of a parallel ridge pattern with a specificity of 99%, sensitivity of 86%, and a positive predictive value of 84% (5, 10–12). The parallel ridge pattern consists of linear pigmentation located predominantly on the ridges (Figures 8d.4–8d.9). This pattern is typically located in the macular portions of melanomas on volar skin and can be seen in both in situ and invasive melanomas. However, in melanoma in situ, the lesion will usually display only tan to brown lines without any other colors or visible structures. Invasive melanomas can also display pigmentation on the ridges, but it will rarely be the only feature seen, and it will rarely manifest only tan to brown ridges (see multicomponent pattern later) (13). While the ridge pattern should always raise suspicion for melanoma, it is important to underscore that exceptions to this rule exist. Benign volar lesions found in patients with darker skin (ethnic pigmentation), Peutz–Jeghers syndrome, and Laugier–Hunziker syndrome can display a parallel ridge pattern (14–17) (Figure 8d.10). In addition, chemotherapy-induced volar pigmentation, exogenous dye, and subcorneal blood (see Chapter 11b) can also manifest with a parallel ridge pattern (Figures 8d.11-8d.13) (18–22). Lastly, congenital nevi can also occasionally display a ridge pattern.

Diffuse pigmentation with variable shades of brown color and serrated pattern

The second most common pattern seen in ALM is the diffuse pigmentation with variable shades of brown (9). This pattern consists of structureless diffuse pigmentation that involves both the ridges and furrows and displays various shades of brown color (Figures 8d.7 and 8d.14) and can be seen in both in situ and invasive ALMs. Another feature occasionally encountered in ALM is the serrated pattern (Figure 8d.15), which consists of projections (similar to streaks) at the edge of the tumor.

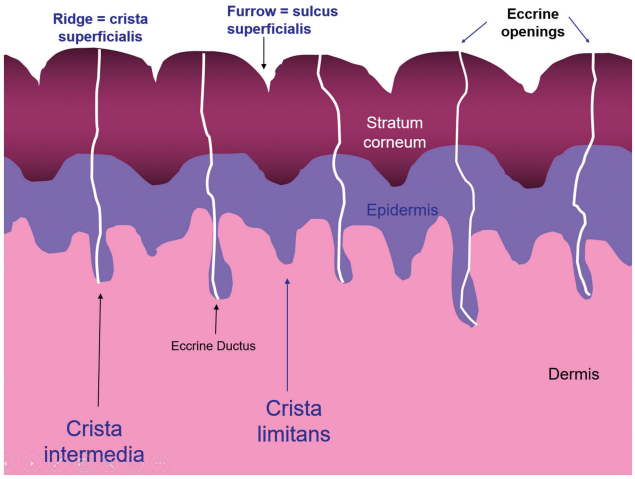

FIGURE 8D.1 Schematic representation of the anatomy of volar skin.

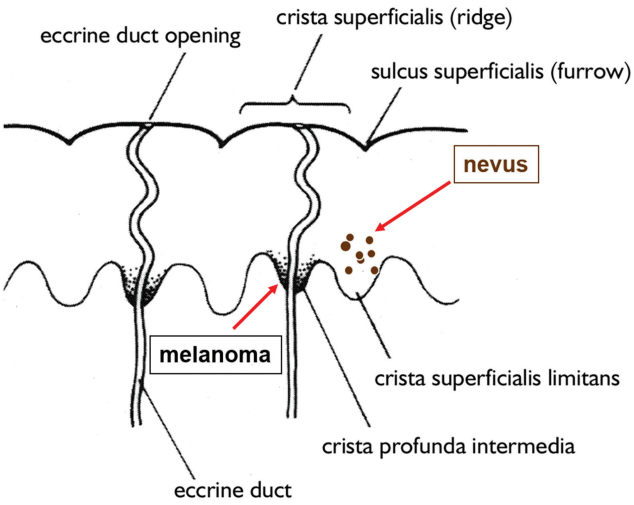

FIGURE 8D.2 Volar nevi tend to transfer pigment to keratinocytes associated with the crista limitans, which results in a visible parallel furrow pattern. ALM tends to cluster around the crista intermedia, which results in a visible parallel ridge pattern.

Atypical fibrillar pattern

The explanation of the mechanical frictional forces responsible for creating the fibrillar pattern is described in Chapter 11b. Since constant frictional pressure is required to form the fibrillar pattern, any lesion on the palms displaying a fibrillar pattern should be considered atypical unless there are extenuating circumstances to account for constant frictional forces being applied to the palm/s, resulting in the conversion of a parallel furrow pattern nevus into a fibrillar pattern nevus. On plantar skin, an atypical fibrillar pattern (type B) is when the fibrillar lines display increased variability in their color and thickness and when they are distributed in a disorganized manner (10, 23–27). In addition, fibrillar lines with a gray color should always be considered atypical (9, 19).

Milky-red pattern

This pattern is defined by the presence of homogeneous reddish/whitish colors. This is mainly seen in thicker melanomas that have a nodular component that is vascularized.

Multicomponent pattern

The multicomponent pattern consists of multiple patterns present focally within the lesion, including focal presence of a parallel ridge pattern, furrow pattern, or fibrillar pattern. The focal ridge pattern tends to be found at the periphery of the melanoma. In addition, invasive melanomas will often manifest structureless diffuse pigmented areas with multiple colors, ranging from brown to red, blue-white, and black, and multiple structures, including irregular dots and globules, streaks (serrated edge), irregular blotches, blue-white veil, regression structures, and atypical vessels (Figures 8d.16 and 8d.17).

ALM with focal benign patterns

Melanoma on volar skin may display patterns associated with nevi, including the parallel furrow and lattice-like pattern; however, these patterns will be present only focally within the melanoma, with the rest of the lesion displaying malignant patterns such as pigmentation on the ridges, diffuse pigmentation with variable shares of colors, and atypical fibrillar pattern. Thus, when evaluating lesions on volar skin, it is imperative to first search for malignant patterns within the entire surface area of the lesion and not to prematurely anchor the diagnosis based on the focal presence of a benign pattern. In other words, malignant patterns trump benign patterns.

Size matters

Most acquired nevi on volar skin will be under 7 mm in greatest diameter. Acquired melanocytic lesions on volar skin that are greater than 7 mm in greatest diameter should raise suspicion for melanoma, independently of the dermoscopic features displayed by the lesion (1).

Algorithms

Most lesions on the palms and soles will manifest a pattern that will allow the observer to confidently classify the lesion as benign or malignant. However, some lesions will not display one of the typical dermoscopy patterns described for nevi and melanomas. Mikoshiba et al. have shown that in such lesions, the presence of asymmetry in the distribution of colors and structures, the presence of more than two colors, blue-white structures, vessels, dots, streaks, or abrupt edges should raise concern for melanoma (28). In addition, the authors mentioned that context (age, size, and location) should not be ignored when trying to differentiate nevi from melanomas.

Lallas et al. created the BRAAFF algorithm (10) to assist clinicians in analyzing volar lesions (Table 8d.1). This algorithm has both positive and negative criteria;, with each criterion having a different score based on the strength of its association with nevi or melanoma. If the sum of all individual criterion scores adds up to more then, the lesion should be considered suspicious for melanoma.

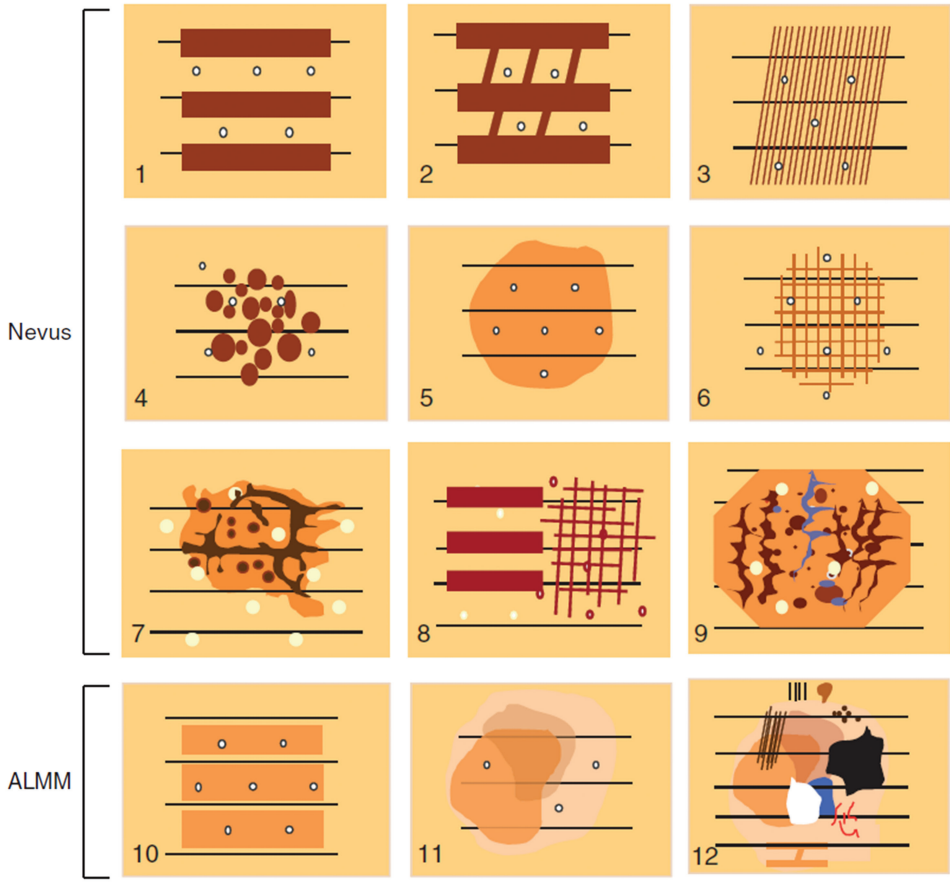

FIGURE 8D.3 Schematic representation of benign and malignant patterns encountered on volar skin. **Benign patterns***: *Parallel furrow pattern* (1): pigmentation following the furrows; *Lattice-like pattern* (2): pigmentation following the furrows plus linear bands of pigment crossing over the ridge from one furrow to the next like rungs of a ladder; *Fibrillar/filamentous pattern* (3): parallel fine streaks crossing the dermoglyphics in a tangential direction; *Globular pattern* (4): globules not associated with a parallel pattern; *Homogeneous pattern* (5): light brown homogeneous pigmentation with an amorphous appearance in a lesion that is less than 7–10 mm in diameter; *Acral reticular pattern* (6): well-defined pigment network not associated with the skin markings. **Malignant patterns**: *Parallel ridge pattern* (10): linear pigmentation of the ridges; *Diffuse multicomponent pigmentation* (11): pigmented blotches of various shades of brown observed in some portions of the lesion; *Multicomponent pattern* (12): abrupt edge, diffuse pigmentation, peripheral irregular globules and dots, multiple colors, atypical streaks in combination with localized areas exhibiting benign patterns (fibrillar, parallel furrow, or lattice-like). *When pigmentation cannot be classified into any of the aforementioned benign (1–6) or malignant (10–12) patterns, then the lesion is classified as having a "**nontypical pattern**."

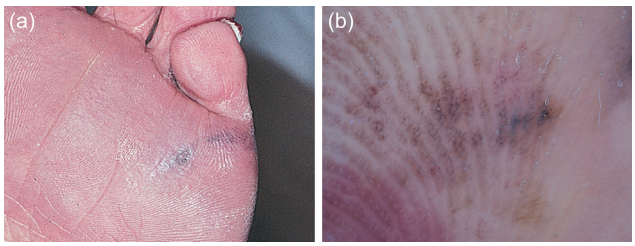

FIGURE 8D.4 (a) Clinical image. (b) Dermoscopic features of acrolentiginous melanoma on the sole. Band-like pigmentation is seen on the surface ridges of the skin markings, demonstrating the stereotypical parallel ridge pattern. Whitish dots regularly distributed in the pigmented bands correspond to openings of eccrine ducts. Also note the blue-gray color, irregular dots, and veil. These are all features commonly seen in melanoma. The blue-gray color suggests invasion. This was a 1.3 mm melanoma.



FIGURE 8D.5 Dermoscopy of acrolentiginous melanoma in situ on the sole. The parallel ridge pattern with variable shades of brown is well demonstrated. Eccrine pores are recognized as whitish dots regularly distributed within the band-like pigmentation.

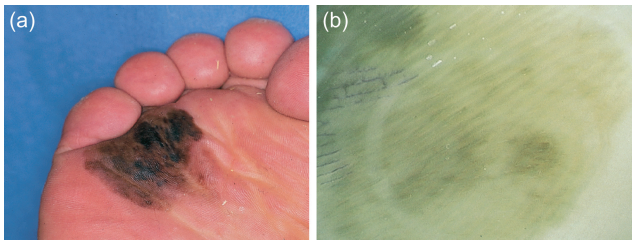

FIGURE 8D.6 (a) Clinical image. (b) Dermoscopic features of acrolentiginous melanoma on the sole. Irregular diffuse pigmentation accompanied by subtle features of the parallel ridge pattern is evident. In addition, the parallel furrow pattern and the lattice-like pattern can be detected focally in the left portion of the image.

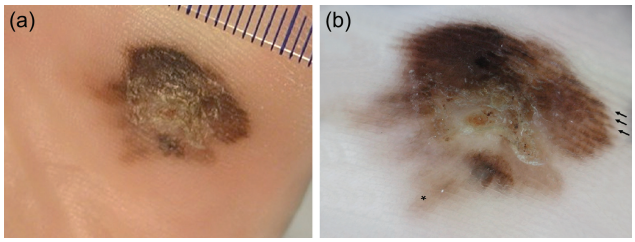

FIGURE 8D.7 (a) Clinical image of an acrolentiginous melanoma. (b) Invasive acrolentiginous melanoma on the foot exhibiting asymmetry, multiple colors, and central hyperkeratosis. Dermoscopy reveals a typical parallel ridge pattern (arrows) and irregular diffuse pigmentation (asterisk).

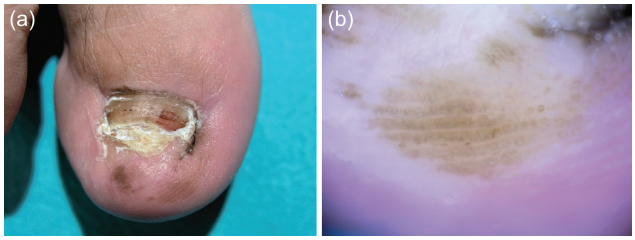

FIGURE 8D.8 (a) Invasive acrolentiginous melanoma on the toe with destruction of the nail apparatus. (b) Dermoscopy reveals the stereotypical parallel ridge pattern on the hyponychium corresponding to an area of in situ tumor. Notice the white eccrine ducts opening on top of the pigmented ridge.

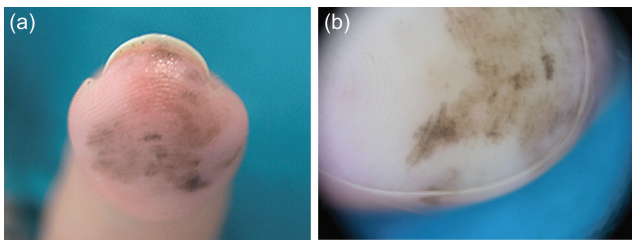

FIGURE 8D.9 (a) In situ acrolentiginous melanoma of the tip of the third finger. (b) Dermoscopy shows a typical irregular brown pigmentation that is located on the ridges (parallel ridge pattern).

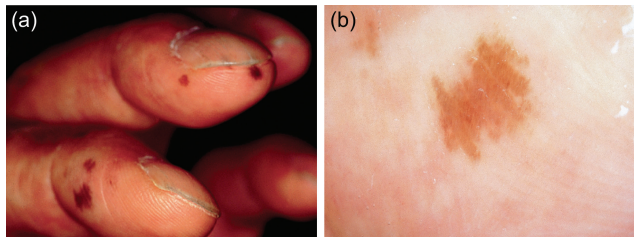

FIGURE 8D.10 (a) Clinical image. (b) Dermoscopic features of pigmented macule on the finger of a patient with Laugier–Hunziker's syndrome. The parallel ridge pattern is evident on dermoscopy. Misdiagnosing these lesions as melanoma can be avoided by recognizing the unique clinical presentation consisting of multiple small brownish macules on multiple fingers and also on the lip in a patient with Laugier–Hunziker's syndrome. (Courtesy of Drs S. Shibata and Y. Tomita.)

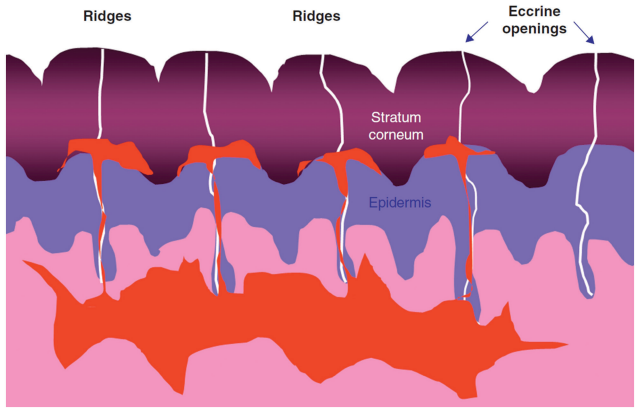

FIGURE 8D.11 Schematic of subcorneal blood. It is surmised that subcorneal blood will track along the least resistant tissue planes, which may be along eccrine glands. This results in the accumulation of blood on the ridges, creating a parallel ridge pattern or pebbles on the ridge pattern.

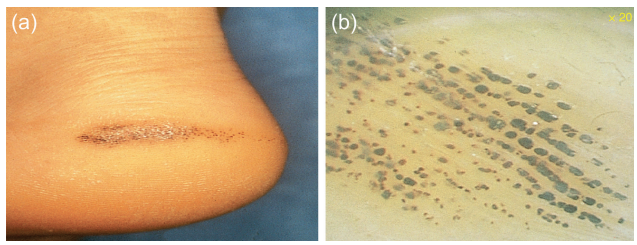

FIGURE 8D.12 (a) Clinical image. (b) Dermoscopic features of "black heel," that is, petechiae on the heel, which is often the result of ill-fitting sport shoes. The pigmentation is prominent on the ridges, somewhat mimicking the parallel ridge pattern. However, it is composed of droplets with smooth margins, and the color is reddish black, indicating that this pigmentation is due to bleeding. This dermoscopic feature is peculiar to this condition and is referred to as "pebbles on the ridges."

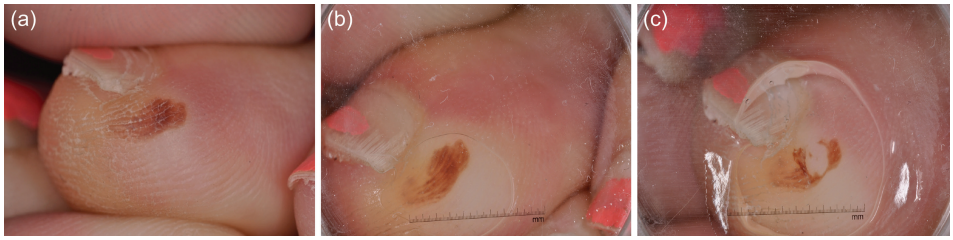

FIGURE 8D.13 (a) Clinical image of a pigmented macule on the toe. (b) Dermoscopy of this lesion reveals a parallel ridge pattern with a rust color. This lesion developed after a tennis match. To confirm that this was consistent with subcorneal hemorrhage, the stratum corneum was pared down with a scalpel, resulting in the removal of the blood. (c) Once the stratum corneum with the blood has been removed, it is clear to see that the underlying skin looks normal.

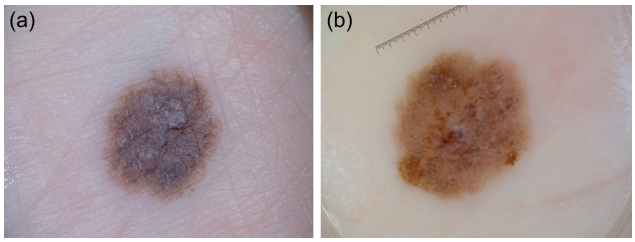

FIGURE 8D.14 (a) This is a 1 cm lesion on the sole. (b) With dermoscopy, one can see a homogeneous pigment pattern. This lesion was an acrolentiginous melanoma.

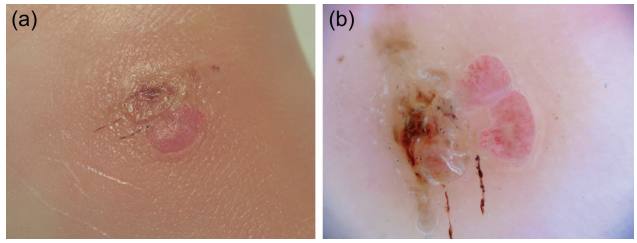

FIGURE 8D.17 (a) Clinical image of an amelanotic ALM. (b) Dermoscopic image of an amelanotic ulcerated acrolentiginous melanoma. In this case, the clues to the diagnosis are the presence of atypical vessels under dermoscopy (corkscrew) and remnants of pigment associated with a hemorrhage and hyperkeratosis.

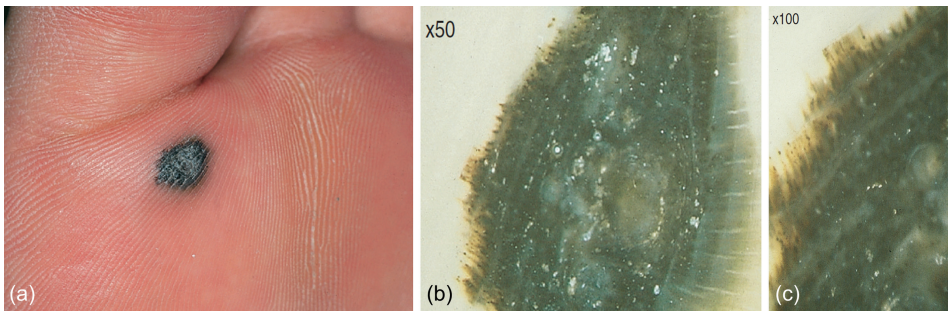

FIGURE 8D.15 (a) Clinical image. (b) Dermoscopic features of malignant melanoma on the sole. This small black nodule, 6.5 mm in diameter, has a macular component at the periphery. Dermoscopically, diffuse black pigmentation predominates, and sharp demarcation (i.e., abrupt cutoff of pigment at the periphery) is clearly recognized at the left margin. In addition, irregular streaks and peripheral dots are detected at the margin.

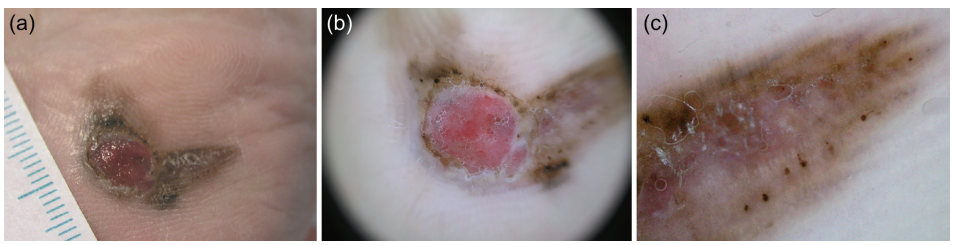

FIGURE 8D.16 (a) Ulcerated invasive acrolentiginous melanoma on the sole. (b) Dermoscopy shows symmetry, multiple colors, and multicomponent pattern. In the central part, an amelanotic nodule with atypical vessels is clearly visible. (c) At the periphery of this ALM, atypical dots and globules with parallel ridge pattern are observable.

TABLE 8D.1: BRAAFF Algorithm for Evaluation of Volar Lesions (from ref 10, with permission)

Positive criteria (anywhere within the lesion)		
B	Irregular blotch	+1
R	Parallel ridge pattern	+3
A	Asymmetry of structures	+1
A	Asymmetry of colors	+1
Negative criteria (anywhere within the lesion)		
F	Parallel furrow pattern	−1
F	Fibrillar pattern	−1

Source: Lallas, A, et al., *Br J Dermatol*, 173(4), 1041–1049, 2015.
A score of ≥1 is required for the diagnosis of acral melanoma.

Key points

- Parallel ridge pattern, diffuse pigmentation with variable shades of brown, multicomponent pattern, atypical fibrillar pattern, and milky-red areas are considered malignant patterns.
- In acral melanoma, it is not uncommon to see focal areas displaying patterns associated with benign lesions. Thus, it is imperative to first search the entire lesion for the presence of features associated with melanoma.
- In lesions that do not manifest a classic benign or malignant pattern, the decision to biopsy or monitor is dependent on the maximum diameter of the lesion.

References

1. Saida T, Koga H, Uhara H. Key points in dermoscopic differentiation between early acral melanoma and acral nevus. *J Dermatol*. 2011;38(1):25–34.
2. Saida T, Koga H, Goto Y, Uhara H. Characteristic distribution of melanin columns in the cornified layer of acquired acral nevus: an important clue for histopathologic differentiation from early acral melanoma. *Am J Dermatopathol*. 2011;33(5):468–73.
3. Saida T, Kawachi S, Koga H. Anatomic transitions and the histopathologic features of melanocytic nevi. *Arch Dermatol*. 2008;144(9):1232–3; author reply 3–4.
4. Saida T, Koga H. Dermoscopic patterns of acral melanocytic nevi: their variations, changes, and significance. *Arch Dermatol*. 2007;143(11):1423–6.
5. Saida T, Miyazaki A, Oguchi S, et al. Significance of dermoscopic patterns in detecting malignant melanoma on acral volar skin: results of a multicenter study in Japan. *Arch Dermatol*. 2004;140(10):1233–8.
6. Saida T, Oguchi S, Miyazaki A. Dermoscopy for acral pigmented skin lesions. *Clin Dermatol*. 2002;20(3):279–85.
7. Okamoto N, Aoto T, Uhara H, et al. A melanocyte--melanoma precursor niche in sweat glands of volar skin. *Pigment Cell Melanoma Res*. 2014;27(6):1039–50.
8. dermoscopedia contributors: Luc Thomas RB. *Acrolentiginous Melanoma: dermoscopedia*; 2019 [updated 17 January 2018 19:40 UTC. Available from: https://dermoscopedia.org/w/index.php?title=Acrolentiginous_Melanoma&oldid=10003.
9. Braun RP, Thomas L, Dusza SW, et al. Dermoscopy of acral melanoma: a multicenter study on behalf of the international dermoscopy society. *Dermatology*. 2013;227(4):373–80.
10. Lallas A, Kyrgidis A, Koga H, et al. The BRAAFF checklist: a new dermoscopic algorithm for diagnosing acral melanoma. *Br J Dermatol*. 2015;173(4):1041–9.
11. Phan A, Dalle S, Touzet S, Ronger-Savle S, Balme B, Thomas L. Dermoscopic features of acral lentiginous melanoma in a large series of 110 cases in a white population. *Br J Dermatol*. 2010;162(4):765–71.
12. Kilinc Karaarslan I, Akalin T, Unal I, Ozdemir F. Atypical melanosis of the foot showing a dermoscopic feature of the parallel ridge pattern. *J Dermatol*. 2007;34(1):56–9.
13. Mun JH, Jo G, Darmawan CC, et al. Association between Breslow thickness and dermoscopic findings in acral melanoma. *J Am Acad Dermatol*. 2018;79(5):831–5.
14. Wei Z, Li GY, Ruan HH, Zhang L, Wang WM, Wang X. Laugier-Hunziker syndrome: a case report. *J Stomatol Oral Maxillofac Surg*. 2018;119(2):158–60.
15. Ko JH, Shih YC, Chiu CS, Chuang YH. Dermoscopic features in Laugier–Hunziker syndrome. *J Dermatol*. 2011;38(1):87–90.
16. Sendagorta E, Feito M, Ramirez P, Gonzalez-Beato M, Saida T, Pizarro A. Dermoscopic findings and histological correlation of the acral volar pigmented maculae in Laugier–Hunziker syndrome. *J Dermatol*. 2010;37(11):980–4.
17. Tamiya H, Kamo R, Sowa J, et al. Dermoscopic features of pigmentation in Laugier–Hunziker-Baran syndrome. *Dermatol Surg*. 2010;36(1):152–4.
18. Kaminska-Winciorek G, Spiewak R. Tips and tricks in the dermoscopy of pigmented lesions. *BMC Dermatol*. 2012;12:14.
19. Savoia F, Ravaioli GM, Tabanelli M, Dika E, Patrizi A. Scraping test for the diagnosis of acral subcorneal hemorrhage. *J Am Acad Dermatol*. 2019;81(2):e29–e30.
20. Tanioka M. Benign acral lesions showing parallel ridge pattern on dermoscopy. *J Dermatol*. 2011;38(1):41–4.
21. Zalaudek I, Argenziano G, Soyer HP, Saurat JH, Braun RP. Dermoscopy of subcorneal hematoma. *Dermatol Surg*. 2004;30(9):1229–32.
22. Robertson SJ, Leonard J, Chamberlain AJ. PlayStation purpura. *Australas J Dermatol*. 2010;51(3):220–2.
23. Bowling J. Fibrillar pattern of an acquired plantar acral melanocytic naevus: correspondence between epiluminescence light microscopy and transverse section histology. *Clin Exp Dermatol*. 2007;32(1):103.
24. Emiroglu N, Cengiz FP, Onsun N. Age and Anatomical Location-Related Dermoscopic Patterns of 210 Acral Melanocytic Nevi in a Turkish Population. *J Cutan Med Surg*. 2017;21(5):388–94.
25. Kiyohara T, Satoh S, Yasuta M, Kumakiri M. Irregular fibrillar pattern is an artifactual expression of parallel ridge pattern on the pressure-loaded area of the sole: the efficacy of oblique view dermoscopy. *J Dermatol*. 2012;39(11):927–8.
26. Miyazaki A, Saida T, Koga H, Oguchi S, Suzuki T, Tsuchida T. Anatomical and histopathological correlates of the dermoscopic patterns seen in melanocytic nevi on the sole: a retrospective study. *J Am Acad Dermatol*. 2005;53(2):230–6.
27. Palleschi GM, Torchia D. Fibrillar pattern of acral melanocytic naevi may be a dermatoscopic, but not a histological artefact. *Clin Exp Dermatol*. 2007;32(3):324.
28. Mikoshiba Y, Minagawa A, Koga H, Yokokawa Y, Uhara H, Okuyama R. Clinical and histopathologic characteristics of melanocytic lesions on the volar skin without typical dermoscopic patterns. *JAMA Dermatol*. 2019;155(5):578–84.

8E MELANOCYTIC LESIONS: OTHER MELANOMA SUBTYPES

Cristian Navarrete-Dechent, Konstantinos Liopyris, Natalia Jaimes, and Ashfaq A. Marghoob

Contents

Introduction . . . 202
Nodular melanoma (NM) . . . 202
Dermoscopic characteristics . . . 202
Desmoplastic melanoma . . . 203
Dermoscopic characteristics . . . 204
Nevoid melanoma . . . 204
Dermoscopic characteristics . . . 204
Spitzoid melanoma . . . 204
Dermoscopic characteristics . . . 205
Verrucous melanoma: Seborrheic keratosis–like melanoma . . . 205
Flat amelanotic melanoma . . . 206
Other rare melanoma subtypes . . . 206
Primary dermal melanoma . . . 206
Polypoid melanoma . . . 206
Follicular melanoma . . . 207
Balloon cell melanoma . . . 207
Pigmented epithelioid melanocytoma ("animal-type melanoma") . . . 207
Nested melanoma . . . 207
Epidermotropic (skin) metastasis . . . 207
Featureless/structureless melanoma . . . 208
Conclusion . . . 208
References . . . 208

Introduction

Melanomas that manifest the clinical ABCDs or have a disorganized dermoscopic pattern are relatively easy to recognize. It's the melanomas that lack the clinical ABCDs, manifest an organized dermoscopic pattern, mimic a benign lesion such as a seborrheic keratosis, or lack recognizable melanoma-specific features (aka feature-poor, featureless, or structureless melanomas) that are at risk for being miscategorized as nonconcerning lesions.[1, 2] Studying the dermoscopic morphology of these so-called "difficult to diagnose melanomas" has provided some clues that can assist in their diagnosis. This chapter will describe the clinical and dermoscopic features of challenging to diagnose melanomas and highlight the clues to correctly identify these cancers. **Table 8e.1** summarizes the main dermoscopic findings.

Nodular melanoma (NM) (see Chapter 8b for details)

A proportion of early NMs escape detection due to their lack of manifesting any of the classic ABCD features described for superficial spreading melanoma (i.e., Asymmetry, Border irregularity, Color variegation, and Diameter larger than 6 mm). In an attempt to improve the early detection of nodular melanoma, an "E" for evolution was added to the ABCD rule, underscoring the importance of growth as a key feature of these cancers.[1, 3, 4] Some have advocated adding "EFG" to the ABCD rule to highlight that these melanomas tend to be "*e*levated," "*f*irm," and "*g*rowing" lesions.[3–5] Although some NMs manifest a relatively banal clinical morphology, dermoscopy can assist in raising concern for the potential of malignancy.

Dermoscopic characteristics

Between 30% and 40% of NMs are amelanotic or hypomelanotic. The remainder of the NM tend to be heavily pigmented blue-black papules or nodules (**Figures 8e.1-8e.2**).

Pigmented NM

The histopathology and growth dynamics of pigmented NMs help to explain the dermoscopic morphology observed in these cancers. NMs are characterized by prominent vertical growth with a relative lack of radial growth. Thus, the dermoscopic features associated with radial growth, including network structures and streaks, are not often seen. In contrast, the dermoscopic features associated with vertical growth, including matrix alterations and tumor cell aggregates, are commonly seen as shiny white lines and globules, respectively. It is uncommon for NMs to spontaneously regress/involute, and thus, the dermoscopic structures associated with regression (scarlike depigmentation and granularity/peppering) are not a prominent feature in these tumors.[4, 6, 7] Although these tumors have neoangiogenic vessels in the dermis, the vessels are virtually invisible with dermoscopy due to the abundant eumelanin pigment present in the dermis/epidermis, which obscures one's ability to see the dermal vessels. The pigment is often so extensive that no dermoscopic structures can be appreciated, and the lesion simply appears as a blue-black nodule with an intermix of different hues of blue, red, and gray color (**Figure 8e.1**). This is opposed to blue nevi, which tend to display a relatively "homogeneous blue" hue. In fact, if blue-gray globules or vessels are visualized in a heavily pigmented nodule, it is more likely that the lesion will prove to be a pigmented nodular basal cell carcinoma (BCC) than a NM. This is due to the observation that in pigmented nodular BCC, the epidermis is not heavily

TABLE 8E.1: Dermoscopic Findings Typically Seen or Most Frequently Reported in Difficult to Diagnose Melanomas

Melanoma type	Dermoscopic findings	Clinical comments	Histopathological comments
Nodular Melanoma *Pigmented NM* *Amelanotic NM*	• Shiny white structures • Blue-black color • Shiny white structures • Atypical vessels (i.e., polymorphous pattern)	• Many lack the classic ABCD features • Palpable lesions • Elevated, firm and growing lesions	• Vertical growth of malignant melanocytes into the dermis with matrix alteration • Lack of a radial growth phase
Desmoplastic melanoma *Pure desmoplastic melanoma* *Mixed desmoplastic melanoma*	• Shiny white structures • Milky-red areas • Regression structures • Atypical vessels (serpentine, polymorphous) • Atypical network • Homogeneous • Hyperpigmented areas • Any lentigo maligna–specific criteria	Mimics a scar or a dermal tumor (e.g., cyst, lipoma)	Predominant desmoplasia throughout the tumor, ≥90% Densely cellular tumor foci without prominent stromal fibrosis, 10–90%
Nevoid melanoma	• Milia-like cysts • Atypical globules • Blue-white veil • Irregular or eccentric hyperpigmented blotches	May resemble a common intradermal and/or compound banal nevus	May resemble a common intradermal and/or compound banal nevus
Spitzoid melanoma	• Atypical network • Shiny white lines • Homogeneous pinkish background • Atypical vessels (i.e., dotted, polymorphous)		Histopathologically malignant tumors comprised of large epithelioid melanocytes resembling those found in Spitz nevi
Verrucous melanoma	• Blue-black sign (presence of "blue and black" areas) • Dots • Globules • Streaks • Bluish-white veil • In addition, there are comedo-like openings, gyri and sulci, and milia-like cysts	Melanomas that clinically resembles pigmented verrucous nevi or seborrheic keratosis	
Primary dermal melanoma	• Subcutaneous tumor with no discernable dermoscopic features • Features seen in nodular melanoma (homogeneous blue-black nodule)	Subcutaneous lesion	Melanomas exclusively confined to the dermis presenting as a solitary nodular lesion in an elderly patient
Follicular melanoma	• Atypical globules • Homogeneous blue-gray or pinkish-red areas • Shiny white structures • Central ulcerations • Atypical vessels	Frequently seen on the nose. Can mimic a pigmented cyst or a comedo	
Balloon cell melanoma	• Multicomponent pattern, disorganized/chaotic lesion. In contrast to balloon cell nevus, no white globules are seen		Large, polygonal, foamy cells with abundant cytoplasm in addition to classic melanoma features
Nested melanoma	Disorganized lesion, atypical dots/globules, homogeneous or structureless areas (brown or red), wide skin markings, irregular or eccentric blotches	Large lesion on chronically sun-damaged skin in older individuals	Nested pattern on histopathology

melanized; it is only the dermal BCC tumor islands that are. Therefore, the light from dermoscopy can still reach the superficial dermis, allowing the observer to see vessels of blue-gray BCC tumor islands.

Amelanotic/hypomelanotic NM

Nonpigmented NMs can be classified as pure amelanotic NM (ANM) or hypomelanotic NM. The latter appears mainly amelanotic to the naked eye but reveals subtle melanin pigmentation when viewed with dermoscopy. For the purposes of this chapter, both pure amelanotic and hypomelanotic NM will be classified as ANM. Since there is minimal to no eumelanin pigment to block the light of dermoscopy, ANMs almost always display a polymorphous vascular pattern and shiny white structures (**Figure 8e.2**). The polymorphous vessels usually consist of dotted and serpentine vessels; rarely will there be vessels with a comma shape, as seen in IDN, or arborizing configuration, as seen in BCC.[8] A recent multicentric study by Soures et al. showed that the presence of serpentine vessels was highly predictive of thicker (>2 mm) NMs, while irregular brown dots/globules were predictive of NM less than 2 mm in thickness.[6]

Desmoplastic melanoma

Desmoplastic melanoma (DM) is characterized by the association of invasive spindle-shaped melanoma cells within a prominent fibrotic stroma.[9, 10] DM comprises fewer than 4% of all cutaneous melanomas, with most cases presenting in patients older than 60 years of age. It typically develops on chronically sun-exposed skin.[11, 12] DM can present as an isolated sub-epidermal neoplasm or in association with a non-DM melanoma, with the most frequent subtype being lentigo maligna (LM). Since most DMs are amelanotic and often lack epidermal involvement, early diagnosis of DM remains challenging.[11–14] Clinical clues to suspect a DM include a firm, subcutaneous, new, or changing scarlike lesion developing on sun-damaged skin of an elderly person. They could be mistaken for a scar or a cyst.

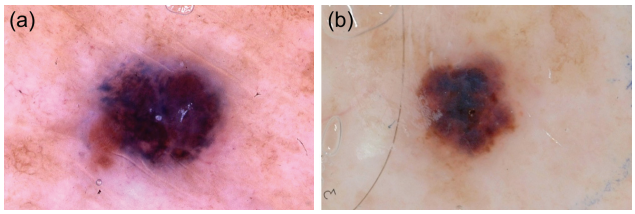

FIGURE 8E.1 Pigmented nodular melanomas. (a) Nodular melanoma showing homogeneous blue. (b) Nodular melanoma showing blue-white veil and irregular globules.

Dermoscopic characteristics

If the DM is not associated with an overlying LM or superficial spreading melanoma, there may be no structures or features visible with dermoscopy (**Figure 8e.3**). Occasionally, one may see shiny white structures, vessels, and/or granularity, especially if the DM involves the papillary dermis.[14, 15] DMs associated with LM may be easier to detect, since the LM acts as a "beacon" for the detection of DM,[15] and the key to their detection is contingent on routinely palpating any suspect LM before performing a biopsy (**Figure 8e.3**). If the suspect LM has a focal firm area, one should entertain the possibility of an associated DM and preform an adequately deep biopsy of the suspect LM together with the area of firmness.

Nevoid melanoma

Nevoid melanoma accounts for fewer than 1% of all melanomas and is associated with a high mortality (15–37.5%). The high mortality rate is presumed to be due to delays in detection,[10] with reported mean Breslow thickness at diagnosis of 2.9 mm (range, 0.4–12.0 mm).[15] On histopathology, nevoid melanomas display malignant melanocytes with a nevoid appearance. Clinically, nevoid melanomas can present as pigmented or nonpigmented tumors. Although some nevoid melanomas can be indistinguishable from superficial spreading melanomas (i.e., manifesting the ABCDs), others may resemble an intradermal and/or compound melanocytic nevus, displaying a dome-shaped to sessile symmetric morphology and mammillated surface, which makes them challenging to detect on clinical examination.[10, 15]

Dermoscopic characteristics

On dermoscopy, nevoid melanomas will not display the benign patterns seen in intradermal nevi (see Chapter 7c). Instead, nevoid melanomas will frequently reveal milia-like cysts, irregular or eccentric globules, blue-white veil (BVW), shiny white structures, irregular or eccentric blotches, and atypical vessels (**Figure 8e.4**).[15]

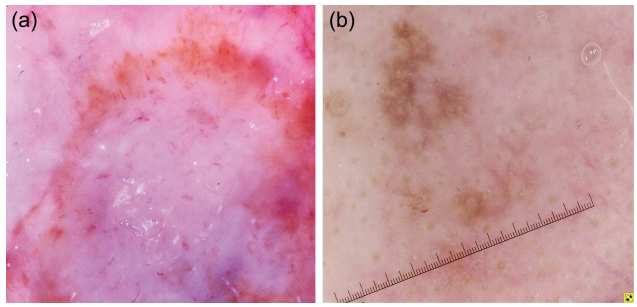

FIGURE 8E.3 Examples of desmoplastic melanomas. (a) Desmoplastic melanoma. (b) Associated with lentigo maligna.

Three dermoscopic patterns have been described for nevoid melanomas[10, 15, 16]

Nevus-like pattern seen in 48% of cases. Nevoid melanomas presenting with a nevus-like pattern are often dome-shaped to sessile mammillated/papillomatous lesions that resemble dermal nevi. Dermoscopy reveals atypical vessels, irregular dots/globules, and/or shiny white structures.

Amelanotic pattern (30%). Nevoid melanomas presenting with an amelanotic pattern will reveal atypical vessels with or without shiny white structures.

Multicomponent pattern (15%). Nevoid melanomas manifesting a multicomponent pattern will reveal at least one of the classic melanoma-specific structures associated with superficial spreading melanoma (see Chapter 8a), which allows an easier diagnosis.

The key to avoid missing a nevoid melanoma is to remain suspicious of any "banal" mammillated intradermal nevus-like appearing lesion that is new or changing in an older individual, lacks a benign pattern under dermoscopy (i.e., intradermal and congenital nevi, Chapters 7a, 7c), and reveals atypical vessels, shiny white structures, atypical dots/globules, or any of the other melanoma-specific structures mentioned in Chapter 9a.

Spitzoid melanoma

The term *spitzoid melanoma* refers to histopathologically malignant tumors containing large epithelioid melanocytes resembling those seen in Spitz nevi.[17, 18] Clinically, spitzoid melanomas typically present as enlarging or changing amelanotic or pigmented palpable lesions (i.e., papule, nodule, or plaque). Spitzoid melanomas can have a symmetric appearance, lacking

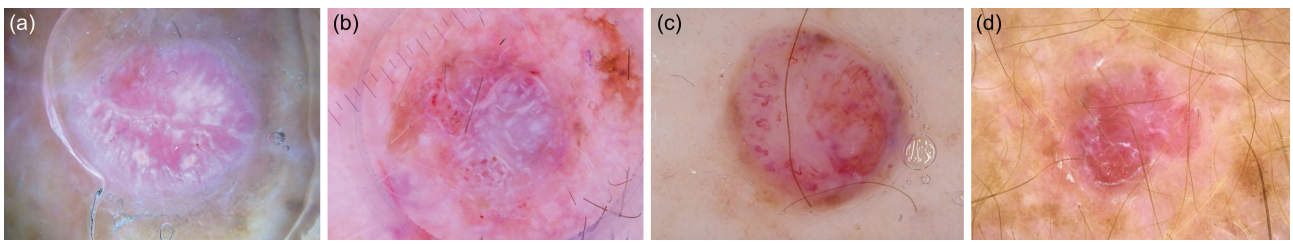

FIGURE 8E.2 Amelanotic nodular melanomas. (a) Pink tumor with shiny white structures. (b) Pink tumor with dotted and glomerular vessels and shiny white lines. (c) Pink tumor with polymorphous vessels. (d) Pink tumor with polymorphous vessels and shiny white structures.

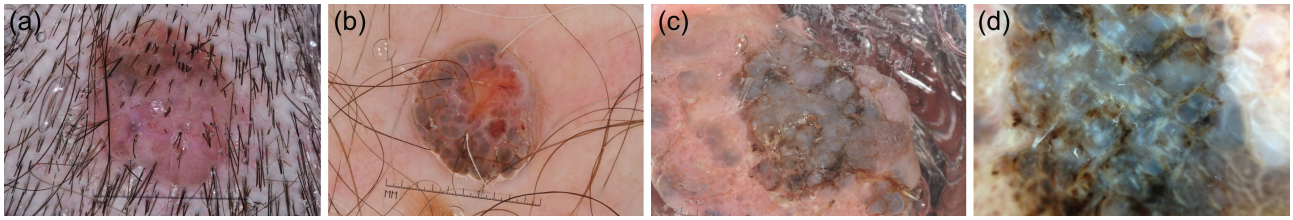

FIGURE 8E.4 Nevoid melanomas. (a) Polymorphous vessels and atypical globules. (b) Milky-red globules mimicking cobblestone pattern. (c) and (d) Patient with a nevoid melanoma of the helix. (c) Nonpolarized light dermoscopy showing atypical globules. (d) Polarized light dermoscopy showing shiny white structures and atypical globules.

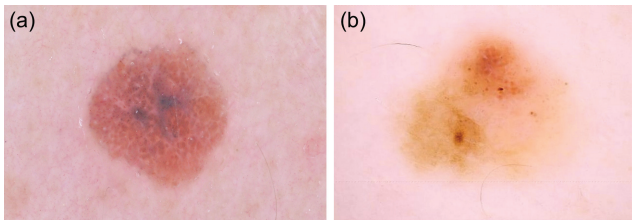

FIGURE 8E.5 Spitzoid melanomas. (a) Negative network and dotted vessels. (b) Irregular globules, tan homogeneous areas, and shiny white lines.

the ABCDs (asymmetry, border irregularity, color variegation, diameter greater than 6 mm).[15, 19]

Dermoscopic characteristics[15]

The following are dermoscopic structures seen in spitzoid melanomas (**Figure 8e.5**)[15]

- Atypical broadened network
- Negative network
- Reticular depigmentation
- Shiny white lines
- Homogeneous pinkish background
- Atypical vessels, including dotted and polymorphous vessels

Two dermoscopic patterns have been described in spitzoid melanomas[15]

1. *Amelanotic pattern* (Spitz nevus–like). This pattern presents with dotted or polymorphous vessels, shiny white lines, negative network, reticular depigmentation, or a multicomponent pattern. These lesions can be morphologically indistinguishable from benign Spitz nevi.
2. *Pigmented pattern* (Reed's nevus–like). This pattern presents with a starburst, globular, homogeneous, negative network, or reticular pattern. These melanomas can be indistinguishable from Reed's nevi.

Since the morphology of spitzoid melanoma can mimic Spitz and Reed nevi, one needs to rely on other clues to decide when a biopsy is warranted. Spitzoid lesions developing in older individuals or lesions that are asymmetrically or rapidly growing should always raise suspicion for melanoma.

Verrucous melanoma: Seborrheic keratosis–like melanoma

Verrucous melanoma (VM) accounts for <3% of all melanomas. Approximately 50% of VMs are misdiagnosed clinically as benign lesions.[10, 16] Clinically, VM can resemble SK, displaying sharply demarcated borders and a keratotic surface with or without invaginated crypts and comedo-like openings. Since VMs clinically resemble SKs, the clinician may fall into the trap of search "satisfaction," searching for dermoscopic features that support the clinical impression of SK and anchor their diagnosis on these features while turning a blind eye to the presence of other dermoscopic features suggestive of melanoma. This bias can even lead to the gross misinterpretation of structures. For example, globules in a VM can be misinterpreted as comedo-like openings and a negative network as gyri and sulci.[20]

The key to avoid missing a VM is to be cognizant of anchoring bias and search satisfaction error when examining presumed SKs. Extra care should be taken to thoroughly examine all quadrants of the lesion to ensure that it does not contain any melanoma-specific structures and that the only visible features are those associated with SK. Again, it is worth underscoring that while the presence of multiple milia-like cysts and comedo-like openings is highly suggestive of a SK, they can also be seen in VM. Thus, in such lesions, before rendering a final diagnosis of SK, one should make sure that there are no melanoma-specific structures present, especially before deploying destructive techniques such as cryosurgery.[21]

An important clue among melanomas that resemble SKs is the presence of "blue-black areas" (**Figure 8e.6**).[22, 23] In addition, melanomas resembling SK can also reveal other melanoma-specific structures, including "atypical dots and globules," "streaks," and/or a "bluish-white veil," that are usually present focally within the lesion. Furthermore, regression structures (i.e., granularity/peppering and scarlike depigmentation) can also be present in some of these melanomas. However, there are a few caveats worth elaborating upon.

- Heavily pigmented SKs (aka melanoacanthoma) can display a black -colored area or BVW. This is due to a thickened epidermis containing melanized keratinocytes. In such thickened areas, other SK-like features such as comedo-like openings and milia cysts tend to be quite prominent. Furthermore, SKs lack dermal involvement. In melanoma, the BWV is due to dermal melanocytes and compact orthokeratosis with an otherwise normal-thickness epidermis. Keeping the histopathology in perspective helps explain clues used to differentiate the BVW in SK from that seen in melanoma: 1) SKs with a BWV

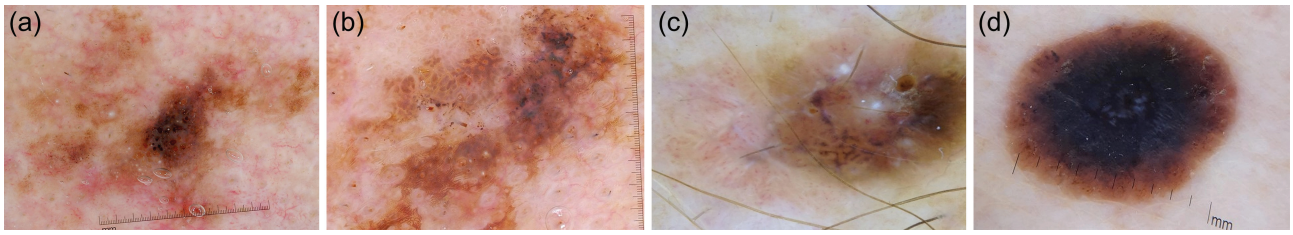

FIGURE 8E.6 Verrucous melanomas. (a) Atypical network on the left side and milia-like cysts and comedo-like openings on the right side. (b) Atypical globules, peppering, and gyri and sulci. (c) Irregular hairpin vessels, shiny white structures, and blue-white veil. (d) Atypical dots and globules and blue-white veil.

will not display any other melanoma-specific structures (Chapters 8 and 9a) such as streaks, atypical network, angulated lines, negative network, shiny white lines, atypical dots and globules;[22] 2) SKs will almost always display multiple comedo-like openings and/or milia cysts within the BWV area, whereas in melanoma, the BWV will not reveal other structures or will reveal shiny white lines; and 3) an underutilized clue is the "wobble sign," which demonstrates that SKs slide en bloc whereas melanomas do not slide en bloc and instead, "wobble."[24]

- Care should be taken not to confuse a negative network for gyri and sulci, since on a two-dimensional image, both structures can look very similar. The clues to differentiating "gyri and sulci" from a "negative network" rely on evaluating the topography of the lesion (i.e., "three-dimensional evaluation"). The negative network is associated with changes occurring at the level of the rete ridges and dermis;[25] thus, the surface of the lesion will be relatively smooth without any clinically visible invaginations on the surface of the skin (i.e., no gyri and sulci). In contrast, "gyri and sulci" are due to raised epidermal ridges alternating with invaginations, which are visible on the surface of the lesion, especially when viewed with side lighting. When in doubt, the "ink test" can be used.[26] The ink test consists of painting the lesion with a gentian violet surgical marking pen and then wiping off the ink with an alcohol wipe. The ink will be retained in sulci, crypts, and comedo-like openings, and hence, the ink will accentuate these structures. In contrast, the ink will be completely wiped off from areas overlying a negative network. In essence, the ink allows the observer to appreciate the third dimension when viewing a two-dimensional image.

Melanomas arising in association with SK can be found in up to 3.7% of collision tumors.[27] Thus, diagnosing these melanomas can be challenging for the same reasons mentioned earlier (i.e., anchoring bias). Besides the dermoscopic structures described for SK-like melanomas in the preceding paragraphs, there is one additional caveat regarding peppering/granularity: A solar lentigo or SK can involute, and during this involution phase, they can reveal regression structures consisting of granularity/peppering (see lichen planus–like keratosis [LPLK], Chapter 6e).[28] Although the presence of granularity makes it difficult to differentiate SK/LPLKs from melanoma, there are a few clues that may help. First, involution of lentigo/SK usually occurs in a centripetal fashion, from the outer edge to the center; thus, a presumed lentigo or SK revealing regression structures in the center with the appearance of the peppering expanding centrifugally should raise concern, since this will be a feature more often associated with melanomas or melanomas arising in a SK. Second, a lentigo or SK that has not yet fully involuted will present remnants of the classic features seen in lentigo/SK, which are usually seen at the edge opposite or lateral to the area of peppering. Third, the granularity in involuting lentigo/SK tends to be "coarser" and appear as clumped granules, whereas in melanoma, they tend to be "fine" with tiny granular specks.[28]

Flat amelanotic melanoma (Chapter 8f)

Nodular (classic) amelanotic melanoma and amelanotic DM have already been covered. This section will cover the features seen primarily in superficial spreading (flat) amelanotic melanoma.[29]

Early amelanotic melanomas lack the ABCD features and tend to display a symmetric shape when seen clinically and with the dermatoscope ("pink patch").[29] This symmetry is due to the inability to visualize the irregular horizontal borders of the melanoma due to lack of pigment (melanin). Due to this phenomenon, when visualized with dermoscopy (*en face*), they seem to be symmetric.

Although amelanotic melanomas lack pigment, they do induce neoangiogenesis and matrix remodeling. Thus, these amelanotic melanomas will almost always reveal with dermoscopy a pink hue with dotted to serpentine to polymorphous vessels with or without shiny white structures (**Figure 8e.7**).

Other rare melanoma subtypes

Primary dermal melanoma

Primary dermal melanomas account for fewer than 1% of all melanomas. They usually present as solitary, smooth-surfaced nodular lesions in elderly patients.[10, 30] Since only a few cases have been reported, the dermoscopy features associated with primary dermal melanomas remain to be fully elucidated.[15] It is believed that the primary focus of the melanoma is confined to the dermis, and the epidermis and superficial papillary dermis are usually not involved. Therefore, based on published cases and personal experience, primary dermal melanomas often do not reveal any specific or discernible dermoscopy finding. However, similarly to DM and epidermotropic metastatic melanoma (see later), some primary dermal melanomas can reveal atypical vessels and shiny white structures or present as bluish nodules when viewed with dermoscopy.[15]

Polypoid melanoma

Polypoid melanoma is a rare tumor characterized by a prominent vertical growth phase.[31, 32] Clinically, polypoid melanomas can display a polypoid or "cauliflower-like" shape.[31] Although

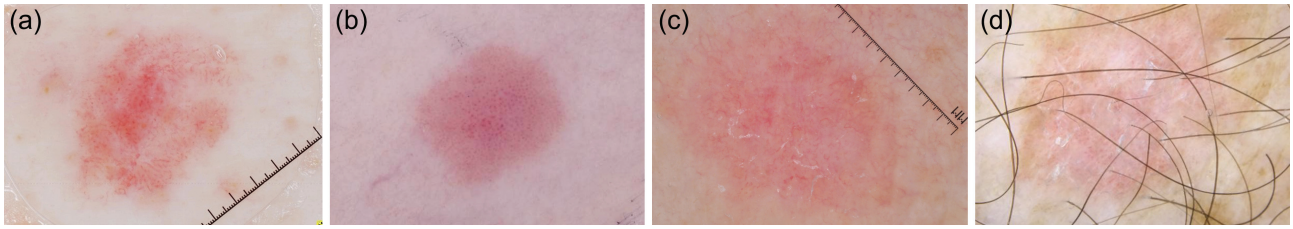

FIGURE 8E.7 Flat amelanotic melanomas. (a) Pink patch with polymorphous vessels (serpentine and dotted). (b) Dotted vessels through the lesion. (c) Polymorphous vessels (dotted and serpentine), scale, and shiny white structures. (d) Polymorphous vessels and scale.

dermoscopic features have been poorly described, polypoid melanomas can reveal similar structures to those seen in nevoid melanomas. Not infrequently, the presence of ulceration impedes the visualization of underlying structures.[31] One caveat to remember regarding the examination of suspect polypoid lesions is to inspect the surface of the lesion that is near the base. This surface is often hidden from view due to the polypoid/sessile part of the lesion overhanging the base. An easy method to inspect the entire surface of polypoid lesions with dermoscopy is to use the wobble test.[24] The wobble test is performed by placing the dermatoscope on the lesion (contact mode) and then applying horizontal pressure in a back and forth motion, causing the lesion to roll. As a result, the undersurface of pedunculated lesions will be exposed, providing important clues to the diagnosis.

Follicular melanoma

Follicular melanoma is an extremely rare variant of primary melanoma that can mimic a comedo or pigmented cyst. Follicular melanoma should be distinguished from LM with secondary follicular invasion.[33] In the former, the melanoma originates from the hair follicle without an associated LM, whereas in the latter, a LM invades the follicle and from there, the melanoma invades the dermis.[10] Dermoscopic descriptions are very limited. A recent systematic review described three patients and found irregular or eccentric globules and homogeneous blue-gray or pinkish-red areas. Shiny white structures, central ulcerations, and atypical vessels were also found.[15, 19]

Balloon cell melanoma

This rare variant of melanoma is diagnosed on histopathology by the presence of large, polygonal foamy cells with abundant cytoplasm, in addition to the classic melanoma features such as nuclear pleomorphism, atypia, mitoses, and a lack of maturation of melanocytes with descent into the dermis. Clinically, balloon cell melanomas fulfill the ABCDs criteria and are relatively easy to detect as probable melanomas based on their clinical morphology. Thus, while these melanomas may be rare, they are not difficult to diagnose. However, we include them in this chapter because we have not yet identified any specific dermoscopic structures to predict this specific melanoma subtype. On dermoscopy, they can reveal a disorganized pattern and display any of the conventional melanoma-specific structures described in Chapters 8 and 9a. One interesting observation is that while white globules are a hallmark of balloon cell nevi, they are not seen in balloon cell melanomas.[15, 34]

Pigmented epithelioid melanocytoma ("animal-type melanoma")

Pigmented epithelioid melanocytoma (PEM) is a recently described term that encompasses different atypical melanocytic lesions such as the animal-type melanoma, which frequently involves lymph nodes but tends to have an indolent clinical course. PEM corresponds to a dermal proliferation of heavily pigmented dendritic and epithelioid melanocytes, admixed with slightly larger and less pigmented epithelioid cells.[35] A study including nine PEMs showed that all lesions presented with a homogeneous blue pigmentation, and some cases had blue-black color and shiny white structures. A characteristic feature was the presence of blue pigmentation in lymphatic vessels.[35]

Nested melanoma

Nested melanoma (aka "nested melanoma of the elderly") is a histopathologic variant of melanoma characterized by the presence of a nested pattern with nests scattered along the dermo-epidermal junction. [36, 37] Nested melanomas usually present in adults older than 60 years. They appear as relatively large outlier lentiginous macules on chronically sun-damaged skin on the lower extremities and trunk.[15, 22, 37, 38] On dermoscopy, these melanomas usually reveal a disorganized pattern with atypical dots/globules.[37] Other features include homogeneous or structureless areas (brown or red), wide skin markings, and irregular or eccentric blotches (black or brown).[15, 23]

Epidermotropic (skin) metastasis

Cutaneous melanoma can metastasize to any organ, but metastasis to the skin remains the most common.[39] Epidermotropic metastasis can clinically resemble blue nevi, dermal nevi, and angiomas. Specific dermoscopic patterns of melanoma metastasis have been described (**Figure 8e.8**):[39]

- *Blue nevus-like pattern.* These epidermotropic metastases are characterized by homogeneous and diffuse blue color with or without different hues of blue, black, and/or gray color. Although they can be indistinguishable from blue nevus or exogenous pigmentation (tattoo), the clinical context, including the history of a prior invasive melanoma, aids in their detection (**Figure 8e.8a and b**).
- *Nevus-like pattern.* These lesions reveal brown, black, or bluish aggregated globules. Some lesions can also reveal reddish globules or atypical vessels (**Figure 8e.8c**).
- *Angioma-like pattern.* Metastases presenting with an angioma-like pattern display homogeneous milky-red area or milky-red globules (**Figure 8e.8d**). The milky-red globules can lacunae seen in angiomas. In contrast to angiomas, the lacunae-like structures in epidermotropic metastasis are not separated from each other by septae or are irregularly separated from each other by ill-defined septae. Furthermore, atypical vessels can often

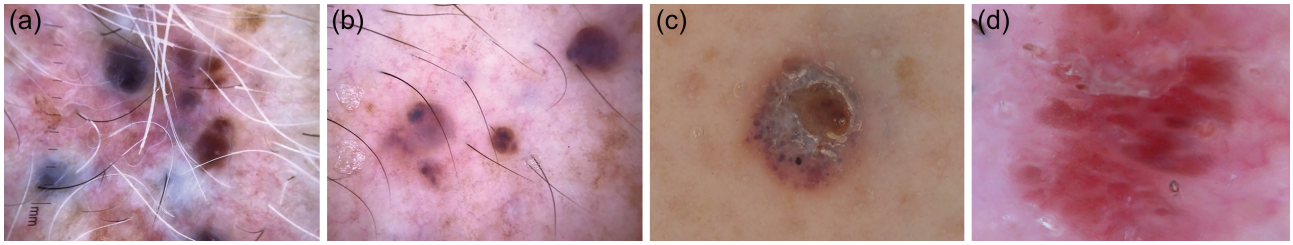

FIGURE 8E.8 Epidermotropic metastasis. (a) and (b) Examples of blue nevus-like metastasis showing a homogeneous blue pattern. (c) Nevus-like cutaneous metastasis showing irregular globules. (d) Angioma-like cutaneous metastasis with lacuna-like milky-red globules with no clear septa.

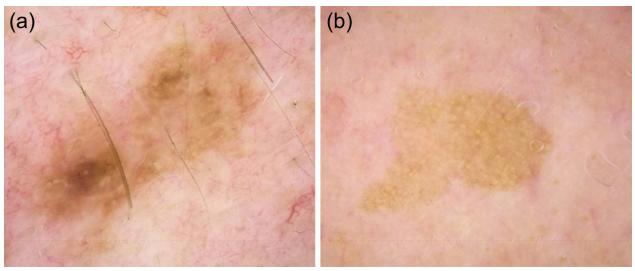

FIGURE 8E.9 Structureless melanomas. (a) 0.5-mm structureless melanoma showing homogeneous brown areas. (b) Structureless in situ melanoma with homogeneous light brown color.

be seen inside the lacunae-like structures. Pink homogeneous papules or pyogenic granuloma–like epidermotropic metastasis are also considered under this subtype.

- *Vascular pattern.* These lesions present with atypical vessels as the predominant structure. Vessel morphology can vary from dotted, serpentine, or corkscrew to polymorphous vessels.
- *Nonspecific pattern.* These lesions do not manifest any of the above-described patterns and are recognized by the presence of pigment and a disorganized dermoscopic morphology.

Featureless/structureless melanoma

Melanomas presenting with pigment but without definable structures are classified as featureless or structureless melanomas. Due to the feature-poor morphology of these melanomas, they tend to be easily overlooked; therefore, whenever an isolated nonspecific lesion (e.g., structureless pink or brown lesion) is encountered, melanoma should always enter the differential diagnosis. As a general rule, these lesions should either undergo biopsy for definitive diagnosis or be subjected to sequential monitoring via the short-term monitoring protocol described in Chapter 13. As a reminder, digital dermoscopic monitoring is reserved only for flat, nonpalpable lesions; palpable or raised lesions should not be subjected to monitoring, since they may represent melanomas in their vertical growth phase (**Figure 8e.9**).[40]

Conclusion

Difficult to diagnose melanomas refer to those melanomas that are challenging to detect without dermoscopy due to the lack of clinical clues such as the ABCD criteria. Overall, these melanomas tend to display a disorganized pattern under dermoscopy; if they appear organized under the dermatoscope, they can still be detected based on correctly identifying any of the following structures/patterns: Starburst or negative network pattern, vessels or ulceration, and any of the following colors—blue-black, gray, or white, including shiny white structures seen under polarized light.[41, 42] Those that are featureless remain the most difficult to detect, and besides monitoring nonpalpable lesions with digital dermoscopy for change, there is no reliable way to diagnose them with dermoscopy.

References

1. Yagerman SE, Chen L, Jaimes N, Dusza SW, Halpern AC, Marghoob A. 'Do UC the melanoma?' Recognising the importance of different lesions displaying unevenness or having a history of change for early melanoma detection. *Australas J Dermatol.* 2014;55(2):119–24.
2. Rose SE, Argenziano G, Marghoob AA. Melanomas difficult to diagnose via dermoscopy. *G Ital Dermatol Venereol.* 2010;145(1):111–26.
3. Lallas A, Apalla Z, Chaidemenos G. New trends in dermoscopy to minimize the risk of missing melanoma. *J Skin Cancer.* 2012;2012:820474.
4. Menzies SW, Moloney FJ, Byth K, et al. Dermoscopic evaluation of nodular melanoma. *JAMA Dermatol.* 2013;149(6):699–709.
5. Chamberlain AJ, Fritschi L, Kelly JW. Nodular melanoma: patients' perceptions of presenting features and implications for earlier detection. *J Am Acad Dermatol.* 2003;48(5):694–701.
6. Sgouros D, Lallas A, Kittler H, et al. Dermatoscopic features of thin (</=2 mm Breslow thickness) vs. thick (>2 mm Breslow thickness) nodular melanoma and predictors of nodular melanoma versus nodular non-melanoma tumours: a multicentric collaborative study by the International Dermoscopy Society. *J Eur Acad Dermatol Venereol.* 2020;34(11):2541–7.
7. Argenziano G, Longo C, Cameron A, et al. Blue-black rule: a simple dermoscopic clue to recognize pigmented nodular melanoma. *Br J Dermatol.* 2011;165(6):1251–5.
8. Menzies SW, Kreusch J, Byth K, et al. Dermoscopic evaluation of amelanotic and hypomelanotic melanoma. *Arch Dermatol.* 2008;144(9):1120–7.
9. Wiesner T, Kiuru M, Scott SN, et al. NF1 mutations are common in desmoplastic melanoma. *Am J Surg Pathol.* 2015;39(10):1357–62.
10. Cabrera R, Recule F. Unusual clinical presentations of malignant melanoma: a review of clinical and histologic features with special emphasis on dermatoscopic findings. *Am J Clin Dermatol.* 2018;19(Suppl 1):15–23.
11. Busam KJ. Desmoplastic melanoma. *Clin Lab Med.* 2011;31(2):321–30.
12. Chen LL, Jaimes N, Barker CA, Busam KJ, Marghoob AA. Desmoplastic melanoma: a review. *J Am Acad Dermatol.* 2013;68(5):825–33.

13. Wharton JM, Carlson JA, Mihm MC, Jr. Desmoplastic malignant melanoma: diagnosis of early clinical lesions. *Hum Pathol.* 1999;30(5):537–42.
14. Jaimes N, Chen L, Dusza SW, et al. Clinical and dermoscopic characteristics of desmoplastic melanomas. *JAMA Dermatol.* 2013;149(4):413–21.
15. Pampena R, Lai M, Lombardi M, et al. Clinical and dermoscopic features associated with difficult-to-recognize variants of cutaneous melanoma: a systematic review. *JAMA Dermatol.* 2020;156(4):430–9.
16. Longo C, Piana S, Marghoob A, et al. Morphological features of naevoid melanoma: results of a multicentre study of the international dermoscopy society. *Br J Dermatol.* 2015;172(4):961–7.
17. Raghavan SS, Peternel S, Mully TW, et al. Spitz melanoma is a distinct subset of spitzoid melanoma. *Mod Pathol.* 2020;33(6):1122–34.
18. Wiesner T, Kutzner H, Cerroni L, Mihm MC, Jr., Busam KJ, Murali R. Genomic aberrations in spitzoid melanocytic tumours and their implications for diagnosis, prognosis and therapy. *Pathology.* 2016;48(2):113–31.
19. Kamino H. Spitzoid melanoma. *Clin Dermatol.* 2009;27(6):545–55.
20. Braga JC, Scope A, Klaz I, Mecca P, Spencer P, Marghoob AA. Melanoma mimicking seborrheic keratosis: an error of perception precluding correct dermoscopic diagnosis. *J Am Acad Dermatol.* 2008;58(5):875–80.
21. Marghoob AA, Changchien L, DeFazio J, et al. The most common challenges in melanoma diagnosis and how to avoid them. *Australas J Dermatol.* 2009;50(1):1–13; quiz 14–15.
22. Carrera C, Segura S, Aguilera P, et al. Dermoscopic clues for diagnosing melanomas that resemble seborrheic keratosis. *JAMA Dermatol.* 2017;153(6):544–51.
23. Carrera C, Segura S, Aguilera P, et al. Dermoscopy improves the diagnostic accuracy of melanomas clinically resembling seborrheic keratosis: cross-sectional study of the ability to detect seborrheic keratosis-like melanomas by a group of dermatologists with varying degrees of experience. *Dermatology.* 2017;233(6):471–9.
24. Braun RP, Krischer J, Saurat JH. The "wobble sign" in epiluminescence microscopy as a novel clue to the differential diagnosis of pigmented skin lesions. *Arch Dermatol.* 2000;136(7):940–2.
25. Farnetani F, Scope A, Mazzoni L, et al. A comparative dermoscopic and reflectance confocal microscopy study of naevi and melanoma with negative pigment network. *J Eur Acad Dermatol Venereol.* 2019;33(12):2273–82.
26. Yagerman S, Marghoob AA. The ink test: identifying 3-dimensional features of seborrheic keratoses under dermoscopy. *JAMA Dermatol.* 2013;149(4):497–8.
27. Cascajo CD, Reichel M, Sanchez JL. Malignant neoplasms associated with seborrheic keratoses. An analysis of 54 cases. *Am J Dermatopathol.* 1996;18(3):278–82.
28. Liopyris K, Navarrete-Dechent C, Dusza SW, et al. Clinical and dermoscopic features associated with lichen planus-like keratoses that undergo skin biopsy: a single-center, observational study. *Australas J Dermatol.* 2019;60(2):e119–e126.
29. Jaimes N, Braun RP, Thomas L, Marghoob AA. Clinical and dermoscopic characteristics of amelanotic melanomas that are not of the nodular subtype. *J Eur Acad Dermatol Venereol.* 2012;26(5):591–6.
30. Sidiropoulos M, Obregon R, Cooper C, Sholl LM, Guitart J, Gerami P. Primary dermal melanoma: a unique subtype of melanoma to be distinguished from cutaneous metastatic melanoma: a clinical, histologic, and gene expression-profiling study. *J Am Acad Dermatol.* 2014;71(6):1083–92.
31. Di Altobrando A, Patrizi A, Dika E, Savoia F. Cauliflower-like exophytic mass on the skin: polypoid melanoma. Clinical, dermoscopic, and histologic features. *An Bras Dermatol.* 2020;95(6):748–50.
32. Perez-Wilson J, Arellano J, Castro A. Polypoid melanoma: an aggressive variant of nodular melanoma. *Cutis.* 2018;101(6):E6–E7.
33. Connolly KL, Giordano C, Dusza S, Busam KJ, Nehal K. Follicular involvement is frequent in lentigo maligna: implications for treatment. *J Am Acad Dermatol.* 2019;80(2):532–7.
34. Jaimes N, Braun RP, Stolz W, Busam KJ, Marghoob AA. White globules correlate with balloon cell nevi nests. *J Am Acad Dermatol.* 2011;65(4):e119–e120.
35. Moscarella E, Ricci R, Argenziano G, et al. Pigmented epithelioid melanocytoma: clinical, dermoscopic and histopathological features. *Br J Dermatol.* 2016;174(5):1115–7.
36. Kutzner H, Metzler G, Argenyi Z, et al. Histological and genetic evidence for a variant of superficial spreading melanoma composed predominantly of large nests. *Mod Pathol.* 2012;25(6):838–45.
37. Longo C, Zalaudek I, Piana S, et al. Dermoscopy and confocal microscopy of nested melanoma of the elderly: recognizing a newly defined entity. *JAMA Dermatol.* 2013;149(8):941–5.
38. Garbe C, Metzler G. Nested melanoma, a newly defined entity. *JAMA Dermatol.* 2013;149(8):905–6.
39. Costa J, Ortiz-Ibanez K, Salerni G, et al. Dermoscopic patterns of melanoma metastases: interobserver consistency and accuracy for metastasis recognition. *Br J Dermatol.* 2013;169(1):91–9.
40. Argenziano G, Kittler H, Ferrara G, et al. Slow-growing melanoma: a dermoscopy follow-up study. *Br J Dermatol.* 2010;162(2):267–73.
41. Rogers T, Marino M, Dusza SW, Bajaj S, Marchetti MA, Marghoob A. Triage amalgamated dermoscopic algorithm (TADA) for skin cancer screening. *Dermatol Pract Concept.* 2017;7(2):39–46.
42. Jaimes N, Marghoob AA. Triage amalgamated dermoscopic algorithm. *J Am Acad Dermatol.* 2020;82(6):1551–2.

8F MELANOCYTIC LESIONS: AMELANOTIC AND HYPOMELANOTIC MELANOMA

Natalia Jaimes, Juergen F. Kreusch, Giuseppe Argenziano, and Scott W. Menzies

Contents

Vascular structures 210
Key points 214
References 214

Amelanotic melanoma accounts for at least 2–8% of all melanomas and represents an important diagnostic challenge for clinicians. Amelanotic melanomas frequently lack the clinical features seen in superficial spreading melanomas, such as asymmetry, irregular borders, and color variegation (i.e., ABC criteria); and they can mimic inflammatory entities, as well as other benign and malignant tumors. The term *amelanotic melanoma* is frequently employed as a clinical description for any melanoma lacking melanin pigmentation. However, to be more precise, there are amelanotic and hypomelanotic melanomas. Pure amelanotic melanomas do not produce any discernable eumelanin, whereas hypomelanotic melanomas produce low levels of eumelanin at least in certain sections of the tumor.

Amelanotic melanomas can present as flat or nodular tumors (Chapter 8c). Nodular amelanotic melanomas are described in Chapter 8c; they tend to lack the classic ABCD criteria for melanoma and present as a pink, elevated, firm, fast-growing tumors (i.e., EFG rule) (5). On the other hand, amelanotic melanomas that are flat or slightly raised present as erythematous macules and plaques, in most cases with well-defined borders, variable border irregularity, with or without ulceration or light brown color at the periphery (7, 9). Not infrequently, nonpalpable amelanotic melanomas display a relatively symmetric silhouette (6). In addition, some of them may reveal epidermal changes such as scale and/or disruption of skin markings (6). Melanomas in advanced stages of regression represent a different entity, as hypopigmentation occurs due to degradation of melanin; thus, they are poorly pigmented or focally depigmented. These tumors are not described in this chapter. Nevertheless, it should be mentioned that they can be distinguished reliably from other types of amelanotic and hypomelanotic melanoma by the dermoscopy features of scarlike depigmentation and peppering granularity (melanophages).

The dermoscopic criteria for amelanotic melanomas rely on the analysis of vascular patterns and shiny white structures, which are only seen with polarized dermoscopy(6, 7, 9). Although amelanotic and hypomelanotic melanomas may appear to have no pigment, only hypomelanotic melanomas may reveal subtle light brown pigmentation under dermoscopy, which is often focally present as peripheral light brown structureless areas. These peripheral tan structureless areas are associated with thin melanomas with a 93.8% positive predictive value (2, 6, 7).

Vascular structures

To have a better visualization of the blood vessels, it is beneficial to apply minimal pressure to avoid blanching the vessels (10). To view vessels, it is strongly recommended to use ultrasound gel or octenidin gel as the contact fluid. Due to its high viscosity, the gel does not flow away, and a good optical contact between the glass plate and the skin surface without pressure can be achieved. The effect of compression can be controlled easily by raising and lowering the pressure of the glass plate upon the skin surface and observing the disappearance and re-filling of the vessels. In addition, noncontact polarized dermoscopy is an alternative to visualize vascular structures, making them more conspicuous and allowing the visualization of shiny white streaks (4).

Assessment of vascular structures comprises the evaluation of three characteristics: (i) The shape of the blood vessels; (ii) the arrangement of the vessels; and (iii) additional features. The additional features include vessels surrounded by a white halo and vessels within a milky-red background. The former are associated with keratinizing tumors and the latter with melanoma. The most common vascular structures observed in melanocytic and nonmelanocytic tumors are described in Tables 8f.1 and 8f.2.

Dotted vessels (short loops) in regular arrangement are highly predictive for a melanocytic lesion (90%, $p < 0.001$) (3). Among the most predictive vascular structures observed in melanomas are predominantly central vessels, hairpin vessels (long loops), milky-red areas, serpentine (previously called linear irregular) vessels, or a combination of two or more morphologies within the same lesion (i.e., polymorphous vessels) (6, 7). The morphology of vessels in melanoma will depend on the stage, tumor growth, and thickness. Vessels in early and thin amelanotic melanomas appear more orderly arranged and homogeneous in shape with a predominant dotted pattern (although dotted vessels by themselves are not predictive of melanoma), as compared with more advanced and thicker tumors, which demonstrate longer, thicker, and more irregular vessels. Hairpin vessels and serpentine vessels are also only observed in tumors with an intermediate thickness (i.e., 0.5–2 mm) (8). Thicker amelanotic melanomas can present with highly irregular and often chaotic vascular structures. Differential diagnoses include pink lesions such as amelanotic Spitz nevi, which can also present with a vascular pattern of dotted vessels; Bowen's disease, which may present with coiled (glomerular vessels); or melanocytic nevi with fibrotic modification and early dermatofibroma. As some of these lesions cannot be distinguished reliably by dermoscopy from early amelanotic melanoma, as a rule, excision is recommended for any pink solitary lesion with this vascular pattern.

Although the presence of the aforementioned vessel morphologies is not 100% specific for amelanotic melanomas, their

TABLE 8F.1: Vascular Structures Most Commonly Seen in and Associated with Melanocytic Tumors[a] (3, 8, 10, 11)

Dermoscopic structures	Morphology	Diagnostic associations	Comment
Comma vessels 	Slightly curved vessels.	Dermal neviCongenital melanocytic nevi	94% PPV for intradermal nevus/congenital
Hairpin vessels 	U shaped loop-like vessels. Not infrequently may be twisted upon its axis.Pink halo common in irritated seborrheic keratosis but can also be seen in melanoma.	Thick melanomas	Nodular melanomas reveal atypical vascular patterns, with the most important single vascular structures being linear irregular vessels and hairpin vessels (8)
Dotted 	Red dots (0.01–0.02 mm).	Spitz nevi and early melanoma (dotted over milky-red background). Clark nevi (dotted over tan background)	90% PPV for a melanocytic skin lesion
Serpentine 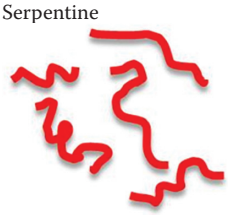	Linear irregular/undulating short vessels.	MelanomaCongenital nevi	67.6% PPV for melanoma
Milky-red globules/vascular blush 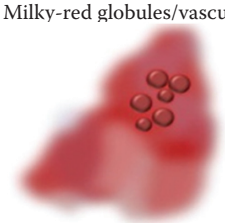	Ill-defined globules of milky-red color and ill-defined areas of milky-red color.	Melanoma, including amelanotic melanoma, desmoplastic melanoma, nodular melanoma	77.8% PPV for melanoma
Polymorphous 	Combination of ≥2 vessel morphologies, the most common combination being dotted and serpentine vessels.	Melanoma, including amelanotic melanoma, desmoplastic melanoma, cutaneous melanoma metastases	52.6% PPV for melanoma
Corkscrew 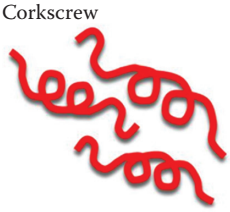	Coiled and tortuous vessels.	Cutaneous melanoma metastases, nodular melanoma, desmoplastic melanoma	

PPV: Positive predictive value

[a] This table highlights vessels that are most commonly associated with melanocytic tumors. However, the presence of a given vessel morphology is not exclusive to a particular diagnosis. For example, dotted vessels can be seen in melanocytic tumors, but they can also be seen in squamous cell carcinoma, porokeratosis, clear cell acanthoma, and dermatoses. Also, although polymorphous vessels are commonly associated with melanoma, they can also be seen in basal cell carcinoma (BCC), stasis dermatitis, etc.

TABLE 8F.2: Vascular structures most commonly seen in nonmelanocytic tumors[a] (3, 10, 11)

Dermoscopic structures	Definition (morphology)	Diagnostic association	Comment
Glomerular vessels 	Coiled vessels mimicking the glomerular apparatus of the kidney.	Bowenoid AK, Bowen disease/ squamous cell carcinoma in situClear cell acanthoma	61.9% PPV for Bowen disease
Hairpin vessels 	U-shaped vessels. Not infrequently may be twisted upon its axis.White halo common in keratinocytic tumors.	Keratinizing tumors such as keratoacanthoma and seborrheic keratosesRarely, basal cell carcinoma (2.6%) (1)	70% PPV for SK
Arborizing 	Vessels with large diameter, branching irregularly into fine capillaries.	Basal cell carcinomaCan also be seen in cysts, furuncles, and other adnexal tumors	94% PPV for BCC
Crown 	Branching or nonbranching vessels radiating toward the center of the lesion but without crossing its center.Often associated with white/yellowish "popcorn"-like globular structures.	Sebaceous hyperplasiaMolluscum contagiosum	83% PPV for sebaceous hyperplasia
Dotted or glomerular in string of pearls or serpiginous distribution 	Vessels distributed in a serpiginous pattern.	Clear cell acanthoma	100% PPV
Strawberry pattern 	Pink to red pseudonetwork. with white-yellow circles (adnexial openings) surrounded by a white halo, over an erythematous background.	Actinic keratosis	

PPV: Positive predictive value

[a] This table highlights vessels that are most commonly associated with nonmelanocytic tumors. However, the presence of a given vessel morphology is not exclusive to a particular diagnosis. For example, arborizing vessels are commonly seen in BCC, but they can also, on rare occasions, be seen in melanoma and intradermal nevi. As another example, although hairpin vessels are commonly associated with seborrheic keratoses, they can also be seen in melanoma.

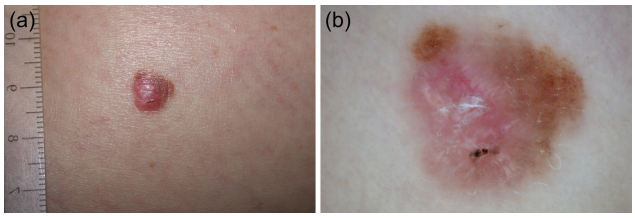

FIGURE 8F.1 (a) Melanoma, clinical image. (b) Partially pigmented melanoma with remnants of pigment network and an amelanotic nodular area typified by milky-red color.

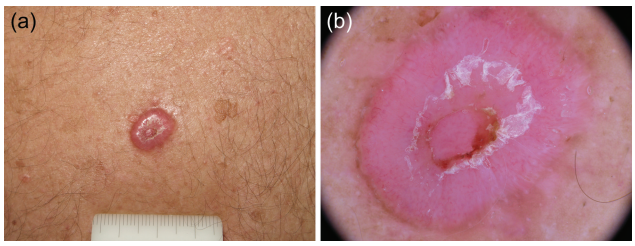

FIGURE 8F.3 (a) Melanoma, clinical image. (b) True amelanotic, ulcerated, nodular melanoma with linear irregular and dotted vessels clearly visible over a milky-red background color.

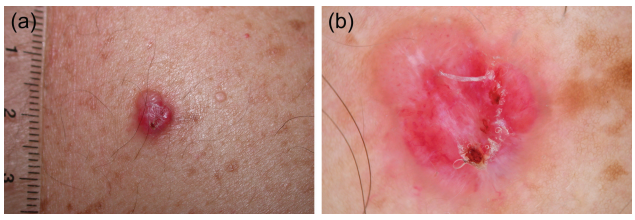

FIGURE 8F.4 (a) Melanoma, clinical image. (b) Amelanotic nodular melanoma typified by polymorphic vessels (combination of dotted, linear irregular, and hairpin vessels) and milky-red areas.

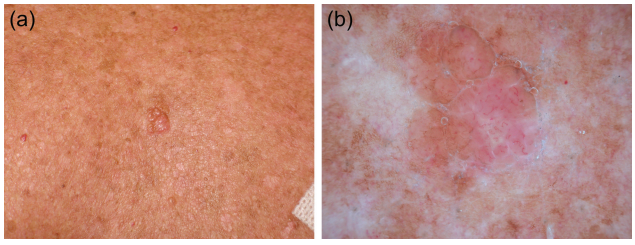

FIGURE 8F.5 (a) Melanoma, clinical image. (b) Hypomelanotic melanoma with linear irregular and hairpin vessels over a milky-red background color.

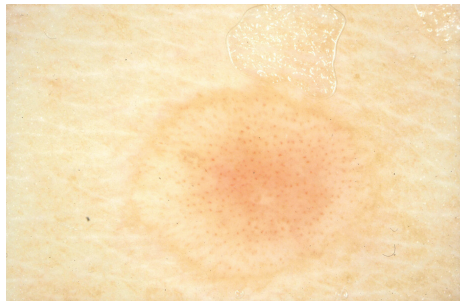

FIGURE 8F.6 Dermoscopy examples of early melanomas showing dotted vessels and variable amount of brown color. (Courtesy of SurPrise e.K., Luebeck, Germany.)

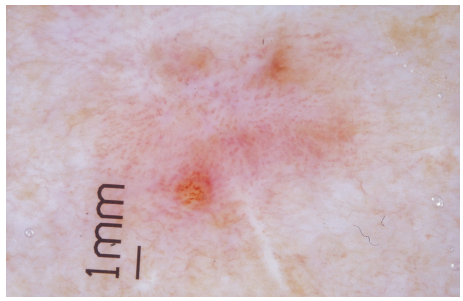

FIGURE 8F.7 Dermoscopy examples of early melanomas showing dotted vessels and variable amount of brown color. (Courtesy of SurPrise e.K., Luebeck, Germany.)

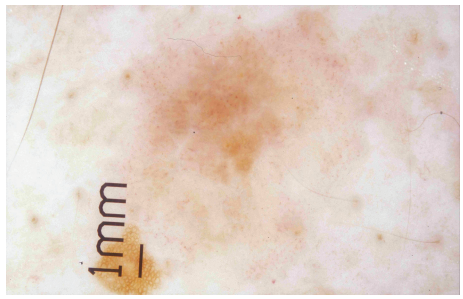

FIGURE 8F.8 Dermoscopy examples of early melanomas showing dotted vessels and variable amount of brown color. (Courtesy of SurPrise e.K., Luebeck, Germany.)

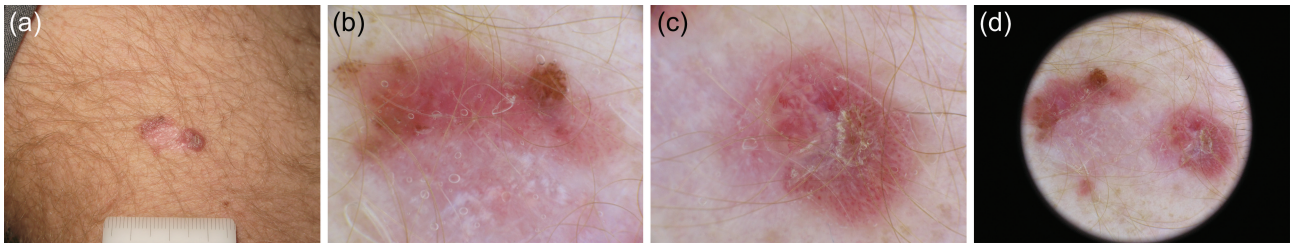

FIGURE 8F.2 (a) Melanoma, clinical image. (b) Partially pigmented, regressive melanoma with remnants of brown network and globules. Milky-red areas together with polymorphic vessels are clearly visible. The latter are typified by a combination of dotted vessels (b, c) and linear irregular and hairpin vessels (Figure 8e.6). A large white scarlike area of regression is also visible (d).

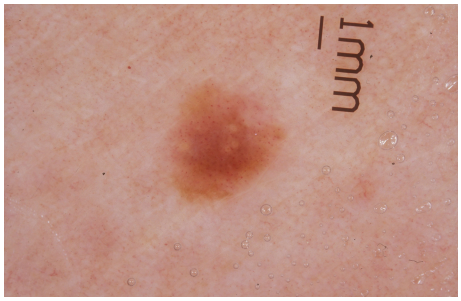

FIGURE 8F.9 Dermoscopy examples of early melanomas showing dotted vessels and variable amount of brown color. (Courtesy of SurPrise e.K., Luebeck, Germany.)

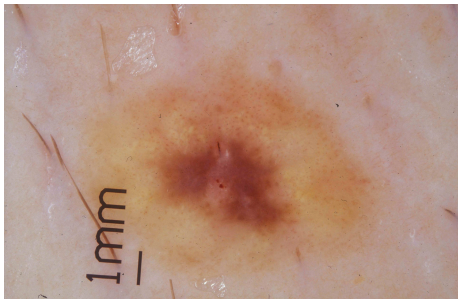

FIGURE 8F.10 Dermoscopy examples of early melanomas showing dotted vessels and variable amount of brown color. (Courtesy of SurPrise e.K., Luebeck, Germany.)

presence in the correct clinical context can be suggestive of melanoma. For example, serpentine/linear irregular vessels and polymorphous vessels have a positive predictive value for melanoma of 67.6% and 52.6%, respectively (3).

Key points

1. It is not uncommon for amelanotic melanomas to present as erythematous symmetric lesions.
2. Consider the diagnosis of an amelanotic melanoma for isolated, pink outlier lesions, even if the lesion does not manifest any of the classic ABCD criteria for melanoma.
3. Vascular structures and shiny white streaks (seen with polarized light) can be the only clues for the diagnosis of amelanotic melanoma.
4. To have a better visualization of the blood vessels, apply minimal pressure to avoid blanching the vessels and/or use noncontact polarized dermoscopy.

The following figures illustrate the diagnosis of amelanotic and hypomelanotic melanoma (Figures 8f.1–8f.12).

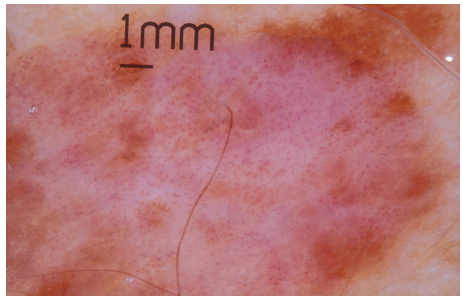

FIGURE 8F.11 Dermoscopy examples of early melanomas showing dotted vessels and variable amount of brown color. (Courtesy of SurPrise e.K., Luebeck, Germany.)

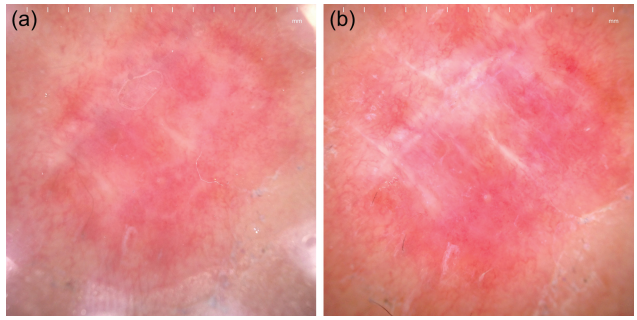

FIGURE 8F.12 Amelanotic melanoma revealing atypical vessels over an erythematous background, and shiny white structures seen with polarized light only (a).

References

1. Altamura D et al. Dermatoscopy of basal cell carcinoma: morphologic variability of global and local features and accuracy of diagnosis. *J Am Acad Dermatol*. Jan 2010;62(1): 67–75. ISSN 1097-6787 (Electronic) 0190-9622 (Linking). Disponível em: http://www.ncbi.nlm.nih.gov/pubmed/19828209.
2. Annessi G et al. Sensitivity, specificity, and diagnostic accuracy of three dermoscopic algorithmic methods in the diagnosis of doubtful melanocytic lesions: the importance of light brown structureless areas in differentiating atypical melanocytic nevi from thin melanomas. *J Am Acad Dermatol*. May 2007;56(5):759–67. ISSN 1097-6787 (Electronic) 0190-9622 (Linking). Disponível em: http://www.ncbi.nlm.nih.gov/pubmed/17316894.
3. Argenziano G et al. Vascular structures in skin tumors: a dermoscopy study. *Arch Dermatol*. Dec 2004;140(12):1485–9. ISSN 0003-987X (Print) 0003-987X (Linking). Disponível em: http://www.ncbi.nlm.nih.gov/pubmed/15611426.
4. Balagula Y et al. The significance of crystalline/chrysalis structures in the diagnosis of melanocytic and nonmelanocytic lesions. *J Am Acad Dermatol*. Aug 2012;67(2):194.e1–8. ISSN 1097-6787. Disponível em: http://www.ncbi.nlm.nih.gov/pubmed/22030020.
5. Chamberlain AJ, Fritschi L, Kelly JW. Nodular melanoma: patients' perceptions of presenting features and implications for earlier detection. *J Am Acad Dermatol*. May 2003;48(5):694–701. ISSN 0190-9622 (Print) 0190-9622 (Linking). Disponível em: http://www.ncbi.nlm.nih.gov/pubmed/12734497.
6. Jaimes N et al. Clinical and dermoscopic characteristics of amelanotic melanomas that are not of the nodular subtype. *J Eur Acad Dermatol Venereol*. May 2012;26(5): 591–6. ISSN 1468-3083 (Electronic) 0926-9959 (Linking). Disponível em: http://www.ncbi.nlm.nih.gov/pubmed/21585561.
7. Menzies SW et al. Dermoscopic evaluation of amelanotic and hypomelanotic melanoma. *Arch Dermatol*. Sep 2008;144(9):1120–7. ISSN 1538-3652 (Electronic) 0003-987X (Linking). Disponível em: http://www.ncbi.nlm.nih.gov/pubmed/18794455.
8. _____. Dermoscopic evaluation of nodular melanoma. *JAMA Dermatol*. Jun 2013;149(6):699–709. ISSN 2168-6084. Disponível em: http://www.ncbi.nlm.nih.gov/pubmed/23553375.

9. Pizzichetta MA et al. Amelanotic/hypomelanotic melanoma: clinical and dermoscopic features. *Br J Dermatol*. Jun 2004;150(6):1117–24. ISSN 0007-0963 (Print) 0007-0963 (Linking). Disponível em: http://www.ncbi.nlm.nih.gov/pubmed/15214897.
10. Zalaudek I et al. How to diagnose nonpigmented skin tumors: a review of vascular structures seen with dermoscopy: part I. Melanocytic skin tumors. *J Am Acad Dermatol*. Sep 2010a;63(3):361–74; quiz 375–6. ISSN 1097-6787 (Electronic) 0190-9622 (Linking). Disponível em: http://www.ncbi.nlm.nih.gov/pubmed/20708469.
11. _____. How to diagnose nonpigmented skin tumors: a review of vascular structures seen with dermoscopy: part II. Nonmelanocytic skin tumors. *J Am Acad Dermatol*. Sep 2010b;63(3):377–86; quiz 387–8. ISSN 1097-6787 (Electronic) 0190-9622 (Linking). Disponível em: http://www.ncbi.nlm.nih.gov/pubmed/20708470.

9A METHODS TO DIFFERENTIATE NEVI FROM MELANOMA: PATTERN ANALYSIS AND MELANOMA-SPECIFIC CRITERIA

Konstantinos Liopyris, Cristian Navarrete-Dechent, Natalia Jaimes, and Ashfaq A. Marghoob

Contents

Pattern analysis 216
Key points 219
References 219

The correct interpretation of the dermoscopic findings in any skin lesion is dependent on the dermoscopist's ability to correctly recognize the presence or absence of specific colors and structures along with their distribution within the lesion. Different structured diagnostic algorithms have been created to guide the observer in their correct interpretation to differentiate benign from malignant neoplasms with a comparable diagnostic accuracy.[1] Usually, these algorithms are best suited for novice dermoscopists, who not infrequently rely on analytic approaches (i.e., identifying specific structures), and thus do not require significant experience to master. The more acquainted the clinician gets with dermoscopy, the less he relies on individual dermoscopic features; thus, as experience is gained, a shift in the thinking process begins to occur, shifting from more analytic approaches to more heuristics approaches, including pattern recognition.[2] The pattern analysis approach requires experience to master, but once mastered, it provides the added benefit of allowing the observer to rapidly evaluate lesions. Interestingly, in a small study, Tschandl et al. showed that when dermoscopy was taught to novices, both ways of teaching had equally good results in increasing diagnostic accuracy (~20%).[3] However, it has been shown that pattern analysis not only reduces the amount of time spent in each lesion but also yields a slightly better diagnostic accuracy as compared with more analytic algorithms.[4–6]

In this chapter, we introduce the reader to the fundamentals of "pattern analysis" for melanocytic lesions.

Pattern analysis

Reliance on pattern analysis to differentiate benign from suspect melanocytic lesions first requires the acknowledgment that the "critical element of becoming an expert is accruing the vast experience that enables experts to recognize patterns effortlessly, most of the time—and to recognize, as well, when the signs and symptoms do not fit a pattern at all."[7] Thus, since benign lesions make up the vast majority of lesions we encounter in daily practice, one approach towards using pattern analysis starts by building experience in recognizing benign patterns of nevi (Chapters 7a-f). Nevi tend to exhibit one of 10 benign patterns (Figure 9a.1, Table 9a.1).[8] Overall, benign patterns tend to demonstrate symmetry of pattern, structure, and color; in other words, they manifest an "organized pattern." Once one is familiarized with nevi patterns, suspicious lesions that deviate from those benign patterns will be easily identified,[9] providing assistance in distinguishing between benign and potentially malignant lesions. Malignant lesions, including melanomas, usually deviate from benign patterns and thus, display some degree of asymmetry of pattern, color, and structure; in other words, they manifest a "disorganized pattern" (Figure 9a.2).

Once the global pattern of the lesion has been evaluated and classified as organized/disorganized and symmetric/asymmetric, the lesion is then evaluated for the presence or absence of melanoma-specific features. Most melanomas are easily recognized on dermoscopy based on the presence of a disorganized pattern and the presence of at least one melanoma-specific structure. (Table 9a.2).[10] However, there are some melanomas that will display an organized pattern, yet the recognition of at least one melanoma-specific structure or a blue-black or gray color under dermoscopy will raise suspicion for melanoma.[11, 12] Therefore, dermoscopic asymmetry by itself is not a prerequisite for the diagnosis of melanoma, as exemplified by those melanomas that manifest dermoscopic symmetry, such as amelanotic melanoma and nodular melanoma, among others (see Chapter 8e on difficult to diagnose melanomas—other melanomas). Lastly, there is a subset of flat, feature-poor or featureless/structureless melanomas, which may prove challenging to diagnose; however, dermoscopy provides useful information by identifying changes over time (i.e., digital monitoring), which allows their correct identification. Interestingly, preliminary data suggest that agreement on the presence and spatial localization of melanoma-specific structures is poor even among experts (unpublished data), yet their presence increases the possibility of malignancy. For example, irregular dots may be confused with irregular globules; however, the heterogeneity in size, shape, and color of the structure, and their chaotic distribution, will raise suspicion for melanoma irrespective of whether the observer classifies the structure as a dot or as a globule.

Overall, dermoscopic evaluation of skin lesions entails the utilization of both heuristic and analytic approaches, which are used in an interactive fashion to correctly classify lesions as benign or malignant. Nonanalytic reasoning, as exemplified by "pattern recognition," is essential to diagnostic expertise, and this skill is developed through practice and clinical experience. Deliberative analytic reasoning is the primary strategy when a case is complex or ill defined, the clinical findings are unusual,

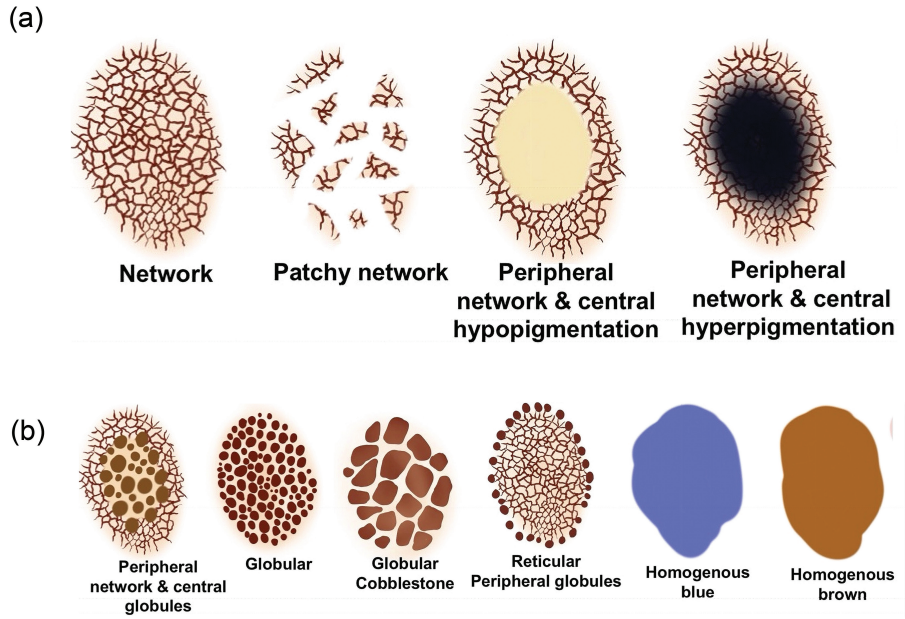

FIGURE 9A.1 Patterns of "benign" nevi.

TABLE 9A.1: The 10 Benign Nevus Patterns

Global pattern	Definition
Reticular diffuse	Diffuse homogeneous network with relatively uniform thickness and color of the network lines. The holes of the network are of relatively uniform size. The network tends to fade at the periphery. This pattern is frequently seen in acquired nevi and small congenital nevi located on the extremities.
Reticular patchy	Homogeneous network with relatively uniform thickness and color of the network lines. The network is present in focal patches distributed in an organized manner separated by homogeneous structureless areas that are lighter in color than the network lines. The structureless areas have the same color as background skin or are slightly darker than the background skin. This pattern is commonly seen in acquired nevi located on the torso and in superficial congenital nevi, especially those located on the lower extremity.
Peripheral reticular with central hypopigmentation	A relatively uniform network at the periphery of the lesion with a central homogeneous and hypopigmented (relative to the color of the network) structureless area. The structureless area has the same color as background skin or is slightly darker than the background skin (but lighter in color compared with the network lines). This type of acquired nevus is more common in individuals with a fair skin phenotype.
Peripheral reticular with central hyperpigmentation	A relatively uniform network at the periphery of the lesion with a central homogeneous, hyperpigmented structureless area or blotch. The blotch has a darker color as compared with the network lines. This type of acquired nevus is more common in individuals with a darker skin phenotype.
Homogeneous tan, brown, or blue pigmentation (sometimes pink)	Primarily consists of a diffuse homogeneous structureless pattern. On occasion, a few globules and/or small focal network fragments may be evident. When the nevi are tan in color, they usually represent acquired nevi in individuals with fair skin phenotypes. When darker brown in color, they usually represent congenital nevi. When blue in color, they represent blue nevi. Nevi in very fair-skinned individuals (including redheads) can manifest a homogeneous pink pattern (NB: amelanotic and hypomelanotic melanomas can manifest in a similar manner; however, most melanomas will also reveal atypical blood vessels and/or shiny white structures).
Peripheral reticular with central globules	A relatively uniform network at the periphery of the lesion with central globules. The histopathology features of these nevi are often the same as those used to describe congenital nevi.
Peripheral globules with central network or homogeneous area and the starburst pattern	The central component of this type of nevus is either reticular or homogeneous. When there is one row of relatively uniform brown globules surrounding the entire perimeter of the lesion, it represents a Clark's nevus that is in its active radial growth phase (i.e., has not yet undergone senescence). When the globules at the perimeter are tiered (more than one row of globules), then the pathology will usually reveal a spitzoid morphology. The classic starburst pattern consists of streaks (radial streaming or pseudopods) present around the entire perimeter of the lesion, giving the appearance of an exploding star. The starburst pattern is seen in Spitz/Reed nevi that are in their active radial growth phase.
Globular (includes cobblestone)	Globules of similar shape, size, and color that are distributed symmetrically throughout the lesion. Globules are usually round to oval in shape. However, sometimes, the globules are large and appear to be compressing each other, creating angulated shapes reminiscent of cobblestones. This pattern is seen most commonly in congenital nevi.
Two component	These lesions reveal two different patterns (reticular-globular, reticular-homogeneous, or globular-homogeneous). One half of the lesion manifests one pattern, while the other half of the lesion manifests a different pattern.
Multicomponent	Two definitions exist for the multicomponent pattern. NB: Only the first definition applies to benign nevi. 1. Organized and/or symmetrically distributed typical dots/globules, typical network, and homogeneous areas. This is the pattern associated with benign nevi. The axis of symmetry need only be in one axis. 2. Symmetrically distributed globules, network, blotches, dots, veil, regression structures, and/or structureless areas. Three or more structures are required to classify the lesion as multicomponent. NB: Although a symmetric multicomponent pattern speaks in favor of a benign nevus, any lesion displaying a multicomponent pattern other than as described in the first definition should be viewed with caution and evaluated in context with the other nevi in the patient (comparative approach). If it is the patient's signature pattern, then it can be followed. If it is an outlier, then consideration should be given to biopsying the lesion.

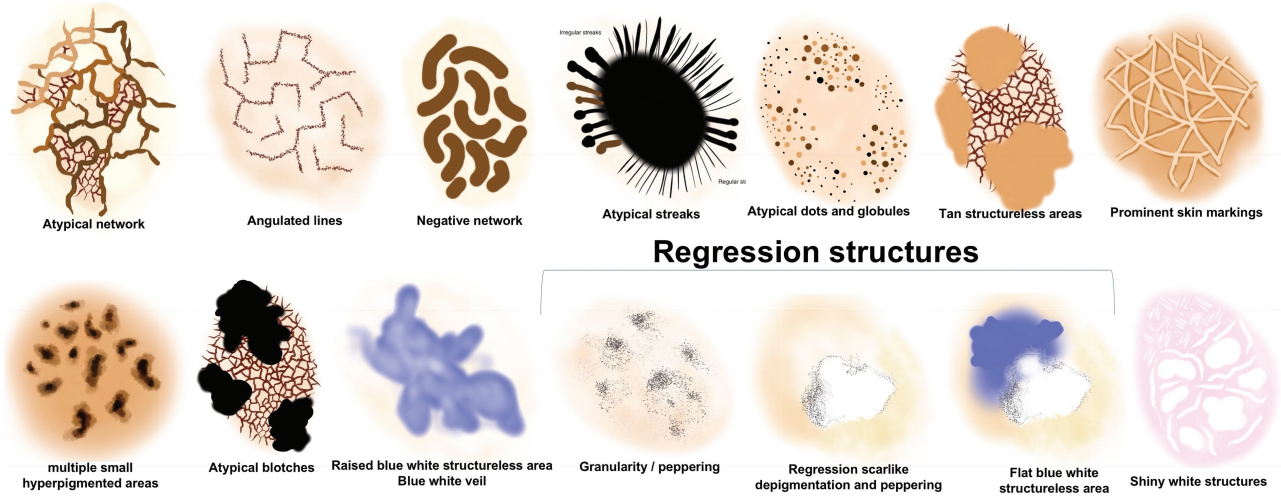

FIGURE 9A.2 Melanoma-specific structures.

TABLE 9A.2: Melanoma-Specific Criteria

Dermoscopic Feature	Definition	Histopathologic Correlate
Atypical Pigment Network	Network with increased variability in the color, thickness, and spacing of the lines of the network; asymmetrically distributed	Lines are caused by pigmented keratinocytes or melanocytes along the dermo-epidermal junction; spaces between the lines (holes) correspond to the suprapapillary plate
Negative Pigment Network	Serpiginous interconnecting broadened hypopigmented lines that surround elongated and curvilinear globules. Can be identified in de novo melanomas but is also common in melanomas arising in pre-existing nevi	Corresponds to distorted and attenuated rete ridges containing confluent and nested melanocytes along the dermo-epidermal junction (corresponds to brown elongated and curvilinear globular structures). This atypical area is flanked by elongated and widened rete ridges (corresponding to the serpiginous hypopigmented areas)
Angulated Lines	Gray to brown lines that meet at acute angles creating a zig-zag pattern. These lines can coalesce to form polygons such as rhomboids. The lines can appear as a solid line or as a line composed of gray dots (pointillism). This feature is mainly seen in melanoma on sun-damaged skin (lentigo maligna)	Histopathology shows a constellation of findings including flattening of the dermo-epidermal junction, confluent melanocytes along the dermo-epidermal junction, and melanophages in the papillary dermis
Globules/Clods, Irregular	Clods, round or oval, with heterogeneity in size, shape, and/or color	Nests of nevomelanocytes at the dermo-epidermal junction or dermis
Dots, Irregular	Dots, black or brown with heterogeneity in color and off-center distribution. These dots are often found in association with an atypical network or are found towards the periphery of melanoma	Aggregates of melanocytes or melanin granules; if black, in stratum corneum; if brown, in epidermis below the stratum corneum
Streaks (Always at the Periphery): Radial Streaming, Pseudopods	Radial streaming: Lines, radial and segmental; pseudopods: Lines, radial and segmental with bulbous projections at their tips	Confluent junctional nests of melanocytes at the periphery of the lesion
Blotch, Irregular	Structureless zone with so much brown-black-blue pigment that it obscures the ability to see any other structures in the area. Blotches are classified as irregular if they are located off-center or if the lesion has multiple blotches	Aggregates of melanin in the stratum corneum or throughout all layers of the epidermis with or without dermal involvement
Regression Structures: Peppering/Granularity	Dots with gray color	Corresponds to free melanin or melanophages in the papillary dermis
Regression Structures: Scarlike Depigmentation	White structureless zone; has a lighter color than the surrounding normal skin, usually seen in association with peppering	Fibrotic papillary dermis
Shiny White Structures (Only Seen with Polarized Dermoscopy)	Shiny white lines that are oriented parallel and orthogonal to each other. They can sometimes coalesce to create grid of square-shaped white-lined structures. This should not be confused for a negative network, which can be seen in both nonpolarized and polarized dermoscopy	Altered matrix collagen and dermal fibroplasia
Blue-Whitish Veil	Structureless zone, blue with a white "ground glass" haze found over a raised area that does not occupy the entire lesion	Heavily pigmented dermal melanocytes combined with compact orthokeratosis
Polymorphous Vessels	Vessels with more than one morphology, usually consisting of dotted and linear serpentine vessels plus any other vessel morphology	Tumoral neo-angiogenesis in the dermis

or the physician has had little clinical experience with the particular disease entity. [7]

Key points

1. Nevi tend to manifest one of 10 benign patterns (Figure 9a.1 and Table 9a.1). The colors and structures in nevi tend to be distributed in an organized and symmetric fashion.
2. Any melanocytic neoplasm that manifests a pattern that deviates from the benign patterns shown in Figure 9a.1 should be viewed with caution.
3. Any lesion that deviates from the benign patterns listed in Table 9a.1 and manifests at least one of the melanoma-specific structures listed in Table 9a.2 should be considered a melanoma until proven otherwise.

References

1. Carrera C, Marchetti MA, Dusza SW, et al. Validity and reliability of dermoscopic criteria used to differentiate nevi from melanoma. *JAMA Dermatol*. 2016;152:798–20.
2. Scope A, Braun RP. The recognition process in dermoscopy: analytic approach vs heuristic approach. *JAMA Dermatol* 2015;151:704–6.
3. Tschandl P, Kittler H, Schmid K, Zalaudek I, Argenziano G. Teaching dermatoscopy of pigmented skin tumours to novices: comparison of analytic vs. heuristic approach. *J Eur Acad Dermatol Venereol*. 2014;29:1198–204.
4. Argenziano G, Soyer HP, Chimenti S, et al. Dermoscopy of pigmented skin lesions: Results of a consensus meeting via the Internet. *J Am Acad Dermatol*. 2003;48:679–93.
5. Carli P, De Giorgi V, Palli D, et al. Dermatologist detection and skin self-examination are associated with thinner melanomas: results from a survey of the Italian Multidisciplinary Group on Melanoma. *Arch Dermatol* 2003;139:607–12.
6. Annessi G, Bono R, Sampogna F, Faraggiana T, Abeni D. Sensitivity, specificity, and diagnostic accuracy of three dermoscopic algorithmic methods in the diagnosis of doubtful melanocytic lesions. *J Am Acad Dermatol*. 2007;56:759–67.
7. Norman G. Building on experience: the development of clinical reasoning. *N Engl J Med*. 2006;355:2251–2.
8. Braun DR, Hofmann R, Marghoob A. Benign nevi pattern: dermoscopedia. 2021.
9. Marghoob AA, Korzenko AJ, Changchien L, Scope A, Braun RP, Rabinovitz H. The beauty and the beast sign in dermoscopy. *Dermatol Surg*. 2007;33:1388–91.
10. Yelamos O, Braun RP, Liopyris K, et al. Dermoscopy and dermatopathology correlates of cutaneous neoplasms. *J Am Acad Dermatol*. 2019;80:341–63.
11. Rogers T, Marino M, Dusza SW, Bajaj S, Marchetti MA, Marghoob A. Triage amalgamated dermoscopic algorithm (TADA) for skin cancer screening. *Dermatol Pract Concept*. 2017;7:39–46.
12. Rogers T, Marino ML, Dusza SW, et al. A clinical aid for detecting skin cancer: the triage amalgamated dermoscopic algorithm (TADA). *J Am Board Fam Med*. 2016;29:694–701.

9B METHODS TO DIFFERENTIATE NEVI FROM MELANOMA: RULES AND ALGORITHMS

Natalia Jaimes

Contents

ABCD rule of dermoscopy 220
Menzies method 220
The seven-point checklist 220
CASH algorithm (10) (Table 9b.4) 221
Summary 222
References 223

Dermoscopic diagnosis involves the recognition of specific structures to rule out or confirm a given diagnosis. Toward this end, several algorithms and rules haven been created to guide the observer in the dermoscopic decision-making process, with the ultimate goal of differentiating benign from suspicious or malignant lesions. This chapter will review different algorithms and scoring systems, including the ABCD rule of dermoscopy, the Menzies method, the seven-point checklist, and the color, architecture, symmetry, and homogeneity (CASH) algorithm.

ABCD rule of dermoscopy

The ABCD rule of dermoscopy is a semi-quantitative scoring system created by Stolz and colleagues in 1994 for the evaluation of pigmented lesions. It analyzes four criteria, including Asymmetry, Border sharpness, Colors, and Dermoscopic structures (Table 9b.1) (1).

- **Asymmetry** refers to the contour and distribution of colors and structures within the lesion in none, one, or two perpendicular axes. In contrast to other rules and algorithms, the ABCD rule of dermoscopy and the CASH algorithm are the only methods that take into account the contour and content of the lesion during the evaluation of asymmetry.
- **Border sharpness** refers to the abrupt cutoff of pigmentation at the perimeter. Border sharpness is evaluated tracing four imaginary lines that divide the lesion into eight pie-shaped sections.

  A score of 1 is given to each segment presenting with an abrupt cutoff of pigment.
- **Colors** include white, red, light brown, dark brown, blue-gray, and black. A score of 1 is given to each color that is present in the lesion.
- **Dermoscopic structures:** The lesion is evaluated for the presence of any of the following five structures: Pigment network, branched streaks, dots, globules, and homogeneous areas. Homogeneous or structureless areas include hyperpigmented blotches, hypopigmented areas, depigmented or scarlike areas that involve more than 10% of the surface area of the lesion.

The score for each of the four criteria is multiplied by a weighted factor. Subsequently, the four scores are added to obtain the final dermoscopy score (Table 9b.1). Sensitivity and specificity for the ABDC rule of dermoscopy are 78–90% and 45–90%, respectively (1–6).

Menzies method

The Menzies method was developed to differentiate invasive melanomas from other pigmented lesions (7). This method evaluates 11 dermoscopic criteria, which are classified into negative and positive features for melanoma. The two negative features have demonstrated a low sensitivity for melanoma, whereas the nine positive features have a high specificity for melanoma (>85%) (Table 9b.2).

- **Negative features** (2) include symmetry of the pattern and the presence of only one color (black, gray, blue, red, dark brown, or tan).
- **Positive features** (9) include blue-white veil, multiple brown dots, pseudopods, radial streaming, scarlike depigmentation, peripheral black dots/globules, broadened network, multiple blue/gray dots, and multiple (five to six) colors.

The presence of both negative features excludes the diagnosis of melanoma. In contrast, the presence of any positive feature raises the suspicion for melanoma. The Menzies method has a sensitivity of 85–92% and a specificity of 38–78% among examiners with various degrees of experience (2, 4, 7, 8, 13).

The seven-point checklist

The seven-point checklist evaluates seven dermoscopic features that are frequently associated with melanoma. These features are categorized into major and minor criteria (3) (Table 9b.3).

- **Major criteria** (3) include atypical pigment network, blue-whitish veil, and atypical vascular pattern. Two points are given to each major criterion that is present in the lesion. Therefore, the score for major criteria ranges between 0 and 6 points.
- **Minor criteria** (4) include irregular streaks, irregular dots/globules, irregular blotches, and regression structures. One point is given to each criterion that is present in the lesions. As a result, the score ranges between 0 and 4 points.

A final score of three or more is suggestive of melanoma (3). This final score is calculated by adding the major and minor criteria scores. The seven-point checklist has a sensitivity of 62–95% and a specificity of 35–97% among experts and nonexperts (2–6).

TABLE 9B.1: The ABCD Rule of Dermoscopy[a]

	Criteria	Points	Multiply points by factor	FDS* range
Asymmetry	No asymmetry	0	**×1.3**	**0–2.6**
	Mono-axial asymmetry	1		
	Bi-axial asymmetry	2		
Border	No sharp border	0	**×0.1**	**0–0.8**
	One segment with sharp border	1		
	Two segments with sharp border	2		
	Three segments with sharp border	3		
	Four segments with sharp border	4		
	Five segments with sharp border	5		
	Six segments with sharp border	6		
	Seven segments with sharp border	7		
	Eight segments with sharp border	8		
Color	White	1	**×0.5**	**0.5–3**
	Red	1		
	Light brown	1		
	Dark brown	1		
	Blue-gray	1		
	Black	1		
Dermoscopic structure	Network	1	**×0.5**	**0.5–2.5**
	Aggregated globules	1		
	Dots	1		
	Structureless areas	1		
	Branched streaks	1		
FDS[b] range				**0.5–8.5**

[a] See further Stolz, W., et al., *Eur J Dermatol*, 4, 521–517, 1994.
[b] FDS: Final Dermoscopy Score: <4.75 = benign; 4.75 to 5.45 = suspicious; > 5.45 = malignant.

TABLE 9B.2: Menzies Method

	Criteria	Description
Negative Features *Neither* can be present in melanoma	Symmetrical pigmentation pattern	Symmetric pigment pattern across all axes
	Presence of only one color	Tan Dark brown Black Gray Blue Red
Positive Features At least *one* feature has to be present to consider a melanoma	Multiple colors	Presence of five or more of the above colors
	Blue-white veil	Irregular and confluent blue pigmentation with an overlying white "ground glass" film, not associated with red-blue lacunae
	Multiple brown dots	Aggregations of dark brown dots, usually within the body of the lesion
	Multiple blue/gray dots	Diffuse, partly aggregated dots, "pepper-like" in appearance
	Peripheral black dots or globules	Black dots or globules at or near the edge of the lesion
	Broadened network	Pigment network with areas of thick grids
	Pseudopods	Finger-like projections with small knobs at their tips, which are directly connected to the tumor body or the pigment network
	Radial streaming	Radial and asymmetric linear extensions at the edge of the lesion
	Scarlike depigmentation	White, irregular area of depigmentation

See further Menzies, S.W., et al., *Arch Dermatol*, 132(10), 1178–1182, 1996, and Menzies, S.W., et al., *Melanoma Res*, 6(1), 55–62, 1996.

A revised version of the seven-point checklist proposes that the presence of any of the minor or major criteria is sufficient to consider a lesion suspicious for melanoma (9). This revised seven-point checklist lowered the threshold for biopsy, using a total score of 1 instead of 3. As a result, a higher sensitivity is achieved but at the cost of a lower specificity. The authors acknowledge that a sensitive and specific method to diagnose melanoma requires that other factors and context be taken into account during the examination. This includes the clinical characteristics of the lesion, age and skin type of patient, location of lesion, whether the lesion is an outlier lesion (i.e., comparative approach), or if the lesion has changed during follow-up.

CASH algorithm (10) (Table 9b.4)

- Color: Refers to the presence of few or many colors
- Architectural disorder: Refers to order versus disorder in the distribution of dermoscopic structures within the lesion

TABLE 9B.3: The Seven-Point Checklist[a]

Criteria		Definition	Score	
			Classic[b]	Revised[c]
Major Criteria	Atypical pigment network	Prominent (hyperpigmented or thick) and irregular network.	2	1
	White-blue areas	Irregular, structureless white-blue area with an overlying "ground glass" film. It cannot occupy the entire lesion.	2	1
	Atypical vascular pattern	Linear irregular or dotted vessels, irregularly distributed outside areas of regression.	2	1
Minor Criteria	Radial streaming (streaks)	Radial and asymmetric linear or bulbous projections at the edge of the lesion.	1	1
	Irregular blotches	Black, brown, and/or gray structureless areas with irregular shape or distribution.	1	1
	Irregular dots and globules	Black or brown round structures irregularly distributed.	1	1
	Regression structures	White scarlike depigmentation and/or "peppering."	1	1

[a] See further Menzies, S.W., et al., *Arch Dermatol*, 132(10), 1178–1182, 1996, and Argenziano, G., et al., *Br J Dermatol*, 2010.
[b] Classic seven-point checklist: For the diagnosis of melanoma, a total score of 3 or more is required.
[c] Revised seven-point checklist: The threshold for excision is 1 point (rather than 3 points).

TABLE 9B.4: CASH Algorithm[a]

Criteria		Score[b]
Color	Light brown	1
	Dark brown	1
	Brown	1
	Red	1
	White	1
	Blue	1
Architectural disorder	None/mild Colors and dermoscopic structures are distributed in an organized or slightly disordered manner.	0
	Moderate The dermoscopic structures lose their uniformity and are distributed in an irregular manner.	1
	Marked The arrangement of colors and dermoscopic structures is completely disorganized (chaotic).	2
Symmetry (Taking into account shape and dermoscopic structures)	Bi-axial symmetry	0
	Mono-axial symmetry	1
	Bi-axial asymmetry	2
Homogeneity/heterogeneity of dermoscopic structures	Network	1
	Dots/globules	1
	Steaks/pseudopods	1
	Blue-white veil	1
	Regression structures	1
	Blotches	1
	Polymorphous vessels	1

[a] See further Henning, J.S., et al. *J Am Acad Dermatol*, 56(1), 45–52, 2007.
[b] A total score of 8 or more is suggestive of melanoma (10).

- Symmetry: Refers to the shape and pattern of the lesion
- Homogeneity or Heterogeneity: Refers to the number of dermoscopic structures

A total CASH score of 8 or more is considered suspicious of melanoma (range 2–17) (10). The sensitivity and specificity for the CASH algorithm are 87–98% and 67–68%, respectively (10, 11).

Summary

The ABCD rule for dermoscopy, the Menzies method, the seven-point checklist, and the CASH algorithm are relatively simple, accurate, and reproducible methods that can be used during the dermoscopic evaluation of skin lesion (3, 12). Although all have a similar sensitivity, methods that rely on pattern analysis (see Chapters 4a and 4b) demonstrate a superior specificity, being the preferred methods utilized by experienced clinicians (2) (Table 9b.5).

A final issue that should be underscored is that none of the aforementioned algorithms has been updated since the time of their original publication. Many new melanoma-specific structures have, however, been identified over the past few years, including shiny white lines, negative network, and angulated lines. These more newly identified melanoma-specific structures should not be ignored by clinicians electing to use one of these algorithms. It still needs to be determined how these algorithms will perform with the addition of the new insights gained over the past decade.

TABLE 9B.5: Diagnostic Accuracy of Different Dermoscopic Algorithms

Algorithm/Rule	Sensitivity (%)		Specificity (%)		Diagnostic Accuracy (%)
	Amelanotic Melanoma	Pigmented Melanoma	Experts	Nonexperts	
ABCD Rule (1, 2, 4–6, 11, 14, 15)		78–98	70–90	45–80	56–78
Menzies Method (2, 7, 8, 11, 14, 15)	54	86–95	71–78	38–76	83
Seven-Point Checklist (2, 3, 5, 6, 8, 9, 11, 14–16)	41	62–95	71–87	35–97	16–88
Revised Seven-Point Checklist (9)		88	75		
CASH Algorithm (10, 11)		87–98	68	67	
Pattern Analysis (2, 5, 6, 9, 15)		82–85	79–88	61–79	68–71

References

1. Stolz W, Riemann A, Cognetta A, et al. ABCD rule of dermoscopy: a new practical method for early recognition of maligant melanoma. *Eur J Dermatol.* 1994;4:521–17.
2. Argenziano G, Soyer HP, Chimenti S, et al. Dermoscopy of pigmented skin lesions: results of a consensus meeting via the Internet. *J Am Acad Dermatol.* 2003;48(5):679–93.
3. Argenziano G, Fabbrocini G, Carli P, De Giorgi V, Sammarco E, Delfino M. Epiluminescence microscopy for the diagnosis of doubtful melanocytic skin lesions. Comparison of the ABCD rule of dermatoscopy and a new 7-point checklist based on pattern analysis. *Arch Dermatol.* 1998;134(12):1563–70.
4. Dolianitis C, Kelly J, Wolfe R, Simpson P. Comparative performance of 4 dermoscopic algorithms by nonexperts for the diagnosis of melanocytic lesions. *Arch Dermatol.* 2005;141(8):1008–14.
5. Annessi G, Bono R, Sampogna F, Faraggiana T, Abeni D. Sensitivity, specificity, and diagnostic accuracy of three dermoscopic algorithmic methods in the diagnosis of doubtful melanocytic lesions: the importance of light brown structureless areas in differentiating atypical melanocytic nevi from thin melanomas. *J Am Acad Dermatol.* 2007;56(5):759–67.
6. Carli P, Quercioli E, Sestini S, et al. Pattern analysis, not simplified algorithms, is the most reliable method for teaching dermoscopy for melanoma diagnosis to residents in dermatology. *Br J Dermatol.* 2003;148(5):981–4.
7. Menzies SW, Ingvar C, Crotty KA, McCarthy WH. Frequency and morphologic characteristics of invasive melanomas lacking specific surface microscopic features. *Arch Dermatol.* 1996;132(10):1178–82.
8. Menzies SW, Kreusch J, Byth K, et al. Dermoscopic evaluation of amelanotic and hypomelanotic melanoma. *Arch Dermatol.* 2008;144(9):1120–7.
9. Argenziano G, Catricala C, Ardigo M, et al. Seven-point checklist of dermoscopy revisited. *Br J Dermatol.* 2010.
10. Henning JS, Dusza SW, Wang SQ, et al. The CASH (color, architecture, symmetry, and homogeneity) algorithm for dermoscopy. *J Am Acad Dermatol.* 2007;56(1):45–52.
11. Henning JS, Stein JA, Yeung J, et al. CASH algorithm for dermoscopy revisited. *Arch Dermatol.* 2008;144(4):554–5.
12. Kittler H, Pehamberger H, Wolff K, Binder M. Diagnostic accuracy of dermoscopy. *Lancet Oncol.* 2002;3(3):159–65.
13. Menzies SW, Ingvar C, McCarthy WH. A sensitivity and specificity analysis of the surface microscopy features of invasive melanoma. *Melanoma Res.* 1996;6(1):55–62.
14. Blum A, Rassner G, Garbe C. Modified ABC-point list of dermoscopy: a simplified and highly accurate dermoscopic algorithm for the diagnosis of cutaneous melanocytic lesions. *J Am Acad Dermatol.* 2003;48(5):672–8.
15. Pagnanelli G, Soyer HP, Argenziano G, et al. Diagnosis of pigmented skin lesions by dermoscopy: web-based training improves diagnostic performance of non-experts. *Br J Dermatol.* 2003;148(4):698–702.
16. Haenssle HA, Korpas B, Hansen-Hagge C, et al. Seven-point checklist for dermatoscopy: performance during 10 years of prospective surveillance of patients at increased melanoma risk. *J Am Acad Dermatol.* 2010;62(5):785–93.

9C METHODS TO DIFFERENTIATE NEVI FROM MELANOMA: RULES TO AVOID MISSING A MELANOMA

Gabriella Brancaccio, Teresa Russo, Elvira Moscarella, and Giuseppe Argenziano

Contents

Rule #1: Look at all or as many lesions as possible . . . 224
Rule #2: Undress high-risk patients. . . . 224
Rule #3: Use the 10 second rule when evaluating single lesions . . . 225
Rule #4: Compare and monitor multiple moles . . . 225
Rule #5: Excise doubtful nodular lesions . . . 226
Rule #6: Excise lesions revealing spitzoid features in post-pubertal patients . . . 226
Rule #7: Combine clinical, dermoscopic, and histologic criteria. . . . 226
References . . . 228

Dermoscopy significantly improves the sensitivity and specificity for melanoma diagnosis. The dual benefit of dermoscopy allows the detection of clinically inconspicuous melanomas and enables the recognition of benign lesions that clinically mimic cutaneous malignancy, thereby reducing the number of unnecessary biopsies.

The classic approach for rendering a diagnosis using dermoscopy is the so-called pattern analysis method [1]. Pattern analysis is a qualitative assessment procedure that evaluates the global pattern of the lesion, followed by assessment for the presence or absence of focal features associated with nevi or melanomas. With pattern analysis, the evaluator renders a decision taking into account both global and local features without using any scoring system. Pattern analysis has the advantage of taking into consideration all the available morphologic information but has the disadvantage of being highly subjective, not well reproducible, and dependent on the experience of the clinician. To overcome these limitations, several semi-quantitative methods have been developed, including the ABCD rule, the Menzies method, the CASH method, and the seven-point checklist. These algorithms are relatively simple and easy to use, are more objective, achieve good diagnostic accuracy, and can be used by nonexperts.

For all the analytically based scoring algorithms, a given pigmented lesion must first be classified as either a melanocytic tumor (nevus vs. melanoma) or a non-melanocytic tumor (e.g., seborrheic keratosis, basal cell carcinoma [BCC], squamous cell carcinoma [SCC], angioma, dermatofibroma [DF]). Only once the diagnosis of a nonmelanocytic lesion is ruled out and the lesion in question is determined to be of melanocytic origin can it be evaluated via one of the aforementioned algorithms.

The seven-point checklist is one of the analytically based diagnostic algorithms that provides a quantitative scoring system requiring the observer to identify a limited number of structures [2]. This method is based on identifying three major (atypical pigment network, blue-white veil, atypical vascular pattern) and four minor criteria (irregular streaks, irregular dots and globules, irregular blotches, and regression structures). A score of three or more classifies the lesion as suspicious for melanoma. The seven-point checklist method can be further simplified by considering lesions suspicious for melanoma if they reveal any one of the seven criteria.

While the above-mentioned algorithms have improved our ability to detect melanoma, some melanomas remain difficult to diagnose. Experience has assisted us in recognizing seven rules that further enhance our ability to detect melanomas, including those that fail to be detected via conventional methods [3].

Rule #1: Look at all or as many lesions as possible

Melanoma may clinically mimic a wide range of benign melanocytic and nonmelanocytic skin lesions. In particular, some early and small melanomas may lack the classic clinical ABCD criteria and can resemble a benign nevus. On the other hand, thick melanomas such as nodular melanomas may mimic an intradermal nevus, a pyogenic granuloma, or a dermatofibroma. In all these cases, dermoscopy may add useful information to the clinical assessment, as dermoscopic criteria of melanoma usually become apparent before the clinical ABCD criteria become manifest. This is especially relevant for early melanomas like the one presented in Figure 9c.1, in which the small size and clinical characteristics do not raise any suspicion for malignancy. However, dermoscopy reveals clear-cut features of melanoma.

Moreover, in the context of patients with multiple nevi, examining all lesions is the only way to help detect melanomas displaying a clinical morphology resembling a nevus (Figure 9c.2). While opponents of the technique of examining all nevi argue that this process is burdensome, time-consuming, and cost-ineffective, experienced dermoscopists have shown that dermoscopic examination of all nevi adds very little extra time (2 min) to a routine examination [4].

Rule #2: Undress high-risk patients

One recommended method to facilitate detection of early-stage melanoma and nonmelanoma skin cancer, particularly in high-risk patients such as those with a personal or family history of skin cancer, is total body skin examination

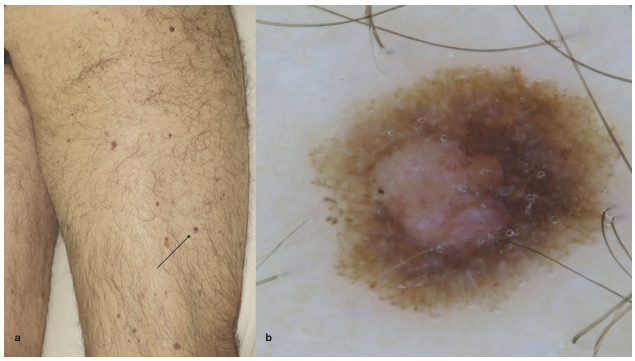

FIGURE 9C.1 Superficial spreading melanoma arising on the leg of a 40-year-old man. The lesion was flat, macular, and small in diameter, with no suspicious clinical features (a). Under dermoscopy, clear-cut melanoma features were evident, including asymmetry, irregular globules, and an eccentric amelanotic component (b). To maximize sensitivity for melanoma, the dermoscopic examination should include evaluation of all lesions, without clinical preselection of only the clinically suspicious ones.

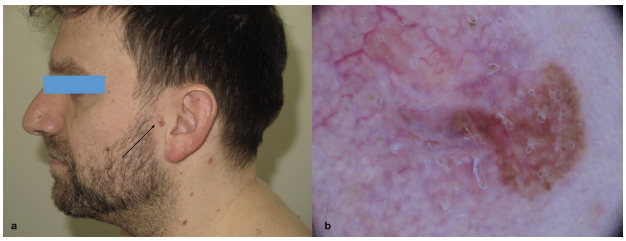

FIGURE 9C.2 Nevus-associated melanoma in a patient with multiple nevi and a history of melanoma. The lesion in the preauricular region was clinically inconspicuous, resembling a dermal nevus (a). On dermoscopy, the lesion was highly asymmetrical, with serpentine vessels, eccentric hyperpigmentation, and structureless areas (b).

(TBSE). TBSE involves a visual inspection of the patient's complete body surface for lesions suggestive of skin cancer. The American Cancer Society guidelines recommend that cancer-related screening, including skin examination, be part of a general periodic health examination [5]. However, it has been reported that only about 30% of dermatologists perform TBSE on all their patients. A study assessing the risk of missing a skin cancer found that several patient factors were significantly associated with an increased chance of finding a skin cancer if a TBSE was performed. These factors include older age, male gender, previous history of nonmelanoma skin cancer, fair skin type, skin tumor as the reason for consultation, and presence of an equivocal lesion located on uncovered areas [6]. In younger individuals, the presence of over 50 melanocytic nevi is considered one of the strongest risk factors for melanoma. Simply counting the number of nevi located on the arms can help identify individuals harboring a heavy nevus burden. Nevus counts of more than 20 nevi on the arms correlate with a high nevus count on the rest of the body. Thus, TBSE should be offered at least to the following high-risk groups: (i) patients with a personal history of any skin malignancy or a family history of melanoma (in first-degree relatives), (ii) patients under the age of 50 years who present with more than 20 nevi on the arms,

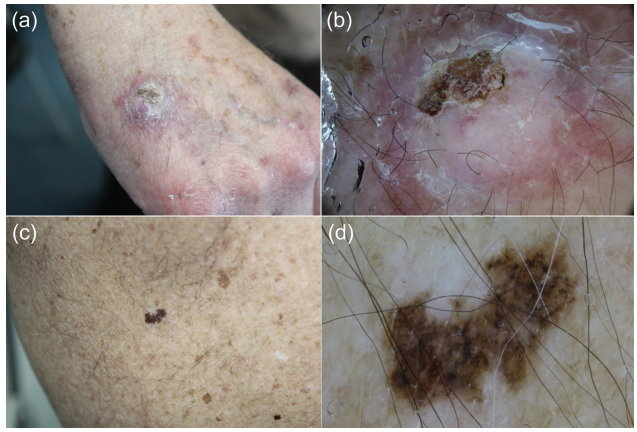

FIGURE 9C.3 Clinical and dermoscopic aspect of a squamous cell carcinoma on the dorsum of the hand of a 70-year-old man. (a, b) Since the patient had one tumor on a visible area of the skin and extensive sun damage, we decided to perform a total body skin examination, and the exam revealed an in situ melanoma on the patient's back. (c, d) Clinically, it was a solitary hyperpigmented macule. Under dermoscopy (d), atypical network and regression structures were detected.

and (iii) patients over the age of 50 years who present with evidence of chronic solar damage (Figure 9c.3).

Rule #3: Use the 10 second rule when evaluating single lesions

When examining a cutaneous lesion, experienced dermoscopists are usually able to make a diagnosis in a few seconds. This is because the vast majority of skin neoplasms exhibit repetitive morphologic characteristics, which are easily recalled and recognized. It has also been demonstrated that even after short training, recognition of one of the stereotypical patterns is usually straightforward [7].

On the contrary, a small proportion of lesions lack a dermoscopic pattern that is typical enough to allow a definite diagnosis. These cases result in a diagnostic dilemma, which is evidenced by the prolonged time of dermoscopic examination. If after 10 seconds of dermoscopic evaluation, a definitive diagnosis cannot be made, the lesion should be considered suspicious due to diagnostic uncertainty.

A characteristic example is presented in Figure 9c.4, in which no specific dermoscopic features are present, and thus, the clinician is unable to diagnose the lesion as benign or malignant with confidence. While such lesions, as long as they are nonpalpable, can be subjected to short-term digital monitoring, the threshold for biopsy should be low enough to maximize early excision of possible melanomas.

Rule #4: Compare and monitor multiple moles

Some clinicians believe that performing a biopsy on all clinically atypical lesions is the only safe way to avoid missing a melanoma. However, this approach may not be practical for patients who harbor numerous atypical melanocytic nevi. Another strategy endorsed by some is to excise all conspicuous

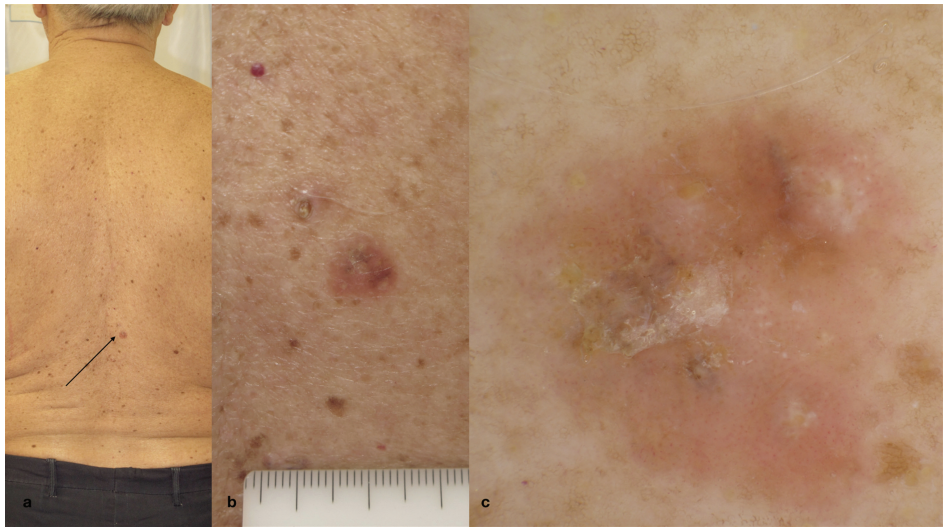

FIGURE 9C.4 This hypopigmented plaque was observed on the lower back of a 75-year-old man (a, b). On dermoscopy, dotted vessels and scaling over a pinkish background were seen (c). Since no specific dermoscopic features of a benign or malignant lesion were present, it was excised. Histopathology revealed an in situ melanoma.

outlier atypical lesions while simultaneously capturing digital images of all lesions deemed to be only slightly atypical and subjecting them to short-term follow-up (i.e., digital monitoring). The rationale behind short-term monitoring is that melanomas that cannot be diagnosed clinically or dermoscopically on initial inspection can be diagnosed based on dermoscopic changes observed during follow-up monitoring [8–13]. Short-term monitoring experience has shown that lesions displaying dermoscopic changes observed after an average follow-up of 3 months have an 11% probability of being an early and thin melanoma [13]. Thus, short-term monitoring appears to be an acceptable strategy that maximizes both sensitivity and specificity for melanoma diagnosis, which helps avoid missing a melanoma while at the same time minimizing the excision of benign lesions. It should be emphatically emphasized that monitoring protocols should only be applied to lesions that are moderately atypical, flat, or only slightly raised, without a history of change or dermoscopic evidence of melanoma, or for mildly atypical lesions with a history of change [13] (Figures 9c.5, 9c.6).

Rule #5: Excise doubtful nodular lesions

Nodular melanoma may lack the classic ABCD criteria and may mimic benign tumors, including dermal nevi, vascular lesions, dermatofibromas, or seborrheic keratosis. Even the classic dermoscopic criteria of melanoma may be missing, since most of the criteria are based on features observed in superficial spreading melanoma with melanin/melanocytes located primarily in the epidermis or at the dermo-epidermal junction [14–16]. Clues to help detect nodular melanoma include the presence of blue and black color within the lesion [16], presence of milky-red areas, polymorphous vascular pattern, or the presence of shiny white lines. The presence of polymorphous vascular pattern and the presence of shiny white lines are especially important criteria for nodular melanomas lacking significant pigmentation [17, 18]. In addition, so as not to miss a melanoma, any nodular lesion that does not display diagnostic dermoscopic features associated with a benign diagnosis (e.g. DF, intradermal melanocytic nevus (IDN), angioma) should be viewed with suspicion even if it lacks blue-black color, vessels, or shiny white structures. (Figures 9c.7, 9c.8). We would like to underscore that nodular lesions should never, ever be subjected to short-term monitoring, since a delay in the treatment of nodular melanoma of as little as a few months can negatively impact prognosis. Thus, in the case of atypical nodular lesions, the best strategy is "if in doubt, cut it out!"

Rule #6: Excise lesions revealing spitzoid features in post-pubertal patients

The accuracy in diagnosing Spitz nevi, especially the pigmented variant, has improved dramatically with the use of dermoscopy [19–20]. We owe this improved diagnostic accuracy to the fact that many Spitz nevi display a strikingly characteristic starburst pattern. However, it has also been documented that although the starburst pattern is usually associated with the diagnosis of a Spitz nevus, it may on rare occasions be seen in melanoma. Thus, especially in adults, a biopsy should be performed on lesions displaying spitzoid features under dermoscopy (Figure 9c.9) [21].

Rule #7: Combine clinical, dermoscopic, and histologic criteria

On occasion, the index of suspicion for melanoma can only be raised when the dermoscopic features do not confirm the clinical impression. To minimize the risk of missing melanoma, clinical diagnoses should be based on correlating the clinical naked eye findings with the dermoscopic findings. For example, in the context of clinically banal lesions, what is seen with dermoscopy should fit with the initial clinical impression, and a red flag should be raised when unexpected features are observed [22].

Histopathologic examination remains the gold standard for diagnosing melanocytic lesions, but similarly to any other diagnostic method, it is not free of limitations or technique

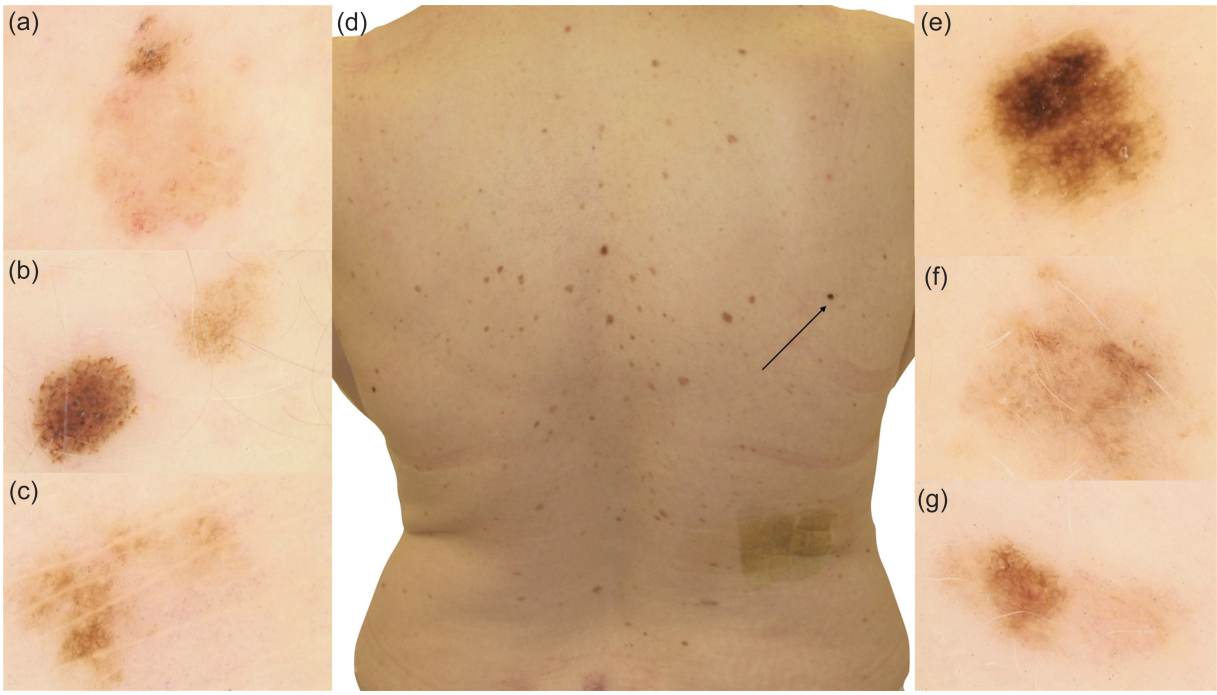

FIGURE 9C.5 Multiple melanocytic lesions on the back of a 48-year-old woman with a previous history of melanoma. All lesions were dermoscopically monitored for 1 year. The lesion in panel (F) proved to be a melanoma (see Figure 5c.6).

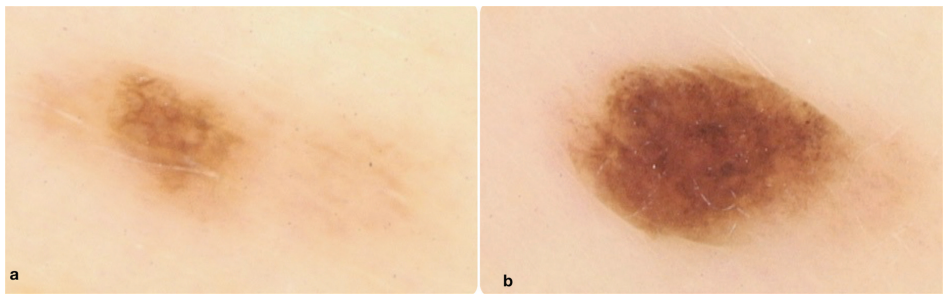

FIGURE 9C.6 One-year follow-up of a pigmented macule on the back of a 48-year-old woman. The lesion was growing asymmetrically, with enlargement of the hyperpigmented area and development of peripheral streaks. Excision revealed a superficial spreading melanoma 0.3 mm in thickness.

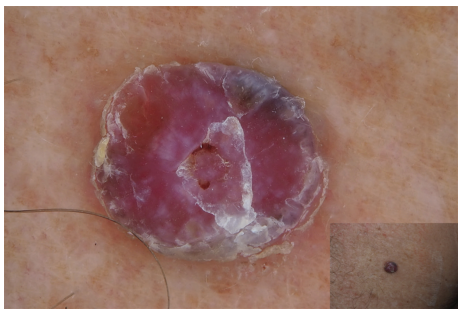

FIGURE 9C.7 Nodular amelanotic melanoma. Dermoscopically, it lacks the classic criteria for melanoma. Clues for melanoma include the presence of milky-red areas throughout the lesion and a residual brown-blue area at the periphery.

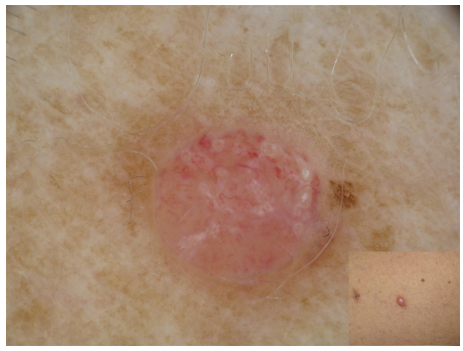

FIGURE 9C.8 Nodular amelanotic melanoma clinically simulating a dermal nevus. This melanoma is quite challenging. Dermoscopically, the presence of polymorphous vessels and of whitish areas helps to exclude the diagnosis of a dermal nevus. Nodular lesions lacking features of a benign lesion and nodular lesions displaying blue-black color, shiny white structures, milky-red areas, or polymorphous vessels should generally be biopsied.

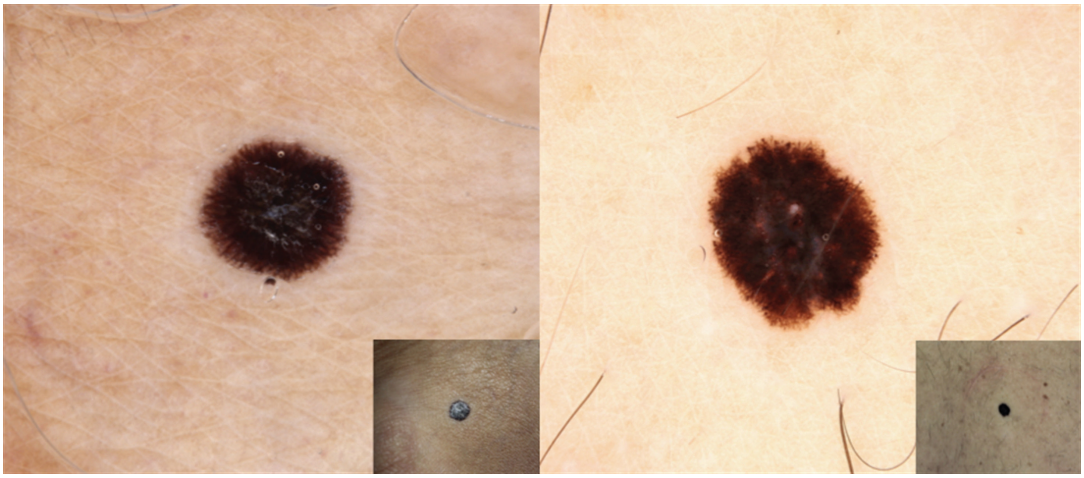

FIGURE 9C.9 (a) An atypical pigmented lesion, slightly elevated, on the heel of a 46-year-old man. Dermoscopically this melanoma simulates a Spitz/Reed nevus. It is characterized by a central black-brown homogeneous pattern and a starburst pattern at the periphery. The general rule is to excise spitzoid lesions in adults. This rule was the key in the biopsy of this melanoma. (b) A heavily pigmented lesion on the back of a 39-year-old man with features clinically simulating a Reed nevus. Dermoscopy reveals a pattern also simulating a Spitz/Reed nevus with starburst pattern. The age of the patient and the presence of globules at the periphery and a hint of a white veil in the center should raise the suspicion for melanoma.

failures. Lesions that may be difficult to interpret histopathologically are represented by spitzoid tumors, lesions exhibiting a high degree of regression, and nevus-associated melanoma, in which the histopathologic diagnosis of melanoma can be missed if the nonrepresentative area of the specimen is evaluated [23]. Moreover, it has to be emphasized that clinically and dermoscopically difficult lesions will often prove to have equivocal histopathology findings, especially if the pathologist is not provided with relevant clinical information. Thus, histopathologic reports should always be interpreted in the context of the clinical setting, and the diagnosis of lesions lacking a satisfactory clinico-dermoscopic-histopathologic correlation should be managed with caution [24].

References

1. Pehamberger H, Steiner A, Wolff K. In vivo epiluminescence microscopy of pigmented skin lesions. I. Pattern analysis of pigmented skin lesions. *J Am Acad Dermatol.* 1987;17:571–83.
2. Argenziano G, Fabbrocini G, Carli P, et al. Epiluminescence microscopy for the diagnosis of doubtful melanocytic skin lesions. Comparison of the ABCD rule of dermatoscopy and a new 7-point checklist based on pattern analysis. *Arch Dermatol.* 1998;134:1563–70.
3. Lallas A, Zalaudek I, Apalla Z, et al. Management rules to detect melanoma. *Dermatology.* 2013;226:52–60.
4. Zalaudek I, Kittler H, Marghoob AA, et al. Time required for a complete skin examination with and without dermos- copy: a prospective, randomized multicenter study. *Arch Dermatol.* 2008;144:509–13.
5. Smith RA, Cokkinides V, Brawley OW. Cancer screening in the United States, 2009: a review of current American Cancer Society guidelines and issues in cancer screening. *CA Cancer J Clin.* 2009;59:27–41.
6. Argenziano G, Zalaudek I, Hofmann-Wellenhof R, et al. Total body skin examination for skin cancer screening in patients with focused symptoms. *J Am Acad Dermatol.* 2012;66(2):212–9.
7. Tschandl P, Kittler H, Schmid K, et al. Teaching dermatoscopy of pigmented skin tumours to novices: comparison of analytic vs.heuristic approach. *J Eur Acad Dermatol Venereol.* Jun 2015;29(6):1198–204.
8. Altamura D, Avramidis M, Menzies SW. Assessment of the optimal interval for and sensitivity of short-term sequential digital dermoscopy monitoring for the diagnosis of melanoma. *Arch Dermatol.* 2008;144(4):502–6.
9. Argenziano G, Mordente I, Ferrara G, et al. Dermoscopic monitoring of melanocytic skin lesions: clinical outcome and patient compliance vary according to follow-up protocols. *Br J Dermatol.* 2008;159(2):331–6.
10. Kittler H, Guitera P, Riedl E, et al. Identification of clinically featureless incipient melanoma using sequential dermoscopy imaging. *Arch Dermatol.* 2006;142(9):1113–9.
11. Haenssle HA, Krueger U, Vente C, et al. Results from an observational trial: digital epiluminescence microscopy follow-up of atypical nevi increases the sensitivity and the chance of success of conventional dermoscopy in detecting melanoma. *J Invest Dermatol.* 2006;126(5):980–5.
12. Skvara H, Teban L, Fiebiger M, et al. Limitations of dermoscopy in the recognition of melanoma. *Arch Dermatol.* 2005;141(2):155–60.
13. Menzies SW, Gutenev A, Avramidis M, et al. Short-term digital surface microscopic monitoring of atypical or changing melanocytic lesions. *Arch Dermatol.* 2001;137(12):1583–9.
14. Brancaccio G, Russo T, Lallas A, et al. Melanoma: clinical and dermoscopic diagnosis. *G Ital Dermatol Venereol.* 2017 Jun;152(3):213–23. doi: 10.23736/S0392-0488.17.05571-7. Epub 2017. Review.
15. Menzies SW, Moloney FJ, Byth K, et al. Dermoscopic evaluation of nodular melanoma. *JAMA Dermatol.* 2013;149(6):699–709.
16. Argenziano G, Longo C, Cameron A, et al. Blue-black rule: a simple dermoscopic clue to recognize pigmented nodular melanoma. *Br J Dermatol.* 2011;165(6):1251–5.
17. Geller S, Pulitzer M, Brady MS, et al. Dermoscopic assessment of vascular structures in solitary small pink lesions-differentiating between good and evil. *Dermatol Pract Concept.* 2017;7(3):47–50.
18. Steglich RB, Meotti CD, Ferreira MS, et al. Dermoscopic clues in the diagnosis of amelanotic and hypomelanotic malignant melanoma. *An Bras Dermatol.* 2012;87(6):920–3.
19. Ferrara G, Argenziano G, Soyer HP, et al. The spectrum of Spitz nevi: a clinicopathologic study of 83 cases. *Arch Dermatol.* 2005;141(11):1381–7.
20. Requena C, Botella R, Nagore E, et al. Characteristics of spitzoid melanoma and clues for differential diagnosis with spitz nevus. *Am J Dermatopathol.* 2012;34(5):478–86.

21. Lallas A, Moscarella E, Longo C, et al. Likelihood of finding melanoma when removing a Spitzoid-looking lesion in patients aged 12 years or older. *J Am Acad Dermatol.* 2015;72(1):47–53.
22. Zalaudek I, Ferrara G, Di Stefani A, et al. Dermoscopy for challenging melanoma; how to raise the 'red flag' when melanoma clinically looks benign. *Br J Dermatol.* 2005;153(1):200–2.
23. Crotty KA, Scolyer RA, Li L, et al. Spitz naevus versus Spitzoid melanoma: when and how can they be distinguished? *Pathology.* 2002;34(1):6–12. Review.
24. Russo T, Piccolo V, Ferrara G, et al. Dermoscopy pathology correlation in melanoma. *J Dermatol.* 2017;44(5):507–14.

9D METHODS TO DIFFERENTIATE NEVI FROM MELANOMA: METHODS TO IMPROVE SENSITIVITY AND SPECIFICITY IN MELANOMA DIAGNOSIS

Neda Shahriari, Jane M. Grant-Kels, Harold Rabinovitz, Margaret C. Oliviero, and Alon Scope

Contents

Introduction . . . 230
Lesion morphology by patient-related factors . . . 232
Age . . . 232
Skin type and UV exposure . . . 232
Anatomic site . . . 232
"Signature" pattern of nevi . . . 233
Melanoma risk per history . . . 233
Patient concern . . . 234
Total body photography and dermoscopic monitoring . . . 234
Reflectance confocal microscopy . . . 234
Practical considerations . . . 235
Conclusion . . . 235
References . . . 235

Introduction

The mortality rate associated with melanoma has served as the impetus for increased surveillance and early detection of this malignancy with the aim of detecting it while it is easily curable via simple surgical excision. This is of utmost significance, as the melanoma incidence has doubled in rate from 1982 to 2011 [1], with an estimated 9320 deaths attributable to melanoma in 2018 [2]. Dermoscopy has significantly increased the specificity and sensitivity for the detection of melanoma; however, there are cases in which the isolated use of dermoscopy may result in potential diagnostic pitfalls. Therefore, a more integrative approach to diagnosis can aid the decision-making process to further improve diagnostic accuracy.

Sensitivity measures the proportion of melanomas that are correctly diagnosed as suspicious and more importantly, surgically removed. An increase in sensitivity means that fewer melanomas are missed. Specificity measures the proportion of benign lesions that are correctly diagnosed as benign and spared from unnecessary biopsies. These diagnostic tests are mostly reported in study settings; in real life, it is difficult to identify and include the missed melanomas in the calculation of true sensitivity. Similarly, our true specificity looking at patients' skin is extremely high, because we remove only a small fraction of the myriad of skin lesions examined.

During the diagnostic process, the clinician integrates multiple sources of information: Patient history, clinical inspection, palpation, dermoscopic examination, comparison of the lesion of concern with other patient's lesions, and ancillary imaging techniques including total body photography, digital dermoscopy, and reflectance confocal microscopy (RCM), to name a few. Depending on the grade of difficulty of the lesion and the experience of the clinician, the number of techniques used during the diagnostic process will vary, with more experience and simple lesions requiring fewer diagnostic aids.

For skin cancer, in particular for melanoma, the level of diagnostic difficulty can be stratified into three levels (Figure 9d.1):

1. "Obvious from the doorway"—melanoma that can be easily diagnosed by visual inspection
2. "Apparent on close inspection"—melanoma that can be fairly confidently diagnosed based on clinical and dermoscopic examination
3. "Diagnosis by data integration"—melanoma that is difficult to diagnose based on clinical and dermoscopic evaluation

A "doorway" melanoma is represented by classic clinical features with noticeable ABCD signs—*a*symmetry, *b*order irregularity, *c*olor variegation, *d*iameter >6 mm (Figure 9d.2) [3], and the "ugly duckling" sign [4]. The "ugly duckling" sign refers to the evaluation of lesions in the context of the patient's other surrounding nevi; the "outlier" lesion that does not follow the pattern of surrounding nevi is considered suspicious for melanoma. A "doorway" melanoma will be missed if overlooked, for example, if it is hidden from view. Patients receiving full skin inspection have a six-fold greater chance of having their melanoma detected in comparison to those undergoing partial examination [5]. Furthermore, providers should explicitly ask patients about new or concerning lesions, since patients may be reluctant at times to spontaneously communicate their concern, even in the presence of a "doorway" melanoma.

"Apparent on close inspection" melanomas can usually be diagnosed by closely looking at the lesion, using clinical and dermoscopic evaluation to identify a chaotic pattern of multiple colors and structures and melanoma-specific criteria (Figure 9d.3). These melanomas may at times be unnoticed if visualized only with the naked eye. The physician should inspect both clinically and dermoscopically all lesions that are of concern to the patient, that appear as "ugly ducklings," and that are identified as new or changing. Some melanomas may also be "apparent on close inspection" but difficult to spot in a sea of multiple pigmented lesions, including atypical nevi in patients with high nevus counts, or multiple seborrheic keratoses and lentigines, as seen in patients with sun-damaged skin. Dermoscopic examination of all the patient's lesions has been

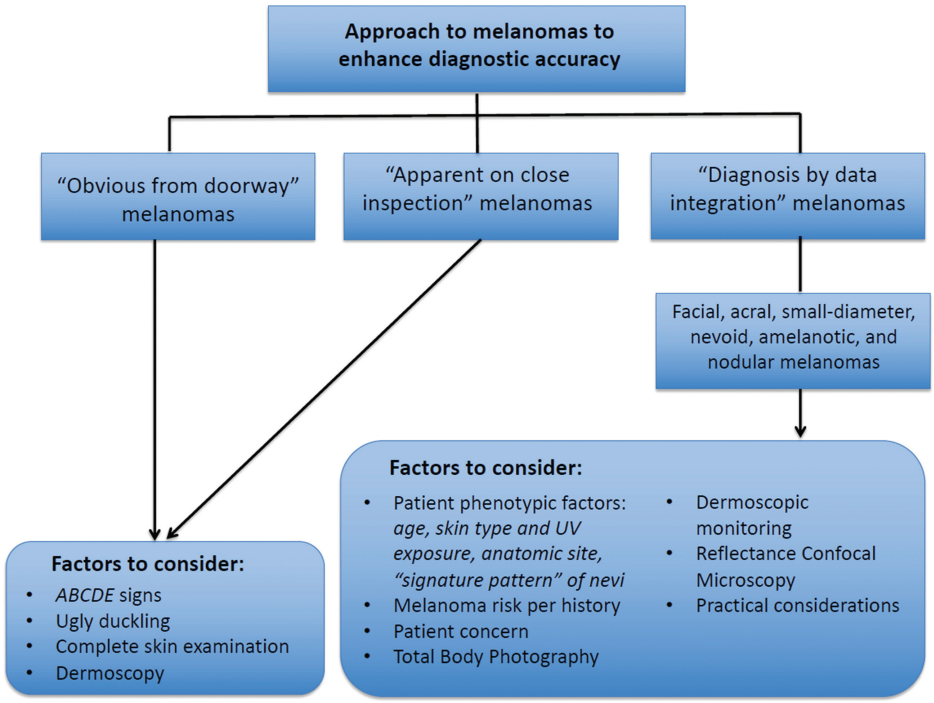

FIGURE 9D.1 Approach to melanoma diagnosis by diagnostic difficulty.

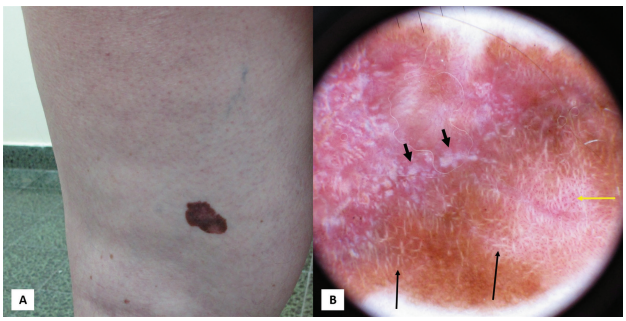

FIGURE 9D.2 Melanoma 0.3 mm in thickness, "obvious from the doorway." (a) Clinically, this pigmented plaque on the distal posterior thigh fulfils all the ABCD criteria, with contour asymmetry, border irregularity, multiple colors (shades of brown and pink), and diameter of 22 mm. It can also be spotted from across the room as an ugly duckling that is very different from the patient's other pigmented lesions. (b) Dermoscopically, there is asymmetric distribution and a multitude of colors (white, red, brown), and melanoma-specific criteria, including chrysalis structures as shiny white lines (black arrows) and strands (black arrowheads), as well as dotted vessels (yellow arrow).



FIGURE 9D.3 Melanoma in situ, "apparent on close inspection." (a) Clinically, this is an 8 mm brown macule on the dorsal forearm (arrow). (b) Dermoscopically, there is an irregular globular-homogeneous pattern, asymmetric distribution of structures and colors (brown, gray, pink), as well as melanoma-specific criteria, including negative network (black arrow), regression structure (yellow asterisk), and dotted vessels (yellow arrows).

shown to further increase sensitivity for the detection of suspicious lesions [6]. In addition, using total body photography may assist in identifying and focusing closely on the new or changed lesion in the background of numerous nevi.

The remaining stratum, "diagnosis by data integration," refers to the approach used to identify a subset of melanomas that are difficult to diagnose based on clinical and dermoscopic evaluation alone. Difficult to diagnose melanomas include amelanotic, nodular, nevoid, facial, acral, and small-diameter melanomas. The difficulty in diagnosis arises from several factors, which may include lack or scarcity of ABCD criteria (e.g., nodular melanoma), nonpigmented lesions (e.g., amelanotic melanoma), and scant clinical and dermoscopic criteria (e.g., facial melanoma).

In order to augment detection of subtle melanomas, several factors should be considered and integrated:

- Close-up clinical and dermoscopic exam
- "Ugly duckling" sign
- Lesion morphology by patient-related factors
- Melanoma risk per history

- Patient concern
- Total body photography (TBP) and dermoscopic monitoring
- Reflectance confocal microscopy
- Practical considerations

None of these factors will always be decisive in making the diagnosis; however, consideration and integration of these factors can significantly increase diagnostic accuracy.

Lesion morphology by patient-related factors

The morphology of most skin lesions is predictable. A large proportion of variability in lesion morphology can be accounted for by patient-related factors—age, skin phototype and associated ultraviolet exposure, anatomic location of the lesion, and "signature" patterns of the patient's other nevi. A lesion that defies the expected pattern should raise suspicion.

Age

Age impacts the dermoscopic patterns of nevi observed. Typically, nevi with a dermoscopic globular pattern predominate in childhood with a shift towards a predominant reticular pattern in adulthood [7, 8]. The dermoscopic pattern of peripheral globules is another age-related pattern observed in nevi of young adults; its presence correlates with growth [9]. There is a continuous decrease in this pattern with every increased decade of age, with an eventual frequency of <1% after the fourth decade of life [7]. The significance of these findings is relevant to melanoma diagnosis in that globular and peripheral globular patterns under dermoscopy are suggestive of benign nevi in younger populations. In contradistinction, observation of a new globular lesion should not be cursorily overlooked in later adulthood. Similarly, in patients greater than 50 years of age, the peripheral globular pattern is quite rare, and therefore, strong consideration for a biopsy would be appropriate [7, 10]. Furthermore, new or changing lesions in patients younger than 50, in particular younger than 30 years old, represent far fewer melanomas as compared with new or changing lesions noted in patients older than 50 years of age [11]. Therefore, since in older patients a new or changing melanocytic lesion is more likely to be melanoma (Figures 9d.4, 9d.5) than in younger patients, a lower threshold for biopsy should be exercised in the older population group.

Skin type and UV exposure

Not surprisingly, individuals with skin type I display nevi with light brown or pink homogeneous dermoscopic patterns, or reticular pattern with central hypopigmentation. In contrast, patients with skin type IV typically demonstrate dark brown nevi, often showing a reticular pattern with central hyperpigmentation [12]. Furthermore, the Study of Nevi in Children (SONIC) showed that pediatric patients with darker skin types were more likely to have reticular nevi with a smaller size in comparison to the lighter skin phenotypes [8]. Hence, a lesion that appears darker compared with the patient's other nevi and is out of line with the skin type should be flagged as suspicious (Figure 9d.6).

The degree of ultraviolet radiation exposure also impacts the morphology of nevi. Features that can be observed include lesion enlargement, darkening or lightening of pigment network, erythema, and the appearance of dots, globules, or pigment lamella forming a blotch [12–14]. Some of these changes may be reversible; nonetheless, awareness of patient's exposure to phototherapy should further guide the clinician in nevi evaluation.

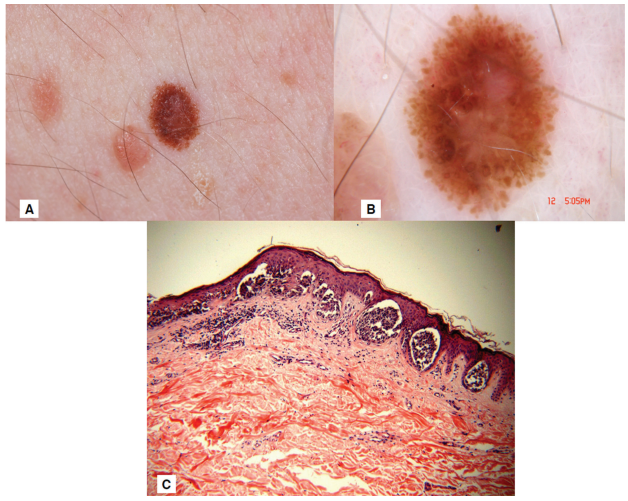

FIGURE 9D.4 Melanoma in a patient older than 50 years of age depicting the dermoscopic globular pattern. (a) Clinically, this is a 5 mm brown macule on the trunk of a patient above the age of 50. (b) Dermoscopically, there is central hypopigmentation with a peripheral globular pattern that dominates. (c) Histopathologically, the lesion demonstrates atypical nested proliferation at the dermo-epidermal junction, as well as cells in pagetoid spread, consistent with melanoma.

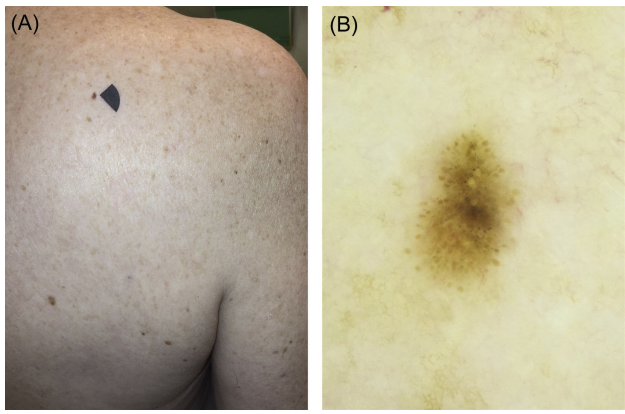

FIGURE 9D.5 Melanoma on a 58-year-old male. (a) Clinically, this was a brown, subtle macule. (b) Under dermoscopy, atypical peripheral globules are seen. Histopathologically, the lesion proved to be a melanoma.

Anatomic site

There is a higher proportion of globular patterned nevi on the upper back as compared with the lower back or extremities [8, 15]. We can also note an increasing predominance in reticular patterned nevi as our gaze moves centrifugally from the torso towards the extremities [8, 15]. The observation of cephalo-caudal transition from globular to reticulated nevi as well as an overall higher percentage of globular nevi in the pediatric population seems to suggest a congenital origin for the globular dermoscopic pattern [10]. Therefore, the observation

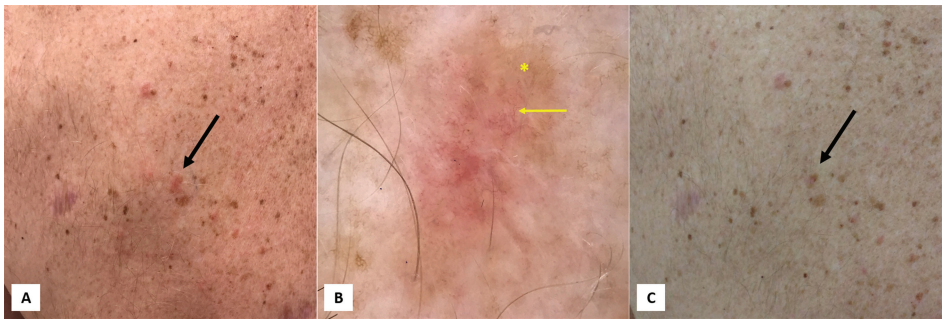

FIGURE 9D.6 Melanoma in situ, "diagnosis by data integration." (a) Clinically, this is a 4 mm dark brown to black macule on the upper back, which is an "ugly duckling" in being darker than the other pigmented lesions of the patient (female, 50s, with family history of melanoma). (b) Dermoscopically, there is an asymmetric reticular-homogeneous pattern with hyperpigmented central blotch. This dermoscopic pattern was different from that seen in the other nevi and more in line with a darker skin type than the patient's photo-type III.

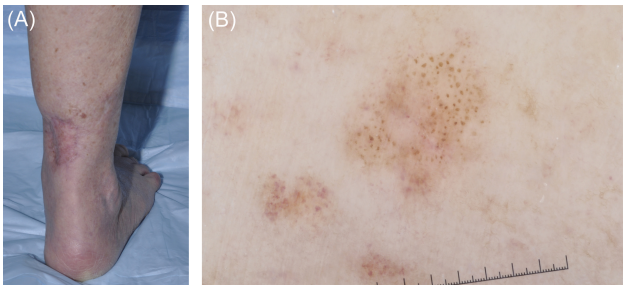

FIGURE 9D.7 Patient with history of melanoma; a new brown macule was observed on the posterior leg (a). Dermoscopy revealed an atypical globular pattern (b). Histopathology demonstrated a melanoma.

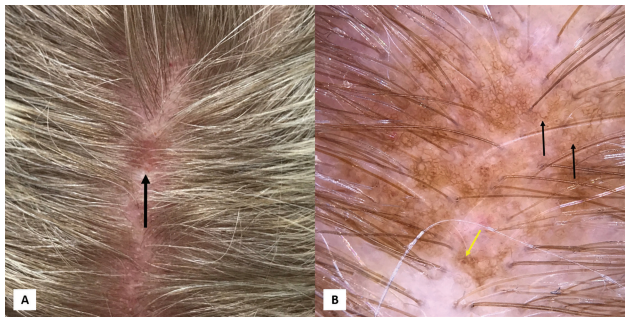

FIGURE 9D.8 Melanoma 0.7 mm in thickness, "diagnosis by data integration." (a) Clinically, this is a 9 mm pink macule on the upper back of the patient (male, 50s, with a personal history of melanoma). (b) Dermoscopically, the lesion is nearly amelanotic, with scant structureless light brown pigmentation at the periphery (asterisk) and a few serpentine vessels (arrow). (c) Looking at total body photography images from 4 years ago reveals that this lesion was present then and has markedly grown. Taking together the patient's melanoma risk, photographic evidence of change, and the irregular vessels under dermoscopy, the lesion becomes highly suspicious for melanoma.

of a new globular patterned nevus on the lower extremities of an adult should raise suspicion for possible malignancy, and consideration should be given to a biopsy or close monitoring (Figure 9d.7).

"Signature" pattern of nevi

Nevi are highly variable; however, intra-individual comparative analysis reveals "perceived similarity clusters" (PSCs), which are defined as the most common pattern of nevi observed in a patient [16]. The recognition of these PSCs allows identification of "ugly duckling" nevi, given that they do not bear a resemblance to any of the PSCs. The sensitivity of the "ugly duckling" sign for melanoma diagnosis has been demonstrated to be 0.9 across a cohort of individuals with different levels of expertise [17]. One study showed that the mean number of patterns observed in each patient is 2.1, which does not differ for those patients with atypical nevus syndrome [16]. Another study evaluating nevi based on dermoscopic pattern analysis demonstrated one dominant global dermoscopic pattern, which occurs in 40% or more of lesions, and one to two minor patterns, occurring in 20–39% of nevi [18]. Utilizing a computerized analysis system, 205 randomized nevi from 18 different patients were presented to the computer with effective clustering of lesions into 18 groups corresponding to the 18 respective patients corroborating the finding of dermoscopic pattern analysis [19]. The importance of this consideration is underscored because the evaluation of lesions in the context of a patient's other nevi decreases propensity for excision recommendations as compared with isolated lesion analysis based purely on morphology alone [20].

Melanoma risk per history

The patient's probability of developing melanoma is weighed into the level of suspicion when evaluating an equivocal lesion (Figure 9d.8). Patients who have had cutaneous melanoma are at 10-fold increased risk for the development of a second melanoma as compared with patients with no history of melanoma [21]. The risk of subsequent melanoma becomes steeper, with one study estimating a 16% probability at year 1 and 31% chance at year 5 for a third melanoma [22]. Some studies have even reported second melanomas occurring at a higher frequency on the same body site as the initial one, particularly when the melanoma occurred on the extremities [23, 24]. Given the propensity for certain individuals to develop multiple primary melanomas, the question arises as to whether an individual produces melanomas with similar dermoscopic and clinical characteristics. This finding would suggest that surveillance be geared towards these precise features. A small retrospective

study has shown that as many as half of patients with multiple primary melanomas demonstrated similar dermoscopic findings between their melanomas. This was particularly notable among elderly patients, with melanomas on sun-damaged skin, featuring pigment network and regression structures [25].

Patient concern

It is prudent to consider patient concern in the clinician's algorithm for assessment of cutaneous lesions. Elicitation of patient concern for any noticeable new or changing lesion can help focus the attention on truly concerning lesions. Furthermore, assessment of symptoms associated with any lesion can further highlight lesions that may be malignant. Analysis of patterns of melanoma detection has revealed that more than half of patients (57%) detected their own melanomas, with a higher propensity for female self-detection than in males: 69% and 47%, respectively [26]. The higher propensity for female self-detection is multifactorial and has been attributed to greater knowledge about the disease, greater tendency for skin self-examination, and higher likelihood to have professional skin cancer screening [26]. Patients who perform routine self-skin exams are more likely to be diagnosed with thinner melanomas [26]; therefore increased patient education and encouragement to perform self-skin exams can be highly beneficial in melanoma detection [27, 28].

Total body photography and dermoscopic monitoring

Patients with many atypical nevi can present a surveillance challenge, since new or changing lesions may be difficult to identify. Baseline TBP consists of 12 to 24 high-resolution clinical photographs of a patient's cutaneous surface, which serve as baseline. The premise for its use in the detection of melanoma stems from the notion that melanomas appear as new or changing lesions on the skin, while most nevi remain static [11]. Several early studies delineated the significance of early detection of melanoma through this form of surveillance [29, 30]. TBP predominantly increases specificity; for example, a lesion presenting equivocal clinical and dermoscopic features is reassuringly identified as benign based on long-standing stability compared with previous overview images. Occasionally, TBP can also increase sensitivity; for example, an early melanoma may display subtle clinical and dermoscopic features yet may elicit concern because of its detection as a new or changed lesion (Figure 9d.8). As a result, TBP has been demonstrated to decrease the benign:malignant ratio of lesion biopsy specimens—as low as 3:1 in one study—since evidence of nevi stability decreases the chance of an unnecessary biopsy [11].

Sequential digital dermoscopic imaging (SDDI), which involves the successive capture of dermoscopic images of suspicious skin lesions, allows the evaluation of dermoscopic findings over time. SDDI is specifically helpful in the detection of melanoma in lesions that lack the characteristic clinical and dermoscopic features of melanoma (Figure 9d.9) [31]. By detecting subtle dermoscopic morphologic changes, incipient melanomas without classic dermoscopic changes can be detected earlier [31]. SDDI has been shown to improve the specificity and sensitivity for melanoma diagnosis as compared with utilization of dermoscopy solely, with one study demonstrating sensitivity of 95.31% and specificity of 99.9% [32]. The combination of dermoscopy and SDDI has been shown to double the sensitivity for melanoma and reduce the excision or referral rate of benign lesions by more than 50% [33]. Though some studies have shown greater efficacy of melanoma detection with TBP as compared with SDDI [34], some individuals advocate the use of both techniques during surveillance in a "multimodal approach" to increase melanoma diagnostic accuracy [35].

Reflectance confocal microscopy

RCM is a noninvasive diagnostic modality that captures images in vivo at an orientation that is parallel to the surface of the skin. RCM offers cellular-level magnification and resolution, and can facilitate the distinction between nevi and melanoma, facilitating the diagnostic process and curbing unnecessary biopsies. RCM operates through emission of a low-energy diode laser light source that is directed toward a specific area of tissue or lesion; the subsequent back-scattering of light, which occurs dependent on differences in refractive indices within the skin tissue, highlights structures within the lesion [36]. Typically, melanin, keratin, and collagen have a higher refractive index than surrounding tissue, causing these structures to appear particularly white as compared with background tissue [36, 37]. RCM is an exceptional adjunct to dermoscopy and clinical examination for increasing sensitivity and specificity. A systematic review pooling data from five studies evaluated the diagnostic accuracy of RCM for the detection of melanoma and noted a per lesion sensitivity of 93% (range 91–97%) and specificity of 76% (range 68–86%) [38]. The number of lesions required to excise for melanoma detection was 2.4 [39].

The best use of RCM as an adjunct to dermoscopy in increasing melanoma detection would entail its use in dermoscopic equivocal lesions where the differential diagnosis is between melanoma and another entity. This includes nevi with irregular dermoscopic patterns but clear-cut RCM patterns suggestive of nevi, lesions on sun-damaged skin with the differential diagnosis of a solar lentigo (Figure 9d.10), and lesions with gray-dot granularity under dermoscopy, which are suggestive of melanophages, as seen in lichen planus–like keratosis, pigmented actinic keratosis, or melanoma [40]. RCM has also been

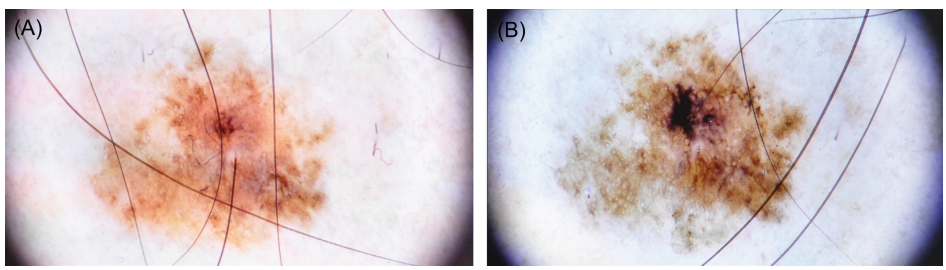

FIGURE 9D.9 Brown macule monitored with sequential digital dermoscopic imaging depicting pigmentary changes suggestive of melanoma.

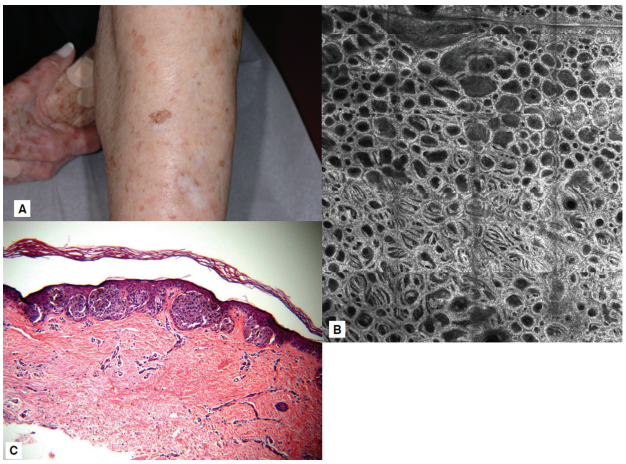

FIGURE 9D.10 Melanoma in situ on sun-damaged skin, "diagnosis by data integration." (a) Clinically, the lesion is a 1 cm brown patch located on the extremity resembling a solar lentigo. (b) RCM mosaic at the level of the dermo-epidermal junction shows areas with a regular ringed pattern alongside regions with an irregular meshwork pattern. There are thick elongated junctional nests that traverse the papillae, an RCM pattern suspicious for melanoma on sun-damaged skin that has been termed "mitochondria-like" [42]. (c) Histopathology demonstrates a broad junctional proliferation composed of large and confluent nests.

depicted as highly reliable in the following settings: Lesions on the head and neck area, evaluation of lesions in the setting of chronically sun-damaged skin, lesions on the legs, and lesions with noticeable regression under dermoscopy [38]. However, RCM should not override the clinical and dermoscopic impression, given false negative rates of melanoma with RCM, though this was low at 3.5% in one study [41].

Practical considerations

We strive to increase the detection of melanomas while also maintaining balance through limitation of unnecessary biopsies. On this front, the number of lesions in doubt and the location of lesions should be considered. For example, removal of one equivocal lesion in a noncosmetically sensitive area can sometimes be the simplest approach in management. For a lesion suspicious for nodular melanoma, we do not recommend noninterventional observation but rather, to perform a biopsy, given the potentially aggressive nature of this type of melanoma. Despite the extensive tools in our armamentarium, the sensitivity of melanoma is not perfect, and therefore, patients should be educated on concerning features so that they can seek examination sooner if a lesion is not behaving as predicted.

Conclusion

The diagnosis of melanoma is complex, particularly when evaluating melanomas that are not easily identifiable utilizing traditional algorithms. Conventionally, the ABCDE method for clinical examination was utilized; however, it remains challenging in particular cases to distinguish between nevi and melanoma. While the delineation of dermoscopic algorithms (e.g., seven-point checklist and Menzies' method) has increased diagnostic accuracy, room for improvement remains. Therefore, an integrative approach is required beyond full-body skin examination and dermoscopy—pooling patient-specific factors, patient's melanoma risk, and diagnostic modalities like TBP, dermoscopic monitoring, and RCM in order to increase the specificity and sensitivity of melanoma detection.

References

1. Guy GP, Jr, Thomas CC, Thompson T, Watson M, Massetti GM, Richardson LC. Vital signs: melanoma incidence and mortality trends and projections-United States, 1982–2030. *MMWR Morb Mortal Wkly Rep.* 2015;64(21):591–6.
2. Siegel RL, Miller KD, Jemal A. Cancer statistics, 2018. *CA Cancer J Clin.* 2018;68(1):7–30.
3. Rigel DS, Friedman RJ, Kopf AW, Polsky D. ABCDE—an evolving concept in the early detection of melanoma. *Arch Dermatol.* 2005;141:1032–4.
4. Grob JJ, Bonerandi JJ. The ugly duckling sign: identification of the common characteristics of nevi in an individual as a basis for melanoma screening. *Arch Dermatol.* 1998;134(1):103–4.
5. Rigel DS, Friedman RJ, Kopf AW, Weltman R, Prioleau PG, Safai B, Lebwohl MG, Eliezri Y, Torre DP, Binford Jr RT, Cipollaro VA. Importance of complete cutaneous examination for the detection of malignant melanoma. *J Am Acad Dermatol.* 1986 1;14(5):857–60.
6. Seidenari S, Longo C, Giusti F, Pellacani G. Clinical selection of melanocytic lesions for dermoscopy decreases the identification of suspicious lesions in comparison with dermoscopy without clinical preselection. *Br J Dermatol.* 2006;154(5):873–9.
7. Zalaudek I, Schmid K, Marghoob AA, et al. Frequency of dermoscopic nevus subtypes by age and body site: a cross-sectional study. *Arch Dermatol.* 2011;147:663–70.
8. Scope A, Marghoob AA, Dusza SW, et al. Dermoscopic patterns of naevi in fifth grade children of the Framingham school system. *Br J Dermatol.* 2008;158:1041–9.
9. Kittler H, Seltenheim M, Dawid M, Pehamberger H, Wolff K, Binder M. Frequency and characteristics of enlarging common melanocytic nevi. *Arch Dermatol.* 2000;136:316–20.
10. Scope A, Marchetti MA, Marghoob AA, et al. The study of nevi in children: principles learned and implications for melanoma diagnosis. *J Am Acad Dermatol.* 2016;75(4):813–23.
11. Banky JP, Kelly JW, English DR, Yeatman JM, Dowling JP. Incidence of new and changed nevi and melanomas detected using baseline images and dermoscopy in patients at high risk for melanoma. *Arch Dermatol.* 2005;141(8):998–1006.
12. Zalaudek I, Docimo G, Argenziano G. Using dermoscopic criteria and patient-related factors for the management of pigmented melanocytic nevi. *Arch Dermatol.* 2009;145:816–26.
13. Kilinc Karaarslan I, Teban L, Dawid M, Tanew A, Kittler H. Changes in the dermoscopic appearance of melanocytic naevi after photochemotherapy or narrowband ultraviolet B phototherapy. *J Eur Acad Dermatol Venereol.* 2007;21(4):526–31.
14. Hofmann-Wellenhof R, Wolf P, Smolle J, Reimann-Weber A, Soyer HP, Kerl H. Influence of UVB therapy on dermoscopic features of acquired melanocytic nevi. *J Am Acad Dermatol.* 1997;37(4):559–63.
15. Fonseca M, Marchetti MA, Chung E, et al. Cross-sectional analysis of the dermoscopic patterns and structures of melanocytic naevi on the back and legs of adolescents. *Br J Dermatol.* 2015;173:1486–93.
16. Wazaefi Y, Gaudy-Marqueste C, Avril MF, Malvehy J, Pellacani G, Thomas L, Triller R, Bruneu Y, Monestier S, Richard MA, Fertil B. Evidence of a limited intra-individual diversity of nevi: intuitive perception of dominant clusters is a crucial step in the analysis of nevi by dermatologists. *J Invest Dermatol.* 2013;133(10):2355–61.
17. Scope A, Dusza SW, Halpern AC, Rabinovitz H, Braun RP, Zalaudek I, Argenziano G, Marghoob AA. The "ugly duckling" sign: agreement between observers. *Arch Dermatol.* 2008;144(1):58–64.

18. Scope A, Burroni M, Agero AL, Benvenuto-Andrade C, Dusza SW, Rubegni P, Bono R, Dell'Eva G, Salaro C, Marghoob AA. Predominant dermoscopic patterns observed among nevi. *J Cutan Med Surg.* Jul 2006;10(4):170–4.
19. Burroni M, Dell'Eva G, Corona R, et al. Inter- and intravariability of pigmented skin lesions: could the ABCD rule be influenced by host characteristics? *Skin Res Technol*. 2004;10:193–9.
20. Argenziano G, Catricalà C, Ardigo M, Buccini P, De Simone P, Eibenschutz L, Ferrari A, Mariani G, Silipo V, Zalaudek I. Dermoscopy of patients with multiple nevi: improved management recommendations using a comparative diagnostic approach. *Arch Dermatol.* 2011;147(1):46–9.
21. van der Leest RJ, Flohil SC, Arends LR, de Vries E, Nijsten T. Risk of subsequent cutaneous malignancy in patients with prior melanoma: a systematic review and meta-analysis. *JEADV.* 2015;29(6):1053–62.
22. Ferrone CR, Porat LB, Panageas KS, Berwick M, Halpern AC, Patel A, Coit DG. Clinicopathological features of and risk factors for multiple primary melanomas. *JAMA*. 2005;294(13):1647–54.
23. Edinger JT, Radfar A, Jukic DM. Two cutaneous malignant melanomas at the same anatomic site: a case report with molecular evaluation. *J Cutan Pathol.* 2009;36(Supplement 1):74–9.
24. Titus-Ernstoff L, Perry A, Spencer S. Multiple primary melanoma, two year results from a population-based study. *Arch Dermatol*. 2006;142:433.
25. Moscarella E, Rabinovitz H, Puig S, Zalaudek I, Oliviero MC, Brown L, Alarcon I, Malvehy J, Longo C, Formisano D, Carrera C. Multiple primary melanomas: do they look the same? *Br J Dermatol.* 2013;168(6):1267–72.
26. Brady MS, Oliveria SA, Christos PJ, Berwick M, Coit DG, Katz J, Halpern AC. Patterns of detection in patients with cutaneous melanoma: implications for secondary prevention. *Cancer.* 2000;89(2):342–7.
27. Dessinioti C, Geller AC, Stergiopoulou A, Swetter SM, Baltas E, Mayer JE, Johnson TM, Talaganis J, Trakatelli M, Tsoutsos D, Tsouroufl is G. Association of skin examination behaviors and thinner nodular vs superficial spreading melanoma at diagnosis. *JAMA Dermatol.* 2018;154(5):544–53.
28. Swetter SM, Pollitt RA, Johnson TM, Brooks DR, Geller AC. Behavioral determinants of successful early melanoma detection: role of self and physician skin examination. *Cancer.* 2012;118(15):3725–34.
29. Kelly JW, Yeatman JM, Regalia C, Mason G, Henham AP. A high incidence of melanoma found in patients with multiple dysplastic naevi by photographic surveillance. *Med J Aust.* 1997;167:191–4.
30. Kopf AW, Rivers JK, Slue W, Rigel DS, Friedman RJ. Photographs are useful for detection of malignant melanomas in patients who have dysplastic nevi. *J Am Acad Dermatol.* 1988;19:1132–4.
31. Kittler H, Guitera P, Riedl E, et al. Identification of clinically featureless incipient melanoma using sequential dermoscopy imaging. *Arch Dermatol*. 2006;142:1113–9.
32. Tromme I, Sacré L, Hammouch F, Legrand C, Marot L, Vereecken P, Theate I, van Eeckhout P, Richez P, Baurain JF, Thomas L. Availability of digital dermoscopy in daily practice dramatically reduces the number of excised melanocytic lesions: results from an observational study. *Br J Dermatol.* 2012;167(4):778–86.
33. Menzies SW, Emery J, Staples M, Davies S, McAvoy B, Fletcher J, Shahid KR, Reid G, Avramidis M, Ward AM, Burton RC. Impact of dermoscopy and short-term sequential digital dermoscopy imaging for the management of pigmented lesions in primary care: a sequential intervention trial. *Br J Dermatol.* 2009;161(6):1270–7.
34. Goodson AG, Florell SR, Hyde M, et al. Comparative analysis of total body and dermatoscopic photographic monitoring of nevi in similar patient populations at risk for cutaneous melanoma. *Dermatol Surg.* 2010;36:1087–98.
35. Adler NR, Kelly JW, Guitera P, Menzies SW, Chamberlain AJ, Fishburn P, Button-Sloan AE, Heal C, Soyer HP, Thompson JF. Methods of melanoma detection and of skin monitoring for individuals at high risk of melanoma: new Australian clinical practice. *MJA*. 2019;210(1):41–7.
36. Gonzalez S, Swindells K, Rajadhyaksha M, Torres A. Changing paradigms in dermatology: confocal microscopy in clinical and surgical dermatology. *Clin Dermatol*. 2003;21:359–69.
37. Rajadhyaksha M, Grossman M, Esterowtiz D, Webb RH, Anderson RR. In vivo onfocal scanning laser microscopy of human skin: melanin provides strong contrast. *J Invest Dermatol*. 1995;104:946–52.
38. Stevenson AD, Mickan S, Mallett S, et al. Systematic review of diagnostic accuracy of reflectance confocal microscopy for melanoma diagnosis in patients with clinically equivocal skin lesions. *Dermatol Pract Concept*. 2013;3:19–27.
39. Borsari S, Pampena R, Lallas A, Kyrgidis A, Moscarella E, Benati E, Raucci M, Pellacani G, Zalaudek I, Argenziano G, Longo C. Clinical indications for use of reflectance confocal microscopy for skin cancer diagnosis. *JAMA Dermatol.* 2016;152(10): 1093–8.
40. Scope A, Longo C. Recognizing the benefits and pitfalls of reflectance confocal microscopy in melanoma diagnosis. *Dermatol Pract Concept*. 2014;4(3):67.
41. Coco V, Farnetani F, Cesinaro AM, Ciardo S, Argenziano G, Peris K, Pellacani G, Longo C. False-negative cases on confocal microscopy examination: a retrospective evaluation and critical reappraisal. *Dermatology*. 2016;232(2):189–97.
42. Braga JC, Macedo MP, Pinto C, Duprat J, Begnami MD, Pellacani G, Rezze GG. Learning reflectance confocal microscopy of melanocytic skin lesions through histopathologic transversal sections. *PLoS One.* 2013;8(12):e81205.

10 COLLISION TUMORS AND EXCEPTIONS TO RULES: FALSE POSITIVE AND FALSE NEGATIVE

Andrea Combalia, Xavier Fustà, Alicia Barreiro, and Cristina Carrera

Contents

Introduction . . . 237
False positives: Benign tumors that simulate cancer . . . 238
Seborrheic keratosis . . . 238
Hemangiomas . . . 239
Dermatofibroma . . . 239
Collision tumors . . . 239
False negatives: Skin cancers that simulate benign lesions . . . 239
Seborrheic keratosis–like melanomas . . . 239
Hemangioma-like melanoma . . . 240
Pyogenic granulomas . . . 240
Nonaccurate skin cancer diagnoses: Dermoscopic diagnoses that prove to be incorrect . . . 240
Basal cell carcinoma . . . 240
Squamous cell carcinomas . . . 241
References . . . 242

Introduction

While dermoscopy has improved our ability to differentiate benign from malignant lesions, "false positive" and "false negative" cases do exist, resulting in unnecessary excisions of benign lesions and more importantly, delay in the detection of malignant tumors.[1] Some lesions that may create these false positive/negative scenarios include collision tumors, featureless lesions, and lesions presenting with structures that are characteristic of other diagnosis.

Collision tumors feature poor lesions and lesions displaying dermoscopic criteria mimicking another diagnosis (exceptions to the established dermoscopic rules) that are particularly prone to misdiagnosis. Collision tumors can display a combination of features or sometimes, reveal a lack of specific criteria for rendering a diagnosis. The different entities comprising collision tumors can often be correctly identified via dermoscopy; however, a focus of a malignancy arising in association with a benign lesion such as a seborrheic keratosis may be overlooked due to anchoring bias and search satisfaction. This error occurs when the observer stops searching for features once the most conspicuous features are identified, and the diagnosis is anchored on them. For example, the clinician may diagnose a lesion as a seborrheic keratosis (SK) by anchoring the diagnosis on the presence of multiple conspicuous comedo openings or milia-like cysts, thereby stopping the search (i.e., search satisfaction) for any feature indicating a focus of malignancy within the SK (Figure 10.1).

Some malignancies, including cutaneous melanomas, may lack any evident dermoscopic features (i.e., *featureless lesions*) to aid in their diagnosis[2, 3]. A combined clinical and dermoscopic approach is required to help in their detection. Total body photography and digital dermoscopic monitoring have proven to be powerful means for identifying featureless melanomas based on observed changes (see Chapter 13).

Dermoscopic structures have strong associations with specific diagnosis, such as the association of aggregated brown globules with melanocytic neoplasms. However, occasionally, specific lesions may display *structures that are normally associated with another diagnosis*, such as globules seen in a clonal SK mimicking a melanocytic tumor. Viewing the histopathology correlates of these structures will reveal the cause of the misdiagnosis. In the example of the clonal SK, nests of pigmented basaloid cells within an acanthotic epidermis are the culprits leading to misdiagnosis, since they, similarly to nests of melanocytes, project as globules on dermoscopy, and this may incorrectly lead the clinician to the diagnosis of a melanocytic neoplasm.

Awareness of exceptions to the established rules in dermoscopy is essential to further improve upon the clinician's diagnostic accuracy. Before discussing some of the specific lesions that may mimic other diagnosis, it needs to be underscored that diagnostic accuracy and management decisions may not be coupled. For example, basal cell carcinomas (BCC) misdiagnosed as melanomas will lead to lowering of the clinician's diagnostic accuracy but will have no impact on the management decision to perform a biopsy. Benign lesions mimicking malignancy will also decrease the clinician's diagnostic accuracy, and although they will have an impact on management decision (i.e., unnecessary biopsy) and will negatively impact the benign to malignant biopsy ratio of the clinician, this will probably have minimal impact on individual patients (Figure 10.2).

On the other hand, malignancies mimicking benign lesions may lead to delays in diagnosis (false negative). While a delay in diagnosing a BCC will likely not lead to significant negative consequences, a delay in diagnosing a melanoma may. These so-called difficult to diagnose melanomas include nodular, nevoid, desmoplastic, spitzoid, amelanotic, and lentiginous melanomas on sun-damaged skin (see Chapters 8c, 8e, 8f). Knowledge of the exceptions to the dermoscopy rules will hopefully help clinicians avoid these pitfalls.

DOI: 10.1201/9780429487873-33

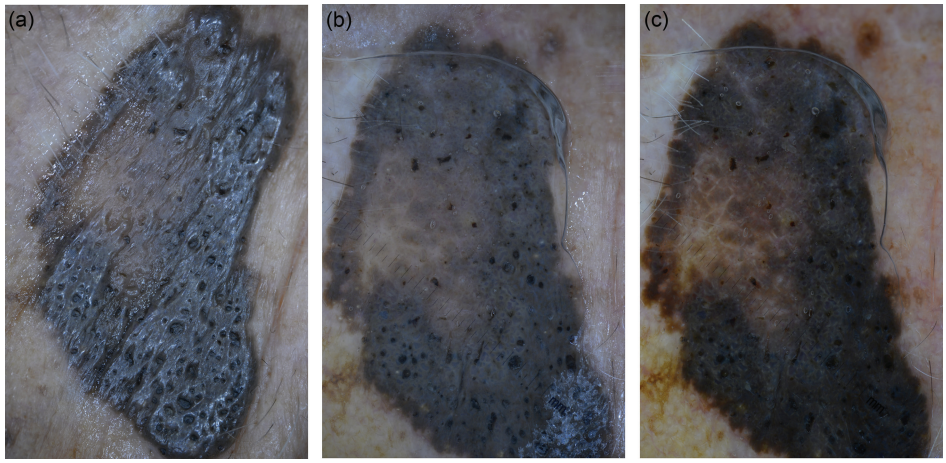

FIGURE 10.1 (a) Clinical image reveals a lesion with morphologic features consistent with seborrheic keratosis (SK). (b) Nonpolarized dermoscopy reveals comedo openings and confirms the clinical suspicion of SK. Search satisfaction occurs when the clinician anchors their diagnosis on the presence of comedo openings and stops searching for other features. (c) With polarized dermoscopy, there is a focal area revealing shiny white lines; a feature associated with malignancy. On histopathology, this proved to be a BCC of Pinkus arising in a SK.

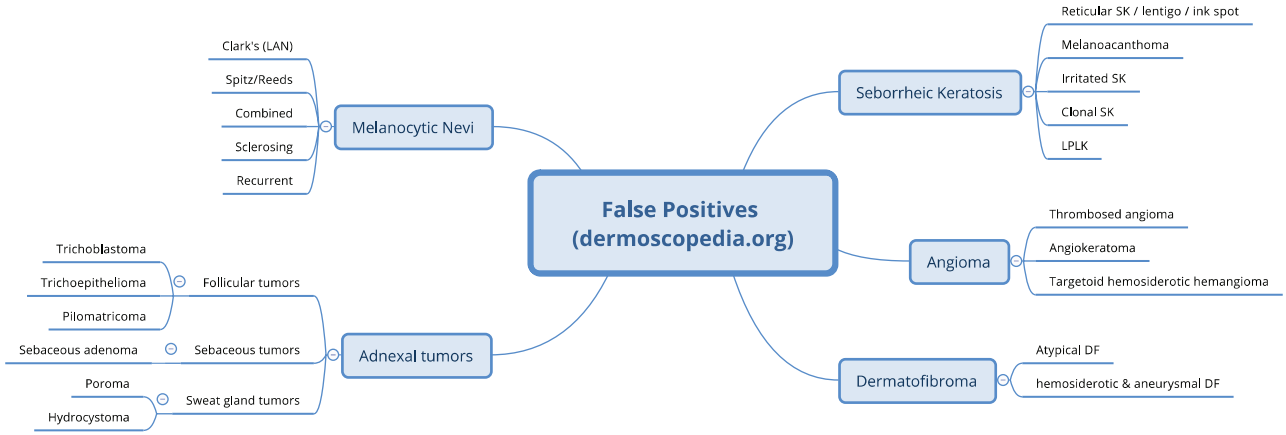

FIGURE 10.2 False positive lesions: Benign tumors that can mimic malignancy.

False positives: Benign tumors that simulate cancer

Benign lesions mimicking malignancy will be included in the differential diagnosis of melanoma and other pigmented tumors (melanocytic or nonmelanocytic).[4]

Seborrheic keratosis

Dermoscopic criteria for the diagnosis of SK include milia-like cysts, comedo-like openings or pseudofollicular openings, fissures and ridges (i.e., cerebriform pattern), light brown fingerprint-like structures, and hairpin vessels (see Chapter 6e). Although the majority of SK can be diagnosed with confidence, there is a subset of difficult lesions that can resemble a skin cancer. Some of these difficult to diagnose SK may be inflamed, highly pigmented, or reveal melanocytic-like structures such as a pigment network–like structure or globule-like structures, resulting in a SK that mimics melanoma or a squamous cell carcinoma (SCC).[5]

1. ***Melanoacanthoma*** is a rare variant of SK. Histopathology demonstrates a deeply pigmented benign proliferation of melanocytes and keratinocytes in a SK. (See Chapter 6e, Figure 6e.2.)
2. ***Inflamed or irritated SK*** may exhibit irregular and asymmetric vascularization, raising the differential diagnosis of amelanotic melanoma and SCC.[5, 6] (See Chapter 6e, Figures 6e.31, 6e.32, 6e.34.)
3. ***Lichen planus–like keratosis*** is a regressing epidermal neoplasm, most frequently a SK or an actinic keratosis. (See Chapter 6e.)
4. ***SK with melanocytic-like structures***. (See Chapter 6e.)
   a. ***SK with pigment network–like structures.*** This network-like structure is usually thinner with larger holes and abrupt ending as compared with the true pigmented network of melanocytic lesions.[6]
      – ***Ink spot lentigo***, also known as reticular SK, is characterized by a prominent black network with a three-dimensional quality. Lines of the network can be thick or thin, and end abruptly at the edge of the lesion. (Figures 6e.2, 8e.12.)

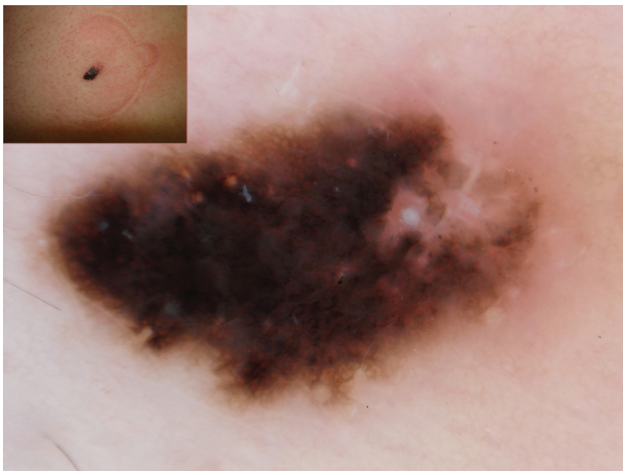

FIGURE 10.3 Clinical image of a heavily pigmented and suspicious lesion (inset). Dermoscopy showed atypical pigmented network, blue-black sign, and focal asymmetric shiny white streaks. The whole picture was suggestive of melanoma, but histopathology confirmed dermatofibroma.

b. ***SK with globule-like structures.***

– ***Clonal SK*** is a rare variant of SK that presents with nests of basaloid cells, resembling globular structures as seen in melanocytic lesions. Under dermoscopy, clonal SK reveal light brown to dark brown/blue globules. (Figure 6e.24.)

Hemangiomas

Cherry angiomas and angiokeratomas. On occasion, vascular lesions such as cherry angiomas and angiokeratomas can mimic melanoma, in particular when there are deep or thrombosed vessels. (See Chapter 6g.)

Targetoid hemosiderotic hemangiomas. (See Chapter 6g.)

Dermatofibroma

Although dermatofibromas (DFs) are well-characterized lesions and demonstrate a high positive predictive value when diagnosed with dermoscopy, some DFs may mimic melanoma (Figure 10.3).[7–9] These difficult to diagnose DFs may present with additional structures such as shiny white lines and atypical vessels, which are also seen in melanoma. However, in DFs, these structures tend to be located towards the center of the lesion and over the scarlike area. In contrast, melanomas reveal a more disorganized pattern, with a random distribution of the structures. In addition, the central scarlike area seen in DFs is usually not associated with other regression structures, while melanomas often reveal granularity, which is often associated with scarlike areas. (See Chapter 6a.)

1. ***Atypical dermatofibromas***

   Some DFs may reveal atypical structures such as atypical network, atypical scarlike area, negative network, and homogeneous pigmentation. As a result, these atypical DFs may be difficult to differentiate from melanoma. (See Chapter 6a.)

2. ***Hemosiderotic and aneurismal dermatofibromas***

   The hemosiderotic variant of DF can reveal a diffuse or localized homogeneous blue, blue-grey, blue-yellow, or blue-red pigmentation. This pigmentation correlates with siderophages containing hemosiderin, as well as hemosiderin deposition in the dermis. (See Chapter 6a.)

Additional clues to help differentiate DFs from skin cancer include:

- Palpation. DFs reveal a positive "dimple sign," which consists of a central depression when the lesion is pressed along its margin.
- The peripheral network in DFs is fine, light brown, and often associated with ring-like globules, which are located toward the center of the lesion between the delicate network and the central scarlike area.

Adnexal tumors. (See Chapter 6h.)

Melanocytic nevi. (See Chapters 7a–7f.)

1. ***Blue nevus.*** The prototypical pattern observed in blue nevi is the homogeneous blue pattern. On occasion, this homogeneous blue pigmentation can also be seen in nodular melanoma/dermal melanoma and cutaneous metastasis of melanoma. Clues to the correct diagnosis of a melanoma or cutaneous metastasis include the history of recent changes and/or a previous invasive melanoma, and the presence of other dermoscopic structures such as differing shades of blue, pink, crystalline structures, and atypical vessels. (See Chapter 7d.)
2. ***Acquired and congenital nevi.*** Early superficial spreading melanomas sometimes lack melanoma-specific structures, and therefore, the dermoscopic diagnosis of early featureless melanomas can be challenging. As a result, patients with the atypical mole syndrome should be followed with digital monitoring, whereby early melanomas can be detected without increasing the number of unnecessary excisions. The appearance of melanoma-specific structures in a congenital nevus, such as atypical network, focal negative network, crystalline structures, streaks, irregular blotches, blue-white veil, or regression structures should be of concern and lead to the excision of the nevus. (See Chapter 7a.)

Collision tumors

Collision tumors include either two different entities that are so close to each other that they clinically appear as one lesion, or the development of one tumor within and intermingled with another one. In any case, the dermoscopic evaluation improves the identification of both components. During routine examination, dermatologists must have in mind that collision tumors are frequent and can be diagnosed easily if suspected. However, rare cases can be challenging when independent dermoscopic criteria are unrecognizable. Collision tumors are frequently found on sun-damaged skin, SK almost always being involved. Usually, collisions between SKs and melanocytic lesions are found in young patients, while the combination of SK and BCC is found in persons older than 60 years old[10] (Figures 10.4, 10.5).

False negatives: Skin cancers that simulate benign lesions

Seborrheic keratosis–like melanomas

Melanomas that simulate SK can be dermoscopically challenging. The presence of blue and black colors (blue-black

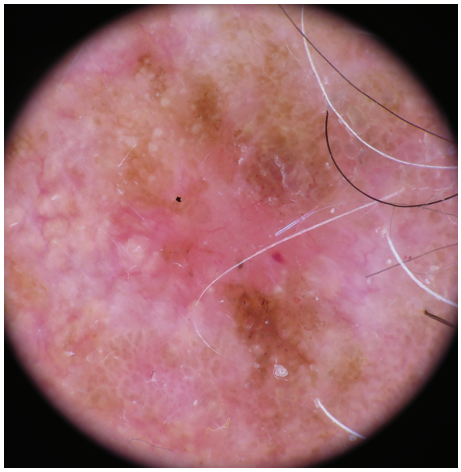

FIGURE 10.4 Dermoscopy of a collision tumor: The central part shows an erythematous area with blue-grey ovoid nest and fine in-focus vessels, allowing the diagnosis of basal cell carcinoma (BCC) to be made. At the periphery, milia-like cysts, fissures, ridges, and the cerebriform pattern suggest a seborrheic keratosis (SK). The lesion was completely excised, and a collision between BCC and SK was confirmed.

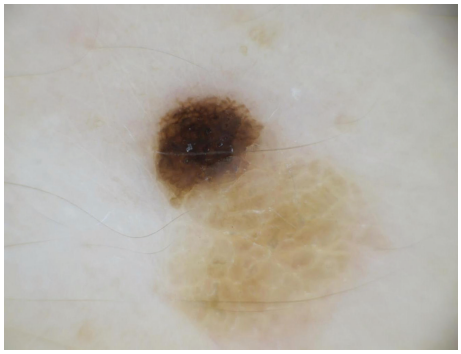

FIGURE 10.5 Dermoscopy of a collision tumor: The upper part of the lesion shows a heavily pigmented lesion with an atypical pigmented network suggesting a melanocytic lesion. The other part of the lesion shows a cerebriform pattern with fissures and ridges, suggesting a seborrheic keratosis. The lesion was completely excised, and a collision between a melanocytic nevus and seborrheic keratosis was confirmed.

sign), pigment network, pseudopods or streaks, and/or blue-white veil, despite the presence of other SK features, allows the correct diagnosis of most of the difficult melanoma cases (Figure 10.6). [6] (See Chapter 8e.)

It is important to note that some skin cancers, including melanoma, can reveal milia-like cysts and comedo-like openings, yet they should be ignored during the evaluation of lesions that are considered melanocytic or until the entire lesion has been completely evaluated. Structures that are easily recognized may produce some diagnostic errors, such as anchoring bias or first impression, where the diagnosis is based on these structures that are easily recognized. As a result, the decision-making process is interrupted once the structure is identified, leaving the rest of the lesion without evaluation; thus, other structures will be unnoticed, and a false negative diagnosis will be rendered.

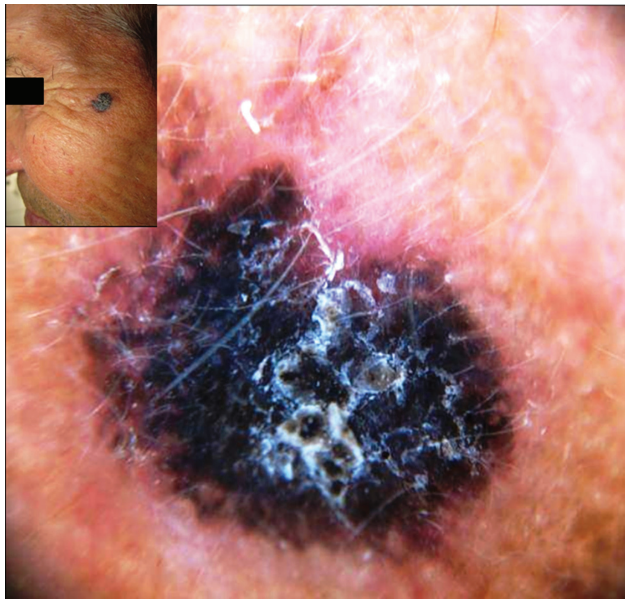

FIGURE 10.6 Hyperkeratotic and pigmented lesion on the face of an 80-year-old male, clinically resembling seborrheic keratosis (inset). Dermoscopy revealed obliteration of the facial pseudonetwork, in addition to central keratin and comedo-like openings. Despite the keratinizing surface, the presence of blue-black sign led to ruling out malignancy. Pathology confirmed invasive cutaneous melanoma (Breslow depth 0.8 mm).

Hemangioma-like melanoma

Rarely, melanomas (primary or metastatic) can clinically and dermoscopically resemble vascular lesions, such as hemangiomas and angiokeratomas. Dermoscopically, these melanomas can reveal red to purple ill-defined lacunar-like structures, usually in combination with atypical vessels, and milky-red areas (Figure 10.7). In contrast, cherry angiomas and angiokeratomas tend to reveal lacunae that are red, dark red, red-blue, or blue-black and are separated by well-defined septae. Clinicians must suspect malignancy in any case of fast-growing hemangioma-like tumor with atypical vessels within the lacunae, or lacunae-like areas with shiny white and milky-red areas (Chapter 6g).

Pyogenic granulomas

Despite their characteristic dermoscopic presentation, pyogenic granulomas should always be histopathologically confirmed. Rare amelanotic nodular melanomas and melanoma metastasis may have a morphology resembling pyogenic granulomas (Chapter 6g).

Nonaccurate skin cancer diagnoses: Dermoscopic diagnoses that prove to be incorrect

Accuracy or validity is established when the dermoscopic diagnosis/impression is shown to be correct. On occasion, skin cancers will be miscalled (i.e., BCC miscalled as melanoma), resulting in lower diagnostic accuracy for the clinician. Yet, this miscalling will have no impact on the management decision to perform a biopsy, and the skin cancer will be diagnosed.

Basal cell carcinoma

BCC may reveal features that mimic structures seen in melanomas, and vice versa, including (Figure 10.2, see Chapters 6b, 8b, 8f):



FIGURE 10.7 This lesion was clinically suggestive of capillary hemangioma. Dermoscopy showed ill-defined lacunar-like structures, milky-red areas, and importantly, vessels within the lacunae. The patient had a history of invasive cutaneous melanoma, and this lesion appeared 20 cm from the scar. Biopsy confirmed the suspicion of melanoma metastasis.

- ***Globules.*** Globules seen in BCC may simulate those globules seen in melanocytic lesions. However, in BCC, globules usually demonstrate a blue-grey color and are not aggregated. In addition, BCCs should lack other features observed in melanocytic lesions, such as network, aggregated globules, or streaks (Figure 10.8).).
- ***Leaf-like areas.*** Leaf-like areas can be mistaken as streaks seen in melanocytic lesions. However, leaf-like areas in BCCs are broader lines that radiate towards the tumor and converge at multiple different focal points, usually at the periphery of the lesions. Each central point will be the center of a few lines, resulting in a leaf-like area. In contrast, streaks in a melanocytic lesion are thinner, centrifugal, and in-focus lines that radiate away from the tumor mass towards normal skin.
- ***Shiny white structures.*** Shiny white structures in BCC appear as blotches and strands, which are usually more disorganized as compared with those in melanomas, which tend to be short lines orthogonally oriented (i.e., shiny white lines or crystalline structures) (Figure 10.9).
- ***Homogeneous blue pigmentation***. On occasions, BCC can present with a large blue ovoid nest that occupies almost the entire lesion, simulating a homogeneous blue pattern. However, BCC may reveal other diagnostic features such as shiny white blotches and strands, in-focus brown dots, or blue-grey nonaggregated globules.
- ***Arborizing vessels.*** Arborizing vessels are commonly observed in BCC, yet they can also be seen in some melanocytic lesions, including thick melanomas and cutaneous melanoma metastases.

Squamous cell carcinomas

Pigmented and nonpigmented SCC can simulate a melanoma when some of the following features are present (see Chapter 6d):

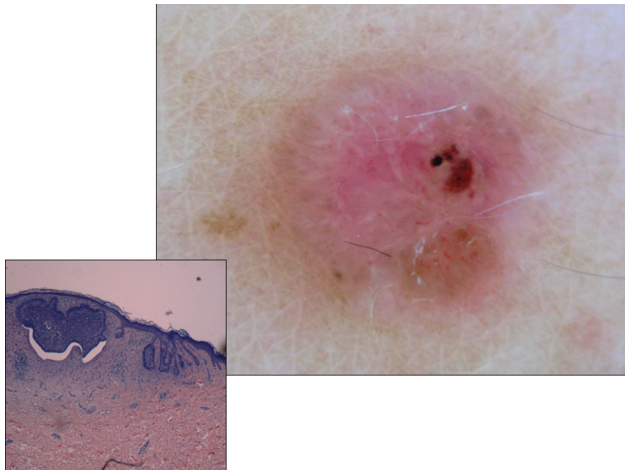

FIGURE 10.8 Dermoscopic image of a nonspecific pink tumor on the abdomen of a 23-year-old female. Dermoscopy revealed milky-red areas, a few short vessels out of focus, and some remnants of peripheral pigment. Overall dermoscopic features were suggestive of inflamed melanocytic lesion; therefore, melanoma should be ruled out. Histopathology confirmed the diagnosis of a nodular basal cell carcinoma (lower box).



FIGURE 10.9 Dermoscopy shows a lesion with a nonspecific pattern. Focal reticular pigmentation and blue grey dots make necessary to rule out melanoma. Histopathology confirmed superficial pigmented basal cell carcinoma.

- ***Structureless lesions***. Following the two-step algorithm, structureless lesions will be considered melanocytic by default. These structureless lesions are either monitored using digital dermoscopy (i.e., short-term digital monitoring), imaged using confocal microscopy, or biopsied.
- ***Brown dots or globules***. Pigmented SCC can present with focal brown dots or globules that are linearly arranged, often towards the periphery of the lesion.
- ***Polymorphous vessels*** are the clue for any malignant tumor, including melanoma and SCC. The clinical appearance with keratin, in the context of a cancerization field, is in favor of SCC. However, any nonspecific tumor with atypical vessels should undergo a skin biopsy

to rule out a malignant skin tumor (i.e., angiosarcoma, Merkel cell carcinoma, metastasis, lymphoma).

References

1. Papageorgiou V, et al. The limitations of dermoscopy: false-positive and false-negative tumours. *J Eur Acad Dermatol Venereol*. 2018. doi:10.1111/jdv.14782
2. Argenziano G, et al. Dermoscopy features of melanoma incognito: Indications for biopsy. *J Am Acad Dermatol*. 2007. doi:10.1016/j.jaad.2006.10.029
3. Puig S, et al. Melanomas that failed dermoscopic detection: A combined clinicodermoscopic approach for not missing melanoma. *Dermatologic Surg*. 2007. doi:10.1111/j.1524-4725.2007.33264.x
4. Carli P, De Giorgi V, Giannotti, B. Dermoscopy as a second step in the diagnosis of doubtful pigmented skin lesions: How great is the risk of missing a melanoma? *J Eur Acad Dermatol Venereol*. 2001. doi:10.1046/j.1468-3083.2001.00147.x
5. Carrera C, et al. Dermoscopy improves the diagnostic accuracy of melanomas clinically resembling seborrheic keratosis: cross-sectional study of the ability to detect seborrheic keratosis-like melanomas by a group of dermatologists with varying degrees of experience. *Dermatology*. 2018. doi:10.1159/000486851
6. Carrera C, et al. Dermoscopic clues for diagnosing melanomas that resemble seborrheic keratosis. *JAMA Dermatol*. 2017. doi:10.1001/jamadermatol.2017.0129
7. Aljasser MI, Martinka M, Kalia S Dermatofibroma mimicking melanoma dermoscopically. *Clin Exp Dermatol*. 2014. doi:10.1111/ced.12155
8. Ferrari A, et al. Typical and atypical dermoscopic presentations of dermatofibroma. *J Eur Acad Dermatol Venereol*. 2013. doi:10.1111/jdv.12019
9. Zaballos P, et al. Dermoscopic findings of haemosiderotic and aneurysmal dermatofibroma: Report of six patients. *Br J Dermatol*. 2006. doi:10.1111/j.1365-2133.2005.06844.x
10. Blum A, et al. Collision skin lesions: results of a multicenter study of the International Dermoscopy Society (IDS). 2017;7:51–62.

11A SPECIAL LOCATIONS: FACE

Sarah N. Hocker, Harold S. Rabinovitz, Margaret C. Oliviero, and Ashfaq A. Marghoob

Contents

Nonmelanocytic facial lesions . . . 243
Dermoscopy of pigmented nonmelanocytic and melanocytic facial lesions . . . 243
Solar lentigines and seborrheic keratoses . . . 245
Facial melanoma and melanoma simulators . . . 246
Facial melanoma . . . 246
Simulators of melanoma . . . 249
Pigmented actinic keratosis . . . 249
Facial lichen planus–like keratosis . . . 250
Pigmented basal cell carcinoma . . . 250
Key points . . . 251
References . . . 251

Dermoscopy of facial lesions can be challenging, mostly because facial lesions often manifest different dermoscopic criteria than the same lesions found on different anatomic parts of the body due to the unique anatomical features of the facial skin. The rete ridges on facial skin are attenuated due to the inherent anatomy of facial skin and due to epidermal thinning resulting from a lifetime of solar exposure (3, 13 (Figure 11a.1). Two predominant patterns are demonstrated with pigmented lesions: an annular and a reticular pattern. An annular pattern is characterized by small circles (follicular openings) surrounded by varying amounts of pigment (Figure 11a.2). Lesions with an annular pattern include Clark's nevus, solar lentigo, early seborrheic keratosis (SK), lichen planus–like keratosis (LPLK), pigmented actinic keratosis (AK), and melanoma in situ (Figures 11a.2-11a.4). The reticular pattern (also known as fingerprinting) is characterized by fine, thin lines that are short, curved, or interrupted. Lesions that can demonstrate a reticular pattern include a solar lentigo and melanoma (Figures 11a.5).

One of the most important roles for dermoscopy of facial lesions remains the early diagnosis of melanoma in situ on sun-damaged skin. The diagnosis of melanoma in situ on sun-damaged skin is made difficult by the fact that there are a number of lesions that can mimic melanoma, including SK, LPLK, and pigmented basal cell carcinoma (BCC). Knowing the basic rules of facial dermoscopy can aid in the differentiation between melanoma simulators and melanoma.

Nonmelanocytic facial lesions

The dermoscopic criteria for facial nonmelanocytic lesions are in general the same as the criteria for nonfacial lesions. BCCs, squamous cell carcinomas, and sebaceous hyperplasia are very common facial lesions, and their features are outlined in the following. This is also true for SK, lentigines, LPLK, AK, and pigmented BCC; however, since these lesions can mimic melanoma, they are discussed in the next section together with melanocytic lesions.

1. BCC (Figures 11a.6–11a.8):
    a. Absence of a pigmented network.
    b. Leaf-like structures (pigmented BCC).
    c. Multiple nonaggregated blue-gray dots or blue globular structures (pigmented BCC).
    d. Large blue to blue-gray ovoid nests (pigmented BCC).
    e. Spoke wheel–like areas or concentric structures (pigmented BCC).
    f. Arborizing (serpentine or serpentine branched) telangiectasias.
    g. Ulceration.
    h. Pink-white to white shiny areas.
2. Squamous cell carcinoma (Figures 11a.9 and 11a.10):
    a. Dotted or glomerular vessels.
    b. Scaling associated with these lesions often makes it difficult to visualize the underlying dermoscopic structures.
3. Sebaceous hyperplasia (Figures 11a.11):
    a. Yellow to yellow-white lobular structures resembling popcorn.
    b. Linear winding or serpentine vessels at the periphery of the lesion that radiate toward the center of the lesion but do not cross the center of the lesion. These vessels are known as "wreath vessels" or "crown vessels."

Dermoscopy of pigmented nonmelanocytic and melanocytic facial lesions

The *annular pattern* is characterized by small hypopigmented circles and follicular openings surrounded by varying amounts of pigment (Figures 11a.3, 11a.4). Benign lesions tend to have circles with the same size and shape, few colors, and are relatively symmetrical. Malignant lesions often have circles of different sizes and shapes, many colors, and are asymmetrical. Gray dots and granules indicate that the lesion may be malignant. The presence of gray dots and granules is called the annular-granular pattern (Figure 11a.4) and is associated with a high suspicion of malignancy.

DOI: 10.1201/9780429487873-34

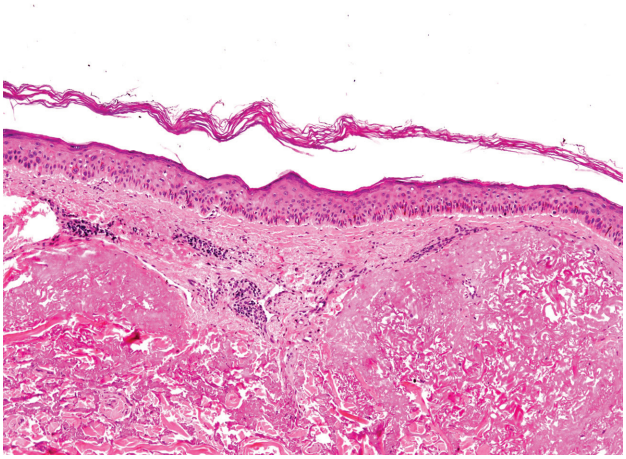

FIGURE 11A.1 Facial skin with characteristic flattening of rete ridges.

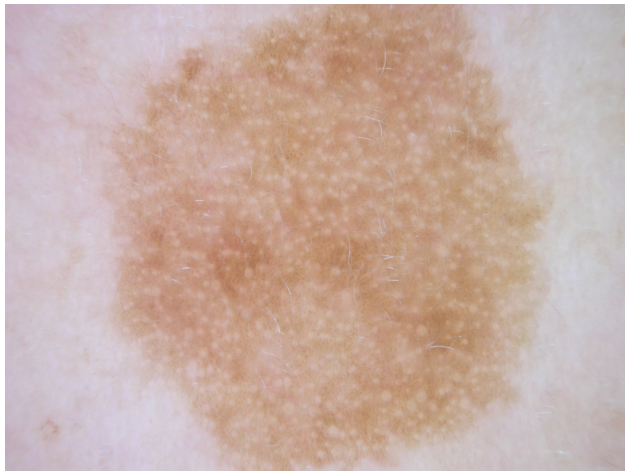

FIGURE 11A.2 Annular pattern demonstrated by a solar lentigo. The pigmentation surrounding the eccrine glands and follicular openings accentuates these structures, forming circles and rings, which creates an annular pattern.

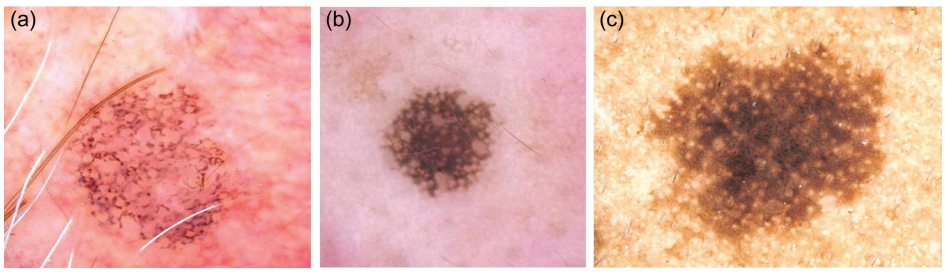

FIGURE 11A.3 Examples of the annular pattern. (a) Lichen planus–like keratosis. (b) Clark nevus. (c) Seborrheic keratosis. Benign lesions typically have circles of the same size with even distribution of pigment.

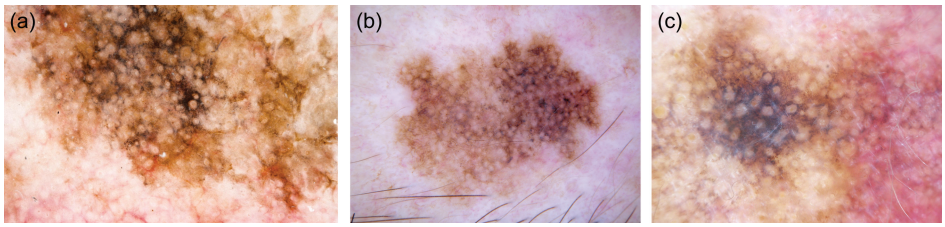

FIGURE 11A.4 (a–c) Malignant lesions often have circles of different sizes and shapes, many colors, and are asymmetrical. Gray dots/granules are a helpful sign (annular-granular pattern).

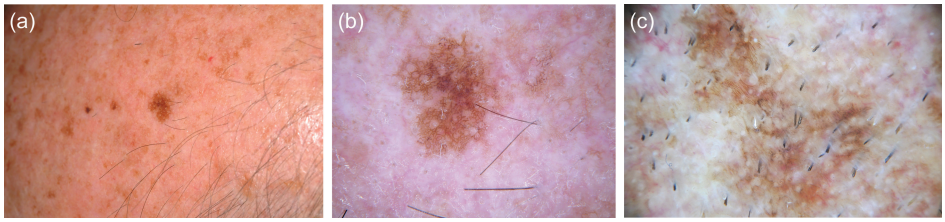

FIGURE 11A.5 (a) Clinical image. (b) The reticular pattern is often seen in solar lentigines. (c) The reticular pattern in a melanoma.

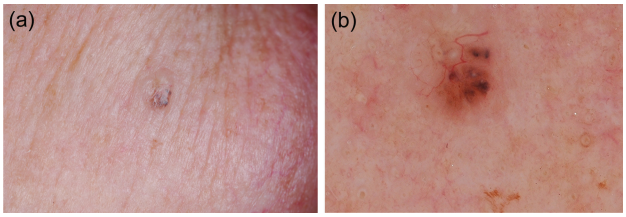

FIGURE 11A.6 (a) Clinical image of a pigmented BCC. (b) Dermoscopy of this BCC reveals blue-gray ovoid nests and arborizing vessels that are bright red and sharply in focus.

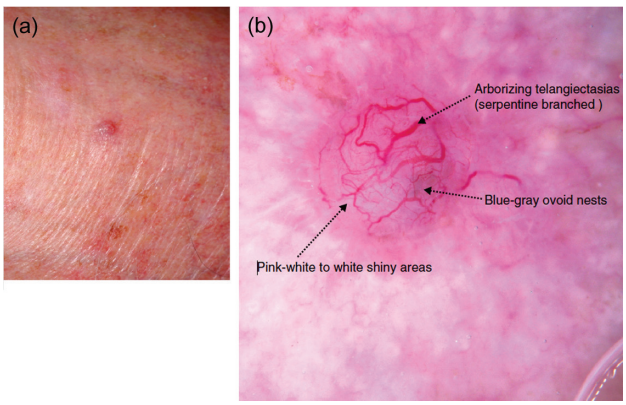

FIGURE 11A.7 (a) Clinical image of a BCC. (b) Dermoscopy image of a basal cell carcinoma demonstrating blue-gray ovoid nests, arborizing vessels, and a pink-white shiny area.

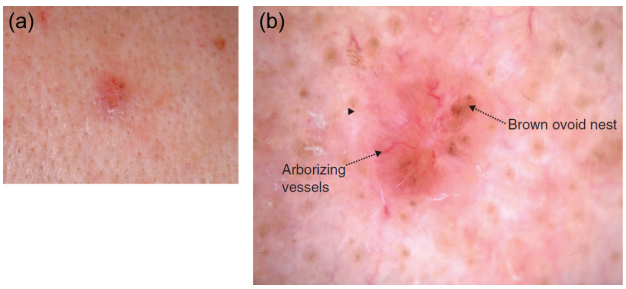

FIGURE 11A.8 (a) Clinical image. (b) Basal cell carcinoma with telangiectasia and brown ovoid nests.

The *reticular pattern* is characterized by fine, thin hyperpigmented lines and is most commonly seen in solar lentigines and sometimes, melanoma (Figures 11a.5). The lines may be interrupted and may appear to have a pattern similar to a fingerprint.

Solar lentigines and seborrheic keratoses

Solar lentigines have the following dermoscopic features (Figures 11a.12 and 11a.13):

a. Annular pattern with areas of light brown and dark brown
b. Reticular pattern with fingerprinting and fine interrupted lines
c. Sharp borders
d. Moth-eaten borders

In addition to the characteristics of a solar lentigo, early SK may have the following features:

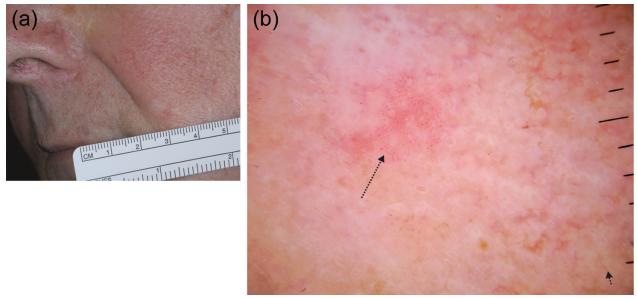

FIGURE 11A.9 (a) Clinical image. (b) Multiple dotted vessels (*arrow*) in a squamous cell carcinoma.

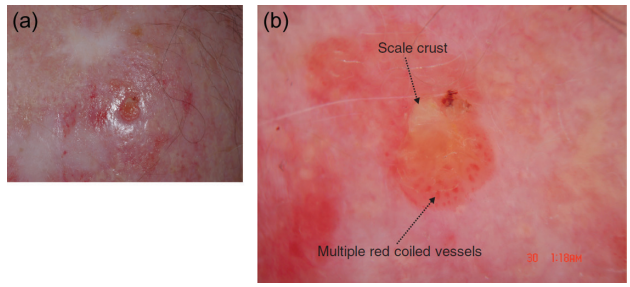

FIGURE 11A.10 (a) Clinical image. (b) Glomerular vessels and scale crust in a squamous cell carcinoma.

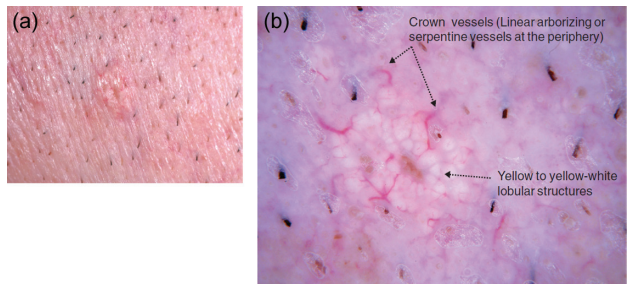

FIGURE 11A.11 (a) Clinical image. (b) Sebaceous hyperplasia with yellow-white lobular structures and linear winding vessels at the periphery of the lesion, which are known as "crown vessels."

a. Fine interrupted lines that are often thicker than those seen in solar lentigines
b. Bulbous projections and ridge formation (fat finger-like structures or gyri)
c. A few milia-like cysts and/or comedo-like openings

The dermoscopic features of mature SK on the face are the same as on other areas of the body (Figures 11a.14 and 11a.15):

a. Sharply demarcated borders
b. Milia-like cysts
c. Comedo-like openings (crypts)
d. Fissures (sulci)
e. Ridges (gyri)
f. Hairpin vessels with a white halo

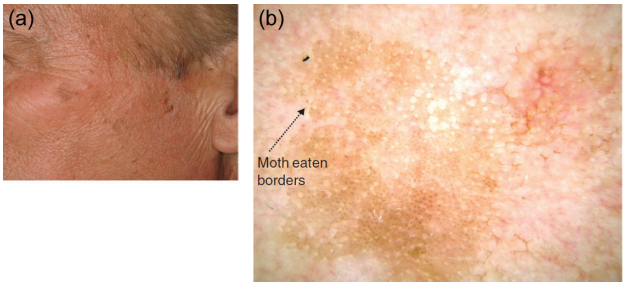

FIGURE 11A.12 (a) Clinical image. (b) Solar lentigines may demonstrate the annular pattern with areas of light and dark brown and moth-eaten borders.

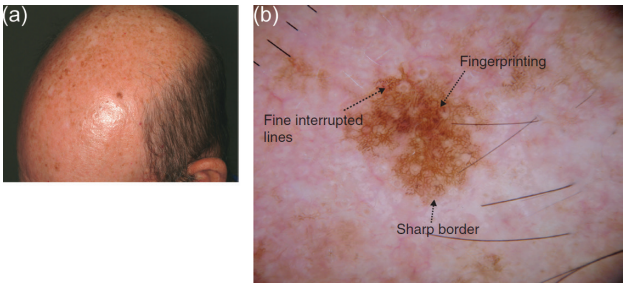

FIGURE 11A.13 (a) Clinical image. (b) Reticular pattern with fingerprinting, fine interrupted lines, and a sharp border may be seen in solar lentigines.

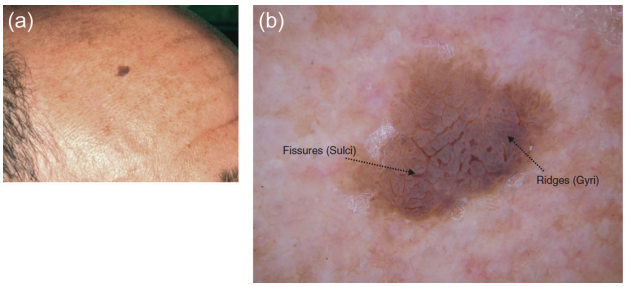

FIGURE 11A.14 (a) Clinical image. (b) Mature seborrheic keratosis on the face with ridges and fissures creating a cerebriform pattern.

Flat pigmented lesions, such as Clark nevi junctional type, are characterized by an annular pattern (Figure 11a.16). Nevi that are raised due to a prominent dermal component, such as in congenital nevi and compound Clark nevi, take on the same dermoscopic features as similar nevi seen on other areas of the body. For example, a dermal nevus with a globular pattern will appear the same on the torso as on the face (Figures 11a.17).

Facial melanoma and melanoma simulators

To say that the dermoscopy diagnosis of melanoma of the face is challenging is an understatement. Much of the difficulty of diagnosing facial melanomas lies in the fact that many other lesions, including pigmented AK, LPLK, and occasionally pigmented BCC, may simulate melanoma.

Facial melanoma

Facial melanomas are typically found in the elderly in areas with photo-damage. The elucidation of clinical and

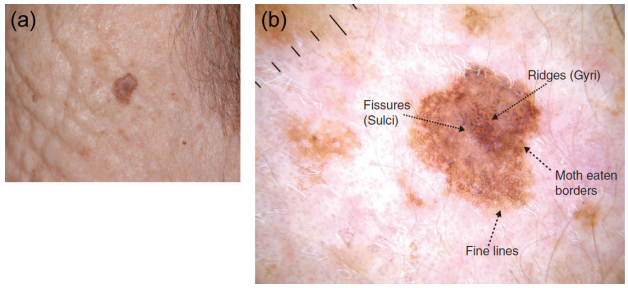

FIGURE 11A.15 (a) Clinical image. (b) Seborrheic keratosis on the face with fine lines, ridges, fissures, and moth-eaten borders.

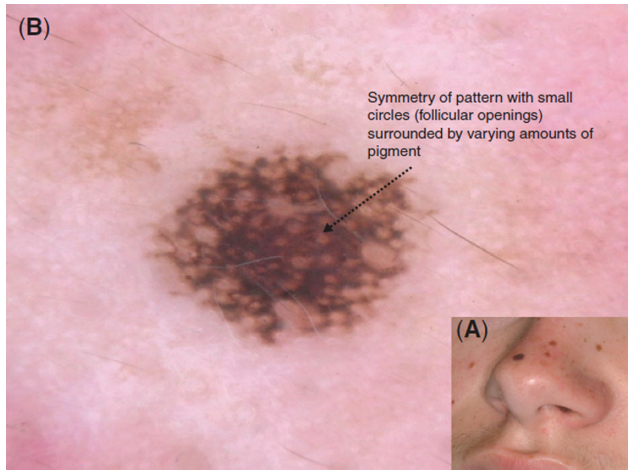

FIGURE 11A.16 (a) Clinical image. (b) Clark nevi junctional type with an annular pattern.

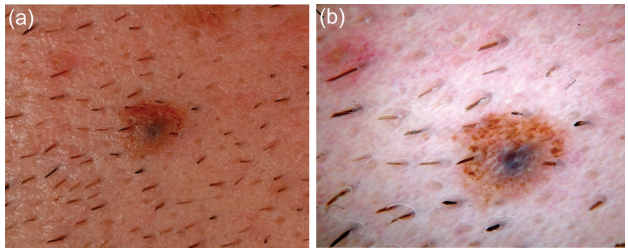

FIGURE 11A.17 (a) Clinical image. (b) Combined melanocytic nevi demonstrating a globular homogeneous pattern.

dermoscopic diagnostic criteria for facial melanoma and melanoma simulators is therefore critical.

Understanding the patterns of early facial melanoma is critical for diagnosing this cancer. The pattern appears to change as the lesion evolves. A facial melanoma progression model has been described in which the earliest manifestations of melanoma in situ on sun-damaged skin are slate-gray dots and granules, which may progress to form angulated lines (zig-zag pattern) (11) (Figures 11a.18–11a.24). The slate-gray dots represent either free melanin or melanin within macrophages. As the gray dots and granules accumulate around the follicles, the annular-granular pattern is formed. Later, short angulated lines can be seen, and these lines can coalesce to form polygonal structures such as rhomboids. As melanoma



FIGURE 11A.18 Facial melanoma progression model with four stages. (From Schiffner, R., in: A.A. Marghoob, R.P. Braun, A.W. Kopf, eds., *Atlas of Dermoscopy*, Taylor & Francis, Oxford, 2005, figure 10.33.)

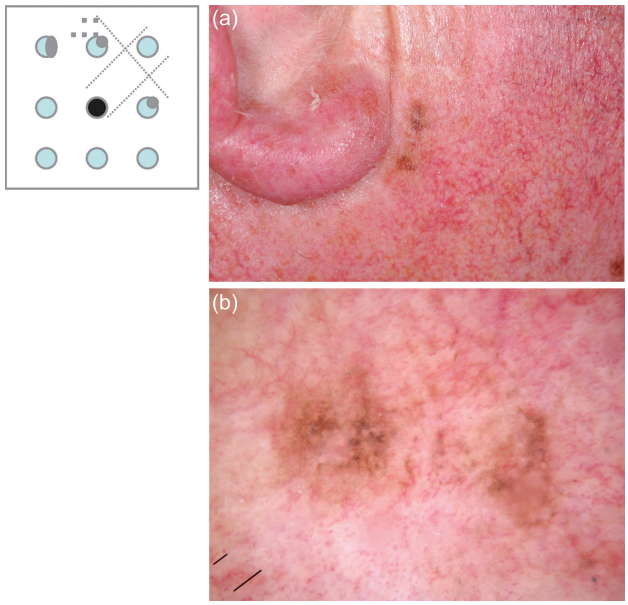

FIGURE 11A.19 The facial melanoma progression model: Stage 1, demonstrating annular-granular structures.

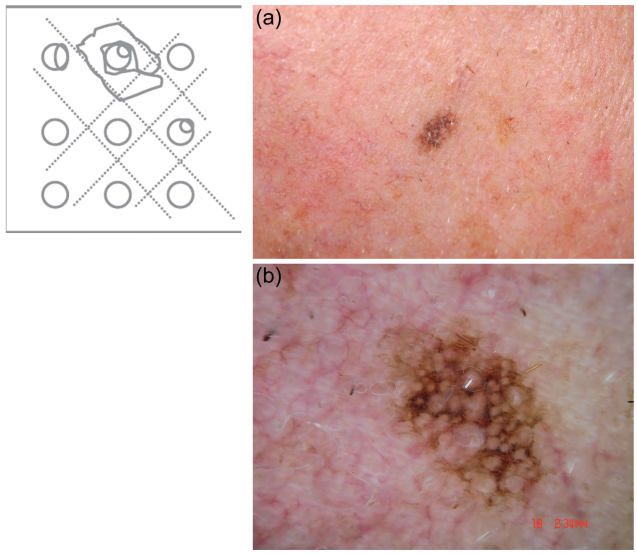

FIGURE 11A.21 The facial melanoma progression model: Stage 1, demonstrating rhomboid structures.

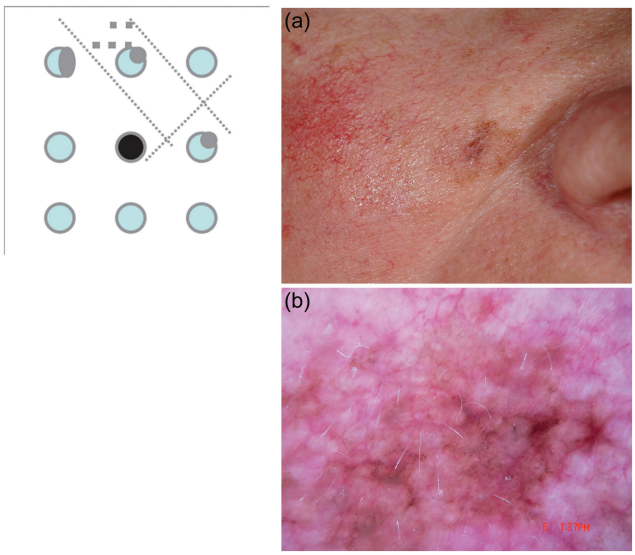

FIGURE 11A.20 The facial melanoma progression model: Stage 1, demonstrating short angulated lines.

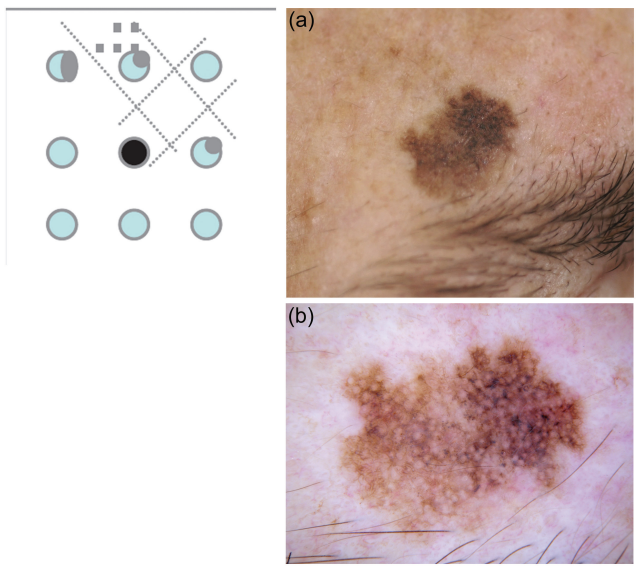

FIGURE 11A.22 The facial melanoma progression model: Stage 2, demonstrating rhomboid structures and perifollicular invasion.

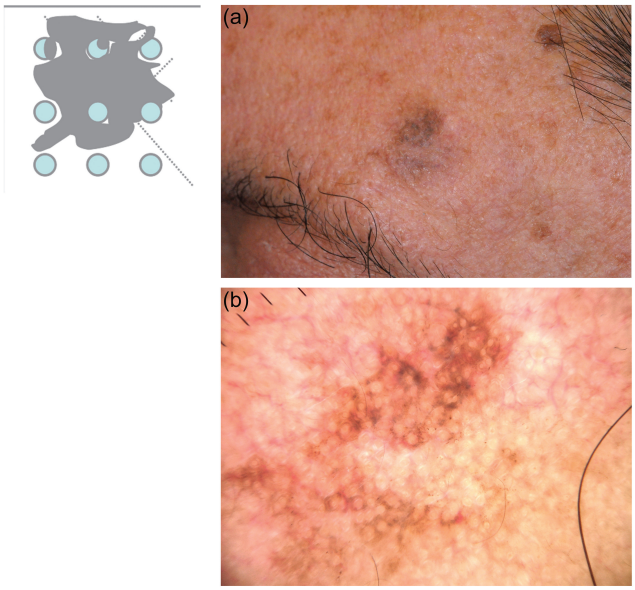

FIGURE 11A.23 The facial melanoma progression model: Stage 3, demonstrating homogeneous areas and follicular openings preserved.

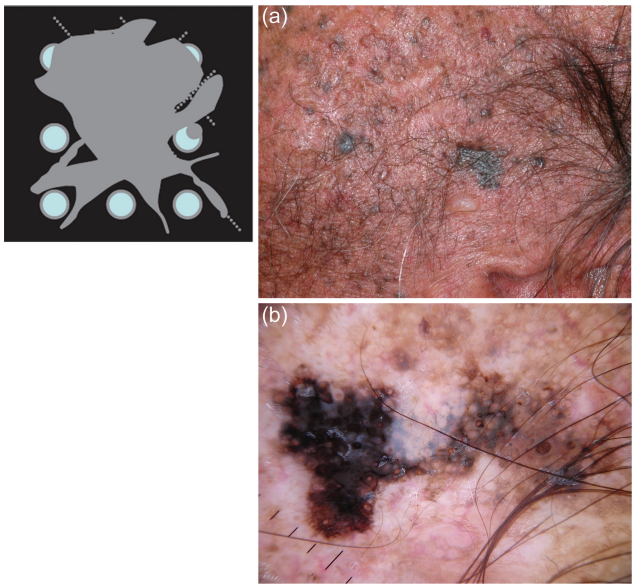

FIGURE 11A.24 The facial melanoma progression model: Stage 4, demonstrating homogeneous areas and follicular openings obliterated.

cells within follicles multiply, asymmetric pigmented follicular openings, often displaying a grayish hue, can be visualized dermoscopically. It must be highlighted that while the presence of a gray color is the single most sensitive feature for lentigo maligna, this lacks specificity, since it can also be seen in pigmented AK and LPLK (14, 15). Although asymmetric follicular openings can be seen in lentigines, in lentigines, their color is tan to brown, and in melanoma, they often have a grayish hue. Asymmetric (grayish) pigmented follicular openings result when there is uneven invasion by melanoma cells located within hair follicles. Furthermore, a structure called circle within a circle or isobar can be seen as the melanoma

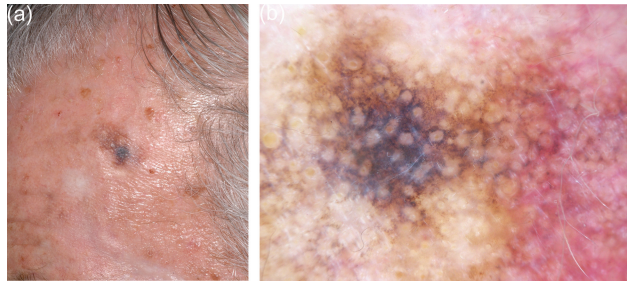

FIGURE 11A.25 (a) Clinical image. (b) Facial melanomas have asymmetry and multiple colors. Diagnosis: Lentigo maligna melanoma.

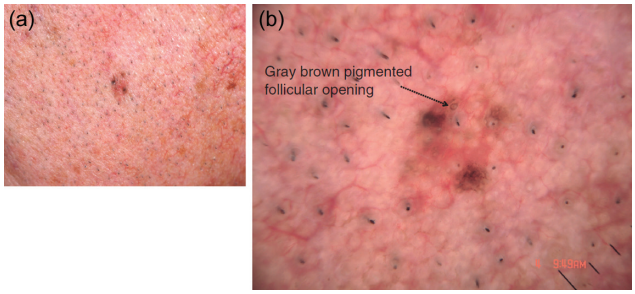

FIGURE 11A.26 (a) Clinical image. (b) Gray-brown follicular openings. Diagnosis: Lentigo maligna.

cells proliferate along the dermo-epidermal junction within and around the follicles (9). In the final stage of the progression model, the polygonal (rhomboid) structures become thickened, and the hair follicles are obliterated as the melanoma becomes more advanced. White scarlike areas may also be present, representing regression. One last important point to highlight is that amelanotic melanomas on the face have the same features as amelanotic melanomas on other body sites, and the reader is encouraged to read the appropriate chapters in this book that describe the features of amelanotic tumors.

Dermoscopic features of facial melanoma include global features of asymmetry and multiple colors (Figure 11a.25). Local features of facial melanoma include (17, 19):

- Gray follicular openings (Figure 11a.26)
- Irregular gray/brown pigmentation between follicles (Figure 11a.27)
- Circle within a circle (Figure 11a.28)
- Slate-gray to blue-gray dots/granules (Figure 11a.29)
- Angulated lines and rhomboidal structures (Figure 11a.30)
- Dark structureless areas obscuring the follicular openings (Figure 11a.31)
- Blue-white veil (Figure 11a.32)
- White shiny structures (visible with polarized light) (Figure 11a.33)

Many of the criteria described for facial melanoma are not unique to facial melanomas. For example, the

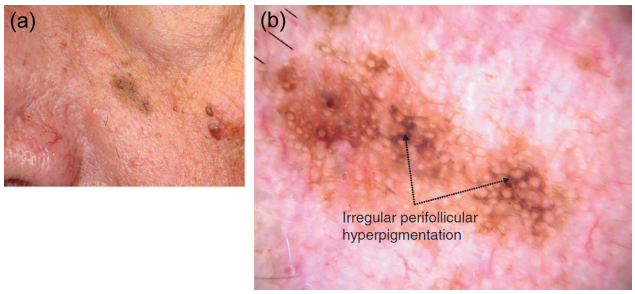

FIGURE 11A.27 (a) Clinical image. (b) Irregular perifollicular hyperpigmentation. Diagnosis: Lentigo maligna.

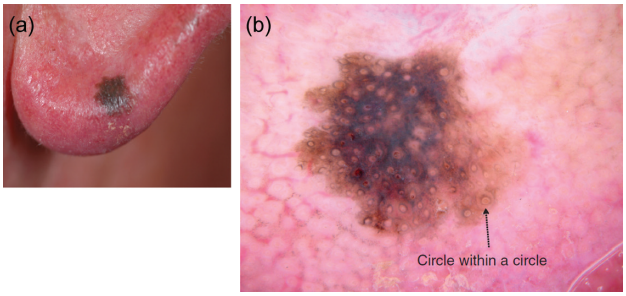

FIGURE 11A.28 (a) Clinical image. (b) Circles within circles (isobars) are not commonly seen in lesions; however, when present, they are suggestive of a diagnosis of lentigo maligna. Diagnosis: Lentigo maligna.

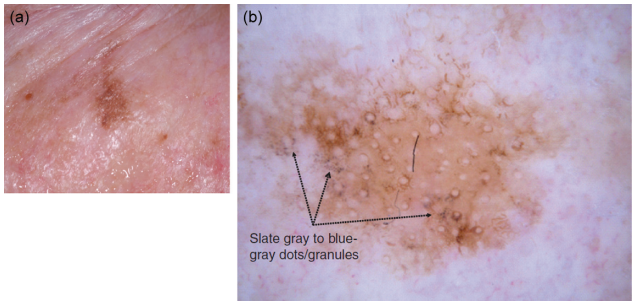

FIGURE 11A.29 (a) Clinical image. (b) Slate-gray to blue-gray dots/granules. Diagnosis: Lentigo maligna.

annular-granular pattern can be seen in pigmented AKs and LPLK (11, 13). However, despite this overlap, when examining a facial lesion, it is imperative that the entire lesion be evaluated dermoscopically, and if any portion of the lesion manifests features suggestive of melanoma, even if only focally present, the lesion should be considered to be a possible melanoma (1). Facial melanoma patterns include annular patterns, reticular patterns, and nonspecific facial melanoma patterns (Figure 11a.34).

Simulators of melanoma

The most common facial melanoma simulators include pigmented AK, LPLK, and BCC.

Pigmented actinic keratosis

Pigmented AKs are collision tumors of solar lentigines and AKs. They often have the dermoscopic features of melanoma, including asymmetrical pigmented follicular openings, polygonal lines, and gray dots/granules. The helpful clues to

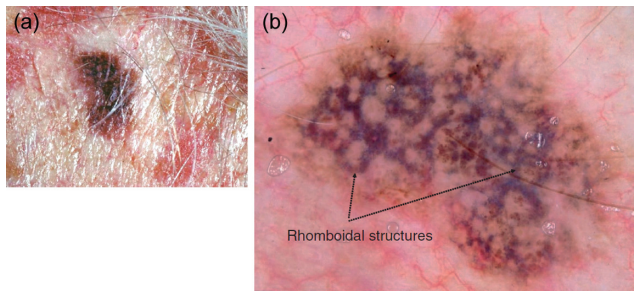

FIGURE 11A.30 (a) Clinical image. (b) Rhomboid structures. Diagnosis: Lentigo maligna.

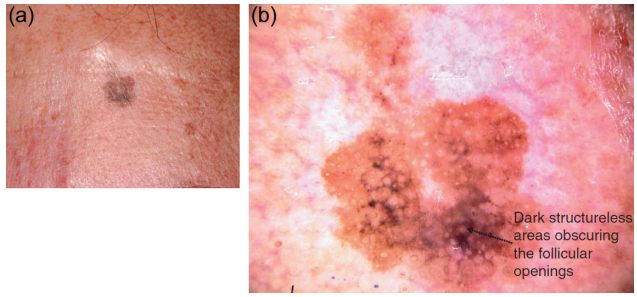

FIGURE 11A.31 (a) Clinical image. (b) Dark structureless areas obscuring the follicular openings. Diagnosis: Lentigo maligna.

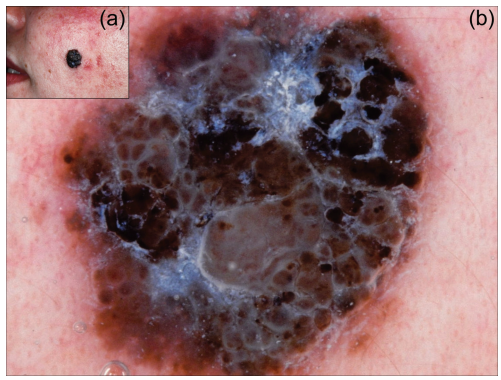

FIGURE 11A.32 (a) Clinical pattern. (b) The blue-white veil appearance on dermoscopy. Diagnosis: Melanoma.

the diagnosis of pigmented AKs include the clinical feature of a fine scale, moth-eaten borders, an annular pattern, a red pseudonetwork, white circles, rosettes, an inner gray halo, and evident follicles (Figure 11a.35). A study conducted by Lallas et al. investigated the diagnostic accuracy of lentigo maligna and pigmented AKs and concluded that white and evident follicles, scales, and a red color were the most significant findings of pigmented AKs (4). A separate study investigated the sensitivity, specificity, and reproducibility of the inner gray halo and found that the inner gray halo is a useful dermoscopic feature in differentiating pigmented AKs from lentigo maligna (present in 94.1% of pigmented AKs and 23.8% of lentigo maligna) (8). However, there are many instances in which a clear diagnosis of pigmented AK cannot be made dermoscopically, and in these cases, a histopathologic specimen should be obtained (20).

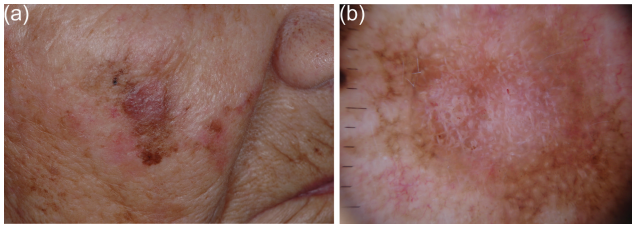

FIGURE 11A.33 (a) Clinical pattern. (b) White shiny structures appearance on dermoscopy. Diagnosis: Melanoma.

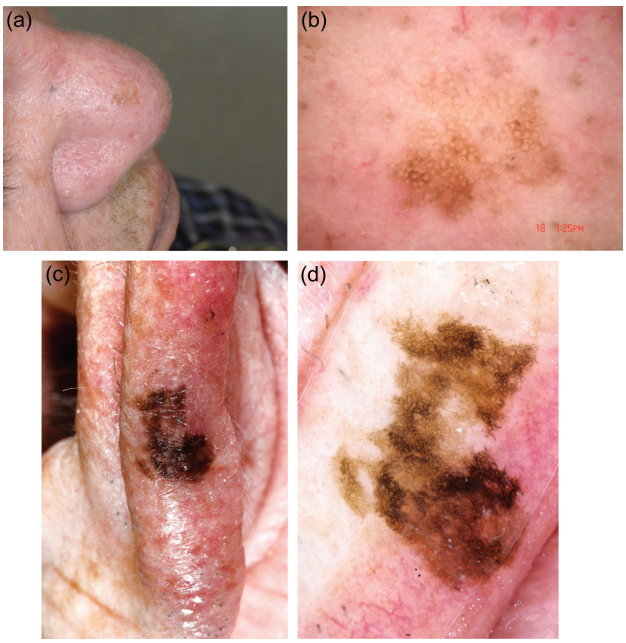

FIGURE 11A.34 Facial melanomas may have (a, b) annular or (c, d) reticular patterns.

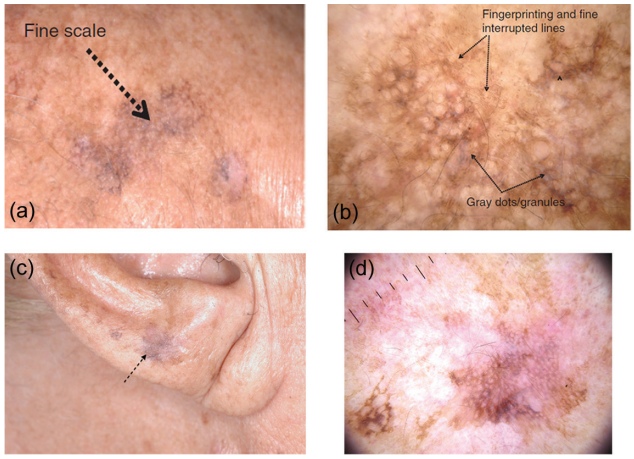

FIGURE 11A.35 (a) Clinical image showing a fine scale (*arrowhead*). (b) Pigmented actinic keratosis with fingerprinting and fine interrupted lines and gray dots/granules. (c) Clinical image showing a fine scale. (d) Pigmented actinic keratosis with fingerprinting and fine interrupted lines and gray dots/granules.

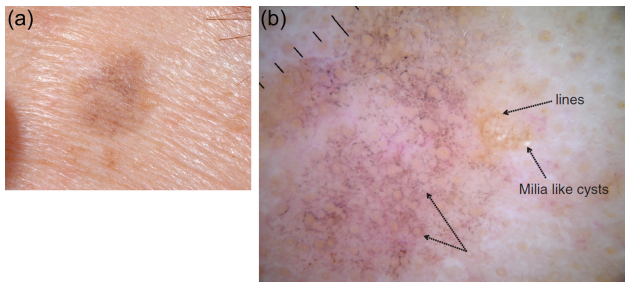

FIGURE 11A.36 (a) Clinical image. (b) Lichen planus–like keratosis with a diffuse granular pattern (*arrows*), milia-like cysts, and a few fine lines.

Facial lichen planus–like keratosis

Facial LPLK is another neoplasm difficult to differentiate from facial melanoma. LPLK is a fairly common lesion, whose origin is not entirely certain; however, it is thought to be a process in which a pre-existing epidermal lesion undergoes regression and involution (2, 5, 6, 10). The pre-existing lesion is usually a solar lentigo, although it can also be an SK. In the literature, two general dermoscopic patterns have been described for LPLK: A diffuse granular pattern and a localized granular pattern (7). The *diffuse granular pattern* is characterized by brownish-gray, reddish-brown, bluish-gray, or whitish-gray granules distributed throughout the lesion. The *localized granular pattern* is often seen in juxtaposition with dermoscopic features or criteria seen with solar lentigines and SK (Figures 11a.36 and 11a.37). The granules in LPLK tend to be larger/coarser compared with the blue-gray fine dots that are seen in melanomas. However, it is important to remember that multiple blue-gray dots have been found in 45% of invasive melanomas and demonstrate a specificity of 91% for invasive melanoma (18). Thus, although the size of the granules in melanoma typically demonstrates fine granules as opposed to the coarse granules of LPLK, if the lesion does not manifest any other structures to confirm the diagnosis of LPLK, such as fingerprint-like lines, then the diagnosis should be considered uncertain, and a biopsy should be contemplated. A retrospective study discovered that the presence of peppering did not show a statistically significant association for the diagnosis of LPLK, but the presence of coarse granules did demonstrate an association (5).

Pigmented basal cell carcinoma

Dark blue BCCs can at times be indistinguishable from thick melanomas. Sometimes, focal areas within the BCC may reveal structures, such as ovoid nests, arborizing vessels, or leaf-like areas, thus making the diagnosis relatively easy (Figures 11a.38 and 11a.39). The diagnosis of a pigmented BCC precludes the presence of a pigment network or pseudonetwork (corresponding to ostial openings surrounded by pigment); thus, if a pigment network or pseudonetwork is present, then the lesion is not a pigmented BCC (18). Furthermore, to diagnose a pigmented BCC, at least one of the following four criteria should be present: Spoke wheel–like areas, large gray-blue ovoid nests, arborizing telangiectasias, and leaf-like structures (18). However, it is important to remember that the decision to biopsy will not change even if a BCC is incorrectly diagnosed as a melanoma or vice versa under dermoscopy—the fact that the lesion has features of a malignancy will remain undisputed.

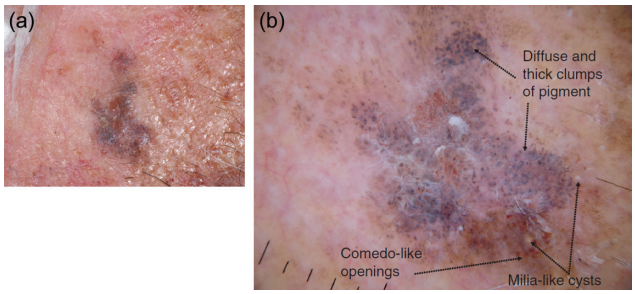

FIGURE 11A.37 (a) Clinical image. (b) Lichen planus–like keratosis with milia-like cysts, comedo-like openings, and clumps of pigment.

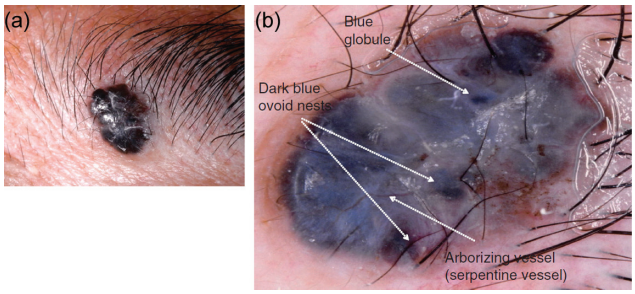

FIGURE 11A.38 (a) Clinical image. (b) Pigmented basal cell carcinoma with a blue-white veil, blue globules, blue-brown ovoid nests, and arborizing vessels.

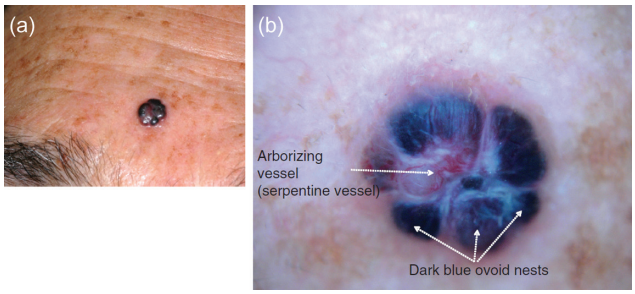

FIGURE 11A.39 (a) Clinical image. (b) Pigmented basal cell carcinoma with a blue-white veil, blue ovoid nests, and arborizing vessels.

The diagnosis of facial melanoma remains challenging. Many criteria have been described to aid in the differentiation between melanoma and melanoma simulators. One general rule is that the presence of scale (associated with AK), white follicles (associated with AK), erythema (associated with AK), reticular or curved lines (associated with lentigo), structureless brown color (associated with lentigo), sharp demarcation with or without a moth-eaten border (associated with lentigo), and classic criteria of SK such as milia-like cysts are rarely seen in lentigo maligna (12, 16). In the absence of any of the aforementioned as the predominant feature, the diagnosis of melanoma should be considered, especially if one of the following features is also present: Gray color, granularity around follicles, asymmetric follicular openings, circle within circle, angulated lines (rhomboidal structures), and blotches.

Key points

1. The dermoscopic features of BCC, SCC, and hemangioma on the face are the same as those found in the similar lesions on nonfacial skin.
2. It is often a challenge to exclude the diagnosis of melanoma in some LPLK and solar lentigines on the face.
3. Pigmented lesions on the face manifest one of two predominant patterns, either an annular or a reticular pattern.
4. The presence of gray color is the most sensitive feature of lentigo maligna.
5. The primary aim when evaluating a pigmented lesion on the face is to rule out melanoma. The management algorithm for facial lesions is located in Chapter 14.

References

1. Argenziano G, Soyer HP, Chimenti S, et al. Dermoscopy of pigmented skin lesions: results of a consensus meeting via the Internet. *J Am Acad Dermatol*. 2003;48:679–93.
2. Jang KA, Kim SH, Choi JH, et al. Lichenoid keratosis: a clinicopathologic study of 17 patients. *J Am Acad Dermatol*. 2000;43:511–16.
3. Laga AC, Murphy GF. The translational basis of human cutaneous photoaging: on models, methods, and meaning. *Am J Pathol*. 2009;174(2):357–60.
4. Lallas A, Tschandl P, Kyrgidis A, Stolz W, Rabinovitz H, Cameron A, Gourhant J, Giacomel J, Kittler H, Muir J, Argenziano G, Hofmann-Wellenhof R, Zalaudek I. Dermoscopic clues to differentiate facial lentigo maligna from pigmented actinic keratosis. *Br J Dermatol*. 2016;174:1079–85. doi:10.1111/bjd.14355.
5. Liopyris K, Navarrete-Dechent C, Dusza SW, Marghoob AA, Deng L, Wilson BB, Marchetti MA. Clinical and dermoscopic features associated with lichen planus-like keratoses that undergo skin biopsy: A single-center, observational study. *Australas J Dermatol*. 2018. doi:10.1111/ajd.12955.
6. Morgan MB, Stevens GL, Switlyk S. Benign lichenoid keratosis: a clinical and pathologic reappraisal of 1040 cases. *Am J Dermatopathol*. 2005;27:387–92.
7. Nagrani N, Jaimes N, Oliviero M, Rabinovitz H. Lichen planus-like keratosis: clinical applicability of in vivo reflectance confocal microscopy for an indeterminate cutaneous lesion. *Dermatol Pract Concept*. 2018;8(3):180–3. doi:10.5826/dpc.0803a06.
8. Nascimento MM, Shitara D, Enokihara MM, Yamada S, Pellacani G, Rezze GG. Inner gray halo, a novel dermoscopic feature for the diagnosis of pigmented actinic keratosis: Clues for the differential diagnosis with lentigo maligna. *J Am Acad Dermatol*. 2014;71(4):708–15. doi:10.1016/j.jaad.2014.05.025.
9. Navarrete-Dechent C, Liopyris K, Cordova M, Busam KJ, Marghoob AA, Chen CJ. Reflectance confocal microscopic and en face histopathologic correlation of the dermoscopic "circle within a circle" in Lentigo Maligna. *JAMA Dermatol*. 2018;154(9):1092–4. doi:10.1001/jamadermatol.2018.2216.
10. Prieto VG, Casal M, McNutt NS. Lichen planus-like keratosis. A clinical and histological reexamination. *Am J Surg Pathol*. 1993;17:259–63.
11. Schiffner R, Schiffner-Rohe J, Voft T, et al. Improvement of early recognition of lentigo maligna using dermatoscopy. *J Am Acad Dermatol*. 2000;42:25–32.
12. Stefanis AJ, Apalla Z, Papageorgiou C, Ioannides D, Nikolaidou C, Lallas A. A tiny facial pigmented macule: overcoming the diagnostic challenge. *Dermatol Pract Concept*. 2018;8(4):322–3. Published 2018 Oct 31. doi:10.5826/dpc.0804a15.
13. Stolz W, Braun-Falco O, Bilek P, Landthaler M. *Color Atlas of Dermatoscopy*. Oxford: Blackwell Scientific Publications; 2002.
14. Tiodorovic-Zivkovic D, Argenziano G, Lallas A Age, gender, and topography influence the clinical and dermoscopic appearance of lentigo maligna. *J Am Acad Dermatol*. 2015;72:801–8.
15. Tiodorovic-Zivkovic D, Zalaudek I, Lallas A, Stratigos AJ, Piana S, Argenziano G. The importance of gray color as a dermoscopic clue in facial pigmented lesion evaluation: a case report. *Dermatol Pract Concept*. 2013;3(4):37–9. Published 2013 Oct 31. doi:10.5826/dpc.0304a09.

16. Tschandl P, Gambardella A, Boespflug A, et al. Seven non-melanoma features to rule out facial melanoma. *Acta Derm Venereol*. 2017;97(10):1219–24.
17. Yadav S, Vossaert KA, Kopf AW, et al. Histopathologic correlates of structures seen on dermoscopy (epiluminescence microscopy). *Am J Dermatopathol*. 1993;15:297–305.
18. Zaballos P, Blazquez S, Puig S, et al. Dermoscopic pattern of intermediate stage in seborrheic keratosis regressing to lichenoid keratosis: report of 24 cases. *Br J Dermatol*. 2007;157:266–72.
19. Zalaudek I, Argenziano G, Soyer HP, et al. Clinically equivocal melanocytic skin lesions with features of regression: a dermoscopic-pathologic study. *Br J Dermatol*. 2003;150:64–71.
20. Zalaudek I, Ferrara G, Leinweber B, et al. Pitfalls in the clinical and dermoscopic diagnosis of pigmented actinic keratosis. *J Am Acad Dermatol*. 2005;53:1071–4.

11B SPECIAL LOCATIONS: PALMS AND SOLES (VOLAR SURFACE)

Ralph P. Braun, Josep Malvehy, and Susana Puig

Contents

Anatomy of volar skin 253
Dermoscopy of melanocytic lesions 254
Benign dermoscopy patterns 254
Malignant dermoscopy pattern on volar skin 259
Subcorneal Hemorrhage 259
Benign vascular lesions: angiomas, nevus flammeus, and hemangiomas 259
Conclusion 262
Key points 262
References 262

The characteristic pigment distribution in lesions located on volar surfaces is in parallel lines when viewed with dermoscopy. This is due to the unique microanatomy of volar skin, which is also responsible for our individualized dermatoglyphics present on our fingers and toes (1–3) (Figure 11b.1). In this chapter, we highlight the dermoscopic criteria associated with benign melanocytic lesions, subcorneal hemorrhage, and angioma/vascular lesions localized to the palms and soles.

Anatomy of volar skin

Visualizing the histologic microanatomy of volar skin allows improved comprehension of the colors, structures, and patterns seen with dermoscopy (1–3):

1. In nonglabrous skin, eumelanin pigment located in the upper dermis appears brown, and eumelanin pigment located in the lower dermis appears bluish. This is due to the physics of light—an effect known as the Tyndall effect. The Tyndall effect is what makes melanin appear black when located superficially in the skin, brown when located below the superficial layer, and blue when located deeper within the skin. It is the presence of a thickened stratum corneum, which makes the skin relatively thicker compared with nonglabrous skin, that helps explain why eumelanin pigment located in the upper dermis appears bluish under dermoscopy (Figure 11b.2). This accounts for why most compound nevi appear brown on nonvolar skin and bluish when located on the palms and soles (Figure 11b.2).
2. Furrows (sulcus superficialis) and ridges (crista superficialis) are created by the rete ridges known as the crista limitans and the crista intermedia, respectively (Figure 11b.1). The crista limitans is associated with the furrow, and the crista intermedia is associated with the ridge of the dermatoglyphics. The eccrine duct traverses through the crista intermedia and opens on the surface of the ridge. For reasons that have not yet been fully elucidated, nevi tend to be predominately localized to the rete ridges of the crista limitans and preferentially transfer melanin pigment to keratinocytes associated with the furrow (Figure 11b.3). In contrast, early melanoma cells tend to cluster around the rete ridges of the crista intermedia (Figure 11b.4). It has been shown that melanocytic stem cells in volar skin reside near the sweat glands. It is speculated that acral melanoma may arise from a mutated stem cell, and at least during the early phases of growth, the melanoma cells may prefer to proliferate in the niche associated with the crista superficialis (4). It is this preferential localization of pigment in benign and malignant melanocytic lesions that is responsible for the parallel pigment pattern seen in volar skin lesions, with nevi displaying preferential pigment distribution in the furrows and early melanoma displaying a preferential distribution of pigment on the ridges. Thus, to differentiate nevi from melanoma, it is critical to identify the furrows and ridges. While this is quite easy to do most of the time, at times, it may be challenging to differentiate the furrows from the ridges. Clues to help differentiate ridges from furrows include the following:
   - Ridges are wider than furrows. The ridges are approximately 0.5 mm in width, and the furrows are approximately 0.2mm in width.
   - The eccrine ducts open on the surface of the ridge, and with dermoscopy, they are visible as small white dots that are evenly distributed along the center of the ridge.
   - The use of ink can facilitate identifying the furrows and ridges. This so-called ink test is described in detail in Figure 11b.5.
3. Absence of follicular openings (glabrous skin).
4. The demarcation line delineating glabrous (non-hair-bearing) from nonglabrous (hair-bearing) skin on the hands and feet is named the "Wallace line" after H. J. Wallace from St. Thomas' Hospital in London. Lesions located below the Wallace line (i.e., volar surface) will reveal the parallel line pattern (Figure 11b.6). Lesions located above the Wallace line will reveal dermoscopy criteria of nonglabrous skin, such as the reticular pattern. Melanocytic lesions located at the junction of the Wallace line often appear atypical, since they will manifest a multicomponent transition pattern with dermoscopic features of both glabrous and nonglabrous skin (Figures 11b.7 and 11b.8h).

DOI: 10.1201/9780429487873-35

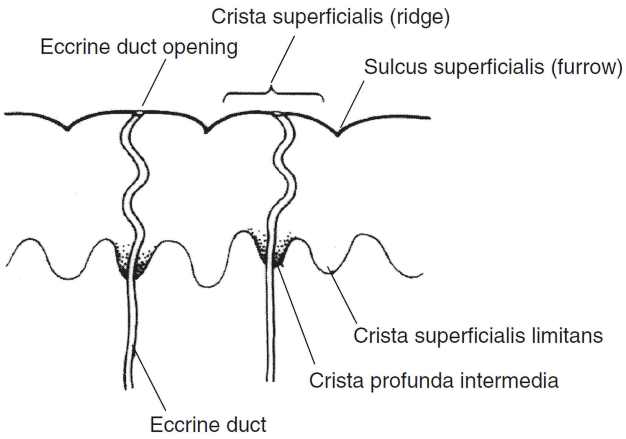

FIGURE 11B.1 Schematic diagram of the anatomy of volar skin.

Dermoscopy of melanocytic lesions

There are numerous myths in the field of medicine, including the one purporting that all melanocytic lesions on palms and soles should be excised. It is unclear why this myth started. Possible reasons may include the false assumption that nevi on volar surfaces have a higher predisposition for transforming into melanoma. Perhaps a more likely reason why this myth took hold is that the prevalence of melanocytic lesions on the palms and soles is low, compounded by the fact that the clinical morphologic features of nevi and early melanoma overlap significantly, making it difficult to differentiate them from each other with the naked eye. Fortunately, with dermoscopy, it has become relatively easy to identify nevi and melanoma based on the preferential localization of pigment in the furrows in nevi versus the ridges in melanoma (Figures 11b.4, 11b.9). Occasionally, pigment may be distributed diffusely across both the ridges and furrows (i.e., without preferential localization to the crista intermedia or limitans), resulting in homogeneous pigmented areas, and such a pattern should also raise concern for melanoma (Figure 11b.10 and Chapter 8d).

Benign dermoscopy patterns

Prior to describing the benign patterns, there is an important principle to bear in mind—namely, context. History, skin type, age, and location are all important in rendering a final decision as to whether a lesion requires a biopsy or not. That said, it is interesting to acknowledge the observation made by Miyazaki et al., who showed that the distribution of the three most common dermoscopic nevus patterns was not random, with the *lattice-like pattern* located mainly on the arch of the foot, the *fibrillar pattern* on the weight-bearing parts of the foot, and the furrow pattern located between the arch and the weight-bearing portion (5). An intriguing question that still needs to be answered is whether this has any diagnostic significance. In other words, do lesions displaying a parallel furrow pattern located on the weight-bearing portion of the foot or lesions with a regular fibrillar pattern located on non-weight-bearing surfaces still carry with them a benign diagnosis? Until we know the answer, we recommend that "benign"-appearing

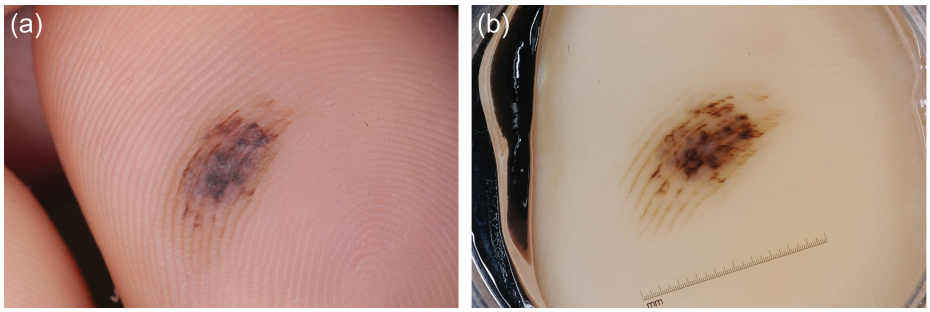

FIGURE 11B.2 (a) Clinical image. (b) Dermoscopy reveals a predominant parallel furrow pattern. The center of this compound nevus has a bluish hue. This blue hue is due to the Tyndall effect.

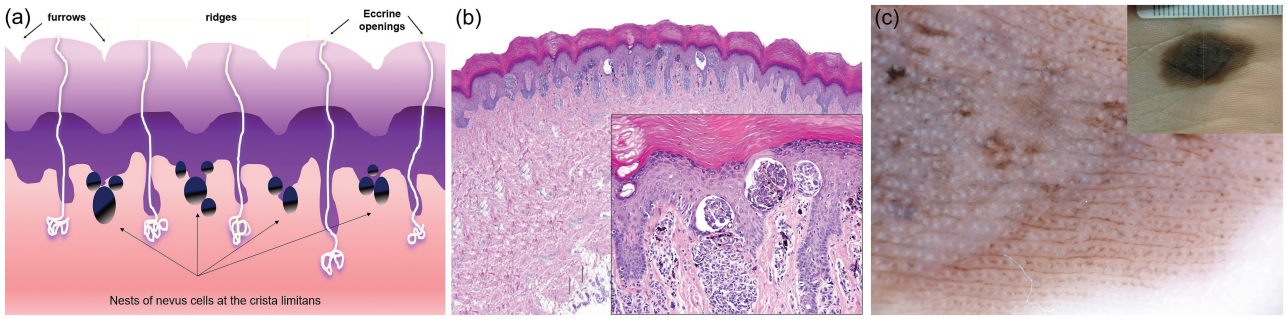

FIGURE 11B.3 (a) Schematic depiction of a melanocytic nevus on volar skin. The nevus cells tend to localize around the crista limitans, which corresponds to the furrows. (b) Histopathologic correlation of the parallel furrow pattern in a congenital nevus with nests of melanocytic cells located predominantly along the dermo-epidermal junction near to the crista limitans (furrows). (c) Dermoscopy of a congenital nevus reveals a typical parallel furrow at the periphery. White dots aligned on the ridge correspond to the openings of the eccrine ducts.

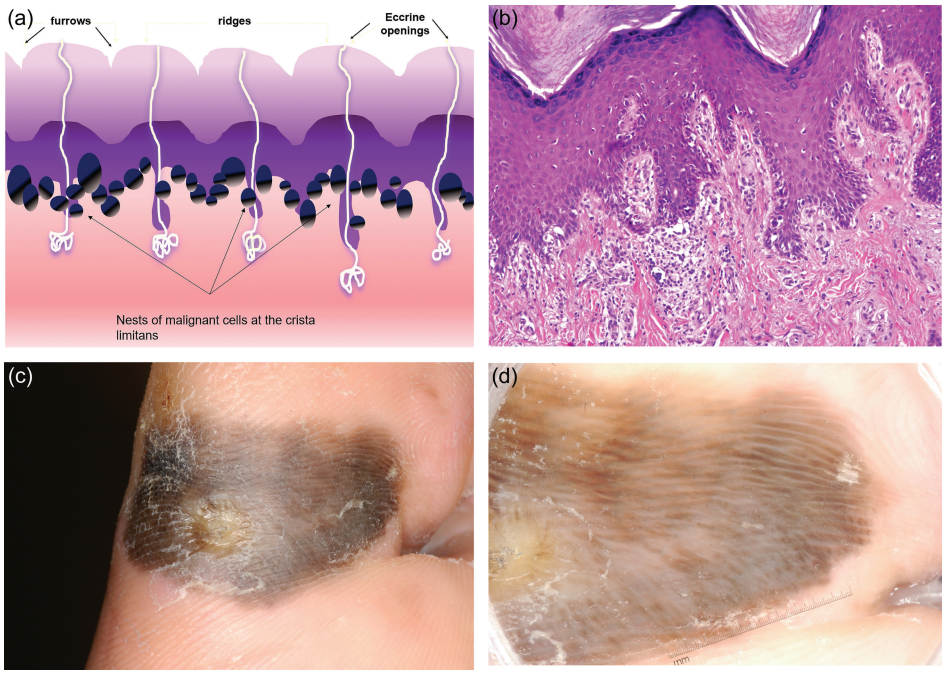

FIGURE 11B.4 (a) Schematic depiction of an ALM on volar skin. The melanoma cells tend to localize around the crista intermedia but can also be found along the crista limitans. When the pigment is predominantly located around the crista intermedia, the pattern seen in dermoscopy is a parallel ridge pattern. (b) Histopathologic correlation of an acral lentiginous melanoma with invasion of the ridges. (c) Clinical image of an acro-lentiginous melanoma. (d) Dermoscopic view of an ALM revealing a parallel ridge pattern.

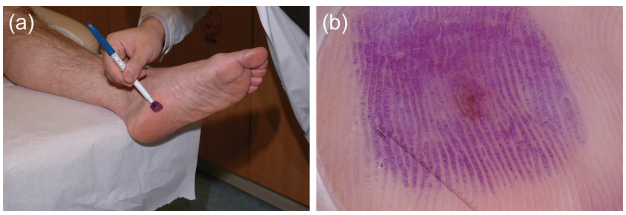

FIGURE 11B.5 (a) The ink test to help find the ridges and furrows: Use a felt tip marker and paint the skin, and then wipe off the excess ink with an alcohol swab. (b) The ink will help outline and highlight the ridges and eccrine duct openings, making it easy to conclude whether the lesion's pigment is located on the ridges or in the furrows when viewed with dermoscopy.

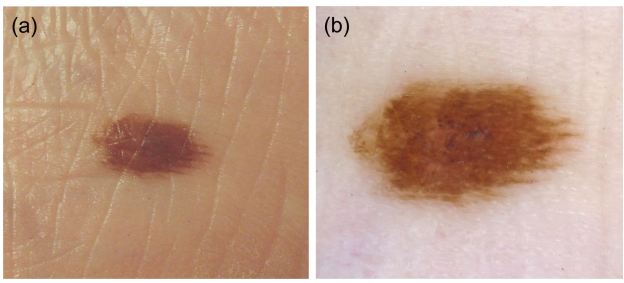

FIGURE 11B.6 (a) Benign compound nevus on the lateral area of the foot. (b) Dermoscopic examination shows a transition pattern with parallel furrow pattern (volar skin) and globules (center) with remnants of pigment network in nonvolar skin (asterisk).

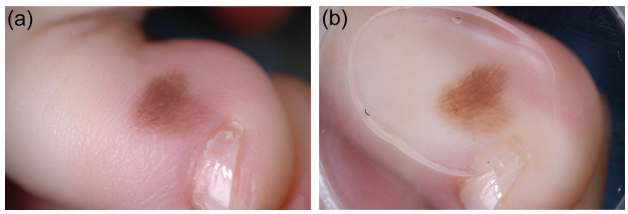

FIGURE 11B.7 (a) This nevus is located on the toe and traverses the Wallace line. The Wallace line separates the volar skin from the nonglabrous skin of the hands and feet. (b) Dermoscopy of this nevus reveals two distinct patterns. The portion on volar skin reveals a parallel pattern, and the portion on the nonglabrous skin a network pattern.

patterns located in the "wrong" location be managed with caution.

Parallel furrow pattern (Figures 11b.8, 11b.9, and 11b.11) consists of linear pigmentation that is predominantly localized to the furrows (5–8). Histology of this pattern reveals melanocytes that are preferentially located around the crista limitans with melanin columns arranged vertically in the epidermis and stratum corneum (Figure 11b.3). There are four parallel furrow pattern subtypes or variants (Figures 11b.12–11b.16) (9–11):

- Single line variant
- Double line variant
- Single dotted line variant
- Double dotted line variant

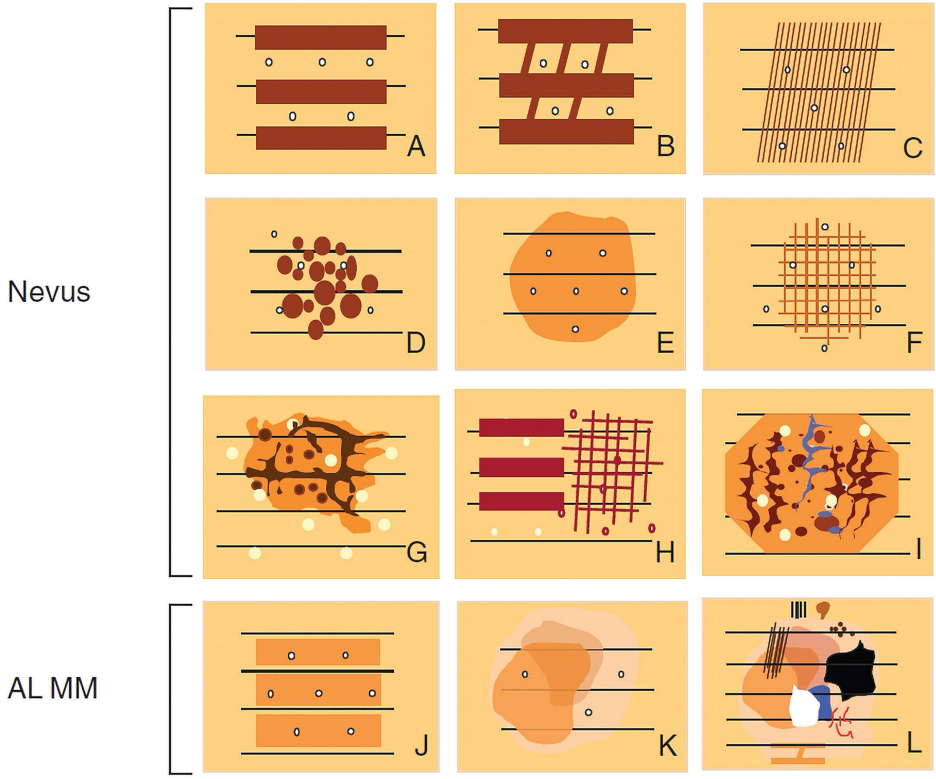

FIGURE 11B.8 Schematic representation of the major patterns encountered in melanocytic lesions on volar skin. The classic benign patterns are: (a) parallel furrow pattern with parallel black lines, which represent the furrows of the volar skin markings and small white dots corresponding to the eccrine duct openings; (b) lattice pattern with pigmentation following the furrows plus linear bands of pigment crossing from one furrow to the next like rungs of a ladder; (c) fibrillar pattern with parallel fine streaks crossing the dermoglyphics in a tangential direction. Other benign patterns include: (d) globular pattern in which the globules are not associated with a parallel pattern; (e) homogeneous diffuse pigment pattern with light brown homogeneous pigmentation with an amorphous appearance; (f) reticular pattern with well-defined pigment network that is not associated with the skin markings. The nontypical benign patterns (g and i) do not conform to a classic benign or to a classic malignant pattern. (g) is a nevus with globules and serration. The schematic shown in panel (h) is called the "transition pattern," since this pattern is frequently seen in nevi that cross over the Wallace line. In such cases, the nonglabrous skin will reveal structures such as network, and the portion of the lesion on volar skin will reveal a parallel pattern. The malignant patterns are: (j) parallel ridge pattern with more prominent pigment on the ridges than on the furrows; (k) homogeneous diffuse irregular pigmented pattern (usually >7 mm to 1 cm in diameter) with pigmented blotches of various shades of brown (as well as other colors such as bluish and pink) observed throughout the entire lesion or in focal areas of a lesion; and (l) the multicomponent pattern, which often reveals an abrupt edge, diffuse pigmentation, peripheral irregular globules and dots, multiple colors, and atypical streaks in combination with localized areas exhibiting benign patterns (fibrillar, parallel furrow, or lattice-like).

These variations of the parallel furrow pattern are commonly seen on palms or on the portion of the sole between the arch of the foot and the weight-bearing portion (5).

The lattice-like pattern is similar to the parallel furrow pattern with the addition of parallel pigment bands that cross over the ridges from one furrow to the next like the rungs of a ladder (9). This pattern can be seen on the palms and is the most common pattern of nevi found on the arch area of the sole (Figures 11b.17 and 11b.18).

The fibrillar pattern consists of multiple thin parallel lines oriented obliquely to the dermatoglyphics and appearing to cross both the furrows and the ridges. This pattern results from the effects of persistent horizontal pressure being applied to the stratum corneum, which in turn, causes the stratum corneum to grow in a slanted direction (in the direction of the lateral pressure). Thus, as the linearly oriented melanin-laden epidermal cells in the stratum granulosum move into the stratum corneum, they begin to travel in an oblique direction in the direction of lateral pressure, which results in the conversion of a parallel furrow or ridge pattern into a fibrillar pattern. It should be intuitively obvious that the fibrillar pattern will be seen frequently in melanocytic lesions located on the weight-bearing parts of the sole and will not generally be seen on the palms, since persistent weight-bearing forces on the palms do not occur under normal circumstances (5, 12–14). Because of this, any fibrillar pattern, even if it has a regular and organized appearance, seen on the palms should raise suspicion for melanoma (Figure 11b.19). In contrast, lesions on the plantar aspect should be evaluated to determine whether the fibrillar pattern is regular (type A) or irregular (type B). In plantar nevi, the fibrillar pattern (type A) tends to consist of thin light brown lines displaying minimal variation in thickness and color and distributed in an organized fashion (Figures 11b.20–11b.22). In plantar melanoma, the fibrillar pattern (type B) consists of lines displaying increased variability in thickness and color,

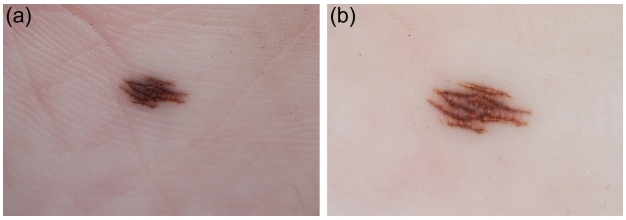

FIGURE 11B.9 (a) Clinical image of a nevus on the sole. (b) Dermoscopy reveals a parallel furrow pattern. Note that the nonpigmented ridges are wider than the pigmented furrows. Also note that the white dots, corresponding to eccrine duct openings, are visible on the ridge.

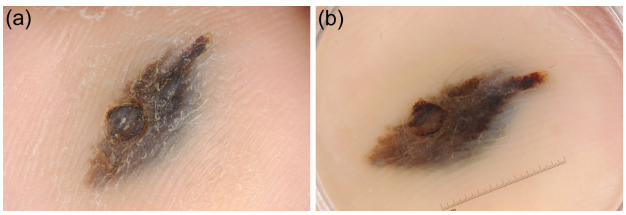

FIGURE 11B.10 (a) Melanoma located on the ball of the foot. (b) Dermoscopy shows diffuse pigmentation involving both the furrows and the ridges.

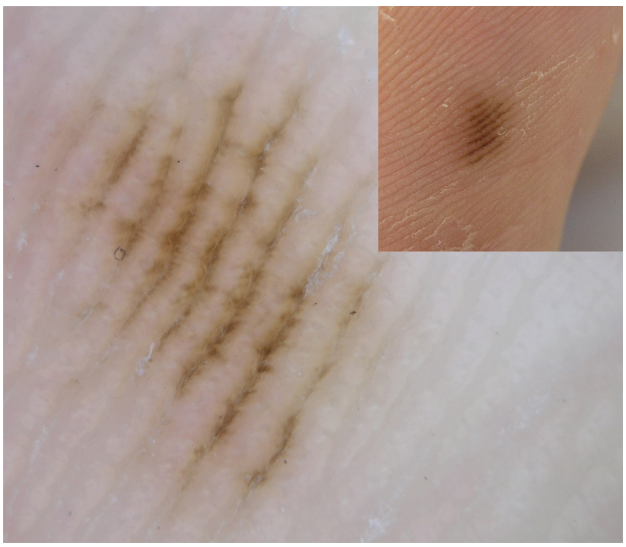

FIGURE 11B.11 Stereotypical parallel furrow pattern in a compound nevus.

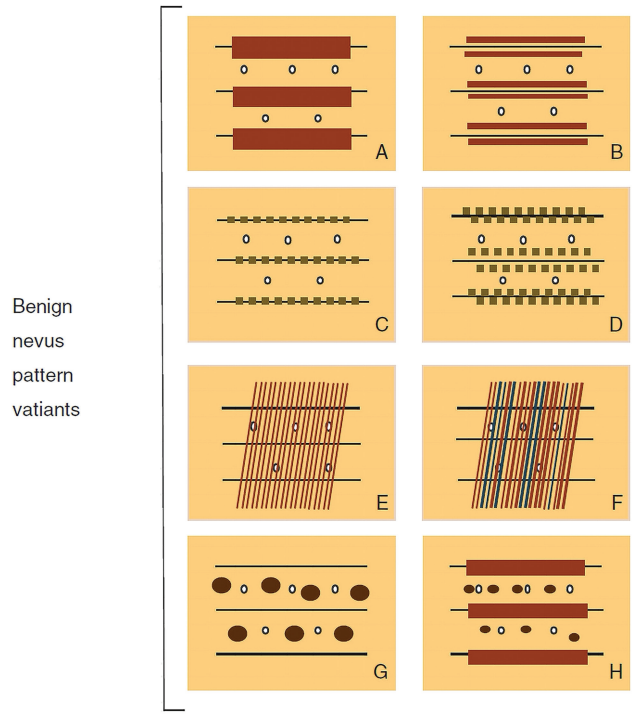

FIGURE 11B.12 Subtypes of benign patterns seen on volar skin: (a) classic parallel furrow pattern; (b) double line furrow pattern; (c) single dotted line parallel furrow pattern; (d) double dotted line parallel furrow pattern; (e) fine typical fibrillar pattern on sole is a benign pattern; (f) atypical fibrillar pattern on sole is considered suspect (NB: both typical and atypical fibrillar patterns on the palms should be considered suspicious); (g) crista dotted pattern is commonly seen in congenital nevi; (h) parallel furrow pattern together with dots/globules on the ridges is known as the "peas in a pod" pattern. This pattern is commonly seen in congenital nevi.



FIGURE 11B.13 Parallel furrow pattern with linear pigmentation within the furrow. Diagnosis: Melanocytic nevus.

and the lines tend to be distributed in a disorganized manner (Figure 11b.23, Chapter 8d). These atypical lines tend to be thicker than the lines seen in nevi, and they often contain gray hues, which is an uncommon color manifest by nevi (15).

Based on this, the stratum corneum growing in a slanted direction and creating the fibrillar pattern is in fact masking the diagnostic underlying pattern, which is either a furrow or a ridge pattern. An interesting technique can occasionally help disclose whether the pigment in a fibrillar lesion originates from the furrows or the ridges. This technique is known as oblique-view dermoscopy and is shown in Figure 11b.24 (15–17). In brief, if you view a fibrillar lesion at an oblique angle, then it may be possible to determine whether the pigment is originating from the ridge or the furrow. Similarly, one can also try directly viewing the lesion with contact dermoscopy while applying downward and horizontal pressure that is directed opposite to the normal frictional forces encountered by the lesion. This can transiently convert the fibrillar pattern back into a parallel pattern and help the observer determine whether the pigment is originating from within the furrows or from the ridges.

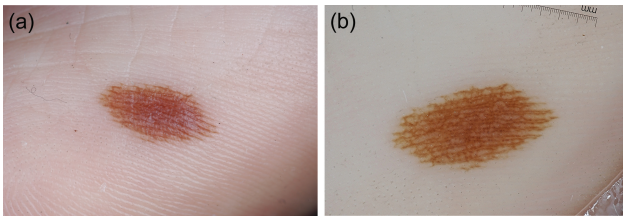

FIGURE 11B.14 (a) Clinical image of a benign acral nevus, with a double parallel line furrow pattern seen with dermoscopy (b).

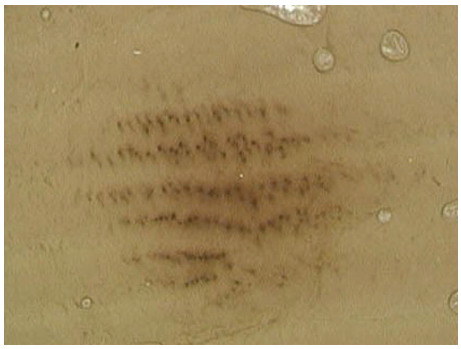

FIGURE 11B.15 Parallel furrow pattern, single dotted line variant, with dotted pigmentation within the furrow. Diagnosis: Melanocytic nevus.

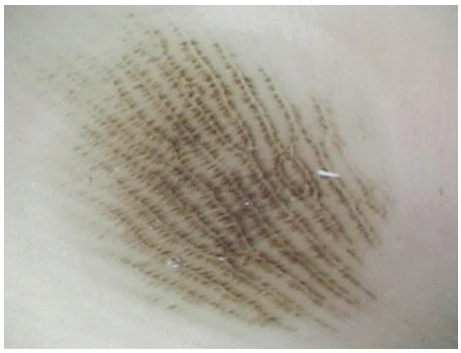

FIGURE 11B.16 Parallel furrow pattern, double dotted variant with dotted pigmentation along both sides of the furrow in a parallel fashion. Diagnosis: Melanocytic nevus.

The reticular pattern can be seen on the arch of the foot. Although nevi on the arch of the foot usually display a lattice-like pattern, some can have a reticular pattern (Figure 11b.25) (8, 9).

The globular pattern, corresponding to nests of nevomelanocytes of varying sizes from small to large, can be seen in volar nevi. These lesions are presumed to be congenital nevi (Figure 11b.26).

The homogeneous pattern (Figure 11b.27) consists of a lesion with uniformly distributed pigment that involves both the furrows and ridges and is devoid of any other structures. Nevi with a parallel furrow pattern may transform over time into a homogeneous pattern. Digital dermoscopy follow-up of homogeneous-patterned nevi has shown that some fade away over time; it is surmised that these nevi disappear or involute via transepidermal elimination of melanocytes (9).

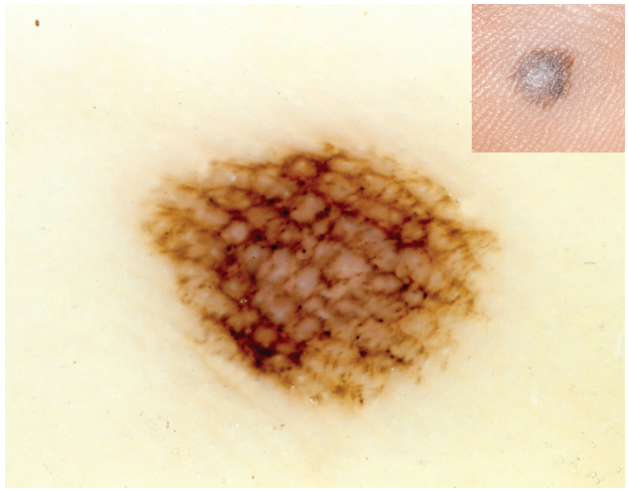

FIGURE 11B.17 Classic lattice pattern in this benign acral nevus.

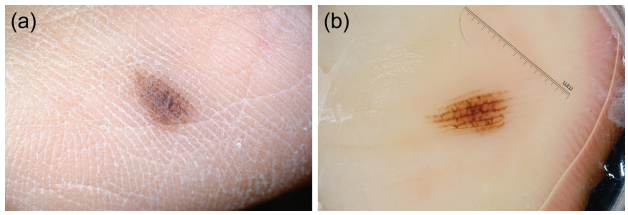

FIGURE 11B.18 (a) Classic lattice pattern. (b) Note the eccrine duct openings on the surface of the ridges.

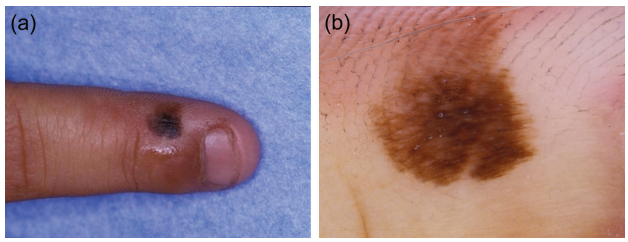

FIGURE 11B.19 (a) Clinical image of an ALM on the volar aspect of the finger. (b) Dermoscopy reveals a fibrillar pattern. Note that any lesion with a fibrillar pattern, regardless of whether it is a typical or an atypical fibrillar pattern, on the hands should be viewed with suspicion for ALM.

The peas in a pod pattern is considered to be a variant of the parallel furrow pattern (Figure 11b.28). This pattern is associated with congenital nevi on volar skin (18). The pattern consists of parallel furrow lines displaying any one of the four line subtypes described earlier (i.e., single line, single dotted line, double line, and double dotted line) in combination with dots/globules located adjacent to or in the center of the ridges.

The nontypical (i.e., nondescript) pattern (Figure 11b.10g, i) consists of a pattern that cannot be classified into one of the aforementioned benign patterns and also does not display melanoma-specific patterns, which are described in the following (Figures 11b.29–11b.32).



FIGURE 11B.20 Fibrillar pattern in a benign melanocytic nevus on the sole. This lesion is located in the area of pressure of the foot.

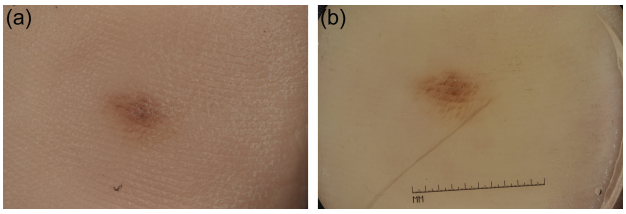

FIGURE 11B.21 (a) Typical fine fibrillar pattern on the weight-bearing area of the sole. (b) Dermoscopic image.

Malignant dermoscopy pattern on volar skin

The malignant dermoscopic patterns for melanomas located on the palms and soles are extensively discussed in Chapter 8d.

Subcorneal Hemorrhage

The presence of trauma-induced subcorneal blood often presents with a parallel ridge pattern, thereby mimicking melanoma (Figures 11b.33 and 11b.34) (19–22). In such cases, the pigment, which can be reddish, bluish, purple, black, brownish, or rust-colored, depending on the oxidative state of the hemoglobin, is deposited along the ridges. Blood within the skin will egress along the path of least resistance, which happens to be adjacent to the eccrine duct. Since the eccrine duct opens on the ridge, the blood will sequester on the ridges. Initially, the blood will appear as globular structures ("pebbles on the ridges"). These focal blood spots will fuse with adjacent ones, resulting in the formation of a parallel ridge pattern. In subcorneal hemorrhage, the pigmentation ends abruptly at the edge



FIGURE 11B.22 Fibrillar pattern with numerous thin lines crossing the furrow in a slanted direction. Diagnosis: Melanocytic nevus.

of the lesion, whereas in melanoma, it tends to fade toward the periphery. In addition, as blood congeals and dries, it starts to crack, and these cracks are visible via dermoscopy; the presence of these cracks is a clue to the presence of dried subcorneal blood (Figure 11b.35). Lastly, since subcorneal blood is localized to the stratum corneum, carefully scraping off the corneal layer with a scalpel will remove the blood, and this technique can be used to confirm the diagnosis of subcorneal hemorrhage (20).

Benign vascular lesions: angiomas, nevus flammeus, and hemangiomas

Two recurrent dermoscopic patterns have been observed in benign volar vascular lesions, consisting of red dots/globules arranged linearly along each side of the ridge with sparing of the eccrine openings, and/or regular lacunae situated on the ridges with sparing of the furrows (23): The lesions revealing lacunae are easy to recognize as benign vascular lesions, since the presence of red to maroon lacunae is diagnostic of angiomas/hemangiomas. In contrast, benign vascular lesions revealing red dots on the ridges can be confused for amelanotic ALM. However, close inspection of the pattern of distribution of the red dots can be used to help differentiate benign from malignant vascular tumors. In benign vascular lesions, the red dots/globules are oriented in regular, parallel lines on either side of the ridge. The reason one observes a double red-dotted parallel ridge pattern in benign vascular lesions such as nevus flammeus is due to the location of clusters of vessels in the papillary dermis, and this is depicted schematically in Figure 11b.36.

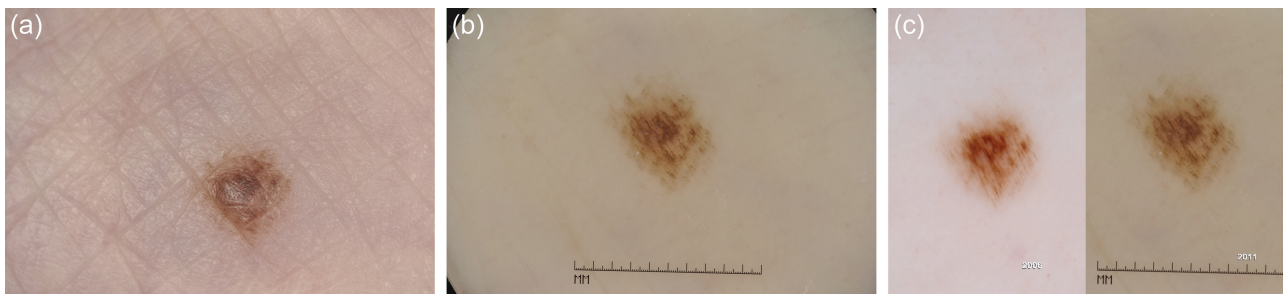

FIGURE 11B.23 This lesion has an atypical fibrillar pattern (a, clinical image; b, dermoscopic image). This lesion was biopsied due to the atypical fibrillar pattern and because it had changed on digital monitoring (c). The pathology diagnosis was an atypical and highly unusual melanocytic lesion with borderline features for melanoma.

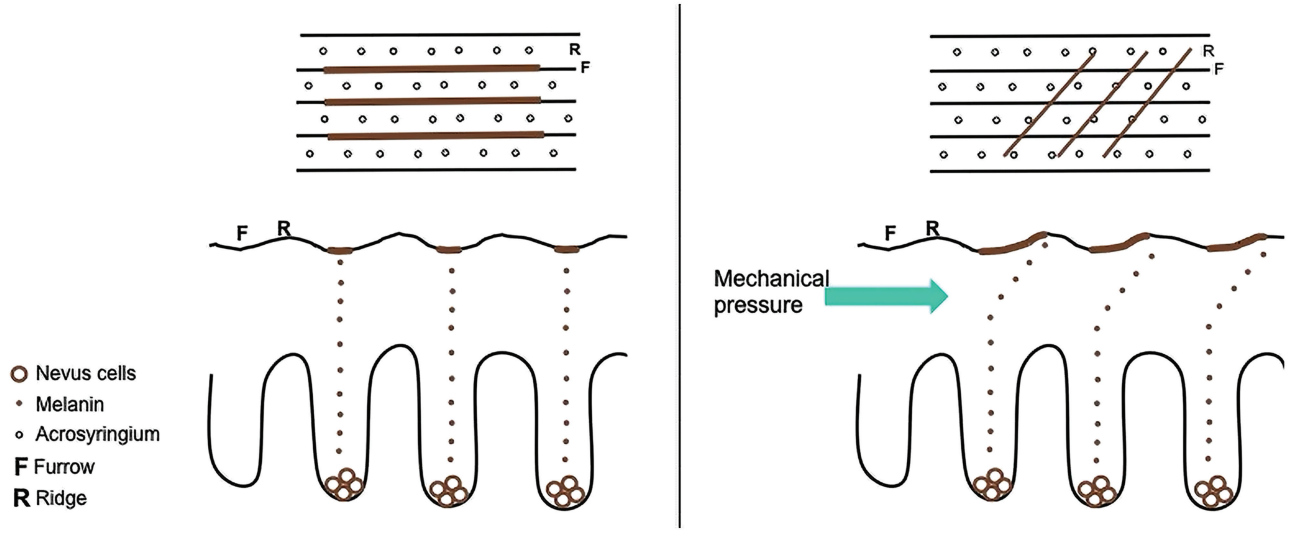

FIGURE 11B.24 Oblique-view dermoscopy.

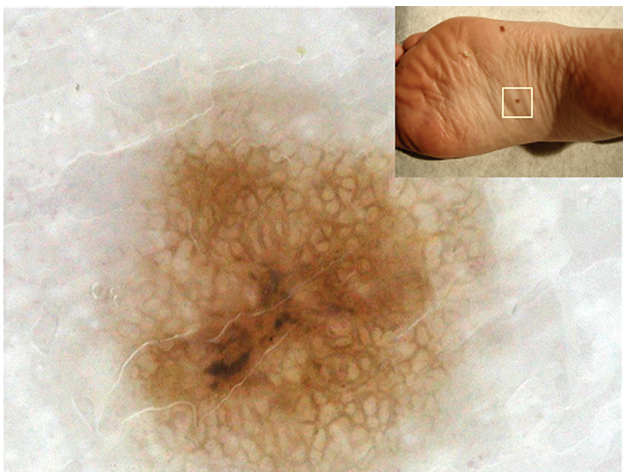

FIGURE 11B.25 Reticulated pattern on the arch of the sole.

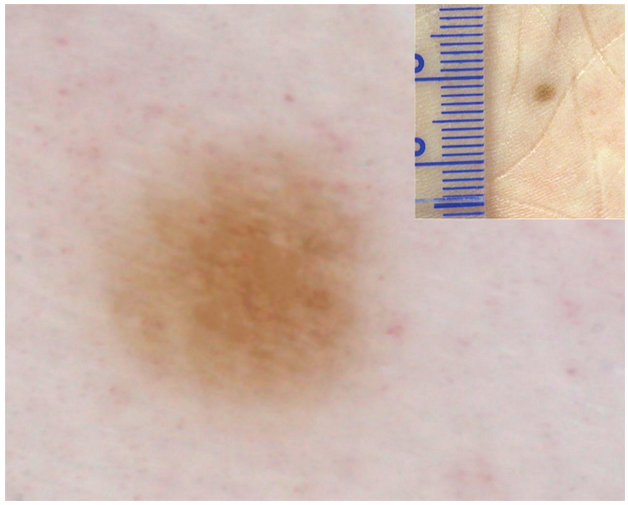

FIGURE 11B.27 Homogeneous pattern.

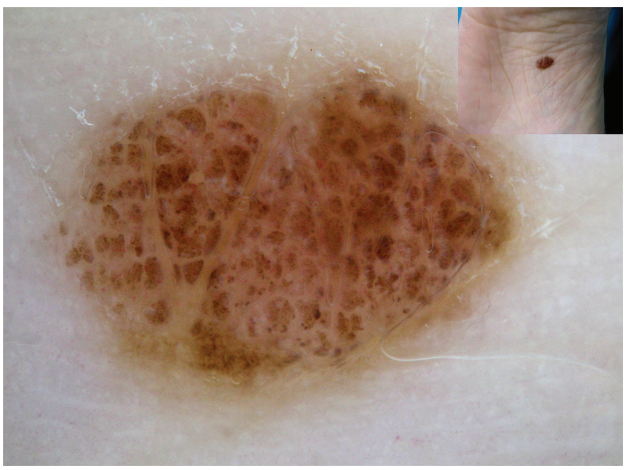

FIGURE 11B.26 Globular pattern (cobblestone) in a compound nevus.

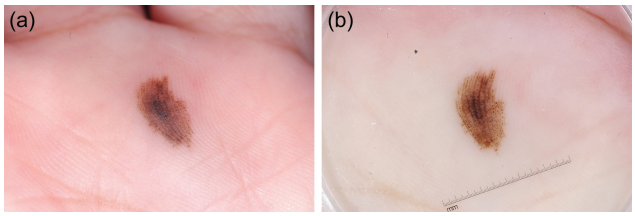

FIGURE 11B.28 (a) Congenital nevus on the palm. (b) Dermoscopy shows a "peas in a pod" pattern, which consists of a parallel furrow pattern together with dots/globules on the ridges (see Figure 12h). Sometimes, the globules on the ridges will be visible, but the pigment in the furrows will not be present. This is considered a variant of the same pattern but is

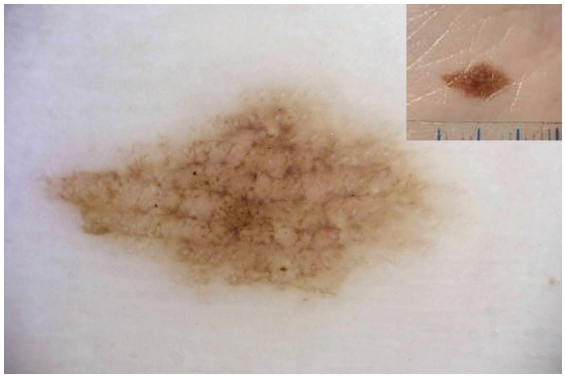

FIGURE 11B.29 Nontypical pattern in a benign nevus on the sole in a patient with dysplastic nevus syndrome.

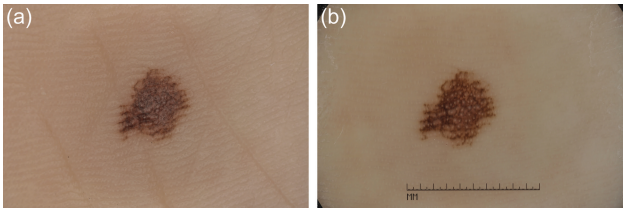

FIGURE 11B.30 Nontypical pattern nevus. (a) Clinical image. (b) Dermoscopic image.

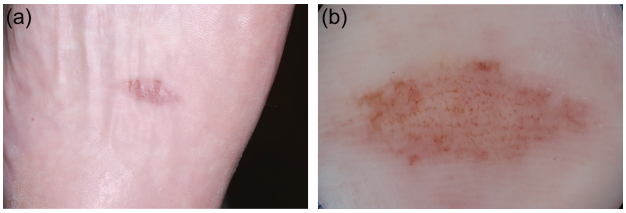

FIGURE 11B.31 Nontypical pattern nevus. (a) Clinical image. (b) Dermoscopic image.

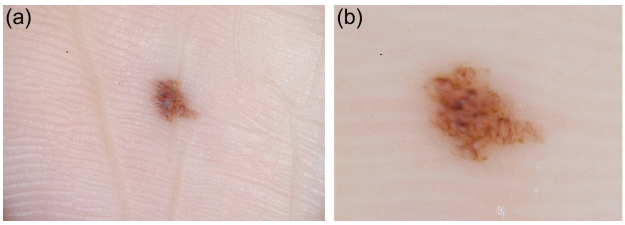

FIGURE 11B.32 Nontypical pattern nevi. (a) Clinical image. (b) Dermoscopic image.

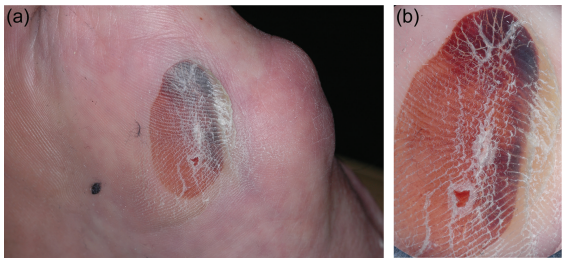

FIGURE 11B.33 (a) Clinical image of an area of trauma on the foot. (b) Dermoscopy reveals a parallel ridge pattern. Paring down the stratum corneum will help confirm that the pigment is due to subcorneal hemorrhage.

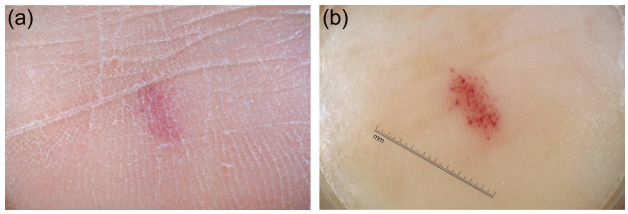

FIGURE 11B.34 (a) Clinical image of subcorneal blood. (b) Dermoscopy reveals a pattern known as "pebbles on the ridge." The pebbles correspond to pockets of congealed blood and are located on the ridges.

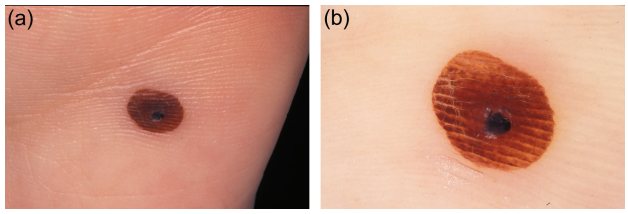

FIGURE 11B.35 Subcorneal hemorrhage. (a) Clinical image demonstrates the characteristics red/orange pigmentation that ends abruptly at the edge of the lesion. (b) Dermoscopy reveals some cracks, which is a clue to the presence of dried subcorneal blood.

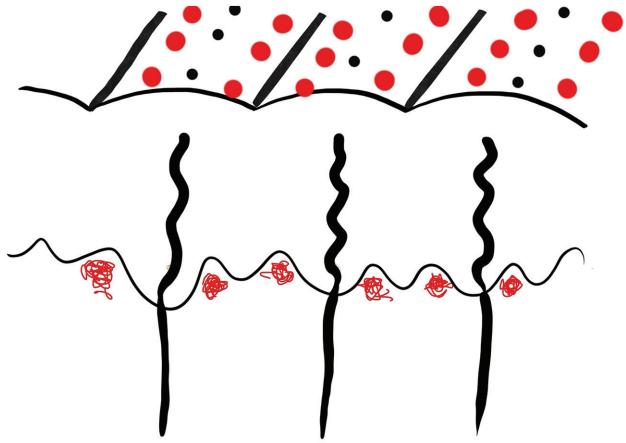

FIGURE 11B.36 Schematic of red dots/globules oriented in regular, parallel lines on both sides of the ridge. The double red-dotted parallel ridge pattern in benign vascular lesions is due to the location of clusters of vessels in the papillary dermis.

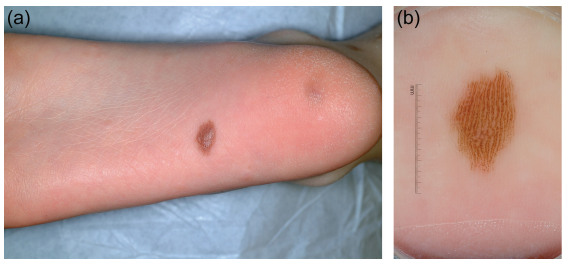

FIGURE 11B.37 (a) Clinical image of a nevus on the sole. (b) Dermoscopy of this lesion reveals a double line furrow pattern on the left side and a double dotted line furrow pattern on the right side. Although this nevus has more than one pattern, it is still considered benign, since it only manifests variations of

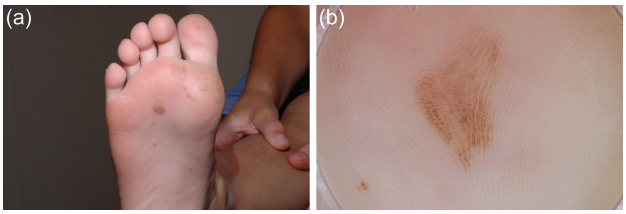

FIGURE 11B.38 (a) Clinical image of a volar nevus. (b) Under dermoscopy, a portion of this lesion has a fibrillar pattern, and another portion has a dotted furrow pattern. Since both these patterns are benign, the entire lesion is considered benign.

The double red-dotted parallel ridge pattern is not seen in amelanotic melanoma. While amelanotic ALM also manifests red dots (vessels) on the ridges, the vessels are distributed randomly along the ridges (24).

Conclusion

Differentiating benign from malignant lesions on volar skin is difficult with the naked eye. Dermoscopy has greatly enhanced our ability to correctly identify nevi and melanoma based on colors, structures, and patterns observed through this looking glass. An algorithm to assist in the decision-making process when evaluating volar melanocytic lesions can be found in Chapter 8d (Figure 8d.21). Lastly, we want to mention that it is not uncommon to encounter nevi on volar skin that manifest more than one benign pattern (Figures 11b.37 and 11b.38). Lesions manifesting more than one of the classic benign patterns are classified as benign lesions in the algorithm shown in Figure 8d.21.

Key points

1. The peculiar microanatomy of volar skin that is responsible for our dermatoglyphics is also responsible for the parallel pigment line patterns observed on the palms and soles.
2. The pigment in nevi tends to be most prominent in the furrows, while in melanoma, it tends to be most prominent on the ridges or encompasses both the ridges and the furrows (diffuse pigmentation with variable shades of brown).
3. Parallel furrow, lattice-like, and typical fibrillar pattern are the most frequent patterns seen in nevi on volar skin.
4. While the parallel ridge pattern is most often associated with melanoma, it can also be seen in subcorneal hemorrhage and in benign vascular lesions.

References

1. dermoscopedia contributors \'96 Josep Malvehy SP. *Palms and Soles* [updated 7 November 2017;13:59. UTC\. Available from: https://dermoscopedia.org/w/index.php?title=Palms_and_Soles&oldid=8823%7D%7D%22.
2. Saida T, Koga H. Dermoscopic patterns of acral melanocytic nevi: their variations, changes, and significance. *Arch Dermatol.* 2007;143(11):1423–6.
3. Saida T, Kawachi S, Koga H. Anatomic transitions and the histopathologic features of melanocytic nevi. *Arch Dermatol.* 2008;144(9):1232–3; author reply 3–4.
4. Okamoto N, Aoto T, Uhara H, et al. A melanocyte--melanoma precursor niche in sweat glands of volar skin. *Pigment Cell Melanoma Res.* 2014;27(6):1039–50.
5. Miyazaki A, Saida T, Koga H, Oguchi S, Suzuki T, Tsuchida T. Anatomical and histopathological correlates of the dermoscopic patterns seen in melanocytic nevi on the sole: a retrospective study. *J Am Acad Dermatol.* 2005;53(2):230–6.
6. Altamura D, Altobelli E, Micantonio T, Piccolo D, Fargnoli MC, Peris K. Dermoscopic patterns of acral melanocytic nevi and melanomas in a white population in central Italy. *Arch Dermatol.* 2006;142(9):1123–8.
7. Altamura D, Zalaudek I, Sera F, et al. Dermoscopic changes in acral melanocytic nevi during digital follow-up. *Arch Dermatol.* 2007;143(11):1372–6.
8. Malvehy J, Puig S. Dermoscopic patterns of benign volar melanocytic lesions in patients with atypical mole syndrome. *Arch Dermatol.* 2004;140(5):538–44.
9. Braun RP, Thomas L, Dusza SW, et al. Dermoscopy of acral melanoma: a multicenter study on behalf of the international dermoscopy society. *Dermatology.* 2013;227(4):373–80.
10. Braun RP, Thomas L, Kolm I, French LE, Marghoob AA. The furrow ink test: a clue for the dermoscopic diagnosis of acral melanoma vs nevus. *Arch Dermatol.* 2008;144(12):1618–20.
11. Saida T, Miyazaki A, Oguchi S, et al. Significance of dermoscopic patterns in detecting malignant melanoma on acral volar skin: results of a multicenter study in Japan. *Arch Dermatol.* 2004;140(10):1233–8.
12. Kimoto M, Sakamoto M, Iyatomi H, Tanaka M. Three-dimensional melanin distribution of acral melanocytic nevi is reflected in dermoscopy features: analysis of the parallel pattern. *Dermatology.* 2008;216(3):205–12.
13. Nagashima Y, Akita M, Tsuchida T. Relationship between the three-dimensional structure of the human plantar epidermis and the dermoscopic patterns seen in melanocytic nevi. *Dermatology.* 2011;222(1):67–73.
14. Palleschi GM, Cipollini EM, Torchia D, Torre E, Urso C. Fibrillar pattern of a plantar acquired melanocytic naevus: correspondence between epiluminescence microscopy and transverse section histology. *Clin Exp Dermatol.* 2006;31(3):449–51.
15. Kiyohara T, Satoh S, Yasuta M, Kumakiri M. Irregular fibrillar pattern is an artifactual expression of parallel ridge pattern on the pressure-loaded area of the sole: the efficacy of oblique view dermoscopy. *J Dermatol.* 2012;39(11):927–8.
16. Maumi Y, Kimoto M, Kobayashi K, Ito N, Saida T, Tanaka M. Oblique view dermoscopy changes regular fibrillar pattern into parallel furrow pattern. *Dermatology.* 2009;218(4):385–6.
17. Sato T, Komatsu H, Tanaka M. Continuous recording of oblique-view dermoscopy images enables observation of the convergence of the fibrillar into the parallel furrow pattern and to differentiate melanocytic naevi from acral melanoma. *Australas J Dermatol.* 2017;58(4):e279–e82.
18. Minagawa A, Koga H, Saida T. Dermoscopic characteristics of congenital melanocytic nevi affecting acral volar skin. *Arch Dermatol.* 2011;147(7):809–13.
19. Robertson SJ, Leonard J, Chamberlain AJ. PlayStation purpura. *Australas J Dermatol.* 2010;51(3):220–2.
20. Savoia F, Ravaioli GM, Tabanelli M, Dika E, Patrizi A. Scraping test for the diagnosis of acral subcorneal hemorrhage. *J Am Acad Dermatol.* 2019;81(2):e29–e30.
21. Tanioka M. Benign acral lesions showing parallel ridge pattern on dermoscopy. *J Dermatol.* 2011;38(1):41–4.
22. Zalaudek I, Argenziano G, Soyer HP, Saurat JH, Braun RP. Dermoscopy of subcorneal hematoma. *Dermatol Surg.* 2004;30(9):1229–32.
23. Marghoob N, Navarrete-Dechent C, Liopyris K, Apalla Z, Lallas A, Marghoob AA. Dermoscopic features of benign vascular lesions presenting on volar skin: a case series and literature review. *J Eur Acad Dermatol Venereol.* 2019;33(12):e444–e5.
24. Liopyris K, Navarrete-Dechent C, Mancebo SE, et al. Dermoscopic appearance of amelanotic volar melanoma compared with volar angioma. *JAMA Dermatol.* 2019;155(4):500–1.

11C SPECIAL LOCATIONS: MUCOSAL SURFACES AND GLABROUS SKIN ON GLANS AND LABIA

Natalia Jaimes and Michael A. Marchetti

Contents

Dermoscopic evaluation 263
Key points 267
References 267

Mucous membranes are epithelial surfaces with mucus-secreting cells that form the lining of body cavities; for example, the mucosa of the mouth lines the oral cavity, including the gingivae, palate, lips, buccal surfaces, and floor of the mouth.[1] Mucous membranes are generally nonkeratinized stratified squamous epitheliums, although different sites demonstrate varying degrees of keratinization. Examples of mucosal surfaces include the conjunctivae, oral mucosa, nasal mucosa, and anogenital mucosa.

Both melanocytic and nonmelanocytic neoplasms can occur on any mucous membrane or mucocutaneous junction. The primary consideration when evaluating pigmented lesions at these sites includes differentiating benign entities, such as labial lentigo, melanotic macule, and melanocytic nevus, from mucosal melanoma and pigmented squamous cell carcinoma. As the incidence of mucosal melanoma is very low (approximately 1 case per 500,000 individuals),[2] early detection is challenging, and the majority of mucosal melanomas are detected via the presence of late-stage symptoms (i.e., growing painful mass, bleeding). Although there are some potential barriers precluding physicians from performing dermoscopy on mucosal surfaces (i.e., time constraints, patient embarrassment, the proximity between evaluator and patient), there are some tips that can help surpass these barriers: [3]

- ***Polarized light.*** Using polarized dermoscopy during the evaluation of mucosal lesions circumvents the need for direct contact between the dermatoscope lens and the mucosal surface.
- ***Protection shield.*** Using a disposable cap or any transparent plastic shield, such as plastic food wrap, to cover the dermatoscope's glass plate. It is essential to add a liquid interface between the lesion and the plastic, as well as between the plastic shield and the dermoscope's glass plate (Figure 11c.1).
- ***Digital dermoscopy.*** Capturing a dermoscopic image of the mucosal lesion spares the clinician from being close, and it also allows monitoring the lesions over time. There are many devices available for this purpose.

Dermoscopic evaluation

Similarly to lesions located on other anatomic sites, dermoscopic evaluation of lesions on mucosal surfaces involves the evaluation of structures, colors, and patterns.

Colors. The colors expressed by mucosal lesions are one of the most sensitive and specific features to differentiate melanoma from other lesions. Overall, benign lesions demonstrate few colors (Figure 11c.2 – 11c.13), while malignant lesions reveal multiple colors; in particular, the presence of blue, gray, or white colors has shown a sensitivity of 100% and a specificity of 64% for melanoma (Figure 11c.15).[4]

Structures. The most common dermoscopic structures observed in mucosal lesions are summarized in **Table 11c.1.**

Patterns. The combination of one or more of the above-mentioned dermoscopic structures will result in a global pattern, which occupies a significant area, if not the entirety, of the lesion.

The most common patterns observed in benign pigmented lesions (labial lentigo, melanotic macule, melanocytic nevus) include: [5–7]

1. ***Ring-like pattern***. Circles or ring-like structures are the predominant structures. This pattern is commonly seen in melanosis and melanotic macules. Incomplete circles, also known as fish scale–like structures, can also be seen (Figure 11c.2).
2. ***Parallel pattern.*** Pigmented parallel lines form this pattern. It is commonly seen in melanosis and melanotic macules (Figures 11c.3–11c.11).
3. ***Globular or dotted pattern.*** Formed by aggregated globules or dots. It is common in nevi but can also be seen in melanotic macules (Figure 11c.12).
4. ***Structureless pattern***. The entire lesion consists of a homogeneous pigmented area, without evidence of dermoscopic structures. Frequently observed in vulvar melanosis. Due to the folds or rugosity of these anatomic sites, there are often interruptions in the pigmentation (Figures 11c.13–11c.14).

Overall, benign lesions tend to present as symmetric lesions, displaying one or two colors and usually one pattern.

In contrast, malignant lesions, including melanoma, tend to present with a ***multicomponent pattern*** composed of different patterns within the same lesion; they are usually asymmetric, disorganized, and demonstrate at least two or three colors.[4, 6] Advanced melanomas can present with any of the melanoma-specific structures seen in cutaneous melanoma, including atypical vessels, off-centered blotches, shiny white structures, and blue-white veil (Figures 11c.15–11c.18).

DOI: 10.1201/9780429487873-36



FIGURE 11C.1 Dermatoscope covered with polyvinyl chloride film.



FIGURE 11C.4 Dermoscopy of a nevus on labia minora with parallel pattern.



FIGURE 11C.2 Dermoscopy image of a lentigo on the lower lip with fish-like structures or incomplete circles.

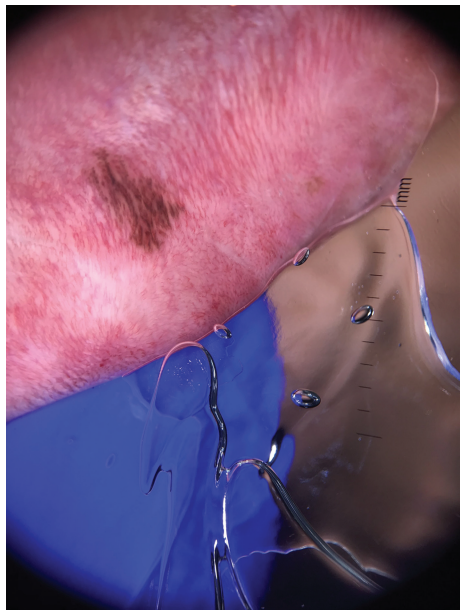

FIGURE 11C.5 Dermoscopic image of a melanotic macule on the lower lip with a parallel pattern.



FIGURE 11C.3 Dermoscopy image of mucosal lentigo on labia minora with parallel pattern.

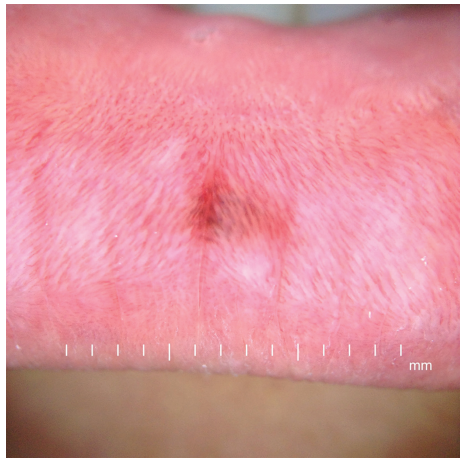

FIGURE 11C.6 Dermoscopic image of a melanotic macule on the lower lip with a parallel pattern.

TABLE 11C.1: Summary of the Most Common Dermoscopic Structures Observed in Mucosal Lesions

Dermoscopic structure	Schematic illustration	Definition	Histopathology
Circles (or ring-like structures)		Pigmented, round to circular structures with a clear center. Variants: • Incomplete circles, also known as fish scale–like structures • Elongated circles, or hyphae-like structures	Hyperpigmentation of the rete ridges with less pigmentation at the top of the dermal papillae. The hyphae structures demonstrate similar hyperpigmentation at the tip. However, the rete ridges are obliquely elongated.
Lines		Pigmented lines that can be thin and curved.Variants: • Parallel lines do not form a network. • Reticular, lines form a network.	Pigmentation in rete ridges.
Globules and dots		Aggregated, pigmented, rounded structures. Usually brown but occasionally gray.	Dots correspond to melanin in the upper dermis. Globules correspond to nevomelanocytes.
Structureless areas		Pigmented homogeneous areas devoid of any dermoscopic structures.	Acanthosis with relatively flat rete ridges.

5–7

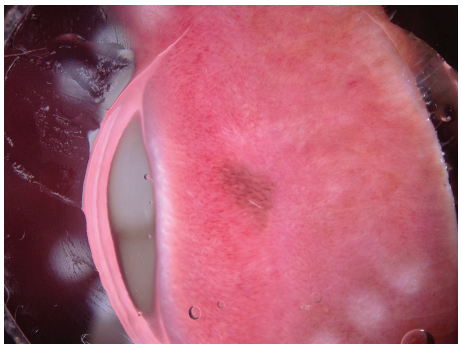

FIGURE 11C.7 Dermoscopic image of a melanotic macule on the lower lip with a parallel pattern.

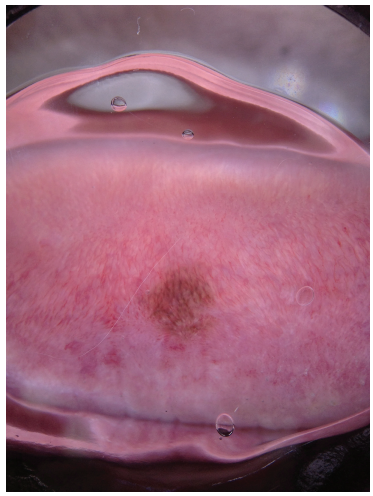

FIGURE 11C.8 Dermoscopic image of a melanotic macule on the lower lip with a parallel pattern.

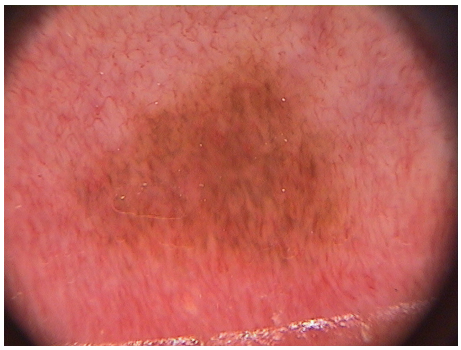

FIGURE 11C.9 Dermoscopic image of a benign melanocytic lesion of the lower lip. This lesion has a parallel pattern.

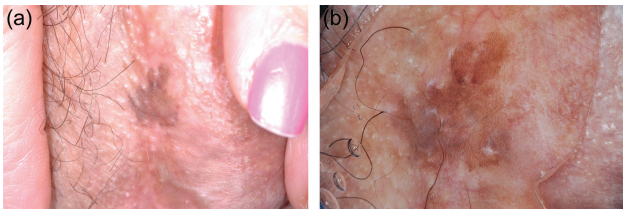

FIGURE 11C.10 Melanotic macule on the vulva displaying a parallel pattern.

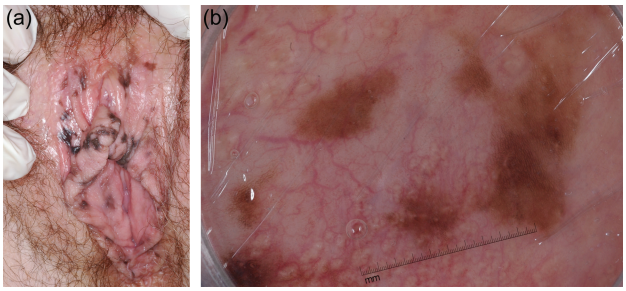

FIGURE 11C.11 One portion of this mucosal melanoma displays a parallel pattern.

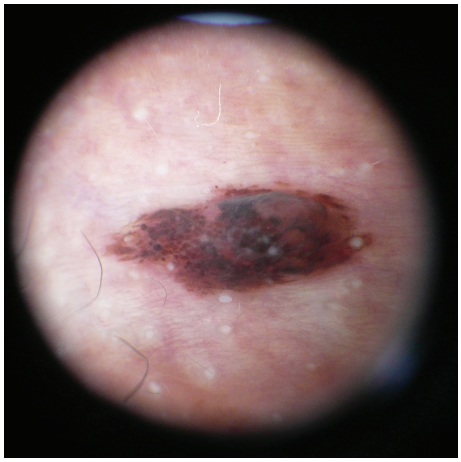

FIGURE 11C.12 Dermoscopic image of a melanocytic nevus on labia majora with a globular pattern.

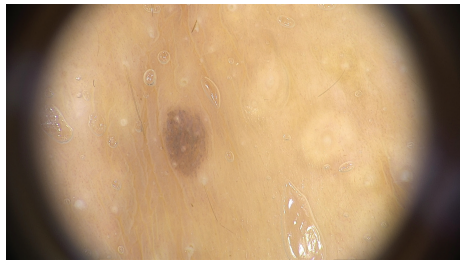

FIGURE 11C.13 Dermoscopic image of a melanocytic nevus with a homogeneous or structureless pattern.

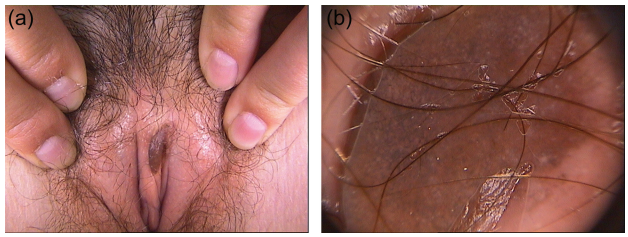

FIGURE 11C.14 Dermoscopic image of a benign melanocytic lesion on the vulva. This lesion has a homogenous structureless pattern.



FIGURE 11C.15 Dermoscopic image of a vaginal melanoma with multiple colors, including black, gray, and red.

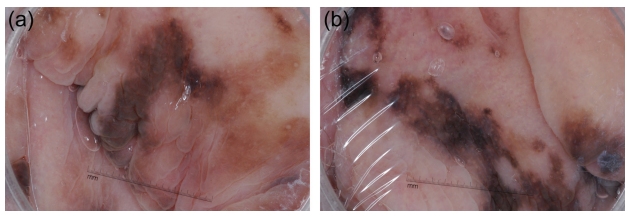

FIGURE 11C.16 Both dermoscopic images are taken from different areas within the melanoma. The structureless areas in this melanoma have a blue-gray color, which is a common color seen in mucosal melanoma.

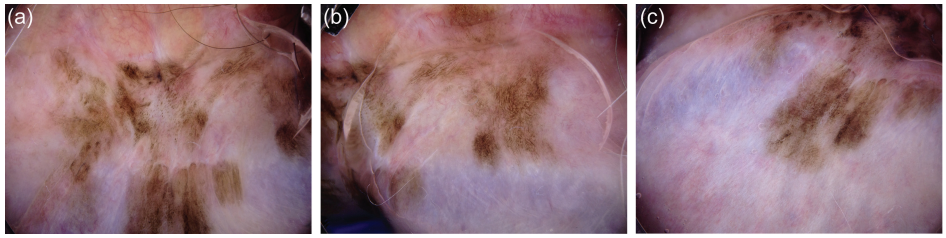

FIGURE 11C.17 (a–c) Recurrent mucosal melanoma in situ on glans (primary melanoma was invasive). Dermoscopy reveals a multicomponent pattern with multiple colors (light brown, dark brown, black, and gray), and more than three dermoscopic structures, including ring-like structures, homogeneous areas, lines, and granularity.

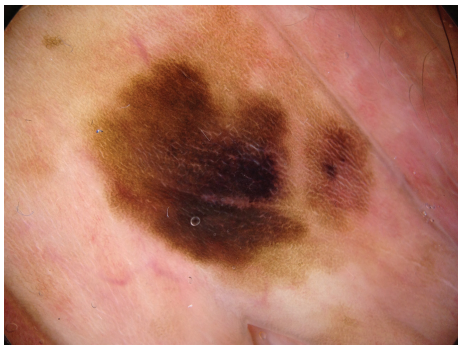

FIGURE 11C.18 Primary melanoma in situ on labia minora. Dermoscopy reveals a multicomponent pattern with multiple colors (light brown, dark brown, black, and red), multiple structures, including ring-like structures, and melanoma-specific structures such as shiny white lines and off-centered blotch.

The presence of structureless areas inside the lesion, together with blue, gray, or white colors, has 100% sensitivity for melanoma and 82% specificity.

As mucosal melanoma is frequently detected at advanced stages, clinicians should carefully examine any new, changing, solitary, or raised pigmented lesion on a mucosal surface that is brought to their attention. Particular caution is recommended when evaluating lesions with these characteristics in older individuals to rule out malignancy. Lesions that are clinically large, irregular, asymmetrical, or ill-defined may benefit from the use of dermoscopy during the physical examination. Dermoscopy findings suspicious for melanoma include lesions with blue, gray or white color, structureless areas, and a chaotic/disorganized appearance (i.e., the presence of at least two or three colors and structures).

Key points

1. Dermoscopic structures in mucosal lesions include circles, lines, structureless areas, dots, and globules.
2. Circles can present as incomplete (or fish scale–like) circles or elongated hyphal-like structures.
3. Benign lesions usually display one pattern composed of one of the mentioned structures with one or two colors. In contrast, melanomas manifest an asymmetric, multicomponent pattern with at least two or three colors.
4. The presence of blue, gray, or white color and structureless areas has a sensitivity of 100% for melanoma, 93% for any malignancy, and a specificity of 64% for melanoma.

References

1. Mucous membrane. NCBI. Published 2019. Accessed Jan 30.
2. Beaudoux O, Riffaud L, Barbe C, Grange F. Prognostic factors and incidence of primary mucosal melanoma: a population-based study in France. *Eur J Dermatol.* 2018;28(5):654–660.
3. Jaimes N, Halpern AC. Practice gaps. Examination of genital area: comment on "Dermoscopy of pigmented lesions of the mucosa and the mucocutaneous junction". *Arch Dermatol.* 2011;147(10):1187–8.
4. Blum A, Simionescu O, Argenziano G, et al. Dermoscopy of pigmented lesions of the mucosa and the mucocutaneous junction: results of a multicenter study by the International Dermoscopy Society (IDS). *Arch Dermatol.* 2011;147(10):1181–7.
5. Mannone F, De Giorgi V, Cattaneo A, Massi D, De Magnis A, Carli P. Dermoscopic features of mucosal melanosis. *Dermatol Surg.* 2004;30(8):1118–23.
6. Lin J, Koga H, Takata M, Saida T. Dermoscopy of pigmented lesions on mucocutaneous junction and mucous membrane. *Br J Dermatol.* 2009;161(6):1255–61.
7. Ferrari A, Buccini P, Covello R, et al. The ringlike pattern in vulvar melanosis: a new dermoscopic clue for diagnosis. *Arch Dermatol.* 2008;144(8):1030–1034.

11D SPECIAL LOCATIONS: NAILS

Amélie Boespflug, Félix Pham, Ralph P. Braun, and Luc Thomas

Contents

Introduction . . . 269
Patient history and general physical examination . . . 269
Clinical and dermoscopic examination . . . 269
- Dermoscopy examination of the nail unit . . . 269
- Dermoscopy of the free edge of the nail plate . . . 269
- Dermoscopy of the nail matrix . . . 270

Nail dermoscopy semiology . . . 270
- Blood spots (subungual hemorrhage) . . . 270
- Background pigmentation . . . 271
  - Brown background pigmentation . . . 271
  - Gray background pigmentation . . . 271
- Parallel micro-lines (striations) over a brown background (band) . . . 272
- Hutchinson's sign and variants . . . 272
  - Pseudo-Hutchinson's sign . . . 272
  - Hutchinson's and micro-Hutchinson's sign . . . 273
  - Atypical Hutchinson's sign . . . 273
- Longitudinal xantho-leukonychia . . . 273
- Longitudinal splinter hemorrhages . . . 273
- Longitudinal erythronychia with an enlarged proximal origin . . . 274
- Localized subungual hyperkeratosis with distal triangular onycholysis . . . 274
- Polychromia . . . 274
  - Atypical vessels . . . 274
- Spots . . . 274
  - Yellow spot(s) . . . 274
  - Red spot(s) . . . 274
  - Purple-blue spot(s) . . . 274

Diagnostic approach to nail pigmentations . . . 275
- Melanocytic versus nonmelanocytic . . . 275
- Background color in melanocytic lesions . . . 275
- Gray-pigmented band: Multiple thin homogeneous grayish lines . . . 275
- Brown-pigmented bands . . . 276
  - Regular pattern: Brown longitudinal parallel lines with regular spacing and thickness . . . 276
  - Irregular pattern: Band with multiple longitudinal brown to black lines with irregular spacing and thickness and disruption of parallelism . . . 276

Nail tumors . . . 276
- Nail unit lentigo . . . 276
- Nevi of the nail matrix . . . 276
  - Acquired nevi of the nail matrix . . . 276
  - Congenital nevus of the nail matrix . . . 276
  - Blue nevus of the nail matrix . . . 277
- Melanoma of the nail matrix . . . 277
  - Melanoma of the nail matrix: Pigmented variant . . . 277
  - Amelanocytic melanoma of the nail matrix . . . 277
- Benign epithelial tumors of the nail matrix . . . 277
  - Onychomatricoma . . . 277
  - Onychopapilloma . . . 277
- Malignant epithelial tumors of the nail matrix . . . 277
  - Squamous cell carcinoma . . . 277
- Other nail tumors . . . 277
  - Glomus cell tumor . . . 277
  - Exostosis . . . 278

Inflammations/infections/trauma-induced/genetic pigmentations . . . 278
- Subungual hemorrhage . . . 278
- Onychotillomania . . . 278
- Warts . . . 279

Fungal infections . . . 279
Ethnic-type pigmentations . . . 279
Drug-induced pigmentation . . . 279
Alopecia areata . . . 279
Lichen planus . . . 279
Psoriasis . . . 279
Which lesions should be biopsied? . . . 279
Bibliography . . . 279

Introduction

Longitudinal pigmentation of the nail, a cause for angst in many clinicians, can be due to a broad number of medical conditions that span from post-traumatic pigmentation, to nail infection, to cancer (6,36). The clinician's angst likely stems from a lack of confidence regarding the underlying diagnosis coupled with an aversion towards performing a nail matrix biopsy, which can cause pain and a permanent nail dystrophy. Furthermore, nail matrix biopsies are often noninformative when executed by an inexperienced physician, because they tend to send nail plate fragments instead of nail matrix sections to the pathologist, hindering his ability to render an accurate diagnosis.

Dermoscopy provides a means for evaluating the nail unit with increased diagnostic accuracy (2), and it can help guide the physician in his sampling of the nail matrix during his biopsy (14, 18).

Of note, early melanomas involving the nail matrix can be difficult to diagnose both dermoscopically and histopathologically, and other factors, such as the age of onset, digits involved, and history of change-, must be taken into account to avoid both unnecessary biopsies and melanoma underdiagnosis.

Patient history and general physical examination

Elements of the patient's personal history that increase the probability that a pigmented nail band may be due to melanoma include the following:

- Duration: When a nail pigmentation is present since birth or developed shortly after, it usually corresponds to a congenital nevus of the nail unit, and this feature is reassuring. Conversely, the later an acquired pigmented nail band appears, the higher the probability that it may be due to a melanoma. A late onset should therefore be considered as worrisome.
- History of melanoma: Although it is well known that a personal or family history of melanoma increases the risk of developing subsequent melanomas, there is insufficient evidence to show that such a history specifically increases the risk of developing subungual melanoma (SUM).
- Digits involved: Isolated nail pigmentation involving the thumb, index finger, or hallux has a greater likelihood of being melanoma then nail pigmentation involving other digits or multiple digits.
- History of trauma: Many patients with SUM recollect sustaining trauma to that digit at some point in the distant past. It remains to be proven whether the association with trauma is due to a recall bias or is due to a biologic phenomenon (28).
- Change: A history of change over a period of months in an acquired pigmented nail band in an adult should raise concern for melanoma (46). While patients may find it difficult to articulate exactly what changes have occurred, they may be able to draw on a piece of paper their impression of what it looked like when they first noticed the pigmentation and how it evolved over time. In addition, it may help to ask patients to search through their smartphone image library for any images that may show what the nail looked like over time. Surprisingly, a very important number of patients are able to provide such images!
- Patient activities and medications: Specific questions on athletic activities, recent trauma, physical exertion, such as long hiking trips, or the use of blood thinners, such as aspirin and warfarin, may help in differentiating subungual hemorrhage from other causes of nail pigmentation. Obtaining a thorough history of any medications the patient is ingesting or receiving via an intravenous route may help identify drugs that may contribute to nail pigmentation (6, 36).

Clinical and dermoscopic examination

A complete examination includes the inspection of all nail units on the hands and feet, including the nail plate, cuticle, paronychium, and hyponychium of each digit. In addition, examination of the mucosal surfaces of the mouth and genitalia can aid in correctly identifying diseases that involve nails and/or mucosae, such as Peutz–Jeghers syndrome and Laugier–Hunziker syndrome (6, 36, 44). Evaluation of the nail unit with dermoscopy should include inspecting the nail plate, hyponychium, cuticle, and the free edge of the nail plate.

Dermoscopy examination of the nail unit

For the examination of the nail apparatus, a viscous solution is a better immersion medium than alcohol; we recommend the use of a gel, such as ultrasound gel or a clear gel-based hand sanitizer. The viscosity of the gel permits it to stay on the nail plate and fill any concavities without rolling off. For the evaluation of the pigmentation, it is useful to vary the focus of the dermoscopic device during the examination. Classic nail (plate) dermoscopy allows the examination of the nail plate, perionychium, and hyponychium.

Dermoscopy of the free edge of the nail plate

Evaluation of the free edge of the nail plate provides additional clues that can assist in the diagnosis of a variety of nail tumors (5). For example, it allows the identification of the "honeycomb"-like pitting of the thickened nail plate associated

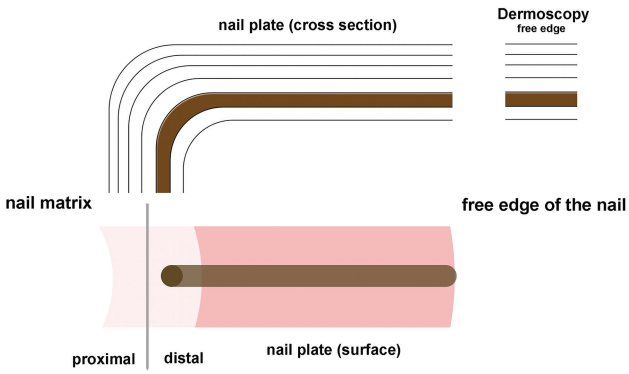

FIGURE 11D.1 Schematic drawing of free edge dermoscopy. As a result of the natural growth of the nail, pigment produced in the proximal nail matrix will be incorporated into the upper portion of the nail plate, and pigment produced in the distal nail matrix will appear in the lower part of the nail plate. The schematic shown here is that of a lesion located in the distal nail matrix.

with onychomatricoma and the subungual hyperkeratosis associated with onychopapilloma and squamous cell carcinoma.

Examination of the free edge of the nail plate can also help determine whether the lesion responsible for the pigmentation is located in the proximal or the distal nail matrix (Figure 11d.1). The proximal nail matrix is responsible for creating the upper portion of the nail plate. A melanocytic neoplasm located in the proximal nail matrix will therefore deposit pigment in the upper nail plate. In such cases, dermoscopy of the free edge will reveal pigment in the upper portion and no pigment in the lower portion of the nail plate. In contrast, melanocytic lesions localized in the distal nail matrix are responsible for a pigmentation that is limited to the lower portion of the free edge of the nail plate. Knowing the location of the source of the pigmented nail band helps guide the nail matrix biopsy. If a doubt persists regarding the origin of the pigmentation, one can obtain a nail clipping and color it with Fontana–Masson stain. This facilitates the visualization of melanin within the nail plate and can help determine whether the pigmentation originated in the proximal or the distal nail matrix.

Dermoscopy of the nail matrix

With noncontact polarized light, it is possible to examine the nail matrix during a surgical biopsy procedure without the risk of contamination of the exposed nail matrix or the sterile surgical instruments, as shown by Hirata et al. in 2005 (13–15). They also described that streaks, pigment network, and globules in the nail matrix and nail bed were most commonly seen in conditions characterized by nail matrix melanocytic hyperplasia. Regular stripes or/and globules are not in favor of melanoma, whereas stripes that are irregular in color, length, or thickness and asymmetrically distributed globules are in favor of melanoma. In contrast, diffuse homogeneous pigmentation was seen in conditions without prominent melanocytic hyperplasia of the nail matrix, such as ethnic-type pigmentation. In addition, intraoperative dermoscopic examination allows more precise targeting of the area that has to be biopsied. Direct dermoscopy of the exposed nail matrix is also useful in cases of nonpigmented subungual tumors such as small squamous cell carcinoma (SCC), in which irregular translucent whitish areas with atypical vessels are seen; glomus cell tumors, in which

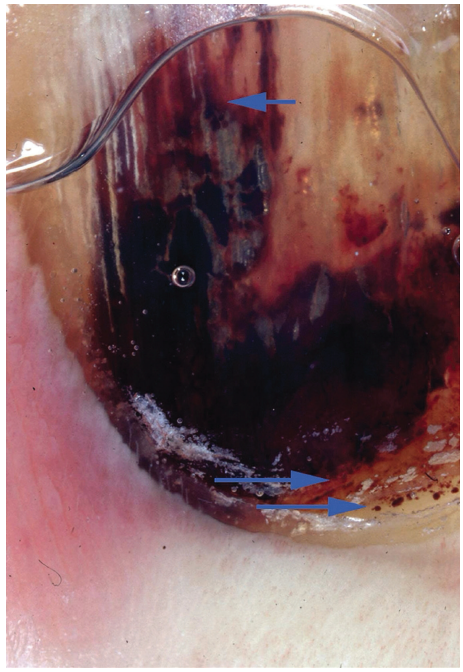

FIGURE 11D.2 Subungual hemorrhage in an adult's first toenail (recent lesion). Dermoscopy shows a characteristic purple coloration of the pigmentation with an elongated parallel linear pattern at the distal edge (short arrow) and a well-demarcated round proximal edge with characteristic features of blood spots (long arrows).

purple ovoid spots are observed; onychopapilloma, in which a regular longitudinal translucent whitish area with longitudinal vessels is visualized; or onychomatricoma, which is characterized by multiple hyperbolic crypts on the ventral aspect of the plate ("sagrada familia sign"), multiple proximal digitations of a white translucent area of the matrix and bed, and the symmetry of these with the crypts ("mirror sign").

Nail dermoscopy semiology

Blood spots (subungual hemorrhage)

Blood spots have a sharply demarcated, round-shaped proximal edge (Figure 11d.2) and a filamentous distal edge (5–7, 36, 44) (Figure 11d.3). Their color varies from purple-red (fresh blood) to black-brown (older blood). Blood spots are usually associated with trauma-induced subungual hemorrhages even when the patient is unable to recollect the trauma. This is typically the case with repetitive microtrauma-induced subungual hemorrhages of the toenail—due to tight or poorly fitting shoes—or in patients on anticoagulation therapy, who can bleed even after relatively mild impacts. On rare occasions, blood spots may arise due to bleeding in an underlying tumor. Thus, before associating blood spots with the diagnosis of an uncomplicated subungual hemorrhage, it is imperative that the entire nail plate, free edge of the nail plate, hyponychium, eponychium, paronychium and cuticle be examined to ensure that all are free of any signs of tumor. Blood spots revealing an otherwise normal nail unit can be dismissed as being related to trauma only if one can confirm that a portion of the proximal nail plate is visible and appears normal. If the proximal nail plate also has blood spots, and one cannot see a normal nail plate emerging from under the cuticle, then re-examination of

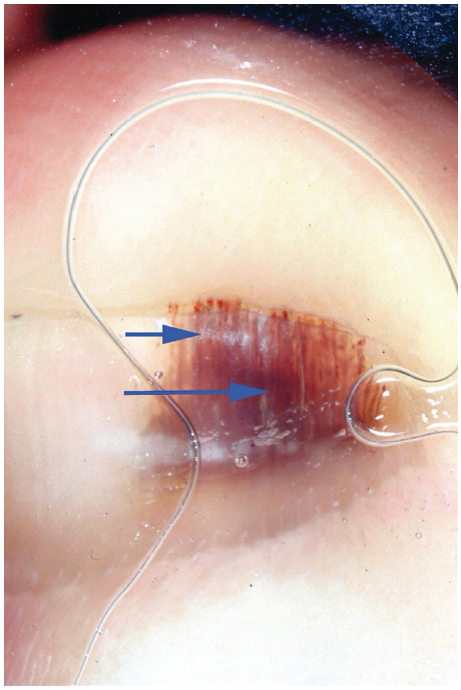

FIGURE 11D.3 Subungual hemorrhage in a child's toenail (old lesion). Note the elongated parallel linear pattern of the distal edge of the pigmentation (short arrow) and the purple-brown coloration of the proximal blood spot (long arrow).

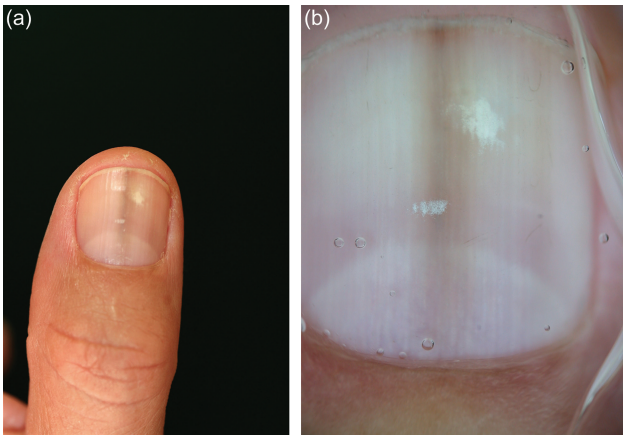

FIGURE 11D.4 (a) Clinical image of a grayish longitudinal nail pigmentation. (b) Dermoscopy shows a homogeneous grayish band in an ungula lentigo.

the nail unit in 3–4 months is mandatory. As the nail grows, it will push the subungual blood distally, revealing a normal nail plate emerging proximally. It is important to remember that a subungual hemorrhage moves distally about two-fold slower than the nail plate itself. If after follow-up, there is no evidence of a normal nail plate emerging from under the cuticle, one needs to consider the possibility of an underlying tumor.

Background pigmentation

Brown background pigmentation

A longitudinal band with a brown background color indicates the presence of a melanocytic proliferation in the nail matrix (6, 34, 36, 43, 44). This is observed in nail matrix nevi and melanomas. The color may vary from light brown to dark brown to black. Patients with skin types I, II, and IIIa tend to present a light brown coloration of the melanonychia striata, whereas types IIIb, IV, V, and VI patients have darker bands (26).



FIGURE 11D.5 Hydroxyurea-induced pigmentation of an adult's fingernail. The dermoscopic pattern is very similar to that of lentigo, with grayish coloration of the background and thin gray lines (between the two short arrows).

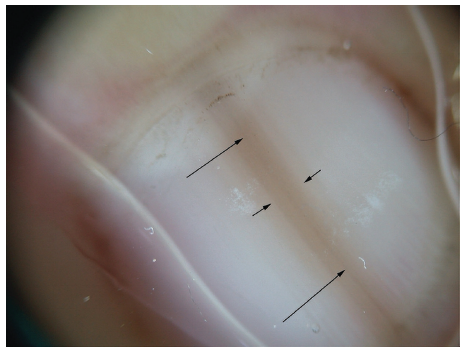

FIGURE 11D.6 Ethnic pigmentation of the toenail plate in a phototype V (North African) adult. Dermoscopy shows grayish coloration of the background (between the two short arrows) and thin superimposed gray lines (long arrows).

Gray background pigmentation

A gray coloration of the nail band is usually associated with a melanocytic activation without the presence of a significant melanocytic proliferation in the nail matrix (6, 34, 36, 43, 44). It is observed in conditions such as lentigo (Figure 11d.4), drug-induced pigmentation (Figure 11d.5), ethnic-type pigmentation (Figure 11d.6), lentiginoses of various types (Figure 11d.7), and repetitive trauma–induced pigmentation (mostly frictional on

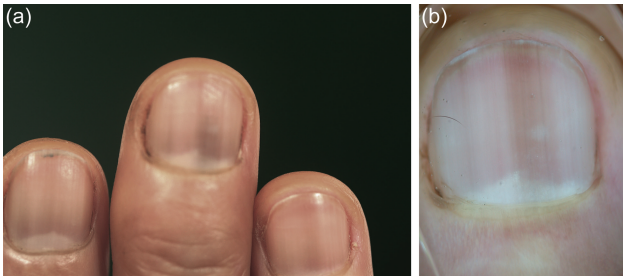

FIGURE 11D.7 (a) Clinical image of a patient with Laugier–Hunziker syndrome showing multiple grayish-pigmented bands. (b) Dermoscopy shows multiple grayish bands in the nail plate. This finding is consistent with Laugier–Hunziker syndrome.



FIGURE 11D.8 (a) Clinical image of a light-colored nevus of the nail matrix. (b) Dermoscopy shows small melanin inclusions in the nail plate and brown longitudinal parallel lines with regular spacing and thickness.

toenails). While a single gray band involving a single digit may, on very rare occasions, be seen in early cases of melanoma in situ or Bowen's disease (SCC in situ), the presence of gray lines involving multiple digits is a reassuring sign associated with benign diagnoses.

Parallel micro-lines (striations) over a brown background (band)

Melanonychia striata due to a melanocyte proliferation consists of a pigmented band that emanates from the nail matrix and usually extends the entire length of the nail plate. This band of pigment when viewed with dermoscopy will reveal multiple linear micro-lines (striations) within it. These micro-lines can demonstrate a regular or irregular pattern. A ***regular parallel pattern*** consists of lines with similar colors and thickness, with organized (even/symmetric) spacing, and with lines that are parallel and extend the entire length of the nail plate (Figures 11d.8 and 11d.9). A regular pattern is associated with melanocytic nevi of the nail matrix (6, 34, 36, 43, 44). In contrast, micro-lines demonstrating an ***irregular parallel pattern*** are associated with melanoma. Lines in an irregular pattern present an increased variability in color and thickness, have an uneven or asymmetric (disorganized) distribution

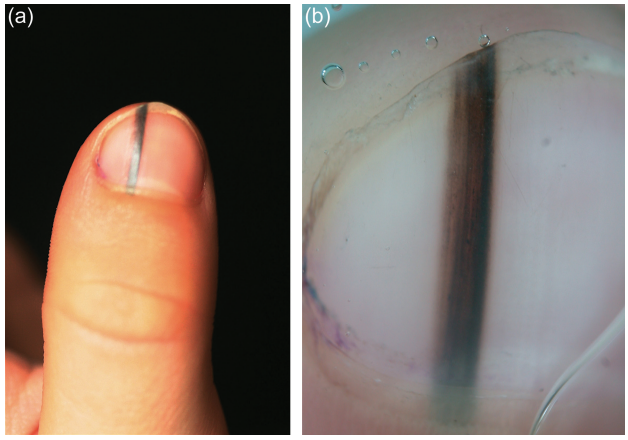

FIGURE 11D.9 (a) Clinical image of a dark nevus of the nail matrix. (b) Dermoscopy shows brown longitudinal parallel lines with regular spacing and thickness. The pigmentation can be observed through the translucent cuticle. This is a pseudo-Hutchinson sign and has to be distinguished from true Hutchinson sign, which corresponds to a true pigmentation of the cuticle or the periungual skin.

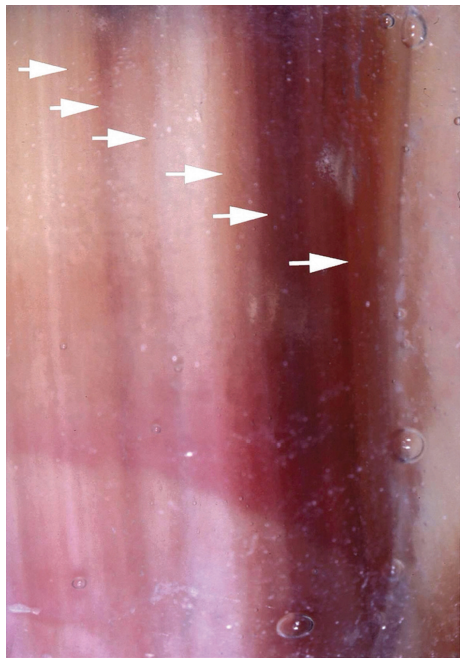

FIGURE 11D.10 (a) Nail apparatus melanoma, acrolentiginous melanoma–type, Clark level III, 0.65 mm thickness in the big toenail. (b) Dermoscopy shows brown coloration of the background and irregularly spaced, pigmented, and thick brown longitudinal lines (arrows).

within the pigmented band, and/or have a disruption of their parallelism (Figures 11d.10 – 11d.15).

Hutchinson's sign and variants

Pseudo-Hutchinson's sign

The term *pseudo-Hutchinson sign* is used to describe the visualization of pigment in the nail plate that is located beneath a translucent cuticle (Figure 11d.9). It has no particular diagnostic significance (6, 34, 36, 43, 44).

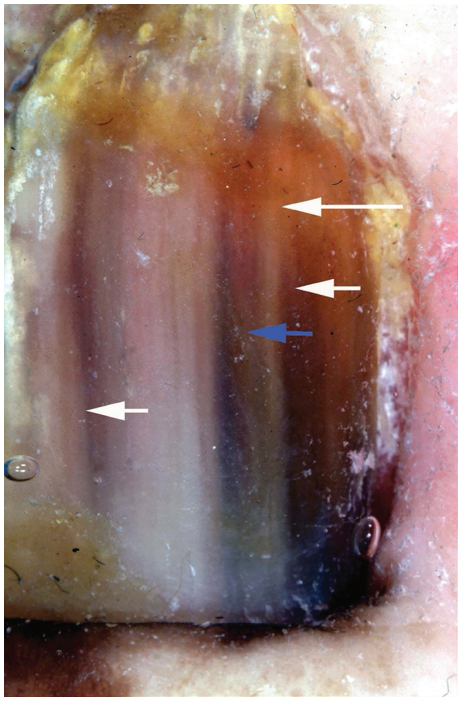

FIGURE 11D.11 (a) Nail apparatus melanoma in a 72-year-old phototype IV male patient on the first left toenail. Note the irregular pattern of the brown lines (different thickness, color, and spacing; white arrows) and an area of parallelism disruption (blue arrow).

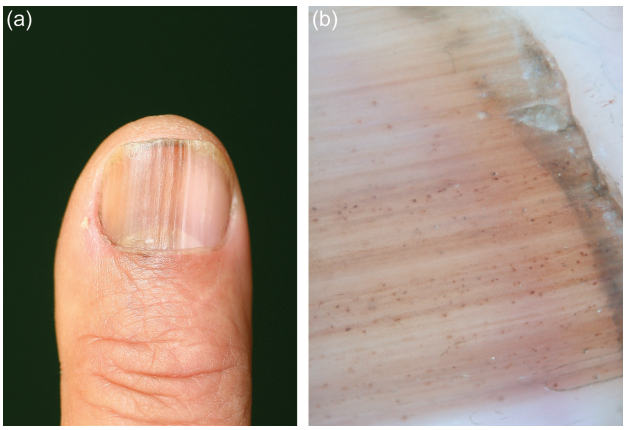

FIGURE 11D.12 (a) Clinical image of an in situ melanoma of the nail matrix. (b) Dermoscopy shows multiple brown bands of irregular spacing thickness and disruption of parallelism. This case also shows granular melanin inclusions in the nail plate.

Hutchinson's and micro-Hutchinson's sign

Hutchinson's sign is defined by the presence of a melanin pigmentation within the periungual skin (cuticle) (Figure 11d.13). When associated with melanonychia striata, it is highly suggestive of melanoma, but it can also be found in congenital nevi involving the nail unit. This area of pigment within the cuticle can be focal and very small, making it almost impossible to discern with the naked eye. However, these small areas of pigment within the cuticle can be observed with dermoscopy and when present, are called micro-Hutchinson's sign. The presence of

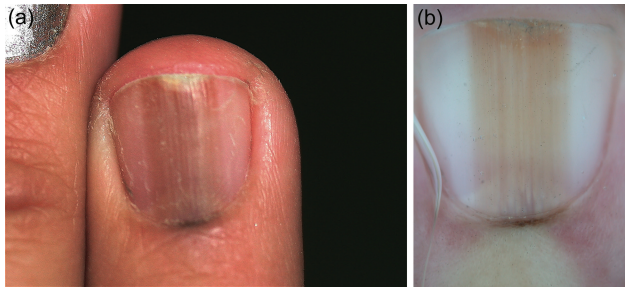

FIGURE 11D.13 (a) Clinical image of an in situ melanoma. (b) Dermoscopic image of an in situ melanoma.

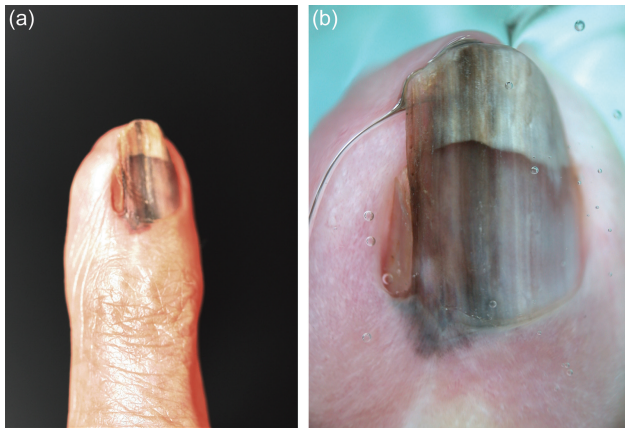

FIGURE 11D.14 (a) Clinical image of an invasive melanoma of the nail matrix. (b) Dermoscopy shows irregular brown bands as well as a Hutchinson sign (pigmentation of the periungual skin).

micro-Hutchinson's sign is associated with melanoma but can also be observed in ethnic-type pigmentation and congenital nevi involving the nail unit (6, 34, 36, 43, 44). It is important to note that a biopsy of the pigmented cuticle (Hutchinson's sign) cannot be used to rule out the diagnosis of melanoma involving the nail matrix.

Atypical Hutchinson's sign

If the pigment is located in areas other than the cuticle, this corresponds to an atypical Hutchinson's sign. This pigmentation can be located on the paronychial skin or on the hyponychium. The rules applied in the evaluation of pigmented lesions on volar skin apply here. In other words, the presence of a parallel ridge pattern or irregular diffuse pigmentation should raise concern for melanoma.

Longitudinal xantho-leukonychia

Leukonychia is defined as a white band on the nail plate, and xanthonychia is defined as a yellow-colored band. These two colors are often observed simultaneously within the same lesion. This phenomenon is generally due to the thickening of the nail plate.

Longitudinal splinter hemorrhages

Splinter hemorrhages under the nail plate are associated with numerous medical conditions, including connective tissue diseases, onychotillomania, coagulation abnormalities, undernutrition, infectious endocarditis, and hematological

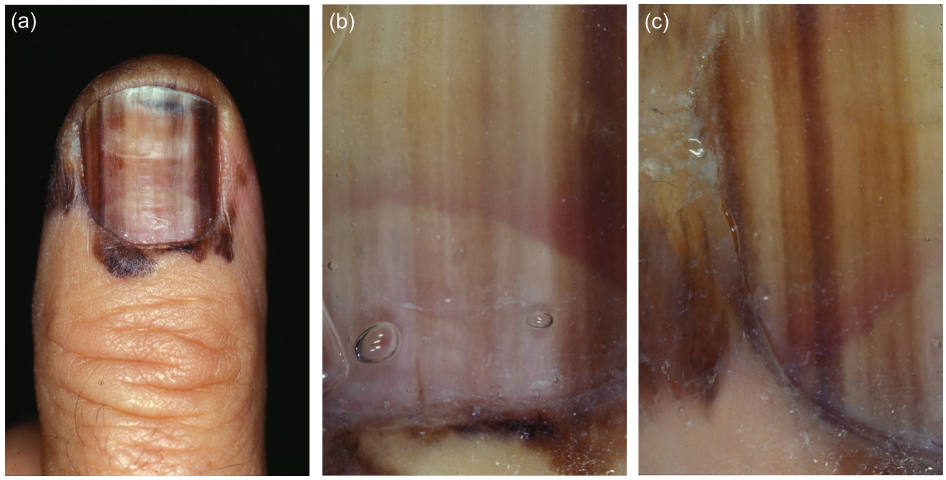

FIGURE 11D.15 (a) Clinical image of an advanced melanoma of the nail matrix with extensive pigmentation of the periungual skin. (b) and (c) Dermoscopy shows irregular brown bands (Breslow 1.2 mm).

disorders. In such cases, splinter hemorrhages usually affect multiple nails. When splinter hemorrhages are present in one digit and are associated with leuko-xanthonychia or polychromia, an epithelial tumor of the nail matrix should be suspected. Splinter hemorrhages associated with amelanotic melanoma of the nail are often randomly distributed and are associated with erythronychia. Splinter hemorrhages can also be seen in benign tumors, including onychopapilloma and onychomatricoma (discussed later).

Longitudinal erythronychia with an enlarged proximal origin

Angiomas of the nail plate have been described; dermoscopically, they show a thin longitudinal erythronychia with a clubbed proximal edge.

Localized subungual hyperkeratosis with distal triangular onycholysis

Localized subungual hyperkeratosis observed at the free edge of the nail plate and associated with leuko-xanthonychia, splinter hemorrhages, or polychromia is indicative for the presence of an epithelial tumor of the nail matrix. These tumors can range from benign onychomatricoma and onychopapilloma to malignant SCC. A triangular erosion (onycholysis) of the distal nail plate is another sign that should prompt further evaluation for the presence of either a benign or a malignant subungual tumor.

Polychromia

Polychromia is defined as the presence of four or more of the following colors: black, red, blue, white, yellow, dark brown, light brown, gray, or purple. Polychromia is seen in malignant amelanotic neoplasms such as SCC or amelanotic melanoma.

Atypical vessels

In dermoscopy, an atypical pattern of the vessels can be seen on the nail bed in case of erosion of the nail plate, which is a very common feature in advanced malignant tumors. An atypical pattern is defined by at least one of the following criteria:

- Linear and irregular vessels (caliber changes from one segment to another of the same vessel).
- Presence of at least three different types of vessels within the same lesion, including dots and globules, comma-like, hairpin-like, linear, corkscrew-like, or arborizing vessels.
- Milky-red areas, defined as structureless pink areas with various shades of pink without identified vascular structures. These areas are found in pyogenic granuloma and in advanced amelanotic melanoma; since these two entities cannot be differentiated based on clinical or dermoscopic examination, a biopsy is mandatory.

Spots

Discrete pigmented spots can be present in the nail plate, and they can be yellow, red, or blue-purple in color.

Yellow spot(s)

A yellow, well-demarcated, structureless, round to ovoid spot is observed in subungual exostosis. It is created by the pressure exerted by the bone pressing on the nail bed Figure 11d.16.

Red spot(s)

Structureless red spots are associated with amelanotic melanoma and pyogenic granuloma. They can be differentiated from blood spots by their red color and their regular ovoid or round shape, while blood spots in subungual hemorrhages have a fibrillar aspect distally.

Purple-blue spot(s)

A structureless purple to blue spot observed through the nail plate is associated with one of two conditions: The presence of a blue nevus of the nail unit or a glomus cell tumor. In the latter, the pressure of the dermo scope on the nail plate can trigger the characteristic "electric" pain associated with this neoplasm. There are three well-described clinical tests that can help diagnose glomus tumors:

- **Love's test**: This test is considered suggestive of the presence of a glomus tumor if the pressure applied using the head of a pin or the tip of a paperclip reproduces pain on the affected fingertip. This test can also help locate the tumor.

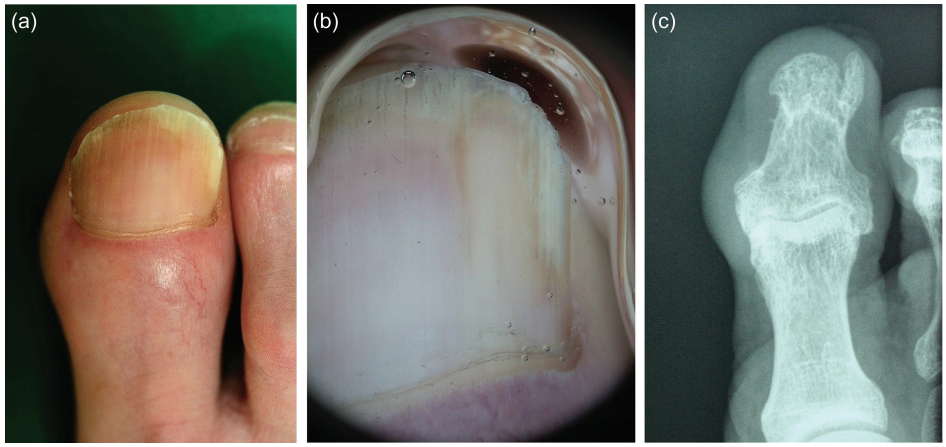

FIGURE 11D.16 Exostosis. (a) Clinical aspect: Nail plate tumefaction with lateral onycholysis; (b) Dermoscopic aspect: Yellow, well-demarcated, structureless ovoid spot; (c) X-ray aspect.

- **Hildreth's test**: This test is considered suggestive of the presence of a glomus tumor if the tenderness observed during the Love's test disappears when the physician applies a tourniquet to the digit involved.
- **The cold sensitivity test** requires that the physician expose the finger to cold by, say, placing the finger in an ice bath. This exposure will elicit increased pain in a patient who has a glomus tumor.

The sensitivity and specificity of these tests, according to one study involving 18 patients, are as follows: Love's test (100%, 78%, respectively); Hildreth's test (77.4%, 100%); and the cold sensitivity test (100%, 100%) (3). Clinical suspicion must be confirmed by histopathologic examination, and the patient must be alerted to the risks of biopsy, which include permanent nail deformity.

Diagnostic approach to nail pigmentations

Melanocytic versus nonmelanocytic

The first goal in the clinical examination of a nail pigmentation is to determine whether the pigmentation is due to a melanocytic proliferation, a melanocytic activation, or a nonmelanocytic process (Figure 11d.17). In most cases, clinical inspection and examination with dermoscopy provide the information needed to differentiate these entities from each other. The patterns of the pigmentation found in nonmelanocytic lesions, including fungal infections and subungual hematoma, are described in the following.

The presence of melanin inclusions in the melanonychia striata—which appear as pinpoint granules of less than 0.1 mm in diameter when visualized with a dermoscope—is associated with melanocytic lesions.

Histologically, the term "melanocyte hyperplasia" should be reserved only for cases in which there is an increased number of melanin-containing melanocytes (>6.5 cells/mm of basal membrane length) within the basal and suprabasal layer. The presence of fewer than 6.5 melanocytes/mm of basal membrane length in a melanocytic lesion should be considered as melanocytic activation.

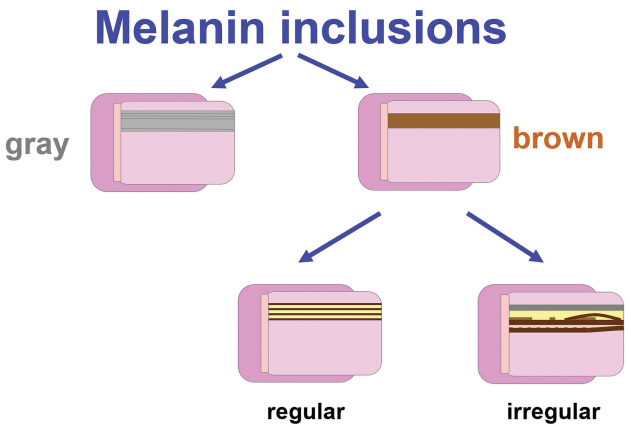

FIGURE 11D.17 Diagnostic algorithm for nail pigmentations of melanocytic origin: In the first step, one has to determine whether a nail pigmentation is of gray or brown color. In a lesion with brown color, we need to determine whether the brown bands are regular (nevus) or irregular (melanoma).

Background color in melanocytic lesions

Pigmentation due to a melanocytic process is either gray or brown in color.

Gray-pigmented band: Multiple thin homogeneous grayish lines

This pattern is usually a result of epithelial hyperpigmentation due to melanocyte activation without melanocytic hyperplasia (Figures 11d.4 – 11d.7).

Pigmented gray bands can be seen in the following context (6, 34, 36, 43, 44):

- Ungual lentigo
- Drug-induced pigmentation
- Endocrine nail pigmentation
- Ethnic pigmentation
- Nail pigmentation associated with HIV infection
- Nail pigmentations associated with inflammatory nail disorders

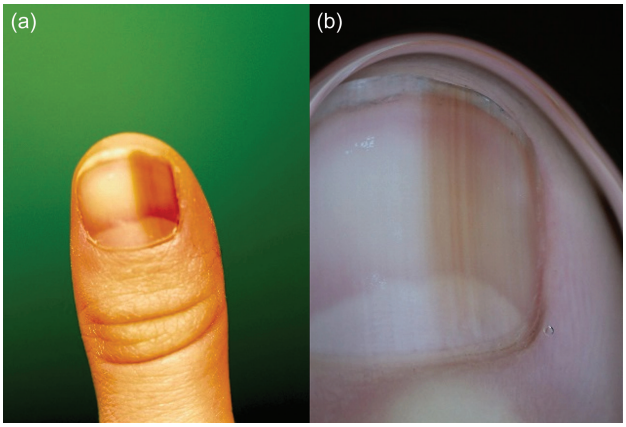

FIGURE 11D.18 Brown micro-lines. Within a brown-pigmented nail band, there are lighter and darker linear micro-lines (striations). (a) Clinical aspect; (b) dermoscopic aspect.

- Laugier–Hunziker syndrome
- Nutritional nail pigmentation
- Traumatic nail pigmentation
- Systemic lupus erythematosus and scleroderma

Brown-pigmented bands

Within a brown-pigmented nail band, there will almost always be lighter and darker linear micro-lines (striations) (Figure 11d.18). These lines can be regular or irregular and are caused by melanocytic hyperplasia or melanocytic proliferation (6, 34, 36, 43, 44).

Because of the architecture of the nail matrix, as well as the dendritic morphology and suprabasal location of nail matrix melanocytes, it can be very difficult to differentiate in situ melanoma from a nevus on a partial biopsy specimen (i.e., punch biopsy specimen) of the nail matrix. Whenever possible, it is therefore preferable to perform a complete longitudinal excision or broad shave biopsy of the nail matrix associated with the band.

In brown-pigmented bands, two patterns can be observed:

Regular pattern: Brown longitudinal parallel lines with regular spacing and thickness

This pattern is usually associated with the homogeneous brown color of the background band (6, 34, 36, 43, 44). The color of the individual micro-lines within the band can vary from light brown to dark brown or black (Figures 11d.8 – 11d.9). However, within any given band, the lines will display minimal variation in the shades of brown throughout the lesion. The spacing between the lines will be organized (evenly/symmetrically distributed), and there will be minimal variation in the thickness of the lines. In addition, the individual micro-lines will be parallel to one another and extend from the proximal to the distal part of the nail plate. This is the typical pattern seen in a nevus of the nail matrix. Congenital nevi (present at birth or developed before the age of 6) will manifest the same pattern of micro-lines, but the color of the bands will tend to be darker when compared with acquired nevi. In addition, the paronychial area (including the cuticle) as well as the hyponychium may reveal pigment distributed in a fibrillar to serrated pattern. Congenital nevi that are dark and extend to the surrounding skin can look like melanoma. In such cases, the young age of the patient and the presence of the band before the age of 5 are reassuring features.

Irregular pattern: Band with multiple longitudinal brown to black lines with irregular spacing and thickness and disruption of parallelism

The background pigmentation of bands that are irregular is also brown. However, the color of the individual micro-lines varies from white to light brown, dark brown, gray, or black (Figures 11d.10 – 11d.15). Irregular micro-lines have differing intensity of pigmentation and increased variability in line thicknesses and spacing. Some lines may not extend completely from the proximal to the distal nail plate, while others may not be aligned parallel to each other. Lines that are not parallel may even merge one into the other, which corresponds to a disruption in parallelism (6, 34, 36, 43, 44). In rapidly growing melanomas the lines will not be parallel, and the entire band will take on a triangular configuration, with the proximal band being wider than the distal band. Blood spots and splinter hemorrhages can also be found in a melanoma that has an irregular pattern.

An irregular pattern is the predominant pattern found in melanomas of the nail matrix. Although melanoma of the nail matrix has the same incidence across all races, it is one of the more frequent melanoma subtypes found in black and Asian populations. Nail matrix melanoma is usually diagnosed in middle-aged to elderly individuals. It affects both fingernails and toenails, with the most frequent digits of involvement being the index finger, thumb, and hallux. Approximately 50% of patients with nail melanoma recall a preceding traumatic event involving the digit with the melanoma. In advanced stages of melanoma, dystrophy of the nail plate or loss of the nail plate can be observed. This is a direct result of the progressive destruction of the nail matrix by the expanding tumor. As already mentioned, pigmentation of the nail fold cuticle and the surrounding skin, known as Hutchinson's sign, is frequently observed in advanced cases of melanoma.

Nail tumors

Nail unit lentigo

Lentigo and lentiginoses seen in Laugier–Hunziker, Peutz–Jeghers, or Carney complex usually will affect multiple nails (Figure 11d.7). Examination of other involved areas such as the palms, soles, and mucous membranes can assist in making the correct diagnosis and cancels the need for a biopsy. Dermoscopy shows gray band-like pigmentation in these cases. Additional new longitudinal pigmented nail bands may develop over the course of time (6, 8, 17, 34, 36, 38, 43, 44).

Nevi of the nail matrix

Acquired nevi of the nail matrix

Acquired melanocytic nevi involving the nail matrix are dermoscopically characterized by their brown background coloration and the regular pattern of the longitudinal micro-lines. The degree of pigmentation of the micro-lines and band is dependent to a great extent on the skin type of the patient.

Congenital nevus of the nail matrix

Congenital nevi (CMN) involving the nail unit can be evident at birth or manifest within the first few years of life. The nevi that are not apparent at birth and develop within the first

few years of life are known as tardive congenital nevi. The clinical morphology of CMN involving the nail unit are usually concerning for melanoma due to their dark pigmentation and the frequent involvement of the skin surrounding the nail. Fortunately, the occurrence of SUM in children is extremely low (21, 37, 40).

Dermoscopy features that are commonly seen in CMN have been associated with SUM in adults. These features include a triangular shape of the melanonychia striata, presence of pigment on the cuticle and hyponychium, as well as nail plate softening or erosion. The pigment present on the hyponychium of CMN involving the nail unit usually manifests a parallel furrow pattern (see Chapter 11b) or a serrated to almost fibrillar pattern that crosses perpendicular to the dermatoglyphics. In some cases, the pigmentation fades away almost completely.

Blue nevus of the nail matrix

Blue nevus of the nail unit is a rare entity. Dermoscopically, it manifests as a blue spot located near the proximal portion of the nail plate. This spot remains stable over time.

Melanoma of the nail matrix

Melanoma of the nail matrix: Pigmented variant

In cases of melanonychia striata developing after puberty, melanoma should always be included in the differential diagnoses. Clinical signs associated with melanoma include:

- Adult onset
- Involvement of a single digit
- Dynamic lesion revealing changes over time
- Triangular shape of the band, which indicates that the lesion is growing relatively fast
- Polychromia
- Hutchinson's sign (presence of pigmentation on the periungual skin)

Dermoscopy provides useful additional information to aid in the diagnosis of melanoma, including:

- Better visualization of multiple shades of brown and black color present in the nail band.
- Visualization of the irregular pattern of micro-lines.
- Brown to black dots and globules may be observed in association with the longitudinal lines (Figures 11d.10–11d.15).
- Micro-Hutchinson's sign. Dermoscopic examination of periungual skin may reveal pigment that is difficult to appreciate with the naked eye.
- Pigmentation on the hyponychium manifesting a parallel ridge pattern, or pigmentation on the lateral and proximal paronychial areas displaying diffuse pigmentation with multiple shades of brown.

Amelanocytic melanoma of the nail matrix

Early amelanotic melanoma of the nail unit is extremely difficult to diagnose, since it may appear only as a faint to almost imperceptible erythronychia (34). As the melanoma grows, it can cause nail dystrophy, including the partial or complete erosion of the nail plate; at this stage, the diagnosis is much easier, since the nail bed may also reveal irregular vessels, an exophytic growth, an ulcer, or a bleeding tumor. Differential diagnoses for such lesions include pyogenic granuloma and infectious conditions such as trauma-induced nail deformities, lichen planus, pustular psoriasis, tuberculosis, and Orf.

Benign epithelial tumors of the nail matrix

Onychomatricoma

Onychomatricoma is a benign tumor of the nail matrix. It exhibits nail dystrophy and a well-demarcated whitish to yellowish band, which will often contain splinter hemorrhages. The band is associated with nail thickening (9, 27, 31, 41, 42). Examination of the free edge of the nail plate reveals the characteristic honeycomb-like punctuations, which are almost pathognomonic for onychomatricoma. The differential diagnosis includes SCC (Figure 11d.19).

Onychopapilloma

Onychopapilloma is a benign neoplasm of the nail bed and the distal matrix. It usually presents as a localized longitudinal erythronychia or leuko-xanthonychia. The nail plate often has splinter hemorrhages. Examination of the distal nail plate and hyponychium will reveal focal distal subungual hyperkeratosis together with V-shaped distal onycholysis (12, 23, 45).

Malignant epithelial tumors of the nail matrix

Squamous cell carcinoma

Bowen's disease, also known as in situ SCC, can affect the nail and/or periungual skin. It generally involves a single digit, but in rare cases, it may involve multiple nail units. The nail plate will usually reveal white-to-yellow longitudinal discoloration of the nail plate, but pigmented cases are not uncommon. In the latter case, pigmentation is grayish rather than brown or black in color. Other features that may be observed include splinter hemorrhages, polychromia, focal subungual hyperkeratosis, distal subungual onycholysis, and a triangular-shaped lunula (4, 20, 30, 42). Dermoscopic features of SCC involving the periungual skin include scale, glomerular vessels, white circles, or tiny gray to brown dots.

Other nail tumors

Glomus cell tumor

Glomus cell tumors are benign hamartomas of the glomus body, which is a specialized arteriovenous anastomosis located in the stratum reticularis that is involved in thermoregulation. Glomus tumors represent 1–5% of soft tissue tumors of the hand, and they are most commonly located in the subungual region.

Glomus cell tumors most commonly appear in young adults (20–40 years) as small, painful, reddish, subungual tumefactions. Pain is increased by pressure and by exposure to cold temperatures.

Nail plate dermoscopy most commonly reveals a structureless purple or blue spot under the nail plate. It can also reveal numerous ramifying vessels within a homogeneous red-blue tumor. Magnetic resonance imaging can help to precisely localize the tumor and facilitate the pre-surgical evaluation of its size. The treatment of glomus cell tumors consists of a complete surgical removal with histological examination. Intraoperative dermoscopy can help delimitate the tumor margins (11, 19, 22, 25, 39).

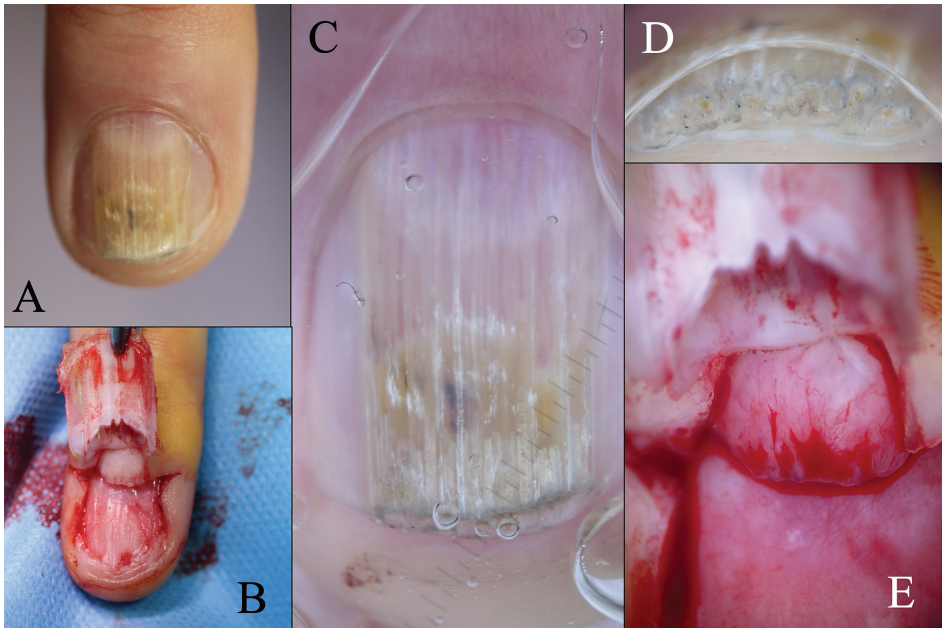

FIGURE 11D.19 Onychomatricoma. (a) Clinical view. (b) Surgical view. (c) Dermoscopy of the nail plate (immersion + contact) objectives a sharply limited longitudinal white-yellowish discoloration with proximal long hairpin-like vessels and distal splinter hemorrhages. Note the sharp demarcation between the involved and uninvolved nail plate and the perfect parallelism of the two lateral borders. (d) Dermoscopy of the free edge of the plate (immersion + contact) shows a thickened nail plate with the presence of round-shaped openings here and there. (e) Per-operative dermoscopy of the nail bed, matrix, and ventral aspect of the plate (noncontact + polarized light) discloses a well-circumscribed tumor overlying the matrix with digitations on its distal edge and poly-concave crypts on the ventral aspect of the plate with hyperbolic shape, also known as "*la Sagrada Familia*" sign.

Exostosis

Subungual exostosis is an isolated, acquired, slow-growing, benign subungual osteochondral outgrowth of the dorsal part of the distal phalanx. It is considered by some to be a variant of an osteochondroma (35).

Subungual exostoses are seen most often in young adults and tend to be localized on the first right hallux. This reactive metaplasia is believed to be caused by either significant acute trauma, minor repeated chronic trauma, or chronic infection.

Clinically, it appears as an asymptomatic or painful subungual or periungual nodule that uplifts the nail and causes nail dystrophy and onycholysis. Dermoscopically, vascular ectasia is the most frequent finding, followed by hyperkeratosis, onycholysis, and ulceration. Subungual hyperkeratosis appears on dermoscopy as a well-delineated yellow spot that becomes more conspicuous when pressure is applied to the nail plate by pressing the dermatoscope's face-plate against the nail plate.

Inflammations/infections/traum a-induced/genetic pigmentations

Subungual hemorrhage

A subungual hemorrhage, also called subungual hematoma, is due to the presence of a collection of blood in the space between the nail bed and the nail plate. Subungual hemorrhage may result from an acute injury or repetitive minor trauma to the nail apparatus (Figures 11d.2, 11d.3). The most frequent digits involved are the thumb and the hallux.

Clinically, a subungual hemorrhage appears as well-circumscribed dots or blotches of red to maroon to black pigmentation. They can raise concern for melanoma clinically, but in these cases, dermoscopy can help differentiate a hemorrhage from a melanoma.

Dermoscopic examination of subungual hemorrhages may show several colors, with purple-black being the most frequent color. In the case of an acute injury, the colors change over time. In early lesions, the most common colors are pink, purple, and red, whereas, in older lesions, the colors are darker, including purple-black, red-black, and brown-black. The blood will migrate proximally as the nail plate grows (6, 10, 32, 36).

The most frequent dermoscopic features are homogeneous blotch or globules located proximally and a filamentous pattern located distally. The filamentous pattern is thought to result from blood moving distally via capillary action. It is important to note that subungual hemorrhage can be present in SUMs. Thus, when evaluating a subungual hemorrhage, it is imperative to evaluate the nail for the presence or absence of a pigmented nail band. In addition, the hyponychium and paronychial area should also be evaluated for the presence or absence of pigment. Subungual hemorrhage in the presence of a pigmented nail band or a Hutchinson's sign warrants a biopsy. In contrast, a subungual hemorrhage that is not associated with a pigmented nail band or a Hutchinson's sign does not need to be biopsied. The diagnosis of a subungual hemorrhage can be confirmed via follow-up, since the blood will slowly move distally with the growing nail and will eventually disappear.

Onychotillomania

In skin types IIIb, IV, and V, post-inflammatory or post-traumatic pigmentation of the skin is not uncommon. This phenomenon can also occur on the nails. This phenomenon is

exemplified by symmetrical pigmentation of the fifth toenail in women due to tight-fitting shoes. Self-inflicted repetitive trauma of the nail in onychotillomania may also cause longitudinal pigmentation. Dermoscopy in these cases will reveal a gray band.

Warts

Infection by human papillomavirus may lead to keratinocyte proliferation in the periungual or subungual region. Dermoscopy can help diagnose periungual warts based on the presence of thrombosed capillaries, which appear as black dots and short lines over a yellow structureless background. Warts located in the subungual region are impossible to differentiate from SCC.

Fungal infections

Nail fungal infections are common, and dermoscopy can help differentiate onychomycosis from traumatic onycholysis. A jagged proximal edge with spikes on the onycholytic area and longitudinal streaks are commonly seen in onychomycosis (Figure 11d.20). In contrast, a proximal linear edge without spikes is associated with traumatic onycholysis (1, 24).

Ethnic-type pigmentations

Ethnic pigmentation often involves multiple digits. Since it predominates on the right hand in right-handed patients and on the left hand in left-handed patients, it likely results from repetitive trauma-induced melanocytic activation. Dermoscopy will reveal a grayish pigmentation (36, 44).

Drug-induced pigmentation

Many drugs can induce pigmentation of the nail plate. Hydroxyurea, bleomycin, minocycline, and azidothymidine (AZT) are amongst the most common. Dermoscopic features are very similar to those observed in lentiginoses, with polydactylic gray longitudinal bands.

Alopecia areata

Alopecia areata is an autoimmune disorder characterized by transient, nonscarring hair loss and preservation of the hair follicle. Alopecia areata can be associated with trachyonychia, where the nail plate shows multiple fine and superficial longitudinal fissures covered by thin scales. In the "shiny" variety of trachyonychia, the nail shows superficial ridging and a myriad of small geometrical pits.

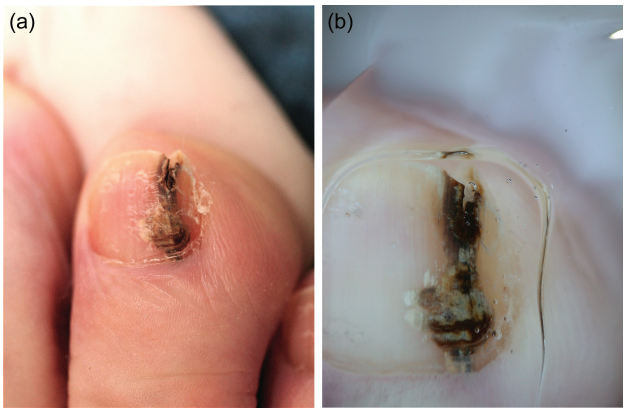

FIGURE 11D.20 (a) Clinical picture of a pigmented band on a nail. (b) Dermoscopy shows a homogeneous pigmentation without identifiable melanin granules in the nail plate. This image is consistent with a nail pigmentation of nonmelanocytic origin. In this case, the pigmentation was due to onychomycosis.

Lichen planus

Lichen planus can affect the nails. Nails are thinned and show longitudinal ridging and fissuring with distal splitting. Dermoscopy shows multiple deep longitudinal fissures reaching the distal part of the nail as well as the partial absence of the nail plate. Dermoscopy can be useful to follow up and evaluate treatment response (16, 29, 33).

Psoriasis

Nail psoriasis is usually associated with skin psoriasis. Pits consisting of punctate nail plate depressions can easily be seen with dermoscopy.

Which lesions should be biopsied?

Any lesion with an irregular dermoscopy pattern should be biopsied. The following situations should alert the physician to the possibility of malignancy (6, 34):

1. An isolated pigmented band on a single digit that develops during the fourth to sixth decade of life.
2. Nail pigmentation that develops abruptly in a previously normal nail plate.
3. Pigmentation that suddenly becomes darker or larger.
4. Acquired pigmentation of the thumb, index finger, or large toe.
5. Pigmentation that develops after a digital trauma and in which subungual hematoma has been ruled out.
6. Nail pigmentation associated with nail dystrophy, including partial nail destruction or absence of the nail plate.
7. If pigmentation of the periungual skin (including lateral nail folds) is found to be present (Hutchinson's sign). This includes pigmentation of the cuticle or the hyponychium.

Bibliography

1. Abdallah NA et al. Onychomycosis: Correlation between the dermoscopic patterns and fungal culture. *J Cosmet Dermatol*. Blackwell Publishing Ltd. 2020;19(5):1196–204. doi: 10.1111/jocd.13144.
2. Alessandrini A, Starace M, Piraccini BM. Dermoscopy in the evaluation of nail disorders. *Skin Append Disorders*. S. Karger AG, 2017: 70–82. doi: 10.1159/000458728.
3. Bhaskaranand K, Navadgi BC. Glomus tumour of the hand. *J Hand Surg*. Churchill Livingstone, 2002;27 B(3):229–31. doi: 10.1054/jhsb.2001.0746.
4. Boespflug A et al. Association of subungual melanoma and subungual squamous cell carcinoma: A case series, *J Am Acad Dermatol*. Mosby Inc. 2018;78(4):760–8. doi: 10.1016/j.jaad.2017.09.038.
5. Braun RP et al. Surgical Pearl: Dermoscopy of the free edge of the nail to determine the level of nail plate pigmentation and the location of its probable origin in the proximal or distal nail matrix. *J Am Acad Dermatol*. 2006;55(3):512–3. doi: 10.1016/j.jaad.2005.09.032.

6. Braun RP et al. Diagnosis and management of nail pigmentations. *J Am Acad Dermatol*. 2007:835–47. doi: 10.1016/j.jaad.2006.12.021.
7. Braun RP et al. Dermoscopy: what's new? *Clin Dermatol*. 2009;27(1):26–34. doi: 10.1016/j.clindermatol.2008.09.003.
8. Castro LGM et al. Guidelines of the Brazilian dermatology society for diagnosis, treatment and follow up of primary cutaneous melanoma - Part I. *Anais Brasileiros de Dermatologia*. Sociedade Brasileira de Dermatologia. 2015;90(6):851–61. doi: 10.1590/abd1806-4841.20154707.
9. Cinotti E et al. Imaging technique for the diagnosis of onychomatricoma. *J Eur Acad Dermatol Venereol*. Blackwell Publishing Ltd. 2018: 874–1878. doi: 10.1111/jdv.15108.
10. Deinlein T, Hofmann-Wellenhof R, Zalaudek I. Acral melanoma mimicking subungual hematoma, *J Am Acad Dermatol*. Mosby Inc. 2016;75(5):e181–e183. doi: 10.1016/j.jaad.2016.02.1222.
11. Duarte AF, Correia O, Barreiros HE Giant subungual glomus tumor: clinical, dermoscopy, imagiologic and surgery details, *Dermatol Online J*. 2016. Available at: https://pubmed.ncbi.nlm.nih.gov/28329592/ (Accessed: 5 April 2021).
12. Ginoux E et al. Intraoperative dermoscopic features of onychomatricoma: a review of 10 cases, *Clin Exp Dermatol*. Blackwell Publishing Ltd, 2017;42(4):395–9. doi: 10.1111/ced.13077.
13. Hirata SH et al. Dermoscopy of the nail bed and matrix to assess melanonychia striata. *J Am Acad Dermatol*. 2005;53(5):884–6. doi: 10.1016/j.jaad.2005.07.032.
14. Hirata SH et al. Dermoscopic examination of the nail bed and matrix. *Int J Dermatol*. 2006;45(1):28–30. doi: 10.1111/j.1365-4632.2004.02335.x.
15. Hirata SH et al. Patterns of nail matrix and bed of longitudinal melanonychia by intraoperative dermatoscopy. *J Am Acad Dermatol*. 2011;65(2): 297–303. doi: 10.1016/j.jaad.2010.06.009.
16. Iorizzo M, Rubin AI, Starace M. Nail lichen striatus: Is dermoscopy useful for the diagnosis? *Pediat Dermatol*. Blackwell Publishing Inc., 2019;36(6):859–63. doi: 10.1111/pde.13916.
17. Jaimes N, Marghoob AA. The morphologic universe of melanoma. *Dermatol Clin*. 2013:599–613. doi: 10.1016/j.det.2013.06.010.
18. Jellinek N. Nail matrix biopsy of longitudinal melanonychia: diagnostic algorithm including the matrix shave biopsy. *J Am Acad Dermatol*. 2007;56(5):803–10. doi: 10.1016/j.jaad.2006.12.001.
19. El Jouari O et al. A painless glomus tumor: A case report 11 Medical and Health Sciences 1103 Clinical Sciences. *J Med Case Rep*. BioMed Central Ltd. 2018;12(1). doi: 10.1186/s13256-018-1837-2.
20. Kok WL, Lee JSS, Chio MTW. Subungual squamous cell carcinoma: The diagnostic challenge and clinical pearls. *Case Rep Dermatol*. S. Karger AG. 2016;8(3):272–. doi: 10.1159/000449364.
21. Lazaridou E et al. Congenital nevus of the nail apparatus - Diagnostic approach of a case through dermoscopy. *Pediatr Dermatol*. 2013;30(6). doi: 10.1111/j.1525-1470.2012.01813.x.
22. Lee T, Jo G, Mun JH. The usefulness of nail plate and intraoperative dermoscopy in subungual glomus tumor. *Int J Dermatol*. Blackwell Publishing Ltd. 2018:e26–e28. doi: 10.1111/ijd.13888.
23. Lesort C et al. Dermoscopic features of onychomatricoma: a study of 34 cases. *Dermatology*. S. Karger AG. 2015;231(2):177–83. doi: 10.1159/000431315.
24. Maatouk I, Haber R, Benmehidi N. Onychoscopic evaluation of distal and lateral subungual onychomycosis: A cross-sectional study in Lebanon. *Curr Med Mycol*. Mazandaran University of Medical Sciences. 2019;5(2):41–4. doi: 10.18502/cmm.5.2.1161.
25. Maehara LDSN et al. Diagnóstico do tumor glômico pela dermatoscopia do leito e da matriz ungueal. *Anais Brasileiros de Dermatologia*. Sociedade Brasileira de Dermatologia. 2010;85(2):236–8. doi: 10.1590/S0365-05962010000200018.
26. De Magalhães Mariano Astur M et al. Reassessing melanonychia striata in phototypes IV, V, and VI patients. *Dermatol Surg*. Lippincott Williams and Wilkins. 2016;42(2):183–90. doi: 10.1097/DSS.0000000000000639.
27. Marchetti A et al. Dermoscopic features of onychomatricoma. *Ann Dermatol Venereol*. Elsevier Masson SAS. 2018;145(4):302–3. doi: 10.1016/j.annder.2018.01.004.
28. Minagawa A, Omodaka T, Okuyama R. Melanomas and mechanical stress points on the plantar surface of the foot. *N Eng J Med*. 2016;374(24):2404–6. doi: 10.1056/nejmc1512354.
29. Nakamura R et al. Dermatoscopy of nail lichen planus. *Int J Dermatol*. 2013;52(6):684–7. doi: 10.1111/j.1365-4632.2011.05283.x.
30. Nojima K et al. Pigmented squamous cell carcinoma of the right thumb: Longitudinal melanonychia and dermoscopic features. *Eur J Dermatol*. John Libbey Eurotext. 2017:561–3. doi: 10.1684/ejd.2017.3122.
31. Okon LG et al. A case of onychomatricoma: Classic clinical, dermoscopic, and nail-clipping histologic findings. *J Am Acad Dermatol*. Mosby Inc. 2017;76(2):S19–S21. doi: 10.1016/j.jaad.2016.04.041.
32. Oztas MO. Clinical and dermoscopic progression of subungual hematomas. *Int Surg*. no date;95(3):239–41. Available at: http://www.ncbi.nlm.nih.gov/pubmed/21067003 (Accessed: 13 November 2017).
33. Papageorgiou C et al. Atypical case of lichen planus recognized by dermoscopy. *Dermatol Pract Concept*. International Dermoscopy Society. 2016;6(4). doi: 10.5826/dpc.0604a09.
34. Phan A et al. Dermoscopic features of acral lentiginous melanoma in a large series of 110 cases in a white population. *Br J Dermatol*. Blackwell Publishing Ltd. 2010;162(4):765–71. doi: 10.1111/j.1365-2133.2009.09594.x.
35. Piccolo V et al. Dermoscopy of subungual exostosis: a retrospective study of 10 patients. *Dermatology*. S. Karger AG. 2017;233(1):80–5. doi: 10.1159/000471800.
36. Ronger S et al. Dermoscopic examination of nail pigmentation. *Arch Dermatol*. American Medical Association. 2002;138(10):1327–33. doi: 10.1001/archderm.138.10.1327.
37. Sawada M et al. Longterm digital monitoring in the diagnosis and management of congenital nevi of the nail apparatus showing pseudo-Hutchinson's sign, *Dermatol Pract Concept*. International Dermoscopy Society. 2014;4(2). doi: 10.5826/dpc.0402a07.
38. Sawada M et al. Proposed classification of longitudinal melanonychia based on clinical and dermoscopic criteria. *Int J Dermatol*. Blackwell Publishing Ltd. 2014;53(5):581–5. doi: 10.1111/ijd.12001.
39. Senhaji G et al. Rare tumor in unusual location - Glomus tumor of the finger pulp (clinical and dermoscopic features): A case report. *J Med Case Rep*. BioMed Central Ltd. 2018;12(1). doi: 10.1186/s13256-018-1721-0.
40. Skornšek N, Orešič Barač T, Marko PB Congenital longitudinal melanonychia: A case report. *Acta Dermatovenerologica Alpina, Pannonica et Adriatica*. Slovenian Medical Society. 2017;26(4):119–20. doi: 10.15570/actaapa.2017.34.
41. Tambe SA et al. Surgical management of onychopapilloma, onychomatricoma, and subungual osteochondroma: Case series. *J Cutan Aesth Surg*. Wolters Kluwer Medknow Publications. 2018;11(3):143–7. doi: 10.4103/JCAS.JCAS_72_18.
42. Teysseire S et al. Dermoscopic features of subungual squamous cell carcinoma: a study of 44 cases. *Dermatology*. S. Karger AG. 2017;233(2–3):184–91. doi: 10.1159/000479059.
43. Thomas L et al. Special locations dermoscopy. Facial, acral, and nail. *Dermatol Clin*. 2013:615–24. doi: 10.1016/j.det.2013.06.006.
44. Thomas L, Dalle S. Dermoscopy provides useful information for the management of melanonychia striata. *Dermatol Ther*. 2007;20(1):3–10. doi: 10.1111/j.1529-8019.2007.00106.x.
45. Tosti A et al. Clinical, dermoscopic, and pathologic features of onychopapilloma: A review of 47 cases. *J Am Acad Dermatol*. Mosby Inc. 2016;74(3):521–6. doi: 10.1016/j.jaad.2015.08.053.
46. Zalaudek I, Docimo G, Argenziano G. Using dermoscopic criteria and patient-related factors for the management of pigmented melanocytic nevi *Arch Dermatol*. 2009:816–26. doi: 10.1001/archdermatol.2009.115.

11E SPECIAL LOCATIONS: HAIR AND SCALP (TRICHOSCOPY)

Anna Waśkiel-Burnat, Lidia Rudnicka, Małgorzata Olszewska, Adriana Rakowska, Ralph M. Trüeb, and Isabel Kolm

Contents

Trichoscopy: Using the dermoscope for diagnosing hair and scalp disorders . . . 281
Patterns of scalp disease revealed by trichoscopy . . . 281
Follicular ostia . . . 281
Blood vessels . . . 283
Perifollicular and interfollicular skin surface . . . 284
Discoloration . . . 284
Scaling . . . 285
Hair shaft patterns . . . 286
Hair shaft disorders . . . 286
Exogenous materials on the scalp . . . 287
Nonscarring alopecia . . . 287
Scarring alopecia . . . 290
Inflammatory scalp diseases . . . 291
Algorithms in trichoscopy . . . 291
Possible application of in vivo reflectance confocal microscopy in diagnosing hair and scalp diseases . . . 291
Key points . . . 291
References . . . 291

Trichoscopy: Using the dermoscope for diagnosing hair and scalp disorders

The standard methods used to diagnose hair and scalp disorders include clinical inspection, pull test, trichoscopy, trichogram, and histopathology.[1–3]

Trichoscopy is a noninvasive diagnostic method, and studies have shown that the use of dermoscopy in the evaluation of hair and scalp disorders improves the diagnostic capability beyond simple clinical inspection.[4–14] Trichoscopy has gained popularity as a valuable tool in the diagnosis of hair and scalp disorders, in the evaluation of disease activity,[15–19] and in monitoring treatment efficacy.[20–22] Trichoscopy is also useful to guide the selection of the appropriate site for scalp biopsy.[23]

In clinical practice, trichoscopy can be performed with the use of a hand-held dermatoscope (10-fold magnification).[24] Videodermatoscopes, ranging from 20- to 1000-fold magnification, have the additional benefit of allowing more precise measurements of the visualized structures, such as hair shaft thickness, making them suitable for monitoring disease severity.[24, 25] Structures that are visualized by trichoscopy that are important in diagnosis include morphology of hair shafts, follicular openings, and perifollicular and interfollicular epidermis and cutaneous microvasculature.[26] Nonpolarized light trichoscopy may be performed with any interface solution, including 90% isopropanol, 70% ethanol, ultrasound gel, or water.[27] In some cases, it is beneficial to perform dry dermoscopy for improved visualization of the scale.[6]

The images presented in this chapter were taken with a Dermlite Foto device attached to a Canon G7 camera and Fotofinder using an alcohol solution as the immersion liquid.

Patterns of scalp disease revealed by trichoscopy

Follicular ostia

Follicular ostia encompass distinctive peripilar features that provide information relating to the condition of the hair follicle.

Empty follicles or empty follicular ostia (Figure 11e.1) may represent the physiologic interval of the hair cycle in which the hair follicle remains empty after the telogen hair has been extruded and before a new anagen hair emerges.[28, 29] This physiologic interval is called *lag phase* or *kenogen*, during which the hair follicle is in a state of physiological rest. The number of empty hair follicles is visibly increased in telogen effluvium, androgenic alopecia, and alopecia areata.

Yellow dots (Figure 11e.2) are characterized by an array of monomorphous, although variably sized, yellow to yellow-pink or yellow-brown, round or polycyclic dots that are devoid of hair or contain dystrophic or vellus hairs.[12] They may correspond to (dilated) follicular infundibula that contain sebaceous and/or keratinous material.[10] Yellow dots can be observed in different types of hair loss. Their structure, number, distribution, and location on the scalp may provide clues in establishing the correct diagnosis.

Regularly distributed yellow dots are typical trichoscopic findings of alopecia areata, observed in 6–100% (mean value: 62%) of cases.[12, 15, 30]. They predominate in chronic, nonactive disease, and their presence is considered a marker of disease severity.[10, 15, 30]

There are controversies regarding the presence and frequency of yellow dots in androgenetic alopecia. According

DOI: 10.1201/9780429487873-38



FIGURE 11E.1 Empty hair follicles. Other features seen in this image include the presence of coiled hairs and broken hairs. These features are indicative of trichotillomania.

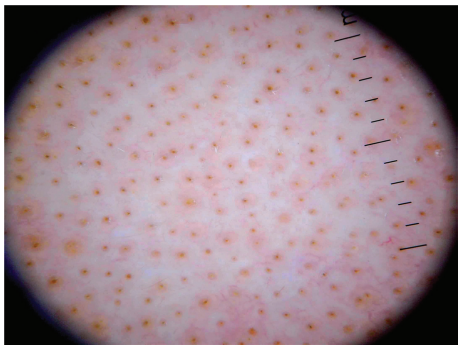

FIGURE 11E.2 Yellow dots. Multiple yellow, round structures devoid of hairs. Yellow dots in a regular distribution are characteristic of alopecia areata.

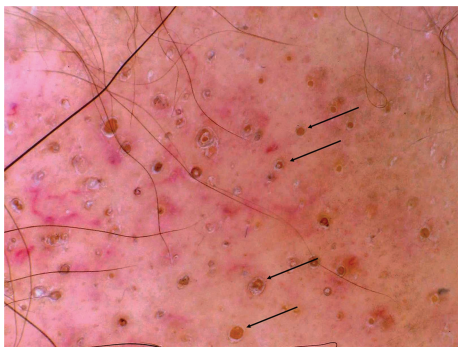

FIGURE 11E.3 Follicular keratosis (large yellow dots) in discoid lupus erythematosus.

to some studies, yellow dots are present in 8–66% of these patients.[12, 31] Yellow dots in androgenetic alopecia are usually homogeneously colored from light yellow to dark brown. They correspond to sebaceous material secreted by intact sebaceous glands associated with miniaturized hair follicles.[32] In androgenic alopecia, the number of yellow dots is significantly higher in the frontal area as compared with the occipital area. Rakowska et al.[33] evaluated the number of yellow dots in patients with female androgenetic alopecia and found $8.86 \pm 4.8/4$ yellow dots per field of vision (at 70-fold magnification) in the frontal area as compared with 1.59 ± 2.0 in the occipital area.[32]

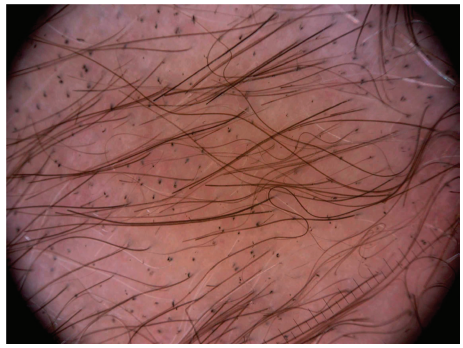

FIGURE 11E.4 Black dots are pigmented hair shafts that are broken or destroyed at the level of the scalp. Black dots are typically seen in active alopecia areata but may be present in other diseases, such as trichotillomania, lichen planopilaris, or monilethrix, among others.

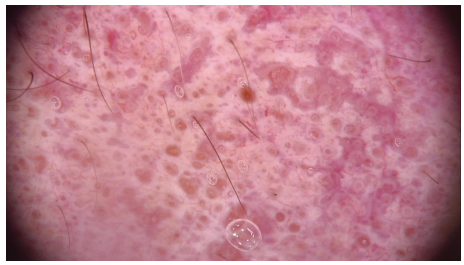

FIGURE 11E.5 Red dots in discoid lupus erythematosus. They correspond to widened infundibula surrounded by dilated vessels and extravasated erythrocytes. The follicle also tends to be plugged with keratotic material.

Large yellow dots (Figure 11e.3) are characteristic of discoid lupus erythematosus and folliculitis capitis abscedens and suphodiens.[34] They correspond to the accumulation of excessive keratin in hair follicles, leading to follicular plugging.

Yellow dots appearing as large three-dimensional soap bubbles in association with dark dystrophic hairs are specific for dissecting cellulitis.[34]

Sparse yellow dots may be observed in chronic telogen effluvium,[35, 36] congenital hypotrichoses,[8] traumatic alopecia,[36] traction alopecia,[37] and kerion celsi.[8]

Some clinicians prefer to calculate the number of empty hair follicles and yellow dots as one variable. The rationale behind this is that: (i) in the vast majority of cases, yellow dots represent empty hair follicles, and (ii) it may be difficult to distinguish an empty hair follicle from a yellow dot that is due to the presence of sebaceous or hyperkeratotic material in the infundibulum.

Black dots (Figure 11e.4), formerly called "cadaverized hairs," represent broken or destroyed pigmented hair shafts at the level of the scalp.[26] They are seen in acute alopecia areata, tinea capitis, trichotillomania, perifolliculitis abscedens et suffodiens of scalp, and anagen alopecia after chemotherapy.[26, 38] In alopecia areata, the presence of black dots is a marker of disease activity and is considered a negative prognostic marker.[16] Black dots are not present in healthy individuals, androgenic alopecia, or telogen effluvium.[38, 39]

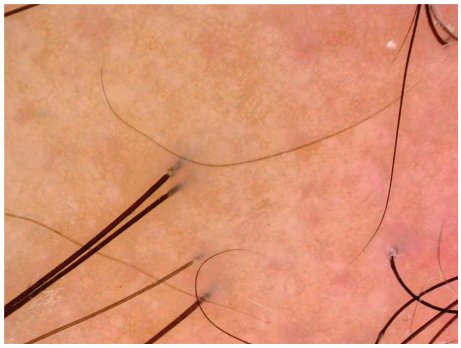

FIGURE 11E.6 White dots in scarring alopecia representing selective follicular destruction.



FIGURE 11E.7 Loss of follicular ostia in scarring alopecia. Note also the actinic damage of the skin.

Red dots (Figure 11e.5) correspond to widened infundibula surrounded by dilated vessels and extravasated erythrocytes and plugging with keratotic material.[40] They are characteristic of active discoid lupus erythematosus and considered as a positive prognostic factor.[34]

White dots (Figure 11e.6) and ***loss of follicular ostia*** (Figure 11e.7) are hallmarks of scarring alopecia (cicatricial alopecia).

For this to be recognizable, it is imperative to look for the contrast between the focal loss of melanin associated with the ostia and the adjacent pigmented epidermis. For this reason, visibility of white dots in primary scarring alopecia is less conspicuous in light-skinned (skin phototype I) individuals.

Two types of white dots have been identified: Classic white dots and pinpoint white dots. Classic white dots result from follicular/perifollicular fibrosis. They are usually over 200 μm in diameter and are evenly white in color with irregular borders. In advanced primary scarring alopecia, white dots become confluent to form areas lacking any follicular ostia. In some diseases that lead to scarring alopecia, such as discoid lupus erythematosus, the areas lacking follicular ostia may develop without the presence of white dots.

The second type of white dots is the pinpoint white dot. These pinpoint dots are small, regular white dots representing the eccrine sweat gland openings. While these pinpoint white dots are part of normal skin, are normally observed on sun-exposed areas, and are quite conspicuous in dark skin phototypes (Fitzpatrick skin phototypes V and VI),[26] they can also be observed in patients with frontal fibrosing alopecia, lichen planopilaris, alopecia areata, androgenetic alopecia, and central centrifugal cicatricial alopecia.[41]

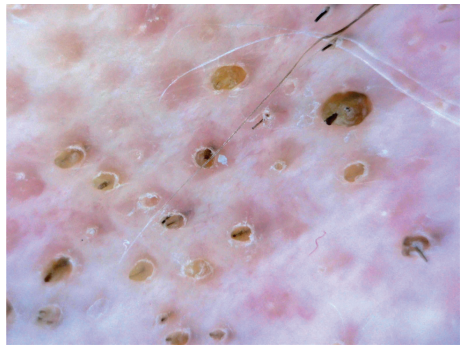

FIGURE 11E.8 Follicular mucinosis in a patient with folliculotropic mycosis fungoides (World Health Organization-European Organization for Research and Treatment of Cancer [WHO-EORTC] classification Stage IVa). Follicular plugs of mucin in dilated ostia.



FIGURE 11E.9 Follicular filiform spicules of monoclonal paraprotein casts associated with multiple myeloma.

Follicular mucinosis (Figure 11e.8) is an uncommon condition, presenting clinically as follicular papules or plaques with associated hair loss, most commonly on the face, neck, and scalp. Using trichoscopy, follicular mucin presents as follicular plugs of amorphous material in dilated follicular ostia. The disease may be primary (idiopathic) or secondary to mycosis fungoides and a number of other diseases.

Follicular filiform spicules (Figure 11e.9) represent another rare paraneoplastic phenomenon associated with multiple myeloma. The eruption is characterized by multiple hyperkeratotic spicules, usually on the face, nose, and scalp.[42]

Blood vessels

Vascular features reflect abnormalities in the skin capillary loop network observed in various conditions of the scalp.

Simple red loops (Figure 11e.10) are seen in normal epidermis, mainly in the occipital area. The pattern is characterized by multiple, fine, red hairpin-shaped structures that are regularly spaced.[43]

Dotted vessels (Figure 11e.11) are tiny red dots normally seen on the frontal area in normal skin.[44]

Arborizing vessels (Figures 11e.12, 11e.13) are characterized by tree-like terminal branching blood vessels. A few thin

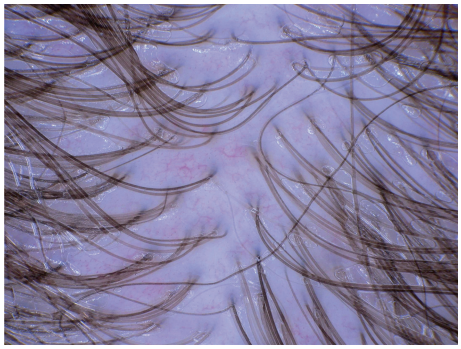

FIGURE 11E.10 Vascular pattern of simple red loops in normal epidermis.

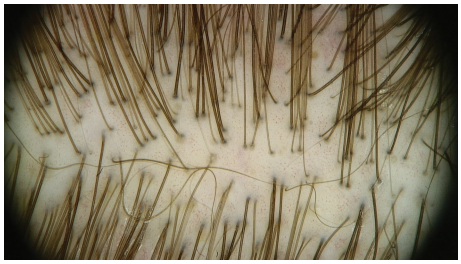

FIGURE 11E.11 Dotted vessels in the frontal area of the scalp in an individual with normal skin.

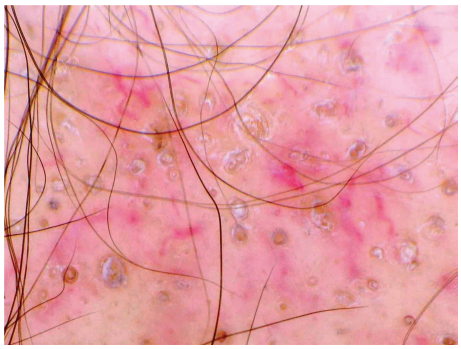

FIGURE 11E.12 Arborizing vessels in a patient with discoid lupus erythematosus. These vascular structures have a wider caliber than normal vascular loops.

arborizing vessels may be present in normal skin.[44] Multiple thin arborizing vessels are the hallmark of seborrheic dermatitis. Thick, focally arranged arborizing vessels are characteristic of discoid lupus erythematosus. This feature of discoid lupus erythematosus can lead to a misdiagnosis of basal cell carcinoma.[26, 45]

Twisted red loops are multiple, relatively evenly spaced, twisted loops in a homogeneous distribution—a feature of psoriasis (Figure 11e.14). Occasionally, twisted loops may be observed around affected follicles in folliculitis decalvans (Figure 11e.15).

Very thin or absent blood vessels may be observed in normal skin but are more common in patients with diseases associated with systemic vasoconstriction, such as hyperthyroidism or scleroderma.

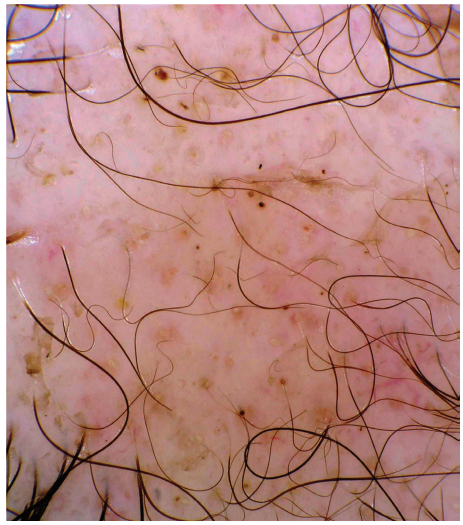

FIGURE 11E.13 A chronic scarred lesion of discoid lupus erythematosus. Absent vascular loops in the center of the lesion and arborizing vessels at the periphery, indicating peripheral disease activity.



FIGURE 11E.14 Twisted red loops in psoriasis with diffuse homogeneous distribution.

Perifollicular and interfollicular skin surface

Discoloration

Brown perifollicular discoloration (*"perifollicular hyperpigmentation," peripilar sign*) (Figure 11e.16) is characterized by the presence of a brown halo, roughly 1 mm in diameter, around the follicular ostium. This finding was initially linked to superficial perifollicular lymphocytic infiltrates in early androgenic alopecia.[12, 46] However, additional research showed that this is a nonspecific sign, present in various forms of hair loss and also in normal skin.[26, 33] In healthy females, the average number of follicular ostia with perifollicular discoloration

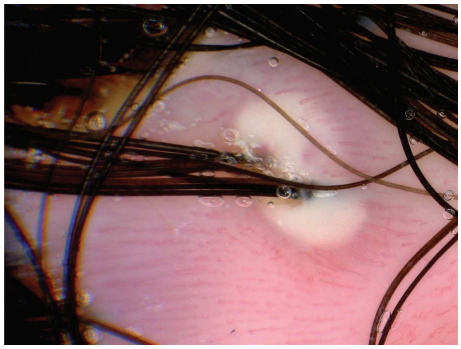

FIGURE 11E.15 Elongated vessels around affected follicles in a case of tufted folliculitis.



FIGURE 11E.16 Peripilar signs (brown perifollicular discoloration; *black arrow*) may be observed in androgenetic alopecia and telogen effluvium. In this patient with androgenetic alopecia, yellow dots and hair shaft thickness diversity are also observed.



FIGURE 11E.17 Honeycomb pigment pattern due to actinic damage of the scalp in a patient with hair loss.

is 4.6%, but it can be as high as 25%.[44] A high percentage of follicular ostia surrounded by a brown discoloration is considered, by some clinicians, to be a feature suggestive of active telogen effluvium or "complicated androgenic alopecia." When seen in telogen effluvium or androgenic alopecia, it portends a poor prognosis, since it is associated with accelerated hair loss within a few months following this trichoscopy finding.

The ***honeycomb pigment pattern*** (Figure 11e.17) on the scalp is characterized by homogeneous, mosaic, or contiguous brown rings. The honeycomb pattern is observed in normal skin with dark skin phototypes but is also common in persons

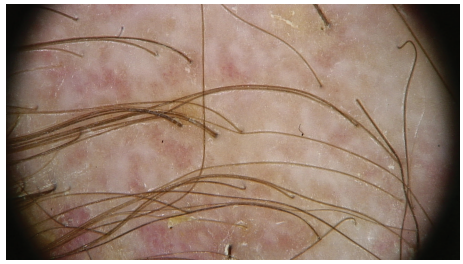

FIGURE 11E.18 Pink (milky-red) and white areas in a patient with lichen planopilaris. Pink areas correspond to early fibrosis and white areas to late fibrosis.



FIGURE 11E.19 White diffuse scaling in a patient with scalp psoriasis.



FIGURE 11E.20 Yellowish diffuse scaling in a patient with seborrheic dermatitis.

with lighter phototypes who have had excessive sun exposure on a scalp that has sparse to no hair. The distribution of this pattern is diffuse in bald scalp and multifocal when some hairs remain in the area.[12, 47, 48]

Pink (milky-red) areas (Figure 11e.18) are trichoscopic markers of early fibrosis in cicatricial alopecias,[34] while ***white areas*** (Figure 11e.18) correspond to the late fibrosing process.[34]

Scaling

There are two types of scaling: Perifollicular and diffuse.[43]

White diffuse scaling (Figure 11e.19) may be observed in psoriasis, discoid lupus erythematosus, and contact dermatitis. ***Yellowish diffuse scaling*** (Figure 11e.20) may be detected in seborrheic dermatitis, discoid lupus erythematosus, and ichthyosis.[43]

In normal skin that is dry (xerosis), mild, diffuse scaling may be observed.[43]

White perifollicular scaling is mainly observed in lichen planopilaris, while ***yellowish tubular scaling*** (Figure 11e.21)

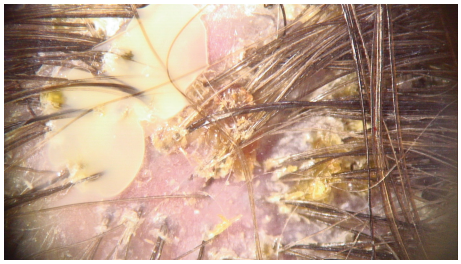

FIGURE 11E.21 Yellowish, perifollicular scaling in a patient with folliculitis decalvans.

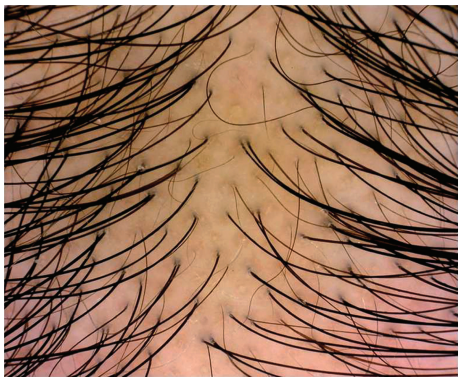

FIGURE 11E.22 Hair shaft thickness heterogeneity is a hallmark finding of androgenetic alopecia. Multiple hairs with different caliber are present. This finding is typical for progressive hair follicle miniaturization.

with collar formation is a characteristic trichoscopic feature of folliculitis decalvans.[43]

Scaling severity can be graded semi-quantitatively by trichoscopy from 0 to 4, where 0 stands for no scaling and 4 for severe scaling in the whole field of vision.[12, 26]

Hair shaft patterns

Hair shaft patterns reflect features that relate to the production and maintenance of the hair shaft. Hair shaft diameter, number of hairs in follicular units, and hair shaft abnormalities need to be evaluated.

Hair shaft diameter heterogeneity (Figure 11e.22) relates to the presence of hairs with increased variability of their caliber. This finding is typical of androgenetic alopecia and reflects the progressive hair follicle miniaturization associated with this condition.[33, 49]

In normal scalp skin, the number of hairs emerging from one follicular opening is between one and four.[44] ***Hair tufting*** refers to the emergence of several hair shafts from dilated follicular ostia. In tufted folliculitis, the number of hair shafts emerging from a follicular opening is significantly increased and ranges between 5 and 20 (Figure 11e.23)[50] In contrast, in androgenetic alopecia, there is a tendency to observe follicular units with one or two hairs instead of follicular units with three or four hairs[33] (Figure 11e.24).

Hair shaft abnormalities result from genetic conditions and/or exogenous factors affecting the integrity of the hair

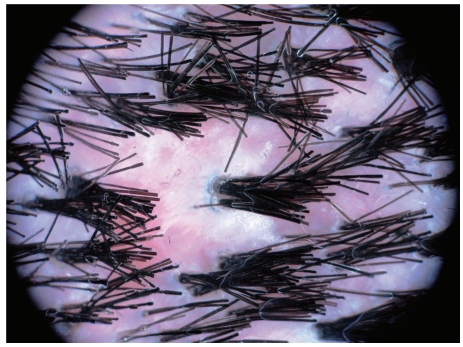

FIGURE 11E.23 Hair tufting. The emergence of several hair shafts together from one dilated ostium.



FIGURE 11E.24 Androgenetic alopecia with predominant follicular units with one hair.

shaft. Hair shaft abnormalities can occur as a localized or generalized disorder. Classic diagnosis is based on the microscopic examination of the hair shaft. Trichoscopy is an effective tool for a rapid diagnosis of both congenital and acquired hair shaft disorders. Hair shaft abnormalities that can be visualized by dermoscopy include *monilethrix*, *pili torti*, *pili canaliculi et trianguli*, *pili annulati*, *trichorrhexis invaginata*, *trichorrhexis nodosa*, and acquired features, such as micro-exclamation mark hairs, comma hairs, or vellus hairs.

Hair shaft disorders

Monilethrix is characterized by a beaded appearance of the hair due to periodic thinning of the shaft. This uncommon hereditary condition is transmitted as an autosomal dominant trait. The phenotype results in hair fragility and patchy dystrophic alopecia. Alopecia is more severe in the occipital and parietal regions, where there is more exposure to friction. Typically, the occipital scalp also presents with follicular keratosis. Trichoscopy reveals hair shafts with uniform elliptical nodes and intermittent constrictions.[51] Hairs are bent regularly at multiple locations and have a tendency to bend and fracture at constriction sites. The term "regularly bended ribbon sign" or "regularly twisted ribbon sign" was suggested for this specific trichoscopic feature of monilethrix.[52]

Pili torti is characterized by a hair that is flattened and twisted 180° on its axis at varying intervals. Additionally, the hair can be grooved and has also been termed ***pili torti et canaliculi.***[53] This hair shaft abnormality can be seen as an isolated hereditary trait and in a number of genetic syndromes, including Menkes kinky hair syndrome, Björnstad syndrome (with sensorineural deafness), and the ectodermal dysplasias. However, more commonly, it is found as *acquired pili torti*



FIGURE 11E.25 Pili torti in a patient with lichen planopilaris. Twisted hairs in an area of inflammatory and fibrotic changes.



FIGURE 11E.26 Trichorrhexis invaginata in Netherton syndrome.

around the edges of patches of cicatricial alopecia, particularly lichen planopilaris (Figure 11e.25), where local inflammatory and fibrosing processes distort the hair follicle. Trichoscopy of pili torti shows regular twists of the hair shaft along the long axis (seen at high magnification on videodermoscopy) and hair shafts bent at different angles at irregular intervals (seen with a hand-held dermoscope). Usually, only some of the hairs on the scalp and only a part of the hair shaft length are affected.[26, 51, 54]

Pili canaliculi et trianguli refers to the triangular hair shafts with longitudinal grooving underlying this uncombable hair syndrome. This feature can only be observed by videodermoscopy at higher magnification (50-fold and higher).

Pili annulati are defined by the characteristic alternating light and dark banding in the hair shaft due to air-filled spaces between the macro-fibrillar units of the hair cortex. Their significance lies in that the affected hairs are more susceptible to fragility, particularly in combination with androgenetic alopecia.[55]

Trichoscopy in patients with pili annulati demonstrates hair shafts with regular light bands, which correspond to dark cavities visible in microscopic examination (i.e., light or white color in trichoscopy correlates with dark in "light microscopy," while dark in trichoscopy correlates with light color in "light microscopy").[54]



FIGURE 11E.27 Trichorrhexis nodosa. Broken hairs with nodes along the hair shaft.

Trichorrhexis invaginata (Figure 11e.26), or bamboo hair, is the marker of Netherton syndrome, a rare autosomal recessive condition characterized by bamboo hair, ichthyosis, and atopic dermatitis. Trichoscopy shows characteristic bamboo hairs (nodes along the hair) and hairs with golf tee–type endings in the scalp hairs and eyebrows[54].

Trichorrhexis nodosa (Figure 11e.27) refers to white knots with transverse fractures along the hair shaft. Trichoscopy reveals brush-like hair fracturing. In general, trichorrhexis nodosa is a nonspecific finding related to excess external stress on the hair. While it may be seen in some genetic hair shaft disorders, it is most frequently a consequence of hair weathering.[51]

See Figure 11e.28 for schematics of hair shaft disorders.

Exogenous materials on the scalp

A variety of exogenous materials of different origins can be visualized by dermoscopy. These include hair dyes (Figure 11e.29), camouflage products (Figures 11e.30, 11e.31), residues from hair styling aids (Figure 11e.32),[56] and ectoparasites (Figure 11e.33).[57, 58] Camouflage products consist of dyes applied to the skin that make the scalp appear to have more hair than it actually does.

Nonscarring alopecia

Androgenetic alopecia is the most common reason for hair loss complaints in both women and men.[14, 59] Trichoscopic features of androgenetic alopecia are hair shaft thickness heterogeneity or diversity (anisotrichosis) (Figure 11e.22), brown perifollicular discoloration (peripilar signs) (Figure 11e.16), empty follicular openings (mainly observed as yellow dots) (Figures 11e.1, 11e.2), increased proportion of thin and vellus hairs, increased number of follicular units with one hair, and decreased number of follicular units with three hairs (Figure 11e.24).[33] In general, a predominant presence of these trichoscopic abnormalities in the frontal area compared with the occipital area is highly indicative of androgenetic alopecia.[32, 33]

Hair shaft thickness diversity is a good marker of androgenetic alopecia, particularly in women. A diversity of more



FIGURE 11E.28 Schematics of hair shafts under trichoscopy. (a) Hair shaft fractures (left to right): Trichoptilosis, trichoschisis/trichoclasis, irregular fractures as seen in mechanical force fractures, and "Golf tee" hair as seen in trichorrhexis invaginata. (b) Hair shaft narrowings (left to right): Monilethrix, monilethrix-like as seen in congenital hypotrichosis, monilethrix-like as seen in Pohl-Pinkus constriction, tapered hair, and exclamation mark hair. (c) Hair shafts with bands (left to right): Interrupted medulla, continuous medulla, pili annulati, interrupted/Morse code–like. (d) Twisted and curled hair shafts (left to right): (lower row) Z-hair/zigzag hair, pili torti, wooly hair, and corkscrew hair; (upper row) "Pigtail" hair as seen in regrowing hairs, coiled hair, and comma hair. (e) Short hair shafts (left to right): Upright regrowing hair, vellus hair, broom fibers, broom hair, flame hair. (From Rudnicka, L., et al., *Atlas of trichoscopy: dermoscopy in hair and scalp disease*. Springer, London, 2012. With permission.)



FIGURE 11E.29 Hair dyes in a patient with androgenetic alopecia. Brown structureless blotches on the scalp.



FIGURE 11E.30 Camouflage dye applied to the skin of the scalp.

than 20% is considered diagnostic for androgenetic alopecia; however, there is no standardized method to calculate the "percentage of diversity."[33]

Peripilar sign (brown perifollicular discoloration) is an early sign for androgenetic alopecia in females and males.[46] It corresponds to perifollicular lymphocytic infiltrates and may be considered as a negative prognostic marker.[60] A characteristic feature of the peripilar sign in androgenic alopecia is its predominance in the frontal scalp area.[32]

The presence of empty follicular openings is associated with the increased frequency and longer duration of kenogen phase observed in androgenetic alopecia. According to Olszewska et al.,[32] the predominance of irregularly distributed yellow dots in the frontal scalp area is an important criterion of female androgenic alopecia. In contrast, for Ross et al.,[12] this feature is of less importance in androgenetic alopecia.

Scalp pigmentation with a reticular (honeycomb) pigment pattern (Figure 11e.17) is eventually observed in patients with advanced androgenetic alopecia as a consequence of unprotected sun exposure.[12]

Androgenetic alopecia is often associated with pain or burning sensation of the scalp (trichodynia). In a series of 403 patients complaining of hair loss, the presence of telangiectasias, usually arborizing red blood vessels (Figure 11e.12), was strongly correlated with the presence of trichodynia.[61]

Androgenetic alopecia often co-exists with other diseases causing hair loss, especially telogen effluvium, and thus, features of both entities may be observed concomitantly.[26].

Alopecia areata is a common hair loss condition characterized by an acute onset of nonscarring hair loss, most commonly in sharply defined areas.



FIGURE 11E.31 Another type of camouflage product. This consists of exogenous pigment applied to the skin of the scalp to make it appear to have more hair than it actually does.



FIGURE 11E.32 Residues from hairspray. Multiple hairs glued together by this semi-translucent solution.

Trichoscopic features of alopecia areata consist of regularly distributed yellow dots, black dots, exclamation mark hairs, broken hairs, tapered hairs, short vellus hairs, upright regrowing hairs, and pigtail hairs.[12, 15, 30]

Exclamation mark hairs (exclamation point hairs or micro-exclamation mark hairs) (Figure 11e.34) are specific for active alopecia areata. They are short hairs with a thin proximal end and a thicker distal end.[26] In trichoscopy, 1–2-mm long exclamation mark-shaped hairs are observed. The exclamation point hairs seen with the unaided eye are typically 5 to 15 mm in length.[26]

Other trichoscopic findings of active alopecia areata include black dots (Figure 11e.4), broken hairs, and tapered hairs.

Yellow dots (Figure 11e.2) and short vellus hairs (Figure 11e.35) are the most common trichoscopic markers of alopecia areata.[30] They predominate in nonactive, long-standing disease. However, they can be seen in all stages of alopecia areata.

In alopecia areata, hair regrowth is characterized by the presence of upright regrowing hairs (Figures 11e.35, 11e.36) and pigtail hairs.



FIGURE 11E.33 Head louse (*Pediculus humanus capitis*) grasping hairs. The elongated body, structure of the head, and three pairs of clawed legs of this 1–2-mm large ectoparasite are visible (image taken with Fotofinder™ Trichoscan).

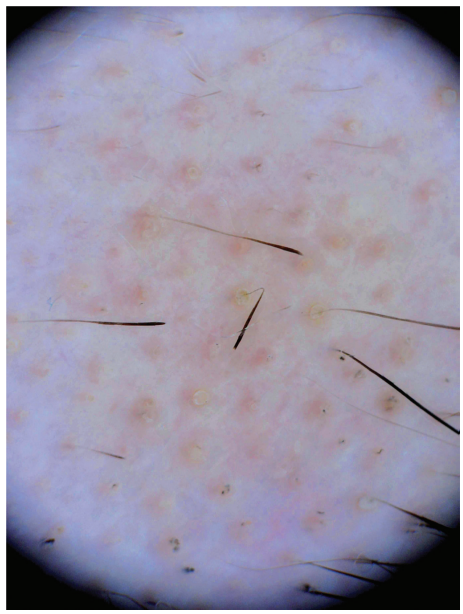

FIGURE 11E.34 Exclamation mark hairs in alopecia areata. Narrowing hair shafts toward the follicle ostia.

Alopecia areata incognita is an uncommon variety of alopecia areata characterized by rapid diffuse shedding of telogen hairs in the absence of typical discrete patches. Clinically, the disease has features of telogen effluvium, but hair loss is often more evident in the "androgen-dependent scalp area."[62, 63] Concomitant presence of yellow dots and short regrowing hairs seen in the terminal hair–bearing scalp is an important trichoscopic clue for the diagnosis.

The main pathology underlying alopecia areata incognita is controversial. According to Rakowska et al.,[39] concomitant presence of yellow dots, hair shaft thickness diversity, and thin regrowing hairs with predominant presence in the "androgen-dependent" scalp area is indicative of acute telogen effluvium developing in a person with mild, previously unrecognized androgenetic alopecia.

Trichotillomania is an impulsive control disorder characterized by a compulsive urge to pull out one's own hair, leading to noticeable hair loss. The most important differential diagnosis is alopecia areata. However, trichotillomania often co-exists

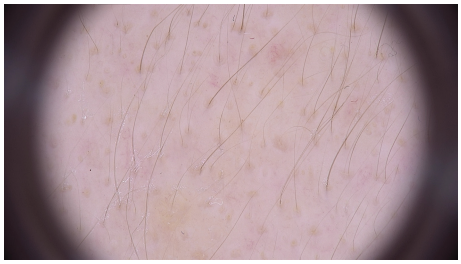

FIGURE 11E.35 Short, vellus hairs in patient and upright regrowing hairs in alopecia areata.



FIGURE 11E.36 Short upright regrowing hairs in alopecia areata.

with alopecia areata,[64] which may pose a special diagnostic challenge.

Trichoscopic features of trichotillomania include coiled hairs, flame hairs, V-sign, tulip hairs (Figure 11e.37), hairs broken at a different length, longitudinally split short hairs, black dots (Figure 11e.4), and hair powder .[65]

Scarring alopecia

Scarring alopecia is both a diagnostic and a therapeutic challenge to the practitioner. On the basis of histopathology findings, the scarring alopecias have been classified into the categories of primary scarring alopecia, where the hair follicle is the primary target of destruction, and secondary scarring alopecia, where the follicular damage results incidentally from events surrounding the hair and impinging on the follicular unit.[12 66]

In a retrospective study of scalp biopsies from patients with scarring alopecia, Trachsler and Trüeb[58] found that the most prevalent diagnoses in order of frequency were lichen planopilaris in 26%, lupus erythematosus in 21%, folliculitis decalvans in 20%, and pseudopelade in 10%. Scalp dermoscopy may be particularly helpful in differentiating these conditions.

Lichen planopilaris is the most common cause of scarring alopecia in adults. It presents with pruritic central or multifocal patches of alopecia, follicular hyperkeratosis, and erythema at the hair-bearing margin. Histopathology reveals a lymphocytic scarring alopecia. The Lassueur–Graham Little syndrome is considered a disseminated variant of lichen planopilaris, and frontal fibrosing alopecia[9] a pattern distribution variant of the disease.[67]

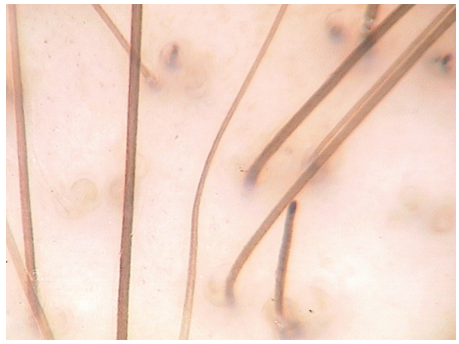

FIGURE 11E.37 Tulip hair in a patient with trichotillomania.

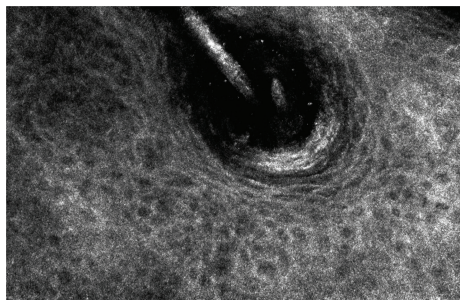

FIGURE 11E.38 A hair shaft emerging from a hair follicle visualized by reflectance confocal microscopy.

Trichoscopic features of lichen planopilaris include white perifollicular scaling, white dots (Figure 11e.6), loss of follicular ostia (Figure 11e.7), acquired pili torti (Figure 11e.25), and perifollicular erythema.[34, 68]

Discoid lupus erythematosus (chronic cutaneous lupus erythematosus) presents as erythematous scaly plaques with follicular plugs, telangiectasias, and progressive central scarring. Histopathology reveals a lymphocytic scarring alopecia. Trichoscopic features of discoid lupus erythematosus include loss of follicular ostia, thick arborizing vessels (Figures11e.12, 11e.13), follicular keratotic plugs (big yellow dots) (Figure 11e.3), and scalp atrophy, occasionally with effaced or absent vascular loops (Figure 11e.14).[34]

Folliculitis decalvans represents chronic and recurrent pustule-follicular scalp inflammation resulting in scarring alopecia. It usually presents in the central scalp area with exudative crusted areas and grouped follicular pustules at the hair-bearing margin with centrifugal progression. Histopathology reveals a neutrophilic scarring alopecia.[66] Trichoscopic features of folliculitis decalvans include severe scaling and crusting, pronounced hair tufting (Figure 11e.23), follicular pustules (Figure11e.15), numerous coiled capillary loops (Figure 11e.15), loss of follicular ostia, and white dots.[34]

Dissecting cellulitis of the scalp presents as multiple firm, dome-shaped papules, which may coalesce to form plaques and nodules.[69] Abscesses and sinus tracts may also be observed. The vertex and occipital area are most commonly affected. The disease is predominantly detected in men of African descent between 20 and 40 years of age. It may occur in association with acne conglobata, hidradenitis suppurativa (follicular occlusion triad), and pilonidal cysts (follicular occlusion tetrad).[69, 70]

Histopathology reveals a neutrophilic scarring alopecia. Trichoscopic findings of dissecting cellulitis include yellow structureless areas and yellow dots with three-dimensional yellow dots, black dots, and perifollicular pustules.[34]

Pseudopelade was first described by Brocq in 1888 as asymptomatic, noninflamed, ivory-white or flesh-colored small, oval-round, reticulate or large, irregular patches of the central scalp area. It is considered a lymphocytic scarring alopecia with selective destruction of hair follicles. It is clinically and histologically indistinguishable from end-stage scarring alopecia of any origin. A distinction must be made from the *pseudopeladic state of Degos*, which represents the nonspecific common end-stage of 60 different etiologies.[14, 71]

Trichoscopic features of classic pseudopelade of Brocq are nonspecific, including loss of follicular ostia and occasionally, white dots (Figure 11e.6). Thus, clinically and by trichoscopy, pseudopelade of Brocq remains a diagnosis of exclusion.[34].

Inflammatory scalp diseases

Tinea capitis is mainly caused by *Microsporum* and *Trichophyton* species.[72] Clinically, tinea capitis is characterized by the presence of hair loss areas with coexistent scaling, inflammation, or pustules.[73] In trichoscopy, comma hairs, corkscrew hairs, Morse code-–like hairs, zigzag hairs, bent hairs, block hairs, or i-hairs are the most common.[65, 74] (See Figure 11e.28.)

Algorithms in trichoscopy

As a significant amount of data is accumulating on the differential diagnoses of hair loss with trichoscopy, algorithms are being developed to simplify differential diagnoses in clinical practice. For example, according to Rakowska et al.,[33] female androgenic alopecia may be differentiated from chronic telogen effluvium based on the following major and minor trichoscopic criteria. Major criteria include (i) more than four yellow dots in four images (70-fold magnification) in the frontal area, (ii) lower average hair thickness in the frontal area compared with the occiput, and (iii) more than 10% of thin hairs (below 0.03 mm) in the frontal area. Minor criteria encompass increased frontal to occipital ratio of (i) single-hair pilosebaceous units, (ii) vellus hairs, and (iii) perifollicular discoloration. According to the authors' evaluation, the fulfillment of two major criteria or one major and two minor criteria is suggestive of female androgenic alopecia based on trichoscopy with a 98% specificity.[32] Inui[8] proposed a simplified algorithm to diagnose the most common diseases causing hair loss.

Possible application of in vivo reflectance confocal microscopy in diagnosing hair and scalp diseases

In vivo reflectance confocal microscopy (RCM) is a new imaging technique, which is gaining popularity in the differential diagnosis of skin cancers and inflammatory skin diseases.[75] Attempts to employ this method in diagnosing hair loss are promising.[38] RCM allows visualization, with high precision, of most features known from trichoscopy in common hair diseases, such as alopecia areata or androgenetic alopecia.[38] Figure 11e.38 shows an RCM image of a hair shaft emerging from a hair follicle.

Key points

- Hair and scalp dermoscopy or trichoscopy is helpful for the diagnosis of hair and scalp disorders. It can also give clues about the disease stage and progression.
- Structures that may be visualized by trichoscopy include hair shafts of different types (terminal, vellus, and hair shaft dystrophies), follicular ostia (empty hair follicles and yellow, black, and white dots), vascular patterns, abnormalities of pigmentation, scaling, and exogenous materials. A single structure is rarely sufficient for diagnosis. Usually, a disease may be suspected or diagnosed based on a combination of different structures co-existing in one patient.

References

1. Mubki T, Rudnicka L, Olszewska M, Shapiro J. Evaluation and diagnosis of the hair loss patient: part I. History and clinical examination. *J Am Acad Dermatol*. 2014;71:415 e1–15 e15.
2. Mubki T, Rudnicka L, Olszewska M, Shapiro J. Evaluation and diagnosis of the hair loss patient: part II. Trichoscopic and laboratory evaluations. *J Am Acad Dermatol*. 2014;71:431 e1–31 e11.
3. Wolff H, Fischer TW, Blume-Peytavi U. The Diagnosis and Treatment of Hair and Scalp Diseases. *Dtsch Arztebl Int*. 2016;113:377–86.
4. Lacarrubba F, Micali G, Tosti A. Scalp dermoscopy or trichoscopy. *Curr Probl Dermatol*. 2015;47:21–32.
5. Rudnicka L, Olszewska M, Rakowska A, Kowalska-Oledzka E, Slowinska M. Trichoscopy: a new method for diagnosing hair loss. *J Drugs Dermatol*. 2008;7:651–4.
6. Inui S, Nakajima T, Itami S. Dry dermoscopy in clinical treatment of alopecia areata. *J Dermatol*. 2007;34:635–9.
7. Inui S, Nakajima T, Shono F, Itami S. Dermoscopic findings in frontal fibrosing alopecia: report of four cases. *Int J Dermatol*. 2008;47:796–9.
8. Inui S. Trichoscopy for common hair loss diseases: algorithmic method for diagnosis. *J Dermatol*. 2011;38:71–5.
9. Kossard S, Zagarella S. Spotted cicatricial alopecia in dark skin. A dermoscopic clue to fibrous tracts. *Australas J Dermatol*. 1993;34:49–51.
10. Lacarrubba F, Dall'Oglio F, Rita Nasca M, Micali G. Videodermatoscopy enhances diagnostic capability in some forms of hair loss. *Am J Clin Dermatol*. 2004;5:205–8.
11. Olszewska M, Rudnicka L, Rakowska A, Kowalska-Oledzka E, Slowinska M. Trichoscopy. *Arch Dermatol*. 2008;144:1007.
12. Ross EK, Vincenzi C, Tosti A. Videodermoscopy in the evaluation of hair and scalp disorders. *J Am Acad Dermatol*. 2006;55:799–806.
13. Toncic RJ, Lipozencic J, Pastar Z. Videodermoscopy in the evaluation of hair and scalp disorders. *Acta Dermatovenerol Croat*. 2007;15:116–8.
14. Trueb RM. Systematic approach to hair loss in women. *J Dtsch Dermatol Ges*. 2010;8:284–97, 84–98.
15. Inui S, Nakajima T, Nakagawa K, Itami S. Clinical significance of dermoscopy in alopecia areata: analysis of 300 cases. *Int J Dermatol*. 2008;47:688–93.
16. Inui S, Nakajima T, Itami S. Coudability hairs: a revisited sign of alopecia areata assessed by trichoscopy. *Clin Exp Dermatol*. 2010;35:361–5.
17. Guttikonda AS, Aruna C, Ramamurthy DV, Sridevi K, Alagappan SK. Evaluation of Clinical Significance of Dermoscopy in Alopecia Areata. *Indian J Dermatol*. 2016;61:628–33.
18. Toledo-Pastrana T, Hernandez MJ, Camacho Martinez FM. Perifollicular erythema as a trichoscopy sign of progression in frontal fibrosing alopecia. *Int J Trichology*. 2013;5:151–3.
19. Verzi AE, Lacarrubba F, Micali G. Heterogeneity of trichoscopy findings in dissecting cellulitis of the scalp: correlation with disease activity and duration. *Br J Dermatol*. 2017;177:e331–e32.
20. Campos S, Brasileiro A, Galhardas C, et al. Follow-up of tinea capitis with trichoscopy: a prospective clinical study. *J Eur Acad Dermatol Venereol*. 2017;31:e478–e80.

21. Ganjoo S, Thappa DM. Dermoscopic evaluation of therapeutic response to an intralesional corticosteroid in the treatment of alopecia areata. *Indian J Dermatol Venereol Leprol*. 2013;79:408–17.
22. Lacarrubba F, Micali G, Tosti A. Absence of vellus hair in the hairline: a videodermatoscopic feature of frontal fibrosing alopecia. *Br J Dermatol*. 2013;169:473–4.
23. Miteva M, Tosti A. Dermoscopy guided scalp biopsy in cicatricial alopecia. *J Eur Acad Dermatol Venereol*. 2013;27:1299–303.
24. Tosti A, Torres F. Dermoscopy in the diagnosis of hair and scalp disorders. *Actas Dermosifiliogr*. 2009;100(Suppl 1):114–9.
25. Olszewska M, Rudnicka L. Effective treatment of female androgenic alopecia with dutasteride. *J Drugs Dermatol*. 2005;4:637–40.
26. Rudnicka L, Olszewska M, Rakowska A, Slowinska M. Trichoscopy update 2011. *J Dermatol Case Rep*. 2011;5:82–8.
27. Gewirtzman AJ, Saurat JH, Braun RP. An evaluation of dermoscopy fluids and application techniques. *Br J Dermatol*. 2003;149:59–63.
28. Rebora A, Kenogen GM. A new phase of the hair cycle? *Dermatology*. 2002;205:108–10.
29. Guarrera M, Rebora A. Kenogen in female androgenetic alopecia. A longitudinal study. *Dermatology*. 2005;210:18–20.
30. Waskiel A, Rakowska A, Sikora M, Olszewska M, Rudnicka L. Trichoscopy of alopecia areata: an update. *J Dermatol*. 2018;45:692–700.
31. Numerous faces of yellow dots. *J Am Acad Dermatol*. 2009;60: AB98.
32. Olszewska M, Warszawik O, Rakowska A, Slowinska M, Rudnicka L. Methods of hair loss evaluation in patients with endocrine disorders. *Endokrynol Pol*. 2010;61:406–11.
33. Rakowska A, Slowinska M, Kowalska-Oledzka E, Olszewska M, Rudnicka L. Dermoscopy in female androgenic alopecia: method standardization and diagnostic criteria. *Int J Trichology*. 2009;1:123–30.
34. Rakowska A, Slowinska M, Kowalska-Oledzka E, et al. Trichoscopy of cicatricial alopecia. *J Drugs Dermatol*. 2012;11:753–8.
35. Karadag Kose O, Gulec AT. Clinical evaluation of alopecias using a handheld dermatoscope. *J Am Acad Dermatol*. 2012;67:206–14.
36. Park J, Kim JI, Kim HU, Yun SK, Kim SJ. Trichoscopic Findings of Hair Loss in Koreans. *Ann Dermatol*. 2015;27:539–50.
37. Shim WH, Jwa SW, Song M, et al. Dermoscopic approach to a small round to oval hairless patch on the scalp. *Ann Dermatol*. 2014;26:214–20.
38. Rudnicka L, Olszewska M, Rakowska A. In vivo reflectance confocal microscopy: usefulness for diagnosing hair diseases. *J Dermatol Case Rep*. 2008;2:55–9.
39. Rakowska A, Slowinska M, Kowalska-Oledzka E, Olszewska M, Czuwara J, Rudnicka L. Alopecia areata incognita: true or false? *J Am Acad Dermatol*. 2009;60:162–3.
40. Tosti A, Torres F, Misciali C, et al. Follicular red dots: a novel dermoscopic pattern observed in scalp discoid lupus erythematosus. *Arch Dermatol*. 2009;145:1406–9.
41. Abraham LS, Pineiro-Maceira J, Duque-Estrada B, Barcaui CB, Sodre CT. Pinpoint white dots in the scalp: dermoscopic and histopathologic correlation. *J Am Acad Dermatol*. 2010;63:721–2.
42. Braun RP, Skaria AM, Saurat JH, Borradori L. Multiple hyperkeratotic spicules and myeloma. *Dermatology*. 2002;205:210–2.
43. Rudnicka L, Olszewska M, Rakowska A. *Atlas of trichoscopy: dermoscopy in hair and scalp disease*. London: Springer; 2012.
44. Rakowska A. Trichoscopy (hair and scalp videodermoscopy) in the healthy female. Method standardization and norms for measurable parameters. *J Dermatol Case Rep*. 2009;3:14–9.
45. Duque-Estrada B, Tamler C, Sodre CT, Barcaui CB, Pereira FB. Dermoscopy patterns of cicatricial alopecia resulting from discoid lupus erythematosus and lichen planopilaris. *An Bras Dermatol*. 2010;85:179–83.
46. Deloche C, de Lacharriere O, Misciali C, et al. Histological features of peripilar signs associated with androgenetic alopecia. *Arch Dermatol Res*. 2004;295:422–8.
47. Miteva M, Tosti A. Hair and scalp dermatoscopy. *J Am Acad Dermatol*. 2012;67:1040–8.
48. de Moura LH, Duque-Estrada B, Abraham LS, Barcaui CB, Sodre CT. Dermoscopy findings of alopecia areata in an African-American patient. *J Dermatol Case Rep*. 2008;2:52–4.
49. de Lacharriere O, Deloche C, Misciali C, et al. Hair diameter diversity: a clinical sign reflecting the follicle miniaturization. *Arch Dermatol*. 2001;137:641–6.
50. Fernandes JC, Correia TM, Azevedo F, Mesquita-Guimaraes J. Tufted hair folliculitis after scalp injury. *Cutis*. 2001;67:243–5.
51. Rudnicka L, Olszewska M, Waskiel A, Rakowska A. Trichoscopy in Hair Shaft Disorders. *Dermatol Clin*. 2018;36:421–30.
52. Rakowska A, Slowinska M, Czuwara J, Olszewska M, Rudnicka L. Dermoscopy as a tool for rapid diagnosis of monilethrix. *J Drugs Dermatol*. 2007;6:222–4.
53. Trueb RM, Tsambaos D, Spycher MA, Muller J, Burg G. Scarring folliculitis in the ectrodactyly-ectodermal dysplasia-clefting syndrome. Histologic, scanning electron-microscopic and biophysical studies of hair. *Dermatology*. 1997;194:191–4.
54. Rakowska A, Kowalska-Oledzka E, Slowinska M, Rosinska D, Rudnicka L. Hair shaft videodermoscopy in netherton syndrome. *Pediatr Dermatol*. 2009;26:320–2.
55. Hofbauer GF, Tsambaos D, Spycher MA, Trueb RM. Acquired hair fragility in pili anulati: causal relationship with androgenetic alopecia. *Dermatology*. 2001;203:60–2.
56. Itin PH, Schiller P, Mathys D, Guggenheim R. Cosmetically induced hair beads. *J Am Acad Dermatol*. 1997;36:260–1.
57. Di Stefani A, Hofmann-Wellenhof R, Zalaudek I. Dermoscopy for diagnosis and treatment monitoring of pediculosis capitis. *J Am Acad Dermatol*. 2006;54:909–11.
58. Trachsler S, Trueb RM. Value of direct immunofluorescence for differential diagnosis of cicatricial alopecia. *Dermatology*. 2005;211:98–102.
59. Trueb RM. Is androgenetic alopecia a photoaggravated dermatosis? *Dermatology*. 2003;207:343–8.
60. Brzezińska-Wcisło L, Rakowska A, Rudnicka L, et al. Łysienie androgenowe kobiet i mężczyzn. Rekomendacje diagnostyczno-terapeutyczne Polskiego Towarzystwa Dermatologicznego. *Dermatology Review/Przegląd Dermatologiczny*. 2018;105:1–18.
61. Willimann B, Trueb RM. Hair pain (trichodynia): frequency and relationship to hair loss and patient gender. *Dermatology*. 2002;205:374–7.
62. Rebora A. Alopecia areata incognita: a hypothesis. *Dermatologica*. 1987;174:214–8.
63. Tosti A, Whiting D, Iorizzo M, et al. The role of scalp dermoscopy in the diagnosis of alopecia areata incognita. *J Am Acad Dermatol*. 2008;59:64–7.
64. Trueb RM, Cavegn B. Trichotillomania in connection with alopecia areata. *Cutis*. 1996;58:67–70.
65. Rakowska A, Slowinska M, Olszewska M, Rudnicka L. New trichoscopy findings in trichotillomania: flame hairs, V-sign, hook hairs, hair powder, tulip hairs. *Acta Derm Venereol*. 2014;94:303–6.
66. Stefanato CM. Histopathology of alopecia: a clinicopathological approach to diagnosis. *Histopathology*. 2010;56:24–38.
67. Zinkernagel MS, Trueb RM. Fibrosing alopecia in a pattern distribution: patterned lichen planopilaris or androgenetic alopecia with a lichenoid tissue reaction pattern? *Arch Dermatol*. 2000;136:205–11.
68. Waśkiel A, Rakowska A, Sikora M, Olszewska M, Rudnicka L. Trichoscopy in lichen planopilaris: an update. Dermatology Review/*Przegląd Dermatologiczny*. 2018;105:63–75.
69. Kanti V, Rowert-Huber J, Vogt A, Blume-Peytavi U. Cicatricial alopecia. *J Dtsch Dermatol Ges*. 2018;16:435–61.
70. Fanti PA, Baraldi C, Misciali C, Piraccini BM. Cicatricial alopecia. *G Ital Dermatol Venereol*. 2018;153:230–42.

71. Degos R, Rabut R, Hewitt J. [Pseudo-peladic state caused by alopecic carcinomatous metastases]. *Bull Soc Fr Dermatol Syphiligr*. 1954;61:509–10.
72. Gupta AK, Mays RR, Versteeg SG, et al. Tinea capitis in children: a systematic review of management. *J Eur Acad Dermatol Venereol*. 2018;32:2264–74.
73. Adesiji YO, Omolade FB, Aderibigbe IA, et al. Prevalence of Tinea Capitis among Children in Osogbo, Nigeria, and the Associated Risk Factors. *Diseases*. 2019;7.
74. Slowinska M, Rudnicka L, Schwartz RA, et al. Comma hairs: a dermatoscopic marker for tinea capitis: a rapid diagnostic method. *J Am Acad Dermatol*. 2008;59(Supplement):S77–9.
75. Kolm I, Kamarashev J, Kerl K, et al. Acral melanoma with network pattern: a dermoscopy-reflectance confocal microscopy and histopathology correlation. *Dermatol Surg*. 2010;36:701–3.

12A DERMOSCOPY IN GENERAL DERMATOLOGY: INFECTIOUS DISEASES

Iris Zalaudek, Nicola di Meo, and Paola Corneli

Contents

Introduction: Entomodermoscopy, a new tool for the diagnosis of infectious diseases . . . 294
Viral diseases . . . 294
Molluscum contagiosum . . . 294
Cutaneous warts . . . 294
Ectoparasitic diseases . . . 294
Scabies . . . 294
Lice infestations . . . 294
Tick bites . . . 295
Tungiasis . . . 296
Cutaneous larva migrans . . . 297
Fungal diseases . . . 297
Tinea nigra . . . 297
Tinea corporis and vellus hair . . . 297
Key points . . . 297
References . . . 297

Introduction: Entomodermoscopy, a new tool for the diagnosis of infectious diseases

The term "entomodermoscopy" originates from the words "entomology" and "dermoscopy" and has been introduced to describe the use of dermoscopy in the diagnosis of infectious skin disorders.[1] This instrument has enabled clinicians to effortlessly and rapidly view any skin condition, leading to observations that link particular dermoscopic morphologies with specific skin diseases.[2] Dermoscopy patterns have been described for a number of viral, bacterial, fungal, and ectoparasitic skin infections (Table 12a.1). Clinical information, including history, clinical and histopathologic findings, and laboratory results, are important and need to be integrated with the dermoscopic findings.

Viral diseases

Molluscum contagiosum

Molluscum contagiosum (MC) is a common viral infection caused by a contagious human-specific poxvirus. Dermoscopically, MC displays a central pore or umbilication in association with polylobular white to yellowish amorphous structures, which are typically surrounded by linear, fine, and blurred telangiectasias ("corona"-like vessels, also known as crown vessels) (Figure 12a.1a, b)[3, 4]. In addition to crown vessels, other vascular patterns have been identified, including radial and punctiform patterns, which can present with inflammation or excoriations.[5]

Cutaneous warts

Cutaneous warts are due to human papillomavirus. On close examination, one can appreciate disruption of dermatoglyphics or skin marking, as well as thrombosed capillaries. Warts can sometimes be difficult to distinguish from other cutaneous lesions, such as callus, corn, or even melanoma.[6] Under dermoscopy, *verruca vulgaris* displays a mosaic pattern, defined as "multiple densely packed papilla, each containing a central red or black dot or loop, which is surrounded by a whitish halo"[7, 8] (Figure 12a.2 a, b). The red and black dots and loops represent normal and thrombosed capillaries, respectively. *Plantar warts* show verrucous, yellowish, structureless areas with an irregular distribution of black dots or streaks corresponding to thrombosed vessels and microhemorrhages due to pressure effects on the sole. In contrast, calluses demonstrate homogeneous opacities, and corns exhibit a translucent central core.[9]

Ectoparasitic diseases

Scabies

Scabies is caused by the mite *Sarcoptes scabiei* var. *hominis* (Figure 12a.3 a). Dermoscopic findings may rapidly provide the diagnosis of scabies without the need for multiple skin scrapings. The dermoscopic patterns of scabies are particularly well observable on the lateral sites of the fingers, toes, palms, and soles, as well as around the mamilla, umbilicus, or genital areas. Placing the dermatoscope over the end of a suspected burrow often reveals a small, dark-brown, delta-shaped structure, representing the anterior body of the adult female mite (her mouth and two front legs); this shape is metaphorically reminiscent of a "jet airplane"[10–15] (Figure 12a.3 b, c). Trailing the delta-shaped structure is a thin tract of whitish scale, representing the burrow, which is reminiscent of a whitish condensation trail (contrail) following the delta-shaped "jet." The posterior part of the mite is usually translucent and often not visible. The "contrail" is caused by the mite's burrow in the skin, which may sometimes contain feces, appearing as small brown dots.

Lice infestations

Pediculus humanis capitis and *Phthirus pubis* are worldwide ectoparasites causing thousands of infestations per year. Dermoscopy allows rapid and reliable diagnosis, permitting the identification of the louse or the nits fixed to the hair shaft, and is useful in monitoring treatment effectiveness.[16, 17] The identification of cemented nits (eggs) located within 1–2 mm from the scalp's surface suggests active pediculosis infestation. Although the adult louse can be elusive and difficult to find, the diagnosis can be confirmed by simply identifying nits on the hair shaft

TABLE 12A.1: Dermoscopic Patterns Associated with Skin Infections and Infestations

	Diagnosis	Dermoscopy pattern	References
Viral	Facial-plane warts	Dotted vessels regularly distributed over a brown to flesh-colored background, often intermingled by whitish lines.	Zalaudek et al., 2008 (1)
	Common warts	Frogspawn pattern. Looped or dotted vessels within papillae that are typically whitish.	Teoli et al., 2006 (33); Vázquez-López et al., 2004 (34)
	Palmo-plantar warts	Yellowish structureless pattern typically with brownish to reddish lines or dots, corresponding to hemorrhages.	Dalmau et al., 2006 (8); Kim et al., 2006 (9)
	Genital warts	Whitish reticulation.	Zalaudek et al., 2008 (1)
	Molluscum contagiosum	Polylobular whitish structureless areas in the center surrounded by elongated blurred telangiectasias.	Morales et al., 2005 (3); Zaballos et al., 2006 (4)
Fungal	Tinea corporis	Coarse scale and chaotic direction/orientation of scaling: Mixed vascular pattern.	Vázquez-López et al., 2004a (34)
	Tinea nigra	Fine superficial wispy-like gray to brownish lines that do not follow the anatomic structures of the furrows or ridges on glabrous skin. Clue: The superficial pigmentation can be easily removed by scraping the stratum corneum with a scalpel.	Smith et al., 2001 (26); Xavier et al., 2008 (27)
Bacterial	Folliculitis	White to yellow dot filling the hair follicle, sometimes surrounded by dotted vessels.	Zalaudek et al., 2008 (1)
	Lupus vulgaris	Fine focused telangiectasias over a typically yellow to golden background. Sometimes, a few milia-like cysts or whitish lines can be present.	Brasiello et al., 2008 (35)
	Trichomycosis palmellina	Yellowish casts around the hair shafts.	Personal observation
Parasites	Cutaneous larva migrans	Translucent brownish structureless areas in a segmental arrangement, which correspond to the body of the larva, whereas the empty burrow reveals red dotted vessels on dermoscopy.	Elsner et al., 1997 (25); Zalaudek et al., 2008 (1)
	Ixodes ricinus	Double pair of anterior legs protruding from the skin surface, whereas the chitinous body is seen as a brown to gray translucent "shield" with pigmented streaks.	Pagliarello et al., 2006 (21); Zalaudek et al., 2008 (1)
	Lice/nits	Vital nits: ovoid, brown structures fixed to the hair shaftEmpty nits: Cases are translucent and typically show a plane and fissured free ending.	Bakos and Bakos, 2007b (36); Di Stefani et al., 2006a (37); Di Stefani et al., 2006b (38); Scanni & Bonifazi, 2006 (39)
	Myiasis	Central opening surrounded by dilated blood vessels from which a yellowish structure with black barb-like spines can be seen. Movements of the larva can be seen.	Bakos and Bakos, 2007a (40)
	Scabies	Brown triangle at the end of a curved whitish line (jet with contrail).	Argenziano et al., 1997 (10); Bauer et al., 2001 (11); Brunetti et al., 1998 (12); Dupuy et al., 2007 (13); Prins et al., 2004 (14); Weinstock et al., 2000 (15)
	Tungiasis	Central pigmented ring with a pore in the middle, eccentric gray-bluish blotch, over a whitish background.	Bakos and Bakos, 2008 (23); Bauer et al., 2004 (11); Bauer et al., 2005 (41); Cabrera et al., 2008 (24); Di Stefani et al., 2005 (42)

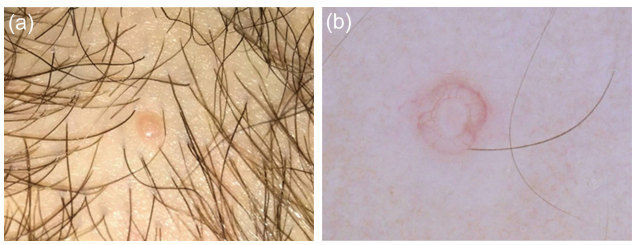

FIGURE 12A.1 (a) Clinical image of a molluscum contagiosum on the forearm of a 31-year-old man. (b) The clinical features raise the suspicion of molluscum contagiosum; dermoscopy leaves little doubt about the diagnosis, exhibiting structureless central polymorphous structures surrounded by crown vessels.

(Figure 12a.4 a, b, c). Dermoscopy confirms the presence of nits and whether they contain viable nymphs, dead nymphs, or are empty: (i) nits containing nymphs have a brown color and ovoid shape; (ii) empty nits appear translucent with an oval shape that is disfigured by a flattened free end; (iii) dead nits contain a collapsed nymph, which appears as a focal brown area within the nits, and an air pocket, appearing as a translucent area.[17] Dermoscopy helps to differentiate nits from pseudonits, i.e., hair casts, debris of hair spray, or scales from seborrheic dermatitis.[18]

Pubic lice or "crabs" are easily diagnosed with dermoscopy by finding *Phthirus pubis* attached to the terminal hair shafts within hair-bearing areas, such as genitalia, eyelashes, and scalp[19] (Figure 12a.5 a, b). However, they can also be found on other body sites containing vellous hair.

Tick bites

Ixoides ricinus is a small human parasite (less than 1 mm), which causes various infectious diseases, mostly Lyme borreliosis (Figure 12a.6 a). Dermoscopy is a helpful noninvasive tool that provides a convenient magnification and confirmation of the diagnosis (Figure 12a.6 b). On dermoscopy, the pair of anterior legs protruding from the surface of the skin is observed, and

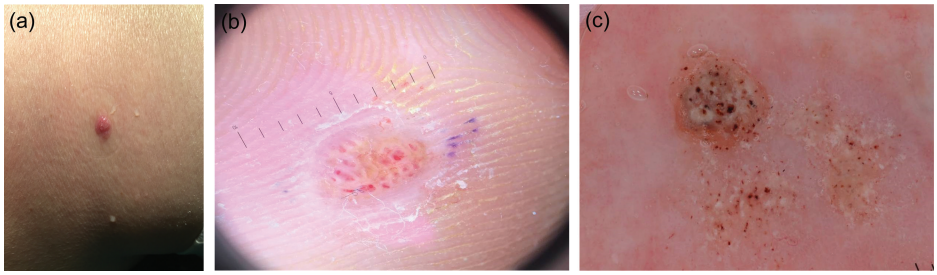

FIGURE 12A.2 (a) Clinical image of a viral wart. (b) Dermoscopy of a viral wart of the palm showing multiple densely packed papilla, each containing a central red or black dot or loop, which is surrounded by a whitish halo known as mosaic pattern. (c) Verrucous lesion with numerous thrombosed capillaries (black dots).

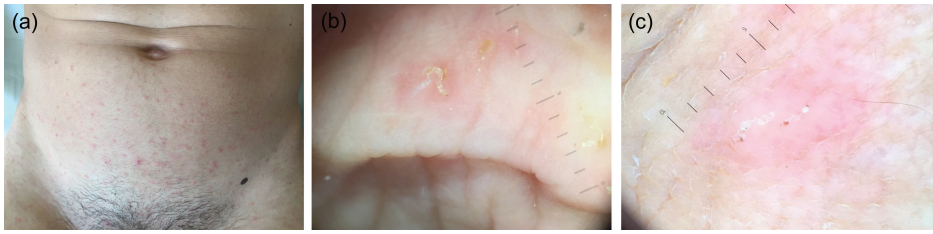

FIGURE 12A.3 (a) Clinical image of scabies. (b) Dermoscopy of cunicule on the lateral site of the finger showing brown triangles and whitish-appearing burrow with the so-called S-italic shape. Dermoscopy of two cunicules showing a linear burrow. At each end of the burrow, there is a delta-shaped structure, which is a small dark triangular structure and corresponds to the scabies mite.



FIGURE 12A.4 Side-by-side comparison of the clinical appearance of head lice nits (a) and pseudonits (b) attached to the hair shaft. With dermoscopy (c), the vital nits appear as roundish structures with a brownish center (arrow), while empty nits appear translucent with one side of the nit having a flat end (square). Dead nits appear with a focal brown color together with an air pocket (arrowhead).

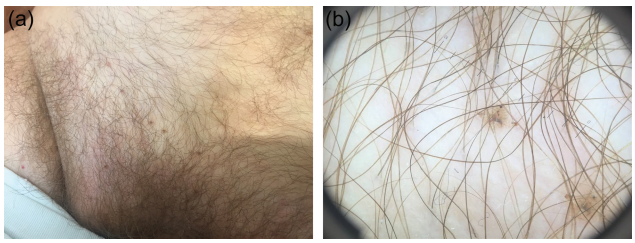

FIGURE 12A.5 (a) Clinical image of *Phthirus pubis* on the pubic area of a 30-year-old man. (b) Dermoscopy image showing the louse between the hair shafts.

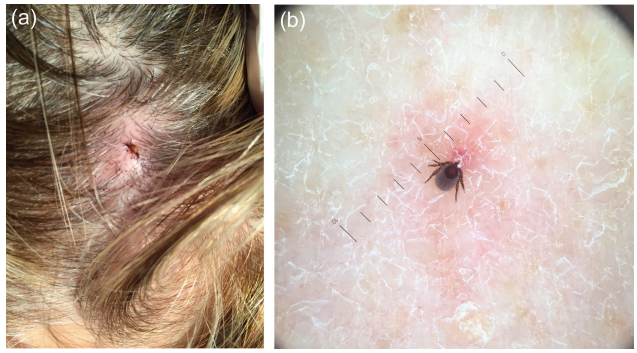

FIGURE 12A.6 (a) Clinical image of *Ixoides ricinus* on the scalp. (b) Dermoscopy image of *Ixoides ricinus* showing the human parasite in an erythematous background, outcome of the tick bite.

the chitinous body is seen as a brown to gray translucent "shield" with pigmented streaks.[20] In addition, dermoscopy is useful in determining whether the tick has been completely extracted.[1, 21]

Tungiasis

Tungiasis is an infectious disease caused by the flea *Tunga penetrans*, which lives in humid sand contaminated by feces of pigs and cows. The parasite penetrates the epidermis, causing reactive hyperplasia and subsequent light brown itchy papules that are typically seen on the soles and the periungueal area.[22]

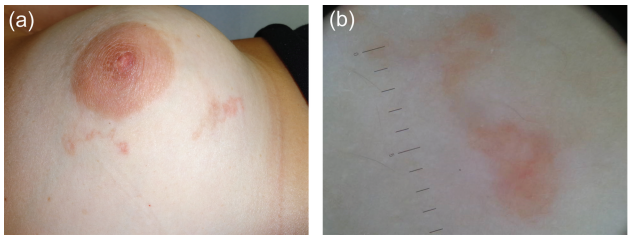

FIGURE 12A.7 (a) Clinical picture of larva migrans on the chest of a 25-year-old woman. (b) Dermoscopy of larva migrans showing a translucent yellowish serpiginous structure, which corresponds to the body of the larva.

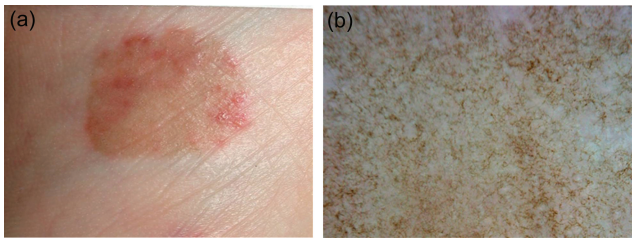

FIGURE 12A.8 (a) Clinical image of tinea nigra. (b) Dermoscopy image showing "pigmented spicules" or wispy lines that do not respect the dermatoglyphic ridges or furrows. (Images courtesy of Wilhelm Stolz, MD.)

Dermoscopic examination shows a central pigmented ring with a central pore and an eccentric gray-bluish blotch over a whitish background.[23, 24]

Cutaneous larva migrans

Cutaneous larva migrans (CLM) is an infection acquired by contact with soil that is contaminated by the feces of cats and dogs (Figure 12a.7 a). There are different species of helminths responsible for the disease, including *Ancilostoma braziliense*, *Ascaris suum*, and *Bunostomum phlebotum*. The larva penetrates through the skin, frequently of the foot. Dermoscopic examination reveals a translucent brownish/yellowish linear structure in a segmental arrangement, which corresponds to the body of the larva, and the empty burrow shows red dotted vessels[1, 25] (Figure 12a.7 b).

Fungal diseases

Tinea nigra

Tinea nigra (TN) is a superficial fungal infection caused by *Hortaea (Phaeoannellomyces) werneckii*, formerly called *Cladosporium werneckii* or *Exophilia werneckii*. Characteristically, TN presents as asymptomatic, irregular, brown-black macules, often mottled in coloration and darker at the border (Figure 12a.8 a). Infection occurs on the stratum corneum of the palms and/or soles of children living in or visiting South and Central America, Asia, or Africa, and rarely, in the United States and Europe. Potassium hydroxide (KOH) examination of TN easily reveals brown to olive-colored, thick, branching hyphae as well as budding yeast cells.[26] TN may mimic junctional nevi or acrolentiginous melanoma, which may lead to unnecessary skin biopsies. Under dermoscopy, TN does not reveal the typical acral patterns (i.e., parallel, fibrillar, or lattice-like patterns) characteristic of melanocytic lesions of the palms/soles and does not respect the dermatoglyphic furrows and ridges. Instead, there are fine, wispy brown strands or "pigmented spicules," which represent pigmented hyphae in the stratum corneum[27] (Figure 2a.8 b).

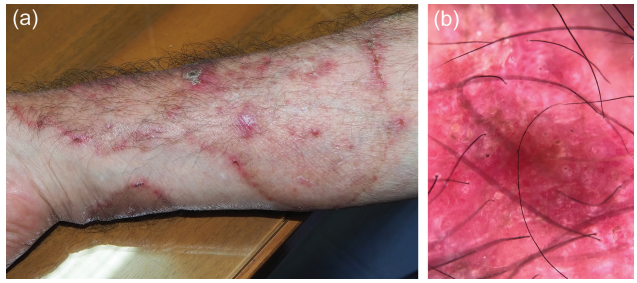

FIGURE 12A.9 (a) Clinical image of tinea corporis on the forearm. (b) Dermoscopic examination reveals the involvement of vellus hair. The presence of multiple small brown spots surrounded by a white-yellowish halo suggests fungal invasion of the hair follicle. (Images courtesy of Vincenzo Piccolo.)

Tinea corporis and vellus hair

Tinea corporis (TC) is a superficial fungal infection caused by dermatophytes such as *Trichophyton rubrum* or *Microsporum canis*, which are the most common[28]. Diagnosis of TC is clinical and supported by a positive KOH examination and culture. Clinically, TC appears with annular erythematous lesions spreading centrifugally with a scaly elevated border (Figure 12a.9a). Dermoscopic examination shows an erythematous background with yellowish scales and crusts due to vesicle rupture without a specific vascular pattern.[29] Hairless skin generally requires only topical treatment. A recent study demonstrated that dermoscopy can guide the treatment of TN on glabrous skin that is resistant to topical antifungal therapy by showing the involvement of vellus hairs.[30] The presence of multiple small brown spots surrounded by a white-yellowish halo is suggestive of fungal invasion of the hair follicle.[31, 32] (Figure 12a.9 b). Therefore, dermoscopy may help in the therapeutic management of TN.

Key points

Specific dermoscopic patterns:

- Molluscum contagiosum: Central polylobular structureless areas surrounded by crown vessels
- Viral warts: Verrucous papule with mosaic pattern
- Scabies: Jet with contrail features
- Lice nits: Ovoid if vital, plane end if empty
- Tick bites: double pair of anterior legs protruding from the surface of the skin, whereas the chitinous body is seen as a brown to gray translucent "shield" with pigmented streaks
- Tungiasis: Central pigmented ring with a pore in the middle, eccentric gray-bluish blotch, in a whitish background
- Larva migrans: translucent brownish linear structure in a segmental arrangement
- Tinea nigra: Wispy brown pigmented strands that do not respect the furrows or ridges on the palms/soles
- Tinea corporis involving vellus hair: Small brown spots surrounded by a white-yellowish halo

References

1. Zalaudek I., Giacomel J., Cabo H., et al. Entodermoscopy: a new tool for diagnosing skin infections and infestations. *Dermatology*, 2008; (216): 14–23.

2. Lallas A., Giacomel J., Argenziano G., Garcia-Garcia B., et al. Dermoscopy in general dermatology: Practical tips for the clinician. *Br J Dermatol*, 2014; (170): 514–26.
3. Morales A., Puig S., Malvehy J. & Zaballos P. Dermoscopy of molluscum contagiosum. *Arch Dermatol*, 2005; (141): 1644.
4. Zaballos P., Ara M., Puig S. & Malvehy J. Dermoscopy of molluscum contagiosum: a useful tool for clinical diagnosis in adulthood. *J Eur Acad Dermatol Venereol*, 2006; (20): 482–3.
5. Ianhez M., Cestari Sda C., Enokihara M.Y., et al. Dermoscopy pattern of molluscum contagiosum: a study of 211 lesions confirmed by histopathology *An Bras Dermatol*, 2011; (86): 74-9.
6. Bae J.M., Kang H., Kim H.O., Park Y.M. Differential diagnosis of plantar wart from corn, callus and healed wart with the aid of dermoscopy. *Br J Dermatol*, 2009; 160: 220–2.
7. Lacarrubba F., Verzì A.E., Dinotta F., et al. Dermatoscopy in inflammatory and infectious skin disorders. *G Ital Dermatol Venereol*, 2015; (150): 521–31.
8. Dalmau J., Abellaneda C., Puig S., Zaballos P. & Malvehy J. Acral melanoma simulating warts: dermoscopic clues to prevent missing a melanoma. *Dermatol Surg*, 2006; (32): 1072–8.
9. Kim H.O., Bae J.M., Kim Y.Y., et al. Differential diagnosis of wart from callus and healed wart with aid of dermoscopy. *Dermatology*, 2006; (212): 307.
10. Argenziano G., Fabbrocini G. & Delfino M. Epiluminescence microscopy. a new approach to in vivo detection of Sarcoptes scabiei. *Arch Dermatol*, 1997;(133): 751–3.
11. Bauer J., Blum A., Sonnichsen K., et al. Nodular scabies detected by computed dermatoscopy. *Dermatology*, 2001; (203): 190–1.
12. Brunetti B., Vitiello A., Delfino S. & Sammarco E. Findings in vivo of Sarcoptes scabiei with incident light microscopy. *Eur J Dermatol*, 1998; (8): 266–7.
13. Dupuy A., Dehen L., Bourrat E., et al. Accuracy of standard dermoscopy for diagnosing scabies. *J Am Acad Dermatol*, 2007; (56): 53–62.
14. Prins C., Stucki L., French L., Saurat J.H. & Braun R.P. Dermoscopy for the in vivo detection of sarcoptes scabiei. *Dermatology*, 2004; (208): 241–3.
15. Weinstock M.A. & Kempton S.A. Case report: teledermatology and epiluminescence microscopy for the diagnosis of scabies. *Cutis*, 2000; (66): 61–2.
16. Criado P.R. Entodermoscopy: dermoscopy for the diagnosis of pediculosis *An Bras Dermatol*, 2011; 86(2): 370–1.
17. Micali G., Tedeschi A., West D.P. et al. The use of videodermoscopy to monitor treatment of scabies and pediculosis *J Dermatol Treat*, 2011; (22): 133–7.
18. Zalaudek I., Argenziano G. Images in clinical medicine. Dermoscopy of nits and pseudonits *N Engl J Med*, 2012: 367(18): 1741.
19. Lacarrubba F., Micali G. The not-so-naked eye: phtiriasis palpebrarum. *Am J Med*, 2013; (126): 960–1.
20. Pagliarello C., Fossati B., Landi F., et al. Dermoscopy of a tick bite: a case report. *Dermatology*, 2006; (212): 31.
21. Zalaudek I., Argenziano G., Di Stefani A., et al. Dermoscopy in general dermatology. *Dermatology*, 2006a; (212): 7–18.
22. Bauer J., Forschner A., Garbe C. & Rocken M. Dermoscopy of tungiasis. *Arch Dermatol*, 2004; (140): 761–3.
23. Bakos R.M. & Bakos L. 'Whitish chains': a remarkable in vivo dermoscopic finding of tungiasis. *Br J Dermatol*. 2008
24. Cabrera R. & Daza F. Tungiasis: eggs seen with dermoscopy. *Br J Dermatol*, 2008; (158): 635–6.
25. Elsner E., Thewes M. & Worret W.I. Cutaneous larva migrans detected by epiluminescent microscopy. *Acta Derm Venereol*, 1997; (77): 487–8.
26. Smith S.B., Beals S.L., Elston D.M. & Meffert J.J. Dermoscopy in the diagnosis of tinea nigra plantaris. *Cutis*, 2001; (68): 377–80.
27. Xavier M.H., Ribeiro. L.H., Duarte H., Saraça G. & Souza A.C. Dermatoscopy in the diagnosis of tinea nigra. *Dermatol Online J*, 2008; (14): 15.
28. Havlickova B., Czaika V.A., Friedrich M. Epidemiologica trends in skin mycoses worldwide. *Mycoses*, 2008; (51) Supplement 4: 2–15.
29. Russo T., Piccolo V., Lallas A., Argenziano G. Recent dvance in dermoscopy. *F1000Res*. 2016; (174):636–8.
30. Gomez-Moyano E., Crespo-Erchica V. Tinea of vellus hair: an indication for systemic antifungal therapy. *Br J Dermatol*, 2010; (163): 603–6.
31. Gomez-Moyano E., Crespo-Erchica V., Martinez Pilar L., Martinez Garcia S., et al.Using dermoscopy to detect tinea of vellus hair *Br J Dermatol*, 2016; (174): 636–8.
32. Piccolo V., Corneli P., Russo T., Zalaudek I., et al. Dermoscopy as useful tool in diagnosis of tinea incognito. *Int J Dermatol*, 2018.

12B DERMOSCOPY IN GENERAL DERMATOLOGY: INFLAMMATORY DERMATOSES (INFLAMMOSCOPY)

Konstantinos Lallas, Zoe Apalla, and Aimilios Lallas

Contents

Dermatitis . . . 299
Seborrheic dermatitis . . . 300
Discoid lupus erythematosus . . . 300
Granuloma annulare . . . 300
Grover's disease . . . 301
Lichen planus . . . 301
Lichen sclerosus . . . 301
Lymphomatoid papulosis . . . 301
Mastocytosis . . . 302
Mycosis fungoides (MF) . . . 302
Necrobiosis lipoidica . . . 302
Pigmented purpuric dermatoses . . . 303
Perforating dermatoses . . . 303
Pityriasis lichenoides . . . 303
Pityriasis rosea . . . 303
Pityriasis rubra pilaris . . . 304
Porokeratosis . . . 304
Prurigo nodularis . . . 304
Psoriasis . . . 304
Site-specific disease types . . . 305
Dermoscopy for treatment monitoring . . . 305
Rosacea . . . 306
Sarcoidosis . . . 306
Urticaria and urticarial vasculitis . . . 306
Conclusion . . . 306
References . . . 307

During the last decade, dermoscopy has been used in conditions other than tumors, including inflammatory dermatoses (inflammoscopy) and parasitoses, with a surprisingly positive outcome. Incorporation of dermoscopic clues with the information obtained from clinical examination, history, and the overall clinical context of the patient facilitates accurate recognition of numerous inflammatory diseases. It also facilitates assessment of the outcome and adverse effects of various treatments.

According to a recent expert consensus, the following five main parameters should be evaluated in inflammatory dermatoses:

1) Morphology of vascular structures
2) Arrangement of vascular structures
3) Follicular alterations
4) Other structures
5) Specific clues

While there are many dermoscopic criteria that are considered highly specific for certain dermatoses, there are others that are "nonspecific." In the latter scenario, co-evaluation of the clinical and dermoscopic clues is necessary to reach a definitive diagnosis.

Dermatitis

The typical dermoscopic pattern of all types of dermatitis consists of dotted vessels in a patchy distribution and yellow scales/sero-crusts (Figure 12b.1).[1, 2] The latter feature (yellow scales/crusts) is considered the dermoscopic hallmark of dermatitis, histopathologically corresponding to the presence of spongiosis and dried serum on the epidermal surface. The presence of scale differs by anatomic location and by the evolutionary stage of the disease. In the acute phase, when spongiosis is prominent, yellow scales/crusts are almost always present; they gradually decrease in the subacute stage and are almost absent in the chronic phase of lichenification. As an example, chronic hand eczema is characterized by brownish and orange-yellowish dots/globules resulting from the spongiotic vesicles and orange-yellowish crusts.[3, 4] In regard to the vascular component, dotted vessels in dermatitis are not as evident as in psoriasis; they are subtle and follow a patchy and asymmetric arrangement. Histopathologically, there is asymmetric papillomatosis and thinning of the rete ridges, as opposed to psoriasis, which is characterized by homogeneous and even acanthosis and papillomatosis of the epidermis.[7]

DOI: 10.1201/9780429487873-40

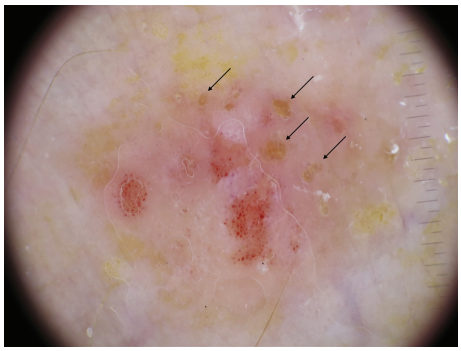

FIGURE 12B.1 Dotted vessels in a patchy distribution and yellow scales/sero-crusts (arrows) typify the dermoscopic pattern of dermatitis.

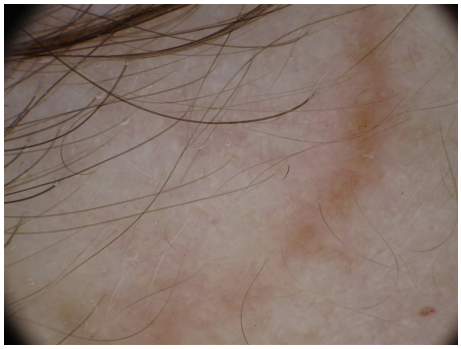

FIGURE 12B.2 Yellow scales and dotted vessels in seborrheic dermatitis. These are useful clues to discriminate seborrheic dermatitis from other facial inflammatory diseases like rosacea, discoid lupus erythematosus, and sarcoidosis.

Seborrheic dermatitis

Like any other type of dermatitis, seborrheic dermatitis is dermoscopically exemplified by dotted vessels in a patchy distribution and fine yellowish scales (Figure 12b.2). Occasionally, white scales can be present.[2] Dermoscopy is particularly useful in discriminating between seborrheic dermatitis and other inflammatory diseases of the face and scalp. In contrast to seborrheic dermatitis, rosacea is dermoscopically characterized by linear vessels forming polygons (polygonal vessels); discoid lupus erythematosus by follicular criteria (keratin plugs and perifollicular white halos); and sarcoidosis by orange color and linear vessels. On the scalp, seborrheic dermatitis also displays linear vessels, as opposed to scalp psoriasis, which is typified by coiled or tortuous vascular structures.[5–8]

Discoid lupus erythematosus

The dermoscopic pattern of discoid lupus erythematosus (DLE) depends on the disease stage, with follicular criteria predominating in earlier stages and atrophy-related structures in the later stages. In particular, follicular plugs and perifollicular whitish halo characterize early DLE lesions (Figure 12b.3). Diffuse hyperkeratosis may also be present. Later, the follicular criteria gradually fade, and the erythema and hyperkeratosis become more evident. In this phase, telangiectatic vessels are also present. As the disease evolves, telangiectasia becomes more prominent, and gray-brown-pigmented granules, dots, and globules or network-like structures may appear

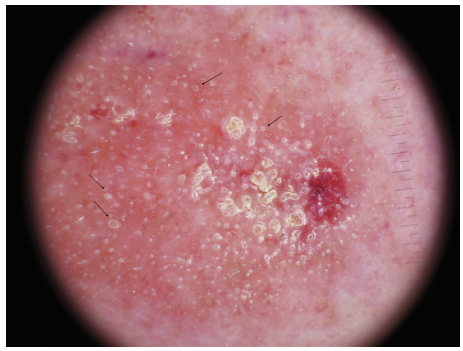

FIGURE 12B.3 Follicular criteria, including follicular plugs and perifollicular whitish halos (arrows), are shown in early DLE lesions.

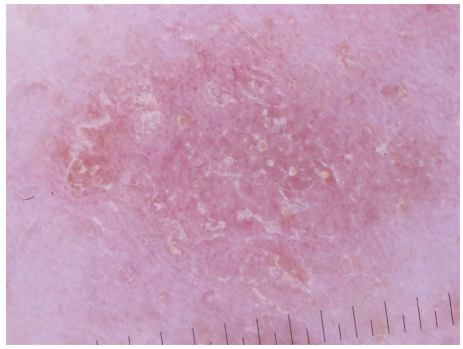

FIGURE 12B.4 Atrophy-related structures are evident in later stages of DLE, including erythema, hyperkeratosis, and telangiectatic vessels corresponding to atrophic epidermis.

(Figure 12b.4).[2, 9–13] At the final stage, white structureless areas are the only remaining dermoscopic feature. All the aforementioned dermoscopic criteria are correlated with the underlying histopathologic alterations. The perifollicular whitish halo corresponds to early perifollicular fibrosis, telangiectatic vessels are seen as a result of the atrophic epidermis, pigmented granules correspond to melanophages, and whitish structureless areas are the result of extensive fibrosis in the late phase of the disease. The differential diagnosis of DLE includes lupus pernio and lupus vulgaris. The latter entities display a different dermoscopic pattern with the absence of follicular alterations as seen in early DLE.[14, 15]Another challenging differential diagnosis is actinic keratosis, which is dermoscopically exemplified by erythema interrupted by white follicular openings (i.e., strawberry pattern).[16]

Granuloma annulare

The dermoscopic pattern of granuloma annulare (GA) depends on the histologic subtype. Similarly to other granulomatous disorders, the palisading variant of GA is dermoscopically characterized by yellowish-to-orange structureless areas (Figure 12b.5). On the other hand, the interstitial subtype is dermoscopically characterized by pink-reddish background and subtle, unfocused vessels of various morphologic types, including dotted, short linear, and linear branching (Figure 12b.6). The absence of orange-yellowish areas in the interstitial subtype reflects the histopathologic absence of well-formed granulomas.[17–19]

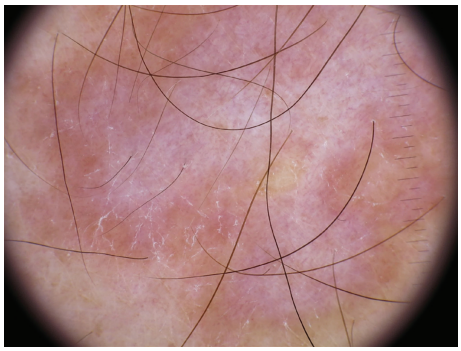

FIGURE 12B.5 The palisading variant of GA is dermoscopically typified by yellowish-orange structureless areas.

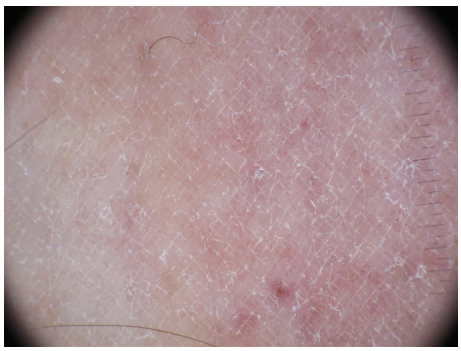

FIGURE 12B.6 The interstitial type of GA lacks yellowish structureless areas due to absence of well-formed granulomas. It is characterized by pink-reddish background and subtle, unfocused vessels of various morphologic types.

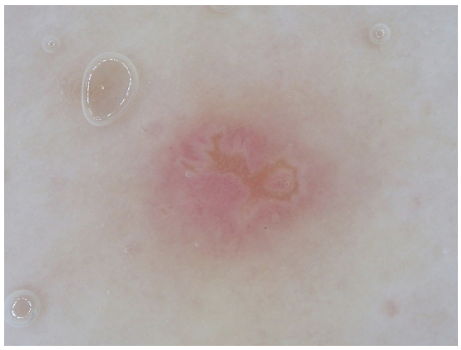

FIGURE 12B.7 The "stellate ulceration" of Grover's disease: A central yellow or brownish eroded area with radial projections.

Grover's disease

The dermoscopic hallmark of Grover's disease is the so-called "stellate ulceration," which consists of a central stellate-shaped yellow or brownish area surrounded by a whitish halo (Figure 12b.7). Background erythema can also be present.[20–23]

Lichen planus

The dermoscopic hallmark of lichen planus (LP) is the "Wickham striae" (WS). It is seen as intersecting white lines that form a network, mainly present in the center of the lesion

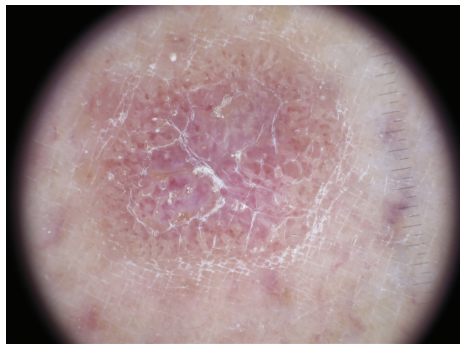

FIGURE 12B.8 "Wickham striae" (whitish lines in the center forming a network) are a very specific dermoscopic feature for lichen planus.



FIGURE 12B.9 In lichen planus pigmentosus, melanophages in the upper dermis are shown as blue-gray granules (arrows) or structureless brown areas.

(Figure 12b.8). The detection of WS is strongly suggestive of LP.[24, 25] Several types of WS have been described, including reticular (most common), linear, annular, radial, and clustered. Histopathologically, WS correspond to orthokeratosis above zones of wedge-shaped hypergranulosis.[24] In addition to WS, vascular structures are also frequent in LP. They are typically dotted or short linear vessels distributed along the peripheral edge of the WS.[26–30]

Multiple blue/gray granules or structureless brown areas represent a frequent finding in late LP (or LP pigmentosus) and correspond to melanophages in the upper dermis (Figure 12b.9). Comedo-like structures filled with roundish corneal masses can be seen in hypertrophic variants of LP.[31, 32]

Lichen sclerosus

Genital lichen sclerosus (LS) displays a characteristic dermoscopic pattern consisting of white structureless areas combined with dotted and linear vessels. Extragenital LS combines white structureless areas with keratotic follicular plugs, simulating comedo-like openings (Figure 12b.10).[33, 34] The latter feature is particularly useful to differentiate lichen sclerosus from other hypopigmented dermatoses, including morphea and vitiligo.

Lymphomatoid papulosis

Lymphomatoid papulosis (LyP) belongs to the spectrum of cutaneous T-cell lymphomas. The dermoscopic pattern of LyP

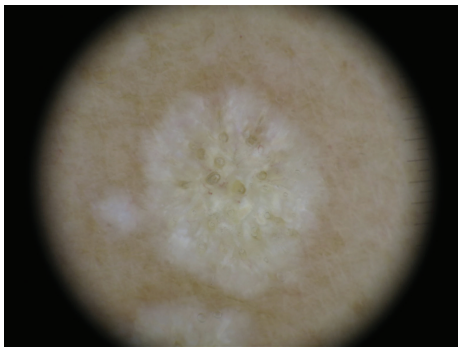

FIGURE 12B.10 The combination of follicular keratotic plugs and white structureless areas differentiates extragenital lichen sclerosus from other hypopigmented dermatoses.

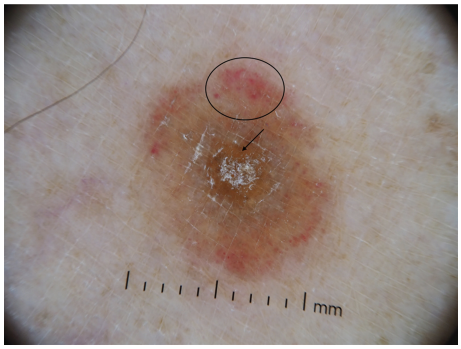

FIGURE 12B.11 Lymphomatoid papulosis (LyP) characterized by a yellow/white structureless center (arrow) and purpuric dots mainly at the periphery (circle).

depends on the age of the lesion. In particular, recent papules/nodules usually display dotted or tortuous/irregular vessels over an erythematous background as well as purpuric spots (Figure 12b.11). At a later stage, the vessels become less evident and tend to aggregate at the periphery of the papules. In hyperkeratotic lesions, a white-yellowish structureless area covers the central part, while necrotic lesions present a dark brown central eschar. These nodules/papules resolve with healing and are dermoscopically characterized by brown-gray structureless areas corresponding to post-inflammatory pigmentation.[35]

Mastocytosis

Different clinical variants of mastocytosis display different dermoscopic patterns. A uniform light brown pigment network typifies maculopapular mastocytosis (urticarial pigmentosa) (Figure 12b.12). Telangiectasia macularis eruptiva perstans is dermoscopically characterized by reticular vessels on an erythematous/brownish background, sometimes associated with a brownish network.[36–39] Dotted vessels and thin and tortuous linear vessels might be seen in both types. Solitary mastocytoma displays diffuse orange to yellowish color or multifocal yellow-to-orange areas on dermoscopy. Overlap of dermoscopic criteria does exist among different types of the disease.[36–40]

Mycosis fungoides (MF)

The most frequent dermoscopic structures seen in patch-stage MF are short-fine, linear, curved vessels and

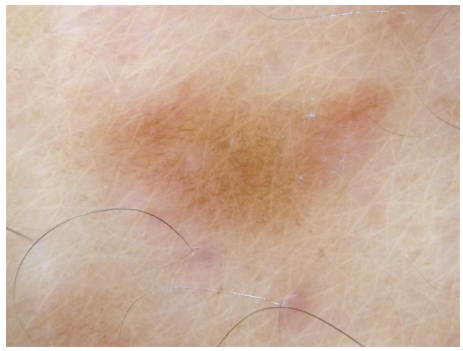

FIGURE 12B.12 A uniform light-brown pigment network typifies maculopapular mastocytosis.

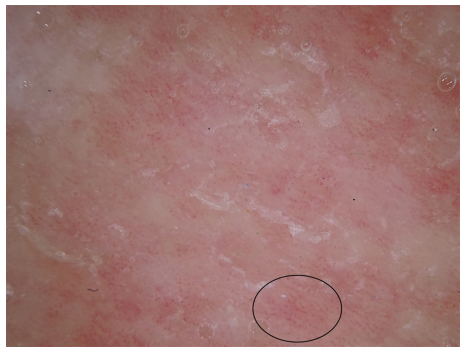

FIGURE 12B.13 Short-fine, linear, curved vessels corresponding to dilated dermal vessels in mycosis fungoides.

orange-yellowish patchy areas. Histopathologically, these findings correspond to dilated dermal vessels and hemosiderin deposits in the dermis, respectively.[41] A peculiar structure consisting of a short linear vessel that has a red dot on one end (spermatozoon-like structure) has also been described in MF (Figure 12b.13).[41] The vascular structures of MF are much more prominent in the poikilodermatous variant of the disease. Erythrodermic MF has been reported to display sparse whitish scales along with widespread dotted vessels and a few spermatozoon-shaped vessels over a white-pinkish background.

Chronic dermatitis, which represents the main differential diagnosis of classic early MF, typically manifests scattered dotted vessels and yellow scales, whereas the characteristic vascular pattern of MF (short-fine linear vessels with or without spermatozoa-like vessels) and orange-brown patchy areas are usually absent.[42]

Necrobiosis lipoidica

The most frequent dermoscopic pattern of necrobiosis lipoidica consists of diffuse structureless orange-yellowish color, or focal orange-yellowish structures, usually combined with vascular structures.[17–19] The morphology of the vessels varies according to the evolution of the disease, with dotted, globular, and glomerular vessels being more common in early stages and fine, linear, and branching vessels in late stages (Figure 12b.14).[43] Often, the linear vessels are predominant and form a dense vascular plexus that may also be seen macroscopically.

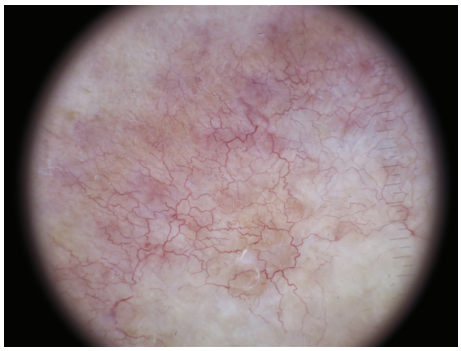

FIGURE 12B.14 Fine, linear, branching vessels combined with diffuse structureless orange-yellowish areas typify necrobiosis lipidoica.



FIGURE 12B.15 The main dermoscopic features for PPDs are red, purpuric dots/globules over a brown to coppery background. White scales are an additional sign enhancing the diagnosis.

Pigmented purpuric dermatoses

The term *pigmented purpuric dermatoses* (PPDs) includes Schamberg disease, Majocchi purpura, eczematoid purpura of Doukas and Kapetanakis, lichen aureus, and pigmented purpuric lichenoid dermatitis of Gougerot-Blum.[44, 45] All forms of PPDs are dermoscopically typified by the presence of round to oval, red, purpuric dots and/or globules (corresponding to extravasated erythrocytes in the dermis) over a brownish to coppery-colored background (corresponding to dermal hemosiderin deposits) (Figure 12b.15).[42] Linear or dotted vessels, white scales, and pigmented structures, including dots/globules and network, are additional features.

Perforating dermatoses

The group of perforating dermatoses includes elastosis perforans serpiginosa, perforating collagenosis, reactive perforating folliculitis. and acquired perforating dermatosis (syn. Kyrle's disease). Dermoscopy of the latter three entities is very similar and typically displays three concentric areas, the so-called "trizonal concentric" pattern, consisting of a central, roundish, brown-yellow structureless area surrounded by a white keratotic collarette and an outer erythematous halo, with or without dotted vessels (Figure 12b.16). A peripheral brown pigmentation has also been described in Kyrle's disease.[46–48]

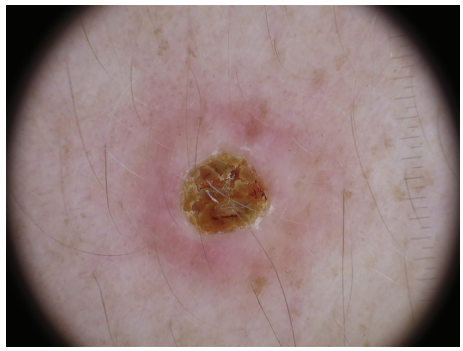

FIGURE 12B.16 The "trizonal concentric" pattern of perforating dermatoses, consisting of three concentric areas: A central roundish, brown-yellow structureless area surrounded by a white keratotic collarette and an outer erythematous halo with or without dotted vessels.



FIGURE 12B.17 A diffuse hemorrhagic area in the central part is the diagnostic hallmark for pityriasis lichenoides.

Pityriasis lichenoides

The dermoscopic findings in acute pityriasis lichenoides (PLEVA) depend on the phase of evolution of each lesion.[49] Early lesions are typified by purpuric dots or diffuse hemorrhagic areas, usually seen towards the center of the lesion (Figure 12b.17). Later stages are characterized by central amorphous brownish crust, while after healing, a central white area due to fibrosis may appear. A rim of pinpoint and/or linear vessels may be seen at the periphery of the lesions. In addition, a peripheral collarette of scales, with an inner free edge, is often evident in all stages.[50]

Chronic pityriasis lichenoides typically combines central orange-yellowish structureless areas and globular or linear vessels with diffuse and/or peripheral whitish scaling.

Pityriasis rosea

The herald and secondary patches of pityriasis rosea are dermoscopically identical and are exemplified by fine scales mainly located at the periphery.[4] A few dotted vessels in an asymmetric distribution are frequently seen (Figure 12b.18). An orange-yellowish hue has also been described. An eczematous reaction might occur in the background of pityriasis rosea, and, in that case, dermoscopy reveals features associated with eczema, namely, yellow sero-crusts.[51, 52,]

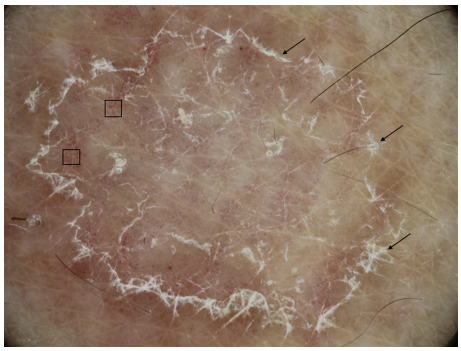

FIGURE 12B.18 Fine scales across the periphery (arrows) and irregularly distributed dotted (boxes) vessels in pityriasis rosea.

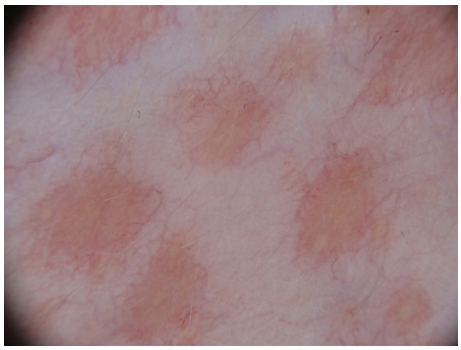

FIGURE 12B.19 Round to oval yellowish areas surrounded by linear or dotted vessels, often combined with central keratin, seal the diagnosis of pityriasis rubra pilaris.

Pityriasis rubra pilaris

Round to oval yellowish areas surrounded by linear or dotted vessels, often combined with central keratin, is the most frequent dermoscopic pattern of pityriasis rubra pilaris (Figure 12b.19).[49, 53] Keratoderma that might occur during the course of the disease is characterized by a variably sized orange area along with whitish scale.[53] Moreover, dermoscopy may facilitate the recognition of the erythrodermic stage by revealing orange blotches and islands of nonerythematous (spared) skin displaying reticular vessels, as opposed to the dotted vessels of psoriasis.[54]

Porokeratosis

The main dermoscopic finding of porokeratosis is a well-defined, roundish, peripherally white-colored double-edged scaly rim forming a groove, which may be continuous or discontinuous around the perimeter of the lesion ("white track") (Figure 12b.20).[55–58] The groove created by the double rim of scale corresponds to the diagnostic cornoid lamella observed on histopathology. Occasionally, the peripheral rim may be translucent or difficult to visualize even with dermoscopy. The simple "ink test" can be used to accentuate the cornoid lamella. This requires staining the lesion with a surgical marking pen (gentian violet) and then wiping off the ink with 70% isopropyl alcohol. In porokeratosis, the ink will remain in the groove once the rest of the ink has been wiped off the surface of the lesion (Figure 12b.21a). The resulting ring of ink around the

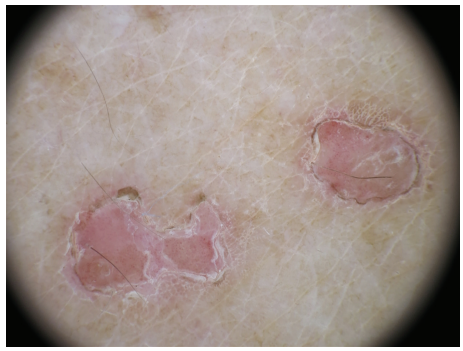

FIGURE 12B.20 The "volcanic crater" of porokeratosis: A white, peripheral rim with dotted vessels in the center resolving of an active lesion.

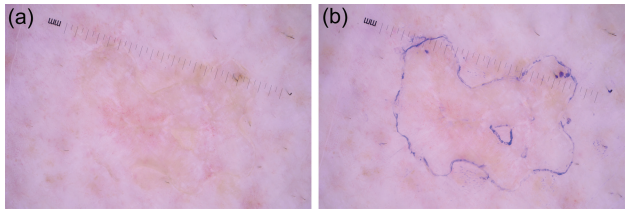

FIGURE 12B.21 (a) The double-edge scaly rim is difficult to appreciate in this porokeratosis, which also reveals dotted vessels and shiny white structures on polarized dermoscopy. (b) The ink test nicely highlights the cornoid lamella and confirms the diagnosis of porokeratosis.

lesion makes it easy to confirm the diagnosis of porokeratosis.[59] The dermoscopic features in the center depend on the age of the lesion. Specifically, in active lesions, dotted or globular vessels might be present, whereas resolving lesions may display blue/gray dots/granules.[60, 61] Finally, late lesions are characterized by a diffuse white color with or without shiny white lines (Figure 12b.21b), suggestive of the underlying epidermal atrophy and dermal fibrosis.

Prurigo nodularis

Prurigo nodularis manifests a peculiar dermoscopic pattern consisting of radially arranged whitish lines ("white starburst pattern") (Figure 12b.22). Another common pattern is a peripheral white halo surrounding red-brown crusts with hyperkeratosis, scales, or central erosion.[62]

Psoriasis

Psoriasis was the first inflammatory skin disease to be explored dermoscopically. Dermoscopy is currently used routinely for the clinical recognition of the disease and also for the assessment of topical and systemic treatment response.

The typical dermoscopic pattern of psoriasis consists of regularly distributed dotted, globular, or coiled (glomerular) vessels over a light red background, combined with white scales (Figure 12b.23). [4, 27, 63–66] Histopathologically, this characteristic pattern corresponds to epidermal psoriasiform hyperplasia with elongated rete ridges and spiraled capillaries vertically oriented in the dermal papillae. While globular and coiled vessels can be seen in psoriasis, the presence of dotted vessels is



FIGURE 12B.22 The white starburst pattern (radially arranged whitish lines) of prurigo nodularis combined with a central erosion.

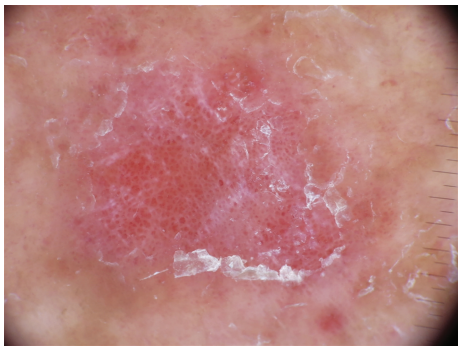

FIGURE 12B.23 Regularly distributed, symmetrically and homogeneously arranged dotted vessels, corresponding to epidermal psoriasiform hyperplasia, represent the dermoscopic hallmark of psoriasis. In addition, diffuse white scales around the lesion are present.

the hallmark of psoriasis. In fact, in clinically suspect lesions with a differential that includes psoriasis, the presence of vessels other than dotted vessels should challenge the diagnosis of psoriasis.[27] Dotted vessels are found in numerous inflammatory diseases, but their symmetric and homogeneous distribution in the lesion is highly indicative of psoriasis or other dermatoses with psoriasiform hyperplasia of the epidermis.[4] The regular distribution of dotted vessels in psoriasis reflects the symmetric elongation of the dermal papillae and the uniform thinning of the rete ridges, allowing visualization of the vertically oriented vessels.

Often, thick superficial scales may impede the visualization of the vascular structures. Mechanical removal of the scales or application of isopropyl alcohol often will help reveal the dotted vessels (dermoscopic Auspitz sign).[66]

Another, less frequent type of vessel distribution is the network-like pattern (syn. plexus-like or "red globular rings" pattern).[63] This pattern of vessel distribution closely simulates the vessels of clear cell acanthoma, but in the context of inflammatory diseases, it is considered highly specific for psoriasis.

As reported in the literature, with the use of the aforementioned criteria, the discrimination of psoriasis from other inflammatory or neoplastic diseases (Bowen's disease and basal cell carcinoma) is strongly enhanced.[67, 68]

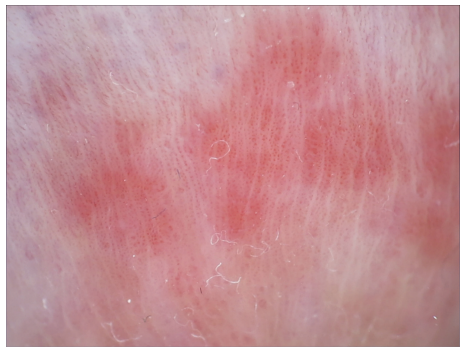

FIGURE 12B.24 Psoriatic balanitis typified by regularly distributed dotted vessels in the absence of scales.

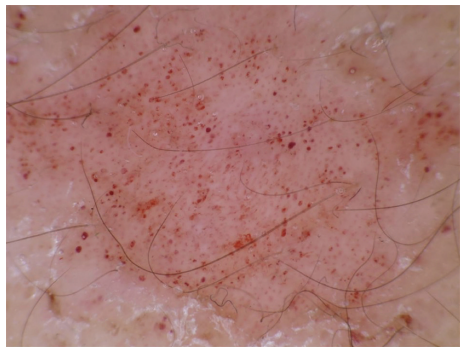

FIGURE 12B.25 Dermoscopy as a tool to assess treatment response of psoriasis. The presence of purpuric/hemorrhagic dots represents an early predictor of favorable response to treatment.

Site-specific disease types

The dermoscopic vascular pattern of psoriasis seems to remain unaltered irrespective of body site (scalp, palms, soles, folds, and genitalia) or clinical subtype (guttate or erythrodermic psoriasis).[69] In contrast, there is variability in the amount and thickness of superficial scales according to the anatomic site. For example, scalp, palmar, and plantar lesions are often hyperkeratotic. Therefore, vessels might not be seen under dermoscopy unless the scales are mechanically removed. For scalp psoriasis, some additional clues have been described, including signet ring vessels, red loops, punctate hemorrhage, pigmentation (perifollicular, honeycomb pigment pattern), and white/yellow scales.[8–11] In palmoplantar pustular psoriasis, dermoscopy might also reveal the underlying pustules in addition to the scales and vessels.[6, 7] Hyperkeratosis is usually absent in inverse psoriasis or psoriatic balanitis (Figure 12b.24), and thus, dermoscopy will reveal multiple regularly distributed dotted vessels without scales.[70, 71] A diffuse reddish background with dotted/glomerular vessels and white scales is the dermoscopic hallmark of erythrodermic psoriasis.[69]

Dermoscopy for treatment monitoring

Dermoscopy can be used for the assessment of early response to systemic agents. A multicentric study showed that the dermoscopic appearance of hemorrhagic dots represents an early predictor of a favorable response to treatment (Figure 12b.25). In addition, in patients treated with topical steroids, the dermoscopic appearance of fine linear vessels represents an initial sign of steroid-induced skin atrophy.[72, 73]

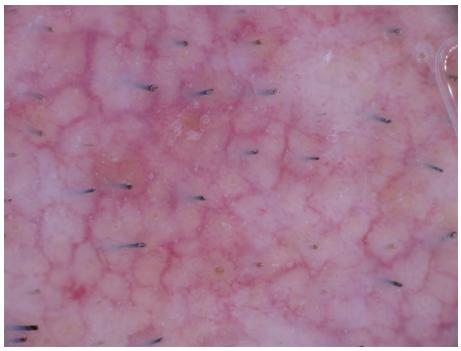

FIGURE 12B.26 Polygonal vessels are a highly specific vascular pattern for rosacea.

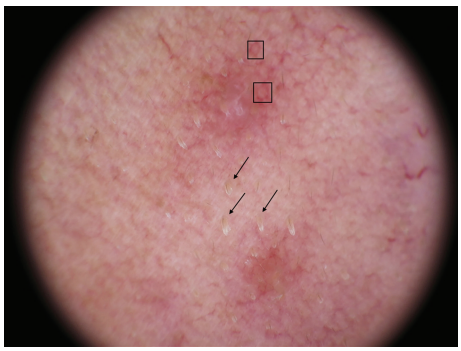

FIGURE 12B.27 *Demodex* tails (arrows) (white follicular plugs) protruding out of the follicle indicate the diagnosis of demodicidosis. Also, in the periphery, polygonal vessels are shown (boxes).

Rosacea

Rosacea is dermoscopically typified by a highly characteristic vascular pattern consisting of intersecting linear vessels that form polygons (polygonal vessels, Figure 12b.26). This vascular pattern is predominant in erythemato-telangiectatic rosacea and is highly specific as compared with other dermatoses included in its differential diagnosis. In papulopustular rosacea, dermoscopy reveals polygonal vessels, although not as prevalent and often combined with visible pustules. In glandular rosacea, polygonal vessels are less evident, and follicular criteria may predominate (i.e., dilated follicles filled with keratin plugs). A rosacea-like eruption has been associated with *Demodex folliculorum* (demodicidosis), and dermoscopy might reveal white follicular "spines" protruding out of the follicle (*Demodex* "tails"). This condition is also often associated with polygonal vessels (Figure 12b.27).[74, 75]

Sarcoidosis

Cutaneous sarcoidosis is dermoscopically characterized by orange areas, which may be diffuse or focal, and the presence of linear branching vessels (Figure 12b.28). The orange-yellowish areas correspond to the dense and compact granulomatous infiltrate. Dotted and glomerular vessels may also be observed but to a lesser degree.[17, 18]Additional dermoscopic features depend on the clinical subtype and include pigmented structures, follicular plugs, scales, dilated follicles, milia-like cysts, and crystalline structures. Of note, a very similar dermoscopic pattern has been suggested to typify other granulomatous disorders such as lupus vulgaris and cutaneous leishmaniasis.[76] To date, dermoscopy is unable to differentiate among the aforementioned granulomatous disorders.

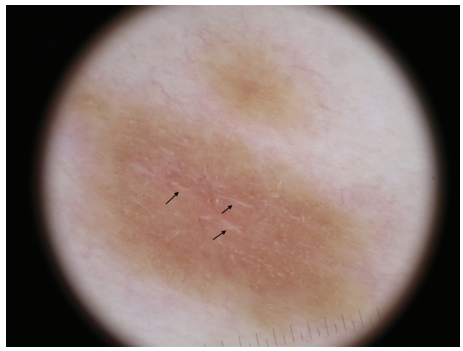

FIGURE 12B.28 Cutaneous sarcoidosis is dermoscopically characterized by diffuse or focal orange areas. Moreover, crystalline structures are shown with arrows.

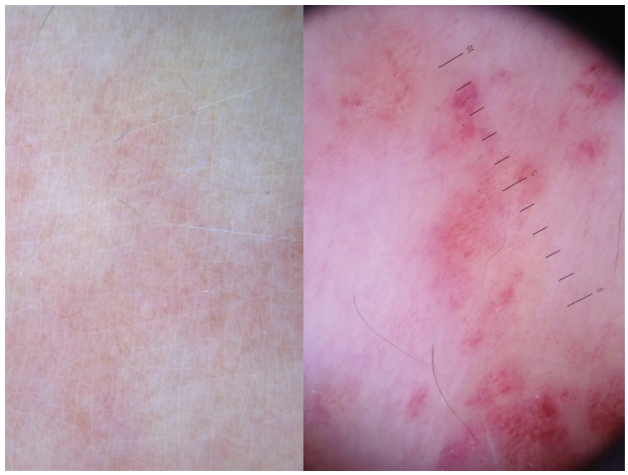

FIGURE 12B.29 Linear vessels in an erythematous background are common in urticaria and urticarial vasculitis. The discrimination between them is based on the presence of areas of vascular network alternating with avascular areas in the former (a) and red-purpuric dots/globules in the latter (b).

Urticaria and urticarial vasculitis

Both diseases are dermoscopically characterized by a network of fine linear vessels over an erythematous background. In urticaria, areas of vascular network alternate with avascular areas. In contrast, in urticarial vasculitis, purpuric dots/globules represent an additional critical feature that is useful in differentiating it from urticaria (Figure 12b.29). Histopathologically, the purpuric dots correspond to focal extravasation of erythrocytes resulting from the vasculitis.[77, 78]

Conclusion

The application of dermoscopy in general dermatology is gaining appreciation among dermatologists, revealing clinically invisible structures and highlighting specific features (vascular, follicular, scales) that can contribute to the "puzzle"

of the differential diagnosis. An integrated approach that takes into consideration the clues from the clinical and dermoscopic examination as well as the patient's history enhances the early and accurate diagnosis of many dermatoses.

References

1. Lallas A, Kyrgidis A, Tzellos TG, et al. Accuracy of dermoscopic criteria for the diagnosis of psoriasis, dermatitis, lichen planus and pityriasis rosea. *Br J Dermatol.* 2012;166:1198–205.
2. Lallas A, Argenziano G, Apalla Z, et al. Dermoscopic patterns of common facial inflammatory skin diseases. *J Eur Acad Dermatol Venereol.* 2014;28:609–14.
3. Errichetti E, Stinco G. Dermoscopy in differential diagnosis of palmar psoriasis and chronic hand eczema. *J Dermatol.* 2016;43:423–5.
4. Errichetti E, Piccirillo A, Stinco G. Dermoscopy as an auxiliary tool in the differentiation of the main types of erythroderma due to dermatological disorders. *Int J Dermatol*. 2016. In press.
5. Kim GW, Jung HJ, Ko HC, et al. Dermoscopy can be useful in differentiating scalp psoriasis from seborrhoeic dermatitis. *Br J Dermatol*. 2011;164:652–6.
6. Kibar M, Aktan Ş, Bilgin M. Dermoscopic findings in scalp psoriasis and seborrheic dermatitis; two new signs; signet ring vessel and hidden hair. *Indian J Dermatol.* 2015;60:41–5.
7. Xu C, Chen D, Liu J, Liu Y, Sun Q. Roles of dermoscopy in the diagnosis and differential diagnosis of scalp psoriasis and seborrheic dermatitis. *Zhonghua Yi Xue Za Zhi*. 2014;94:3467–70.
8. Nikam VV, Mehta HH. A nonrandomized study of trichoscopy patterns using nonpolarized (contact) and polarized (noncontact) dermatoscopy in hair and shaft disorders. *Int J Trichol*. 2014;6:54–62.
9. Lallas A, Apalla Z, Lefaki I, et al. Dermoscopy of discoid lupus erythematosus. *Br J Dermatol.* 2013;168:284–8.
10. Inui S, Itami S, Murakami M, Nishimoto N. Dermoscopy of discoid lupus erythematosus: report of two cases. *J Dermatol.* 2014;41:756–7.
11. Lopez-Tintos BO, Garcia-Hidalgo L, Orozco-Topete R. Dermoscopy in active discoid lupus. *Arch Dermatol.* 2009;145:358.
12. Lallas A, Apalla Z, Argenziano G, Moscarella E, Longo C, Zalaudek I. Clues for differentiating discoid lupus erythematosus from actinic keratosis. *J Am Acad Dermatol.* 2013;69:e5–6.
13. Giacomel J, Zalaudek I, Argenziano G, Lallas A. Dermoscopy of hypertrophic lupus erythematosus and differentiation from squamous cell carcinoma. *J Am Acad Dermatol.* 2015;72(Supplement):S33–6.
14. Pellicano R, Tiodorovic-Zivkovic D, Gourhant JY et al. Dermoscopy of cutaneous sarcoidosis. *Dermatology*. 2010;221:51–4.
15. Brasiello M, Zalaudek I, Ferrara G, et al. Lupus vulgaris: a new look at an old symptom- the lupoma observed with dermoscopy. *Dermatology*. 2009;218:172–4.
16. Lallas A, Apalla Z, Argenziano G et al. Clues for differentiating discoid lupus erythematosus from actinic keratosis. *J Am Acad Dermatol*. 2013;69:e5–6.
17. Pellicano R, Caldarola G, Filabozzi P, Zalaudek I. Dermoscopy of necrobiosis lipoidica and granuloma annulare. *Dermatology*. 2013.
18. Lallas A, Zaballos P, Zalaudek I et al. Dermoscopic patterns of granuloma annulare and necrobiosis lipoidica. *Clin Exp Dermatol*. 2013;38:425–7.
19. Bakos RM, Cartell A, Bakos L. Dermatoscopy of early-onset necrobiosis lipoidica. *J Am Acad Dermatol*. 2012;66:e143–44, 226:319–23.
20. Errichetti E, De Francesco V, Pegolo E, Stinco G. Dermoscopy of Grover's disease:Variability according to histological subtype. *J Dermatol.* 2016. doi:10.1111/1346-8138.13298.
21. Giacomel J, Zalaudek I, Argenziano G. Dermatoscopy of Grover's disease and solitary acantholytic dyskeratoma shows a brown, starlike pattern. *Australas J Dermatol.* 2012;53:315–6.
22. Sadayasu A, Maumi Y, Hayashi Y, et al. Dermoscopic features of a case of transient acantholytic dermatosis. *Australas J Dermatol.* 2016. doi:10.1111/ajd.12434.
23. Marchetti MA, Fonseca M, Dusza SW, et al. Dermoscopic clues to diagnose acantholytic dyskeratosis. *Dermatol Pract Concept*. 2015;5:11–28.
24. Vázquez-López F, Manjón-Haces JA, Maldonado-Seral C, Raya-Aguado C, Pérez-Oliva N, Marghoob AA. Dermoscopic features of plaque psoriasis and lichen planus: new observations. *Dermatology*. 2003;207:151–6.
25. Zalaudek I, Argenziano G. Dermoscopy subpatterns of inflammatory skin disorders. *Arch Dermatol.* 2006;142:808.
26. Vázquez-López F, Alvarez-Cuesta C, Hidalgo-García Y, Pérez-Oliva N. The handheld dermatoscope improves the recognition of Wickham striae and capillaries in lichen planus lesions. *Arch Dermatol.* 2001;137:1376.
27. Vázquez-López F, Vidal AM, Zalaudek I. Dermoscopic subpatterns of ashy dermatosis related to lichen planus. *Arch Dermatol.* 2010;146:110.
28. Vázquez-López F, Gómez-Díez S, Sánchez J, Pérez-Oliva N. Dermoscopy of active lichen planus. *Arch Dermatol.* 2007;143:1092.
29. Güngör Ş, Topal IO, Göncü EK. Dermoscopic patterns in active and regressive lichen planus and lichen planus variants: a morphological study. *Dermatol Pract Concept*.2015;5:45–53.
30. Friedman P, Sabban EC, Marcucci C, Peralta R, Cabo H. Dermoscopic findings in different clinical variants of lichen planus. Is dermoscopy useful? *Dermatol Pract Concept*.2015;5:51–5.
31. Haldar SS, Khopkar U. Dermoscopy of Lichen Planus. In: Khopkar U, Valia A, editors. *Lichen planus*. 1st edn. New Delhi: Jaypee Brothers Medical Publishers; 2013. pp. 148–62.
32. Coelho de Sousa V, Oliveira A. Inflammoscopy in the diagnosis of hypertrophic lichen planus. *J Am Acad Dermatol.* 2015;73:e171–3.
33. Shim WH, Jwa SW, Song M, et al. Diagnostic usefulness of dermatoscopy in differentiating lichen sclerous et atrophicus from morphea. *J Am Acad Dermatol*.2012;66:690–1.
34. Tiodorovic-Zivkovic D, Argenziano G, Popovic D, Zalaudek I. Clinical and dermoscopic findings of a patient with co-existing lichen planus, lichen sclerosus and morphea. *Eur J Dermatol.* 2012;22:143–4.
35. Moura FN, Thomas L, Balme B, Dalle S. Dermoscopy of lymphomatoid papulosis. *Arch Dermatol.* 2009;145:966–7.
36. Vano-Galvan S, Alvarez-Twose I, De las Heras E, et al. Dermoscopic features of skin lesions in patients with mastocytosis. *Arch Dermatol.* 2011;147:932–40.
37. Akay BN, Kittler H, Sanli H, Harmankaya K, Anadolu R. Dermatoscopic findings of cutaneous mastocytosis. *Dermatology*. 2009;218:226–30.
38. Miller MD, Nery NS, Gripp AC, Maceira JP, Nascimento GM. Dermatoscopic findings of urticaria pigmentosa. *An Bras Dermatol.* 2013;88:986–8.
39. Gutiérrez-González E, Ginarte M, Toribio J. Cutaneous mastocytosis with systemic involvement mimicking clinical and dermatoscopically multiple melanocytic nevi. *Dermatol Online J.* 2011;17:15.
40. Unterstell N, Lavorato FG, Nery NS, Mann D, Alves Mde F, Barcauí C. Dermatoscopic findings in telangiectasia macularis eruptiva perstans. *An Bras Dermatol.* 2013;88:643–5.
41. Navarini AA, Feldmeyer L, Töndury B, et al. The yellow clod sign. *Arch Dermatol.* 2011;147:1350.
42. Lallas A, Apalla Z, Lefaki I, et al. Dermoscopy of early stage mycosis fungoides. *J Eur Acad Dermatol Venereol.* 2013;27:617–21.
43. Conde-Montero E, Avilés-Izquierdo JA, Mendoza-Cembranos MD, Parra-Blanco V. Dermoscopy of necrobiosis lipoidica. *Actas Dermosifiliogr.* 2013;104:534–7.
44. Zaballos P, Puig S, Malvehy J. Dermoscopy of pigmented purpuric dermatoses (lichen aureus): a useful tool for clinical diagnosis. *Arch Dermatol.* 2004;140:1290–1.
45. Zalaudek I, Ferrara G, Brongo S, et al. Atypical clinical presentation of pigmented purpuric dermatosis. *J Dtsch Dermatol Ges*. 2006;4:138–40.

46. Errichetti E, Piccirillo A, Stinco G. Dermoscopy of prurigo nodularis. *J Dermatol.* 2015;42:632–4.
47. Kittisak P, Tanaka M. Dermoscopic findings in a case of reactive perforating collagenosis. *Dermatol Pract Concept*. 2015;5:75–7.
48. Ramirez-Fort MK, Khan F, Rosendahl CO, Mercer SE, Shim-Chang H, Levitt JO.Acquired perforating dermatosis: a clinical and dermatoscopic correlation. *Dermatol Online J.* 2013;19:18958.
49. Errichetti E, Stinco G. The practical usefulness of dermoscopy in general dermatology. *G Ital Dermatol Venereol.* 2015;150:533–34.
50. Errichetti E, Lacarrubba F, Micali G, Piccirillo A, Stinco G. Differentiation of pityriasis lichenoides chronica from guttate psoriasis by dermoscopy. *Clin Exp Dermatol.* 2015;40:804–6.
51. Chuh AA. Collarette scaling in pityriasis rosea demonstrated by digital epiluminescence dermatoscopy. *Australas J Dermatol.* 2001;42:288–90.
52. Chuh AA. The use of digital epiluminescence dermatoscopyto identify peripheral scaling in pityriasis rosea. *Comput Med Imaging Graph.* 2002;26:129–34.
53. Lallas A, Apalla Z, Karteridou A, Lefaki I. Dermoscopy for discriminating between pityriasis rubra pilaris and psoriasis. *J Dermatol Case Rep.* 2013;7:20–2.
54. Lallas A, Apalla Z, Karteridou A, et al. Photoletter to the editor: dermoscopy for discriminating between pityriasis rubra pilaris and psoriasis. *J Dermatol Case Rep.* 2013;7:20–2.
55. Delfino M, Argenziano G, Nino M. Dermoscopy for the diagnosis of porokeratosis. *J Eur Acad Dermatol Venereol*. 2004;18:194–5.
56. Zaballos P, Puig S, Malvehy J. Dermoscopy of disseminated superficial actinic porokeratosis. *Arch Dermatol*. 2004;140:1410.
57. Pizzichetta MA, Canzonieri V, Massone C, et al. Clinical and dermoscopic features of porokeratosis of Mibelli. *Arch Dermatol*. 2009;145:91–2.
58. Uhara H, Kamijo F, Okuyama R, et al. Open pores with plugs in porokeratosis clearly visualized with the dermoscopic furrow ink test: report of 3 cases. *Arch Dermatol.* 2011;147:866–8.
59. Navarrete-Dechent C, Uribe P, Marghoob A. Ink-enhanced dermoscopy is a useful tool to differentiate acquired solitary plaque porokeratosis from other scaly lesions. *J Am Acad Dermatol.* 2019;80(6):e137–e138.
60. Oiso N, Kawada A. Dermoscopic features in disseminated superficial actinic porokeratosis. *Eur J Dermatol*. 2011;21:439–40.
61. Panasiti V, Rossi M, Curzio M, et al. Disseminated superficial actinic porokeratosis diagnosed by dermoscopy. *Int J Dermatol*. 2008;47:308–10.
62. Errichetti E, Piccirillo A, Stinco G. Dermoscopy of prurigo nodularis. *J Dermatol.* 2015;42:632–4.
63. Vazquez-Lopez F, Zaballos P, Fueyo-Casado A, et al. A dermoscopy subpattern of plaque-type psoriasis: red globular rings. *Arch Dermatol*. 2007;143:1612.
64. Zalaudek I, Argenziano G. Dermoscopy subpatterns of inflammatory skin disorders. *Arch Dermatol*. 2006;142:808.
65. Vazquez-Lopez F, Kreusch J, Marghoob AA. Dermoscopic semiology: further insights into vascular features by screening a large spectrum of nontumoral skin lesions. *Br J Dermatol*. 2004;150:226–31.
66. Lallas A, Apalla Z, Tzellos T, et al. Dermoscopy in clinically atypical psoriasis. *J Dermatol Case Rep.* 2012;6.
67. Pan Y, Chamberlain AJ, Bailey M, et al. Dermatoscopy aids in the diagnosis of the solitary red scaly patch or plaque-features distinguishing superficial basal cell carcinoma, intraepidermal carcinoma and psoriasis. *J Am Acad Dermatol*. 2008;59:268–74.
68. Zalaudek I, Argenziano G, Leinweber B et al. Dermoscopy of Bowen's disease. *Br J Dermatol*. 2004;150:1112–16.
69. Campione E, Diluvio L, Terrinoni A, et al. Severe erythrodermic psoriasis in child twins: from clinical-pathological diagnosis to treatment of choice through genetic analyses: two case reports. *BMC Res Notes*. 2014;7:929.
70. Lallas A, Apalla Z, Argenziano G, et al. Dermoscopic Pattern of Psoriatic Lesions on Specific Body Sites. *Dermatology.* 2014;228:250–4.
71. Lacarrubba F, Nasca MR, Micali G. Videodermatoscopy enhances diagnostic capability in psoriatic balanitis. *J Am Acad Dermatol.* 2009;61:1084–6.
72. Gniadecki R, Kragballe K, Dam TN, et al. Comparison of drug survival rates for adalimumab, etanercept and infliximab in patients with psoriasis vulgaris. *Br J Dermatol*. 2011;164:1091–6.
73. Vazquez-Lopez F, Marghoob AA. Dermoscopic assessment of long-term topical therapies with potent steroids in chronic psoriasis. *J Am AcadDermatol.* 2004;51:811–3.
74. Lallas A, Argenziano G, Longo C, et al. Polygonal vessels of rosacea are highlighted by dermoscopy. *Int J Dermatol.* 2014;53:e325–7.
75. Rubegni P, Tataranno DR, Nami N, Fimiani M. Rosettes: optical effects and not dermoscopic patterns related to skin neoplasms. *Australas J Dermatol*. 2013;54:271–2.
76. Llambrich A, Zaballos P, Terrasa F, et al. Dermoscopy of cutaneous leishmaniasis. *Br J Dermatol*. 2009;160:756–61.
77. Vazquez-Lopez F, Maldonado-Seral C, Soler-Sanchez T et al. Surface microscopy for discriminating between common urticaria and urticarial vasculitis. *Rheumatology (Oxford)* 2003;42:1079–82.
78. Vazquez-Lopez F, Fueyo A, Sanchez-Martın J, Perez-Oliva N. Dermoscopy for the screening of common urticaria and urticarial vasculitis. *Arch Dermatol*. 2008;144:568.

13 DIGITAL MONITORING: SHORT- AND LONG-TERM

Harald Kittler and Scott W. Menzies

Contents

Digital dermoscopic monitoring for the detection of early melanoma 309
Short-term monitoring 309
Long-term monitoring. 310
The natural history of melanocytic nevi revealed by digital dermoscopy 311
The risks and the benefits of follow-up. 313
Key points 314
References 315

The diagnosis of the majority of melanocytic skin lesions can be made by dermoscopy with certainty. But even with the use of dermoscopy, the diagnostic accuracy for melanocytic skin lesions is not 100%. When a melanocytic skin lesion is doubtful for melanoma, either by clinical examination or by dermoscopic examination, the lesion is usually excised to rule out the disease. This strategy is adequate for most clinical situations. However, when individuals have multiple, sometimes hundreds, of doubtful melanocytic lesions, it becomes impractical to excise them all. Furthermore, in the common scenario of nevus with a banal dermoscopic appearance presenting with a history of change, excision is not usually necessary. However, in such scenarios, it would be reassuring to both the patient and the physician to know the actual biological dynamics of the lesion(s) in question.

It is generally agreed that patients with multiple nevi need regular skin examinations, including self-skin examination and regular follow-up with their physician for full body skin examination. Photographic closeups of lesions may be used for documentation to assist the patient or physician in the surveillance of moles. The advent of digital imaging equipment has made it easy to store, retrieve, and compare dermoscopic images of melanocytic lesions over time (Figure 13.1). Dermoscopic images of melanocytic skin lesions provide a detailed view of subsurface structures that cannot be identified by conventional photographic closeups. Changes within these subsurface structures can be monitored with digital dermoscopy, improving the diagnostic sensitivity for early melanoma by identifying changes in lesions over time that indicate incipient malignancy while reducing the number of biopsies of benign lesions that are biologically indolent (i.e., senescent, not changing).

Digital dermoscopic monitoring for the detection of early melanoma

Sequential digital dermoscopy imaging (SDDI) is a second-level diagnostic tool that involves repeating digital images of an equivocal lesion over time to detect changes. SDDI requires digital dermoscopic images to be captured at different time points and compared side-by-side on a monitor. SDDI improves the diagnostic accuracy for melanoma; it improves specificity by preventing unnecessary skin biopsies of benign lesions by up to 75% while at the same time, improving sensitivity by identifying "featureless" melanomas based on change (19, 22). Such observations in multiple clinical trials have led to the recommendation for the routine use of SDDI by national guidelines (10, 11, 15, 23) and are frequently used during the surveillance of high-risk patients together with dermoscopy and total body photography (17).

Short-term monitoring

In the study by Menzies et al., digital dermoscopy was used for short-term follow-up of melanocytic skin lesions (16). This study was not restricted to patients with multiple nevi. It included melanocytic lesions, which did not display features of melanoma but were otherwise considered doubtful, for example, because of a recent history of change. In a conventional clinical practice (without the possibility of digital monitoring), these lesions may be excised or require clinical review by other methods. A total of 318 melanocytic skin lesions were followed over a median of 3 months. Any change except for overall solar-induced pigment changes or increase/decrease in the number of milia-like cysts was considered to be a significant change (Table 13.1). Of the monitored lesions, 81% remained unchanged. Sixty-one lesions showed morphologic changes. All changing lesions were excised. Of the 61 changing lesions, seven (11% of changed and 2% of total lesions) were found to be early melanoma (five in situ and two invasive with a Breslow thickness of 0.25 and 0.28 mm, respectively). According to the authors, none of these melanomas developed any classic clinical or dermoscopic features of melanoma and therefore, could be identified only by morphologic change recognizable on comparative analysis. The authors concluded that short-term monitoring is a useful adjunct in the assessment of melanocytic lesions, since it enables early detection of featureless melanomas while decreasing the need for excision of clinically suspicious benign lesions.

Since these initial observations, larger series on short-term SDDI have confirmed the identification of dermoscopic featureless melanoma using short-term (6 weeks to 4.5 months) monitoring (2, 3, 5, 9, 12, 13). The interval for short-term SDDI is usually 3 months, and it requires digital dermoscopic images of a suspicious melanocytic lesion to be captured and compared at each time point (i.e., 0 and 3 months) (1). Importantly, no specific type of morphologic change can distinguish melanoma from nevi when lesions are monitored over this short duration; therefore, any change during this period leads to excision of the lesion (Figures 13.1, 13.2) (11). In fact, studies have shown that up to one-third of melanomas discovered via SDDI are featureless (8, 17), and the majority of benign lesions

DOI: 10.1201/9780429487873-41

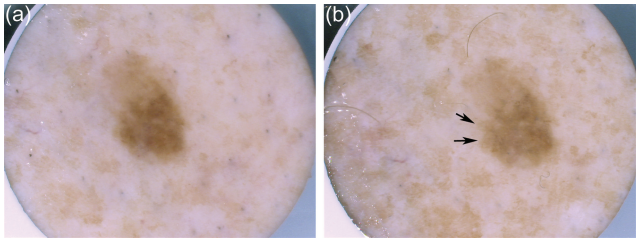

FIGURE 13.1 (a) Short-term monitoring—baseline image. (b) Short-term monitoring—3-month follow-up image. The arrows indicate the focal increase in size and internal architectural change of the lesion. Any change during the short-term monitoring period (2.5–4.5 months) requires excision. Diagnosis: in situ melanoma.

tend to remain unchanged at 2.5–4.5 months (2). It needs to be highlighted that although 94% of melanomas (non–lentigo maligna type) were observed to change during the short-term interval (2.5–4.5 months), only 75% of lentigo maligna change at this time interval. For this reason, a second monitored interval between 6 and 12 months following the baseline image is recommended when lentigo maligna is in the differential diagnosis (2).

The use of short-term SDDI to detect featureless melanomas is recommended to assess suspicious melanocytic lesions that are flat or slightly raised (1, 11). Lesions that are raised or nodular are not appropriate for SDDI, and such lesions should be excised. (14)

Long-term monitoring

The study by Kittler et al. (2000) was tailored for patients with multiple doubtful melanocytic skin lesions. These patients have an increased risk of developing melanoma and were under life-long regular surveillance skin examinations. In a cohort study including 202 patients with multiple melanocytic nevi, 1862 melanocytic lesions were monitored with digital dermoscopy over a median period of 1 year. Interestingly, 96% of the lesions remained stable over time or showed minor, nonsubstantial changes, for example, darker or lighter overall pigmentation (Table 13.1). This finding is important because it shows that even for patients with multiple nevi, in the vast majority of lesions, substantial changes will not occur; patients can thus be reassured. Substantial changes occurred in 75 melanocytic skin lesions (4%), of which 8 were histologically diagnosed as early melanomas.

The interval for long-term SDDI monitoring is usually 6–12 months. In contrast to short-term SDDI, long-term SDDI requires specific changes for the lesion to be excised, including substantial changes such as (Table 13.1):

- Asymmetric change
- Change in shape or color, other than overall pigment lightening or darkening
- Melanoma-specific structures

Nonsignificant changes included:

- Darker or lighter overall appearance
- Change in number or distribution of brown globules
- Decrease in number of black dots
- Disappearance of inflammatory reaction
- Disappearance of parts of the network and replacement with diffuse brown pigmentation (NB: Although this change was considered nonsignificant, it should be noted that this change can also be seen in slow-growing melanomas; 2, 4, 21)

All melanomas identified during follow-up were thinner than 0.75 mm, and five of the eight melanomas were in situ. Six of the eight patients with melanoma were unaware that the lesion had changed over time, confirming that patients have difficulties in detecting subtle changes in lesions. Two melanomas in this study did not enlarge but showed changes only in their dermoscopic structures. Thus, these tumors probably would have been missed or detected much later in the clinical course if followed only by conventional clinical photography. Other studies on long-term follow-up showed similar results, although there was some variation in the ratio of excised melanomas and monitored lesions (6, 7, 8, 18, 20). The changes observed by SDDI are more pronounced when the follow-up intervals are longer. This is true for melanocytic nevi but also for melanomas. In contrast to short-term SDDI, in long-term SDDI, changes observed in melanomas

TABLE 13.1: Classification of Changes

Change	Short-term mole monitoring (3 months)	Long-term mole monitoring (6–12 months)
Significant	Any change other than nonsignificant changes	Asymmetric enlargement
		Focal changes in pigmentation or structure
		Regression features
		Change in color
Nonsignificant global change in pigmentation		Darker or lighter overall appearance
		Change in number or distribution of brown globules
		Decrease in number of black dots
Loss or appearance of milia-like cysts		Disappearance of inflammatory reaction
		Disappearance of small foci of pigment network within central portion of the lesion and replacement by diffuse brown pigmentation

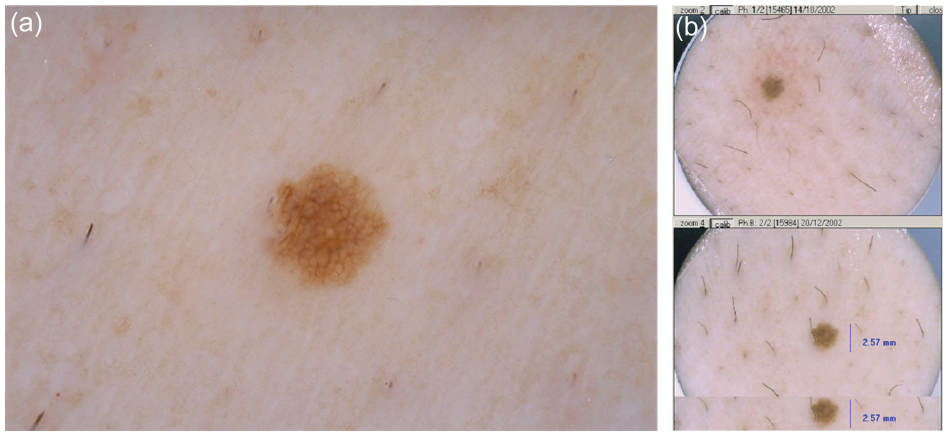

FIGURE 13.2 (a) Baseline image. The advantage of short-term monitoring is that lesions that would normally be observed, such as this dermoscopically banal lesion, can be monitored in the appropriate clinical setting. This 2.5 mm-diameter lesion on the anterior tibia was noted to be new and changing by this 38-year-old woman. Under dermoscopic examination, it is seen as a symmetrical lesion with graduated network at the periphery. However, because of the history of change, the lesion was monitored. (b). Short-term monitoring—baseline image and 2.5-month follow-up image. Here, the lesion has clearly enlarged over the short-term follow-up. Diagnosis: in situ melanoma. Nearly two-thirds of melanomas detected by short-term monitoring lack specific dermoscopy features of melanoma.

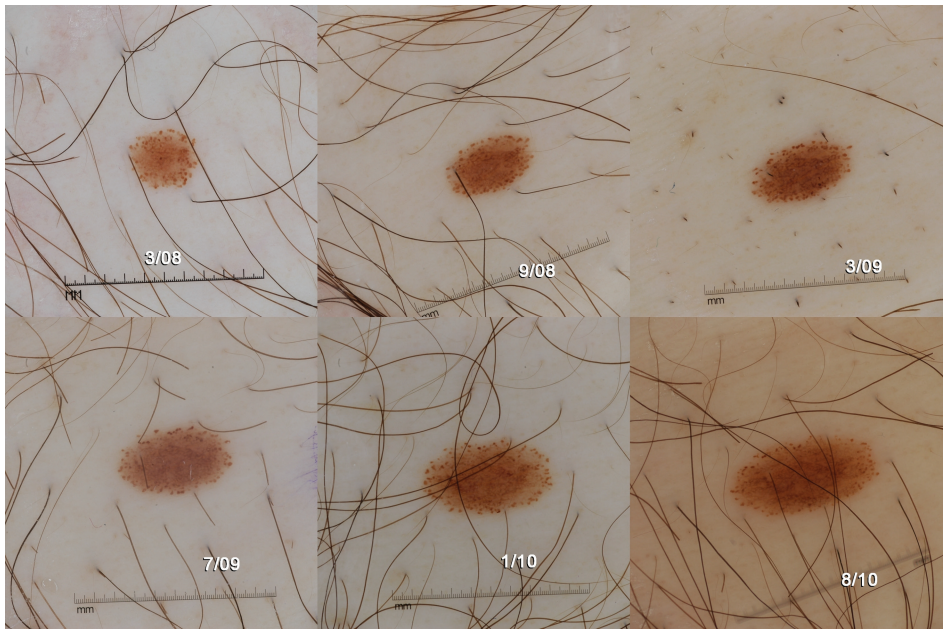

FIGURE 13.3 This lesion manifested with a peripheral rim of globules. This pattern is predictive of a growing nevus as can be seen in the images provided.

are different from those observed in nevi. Melanomas more frequently grow asymmetrically (change in size and shape), whereas nevi more frequently grow symmetrically (change in size but not in shape). Structural changes (appearance of new structures) and color changes (appearance of new colors) are more frequently observed in melanomas than in nevi. The interpretation of follow-up images, therefore, strongly depends on the length of the observation period, with longer follow-up intervals increasing the chances of detecting new melanomas (19). The use of long-term SDDI is recommended for routine surveillance of high-risk patients (1). Therefore, an appropriate selection of patients for long-term SDDI is important.

The natural history of melanocytic nevi revealed by digital dermoscopy

In contrast to melanomas enlarging, melanocytic nevi typically show symmetrical enlargement without structural changes. The dermoscopic sign of a peripheral rim of brown globules is highly characteristic for symmetrically enlarging melanocytic nevi in youth but can also be found in eruptive nevi in immunocompromised patients, for example, after renal transplantation (Figure 13.3). As long as these lesions manifest a single row of peripheral brown globules, develop in younger individuals (Figure 13.4), and do not display any melanoma-specific structures (e.g., atypical network, negative network,

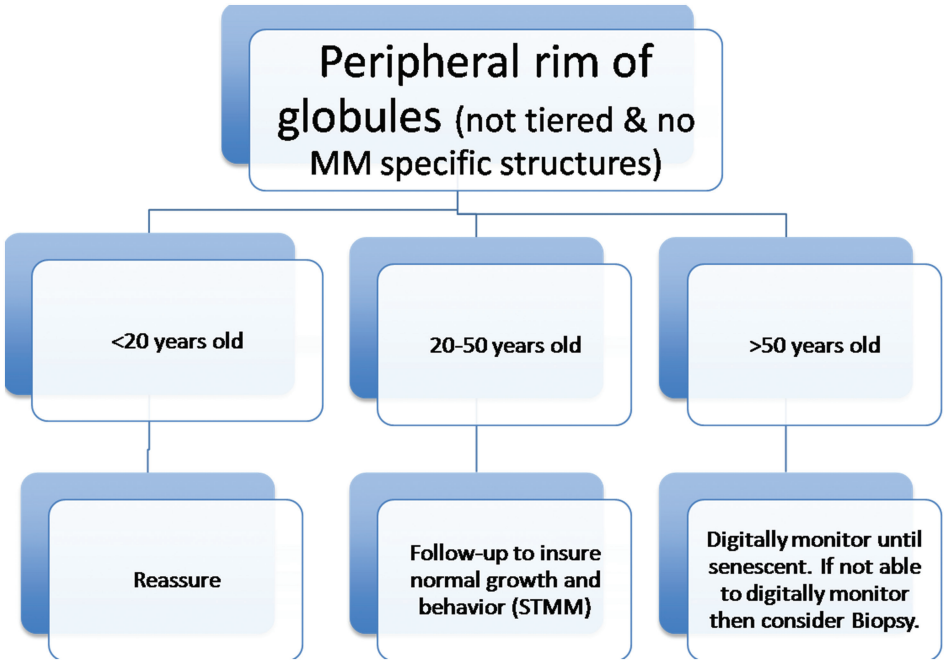

FIGURE 13.4 In a recent study (24), the management approach for nevi with a peripheral rim of globules was outlined. The authors noted that this pattern was common in youth; then, its prevalence started to decline rapidly after the third decade of life, and it was not observed at all after the sixth decade of life. Based on these observations, this management algorithm was proposed.

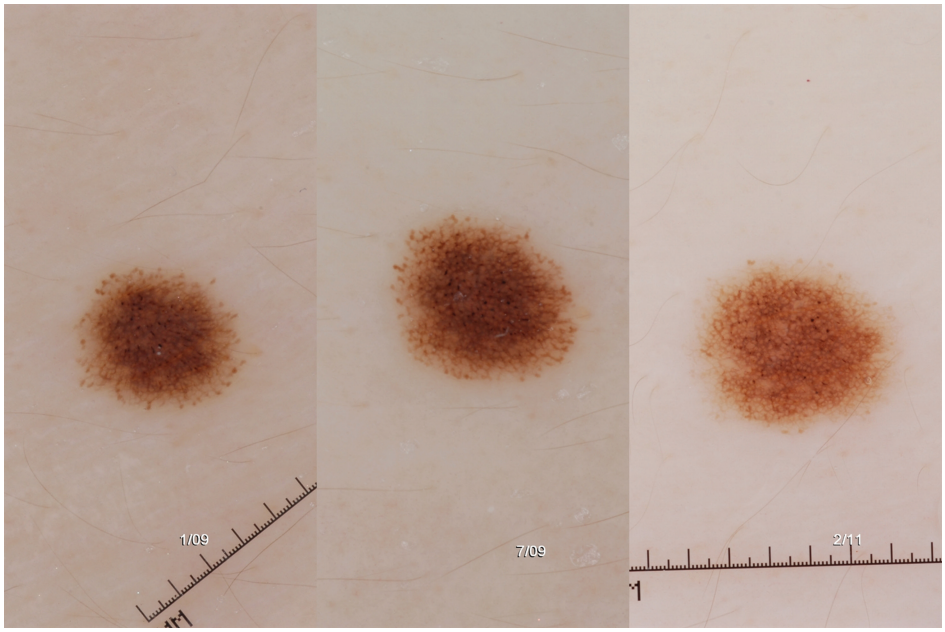

FIGURE 13.5 This lesion had a peripheral rim of small brown globules. The lesion grew in a symmetric fashion. Once it stopped growing, the peripheral rim of globules was no longer present, and the lesion only revealed network (reticular pattern).

atypical streaks, shiny white lines, atypical dots and globules, irregular blotch, blue-white veil, regression structures, atypical vessels, and peripheral brown structureless areas), then there is no need for the excision of these lesions. These nevi represent benign nevi that are growing in a radial (horizontal) plane (Figure 13.3). Once these nevi enter senescence, the peripheral globules are no longer visible, and the nevus will usually manifest a reticular or homogeneous pattern (Figure 13.5). Further scrutiny of these enlarging nevi reveals that most contain relatively small, homogeneous, brown peripheral globules that have the same color as the rest of the nevus. Furthermore, the rest of the nevus will usually have a reticular or homogeneous pattern (Figures 13.3, 14.5). Histopathology and confocal microscopy have shown that the peripheral globules correspond to junctional nevomelanocytic nests at the tips of rete ridges in Clark-type nevi. In contrast to the nevus with a single row of peripheral globules, nevi with multiple rows of peripheral globules as seen in Figure 13.6 (also known as tiered

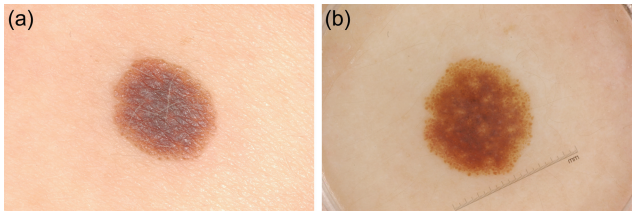

FIGURE 13.6 (a) Clinical image of a Spitz nevus. (b) This lesion has a starburst pattern consisting of a peripheral rim of tiered globules. Tiered globules consist of one peripheral rim of globules staked on top of another.

globules) are classified as lesions having a starburst pattern (see Chapter 7e on Spitz nevus). The starburst pattern, whether created by tiered globules or by streaks, is usually associated with Spitz/Reed nevus. However, both the peripheral globular pattern and the starburst pattern are signs of active radial growth occurring in these nevi. Thus, it can be anticipated that nevi manifesting the aforementioned patterns will enlarge, usually in a symmetric fashion, and once the radial growth phase is over and the nevus has entered senescence, the peripheral globules, streaks, or tiered globules will no longer be visible (Figure 13.5).

Although most growing nevi enlarge in a symmetric fashion, some show asymmetrical enlargement (Figure 13.7). We generally recommend biopsy of these lesions to rule out melanoma. Loss of pigmentation may occur in a melanocytic nevus, resulting in partial to complete disappearance (Figure 13.8). Although this process can occur in youth, it is more common to see it in adults and elderly individuals. It represents the last step in the natural evolution history of a melanocytic nevus and is termed *involution*. This process should not be called regression, because regression is an active process with inflammation occurring in lesions with a halo reaction or with dermoscopic regression structures.

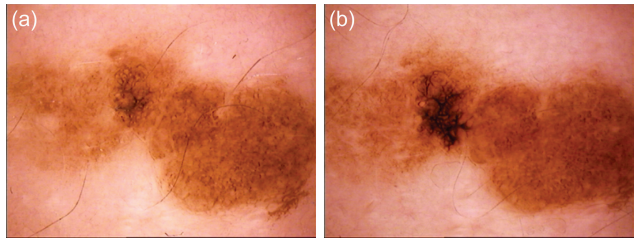

FIGURE 13.9 (a, b) Melanoma in situ arising in a congenital nevus. (a) Baseline image; (b) after 4 months.

Finally, with digital monitoring, we can on occasion observe a melanoma arising in a congenital nevus. An example of a melanoma in situ arising in a congenital nevus is shown in Figure 13.9.

The risks and the benefits of follow-up

The availability of follow-up images improves the detection rate for melanoma while at the same time reducing the excision rate of benign lesions (9, 15). However, the utility of sequential imaging critically depends on patient compliance with follow-up. If the patient does not come back to follow-up, the loss of sensitivity may prove problematic (9). In addition, sensitivity is also lost when the melanoma is not detected or is missed because the change was not identified or was erroneously considered insignificant. It is anticipated that artificial intelligence applications detecting change will remove such human errors. In the common scenario of mildly suspicious nevi, which would normally be observed or excised depending on patient preference, the use of short-term digital monitoring will allow the detection of incipient melanoma in a subset of these lesions while reducing excisions of benign nevi. In selected patients with numerous doubtful melanocytic lesions, excision of all doubtful lesions might not be feasible. Instead, a close follow-up with clinical images and digital dermoscopy

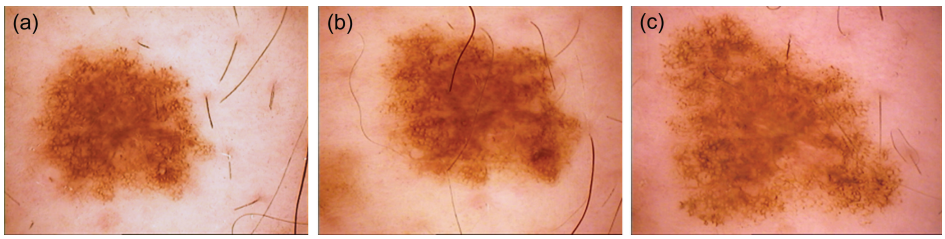

FIGURE 13.7 (a–c) Asymmetrically enlarging melanocytic nevus. These lesions are usually excised to rule out melanoma. (a) Baseline image; (b) 1-year follow-up; (c) 2-year follow-up.

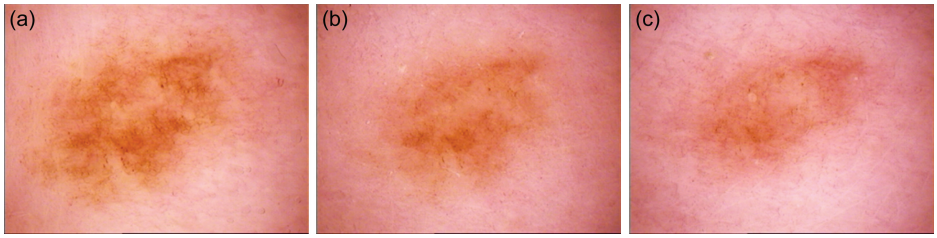

FIGURE 13.8 (a–c) Loss of pigmentation in a melanocytic nevus (involution). (a) Baseline image; (b) after 6 months; (c) after 1 year.

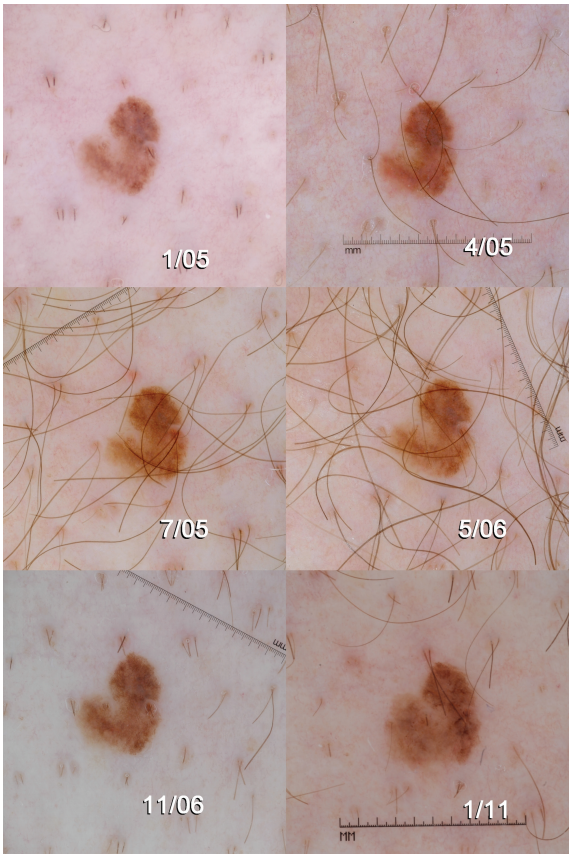

FIGURE 13.10 Long-term monitoring: This is a lesion that was digitally monitored over 6 years. This is a slow-growing melanoma manifesting change in shape, size, and color. This lesion was biopsied and was a 0.15 mm-thick melanoma.

may be offered, depending on the patient's preferences and the physician's judgment of the patient's compliance.

Key points

1. SDDI reduces the benign to malignant biopsy ratio and the number of benign lesions being excised while improving the diagnostic sensitivity of melanoma by identifying dermoscopically "featureless" melanoma.
2. Digital dermoscopic follow-up is restricted to flat or slightly raised melanocytic lesions that are only mildly atypical.
3. *Any* morphologic change seen at three 3 months from baseline (short-term monitoring) requires excision. Over 90% of melanomas and approximately 15% of nevi will display change within 3 months. Between 10% and 30% of changed lesions will prove to be melanoma, and up to one-third of these melanomas will not reveal any melanoma-specific structures.
4. About 75% of lentigo maligna will change within 3 months. In 25% cases of lentigo maligna melanoma, the changes develop more gradually, and thus, a longer follow-up interval is necessary to detect these melanomas. We are of the opinion that a 6- to 12-month follow-up interval will suffice for detecting most lentigo maligna melanomas.
5. In general, changes are more pronounced during long-term follow-up.
6. When follow-up is six 6 months or longer, any lesion with an increase in size (more frequently asymmetric), appearance of new structures, or appearance of new colors requires excision to rule out melanoma (Figures 13.10, 13.11).

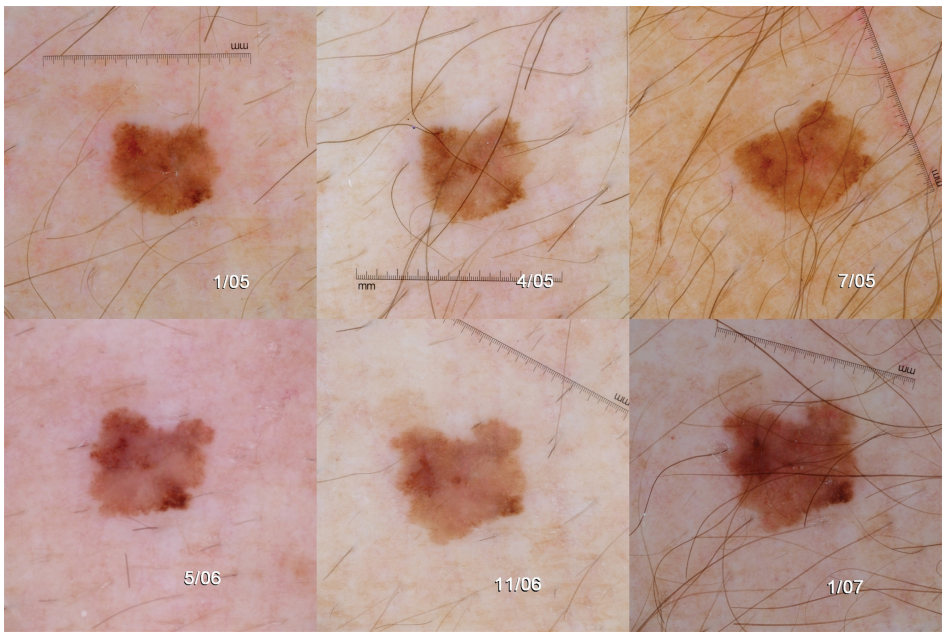

FIGURE 13.11 Long-term monitoring: This slow-growing melanoma was digitally monitored for 2 years. Concern for melanoma was obvious at the first 3-month monitoring interval, but the patient refused to have the lesion biopsied. Notice that there are marked changes in size, shape, and color. The lesion has also developed changes in dermoscopic structures. This lesion was eventually biopsied and was a 0.2 mm melanoma. This lesion and the one in Figure 13.10 highlight that a delay in diagnosis does not necessarily equate with a worse prognosis.

References

1. Adler NR, Kelly JW, Guitera P, Menzies SW, Chamberlain AJ, Fishburn P, Button-Sloan AE, Heal C, Soyer HP, Thompson JF. Methods of melanoma detection and of skin monitoring for individuals at high risk of melanoma: new Australian clinical practice. *Med J Aust*. 2019;210(1):41–7.
2. Altamura D, Avramidis M, Menzies SW. Assessment of the optimal interval for and sensitivity of short-term sequential digital dermoscopy monitoring for the diagnosis of melanoma. *Arch Dermatol*. 2008;144:502–6.
3. Argenziano G, Kittler H, Ferrara G, et al. Slow-growing melanoma: a dermoscopy follow-up study. *Br J Dermatol*. 2010;162:267–73.
4. Argenziano G, Zalaudek I, Ferrara G. Fast-growing and slow-growing melanomas. *Arch Dermatol*. 2007;143:802–3; author reply 803–4.
5. Banky JP, Kelly JW, English DR, Yeatman JM, Dowling JP. Incidence of new and changed nevi and melanomas detected using baseline images and dermoscopy in patients at high risk for melanoma. *Arch Dermatol*. 2005;141:998–1006.
6. Bauer J, Blum A, Strohhäcker U, Garbe C. Surveillance of patients at high risk for cutaneous malignant melanoma using digital dermoscopy. *Br J Dermatol*. 2005;152:87–92.
7. Fuller SR, Bowen GM, Tanner B, Florell SR, Grossman D. Digital dermoscopic monitoring of atypical nevi in patients at risk for melanoma. *Dermatol Surg*. 2007;33:1198–206; discussion 1205–6.
8. Haenssle HA, Krueger U, Vente C, et al. Results from an observational trial: digital epiluminescence microscopy follow-up of atypical nevi increases the sensitivity and the chance of success of conventional dermoscopy in detecting melanoma. *J Invest Dermatol*. 2006;126(5):980–5.
9. Kittler H, Binder M. Risks and benefits of sequential imaging of melanocytic skin lesions in patients with multiple atypical nevi. *Arch Dermatol*. 2001;137:1590–5.
10. Kittler H, Binder M Follow-up of melanocytic skin lesions with digital dermoscopy: risks and benefits. *Arch Dermatol*. 2002;138:1379.
11. Kittler H, Guitera P, Riedl E, et al. Identification of clinically featureless incipient melanoma using sequential dermoscopy imaging. *Arch Dermatol*. 2006;142:1113–9.
12. Kittler H, Pehamberger H, Wolff K, Binder M. Follow-up of melanocytic skin lesions with digital epiluminescence microscopy: patterns of modifications observed in early melanoma, atypical nevi, and common nevi. *J Am Acad Dermatol*. 2000a;43:467–76.
13. Kittler H, Seltenheim M, Dawid M, et al. Frequency and characteristics of enlarging common melanocytic nevi. *Arch Dermatol*. 2000b;136:316–20.
14. Lin MJ, Mar V, McLean C, Kelly JW. An objective measure of growth rate using partial biopsy specimens of melanomas that were initially misdiagnosed. *J Am Acad Dermatol*. 2014;71(4):691–7.
15. Menzies SW, Chamberlain A, Guitera P, Soyer HP, Cancer Council Australia Melanoma Guidelines Working Party. What is the role of sequential digital dermoscopy imaging in melanoma diagnosis? *Clinical Guidelines Network*;2018. Retrieved December, 2019.
16. Menzies SW, Gutenev A, Avramidis M, Batrac A, McCarthy WH. Short-term digital surface microscopic monitoring of atypical or changing melanocytic lesions. *Arch Dermatol*. 2001;137:1583–9.
17. Moloney FJ, Guitera P, Coates E, Haass NK, Ho K, Khoury R, O'Connell RL, Raudonikis L, Schmid H, Mann GJ, Menzies SW. Detection of primary melanoma in individuals at extreme high risk: a prospective 5-year follow-up study. *JAMA Dermatol*. 2014;150(8):819–27.
18. Robinson J, Nickoloff B. Digital epiluminescence microscopy monitoring of high-risk patients. *Arch Dermatol*. 2004;140:49–56.
19. Salerni G, Terán T, Puig S, Malvehy J, Zalaudek I, Argenziano G, Kittler H. Meta-analysis of digital dermoscopy follow-up of melanocytic skin lesions: a study on behalf of the International Dermoscopy Society. *J Eur Acad Dermatol Venereol*. 2013;27(7):805–14.
20. Schiffner R, Schiffner-Rohe J, Landthaler M, Stolz W. Long-term dermoscopic follow-up of melanocytic naevi: clinical outcome and patient compliance. *Br J Dermatol*. 2003;149:79–86.
21. Terushkin V, Dusza SW, Scope A, et al. Changes observed in slow-growing melanomas during long-term dermoscopic monitoring. *Br J Dermatol*. 2012;166:1213–20.
22. Tromme I, Sacré L, Hammouch F, Legrand C, Marot L, Vereecken P, Theate I, van Eeckhout P, Richez P, Baurain JF, Thomas L, Speybroeck N, D. s. Group. Availability of digital dermoscopy in daily practice dramatically reduces the number of excised melanocytic lesions: results from an observational study. *Br J Dermatol*. 2012;167(4): 778–86.
23. Watts CG, Dieng M, Morton RL, Mann GJ, Menzies SW and Cust AE. Clinical practice guidelines for identification, screening and follow-up of individuals at high risk of primary cutaneous melanoma: a systematic review. *Br J Dermatol*. 2015;172(1): 33–47.
24. Zalaudek I, Karin S, Marghoob A, et al. Frequency of dermoscopic nevus subtypes by age and body site: a cross-sectional study. *Arch Dermatol*. 2011;147:663–70.



Taylor & Francis
Taylor & Francis Group
http://taylorandfrancis.com

INDEX

Note: Page locators followed by "f" refer to figures and "t" refer to tables.

A

ABCD rule 72, 220, 221*t*
Absence of follicular openings, 35
Acquired nevi, 153, 239
Acquired pili torti, 286
Acrolentiginous melanoma
  algorithms, 197
  with focal benign patterns, 197
  malignant dermoscopy patterns, 198*f*
    atypical fibrillar pattern, 197
    brown color and serrated pattern, 196, 199*f*, 200*f*
    milky-red pattern, 197
    multicomponent pattern, 197, 200*f*
    parallel ridge pattern, 196, 197*f*–200*f*, 201
  palms and soles, anatomy of, 196, 197*f*
  size, 197
Acrolentiginous melanoma (ALM), 262
AC rule, 86, 87*f*–88*f*
Actinic keratosis (AK), 58, 63, 102
  dermoscopic features, 102
    nonvascular features, 102, 103*f*, 104*f*
    pigmented features, 105, 105*f*, 106, 106*f*
    vascular features, 102, 104*f*, 105, 105*f*, 106*f*
Adnexal neoplasms, 133
  eccrine poroma, 133
    clinical presentation, 133
    dermoscopic features, 133–134, 134*f*, 135*t*
    differential diagnosis, 134
    histopathology, 133
    treatment and management, 134, 134*f*
Agminated/plaque-type BN, 164, 165*f*
AK, *see* Actinic keratosis
Alopecia areata (AA), 34, 279, 288–289
Alopecia areata incognita, 289
Amelanotic/hypomelanotic NM, 203, 204*f*
Amelanotic melanoma, 181–182, 181*f*, 182*f*, 213–214*f*, 277
  vascular structures, 210, 211–212*t*, 214
Amelanotic nodular melanoma, 189, 189*f*
Amelanotic pattern
  nevoid melanomas, 204
  spitzoid melanomas, 205
American Cancer Society guidelines, 225
Anatomic site, 232–233
Androgenetic alopecia, 287, 288
Aneurysmal dermatofibroma, 91, 92*f*–95*f*, 239
Angiokeratomas, 29, 57, 127
  dermoscopic characteristics, 127–128, 127*f*, 128*f*
Angioma-like pattern, 29, 57
  epidermotropic (skin) metastasis, 207–208, 208*f*
Angulated lines pattern, 191, 192, 194
Annular-granular pattern, 19, 191, 191*f*, 192*f*
Annular pattern, 243, 244*f*
Arborizing vessels, 26, 241, 283–284, 284*f*
ASTs, *see* Atypical Spitz tumors
Asymmetric follicular openings, 191, 192*f*, 194
Asymmetric nodular lesions, 174
Asymmetric pigmentation, 19, 20*t*
Asymmetry, 220
  of pattern and structures, 86
Atrophic dermatofibromas, 93, 95
Atypical dermatofibromas, 239
Atypical dots, 180, 182*f*–184*f*
Atypical fibrillar pattern, acrolentiginous melanoma, 197
Atypical globules, 180, 184*f*
Atypical network, 86, 180, 181*f*–184*f*
Atypical pigment network, 11
Atypical Spitz tumors (ASTs), 171, 173
  dermoscopy, 173*f*
Atypical vessels, 59

B

Background pigmentation, nail
  brown background pigmentation, 271
  gray background pigmentation, 271–272, 271*f*, 272*f*
Balloon cell melanoma, 207
Balloon cell nevi (BCN), 155, 155*f*
  dermoscopic characteristics, 177, 179*f*
Banal and atypical/dysplastic nevi, 153
BAP1-inactivated melanocytic tumor (BIMT), 12
Bapoma, 12
Basal cell carcinomas (BCC), 4, 5*f*, 11, 44, 58, 97, 237, 240–241, 243, 245*f*
  arborizing vessels, 26
  blue-gray dots, 24, 26*f*
  blue-gray globules, 24, 26*f*
  blue-gray ovoid nests, 24, 26*f*
  concentric globules, 24
  dermoscopic structures, 97, 98*t*
    histologic subtype prediction, 101
    in pigmented BCCs, 97–99, 98*f*, 99*f*
    in pigmented/nonpigmented BCC, 99–101, 99*f*, 100*f*
  diagnostic accuracy of dermoscopy, 97
  erosions, 24, 26*f*
  leaf-like areas, 24, 24*f*, 25*t*
  multiple aggregated yellowish to whitish globules (MAY globules), 24, 26, 28*f*
  shiny white blotches and strands, 24, 28*f*
  spoke wheel areas, 24, 24*f*, 25*t*–26*t*
  treatment selection and monitoring, 101
  ulcerations, 24, 26*f*
BCN, *see* Balloon cell nevi
Benign dermoscopy patterns, 254–255
  fibrillar pattern, 256–257, 258*f*, 259*f*
  globular pattern, 258, 260*f*
  homogeneous pattern, 258, 260*f*
  lattice-like pattern, 256, 258*f*
  nontypical pattern, 258, 261*f*
  parallel furrow pattern, 255–256, 257*f*, 258*f*
  pod pattern, 258, 260*f*
  reticular pattern, 258, 260*f*
Benign lesions, 50, 243
  acquired and small congenital nevi, 50, 54*f*–55*f*, 55–56
  IDN and dermatofibroma, 56–57
  seborrheic keratosis and solar lentigo, 57
Benign nevus patterns, 216, 217
Benign vascular lesions, 259, 261*f*, 262
BIMT, *see* BAP1-inactivated melanocytic tumor
Birefringence of collagen, 4
Black dots, 34, 35*f*, 282, 282*f*
  and clods, 75, 75*f*
Black lamella, 149
Blood vessels, 142
Blotches, 13–15, 17*f*, 18*f*
Blue-black rule, 86–87, 88*f*
Blue globules, 11
Blue-gray dots, 24, 26*f*, 34–35, 35*f*
Blue-gray globules, 24, 26*f*
Blue-gray ovoid nests, 24, 25*t*, 26*f*
Blue lesions, 164
Blue nevus (BN), 164, 165*f*, 239
  dermoscopy, 164, 165*f*
  diagnostic techniques, 166
  differential diagnosis, 166–167, 167*f*, 167*t*
  epidermotropic (skin) metastasis, 207, 208*f*
  special locations, 164, 165*f*
  variants
    agminated/plaque-type BN, 164, 165*f*
    cellular BN, 165, 166*f*
    combined BN, 165–166, 166*f*
    compound BN, 166
    deep penetrating nevi, 166, 166*f*
    epithelioid BN, 166
    malignant BN, 166
    sclerotic BN, 164–165
Blue ovoid nests, 43
Blue-white structures, 86
Blue-whitish veil (BWV), 18, 19*f*, 180, 181*f*–184*f*
BN, *see* Blue nevus
Border sharpness, 220
Bowenoid actinic keratosis, 112, 112*f*
BRAAFF algorithm, 197, 201*t*
Branched lines, 42
Brown dots, 241
Brown globules, 43
Brown perifollicular discoloration, 284–285, 285*f*
Brown-pigmented bands, 276, 276*f*
  irregular pattern, 273*f*, 274*f*, 276
  regular pattern, 272*f*, 276
BWV, *see* Blue-whitish veil

C

Cadaverized hairs, 34
Capturing dermoscopic images, 6–7
CASH algorithm, 221–222, 222*t*
CCA, *see* Clear cell acanthoma
Cellular BN, 165, 166*f*
Centered vessels pattern, 67
Central white patch, 26*t*, 29–30, 30*f*
Chaos, 45, 46, 49, 70, 72–73
  of border, 72
  of color, 72
  of pattern, 72

Cherry hemangiomas, 125
Chronically sun-damaged skin (CSDS)
  dermoscopic findings, melanomas on, 190–191, 191*f*
  dermoscopic structures
    melanomas on facial skin, 191, 192*f*, 193*t*
    melanomas on nonfacial skin, 192, 193*t*
  differential diagnoses
    flat seborrheic keratosis, 194
    lichen planus–like keratosis (LPLK), 194
    pigmented actinic keratosis (PAK), 192
    solar lentigines, 194
  melanomas on sun-damaged skin, 190
Circumferential peripheral clods, 71
Clark's/dysplastic nevi, 56
Classic white dots, 283
Clear cell acanthoma (CCA), 30, 57–58, 132
  clinical presentation, 132
  dermoscopic features, 133, 133*f*
  differential diagnosis, 133
  histopathology, 132–133
  treatment and management, 133, 133*f*
CLM, *see* Cutaneous larva migrans
Clods pattern, 67, 69
Clonal SK, 239
Cloud structures, 30
Clues, 47*f*, 48*f*, 49
  angulated lines, 78, 78*f*
  black dots and clods, 75, 75*f*
  eccentric structureless area, 74, 75*f*
  gray/blue structures, 73, 74*f*, 75*f*
  lines parallel on ridges, 76, 77*f*
  lines radial/pseudopods, 75, 76*f*
  polymorphous vessels, 76, 77, 77*f*, 78, 78*f*
  thick lines reticular, 74–75, 75*f*
  white lines, 76, 76*f*, 77*f*
CMN, *see* Congenital melanocytic nevi
CNLN, *see* Congenital nevus–like nevi
Cobblestone globules pattern, 140
  melanocytic nevi, 150
Cobble stones, 43
Cockade nevi, 176
  dermoscopic characteristics, 177, 178*f*
Cold sensitivity test, 275
Collagen, 10
Collision tumors and exceptions
  false negatives
    hemangioma-like melanoma, 240, 241*f*
    pyogenic granulomas, 240
    seborrheic keratosis–like melanomas, 239–240, 240*f*
  false positives
    collision tumors, 239, 240*f*
    dermatofibroma, 239, 239*f*
    hemangiomas, 239
    seborrheic keratosis, 238–239
  nonaccurate skin cancer diagnoses
    basal cell carcinoma (BCC), 240–241
    squamous cell carcinomas (SCC), 241–242
Colors, 43, 220
Combined BN, 165–166, 166*f*
Combined nevus, 155–156
Comedo-like openings, 26*t*, 29, 29*f*
Compound BN, 166
Concentric circles, 19, 20*t*
Concentric globules, 24
Concentric isobar pattern, 191
Confluent globules, 139
Congenital lesions, 125
Congenital melanocytic nevi (CMN), 154
  clinical characteristics, 139
  dermoscopic features, 142–144, 143*f*, 144*f*
    blood vessels, 142
    hypertrichosis, 142
    milia-like cysts, 142
    perifollicular hyperpigmentation, 142, 143
  dermoscopy, 139–142, 140*f*–142*f*
    globules, 139, 141*f*
    network, 139
    presence of both network and globules, 141–142
  management of, 144–145
  melanoma, risk of, 144
  variants, 144
Congenital nevi, 239, 276–277
Congenital nevus–like nevi (CNLN), 139
Contact dermoscopy, 4, 90
Crista intermedia, 253
Crista limitans, 253
Cross-polarization, 3
Cross-polarized detector filter, 3
Cross-polarized system, 3
Crown vessels, 30, 31*f*, 135
Crypts, 29, 57
Crystalline structures, 4
CSDS, *see* Chronically sun-damaged skin
Curved lines, 42
Cutaneous angiosarcoma, 129
  dermoscopic characteristics, 130*f*
Cutaneous larva migrans (CLM), 297, 297b
Cutaneous neoplasms
  melanocytic neoplasms, 10–18
    located on special sites, 18–24
  nonmelanocytic neoplasms, 24–31
Cutaneous sarcoidosis, 306, 306*f*
Cutaneous warts, 294, 296*f*

D

Dark blotches, 19
Dark brown triangular structures, 32, 34, 34*f*
Dark dots/globules, 28
Decision algorithm for nonpigmented skin lesions, 61
  prediction without pigment algorithm, 62, 62*f*
    ulceration, 62, 62*f*, 63*f*
    vessel pattern consistent with malignancy, 64–65, 66*f*–68*f*, 67–69
    white clues, 62–64, 63*f*–65*f*
  red flags, 61
Decision algorithm for pigmented lesions, 70
  dermatoscopic decision algorithm, 72, 73*f*
    chaos, 70, 71*f*, 72, 73*f*, 74*f*
    clues, 73–78
    exceptions, 78–80
  red flags, 70
    clinical pattern-breaker, 71
    dermatoscopic clues to change, 71–72, 72*f*
    dermatoscopic uniqueness, 72, 72*f*
    patient concern/clinical evidence of change, 70
Deep penetrating nevi, 166, 166*f*
Dermal epidermal junction (DEJ), 3, 11, 180
Dermatofibromas (DFs), 7, 57, 90, 239, 239*f*
  central white patch, 29–30, 30*f*
  dermoscopic patterns, 90–91, 91*f*–93*f*, 95*t*
  peripheral delicate network, 30, 30*f*
  ring-like globules, 30
  variants, 90–95
Dermatoscope, 1, 2
Dermatoscopic chaos, 70
Dermatoscopy, 2
Dermoscopic camera lenses, 6
Dermoscopic differential diagnosis, 13
Dermoscopic patterns, 90–91, 91*f*–93*f*, 95*t*
Dermoscopic structures, 220
  histologic subtype prediction, 101
  in pigmented BCCs, 97
    large blue-gray ovoid nests, 98, 98*f*
    leaf-like structures, 98–99, 99*f*
    multiple blue-gray dots, 97, 98*f*
    multiple blue-gray nonaggregated globules, 97–98, 98*f*
    spoke wheel–like structures/concentric globule, 99, 99*f*
  in pigmented/nonpigmented BCCs
    arborizing telangiectasia/short-fine telangiectasia, 99–100, 99*f*, 100*f*
    multiple aggregated yellow-white (MAY) globules, 100–101, 100*f*
    shiny white blotches and strands, 100, 100*f*
    ulceration/erosions, 100, 100*f*
Dermoscopy, 1, 2, 10; *see also individual entries*
  colors, 10, 10*f*, 11*f*
  diagnostic accuracy, 97
  histological correlates
    diagnostic improvement, 35–36
    histologic subtypes and guiding treatment, 36
    prognostic information, 36
  light source and technique, 90, 91*f*, 92*f*, 94*f*
Desmoplastic melanoma (DM), 203
  dermoscopic characteristics, 204, 204*f*
DFs, *see* Dermatofibromas
Diagnosis, 43
Diagnostic accuracy, dermoscopic algorithms, 222, 223*t*
Diffuse granular pattern, 250
Diffuse gray dots, 30, 30*f*
Diffuse network/reticular pattern, 50
Diffuse reticular pattern, 139
Digital dermoscopic monitoring, 309
  melanocytic nevi revealed by, 311–313, 311*f*
  risks and benefits, 313–314
Digital dermoscopy, 263
Direct dermoscopy, nail matrix, 24
Discoid lupus erythematosus (DLE), 290, 300, 300*f*
Discoloration, 284–285
Disorganized lesions, 58–59
Dissecting cellulitis, 290–291
DLE, *see* Discoid lupus erythematosus
DM, *see* Desmoplastic melanoma
Doorway melanoma, 230
Dots, 13, 16*f*
Dotted-globular pattern, 22
Dotted vessels, 68, 210, 283, 284*f*

E

Eccentric structureless area, 74, 75*f*
Eccrine ducts, 253

Eccrine poroma, 133
clinical presentation, 133
dermoscopic features, 133–134, 134*f*, 135*t*
differential diagnosis, 134
histopathology, 133
treatment and management, 134, 134*f*
Eclipse nevus, 157
dermoscopic characteristics, 158*f*
Ectoparasitic diseases
cutaneous larva migrans (CLM), 297, 297b
lice infestations, 294–295, 296*f*
scabies, 294, 296*f*
tick bites, 295–296, 296*f*
tungiasis, 296–297
Eczematous reaction, 176
Empty follicles, 35, 281
Entomodermoscopy, 32, 294
Entomology, 32
Epidermal structures, 4
Epidermolysis bullosa nevi, 177–178
Epidermotropic (skin) metastasis, 207–208, 208*f*
Epithelioid BN, 166
EQ, *see* Erythroplasia of Queyrat
Equivocal lesions, 58
disorganized lesions, 58–59
organized lesions, 59
Erosions, 24, 26*f*
Erythroplasia of Queyrat (EQ), 112, 113*f*
EVD, *see* Ex vivo dermoscopy
Exceptions, 78–80, 79*f*–80*f*
Exostosis, 278
Ex vivo dermoscopy (EVD), 35, 36

F

Face
facial melanoma, 246, 247*f*, 248*f*, 249, 249*f*
melanocytic facial lesions, 243, 245
melanoma simulators
facial lichen planus–like keratosis, 250, 250*f*, 251*f*
pigmented actinic keratosis, 249, 250*f*
pigmented basal cell carcinoma, 250, 251*f*
nonmelanocytic facial lesions, 243
pigmented nonmelanocytic facial lesions, 243, 245
solar lentigines, 245, 246*f*
Facial lichen planus–like keratosis, 250, 250*f*, 251*f*
Facial melanoma, 246, 247*f*, 248*f*, 249, 249*f*
Facial skin, 18–19, 21*f*
False negatives
hemangioma-like melanoma, 240, 241*f*
pyogenic granulomas, 240
seborrheic keratosis–like melanomas, 239–240, 240*f*
False positives
collision tumors, 239, 240*f*
dermatofibroma, 239
hemangiomas, 239
seborrheic keratosis, 238–239
Fibrillar pattern, 22
benign dermoscopy patterns, 256–257, 258*f*, 259*f*
Fibroepithelioma of Pinkus, 58
Fingerprint-like areas, 116, 117*f*, 118*f*
Fish scale–like pattern, 21*t*, 22
Fissures, 25*t*, 29
Flat amelanotic melanoma, 206, 207*f*
Flat seborrheic keratosis, 194
Follicular filiform spicules, 283, 283*f*
Follicular keratotic plugs, 35
Follicular melanoma, 207
Follicular mucinosis, 283, 283*f*
Follicular ostia, 281–283
Follicular plugs with halo (FPWH), 102
Folliculitis decalvans, 290
FPWH, *see* Follicular plugs with halo
Fried egg nevus type, 150
Fungal diseases
tinea corporis (TC), 297, 297*f*
tinea nigra (TN), 297, 297*f*
vellus hairs, 297, 297*f*
Furrows, 253

G

Globular pattern
benign dermoscopy patterns, 258, 260*f*
congenital melanocytic nevi (CMN), 141
melanocytic nevi, 149–150, 149*f*, 150*f*
mucosal surfaces, 263, 266*f*
Globules, 11–13, 12*t*, 15*f*, 16*f*, 241, 241*f*
cobblestone pattern, 139
globular pattern, 141
Glomus cell tumors, 277–278
Granularity/peppering, 15
Granuloma annulare, 300, 301*f*
Gray background pigmentation, 271–272, 271*f*, 272*f*
Gray-blue granularity, 4
Gray/blue structures, 73, 74*f*, 75*f*
Gray dots, 49, 243
Gray-pigmented band, 275–276
Grover's disease, 301, 301*f*
Growing nevi, 153–154

H

Hair and scalp
blood vessels, 283–284
exogenous materials on scalp, 287
follicular ostia, 281–283
hair shaft disorders, 286–287
hair shaft patterns, 286
inflammatory scalp diseases, 291
nonscarring alopecia, 287–290
perifollicular and interfollicular skin surface, 284–285
scaling, 285–286
scarring alopecia, 290–291
trichoscopy
algorithms in, 291
dermoscope for diagnosis, 281
trichoscopy, dermoscope for diagnosis, 281
in vivo reflectance confocal microscopy, application, 290*f*, 291
Hair follicles (HF), 102
Hairpin vessels, 57, 210
Hair shaft abnormalities, 286
Hair shaft diameter heterogeneity, 286, 286*f*
Hair shaft disorders, 286–287
Hair shaft patterns, 286
Hair tufting, 286, 286*f*
Halo nevi, 154–155, 155*f*
dermoscopic characteristics, 176, 178*f*
Hemangioma-like melanoma, 240, 241*f*
Hemangiomas, 57, 125, 239
dermoscopic characteristics, 125, 126*f*, 127*f*
Hemosiderotic dermatofibromas, 239
HF, *see* Hair follicles
Hildreth's test, 275
Homogeneous blue color, 56
Homogeneous blue pattern, 12*t*, 13, 17*f*
Homogeneous blue pigmentation, 241
Homogeneous brown, 56
Homogeneous light brown pigmentation, 116, 118*f*
Homogeneous pattern, 20*t*, 22
benign dermoscopy patterns, 258, 260*f*
melanocytic nevi, 150–151, 151*f*
Reed nevus, 170, 171*f*
Homogeneous tan/pink, 56
Honeycomb pigment pattern, 285, 285*f*
Hutchinson's sign and variants
atypical Hutchinson's sign, 273
Hutchinson's and micro-Hutchinson's sign, 273, 273*f*
pseudo-Hutchinson's sign, 272, 272*f*
Hybrid dermatoscopes, 3, 4, 6
Hypertrichosis, 142
Hyphal pattern, 21*t*, 22
Hypomelanotic/amelanotic BN, 165
Hypomelanotic melanoma, 213–214*f*
vascular structures, 210, 211–212*t*, 214

I

IDN, *see* Intradermal nevi
IDS, *see* International Society of Dermoscopy
IEC, *see* Intraepidermal carcinoma
Infantile hemangiomas, 125
Infectious diseases
dermoscopic patterns associated with skin infections and infestations, 294, 295*t*
ectoparasitic diseases
cutaneous larva migrans (CLM), 297, 297b
lice infestations, 294–295, 296*f*
scabies, 294, 296*f*
tick bites, 295–296, 296*f*
tungiasis, 296–297
entomodermoscopy, 294
fungal diseases
tinea corporis (TC), 297, 297*f*
tinea nigra (TN), 297, 297*f*
vellus hairs, 297, 297*f*
viral diseases
cutaneous warts, 294, 296*f*
molluscum contagiosum (MC), 294, 295*f*
Infectious skin diseases, 32, 33*f*
molluscum contagiosum, 32
scabies, 32
warts, 32
Inflamed seborrheic keratosis, 238
Inflammatory dermatoses
cutaneous sarcoidosis, 306, 306*f*
dermatitis, 299, 300*f*
discoid lupus erythematosus (DLE), 300, 300*f*
seborrheic dermatitis, 300, 300*f*
granuloma annulare, 300, 301*f*
Grover's disease, 301, 301*f*
lichen planus (LP), 301, 301*f*
lichen sclerosus (LS), 301, 302*f*
lymphomatoid papulosis (LyP), 301–302, 302*f*
mastocytosis, 302, 302*f*
mycosis fungoides (MF), 302, 302*f*

necrobiosis lipoidica, 302, 303*f*
perforating dermatoses, 303, 303*f*
pigmented purpuric dermatoses, 303, 303*f*
pityriasis lichenoides, 303, 303*f*
pityriasis rosea, 303, 303*f*
pityriasis rubra pilaris, 304, 304*f*
porokeratosis, 304, 304*f*
prurigo nodularis, 304, 305*f*
psoriasis, 304–305, 305*f*
dermoscopy, treatment monitoring, 305, 305*f*
site-specific disease types, 305
rosacea, 306, 306*f*
urticaria and urticarial vasculitis, 306, 306*f*
Inflammoscopy, 31, 31*t*
dermatitis, 32, 32*f*
granulomatous skin diseases, 32, 33*f*
lichen planus, 32, 32*f*
psoriasis, 31, 31*f*
rosacea, 32
Ink spot lentigines, 116
Ink spot lentigo, 238
Inner gray halo, 29
Interfollicular changes, 19
International Society of Dermoscopy (IDS), 42
Intradermal nevi (IDN), 19, 56–57, 99
eclipse nevus, 157
dermoscopic characteristics, 158*f*
miescher nevus, 157
dermoscopic characteristics, 157–158, 159*f*
unna nevus, 158–159, 160*f*
dermoscopic characteristics, 159, 160*f*–162*f*, 163
Intraepidermal carcinoma (IEC), 110
Invasive squamous cell carcinoma, 112–114, 113*f*, 114*f*
Inverse network, *see* Negative network
Involution, 313
Irregular blotches, 13
Irregularly distributed red dots, 32, 32*f*
Irregular pattern, 24

K

Kaposi's sarcoma (KS), 129
dermoscopic characteristics, 129*f*
Keratinizing tumors
circles in linear arrangement, 28
dark dots/globules, 28
inner gray halo, 29
rosettes, 28*f*, 29
scales, 29
strawberry pattern, 28, 28*f*
white circles, 25*t*, 28
Keratoacanthoma (KA), 58, 112, 113*f*
KS, *see* Kaposi's sarcoma

L

Lacunae, 29, 29*f*, 30*f*
Lassueur–Graham Little syndrome, 290
Lattice-like pattern, 21
benign dermoscopy patterns, 256, 258*f*
LC, *see* Lymphangioma circumscriptum
Leaf-like areas, 24, 24*f*, 25*t*, 241
LEDs, *see* Light-emitting diodes
Lentigo maligna (LM), 11, 59, 102, 109, 110
Leukonychia, 273
Lice infestations, 294–295, 296*f*
Lichen planopilaris (LPP), 35, 290
Lichen planus (LP), 32, 32*f*, 279, 301, 301*f*
Lichen planus-like keratosis (LPLK), 15, 99, 121–122, 194
diffuse granular pattern, 122, 123*f*
diffuse gray dots, 30, 30*f*
localized granular pattern, 123, 123*f*
pink to orange macule, shiny white lines, 123, 123*f*
Lichen sclerosus (LS), 301, 302*f*
dermoscopic characteristics, 177, 178*f*
Light-emitting diodes (LEDs), 2
Linear vessels, 65
Lines parallel on ridges, 76, 77*f*
Lines radial/pseudopods, 75, 76*f*
Lipidized dermatofibromas, 93*f*, 94*f*, 95
LM, *see* Lentigo maligna
LM melanoma (LMM), 190
Localized granular pattern, 250
Localized subungual hyperkeratosis, 274
Longitudinal erythronychia, 274
Longitudinal xantho-leukonychia, 273
Long-term monitoring, 310–311, 314*f*
Love's test, 274
LP, *see* Lichen planus
LPLK, *see* Lichen planus-like keratosis
LPP, *see* Lichen planopilaris
LS, *see* Lichen sclerosus
Lymphangioma, 57
Lymphangioma circumscriptum (LC), 128
dermoscopic characteristics, 128*f*
Lymphomatoid papulosis (LyP), 301–302, 302*f*

M

Malignant BN, 166
Malignant lesions, 243
Malignant neoplasms, 61
Mastocytosis, 302, 302*f*
MAY globules, *see* Multiple aggregated yellowish to whitish globules
MC, *see* Molluscum contagiosum
Melanin, 10, 61
Melanoacanthoma, 238
Melanocyte hyperplasia, 275
Melanocytic activation, 23
Melanocytic facial lesions, 243, 245
Melanocytic lesions, 22
dermoscopy of, 254, 255*f*, 257*f*
Melanocytic neoplasms
angulated lines, 11, 15*f*
blotches, 13–15, 17*f*, 18*f*
blue-whitish veil, 18, 19*f*
dots, 13, 16*f*
globules, 11–13, 15*f*, 16*f*
homogeneous blue pattern, 13, 17*f*
located on special sites, 18, 20*f*–21*f*
facial skin, 18–19, 21*f*
mucosal sites, 22–23, 23*f*
nails, 23–24, 23*f*
volar skin, 19, 21–22, 22*f*
negative network, 11, 12*t*, 14*f*–15*f*
pigmented network, 10–11, 12*t*, 13*f*, 14*f*, 14*t*
regression structures, 15, 18*f*, 19*f*
shiny white structures, 15–18, 19*f*
streaks, 13, 16*f*, 17*f*
Melanocytic nevi
acquired nevi, 153
balloon cell nevus, 155, 155*f*
banal and atypical/dysplastic nevi, 153
combined nevus, 155–156
congenital melanocytic nevi (CMN), 154
dermatoscopic patterns, 146–148, 147*f*, 147*t*, 148*f*, 149*f*
globular pattern, 149–150, 149*f*, 150*f*
growing nevi, 153–154
halo nevi, 154–155, 155*f*
homogeneous pattern, 150–151, 151*f*
multicomponent nevi, 152–153, 153*f*
peripheral reticular with central globules pattern, 150
reticular/patchy reticular pattern, 146–149, 148*f*
starburst pattern, 151–152, 152*f*
traumatized nevus, 155, 155*f*
two-component pattern, 152
ultraviolet radiation, 155
Melanocytic proliferation, 23
Melanoma, 59
risk of, CMN, 144
specific criteria, 216, 218*t*
specific structures, 216, 218*f*
Melanoma simulators
facial lichen planus–like keratosis, 250, 250*f*, 251*f*
lichen sclerosus nevi, dermoscopic characteristics, 177, 178*f*
pigmented actinic keratosis, 249, 250*f*
pigmented basal cell carcinoma, 250, 251*f*
recurrent nevi
dermoscopic characteristics, 177, 178*f*
vs. recurrent melanoma, 177, 177*t*
Melanoma subtypes
balloon cell melanoma, 207
desmoplastic melanoma (DM), 203
dermoscopic characteristics, 204, 204*f*
epidermotropic (skin) metastasis, 207–208, 208*f*
featureless/structureless melanoma, 208, 208*f*
flat amelanotic melanoma, 206, 207*f*
follicular melanoma, 207
nested melanoma, 207
nevoid melanoma, 204
dermoscopic characteristics, 204, 205*f*
nodular melanoma (NM)
amelanotic/hypomelanotic NM, 203, 204*f*
dermoscopic characteristics, 202
pigmented NM, 202–203
pigmented epithelioid melanocytoma, 207
polypoid melanoma, 206–207
primary dermal melanoma, 206
spitzoid melanoma, 204–205
dermoscopic characteristics, 205, 205*f*
verrucous melanoma, 205–206, 206*f*
Melanonychia striata, 23
Menzies method, 220, 221*t*, 222
Meyerson's nevi, dermoscopic characteristics, 176
MF, *see* Mycosis fungoides
Micro-Hutchinson's sign, 23, 273, 273*f*
Miescher nevus, 157
dermoscopic characteristics, 157–158, 159*f*
Milia-like cysts, 25*t*, 29, 29*f*, 142
Milky-red pattern, acrolentiginous melanoma, 197

Molluscum contagiosum (MC), 32, 294, 295*f*
Monilethrix, 286
Monomorphic red dots, 31, 32*f*
Monomorphous vessel patterns, 65, 67
Moth-eaten border, 116, 117*f*
MTS, *see* Muir-Torre syndrome
Mucosal sites, 22–23, 23*f*
Mucosal surfaces, dermoscopic evaluation, 263, 264*f*–266*f*, 267
Mucous membranes, 263
Muir-Torre syndrome (MTS), 135
Multicomponent nevi, 152–153, 153*f*
Multicomponent pattern, 23, 170, 171*f*
  acrolentiginous melanoma, 197, 200*f*
  mucosal surfaces, 263, 266*f*, 267*f*
  nevoid melanomas, 204
Multiple aggregated yellowish to whitish globules (MAY globules), 24, 26, 28*f*
Multiple colors, 180, 182*f*–184*f*
Multiple image database programs, 7
Multiple roset, 29
Multiple vessels, 65
Mycosis fungoides (MF), 302, 302*f*

N

Nail apparatus melanoma (NAM), 23
Nail matrix
  acquired nevi of, 276
  benign epithelial tumors
    onychomatricoma, 277, 278*f*
    onychopapilloma, 277
  blue nevus of, 277
  congenital nevus of, 276–277
  malignant epithelial tumors, 277
  melanoma of
    amelanotic melanoma, 277
    pigmented variant, 277
Nail plate dermoscopy, 277
Nails, 23–24, 23*f*
  alopecia areata, 279
  dermoscopic examination, 269
    background pigmentation, 271–272
    blood spots, 270–271, 270*f*, 271*f*
    of free edge of nail plate, 269–270
    Hutchinson's sign and variants, 272–273, 272*f*, 273*f*
    localized subungual hyperkeratosis, 274
    longitudinal erythronychia, 274
    longitudinal splinter hemorrhages, 273–274
    longitudinal xantho-leukonychia, 273
    of nail matrix, 270
    parallel micro-lines, 272, 272*f*, 273*f*
    polychromia, 274
    spots, 274–275
  diagnostic approach
    brown-pigmented bands, 276, 276*f*
    gray-pigmented band, 275–276
    melanocytic process, 275
    melanocytic *vs.* nonmelanocytic process, 275, 275*f*
  drug-induced pigmentation, 279
  ethnic-type pigmentations, 279
  fungal infections, 279, 279*f*
  lichen planus, 279
  nail tumors
    exostosis, 278
    glomus cell tumors, 277–278
    nail matrix (*see* nail matrix)
    nail unit lentigo, 276
  onychotillomania, 278–279
  patient history and general physical examination, 269
  psoriasis, 279
  subungual hemorrhage, 278
  warts, 279
NAM, *see* Nail apparatus melanoma
Necrobiosis lipoidica, 302, 303*f*
Negative network, 11, 12*t*, 14*f*–15*f*, 15, 59, 81, 169, 180, 184*f*
Nested melanoma, 182–183, 207
Network
  diffuse reticular pattern, 139
  and globules
    central globules with peripheral network, 141
    multiple structures, 142
    structureless/homogeneous pattern, 142
    target network pattern with globules in holes, 141
  patchy reticular pattern, 139
Nevi, signature pattern, 233
Nevi *vs.* melanoma
  improve sensitivity and specificity in melanoma diagnosis, 230–232
    dermoscopic monitoring, 234
    lesion morphology by patient-related factors, 232–233, 232*f*
    melanoma risk, 233–234, 233*f*
    patient concern, 234
    practical considerations, 235
    reflectance confocal microscopy (RCM), 234–235, 235*f*
    total body photography, 234
  pattern analysis, 216–219
  rules, avoid missing melanoma
    combine clinical, dermoscopic, and histologic criteria, 226, 228
    excise doubtful nodular lesions, 226, 227*f*
    excise lesions revealing spitzoid features, 226, 228*f*
    look as many lesions as possible, 224
    multiple moles, compare and monitor, 225–226, 227*f*
    10 second rule, evaluate single lesions, 225
    undress high-risk patients, 224–225
  rules and algorithms
    ABCD rule, 220, 221*t*
    CASH algorithm, 221–222, 222*t*
    Menzies method, 220, 221*t*, 222
    seven-point checklist method, 220–221, 222*t*
Nevoid melanoma, 204
  dermoscopic characteristics, 205*f*
Nevus-associated melanomas, 182
Nevus-like pattern
  epidermotropic (skin) metastasis, 207, 208*f*
  nevoid melanomas, 204
Nevus spilus, 144
Nevus spilus maculosus, 144
Nevus spilus papulosis, 144
NMs, *see* Nodular melanomas
Nodular amelanotic melanomas, 210
Nodular melanomas (NMs), 187–189, 187*f*, 188*f*
  amelanotic/hypomelanotic NM, 203, 204*f*
  dermoscopic characteristics, 202
  pigmented NM, 202–203
Nonaccurate skin cancer diagnoses
  basal cell carcinoma (BCC), 240–241
  squamous cell carcinomas (SCC), 241–242
Noncontact dermoscopy, 4
Nonmelanocytic facial lesions, 243
Nonmelanocytic lesions
  actinic keratosis, 102–106, 108–110
  adnexal neoplasms, 133–134
  basal cell carcinoma, 97–101
  Bowen's disease, 110–112
  clear cell acanthoma, 132–133
  dermatofibroma, 90–95
  invasive squamous cell carcinoma, 112–114
  keratoacanthoma, 112
  lichen planus–like keratosis (LPLK), 121–123
  sebaceous neoplasms, 134–136
  seborrheic keratoses, 116–118, 120, 121
  solar lentigines, 116
  vascular lesions, 125–131
Nonmelanocytic neoplasms, 25*t*–26*t*
  angiokeratoma, 29
  angioma, 29
  basal cell carcinoma, 24–28
  clear cell acanthoma, 30
  dermatofibroma, 29–30
  keratinizing tumors, 28–29
  lichen planus-like keratosis, 30
  porokeratosis, 31
  sebaceous neoplasms, 30–31
  seborrheic keratoses, 29
Nonmelanocytic tumors, 167
Nonpigmented actinic keratosis, 58–59, 109, 109*f*, 110*f*
Nonpigmented Bowen's disease, 110–111, 111*f*
Nonpigmented Spitz nevus, 169, 170*f*
Nonpigmented structures, 58
Nonpolarized dermoscopy (NPD), 2–3, 2*f*, 3*f*, 90
Nonscarring alopecia, 287–290
Nonspecific dermoscopic structures, 27*t*–28*t*
Nonspecific pattern, epidermotropic (skin) metastasis, 208
Nontypical pattern, benign dermoscopy patterns, 258, 261*f*
Nonvascular features, AK
  follicular plugs with halo (FPWH), 102, 103*f*, 104*f*
  rosettes, 102, 103*f*
  scales, crusts, and structureless areas, 102, 103*f*, 104*f*
NPD, *see* Nonpolarized dermoscopy

O

Onychomatricoma, 277, 278*f*
Onychopapilloma, 277
Onychotillomania, 278–279
Orange-yellowish patches, 32, 33*f*
Organized lesions, 59

P

PAK, *see* Pigmented actinic keratosis
Palmoplantar skin, 19
Palms and soles
  benign dermoscopy patterns, 254–255

fibrillar pattern, 256–257, 258*f*, 259*f*
globular pattern, 258, 260*f*
homogeneous pattern, 258, 260*f*
lattice-like pattern, 256, 258*f*
nontypical pattern, 258, 261*f*
parallel furrow pattern, 255–256, 257*f*, 258*f*
pod pattern, 258, 260*f*
reticular pattern, 258, 260*f*
benign vascular lesions, 259, 261*f*, 262
melanocytic lesions, dermoscopy of, 254, 255*f*, 257*f*
subcorneal hemorrhage, 259, 261*f*
volar skin
anatomy of, 253, 254*f*
malignant dermoscopy pattern, 259
Papillomatous nevus, 159
Parallel furrow pattern, 19, 20*t*, 255–256, 257*f*, 258*f*
Parallel lines, 42
Parallel pattern, 21*t*, 22
mucosal surfaces, 263, 264*f*–266*f*
Parallel ridge pattern, 20*t*, 21
acrolentiginous melanoma, 196, 197*f*–200*f*, 201
Patchy network/reticular pattern, 50, 55
Patchy reticular pattern, 139
Pattern analysis, 42
basic elements, 42, 43*f*
patterns formed, 42–43, 44*f*–46*f*, 45*t*
Chaos and Clues, 45
colors, 43, 46*f*
PBD, *see* Pigmented Bowen's disease
PD, *see* Polarized dermoscopy
PDT, *see* Photodynamic therapy
Pediculus humanis capitis, 294
PEM, *see* Pigmented epithelioid melanocytoma
Peppering, 4, 180
Perceived similarity clusters (PSCs), 233
Perforating dermatoses, 303, 303*f*
Perifollicular hyperpigmentation, 142, 143
Peripheral annular double-rim, 31, 31*f*
Peripheral black dots and clods, 49
Peripheral delicate network, 30, 30*f*
Peripheral light brown structureless areas, 180, 181*f*–184*f*
Peripheral network
with central brown globules, 55
with central hyperpigmentation, 55
with central hypopigmentation, 55
reticular pattern, 56
Peripilar hair casts, 35
Peripilar sign, 35
PG, *see* Pyogenic granuloma
Photodynamic therapy (PDT), 101
Phthirus pubis, 294
Pigmented actinic keratosis (PAK), 59, 105, 109–110, 110*f*, 192, 249, 250*f*
Pigmented basal cell carcinoma, 250, 251*f*
Pigmented basal keratinocytes, 28
Pigmented Bowen's disease (pBD), 28, 111–112, 112*f*
Pigmented epithelioid melanocytoma (PEM), 207
Pigmented invasive squamous cell carcinoma, 114, 114*f*
Pigmented lesions, algorithms for, 86
AC rule, 86, 87*f*–88*f*
blue-black rule, 86–87, 88*f*
chaos and clues, 87–89, 88*f*
three-point checklist, 86, 87*f*–88*f*, 87*t*
Pigmented network, 10–11, 12*t*, 13*f*, 14*f*, 14*t*, 90, 116, 117*f*
Pigmented NM, 202–203
Pigmented pattern, spitzoid melanomas, 205
Pigmented purpuric dermatoses (PPDs), 303, 303*f*
Pigmented Spitz nevus, 169–170, 170*f*
Pigmented structures, 58
Pili annulati, 287
Pili canaliculi et trianguli, 287
Pili torti, 286
Pili torti et canaliculi, 286
Pilomatricoma, 136
clinical presentation, 136
dermoscopic features, 137
differential diagnosis, 137, 137*f*
histopathology, 137
treatment and management, 137
Pink (milky-red) areas, 285, 285*f*
Pinpoint white dots, 34, 35*f*, 283
Pityriasis lichenoides, 303, 303*f*
Pityriasis rubra pilaris, 304, 304*f*
Plantar warts, 294
Pod pattern, benign dermoscopy patterns, 258, 260*f*
Polarized dermoscopy (PD), 3–4, 4*f*, 90
vs. nonpolarized dermoscopy, 4–6, 5*f*–7*f*, 5*t*
Polarized light, 3, 4, 263
Polychromia, 274
Polygonal vessels, 32
Polymorphous vessels, 49, 76, 77, 77*f*, 78, 78*f*, 241–242
Polypoid melanoma, 206–207
Popcorn-like structures, 30, 31*f*
Porokeratosis, 31, 304, 304*f*
Port-wine stain (PWS), 127
PPDs, *see* Pigmented purpuric dermatoses
Prediction without pigment algorithm, 61, 62, 62*f*, 89
ulceration, 62, 62*f*, 63*f*
vessel pattern consistent with malignancy, 64–65, 66*f*–68*f*, 67–69
white clues, 62–64, 63*f*–65*f*
Primary dermal melanoma, 206
Primary diagnostic algorithms
decision algorithm for nonpigmented skin lesions, 61–69
pattern analysis revised, 42–49
top-down 2-step pattern analysis algorithm, 50–59
Protection shield, 263
Proximal nail matrix, 23
Prurigo nodularis, 304, 305*f*
PSCs, *see* Perceived similarity clusters
Pseudo-Hutchinson's sign, 272, 272*f*
Pseudonetwork pattern, 11, 19, 20*t*, 116, 118*f*
Pseudopelade, 291
Pseudopods, 13
Purple spot, 274–275
PWS, *see* Port-wine stain
Pyogenic granuloma (PG), 128–129, 240
dermoscopic characteristics, 128–129, 128*f*

R

Radial lines, 42
RCM, *see* Reflectance confocal microscopy
Recurrent nevi
dermoscopic characteristics, 177, 178*f*
vs. recurrent melanoma, 177, 177*t*
Red corona, 32
Red dots, 13, 282*f*, 283
Red flags, 61
Red lacunes, 43
Red spot, 274
Reed nevus, 169, 170–171, 170*f*
Reed's nevi, 13
Reflectance confocal microscopy (RCM), 234–235, 235*f*
Regression structures, 15, 18*f*, 19*f*, 59
Regular blotch, 13
Regular brown pattern, 24
with dots/globules/blotches, 24
Regular gray pattern, 24
Regular pigment blotch, 149
Reticular lines, 42
Reticular pattern, 244*f*, 245
benign dermoscopy patterns, 258, 260*f*
Reed nevus, 170, 171*f*
Reticular vessels pattern, 67
Revised pattern analysis, 70
Ridges, 25*t*, 29, 29*f*, 253
Ring-like globules, 30, 90
Ring-like pattern, 21*t*, 22
mucosal surfaces, 263, 264*f*
Rosacea, 306, 306*f*
Rosettes, 16, 17–18, 28*f*, 29, 102

S

Scabies, 32, 294, 296*f*
Scales, 29
Scarlike areas, 180
Scarlike depigmentation, 15
Scarring alopecia, 290–291
SCC, *see* Squamous cell carcinomas
Sclerotic BN, 164–165
SDDI, *see* Sequential digital dermoscopic imaging
Sebaceous adenoma, 135
clinical presentation, 135
dermoscopic features, 135, 137*f*
differential diagnosis, 136
histopathology, 135
treatment and management, 136
Sebaceous hyperplasia, 57, 134, 243, 245*f*
clinical presentation, 134
dermoscopic features, 135, 135*f*
differential diagnosis, 135, 136*t*
histopathology, 135
treatment and management, 135
Sebaceous neoplasms, 134, 136*t*
crown vessels, 30, 31*f*
popcorn-like structures, 30, 31*f*
sebaceous adenoma, 135
clinical presentation, 135
dermoscopic features, 135, 137*f*
differential diagnosis, 136
histopathology, 135
treatment and management, 136
sebaceous hyperplasia, 134
clinical presentation, 134
dermoscopic features, 135, 135*f*
differential diagnosis, 135, 136*t*
histopathology, 135
treatment and management, 135
Seborrheic dermatitis, 300, 300*f*
Seborrheic keratosis (SK), 5*f*, 116–117, 237
cerebriform pattern, 120, 121*f*
comedo-like openings, 29, 29*f*, 118, 119*f*
crypts, 29

fat-fingers, 121, 121*f*
fissures, 29, 29*f*, 118, 120, 120*f*
with globule-like structures, 239
inflamed SK, 238
lichen planus–like keratosis, 238
melanoacanthoma, 238
with melanocytic-like structures, 238–239
milia-like cysts, 29, 29*f*, 117–118, 119*f*
network-like structures, 120, 120*f*
ridges, 29, 29*f*, 120
sharply demarcated borders, 121
typical hairpin blood vessels, 121, 121*f*, 122*f*
wobble test, 121
Segmental radial lines, 72
Sequential digital dermoscopic imaging (SDDI), 234, 309–311
Serpiginous vessels pattern, 67
Seven-point checklist method, 220–221, 222*t*, 224
Shiny white blotches and strands, 16, 17, 24, 28*f*
Shiny white lines, 16–17, 59, 180, 184*f*
Shiny white structures (SWS), 15–18, 19*f*, 241, 241*f*
Short-term monitoring, 309–310, 310*f*
Simple red loops, 283, 284*f*
Situ/Bowen disease, 28
Solar lentigines, 116, 117*f*, 194, 245, 246*f*
Source polarized filter, 3
Spitz nevus, 169
atypical Spitz tumors (ASTs), 171, 173
dermoscopy, 173, 173*f*
evolution, 171
nonpigmented Spitz nevus, 169, 170*f*
pigmented Spitz nevus, 169–170, 170*f*
spitzoid-looking lesions, management of, 173–174, 174*f*
spitzoid melanoma dermoscopy, 171, 172*f*
Spitzoid, 171
Spitzoid melanoma, 204–205
dermoscopic characteristics, 205, 205*f*
Spitzoid melanoma dermoscopy, 171, 172*f*
Spitzoid tumors, 169
Spitz/Reed's nevi, 81
Splinter hemorrhages, 273, 274
Spoke wheel areas, 24, 24*f*, 25*t*–26*t*
Squamous cell carcinomas (SCC), 58, 62, 277, 241–242, 243, 245*f*
SSM, *see* Superficial spreading melanoma
Starburst pattern, 56, 81
melanocytic nevi, 151–152, 152*f*
Reed nevus, 170
Strawberry pattern, 25*t*, 28, 28*f*, 192
Streaks, 12*t*, 13, 16*f*, 17*f*
String of pearls vascular pattern, 30, 30*f*
Structureless lesions, 241
Structureless melanoma, 208, 208*f*
Structureless pattern, 42
mucosal surfaces, 263, 266*f*
Subcorneal hemorrhage, 259, 261*f*
Subungual exostosis, 278
Subungual hemorrhage, 270–271, 270*f*, 271*f*, 278
Subungual hyperkeratosis, 278
Subungual melanoma (SUM), 269
Superficial basal cell carcinoma, 6
Superficial dermis, 3
Superficial spreading melanoma (SSM), 180, 190
amelanotic melanomas, 181–182, 181*f*, 182*f*
atypical dots, 180, 182*f*–184*f*
atypical globules, 180, 184*f*
atypical network, 180, 181*f*–184*f*
blue-white veil, 180, 181*f*–184*f*
dermoscopic features, 180, 185*t*
multiple colors, 180, 182*f*–184*f*
negative network, 180, 184*f*
nested melanoma, 182–183
nevus-associated melanomas, 182
peripheral light brown structureless areas, 180, 181*f*–184*f*
regression structures, 180
shiny white lines, 180, 184*f*
SWS, *see* Shiny white structures
Symmetric follicular pigmentation, 116, 118*f*
Symmetric nodular lesions, 174

T

Targetoid hemosiderotic hemangioma (THH), 129–130
dermoscopic characteristics, 130, 130*f*
Targetoid nevi
cockade nevi, 176
dermoscopic characteristics, 177, 178*f*
halo nevi, 176
dermoscopic characteristics, 176, 178*f*
Meyerson's nevi
dermoscopic characteristics, 176
TBP, *see* Total body photography
TBSE, *see* Total body skin examination
TC, *see* Tinea corporis
THH, *see* Targetoid hemosiderotic hemangioma
Thick lines reticular, 74–75, 75*f*
Three-point checklist, 86, 87*f*–88*f*, 87*t*
Tinea capitis, 291
Tinea corporis (TC), 297, 297*f*
Tinea nigra (TN), 297, 297*f*
Top-down 2-step pattern analysis, 50, 51*f*–53*f*
benign lesions, 50
acquired and small congenital nevi, 50, 54*f*–55*f*, 55–56
IDN and dermatofibroma, 56–57
seborrheic keratosis and solar lentigo, 57
equivocal lesions, 58
disorganized lesions, 58–59
organized lesions, 59
Total body photography (TBP), 234
Total body skin examination (TBSE), 224–225
Traumatized nevus, 155, 155*f*
Triage, 86
Triage algorithms
decision algorithm for pigmented lesions, 70–80
skin cancer triage, 86–89
TADA, 81–84
Triage amalgamated dermoscopic algorithm (TADA), 81, 82*f*, 89
isorganized pattern, 81, 83*f*
organized-appearing lesion manifestation, 84*f*
four colors, 81–83
two patterns, 81
two structures, 81
unequivocal seborrheic keratosis, angioma, and dermatofibroma, 81, 82*f*, 83*f*
Trichoepithelioma, 137
clinical presentation, 137–138
dermoscopic features, 137*f*, 138
differential diagnosis, 138
histopathology, 138
treatment and management, 138
Trichorrhexis invaginata, 287, 287*f*
Trichorrhexis nodosa, 287, 287*f*
Trichoscopy, 34, 34*t*, 281, 286
absence of follicular openings, 35
black dots, 34, 35*f*
blue-gray dots, 34–35, 35*f*
empty follicles, 35
follicular keratotic plugs, 35
peripilar hair casts, 35
peripilar sign, 35
pinpoint white dots, 34, 35*f*
white patches, 34, 35*f*
yellow dots, 34, 35*f*
Trichotillomania, 289–290, 290*f*
Trizonal concentric pattern, 303
Tumors of hair follicle, 136, 136*t*
pilomatricoma, 136
clinical presentation, 136
dermoscopic features, 137, 137*f*
differential diagnosis, 137
histopathology, 137
treatment and management, 137
trichoepithelioma, 137
clinical presentation, 137–138
dermoscopic features, 137*f*, 138
differential diagnosis, 138
histopathology, 138
treatment and management, 138
Tungiasis, 296–297
Twisted red loops, 284, 285*f*
Two-component nevi, 152
Tyndall effect, 253, 254*f*
Typical/regular pigment network, 11

U

Ugly duckling, 230
Ulcerations, 24, 26*f*, 81
Ultraviolet radiation, 155
Unna nevus, 158–159, 160*f*
dermoscopic characteristics, 159, 160*f*–162*f*, 163
Urticaria, 306, 306*f*
Urticarial vasculitis, 306, 306*f*

V

Vascular features, AK
combinations of features, 105, 105*f*, 106*f*
dotted vessels, 105, 105*f*
hairpin vessels with white halo, 105, 105*f*
linear wavy vessels, 102, 104*f*
pink-red pseudonetwork, 102, 104*f*
Vascular lesions, 125
Vascular malformations, 127
dermoscopic characteristics, 127*f*
Vascular pattern, epidermotropic (skin) metastasis, 208
Vascular structures, 91
Vellus hairs, 297, 297*f*
Verruca vulgaris, 294
Verrucous melanoma, 205–206, 206*f*
Vessels, 81
arrangements, 65
types, 65
Viral diseases
cutaneous warts, 294, 296*f*

molluscum contagiosum (MC), 294, 295*f*
Volar skin, 19, 21–22, 22*f*
anatomy of, 253, 254*f*
malignant dermoscopy pattern, 259

W

Wallace line, 253
Warts, 32, 279
White circles, 25*t*, 28
White diffuse scaling, 285, 285*f*
White dots, 283, 283*f*
White globules, 11
White lines, 49, 76, 76*f*, 77*f*
White network, 169
White network appearance, 90
White patches, 34, 35*f*
White perifollicular scaling, 285, 286*f*
White shiny structures, 4
White/yellow amorphous structures, 32, 33*f*
Wickham striae (WS), 301, 301*f*
Wreath vessels, 243
WS, *see* Wickham striae

Y

Yellow crusts/scales, 32
Yellow dots, 34, 35*f*, 281–282, 282*f*, 289, 290*f*
Yellowish tubular scaling, 285, 286*f*
Yellow spot, 274