

# Amyloidosis cutis dyschromica

Swetha S. Kurian, Reena Rai, Subbarao Tadury Madhukar<sup>1</sup>

Departments of Dermatology, Venereology and Leprology, <sup>1</sup>Pathology, PSG Institute of Medical Sciences and Research (PSG IMSR), Coimbatore, Tamil Nadu, India

## ABSTRACT

Amyloidosis cutis dyschromica is a very rare form of primary cutaneous amyloidosis characterized by prepubertal onset of hyper and hypopigmented spots and amyloid deposits in the papillary dermis. We report a case of a 26 year old female with amyloidosis cutis dyschromica who presented with dyschromic skin since birth.

**Key words:** Amyloidosis, dyschromica, genetic

## INTRODUCTION

Amyloidosis cutis dyschromica (ACD) is a very rare form of primary cutaneous amyloidosis (PCA) with very few cases reported in literature.<sup>[1,2]</sup> PCA is a rare chronic progressive disease with deposition of amyloid in the skin without systemic involvement. ACD was first defined by Morishima in 1970.<sup>[3]</sup> It is characterized by hyper and hypopigmented spots, prepubertal onset and amyloid deposits in papillary dermis. We report a case of ACD in which the patient presented with dyschromic skin since birth and positive family history.

## CASE REPORT

A 26-year-old female presented with hyperpigmentation of skin since birth and progressively developed, hypo- and de-pigmented spotty macules over the extremities and trunk during childhood. She was born to parents of second-degree consanguineous marriage, with history of similar skin lesions in maternal uncle. Patient did not give any history of photosensitivity, blistering, itching or developmental delay.

General physical examination was normal. Cutaneous examination revealed diffuse hyperpigmentation with mottled spotty, well-defined, de-pigmented and hypopigmented macules ranging from pinpoint to 2 × 2 cm in size. Some of the de-pigmented macules were atrophic [Figure 1]. Her face and abdomen was relatively spared with involvement of the extremities. Hair, teeth, nails and oral mucosa were normal. Ophthalmology and ENT assessments were normal. Systemic examination was unremarkable.

Histopathology of hypopigmented lesion showed atrophic epidermis with loss of rete ridges. The upper dermis revealed eosinophilic extracellular nodular deposits and mild perivascular aggregates of chronic inflammatory cells, of which lymphocytes predominate [Figure 2]. These eosinophilic deposits stained brick red with Congo Red stain [Figure 3].

Histopathology of the hyperpigmented lesion also showed eosinophilic deposits that stained brick red with Congo Red.

All other routine investigations were within normal limits.

With these findings, a diagnosis of ACD was made.

## DISCUSSION

ACD is a very rare variant of PCD, first defined by Morishima in 1970.<sup>[3]</sup> It is characterized by i) mottled hyper- and hypo-pigmentation ii) little or no itching iii) pre-pubertal onset and iv) amyloid deposits below epidermis.<sup>[3,4]</sup>

ACD must be differentiated from other causes of dyschromica including dyschromatosis universalis hereditaria, xeroderma pigmentosum and poikiloderma-like amyloidosis.<sup>[3-7]</sup> The former two conditions do not exhibit amyloid deposits in skin. The latter shows a similar clinical cutaneous picture as ACD but with additional features such as poikilodermic lesions, lichenoid papules, blisters, photosensitivity, short stature and palmo-plantar keratoderma.<sup>[1]</sup>

Access this article online

Website: [www.idoj.in](http://www.idoj.in)

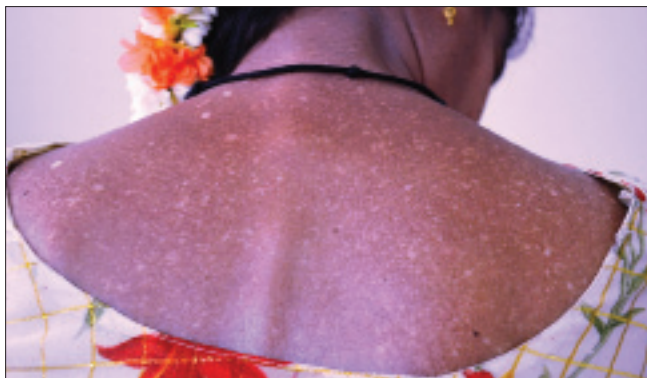DOI: 10.4103/2229-5178.120678

Quick Response Code:

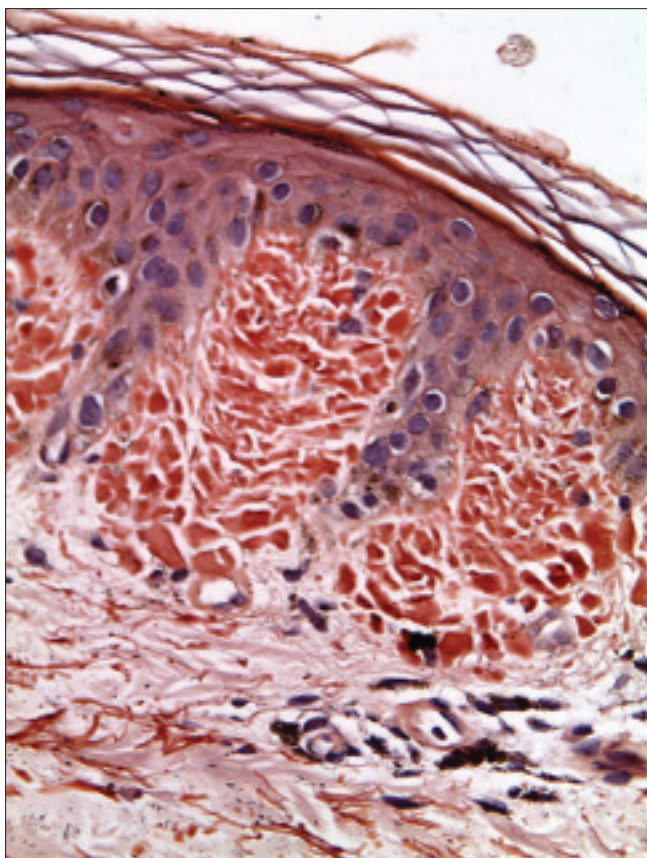


### Address for correspondence:

Dr. Reena Rai,  
Department of Dermatology,  
PSG Institute of Medical Sciences and Research (PSG IMSR), Peelamedu, Coimbatore, Tamil Nadu, India.  
E-mail: [drreena\\_rai@yahoo.co.in](mailto:drreena_rai@yahoo.co.in)



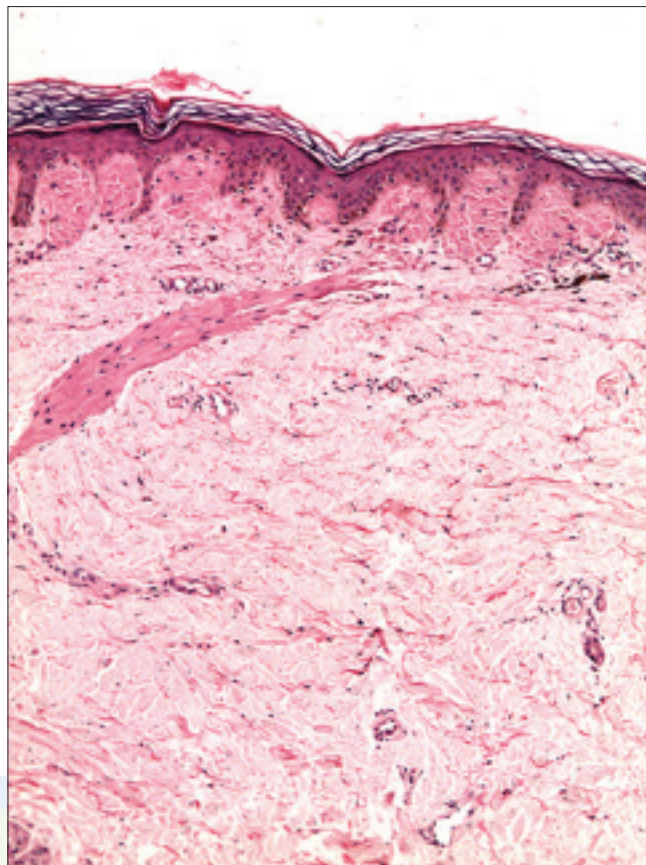
**Figure 1:** Multiple hypopigmented and depigmented macules over upper back with few atrophic lesions on left shoulder



**Figure 3:** Deposits showing positive reaction with Congo Red (×400)

The cause of ACD is unknown but genetic factors and sun exposure have been implicated. It has been proposed that genetic factors cause prolonged DNA repair in keratinocytes following UV damage.<sup>[2,4,8]</sup> The source of amyloid is unclear.<sup>[9]</sup> A possible cause may be phagocytosis of damaged keratinocytes by histiocytes or fibroblasts that produce amyloid material in the skin.<sup>[6,10,11]</sup> Keratinocyte destruction may lead to amyloid deposits derived from cytokeratin.<sup>[12]</sup>

Various modes of treatment have been used with variable results. Sun avoidance and protection, topical corticosteroids,



**Figure 2:** Eosinophilic globular deposits of amyloid in papillary dermis (H and E, ×100)

keratolytics, dimethyl sulfoxide, capsaicin, and carbon dioxide laser have been tried.<sup>[13]</sup> However, systemic acitretin has been reported to have good response.<sup>[14]</sup>

This case differs from most other cases reported in literature due to presence of lesions since birth and atrophic depigmented macules, although one case of atrophic depigmentation has been reported.<sup>[1]</sup>

## REFERENCES

1. Yang W, Lin Y, Yang J, Lin W. Amyloidosis cutis dyschromica in two female siblings: Cases report. *BMC Dermatol* 2011;11:4.
2. Vijaikumar M, Thappa DM. Amyloidosis cutis dyschromica in two siblings. *Clin Exp Dermatol* 2001;26:674-6.
3. Morishima T. A clinical variety of localized cutaneous amyloidosis characterized by dyschromia (amyloidosis cutis dyschromica). *Jpn J Dermatol Series B* 1970;80:43-52.
4. Moriwaki S, Nishigori C, Horiguchi Y, Imamura S, Toda K, Takebe H. Amyloidosis cutis dyschromica: DNA repair reduction in the cellular response to UV light. *Arch Dermatol* 1992;128:966-70.
5. Wu CY, Huang WH. Two Taiwanese siblings with dyschromatosis universalis hereditaria. *Clin Exp Dermatol* 2009;34:e666-9.
6. Ogino A, Tanaka S. Poikiloderma-like cutaneous amyloidosis. Report of a case and review of the literature. *Dermatologica* 1977;155:301-9.
7. Ho MH, Chong LY. Poikiloderma-like cutaneous amyloidosis in an ethnic Chinese girl. *J Dermatol* 1998;25:730-4.
8. Choonhakarn C, Wittayachanyapong S. Familial amyloidosis cutis

Kurian, *et al.*: Amyloidosis cutis dyschromica

- dyschromica: Six cases from three families. *J Dermatol* 2002;29:439-42.
9. Wang WJ, Chang YT, Huang CY, Lee DD. Clinical and histopathological characteristics of primary cutaneous amyloidosis in 794 Chinese patients. *Zhonghua Yi Xue Za Zhi (Taipei)* 2001;64:101-7.
  10. Tan T. Epidemiology of primary cutaneous amyloidosis in southeast Asia. *Clin Dermatol* 1990;8:20-4.
  11. Ortiz-Romero PL, Ballestin-Carcavilla C, Lopez-Estebarez JL, Iglesias-Diez L. Clinicopathologic and immunohistochemical studies on lichen amyloidosis and macular amyloidosis. *Arch Dermatol* 1994;130:1559-60.
  12. Chang YT, Wong CK, Chow KC, Tsai CH. Apoptosis in primary cutaneous amyloidosis. *Br J Dermatol* 1999;140:210-5.
  13. Ozkaya-Bayazit E, Kavak A, Gungor H, Ozamagon G. Intermittent use of topical dimethyl sulfoxide in macular and papular amyloidosis. *Int J Dermatol* 1998;37:949-54.
  14. Ozcan A, Senol M, Aydin NE, Karaca S. Amyloidosis cutis dyschromica: A case treated with acitretin. *J Dermatol* 2005;32:474-7.

**Cite this article as:** Kurian SS, Rai R, Madhukar ST. Amyloidosis cutis dyschromica. *Indian Dermatol Online J* 2013;4:344-6.

**Source of Support:** Nil, **Conflict of Interest:** None declared.

